



衛生福利部雙和醫院
(委託臺北醫學大學興建經營)
Taipei Medical University · Shuang Ho Hospital,
Ministry of Health and Welfare



MSK & Soft tissue US in ER 骨骼肌肉軟組織急症之應用

急診進階超音波

陳國智醫師 雙和醫院急診醫學科

juice119@gmail.com

POCUSacademy.com

陳國智 醫師 / POCUSacademy.com



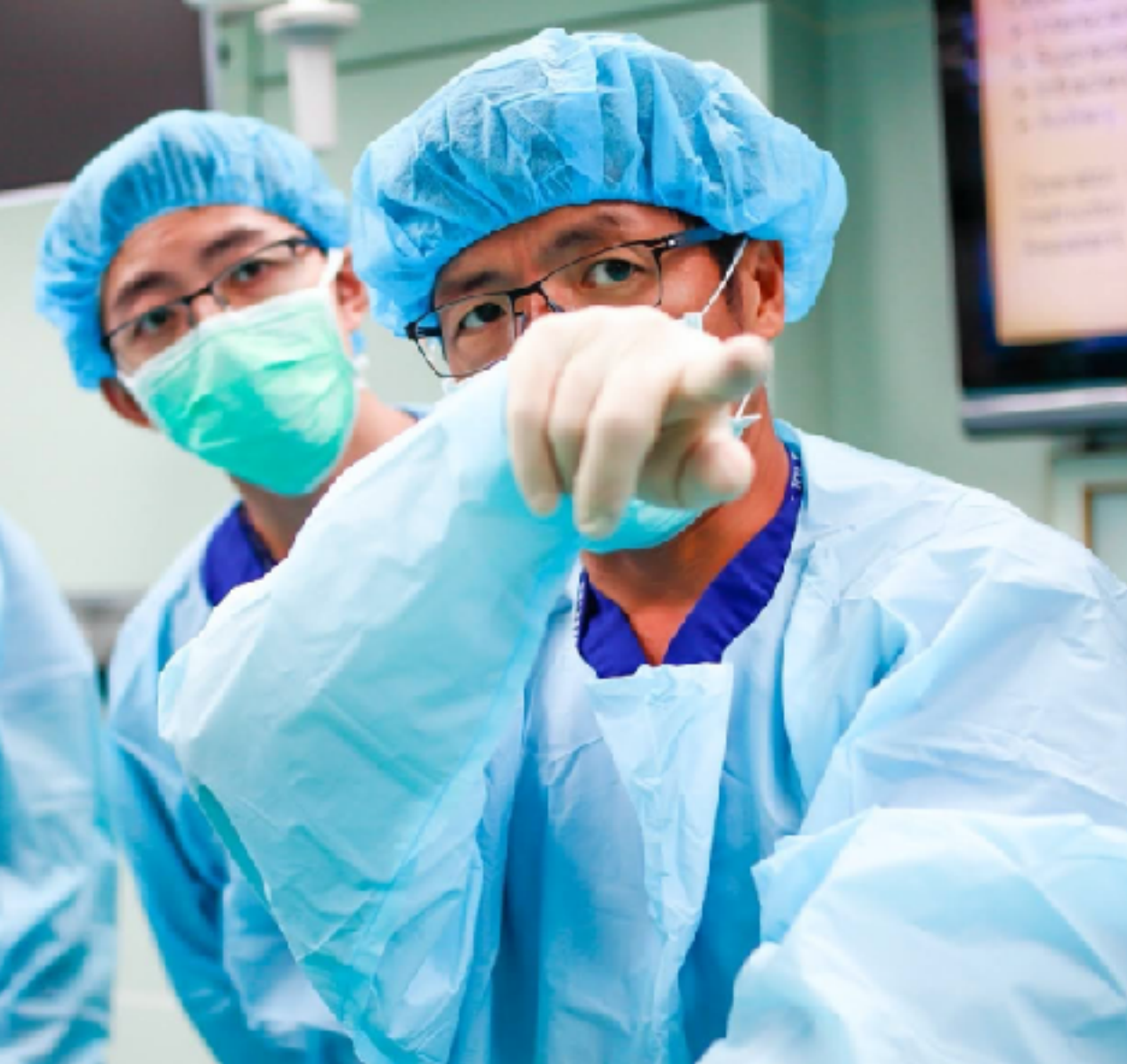台灣疼痛醫學會專科醫師
急診超音波臨床評核醫師
醫用超音波學會指導醫師
WINFOCUS director / instructor
Certified Interventional Pain Sonologist

急診 / 重症 / 介入 / 急性疼痛

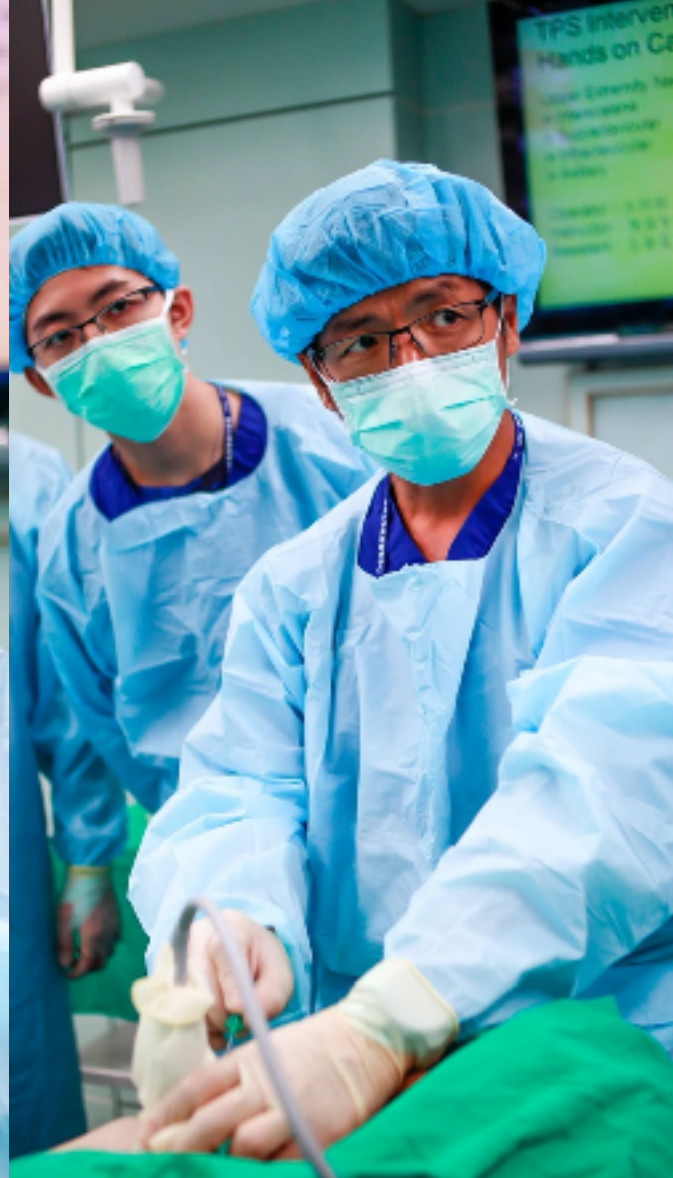經歷

新光急診超音波訓練中心主任
西園醫院急診醫學科主任
急診醫學會超音波委員會主委
台灣疼痛醫學會大體模擬手術講師
急救加護醫學會重症超音波負責人

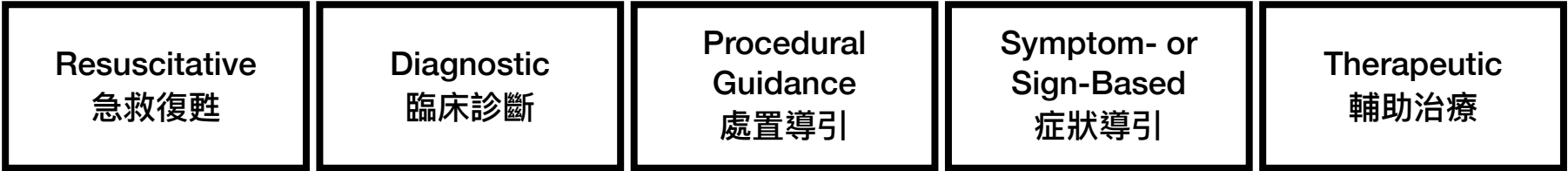juice119@gmail.com



Diagnostician



Interventionist



Core Applications (2023 ACEP Emergency Ultrasound Guidelines)
15項急診超音波核心應用

陳國智醫師

Aorta

DVT

Trauma

Thoracic/Airway

Cardia/HD assessment

Procedural Guidance

US-guided NB

Testicular

Ocular

Skin & Soft tissue

Hepatobiliary

Urinary tract

Pregnancy

Bowel

MSK

REVIEW

Open Access



An overview of point-of-care ultrasound for soft tissue and musculoskeletal applications in the emergency department

Kuo-Chih Chen^{1,2}, Aning Chor-Ming Lin^{3,2*}, Chee-Fah Chong^{1,2} and Tzong-Luen Wang^{1,2}

Musculoskeletal Ultrasound in the Emergency Department

Vito Chianca, MD¹ Francesco Di Pietto, MD, PhD² Marcello Zappia, MD, PhD³
Domenico Albano, MD^{1,4} Carmelo Messina, MD^{1,5} Luca Maria Sconfienza, MD, PhD^{1,5}

¹IRCCS Istituto Ortopedico Galeazzi, Milano, Italy

²Dipartimento di Diagnostica per immagini, Pineta Grande Hospital, Castel Volturno (CE), Italy

³Department of Medicine and Health Sciences, Università del Molise, Campobasso, Italy

⁴Section of Radiological Sciences, Department of Biomedicine, Neurosciences and Advanced Diagnostics, University of Palermo, Palermo, Italy

⁵Dipartimento di Scienze Biomediche per la Salute, Università degli Studi di Milano, Milano, Italy

Semin Musculoskelet Radiol 2020;24:167–174.



Address for correspondence: Vito Chianca, MD, IRCCS Istituto Ortopedico Galeazzi, via Riccardo Galeazzi 4, 20161 Milano, Italy (e-mail: vitochianca@gmail.com).

Soft tissue infection
Joint effusion
Foreign body
Long bone fracture
Muscle & Tendon injury
Vascular occlusion
Procedures



Seminars in
ROENTGENOLOGY

Musculoskeletal Ultrasound in the Emergency Department: Is There a Role?

Michael V. Perone, MD, and Corrie M. Yablon, MD <https://doi.org/10.1053/j.ro.2020.09.004>

Skin, Soft Tissue, and Musculoskeletal Ultrasound



Amy Marks, MD^{a,*}, Evelyn Schraft, MD^a, Michael Gottlieb, MD^a

KEYWORDS

- Ultrasound • Skin • Soft tissue • Cellulitis • Abscess • Musculoskeletal
- Arthrocentesis

KEY POINTS

- Point-of-care ultrasound (POCUS) is an efficient and easy tool to assist in the diagnosis of skin, soft tissue, and musculoskeletal conditions at the bedside.
- POCUS may be used for the evaluation of cellulitis, abscess, necrotizing fasciitis, foreign bodies, and hematomas.
- POCUS may also be used to assist in procedures, such as foreign body removal, hematoma blocks, and arthrocentesis as well as in the evaluation of musculoskeletal complaints including fractures, dislocations, and tendon ruptures.

解剖

Anatomy

形態

Pattern

診斷

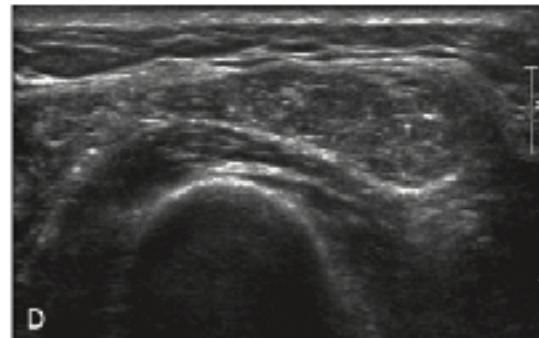
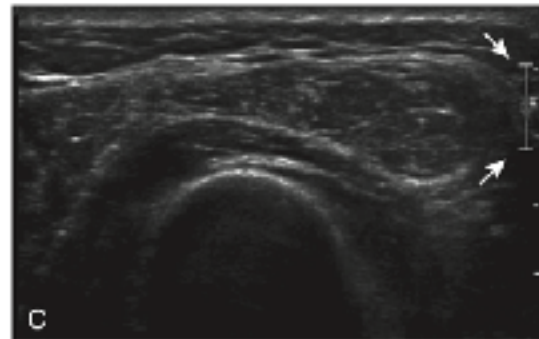
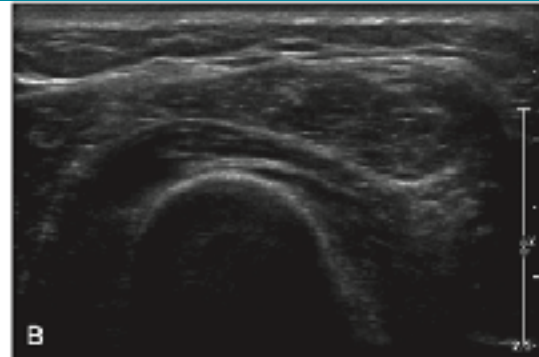
Diagnosis

HOLISTIC ULTRASOUND

Holistic medicine

Treatment that deal with the whole person,
not just the injury or disease

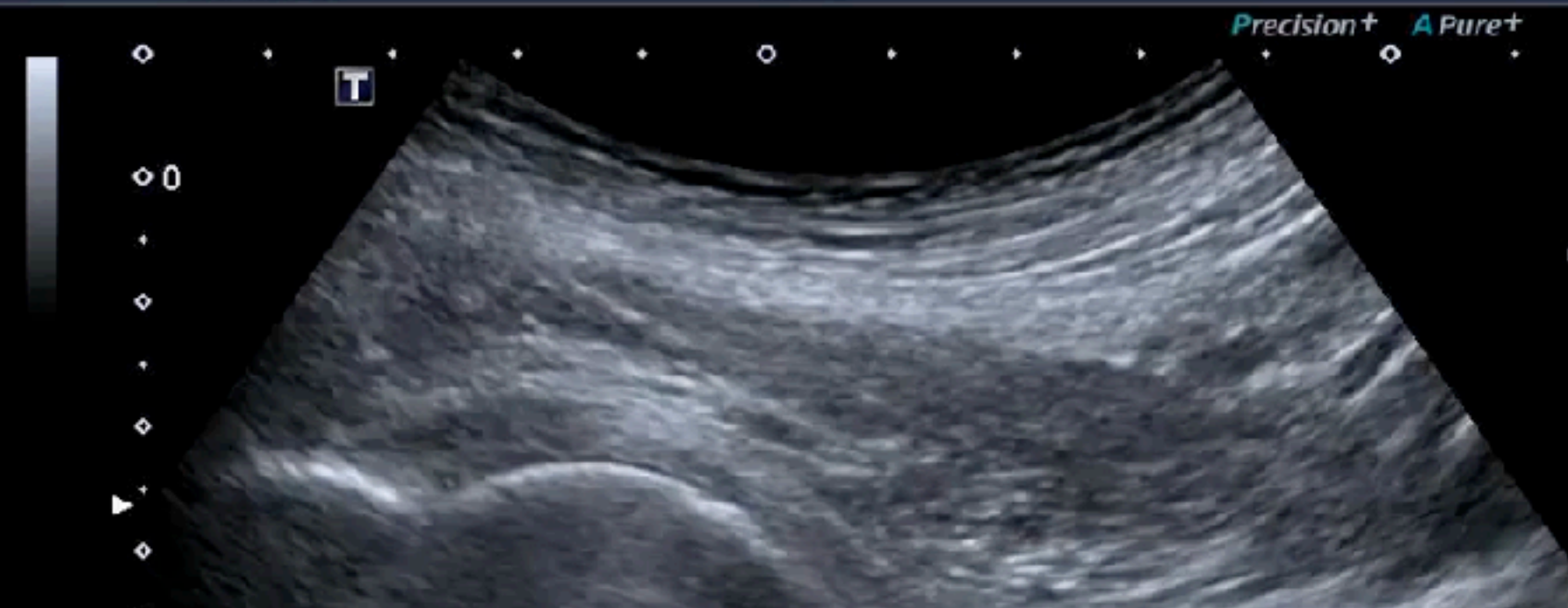優化影像三大手法



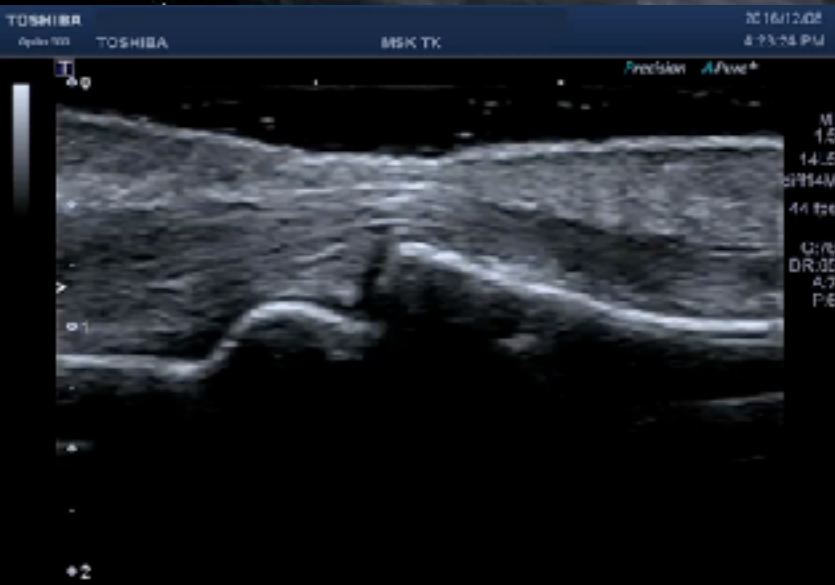深度/Depth

焦點/Focus

亮度/Gain



MI 1.5
6C1
diffT5.0
14 fps
G:80
DR:65
A:6
P:7



**Steady hand
Window
Sono-anatomy**



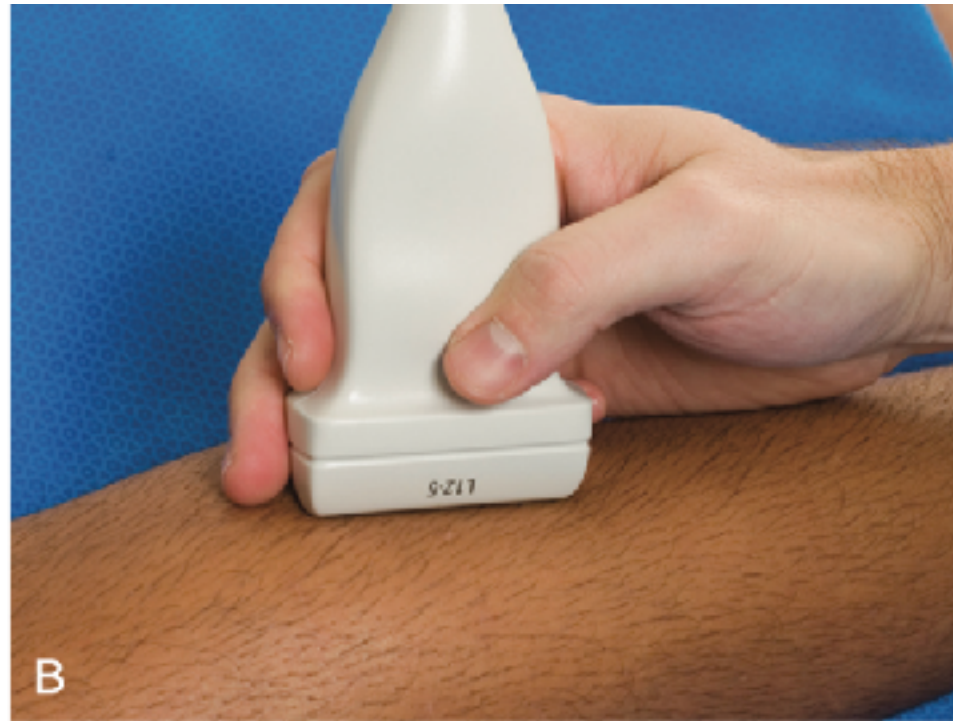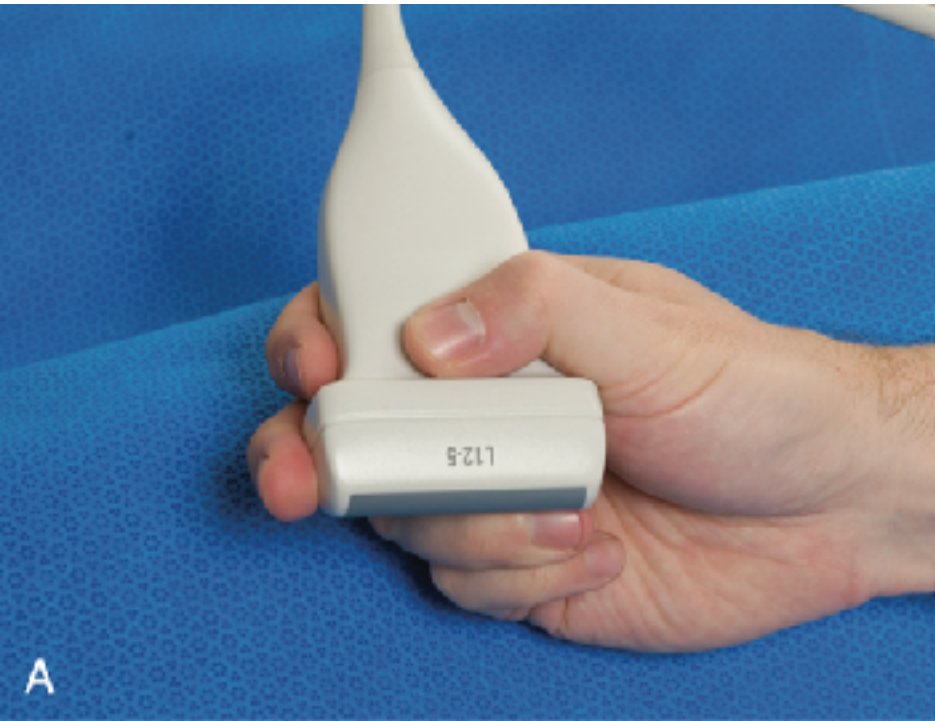Steady Hand



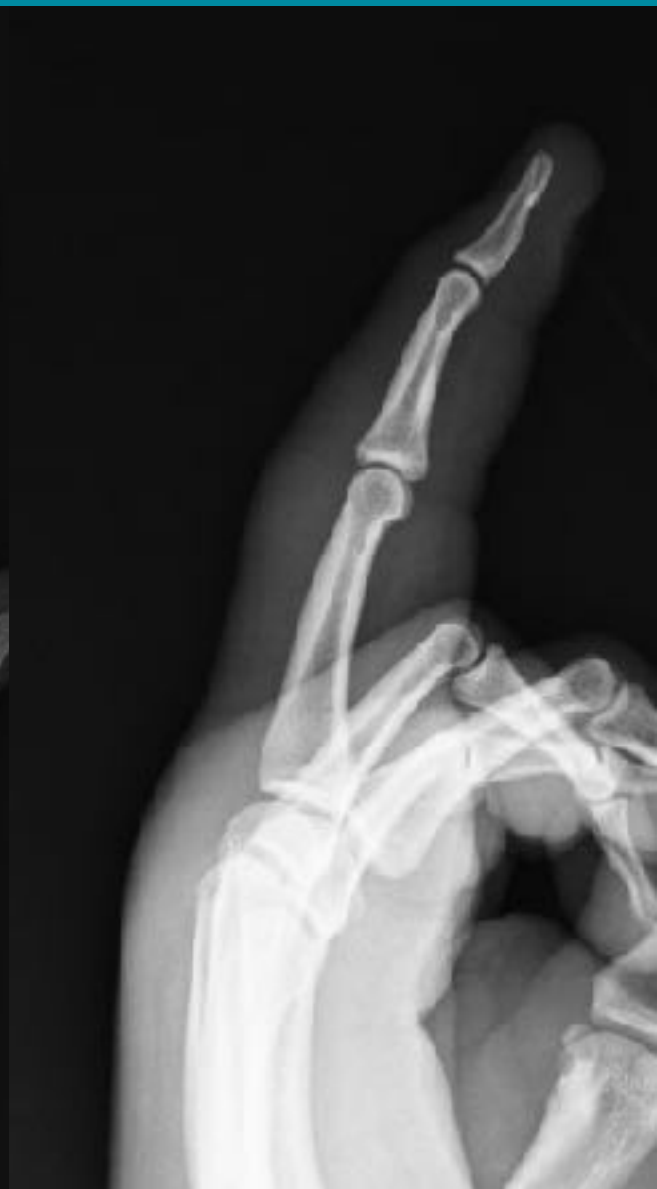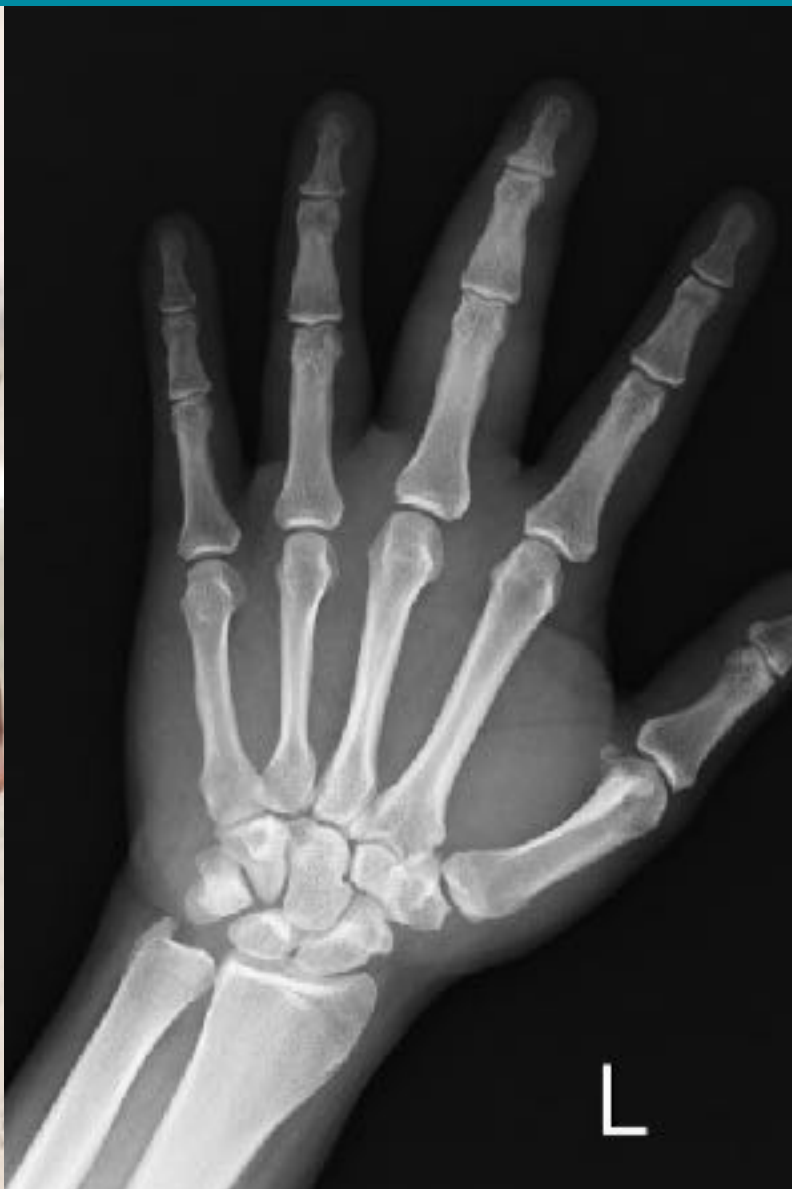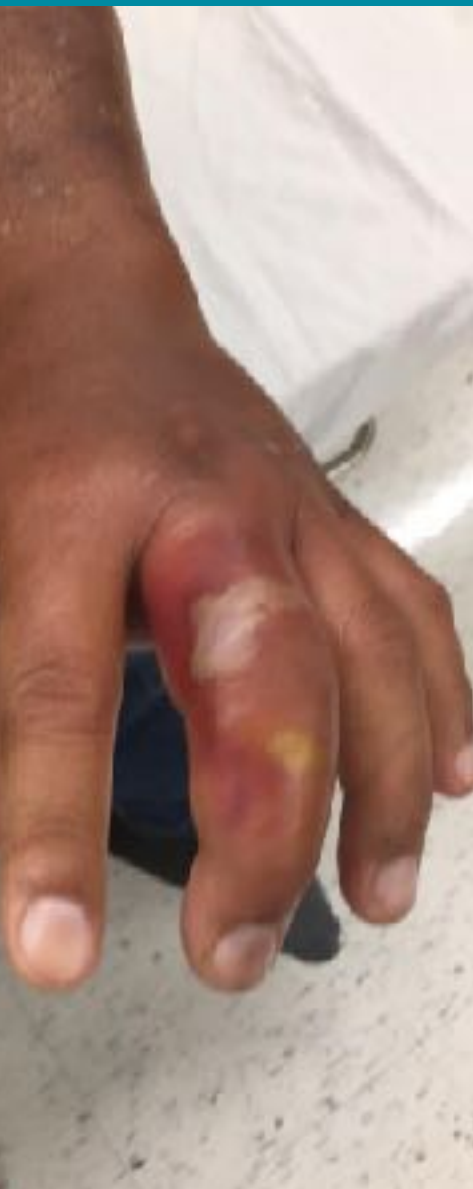探頭

操作者的手

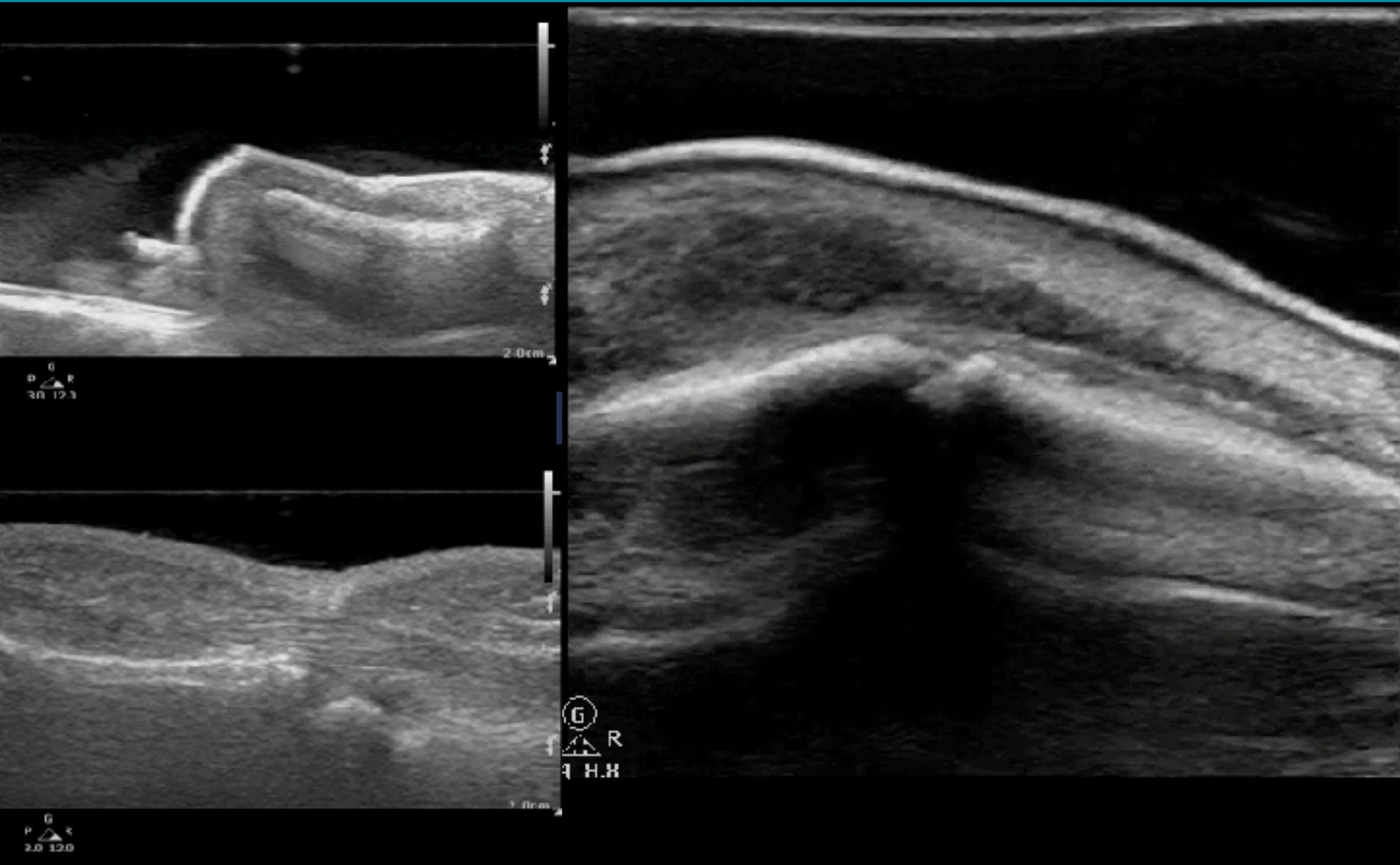
皮膚



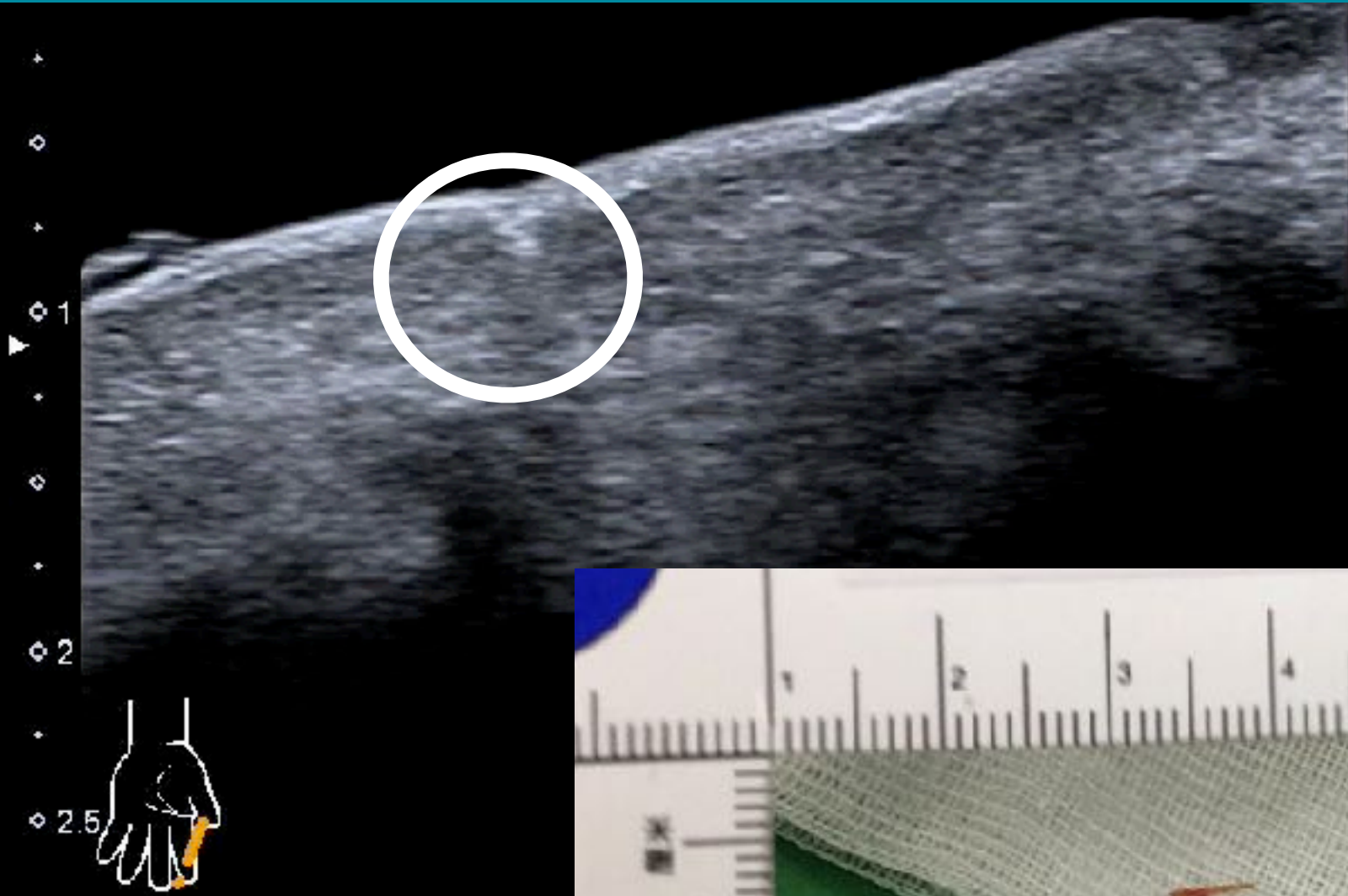
左手中指腫痛




Water bath method



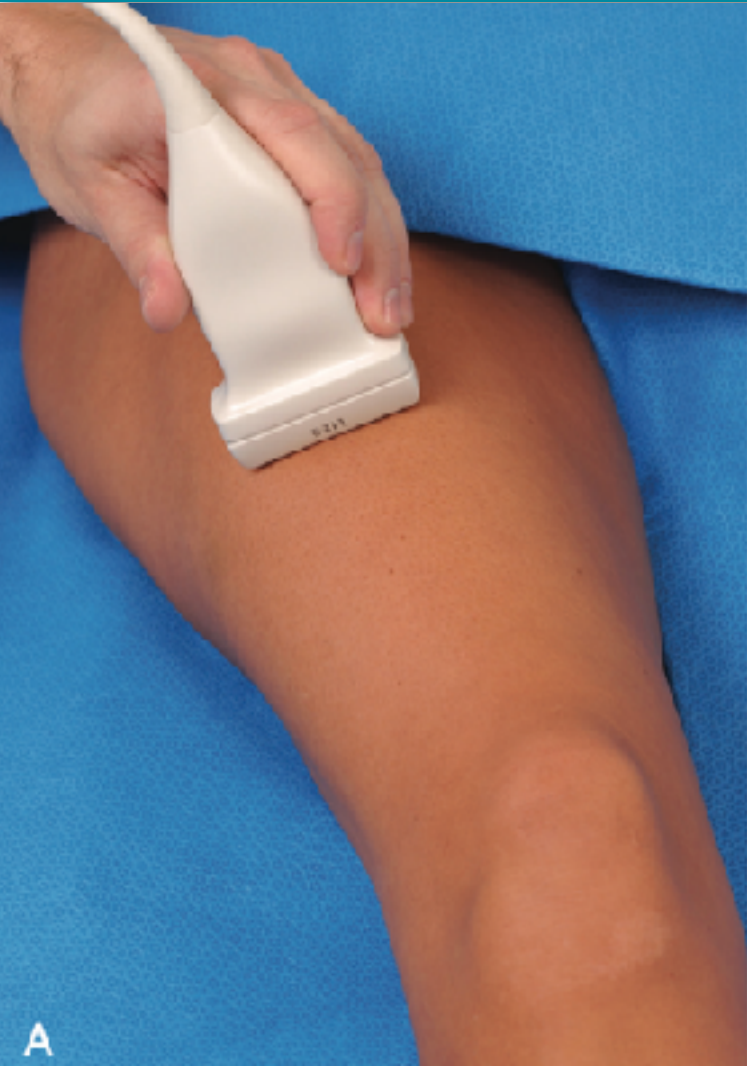Create window



M
1.5
11L4
diffT9.0
30 fps
G:86
DR:60
A:6
P:3



MSK掃描原則

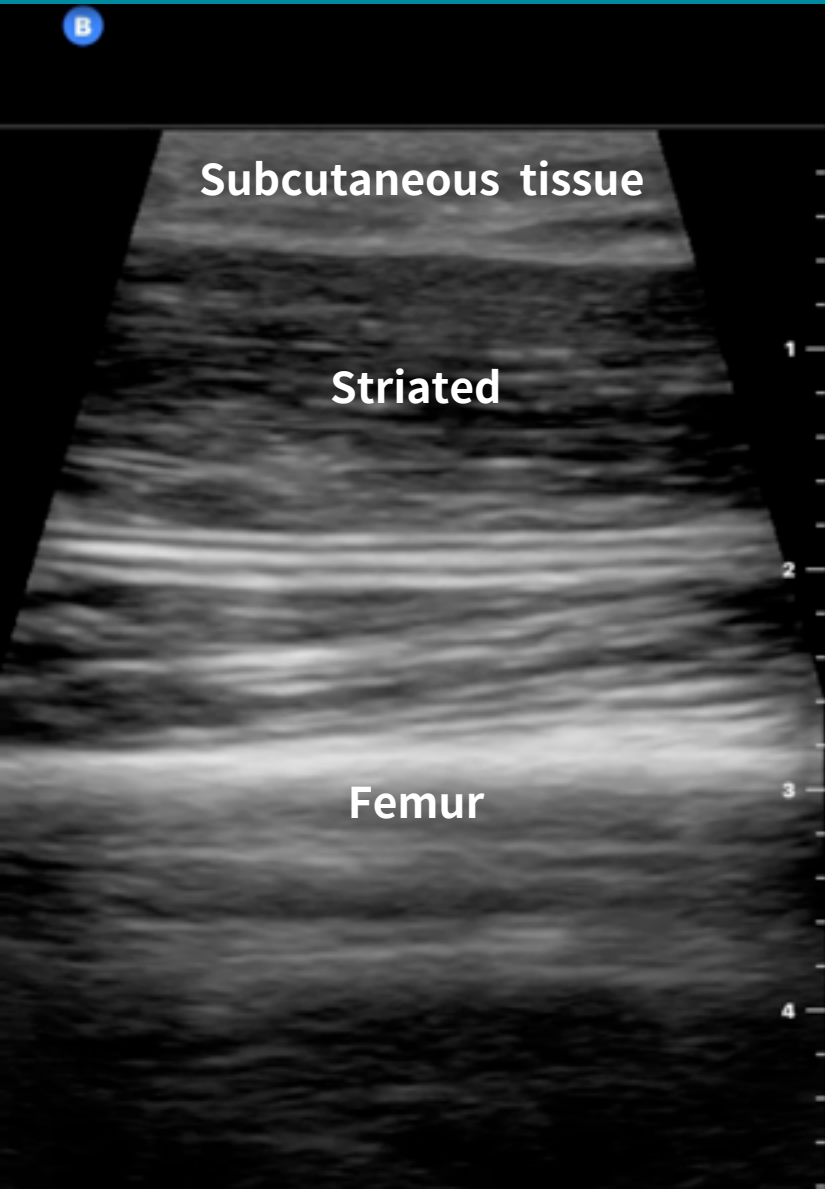


管狀構造橫掃優先

先找外在明顯定位

確認內在明顯標的

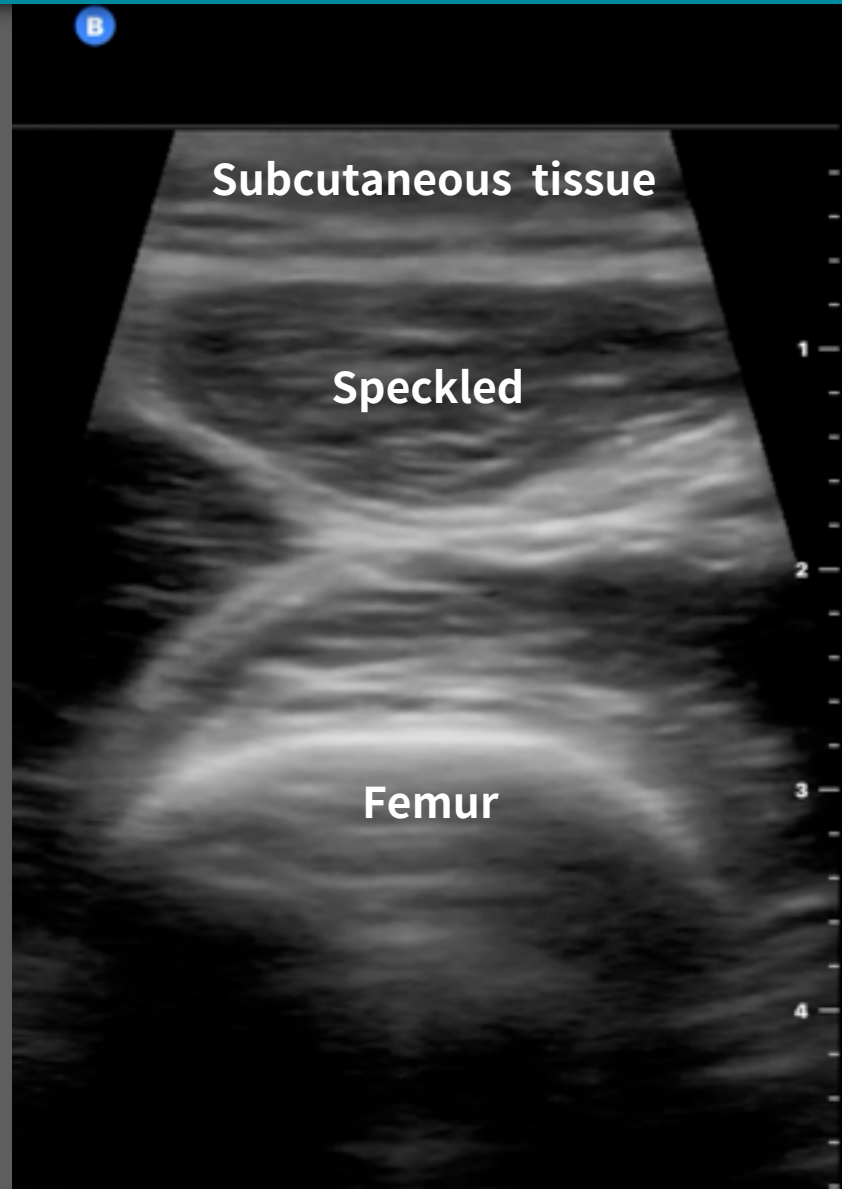
MSK的重要三界線(白線)



皮膚

筋膜

骨頭

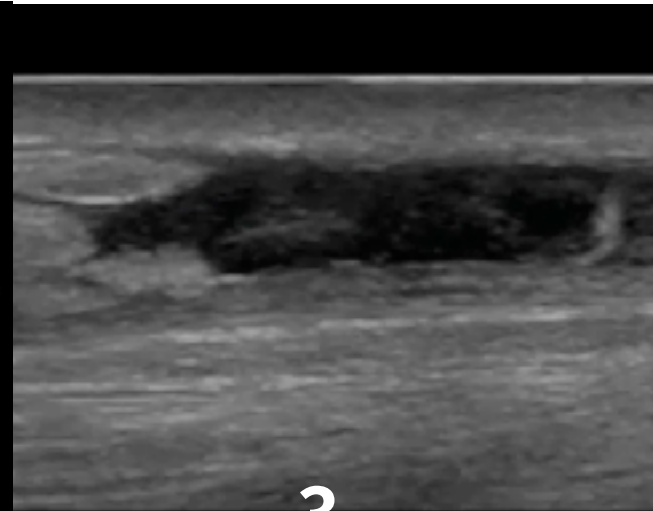
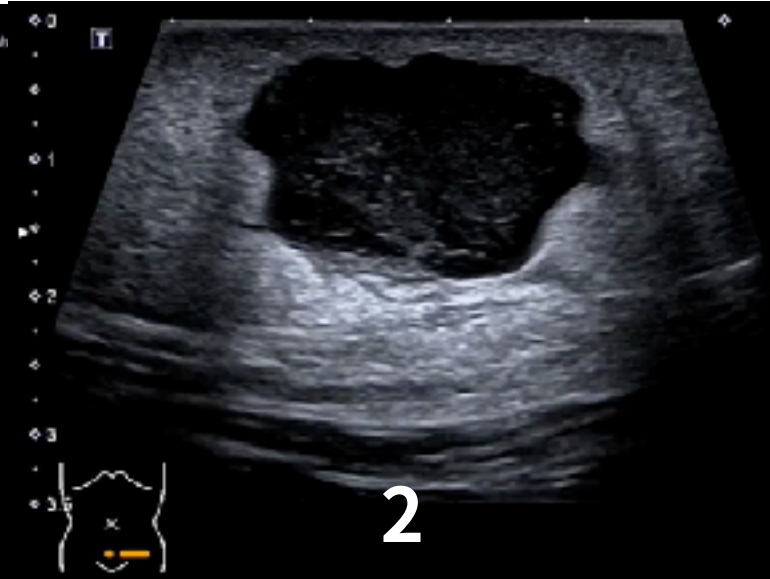
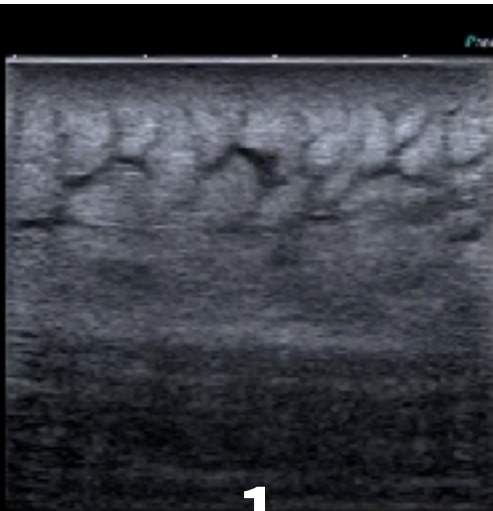

軟組織感染症

蜂窩性組織炎

膿瘍

壞死性筋膜炎



Cobblestone

Collection

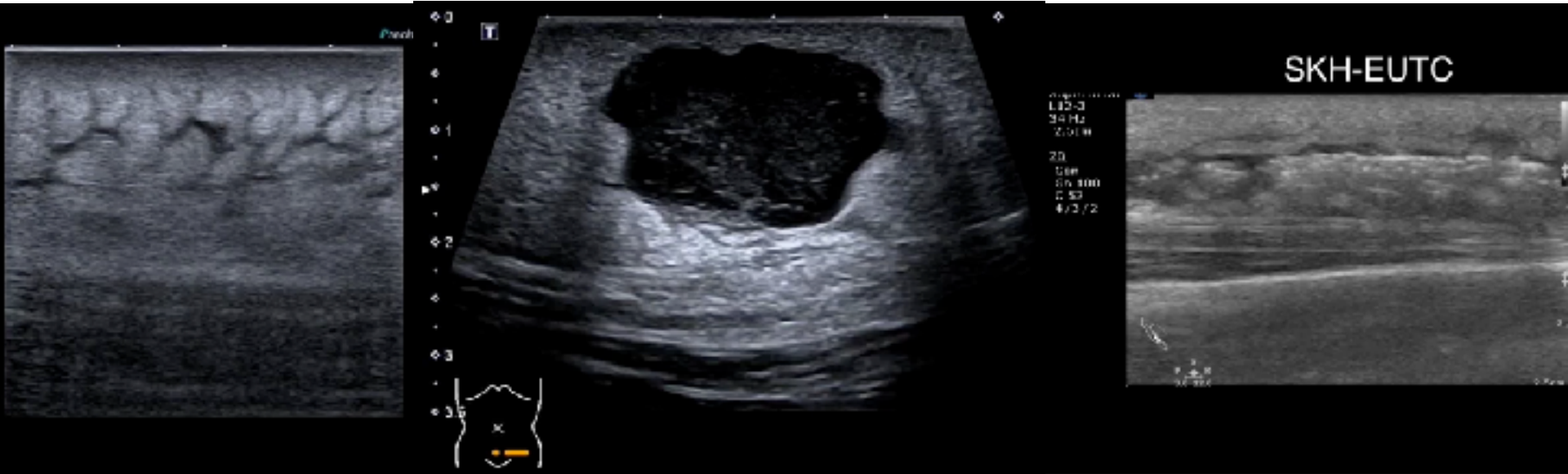Fascial fluid >4mm

軟組織感染症

蜂窩性組織炎

膿瘍

壞死性筋膜炎

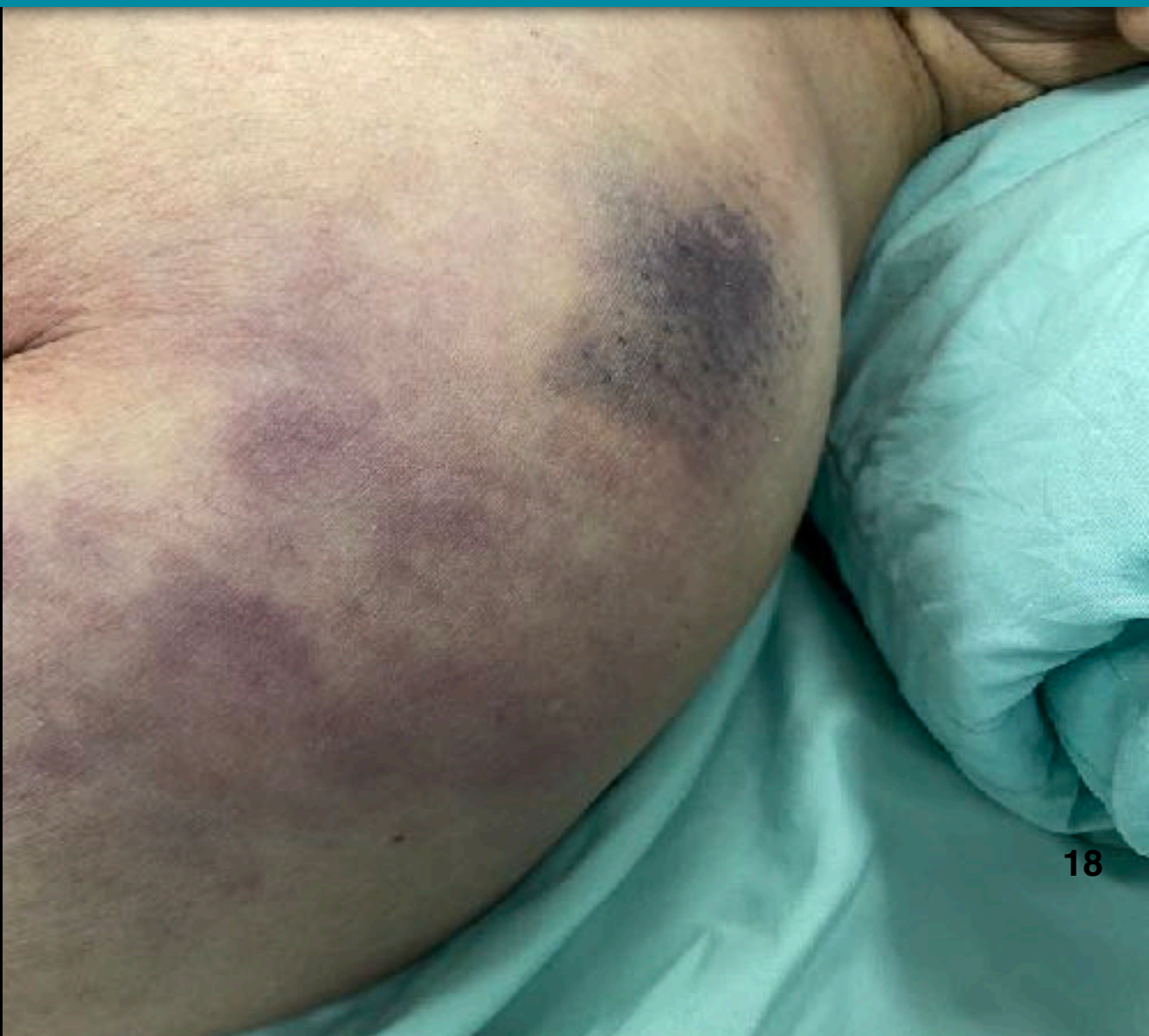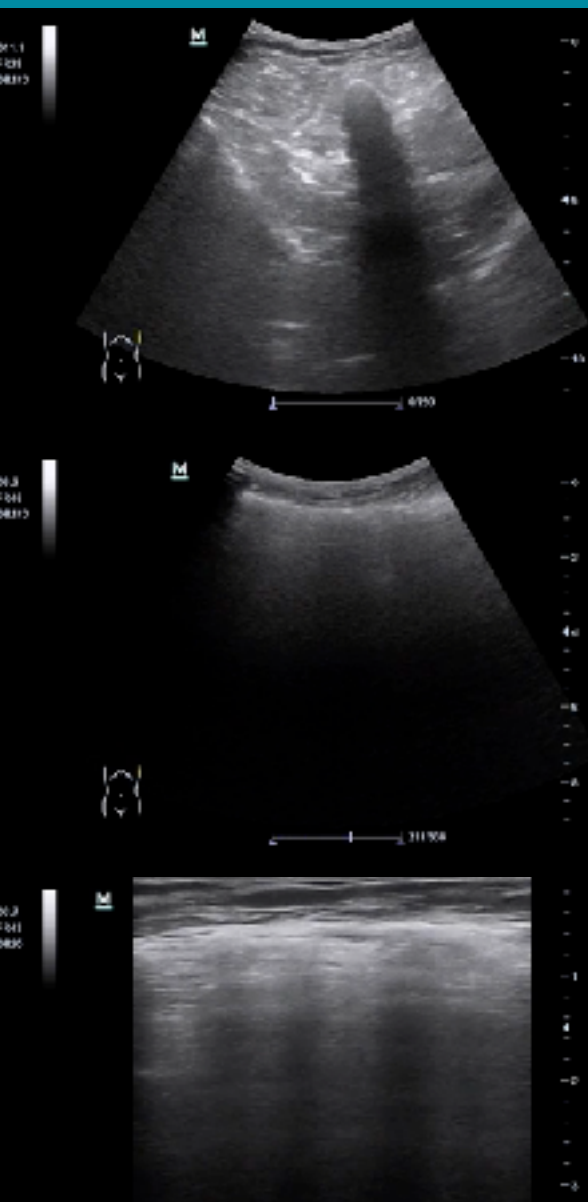


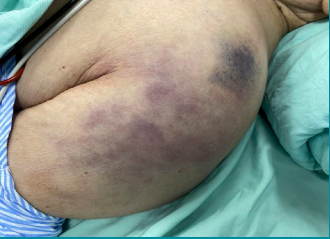Cobblestone

Collection

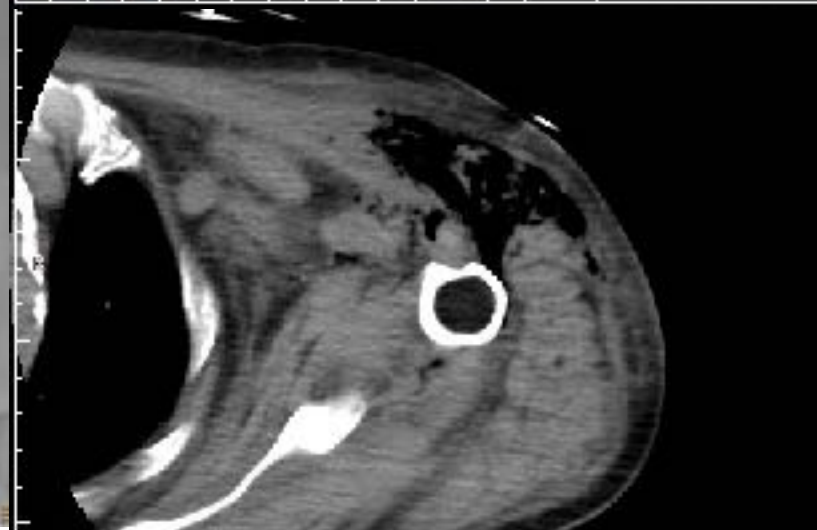
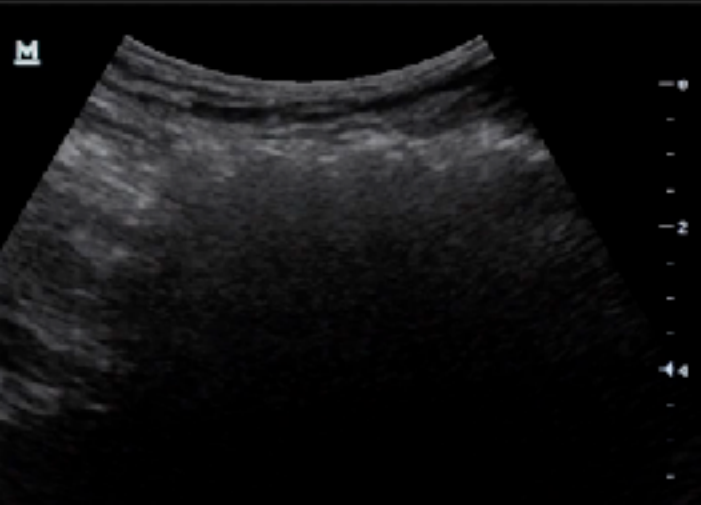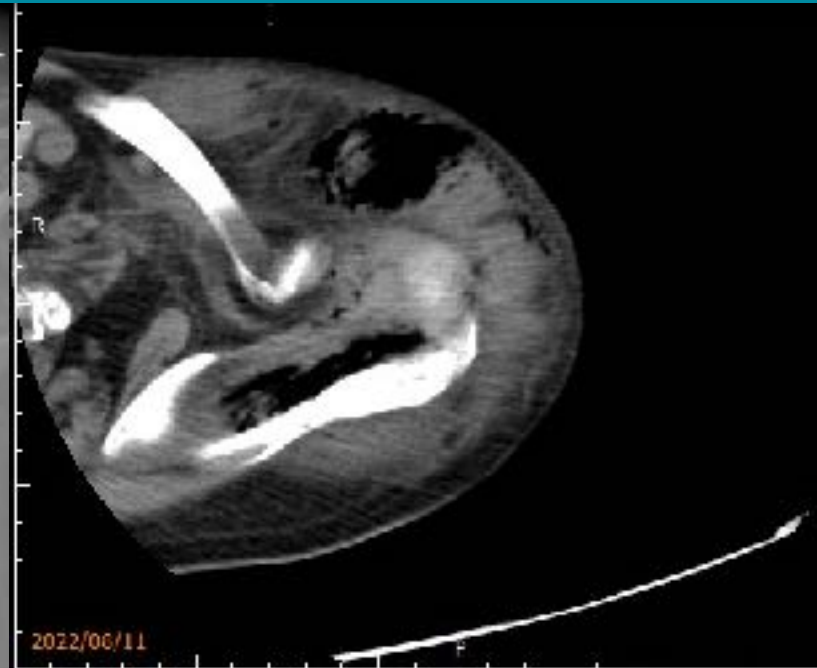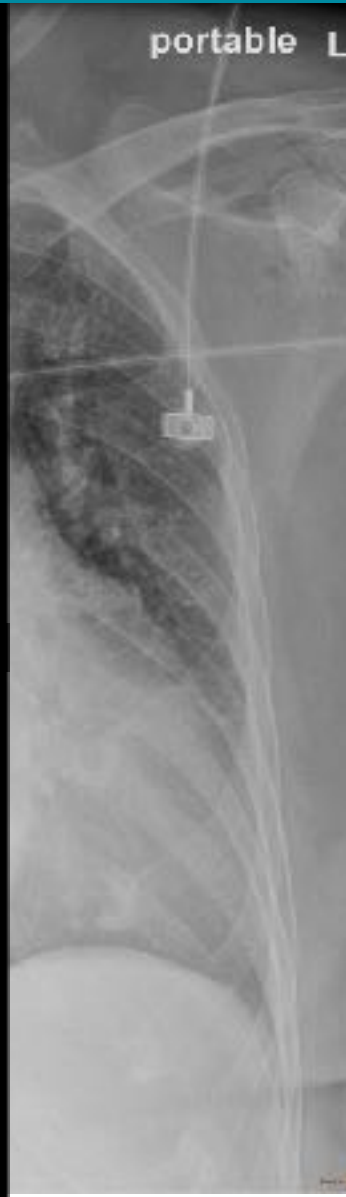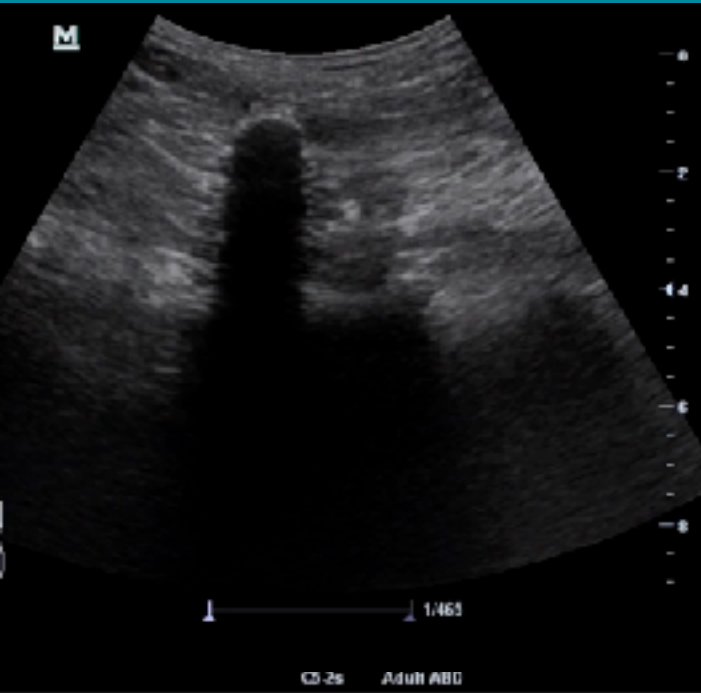
Subcutaneous
Thickening
Air
Fascial
Fluid

83F，前天跌倒，左手痛，BP 69/43

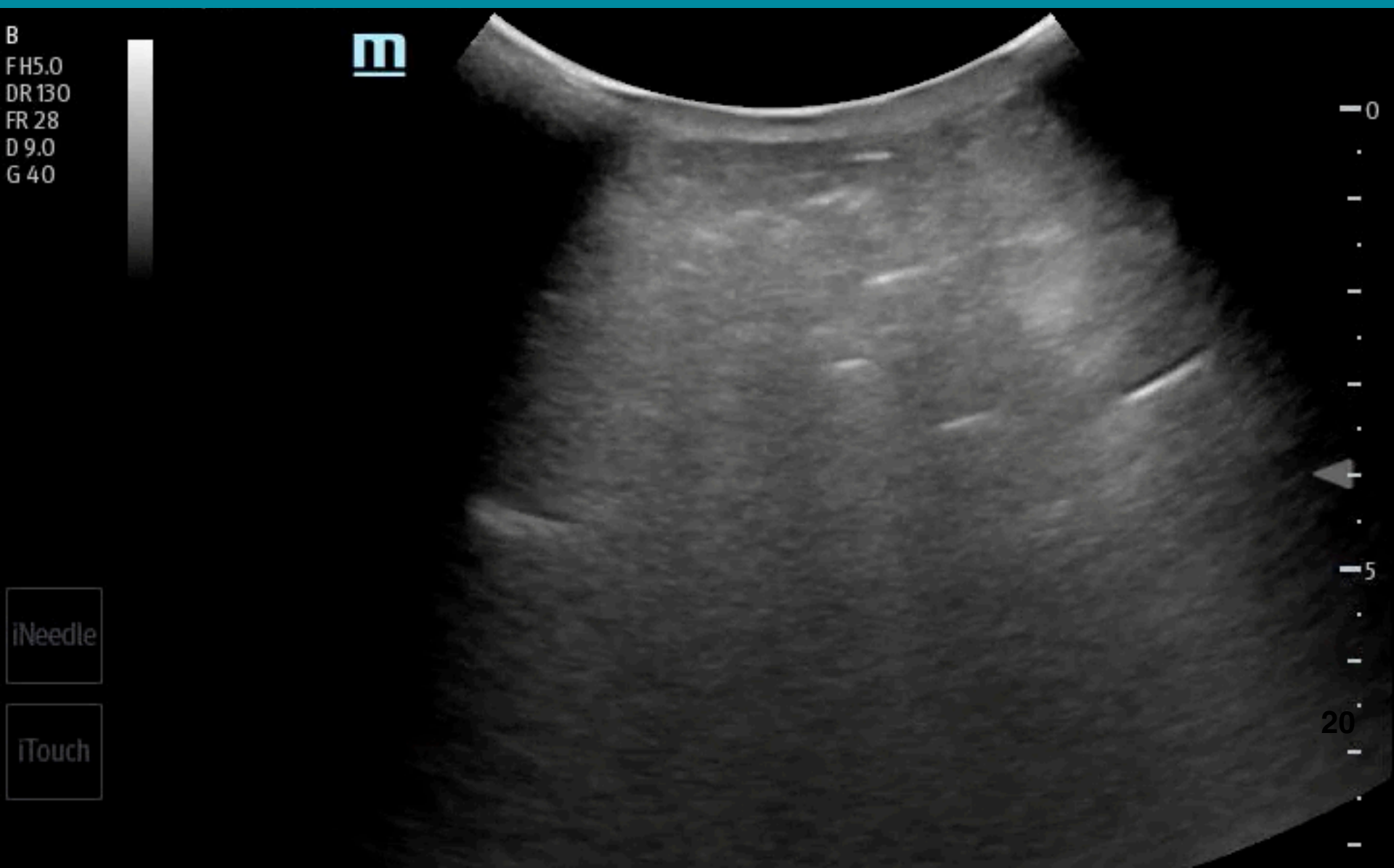




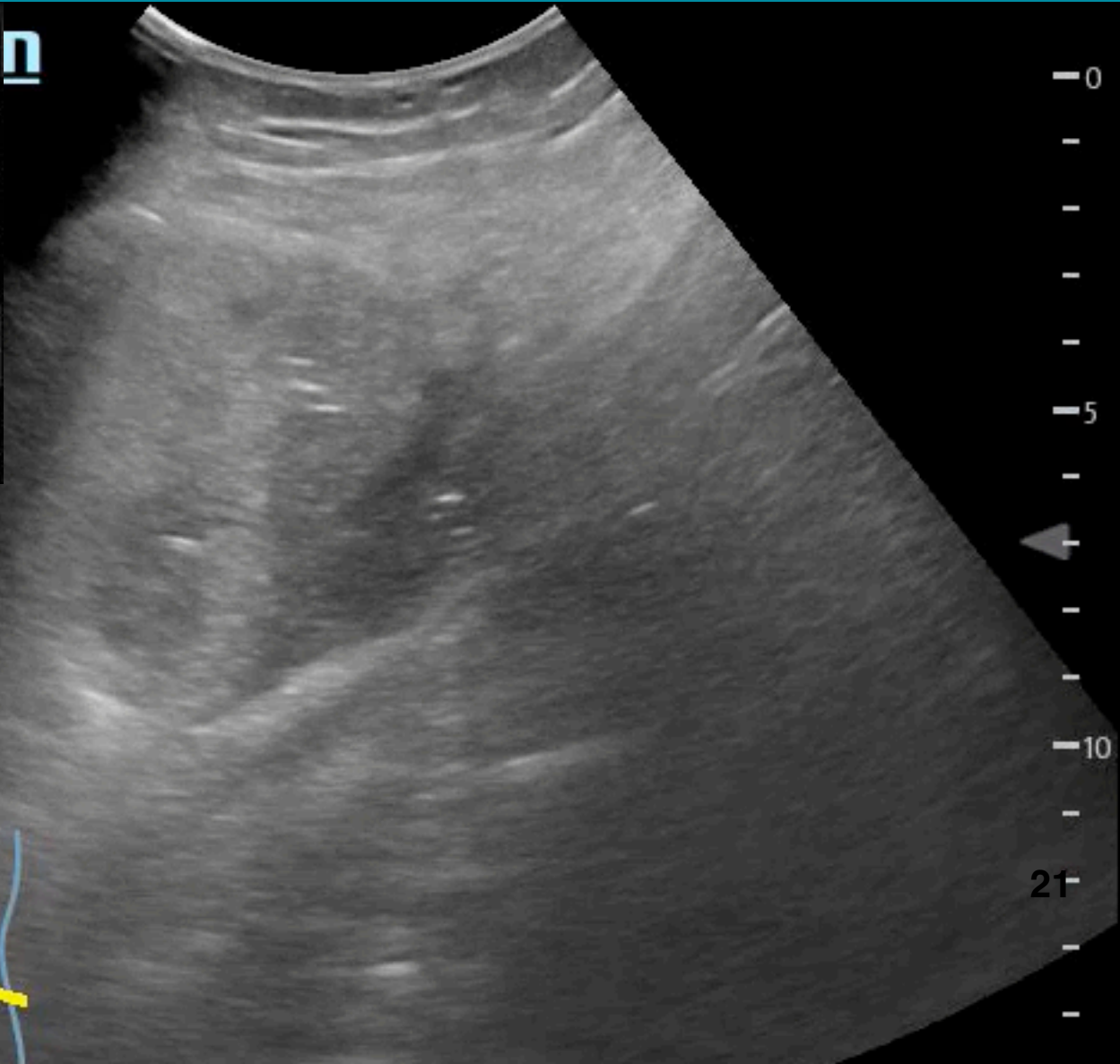
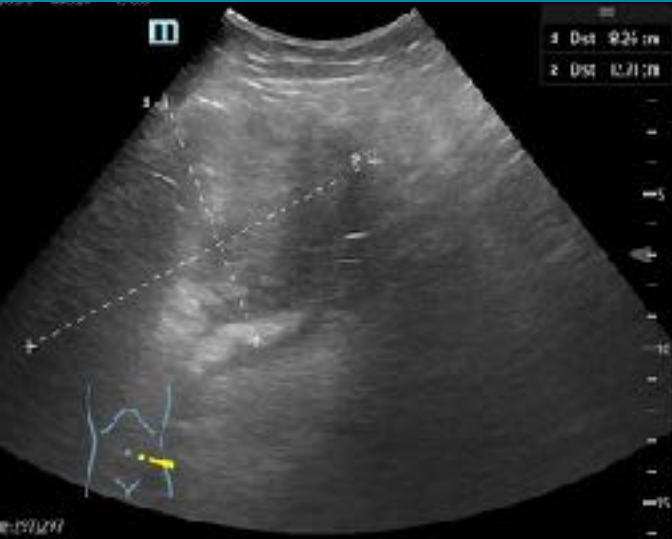NF with shock



72F, 左腹腫痛、食慾下降及腹瀉約1個月， 這兩天開始紅腫



72F, 左腹腫痛、食慾下降及腹瀉約1個月， 這兩天開始紅腫

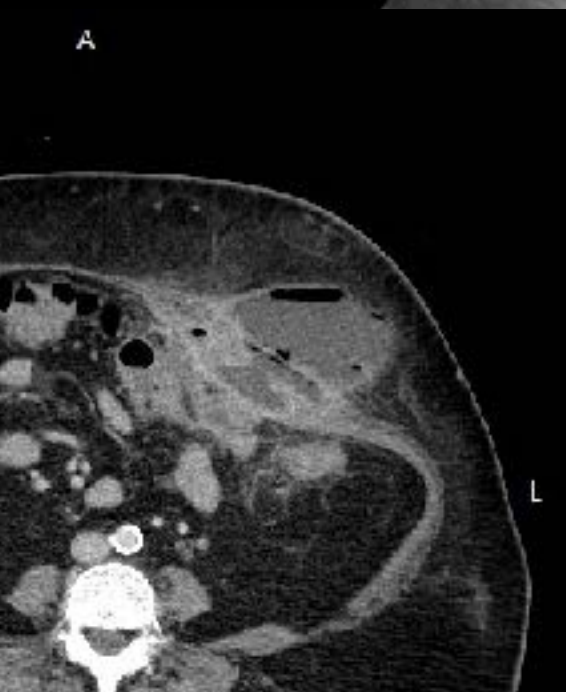
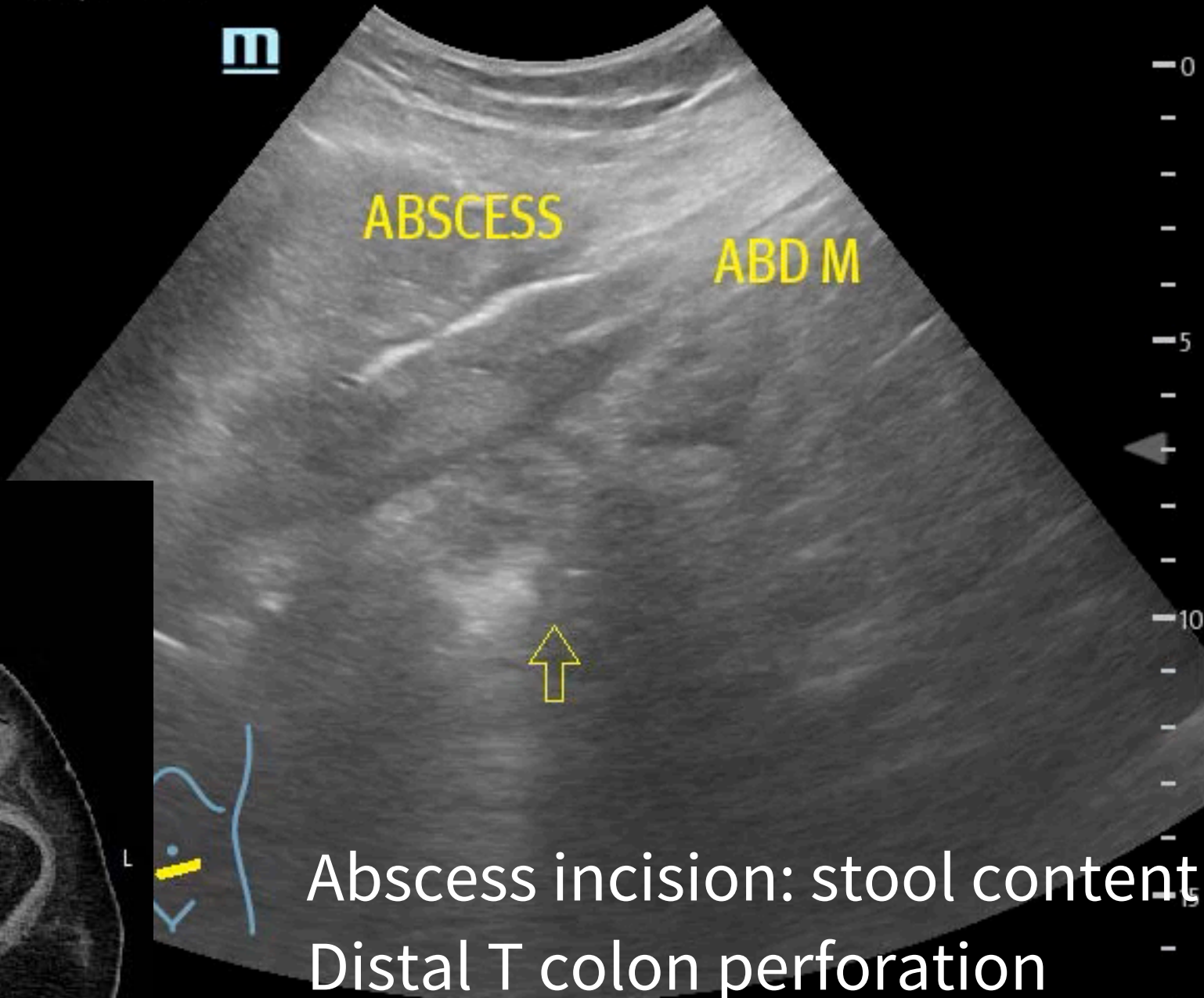


iNeedle

iTouch

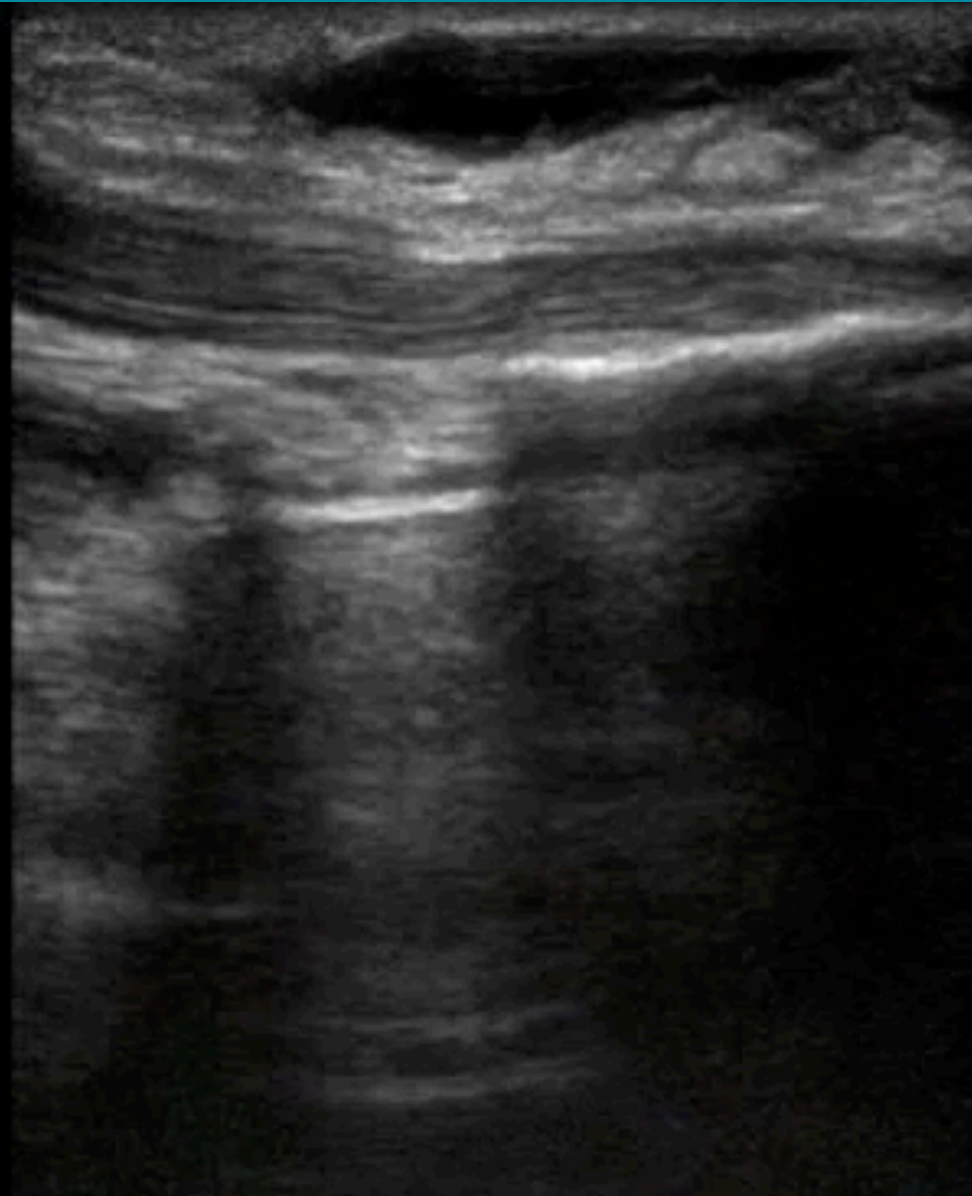
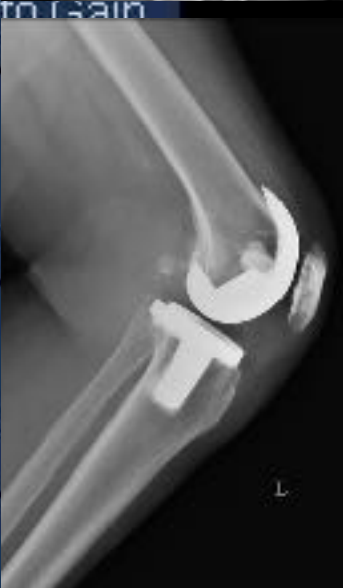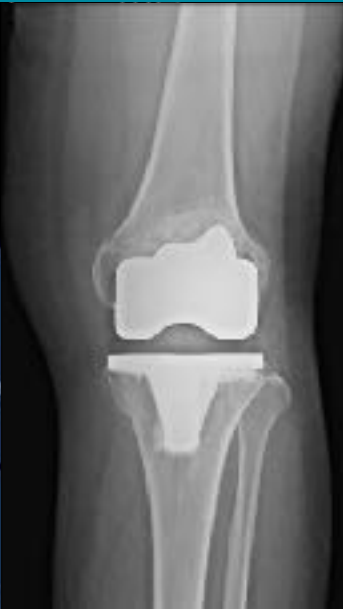C5-2s AP 96.6% MI 0.91 TIS 0.6

B
FH5.0
DR 130
FR 17
D 17.0
G 50



Abscess incision: stool content
Distal T colon perforation

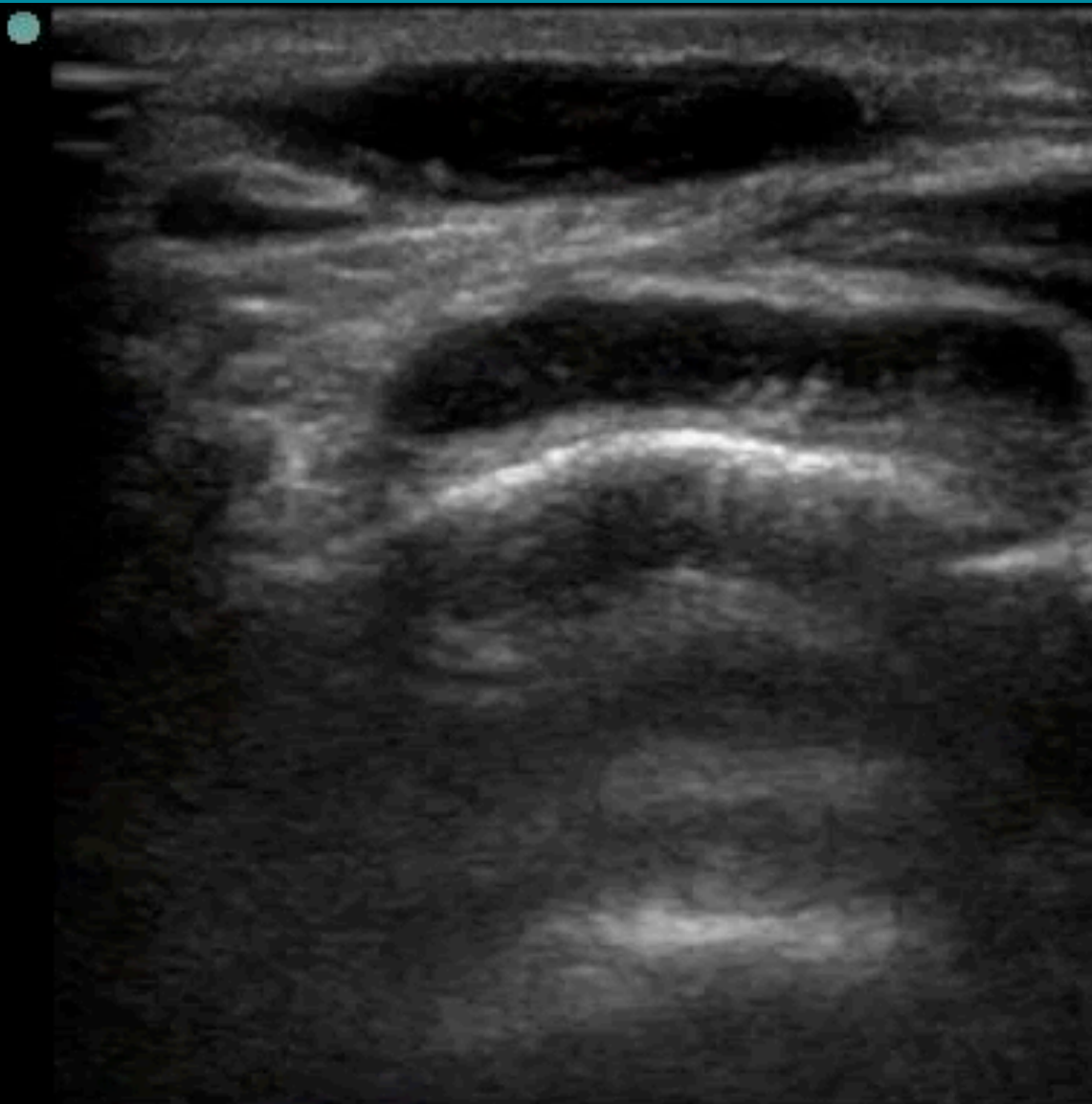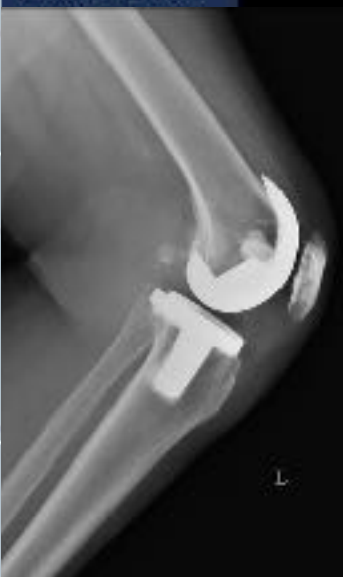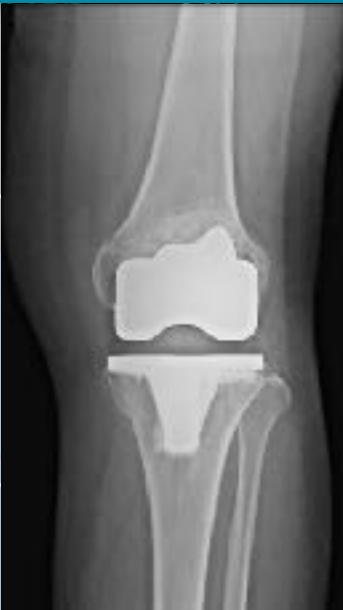72F, left knee cellulitis



H
E
2
T
0

18

72F, left knee cellulitis

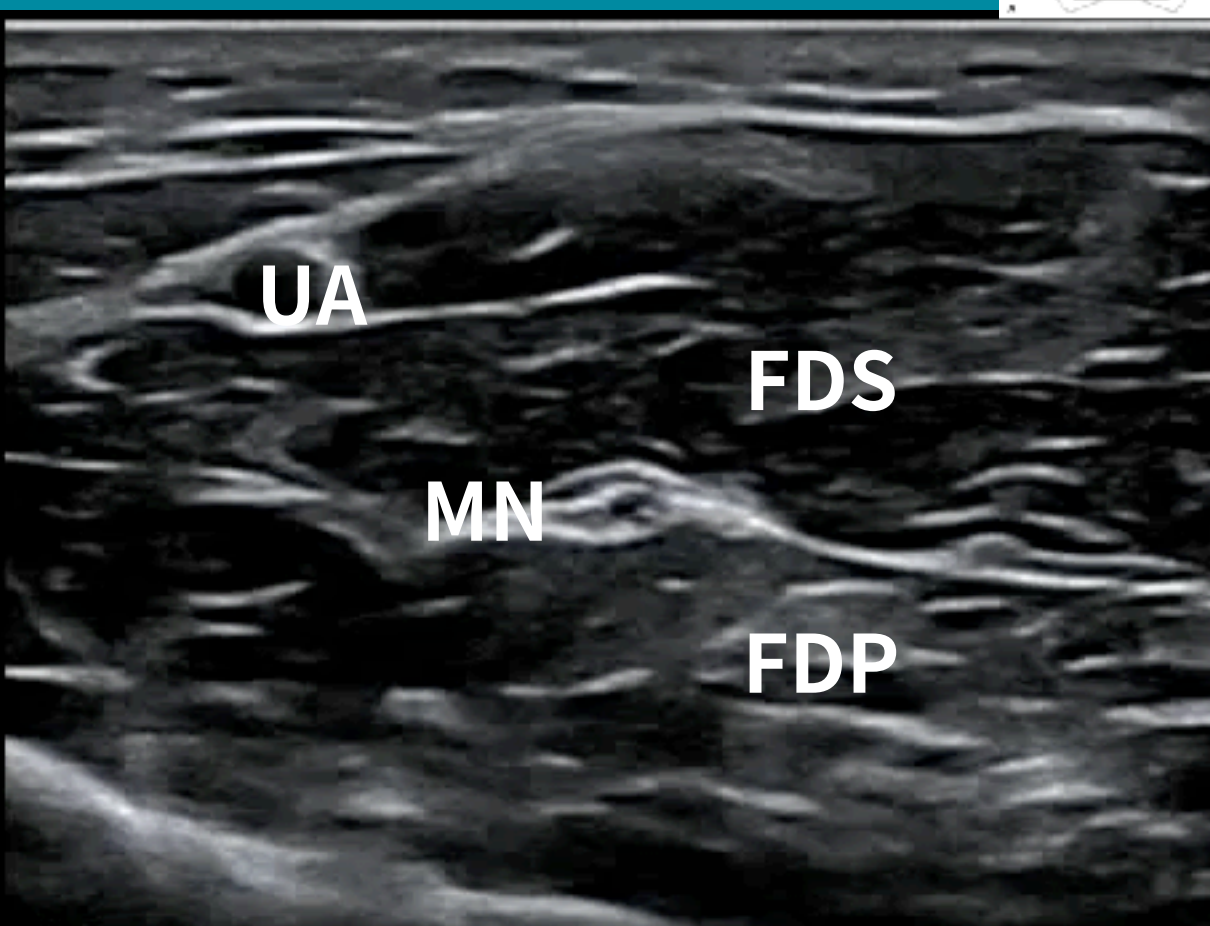
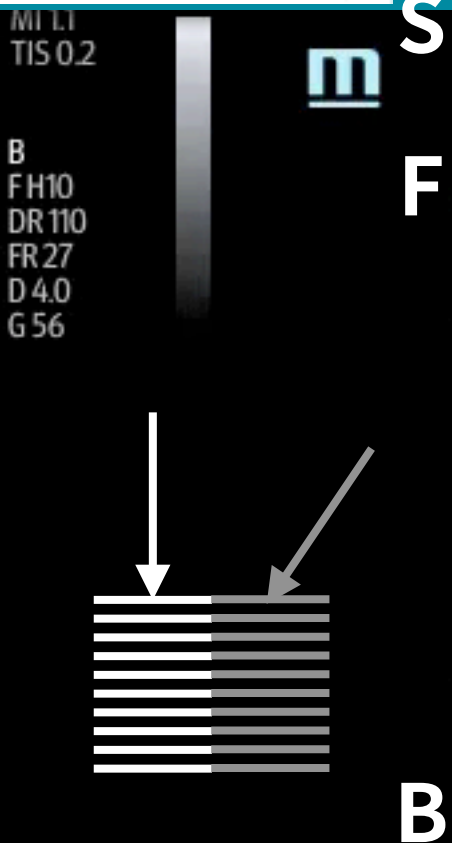
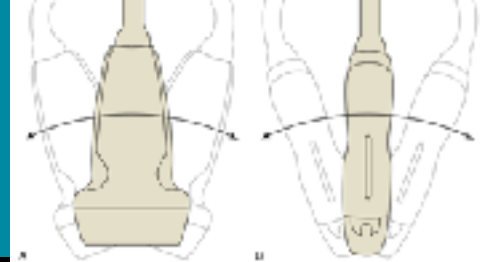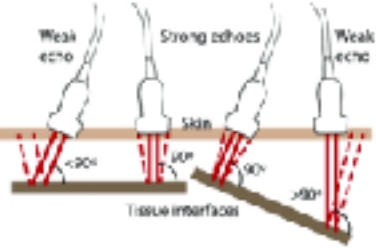


Vas
HFL
19%
MI
0.7
TIS
0.1



4.0

Anisotropy



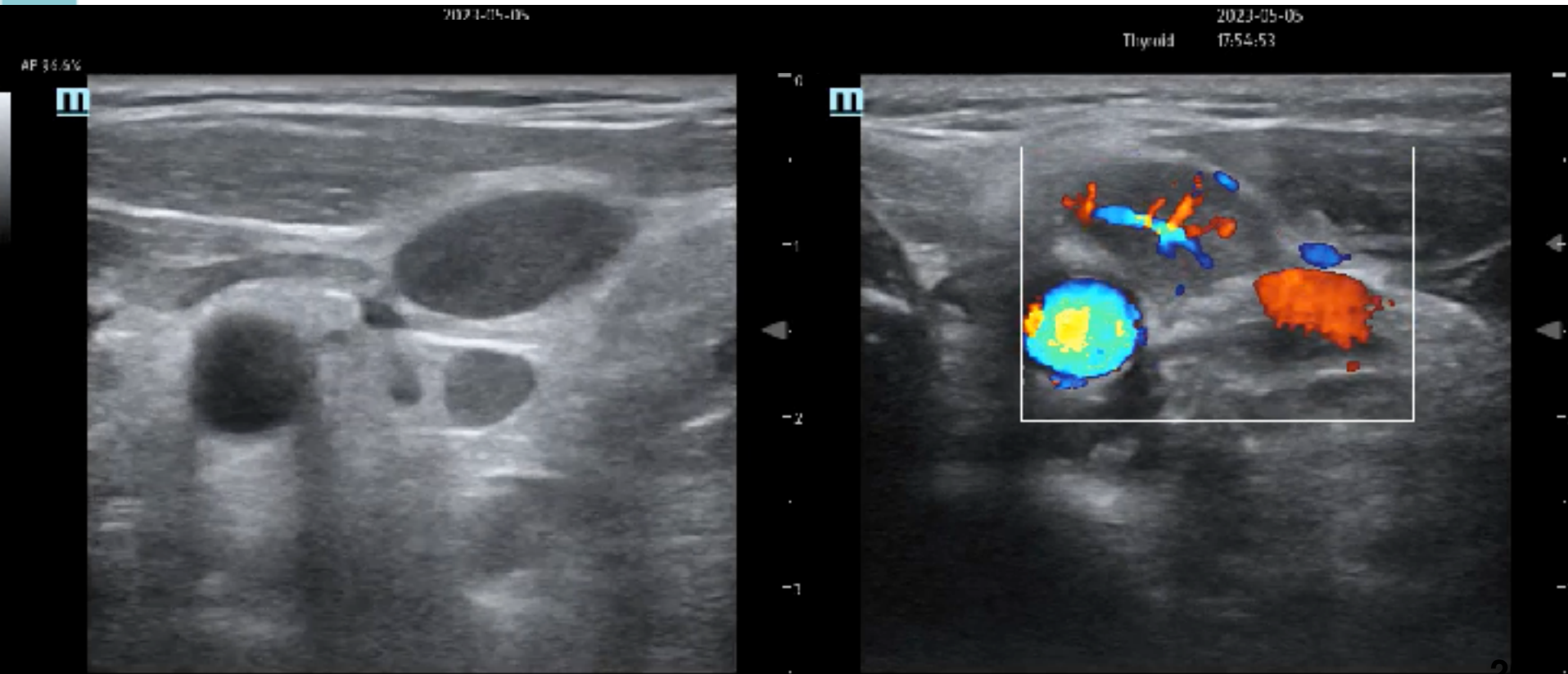
Tendon

Nerve

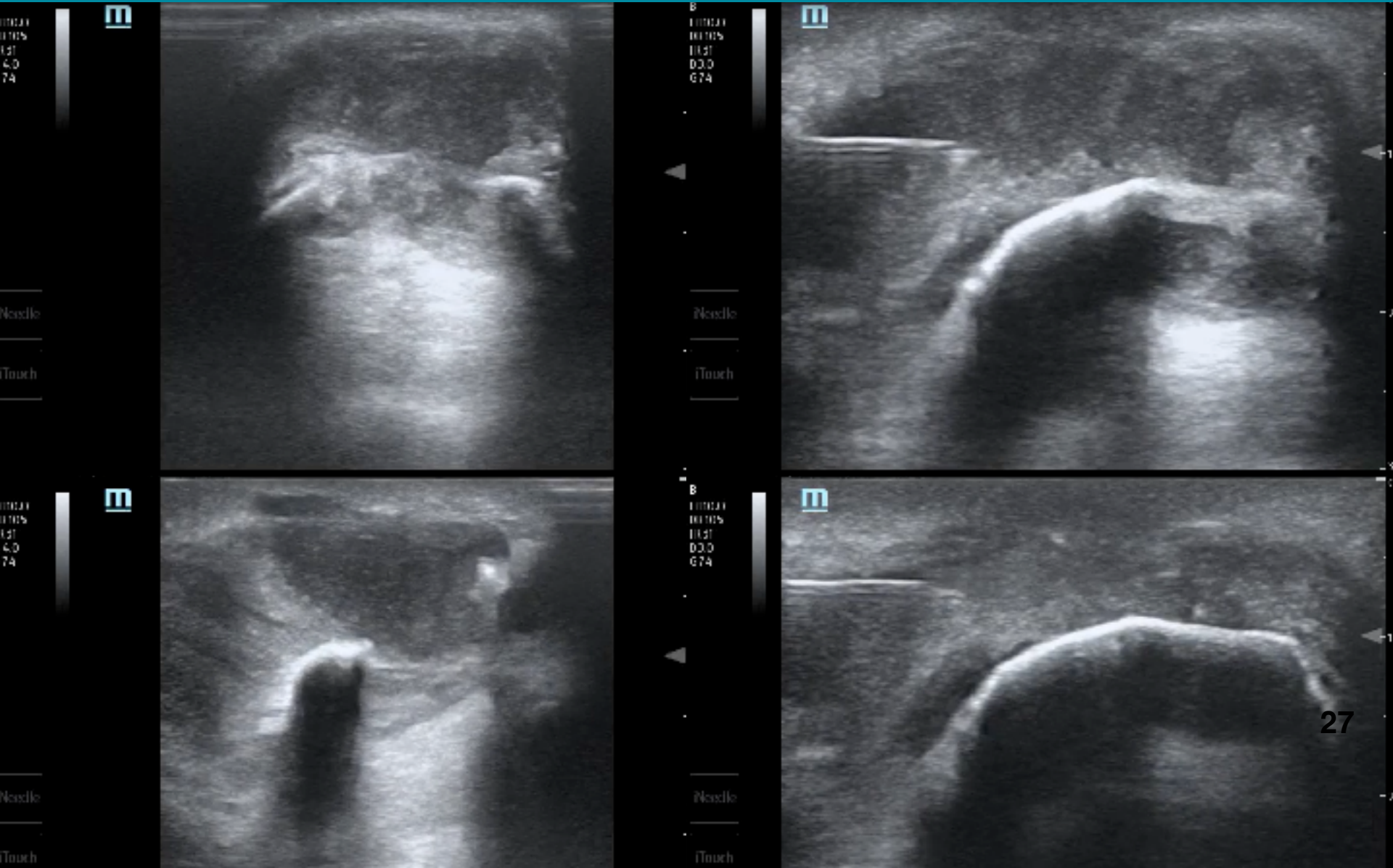
Muscle

41F, fever & neck pain

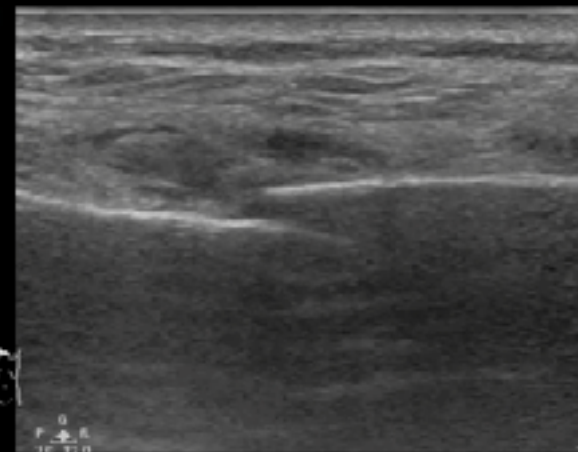
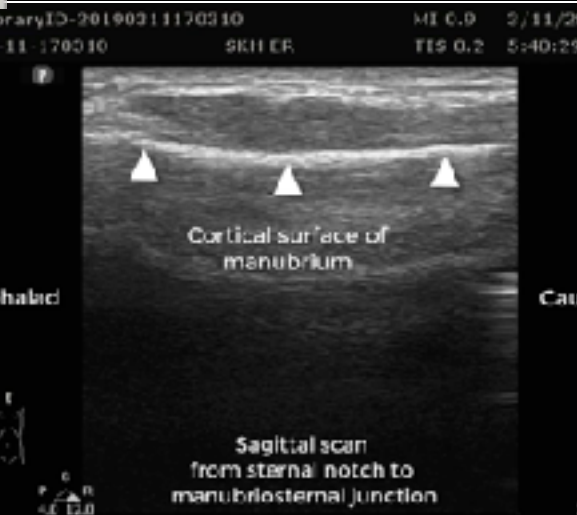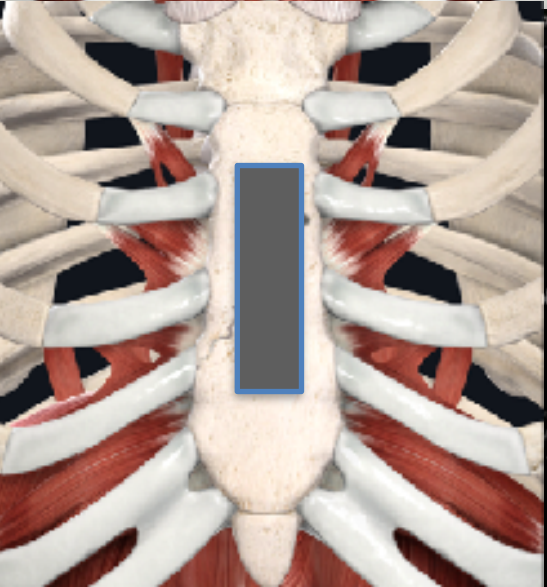
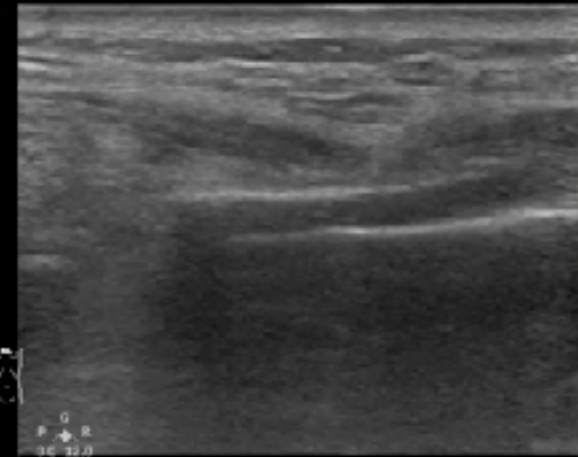
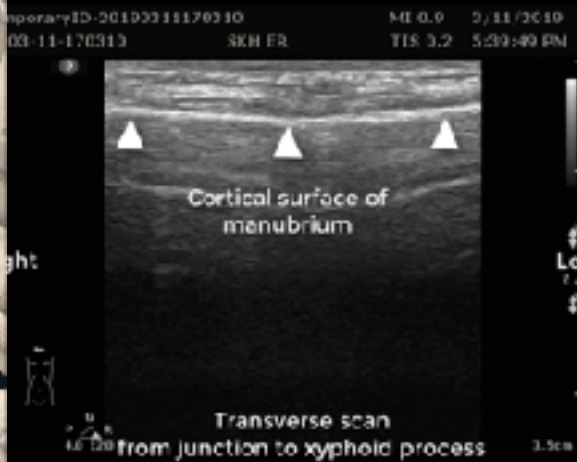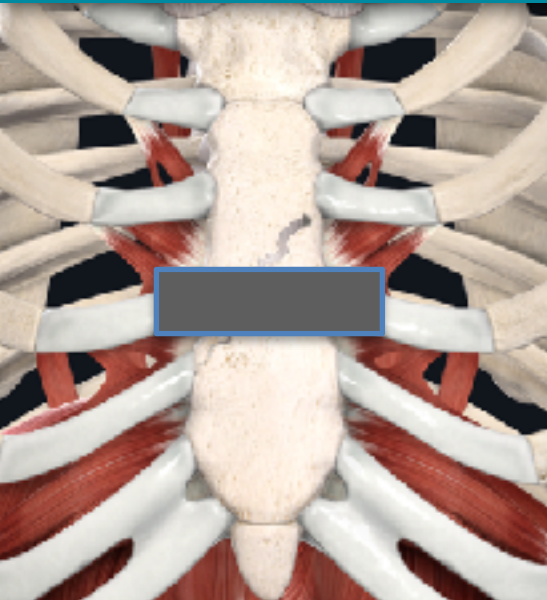
Cervical lymphadenitis



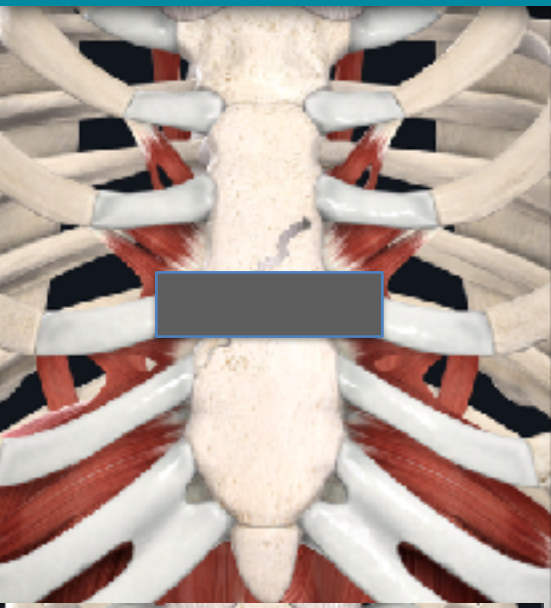
64M, submandibular abscess



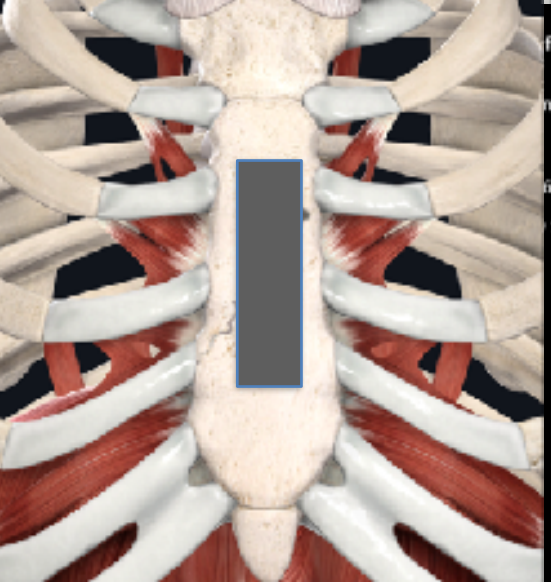
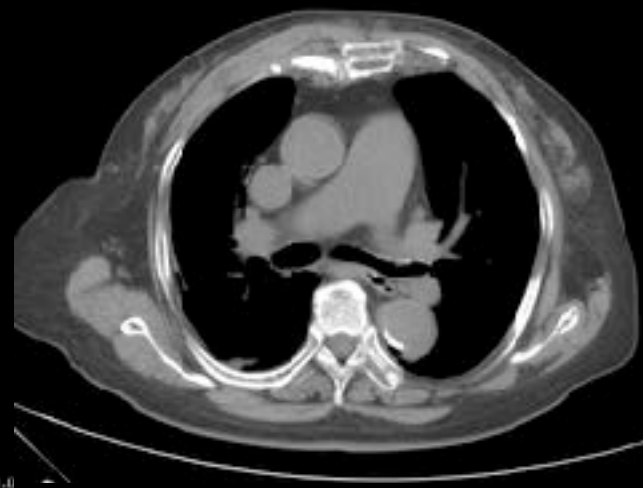
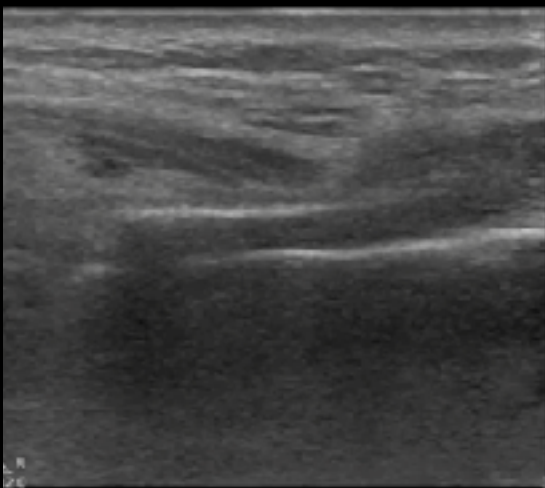
Sternal fracture



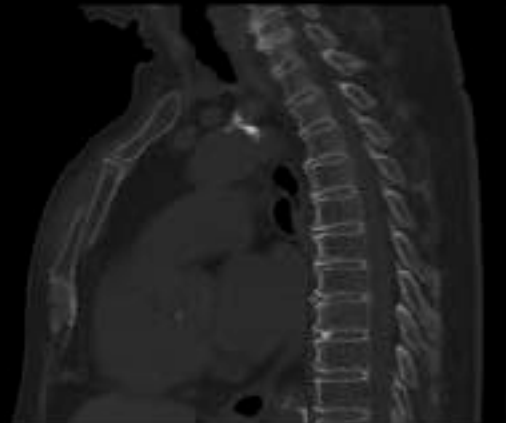
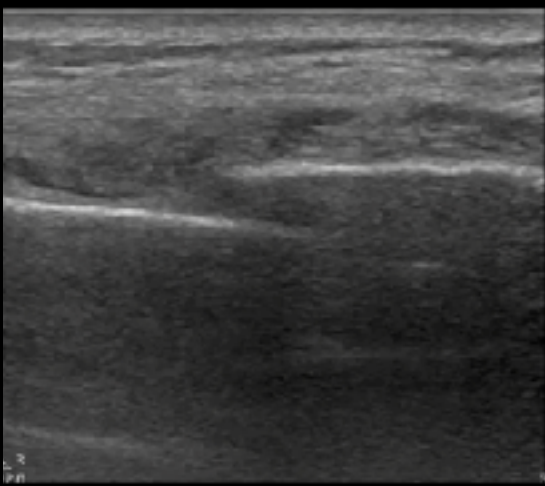
骨折判斷 - 適用長骨&平骨



高低落差

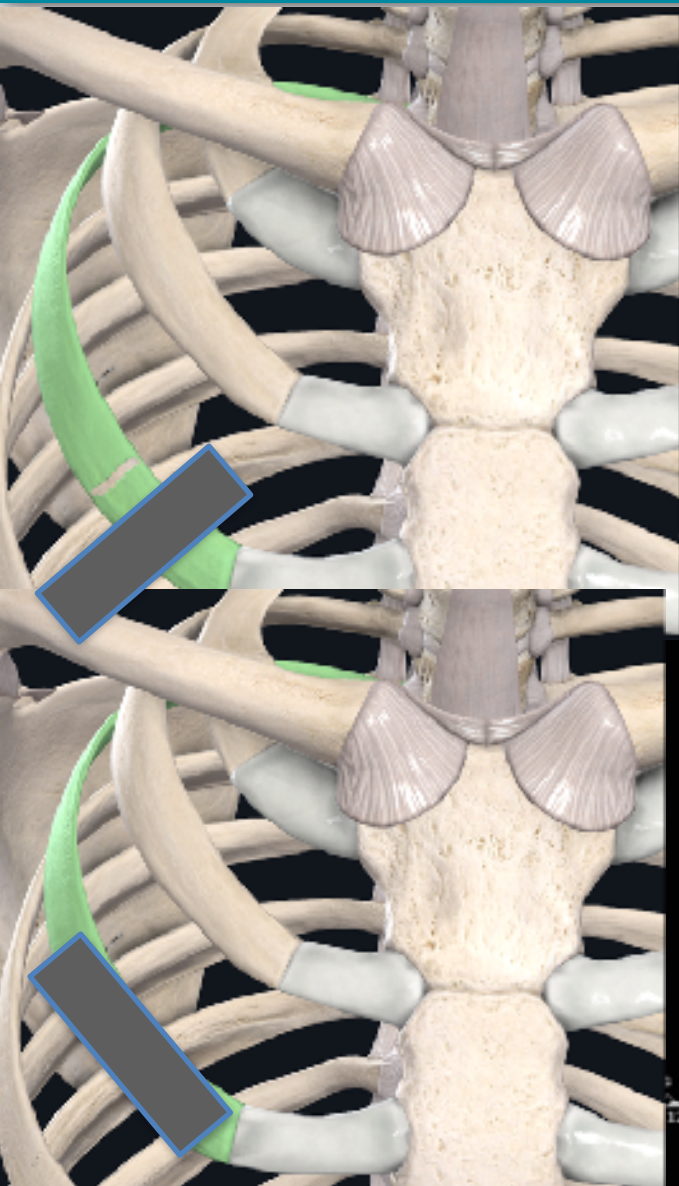


不連續

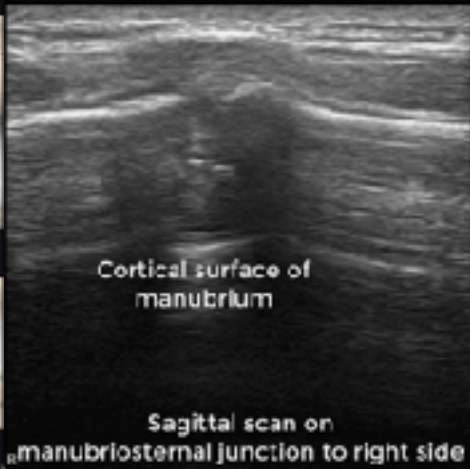

血腫

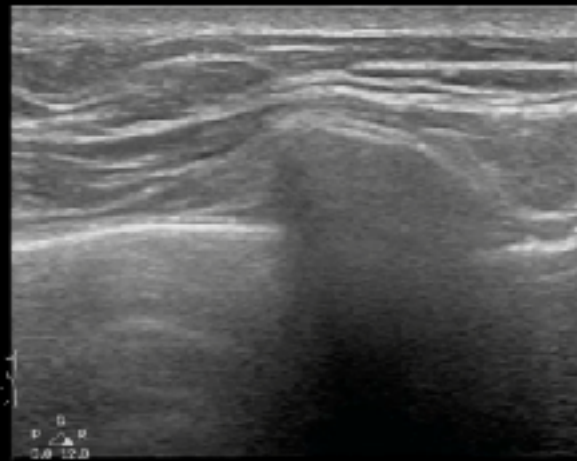
Rib fracture



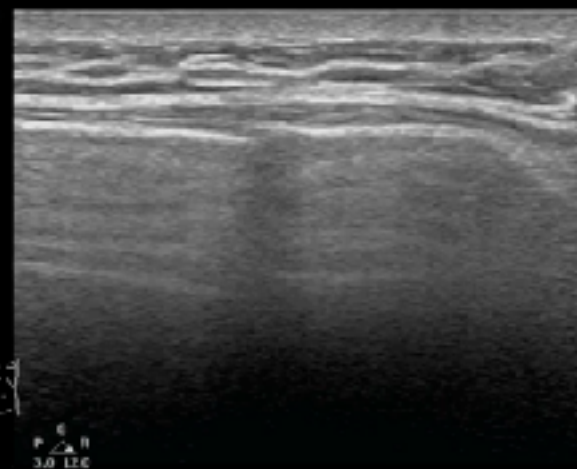
20190311170310 MI 0.9 3/11
SID SKH-ER TIS 0.2 5:40



Superficial
L12-3
46 Hz
3.0cm
2D
Res
Gn 96
C 56
3/2 / 1

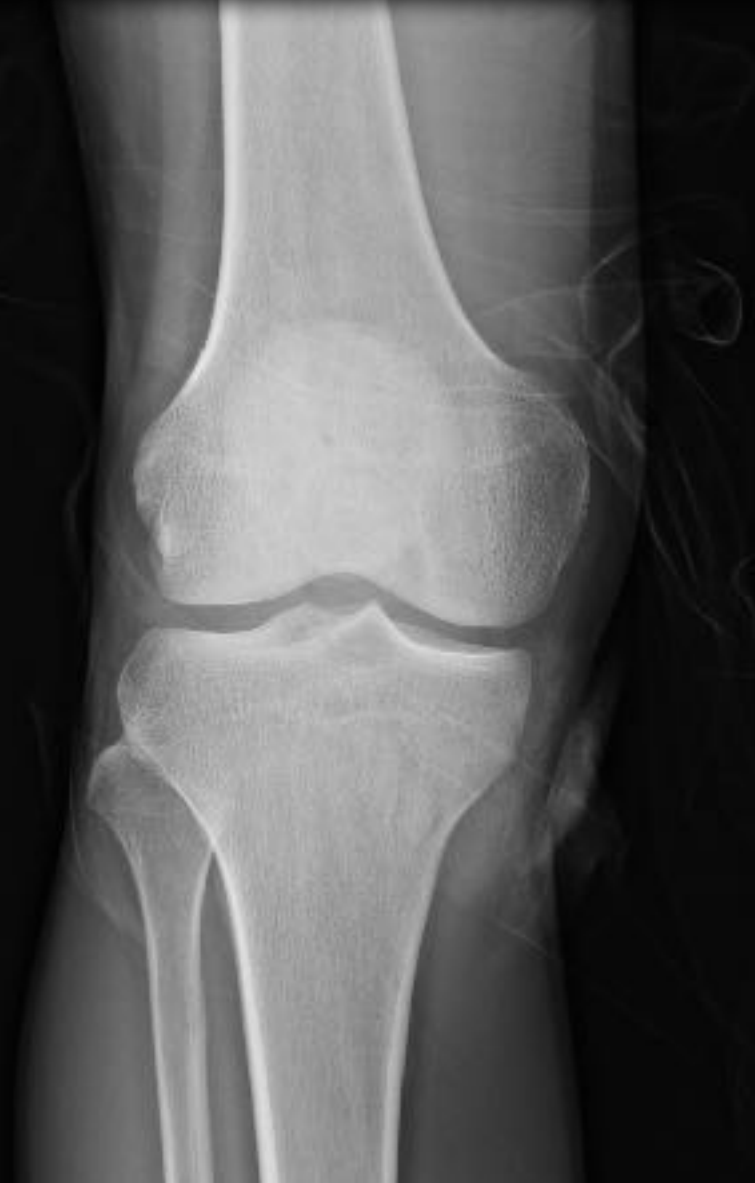

Superficial
L12-3
46 Hz
3.0cm
2D
Res
Gn 96
C 56
3/2 / 1

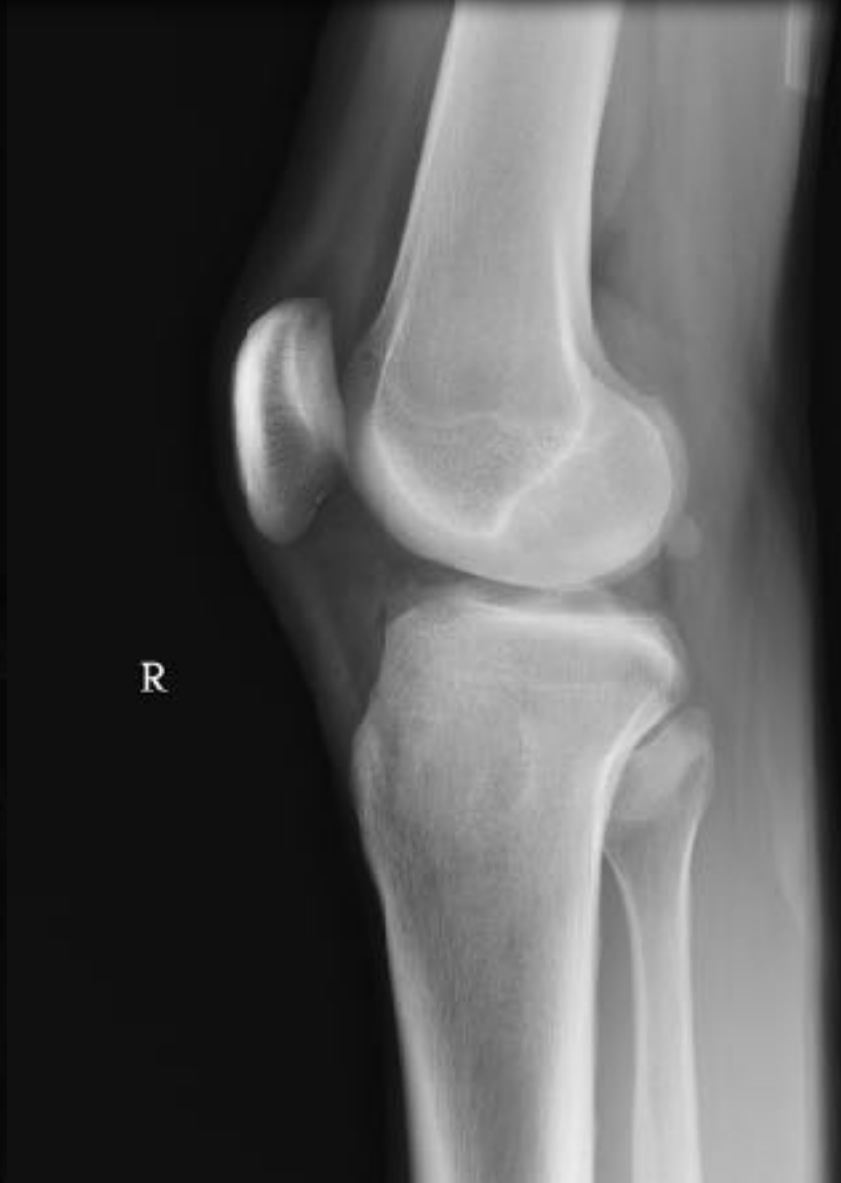

23M，車禍，右膝腫痛

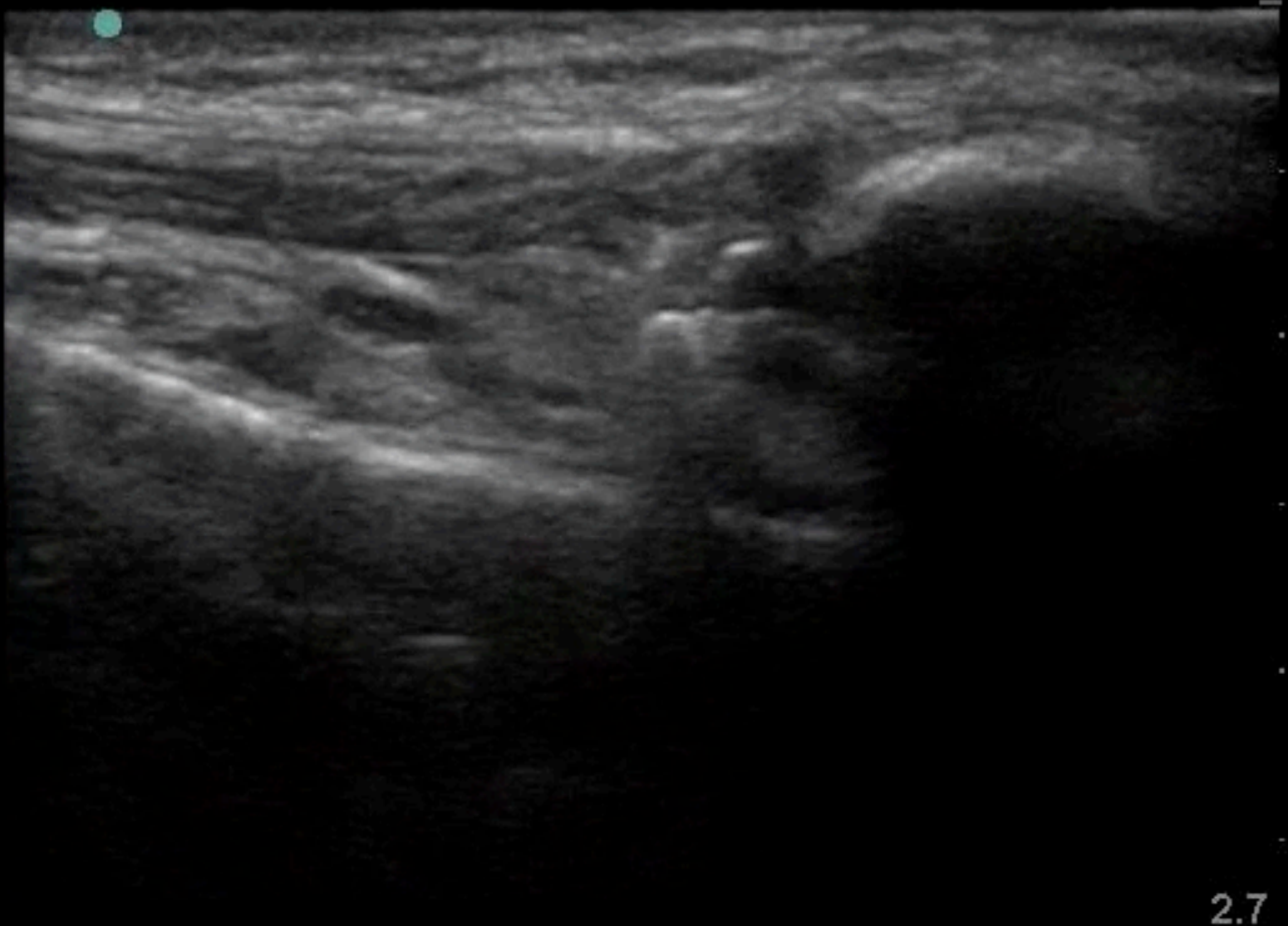
R



R



23M，車禍，右膝腫痛



HFL



57%

MI

0.7

TIS

0.1



Patient



Auto Gain



Res



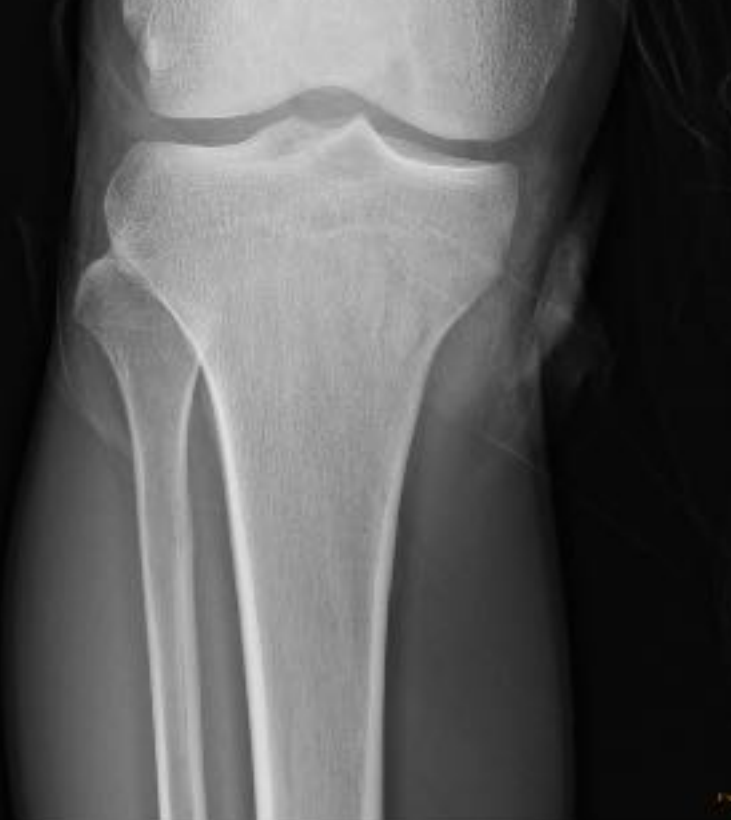Clip



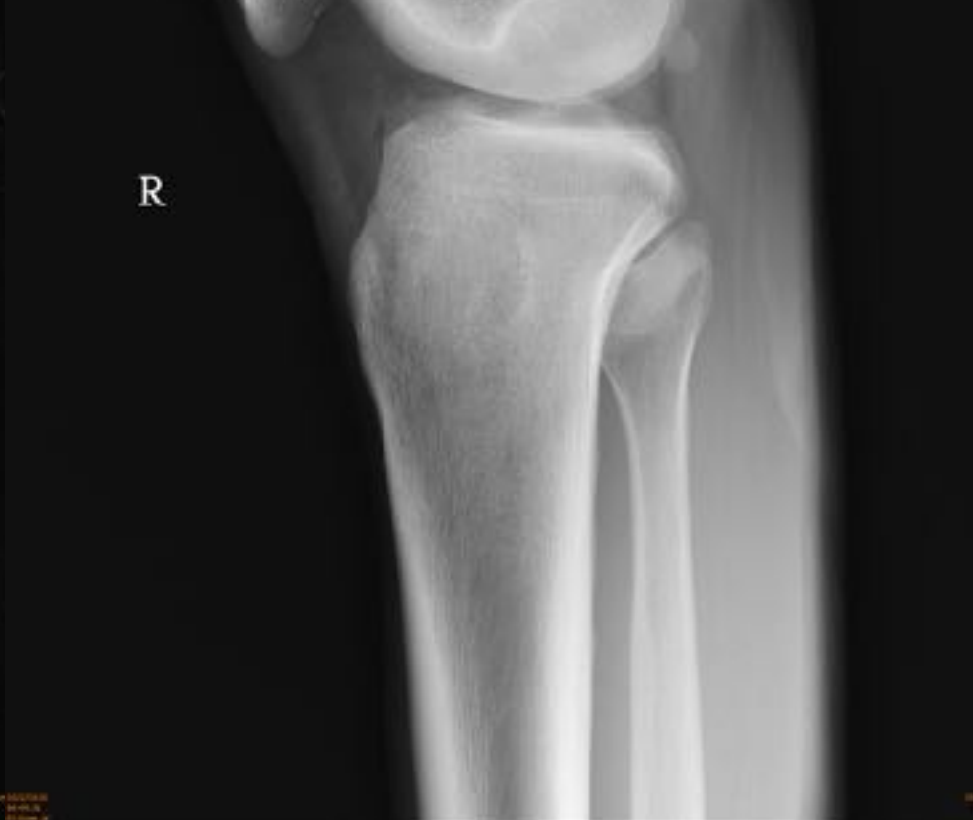Page 1/3

2.7

R



R



12/08/11
14:43:34
0.00000

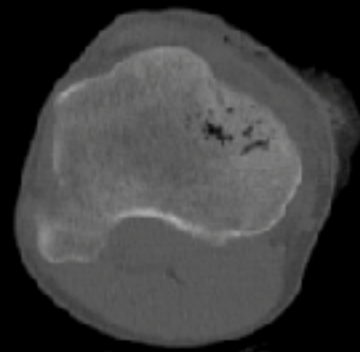
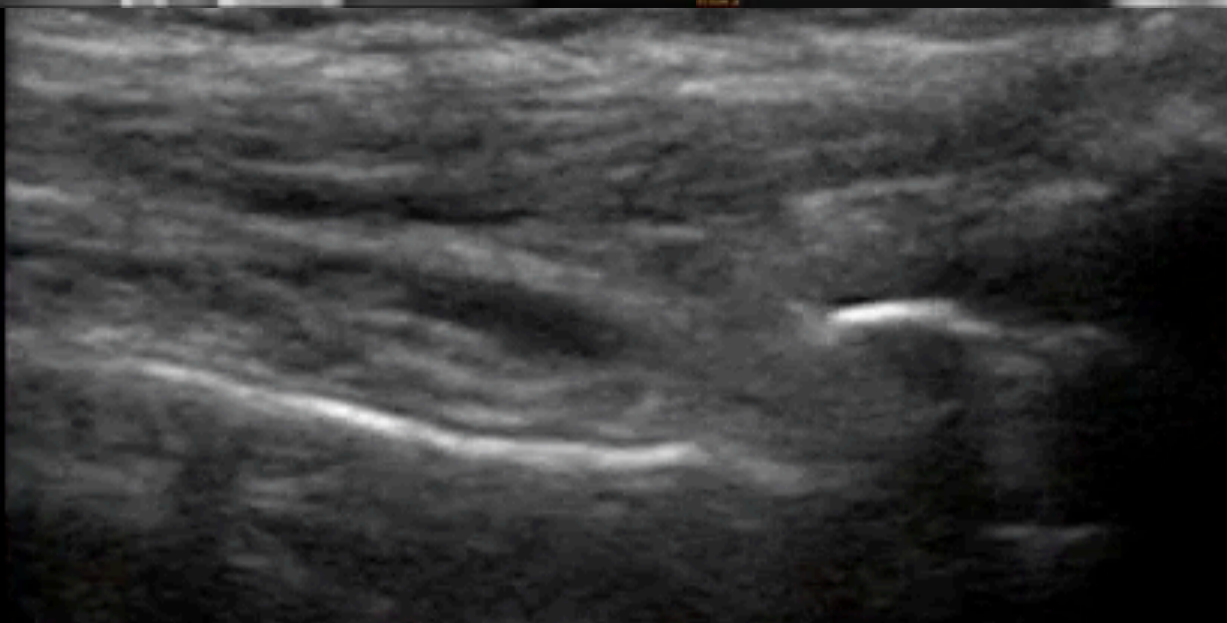
12/08/11
14:43:34
0.00000



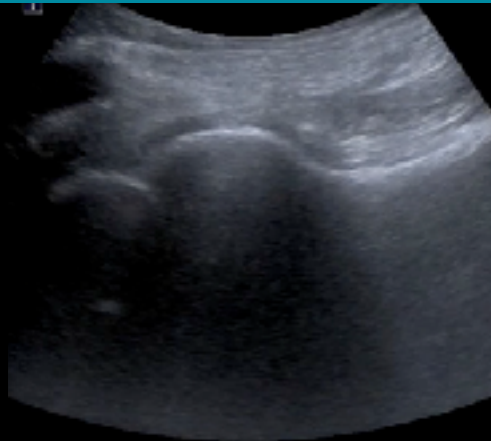Patient



Auto Gain

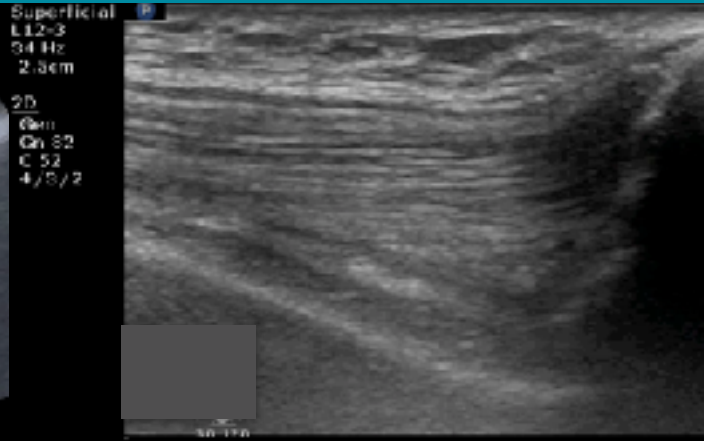


Lower extremity joints



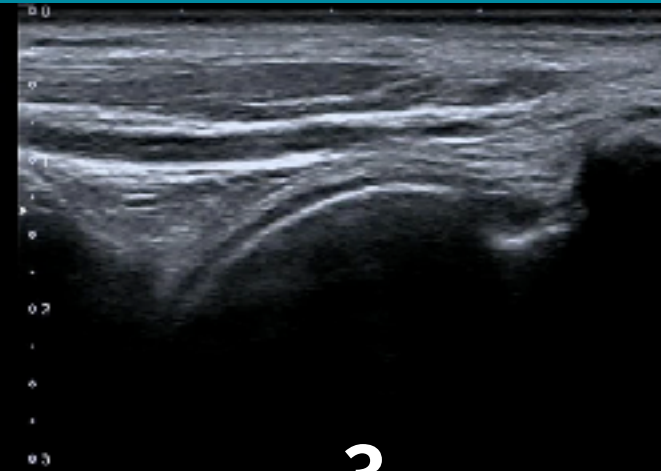1

Hip



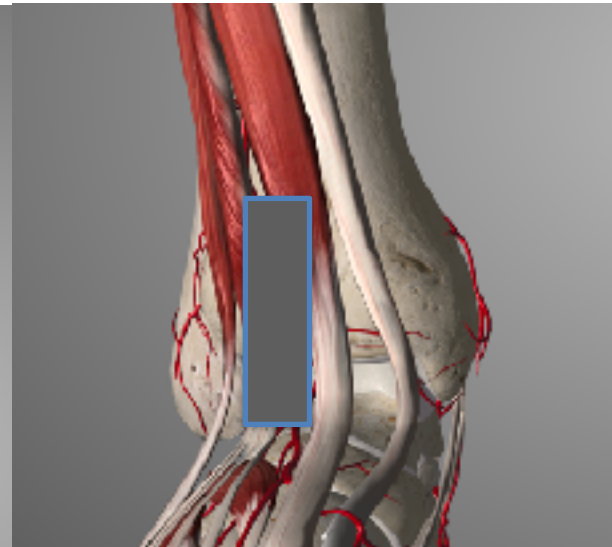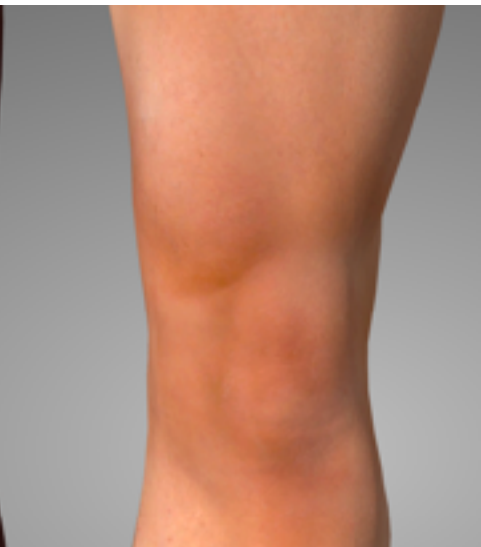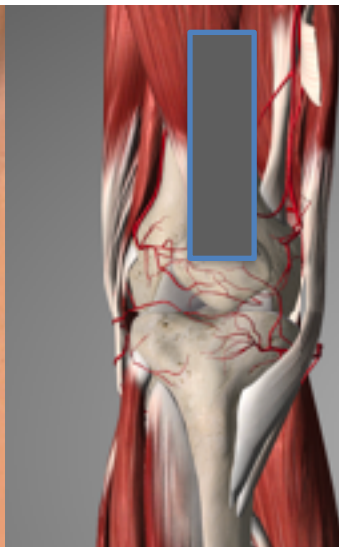
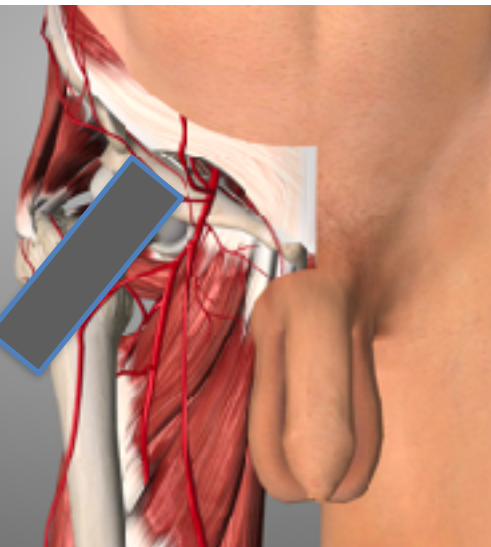
2

Knee

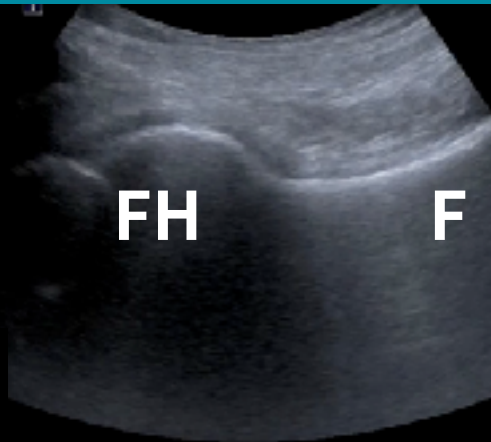


3

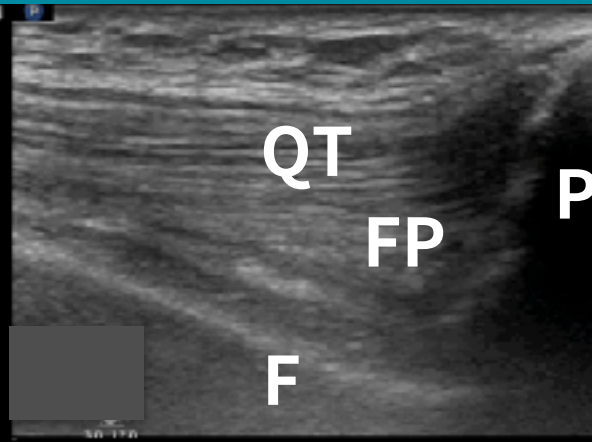
Ankle



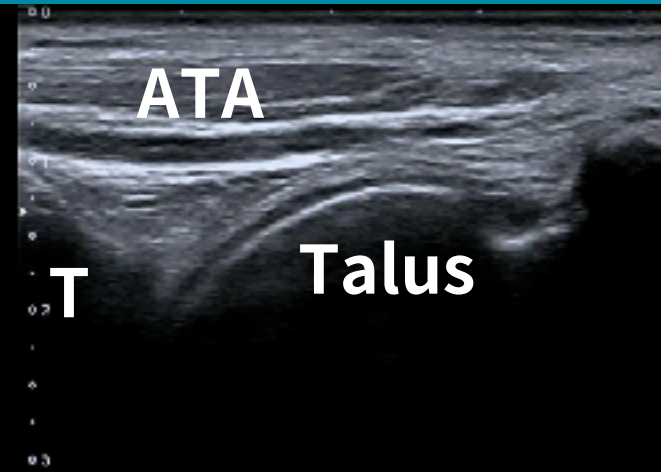
LE Joint effusion



Hip

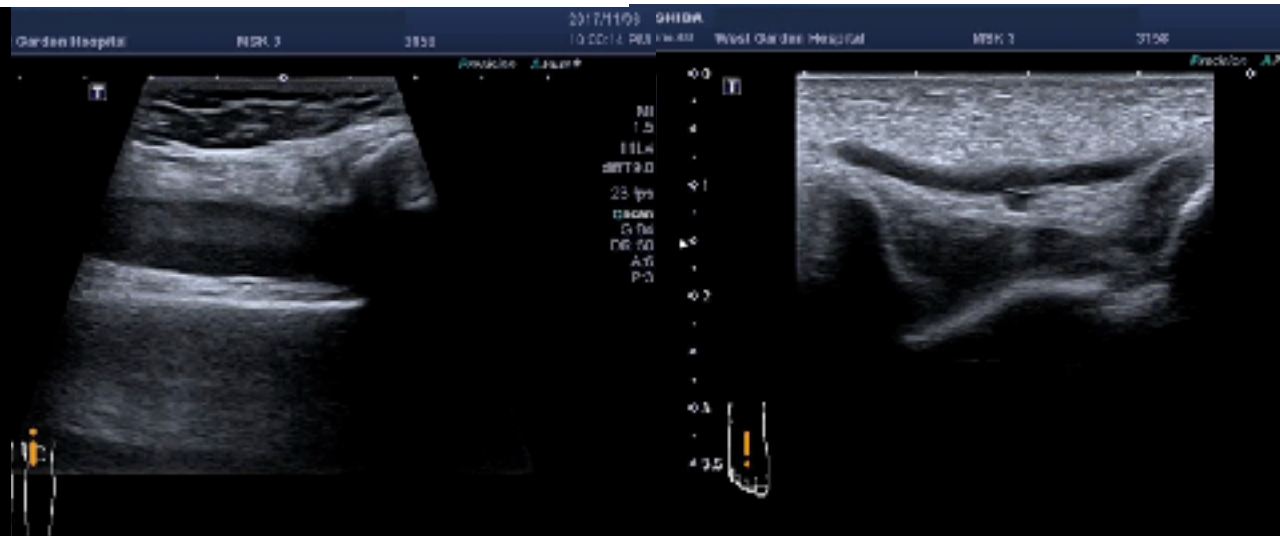
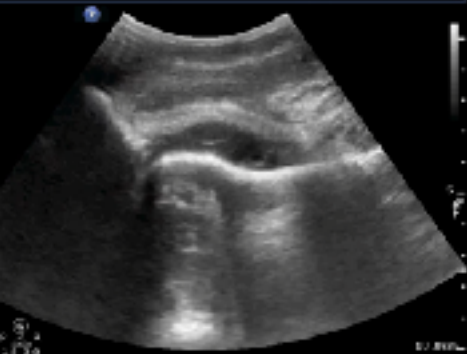

Knee

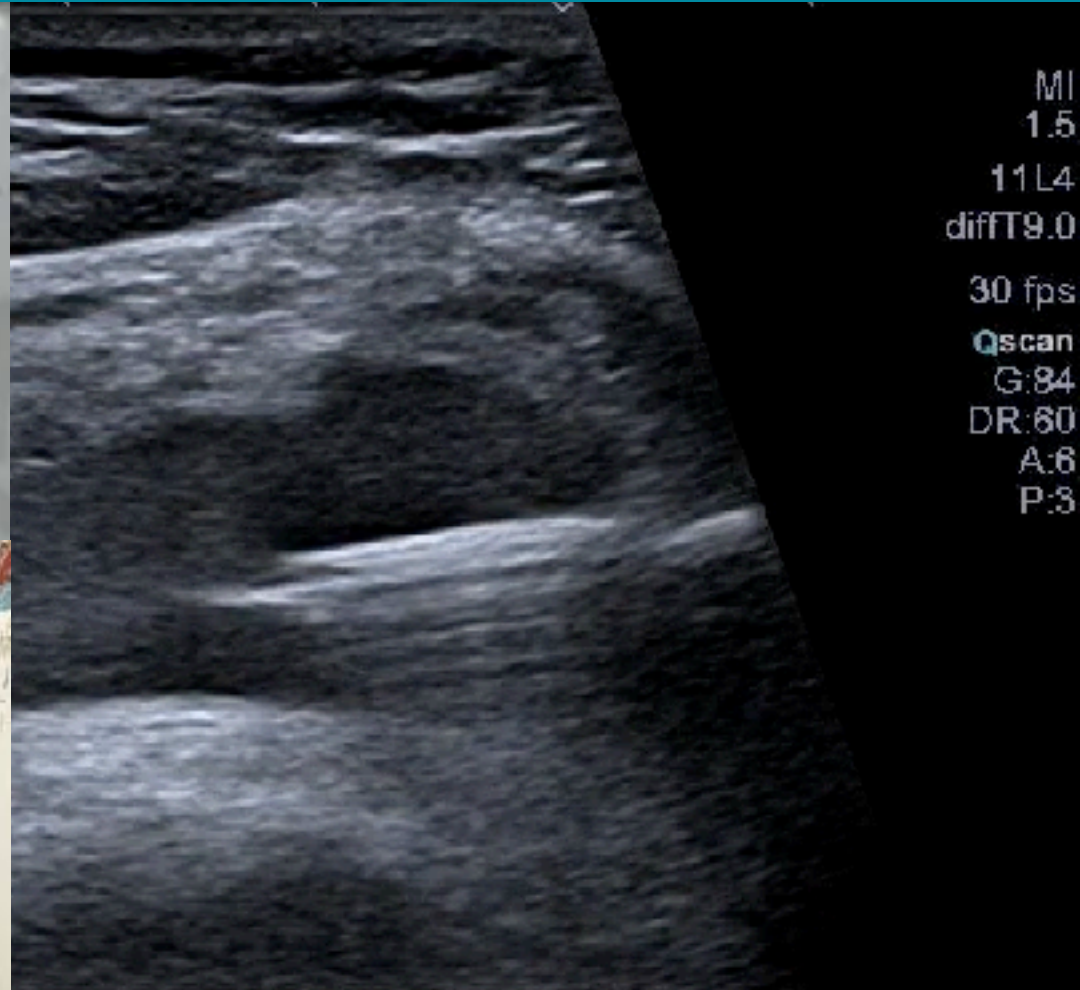


Ankle

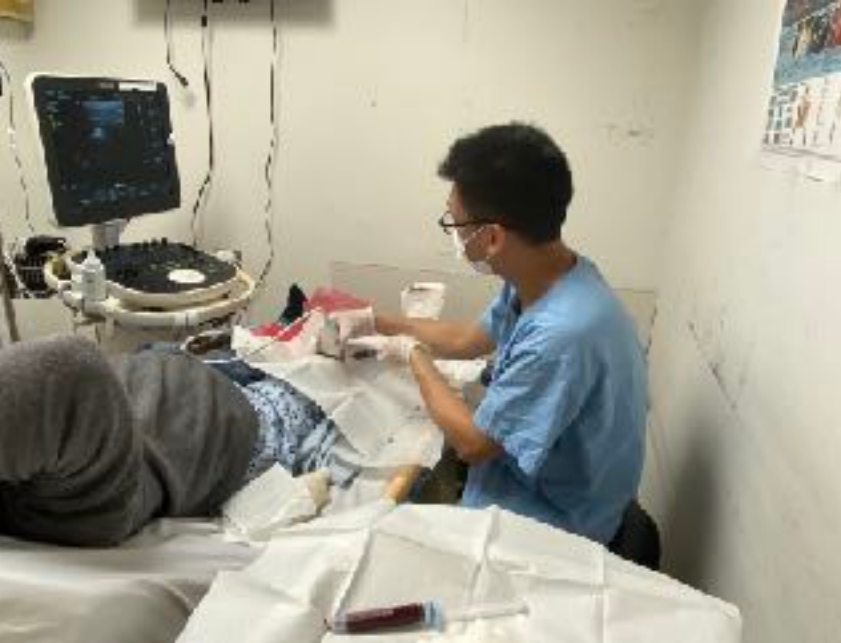SKH-EUTC@ChenKC



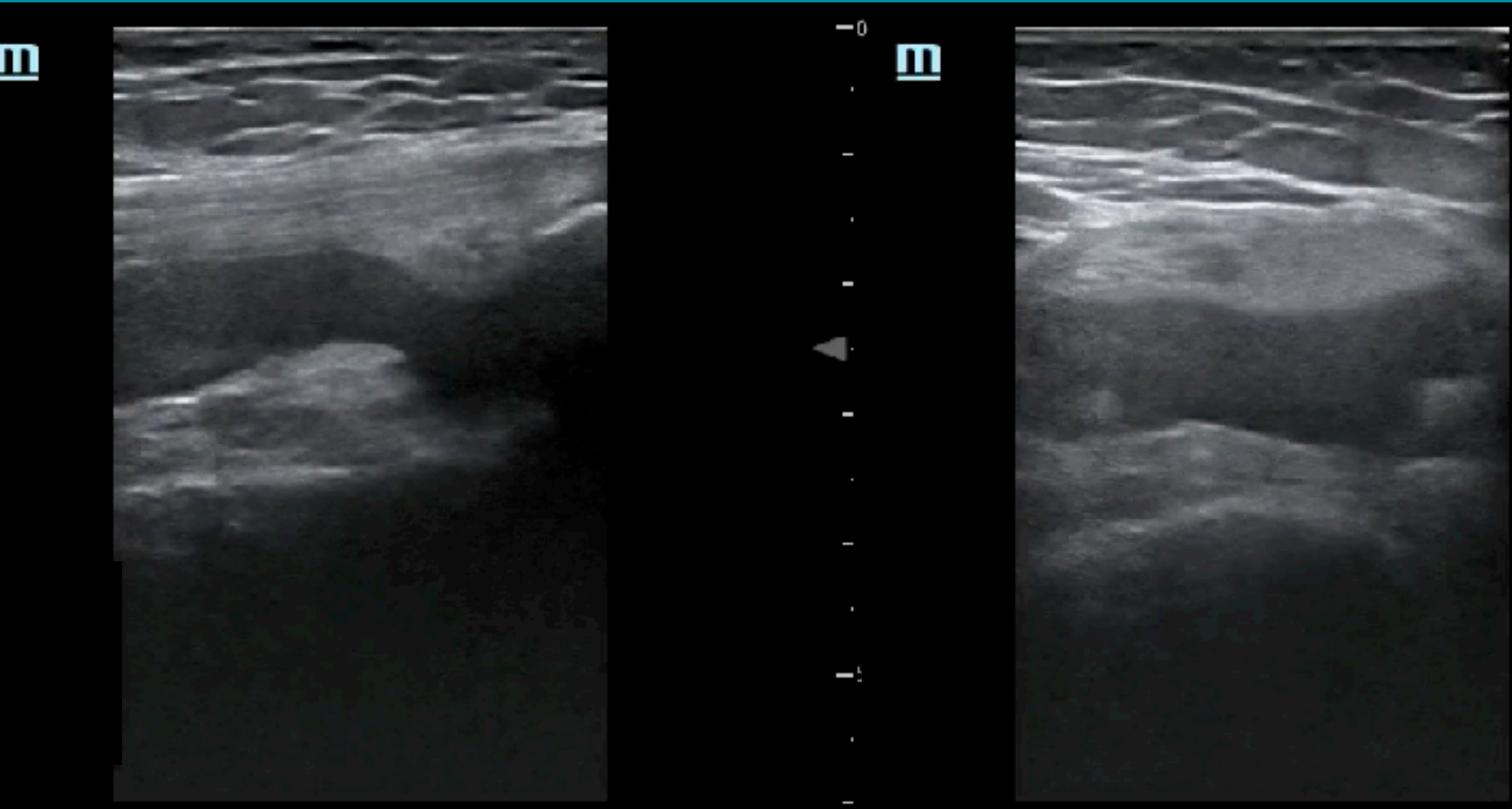
Needling for hemarthrosis



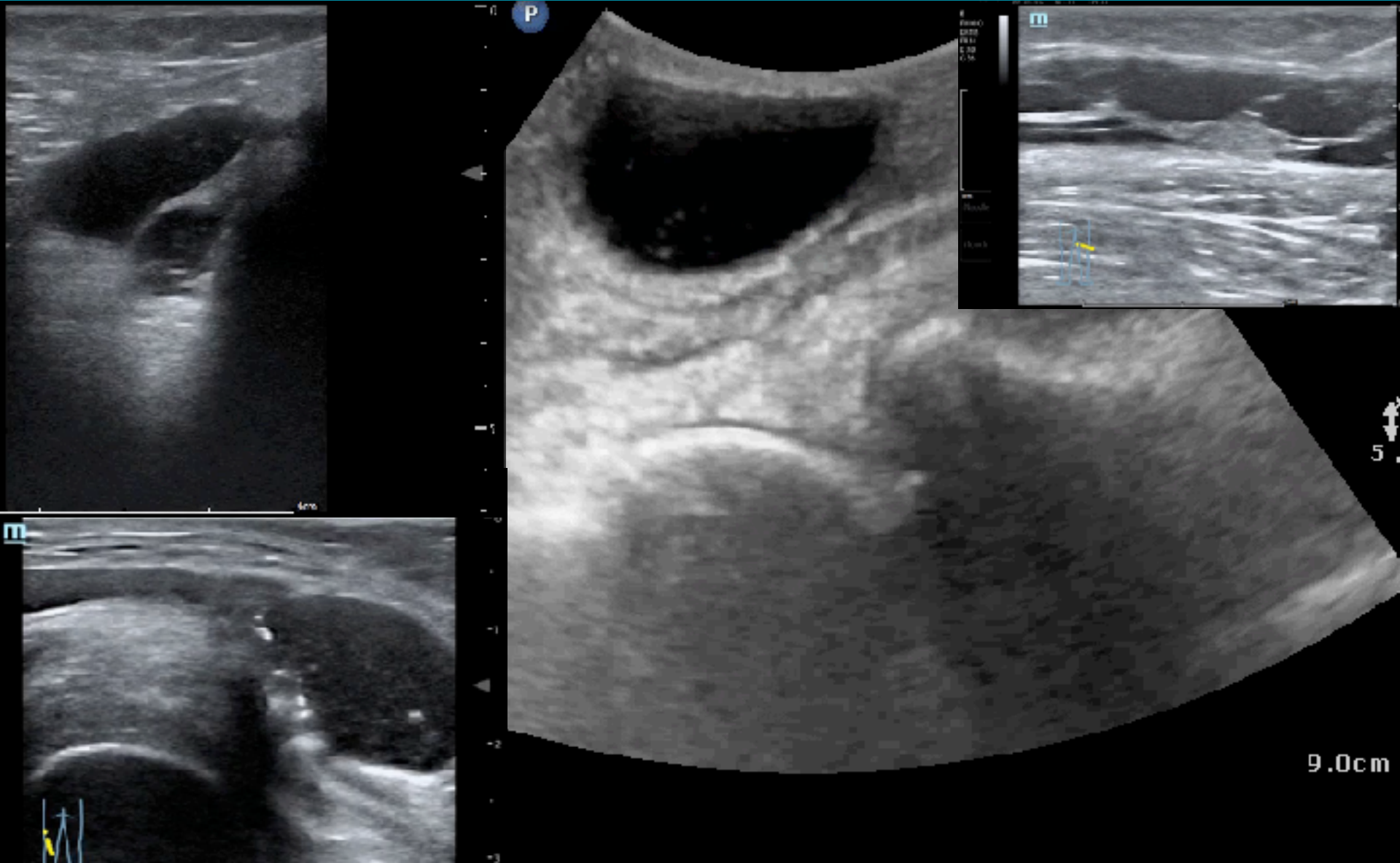
MI
1.5
11L4
diffT9.0
30 fps
Qscan
G:84
DR:60
A:6
P:3



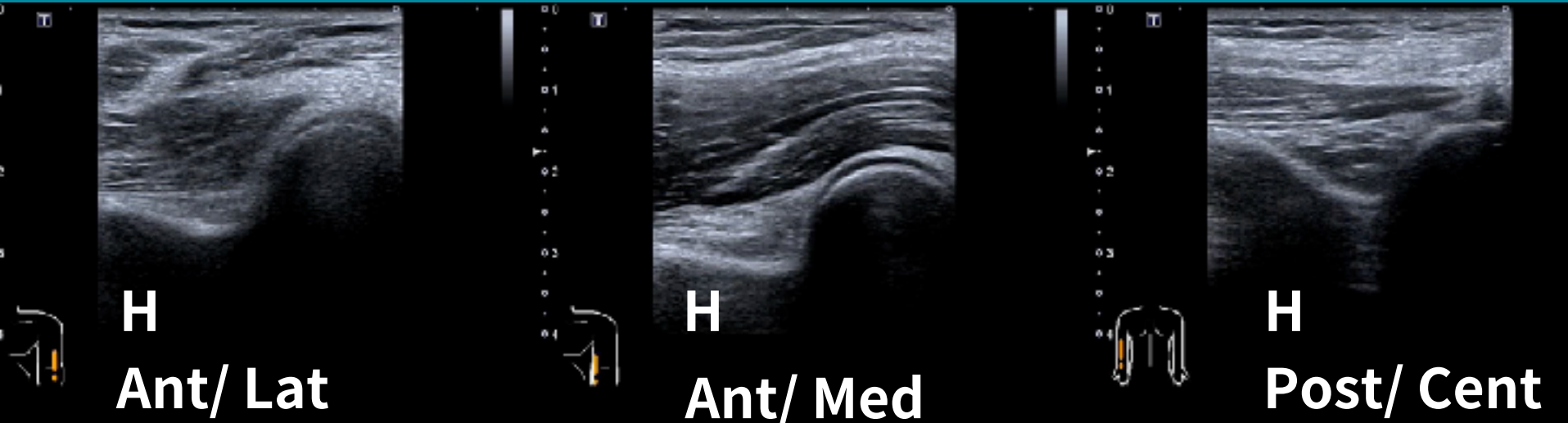
Lipohemarthrosis



Baker's cyst



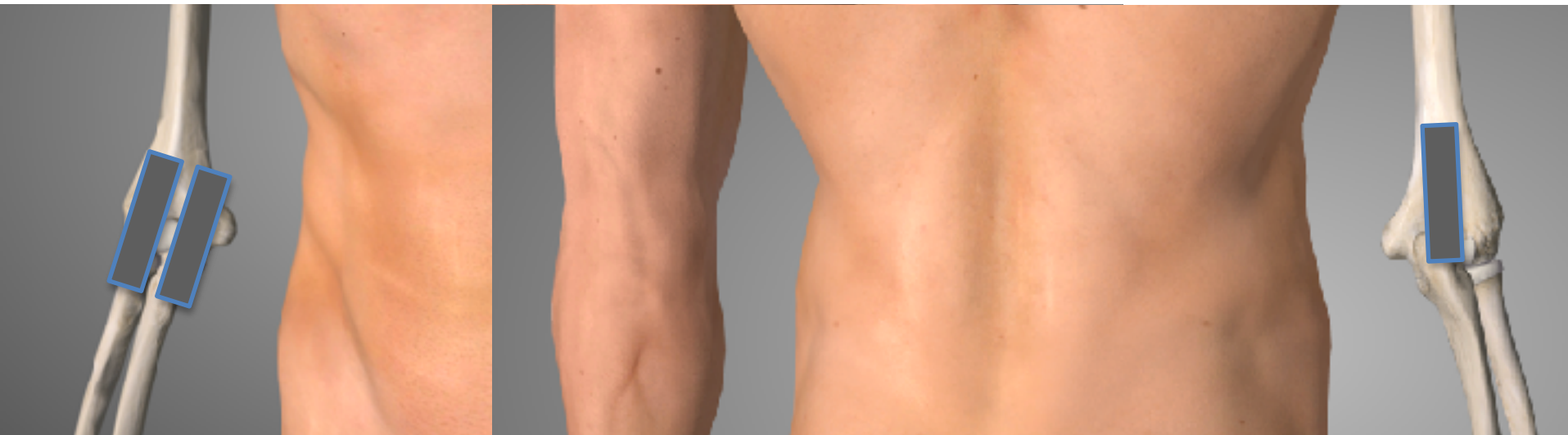Elbow joint



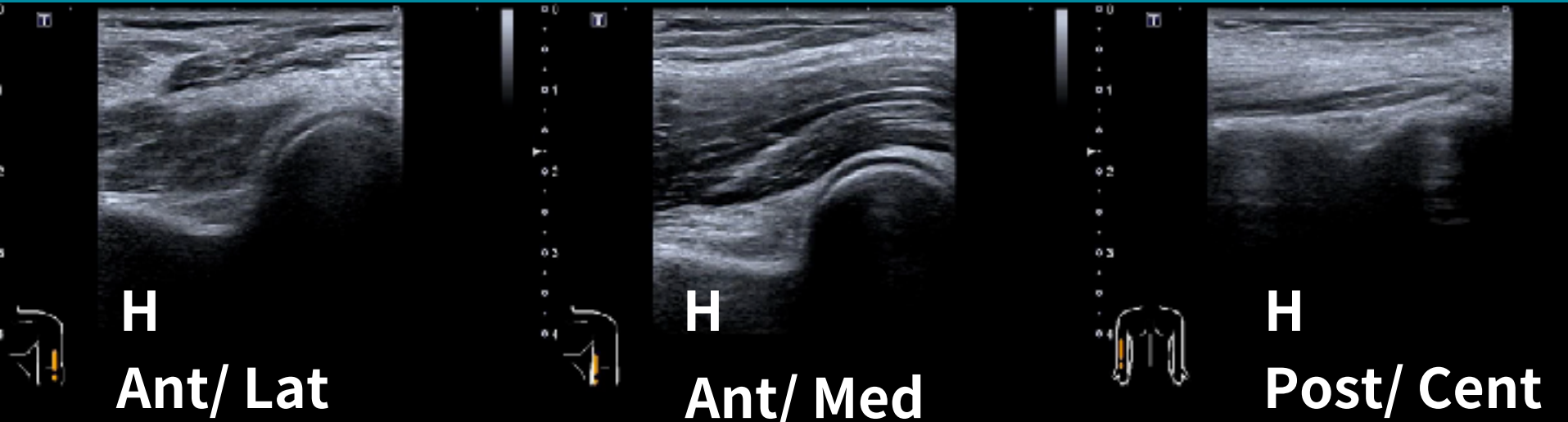
Radial fossa

Coronoid fossa

Olecranon fossa



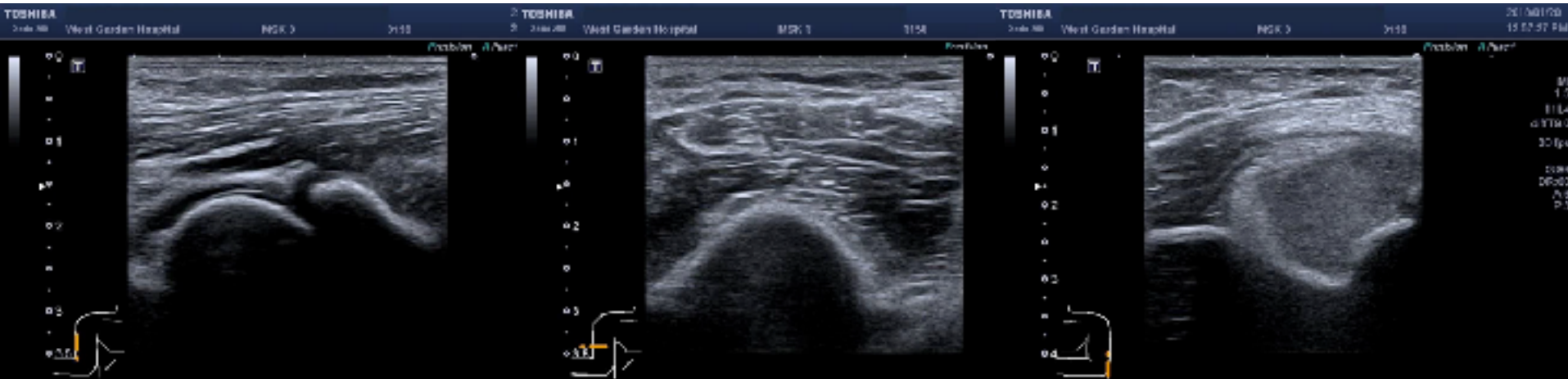Elbow effusion



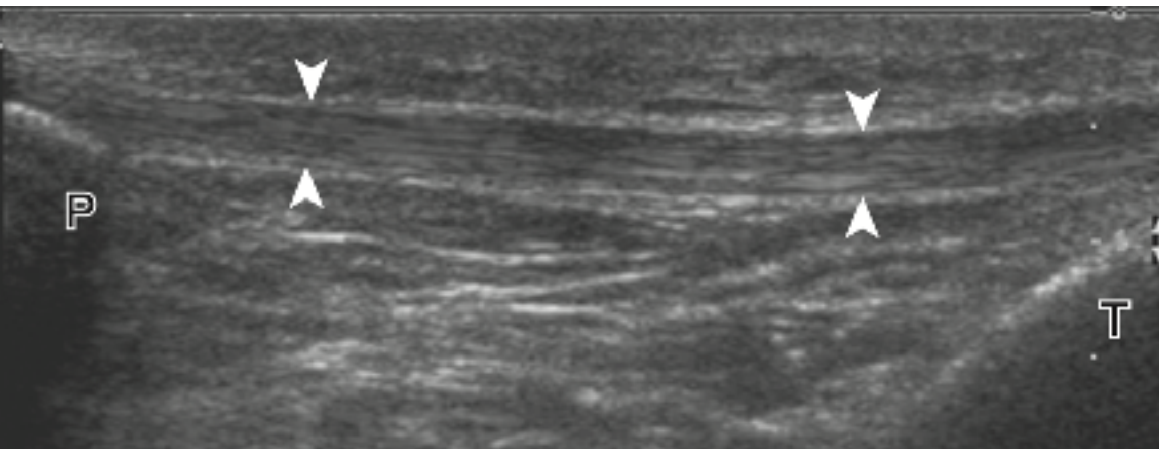
Radial fossa

Coronoid fossa

Olecranon fossa

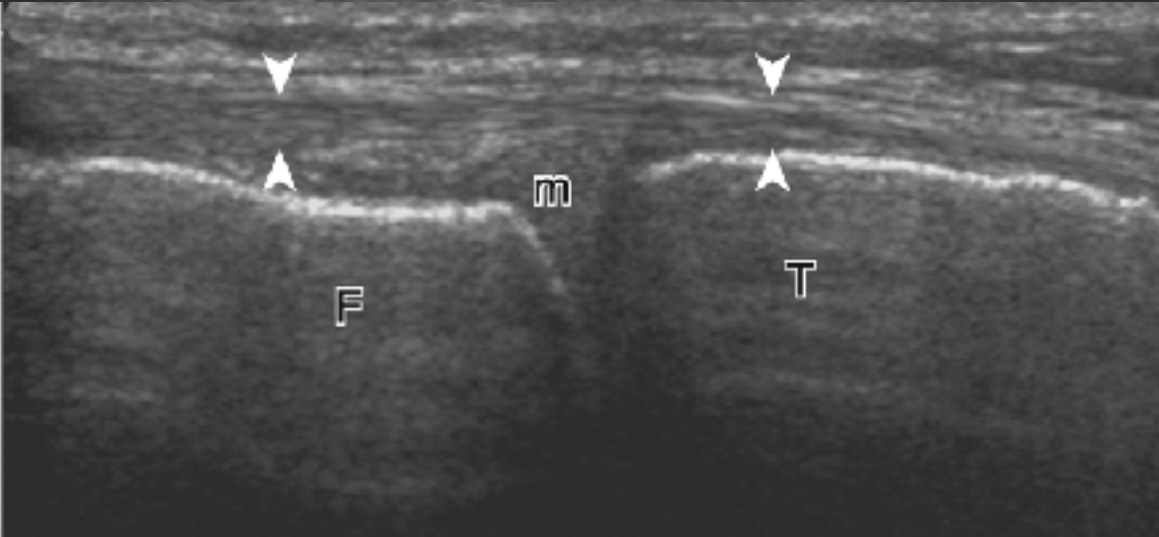


Tendon 韌帶



高回音

Fibrillar



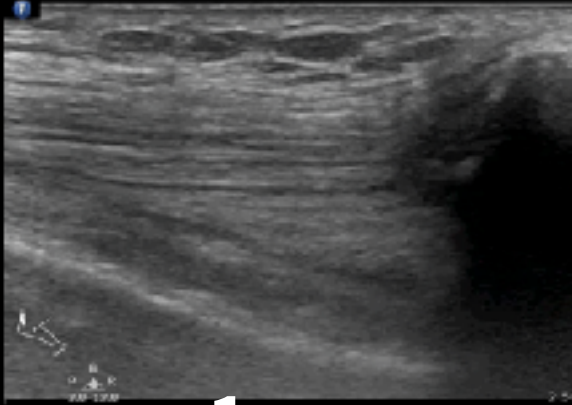
Grade of Injury

I : no fiber disruption

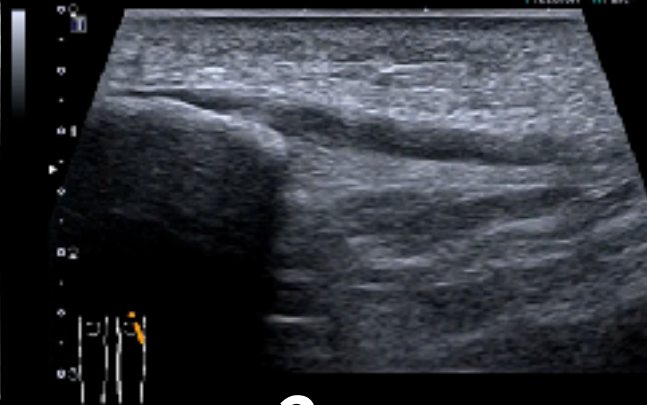
II : partial fiber disruption

III: complete fiber disruption

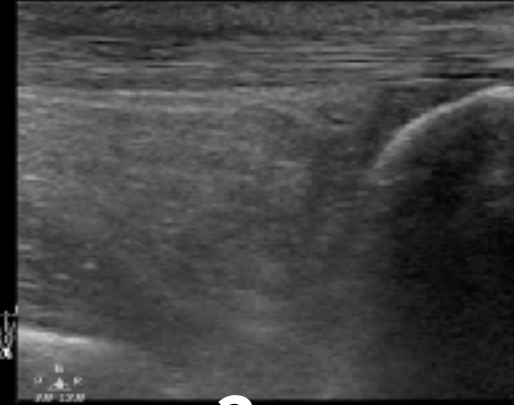Tendon



1



2

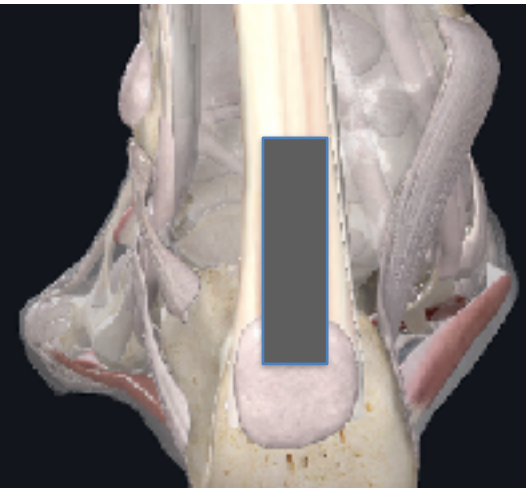
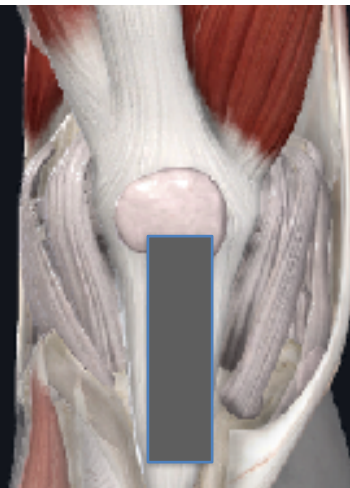
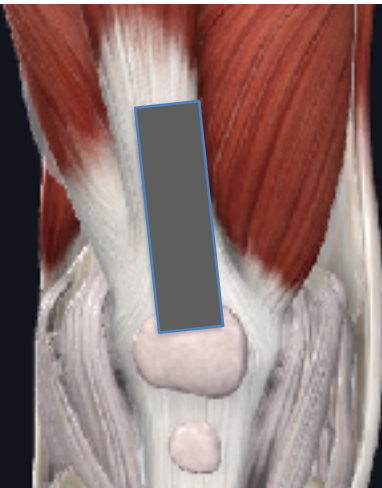
3

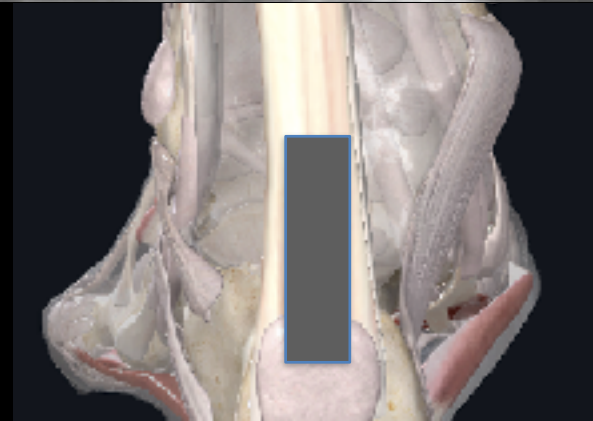
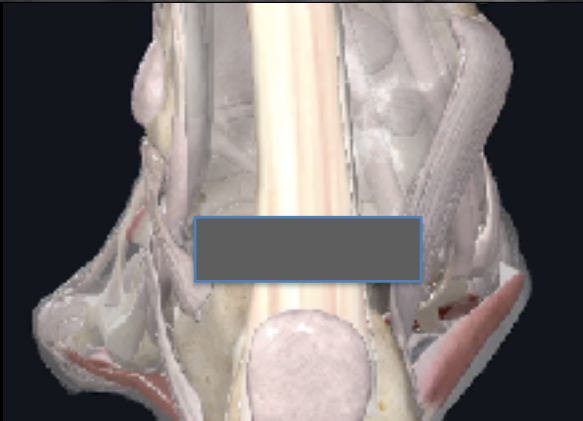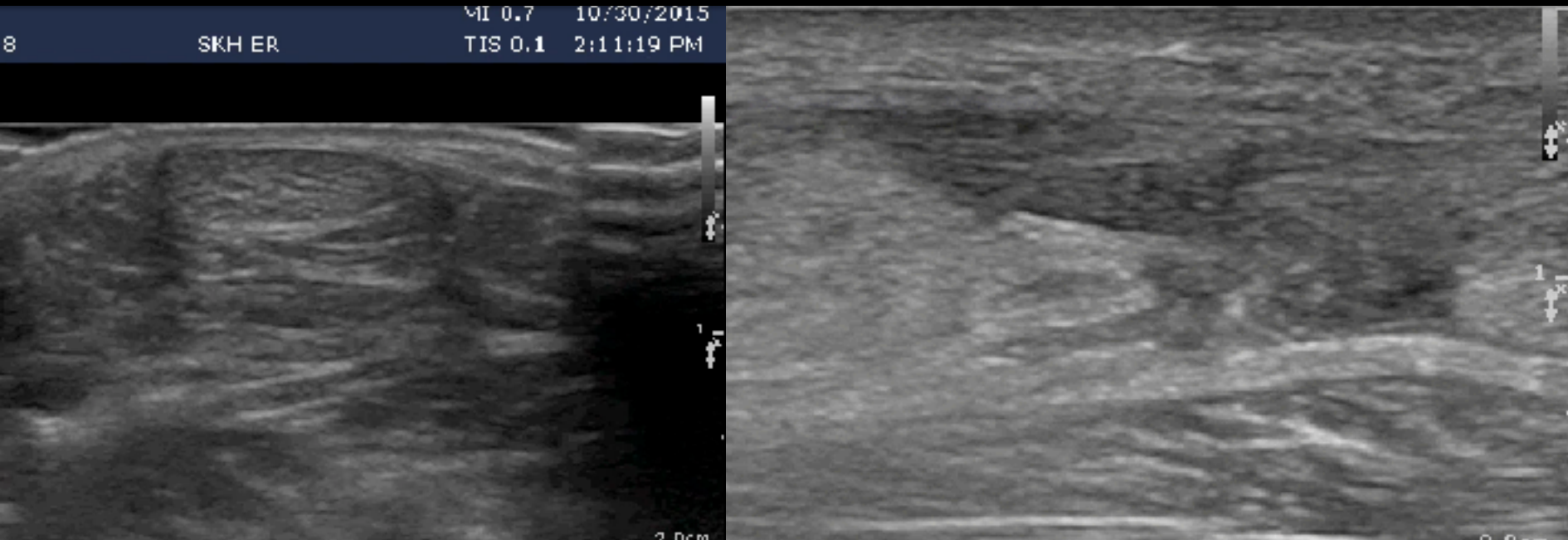
**Quadriceps
Tendon**

**Patellar
Tendon**

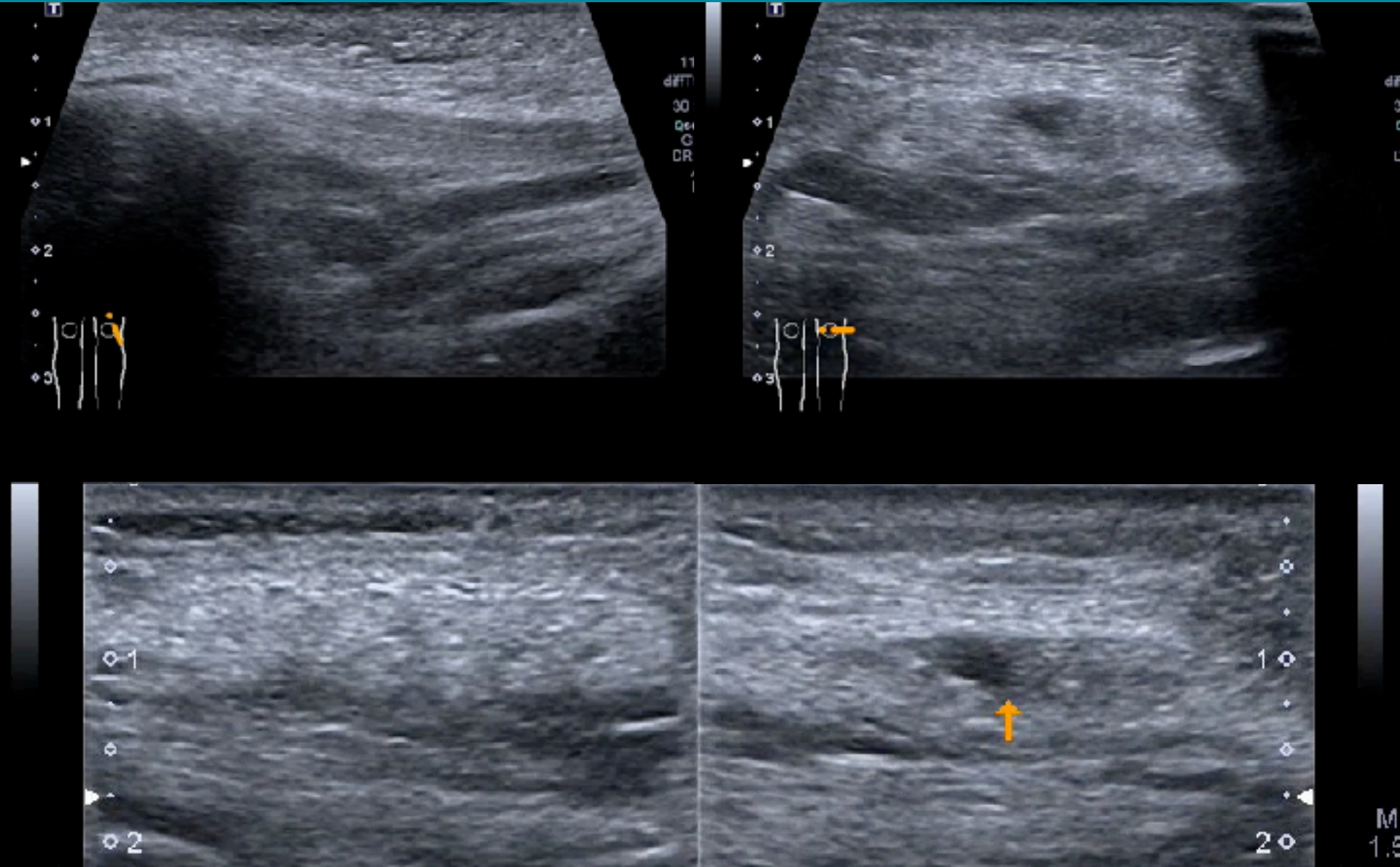
**Achilles
Tendon**



Achilles tendon rupture



Patellar tendon injury



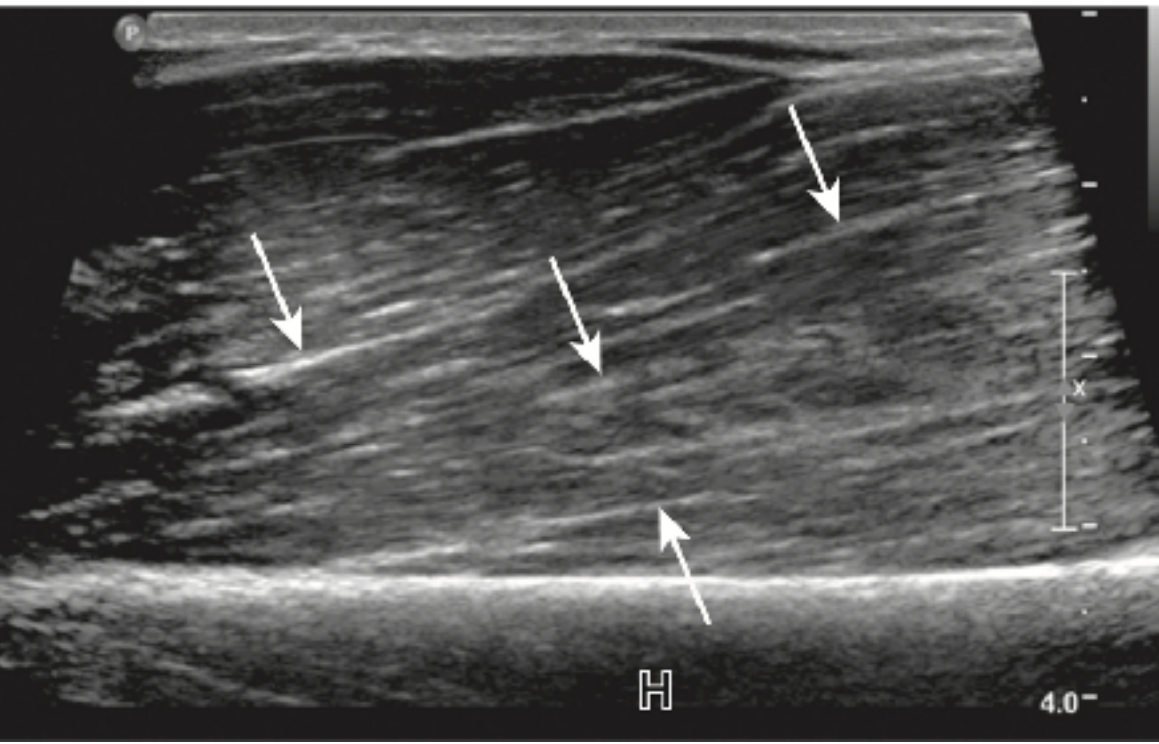
Muscle 肌肉

Grade of Injury

I : no fiber disruption

II : partial fiber disruption

III: complete fiber disruption

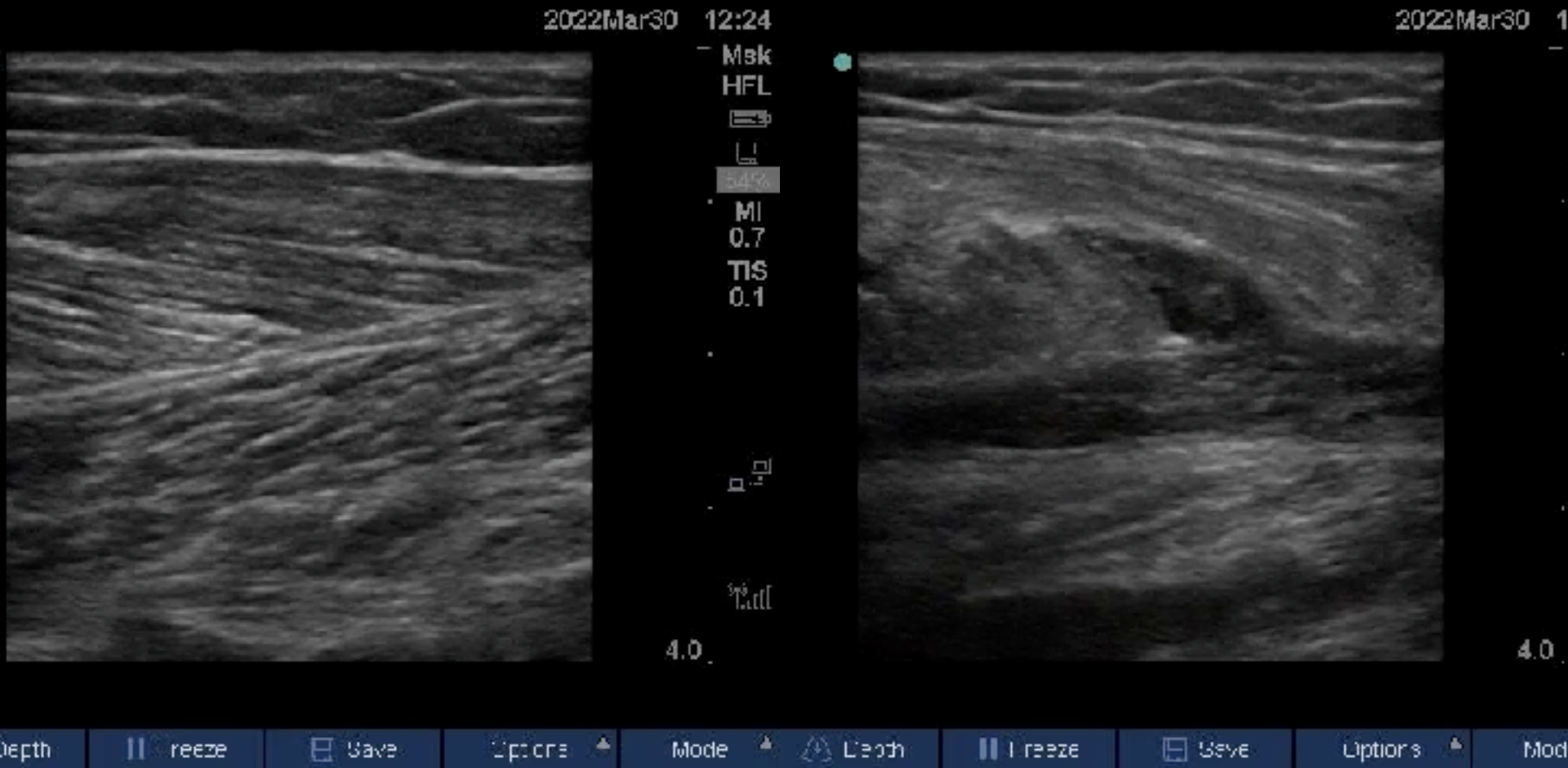


Bristal brush

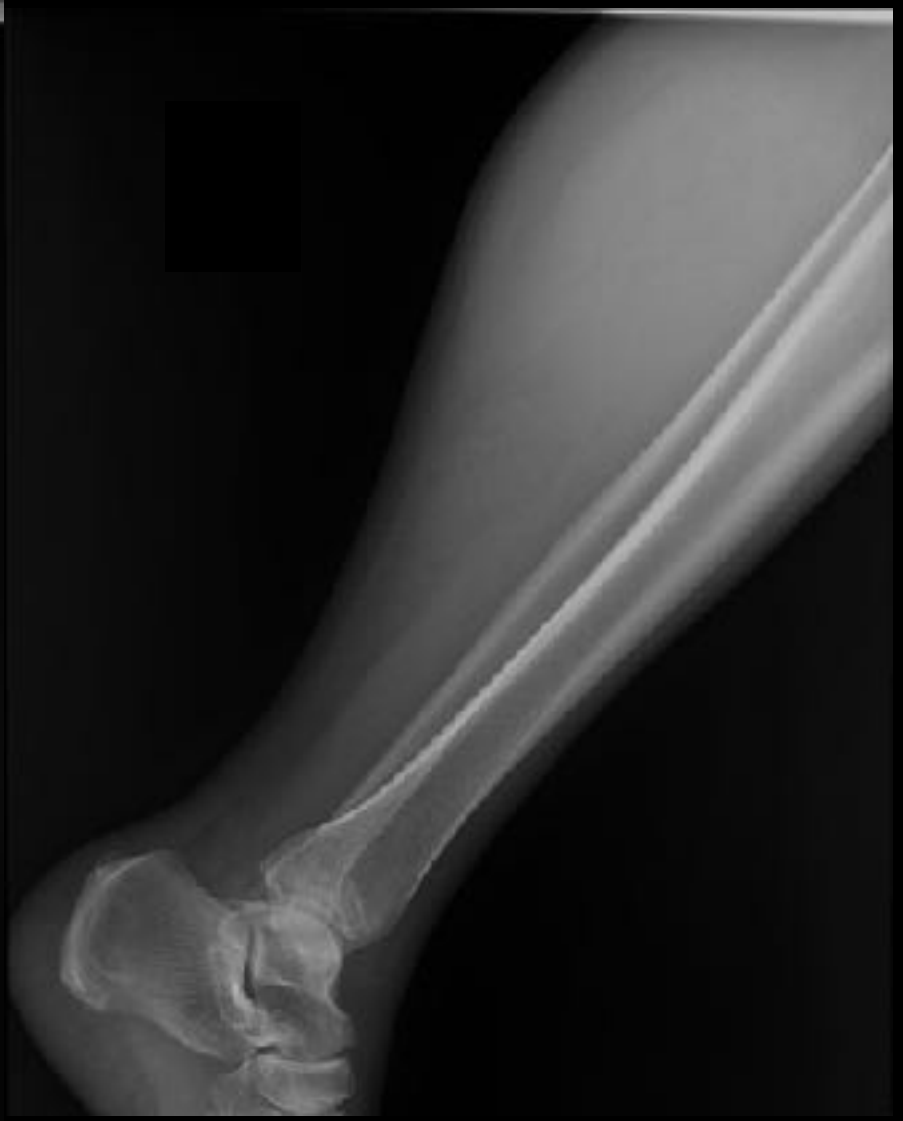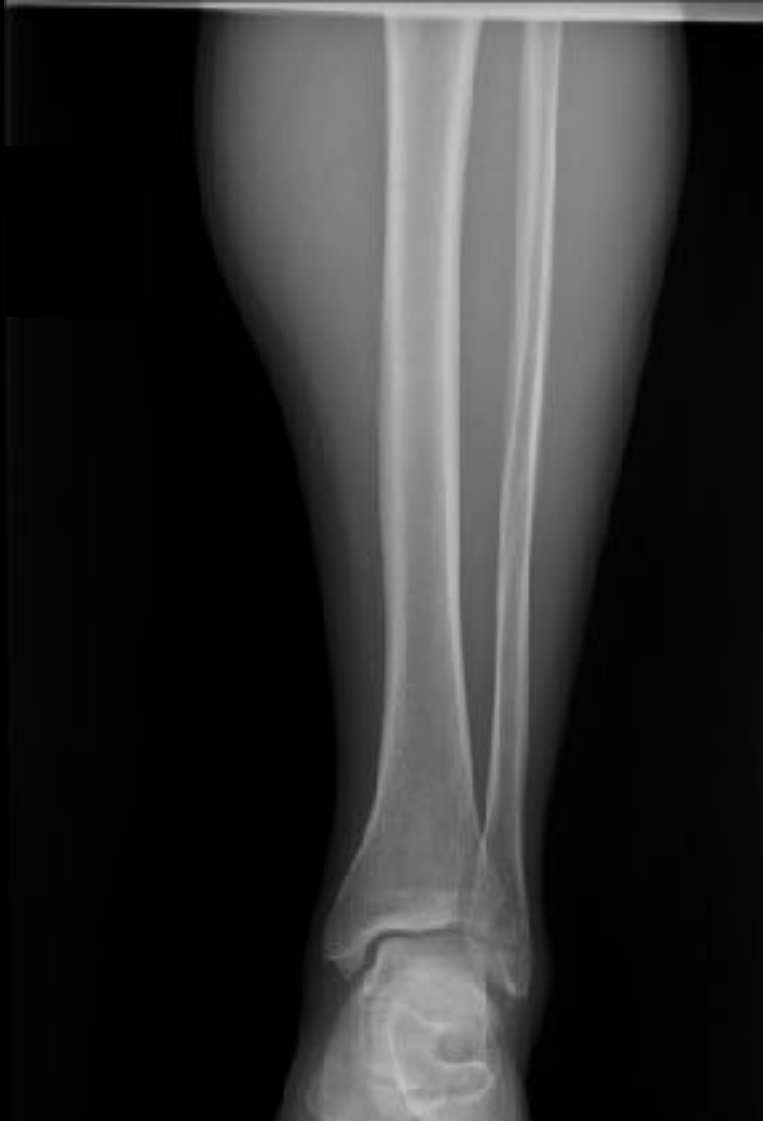Hypoechoic
mucle

Hyperechoic
fibroadipose tissue

Calf muscle tear

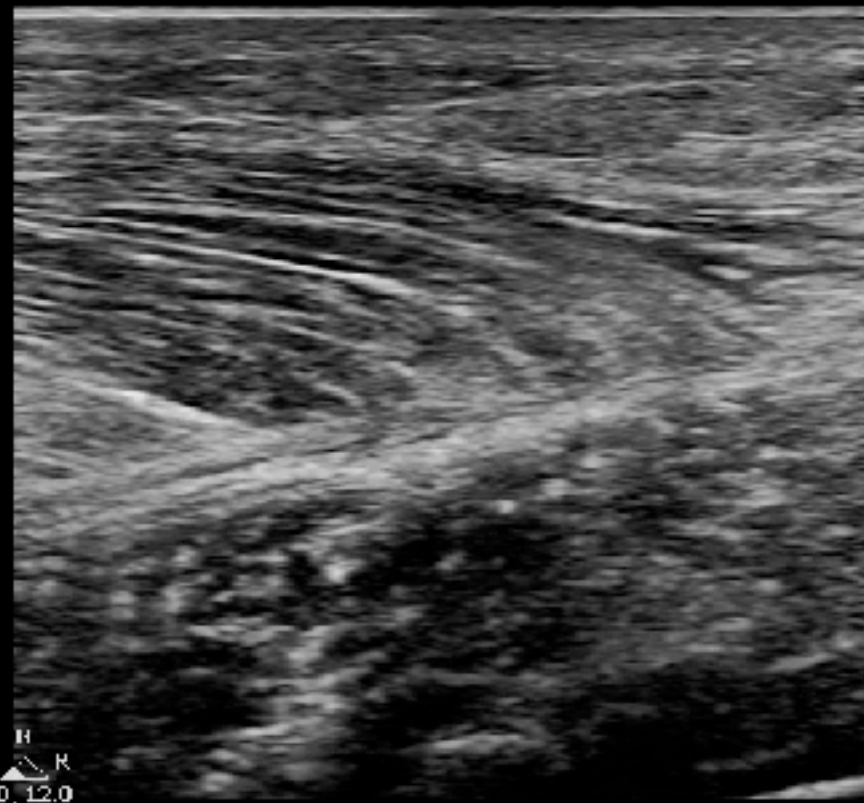

58M, right leg pain while running

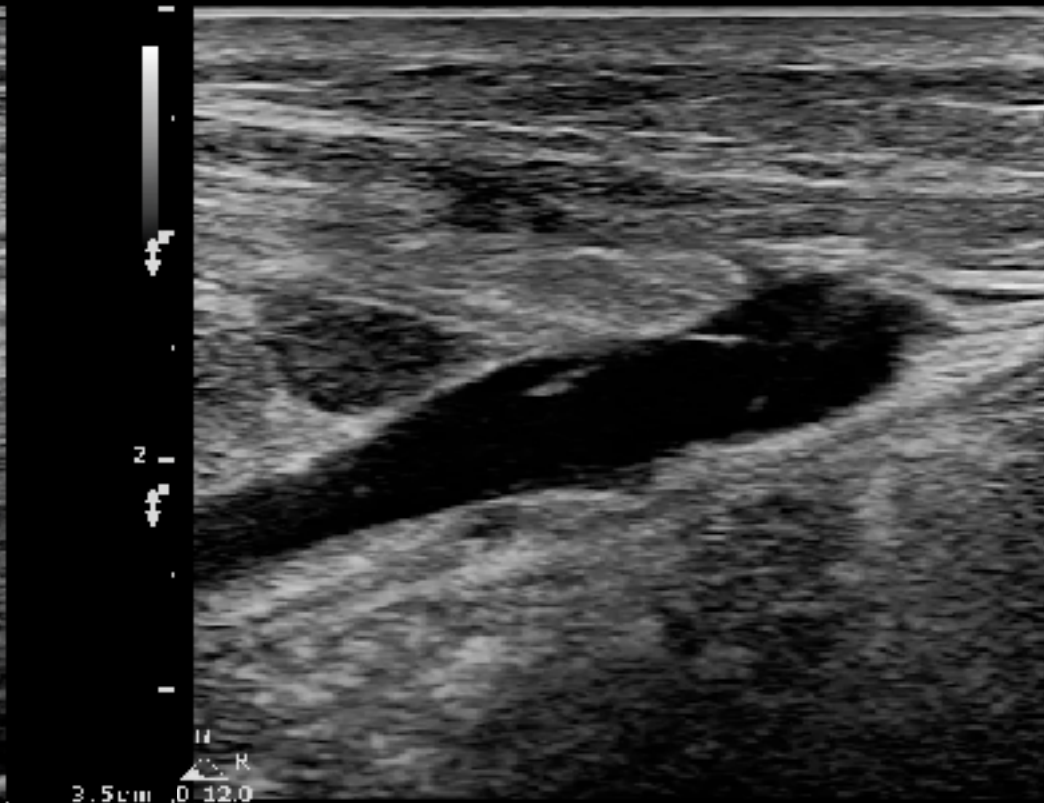


Calf muscle tear

Left calf



Right calf





FORMOSA XTREME
TRIATHLON
WY WAYPOINT



FAT



XTRI

226 游: 3.8Km - 騎180Km - 跑42km

秀姑巒溪

新白陽

武嶺

4天前
左腳不小心
撞到石頭。
致血腫疼痛



T

0

1

2

3

4

A +

B

diffT

30

Q

C

D

2021/12/01 OSHIBA

11:20:31 AM 11/10/21

2021/12/01

11:21:11 A

West Garden Hospital

MSK 3

3155

West Garden Hospital

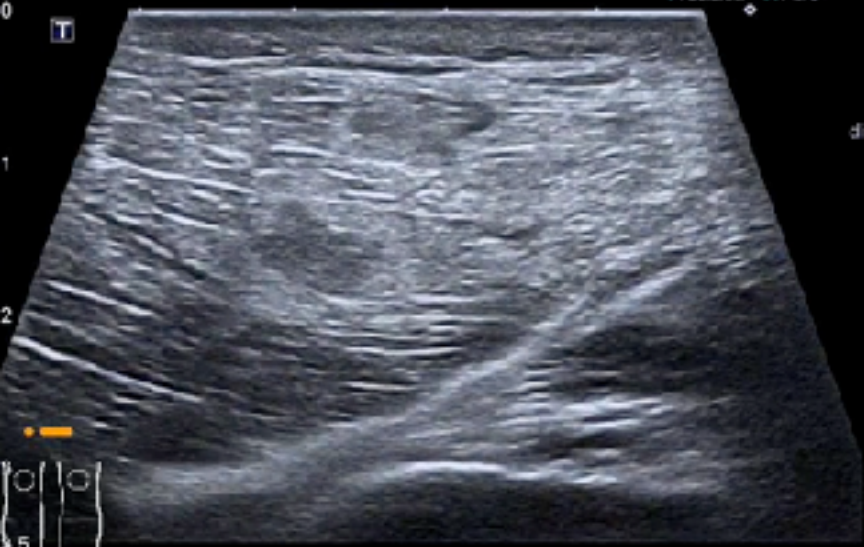
MSK 3

3155

Precision A Pure+

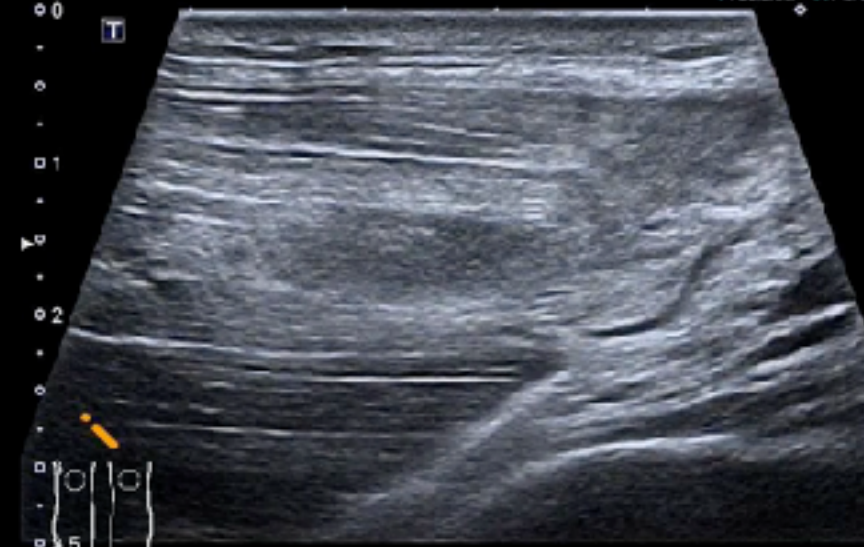Precision A Pure+

T



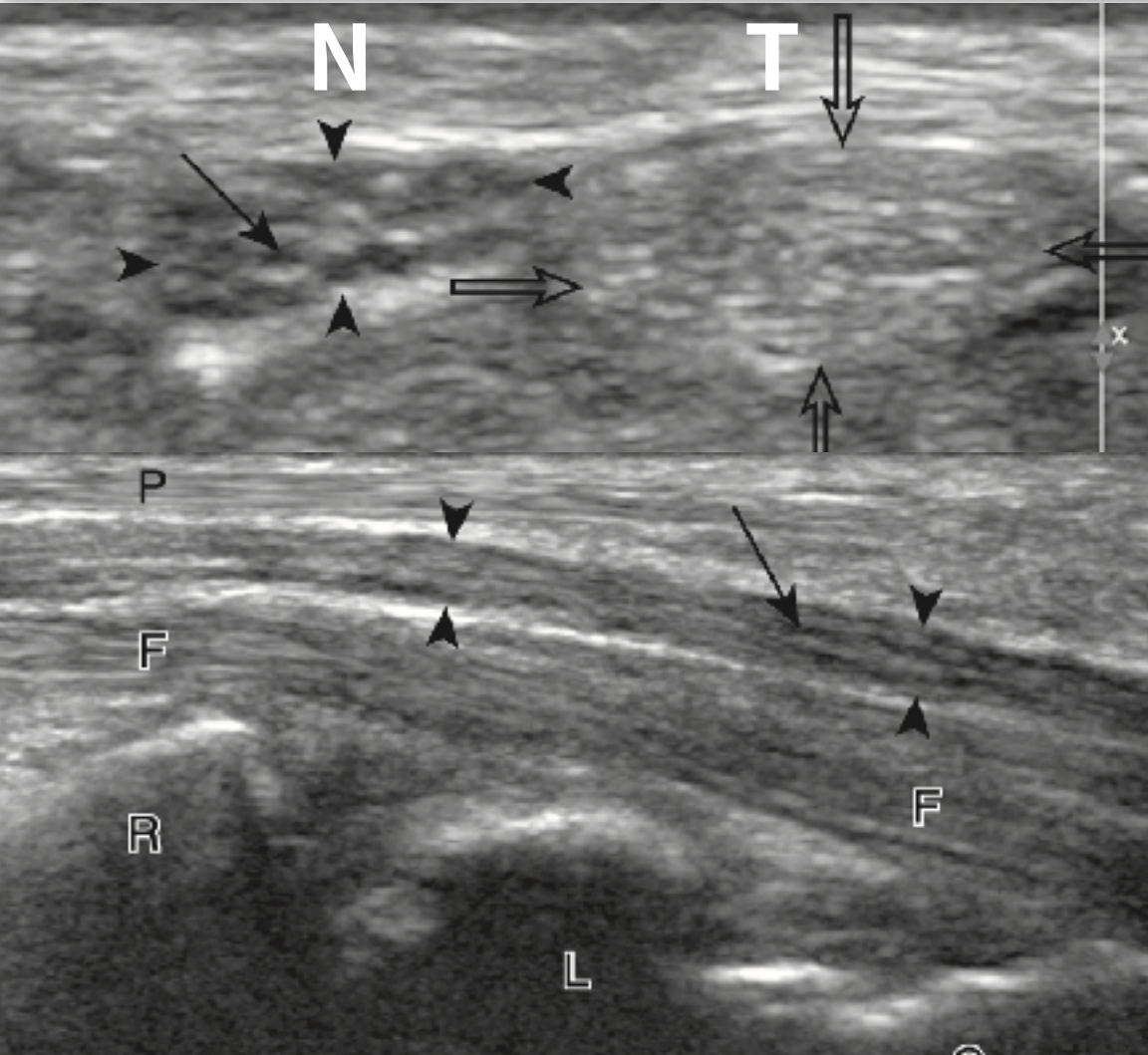
M: 1.2
IBL: 7
diffT: 14.0
30 fps
Qscan
G: 20
DR: 60
A: 6
P: 3

T



IBL: 7
diffT: 14.0
30 fps
Qscan
G: 20
DR: 60
A: 6
P: 3

Nerve



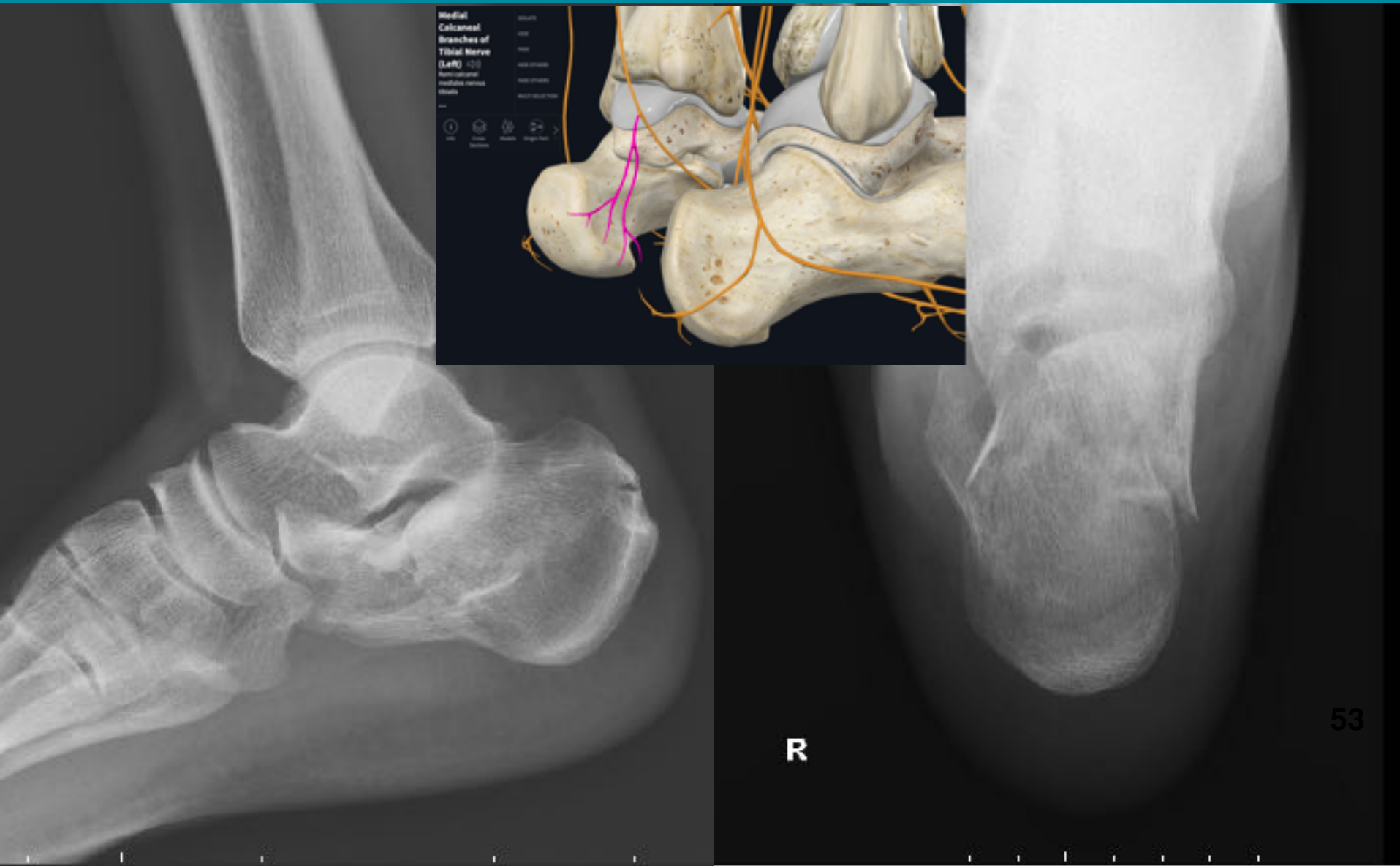
Hypoechoic

Hyperechoic

Honeycomb

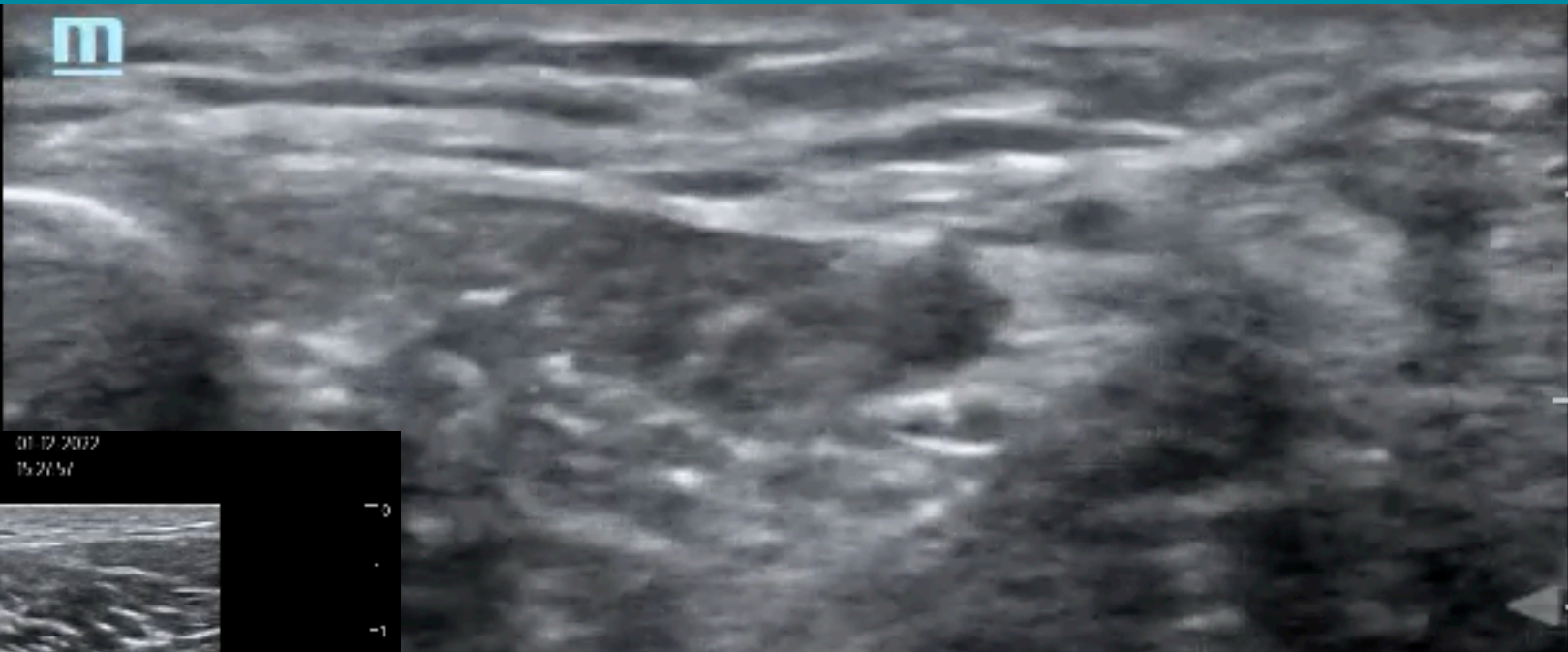
Fibrillar

34M，貨車車斗跌下，足踝腫痛

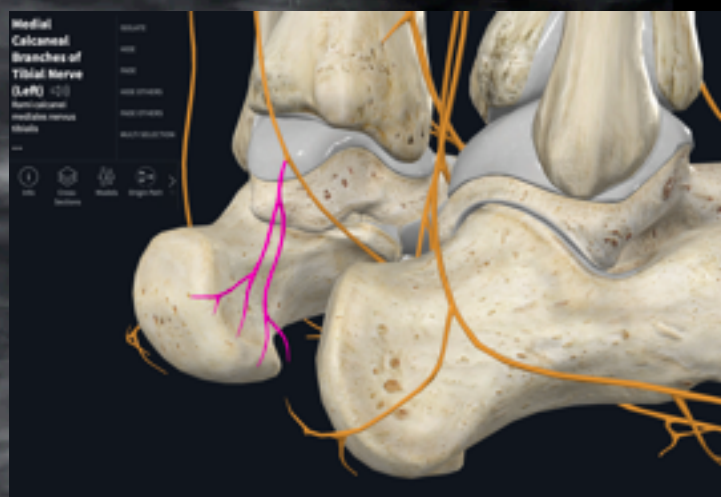
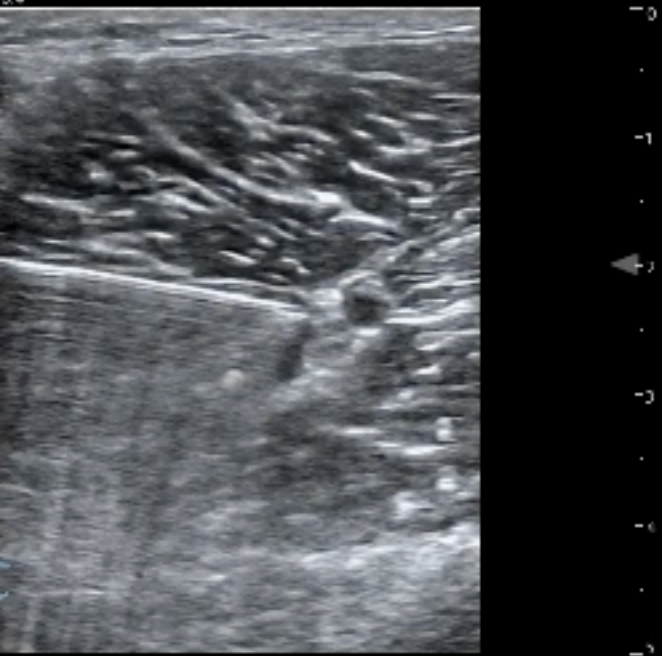


Tibial nerve block

B
F5.4~11.5
DR 105
FR 41
D 3.0
G 50



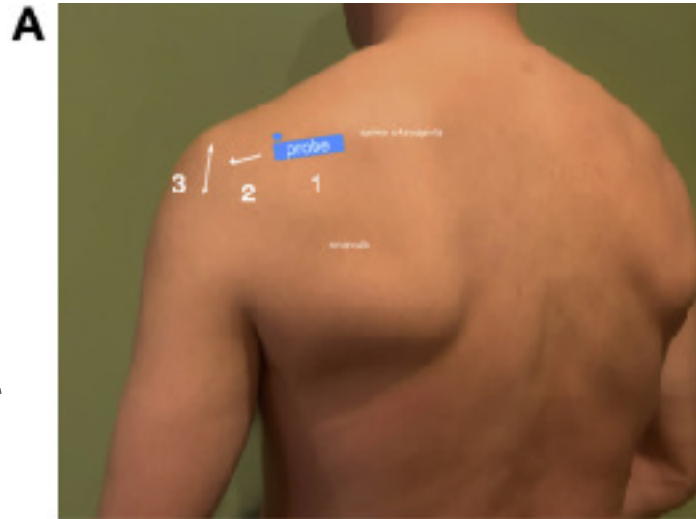
60Hz 34Years 01.12.2022
0.4 Nerve 15.21.57



Musculoskeletal Ultrasonography to Diagnose Dislocated Shoulders: A Prospective Cohort

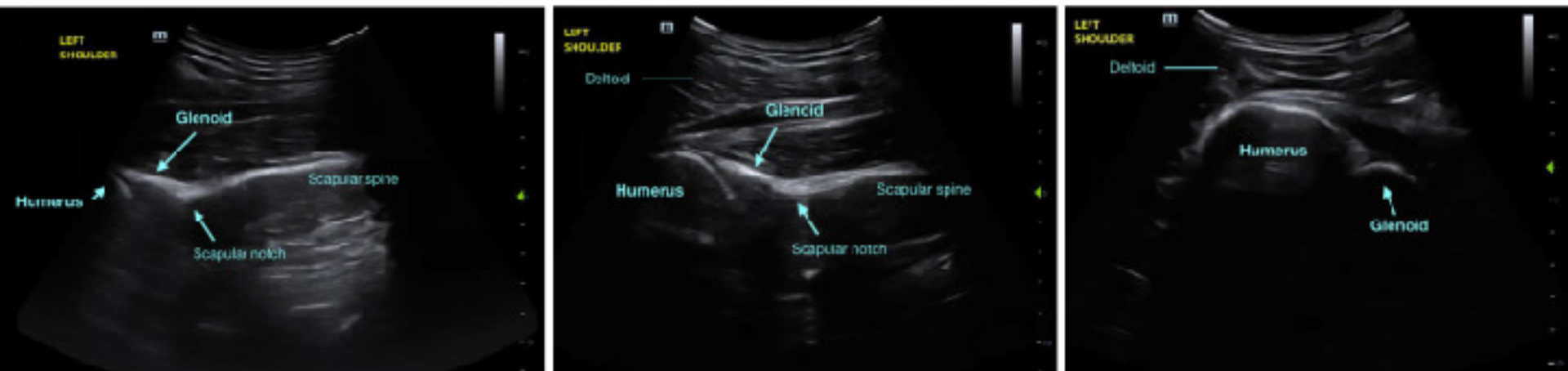Michael A. Secko, MD, RDMS*; Lindsay Reardon, MD; Michael Gottlieb, MD; Eric J. Morley, MD; Mathew R. Lohse, MD; Henry C. Thode, Jr, PhD; Adam J. Singer, MD

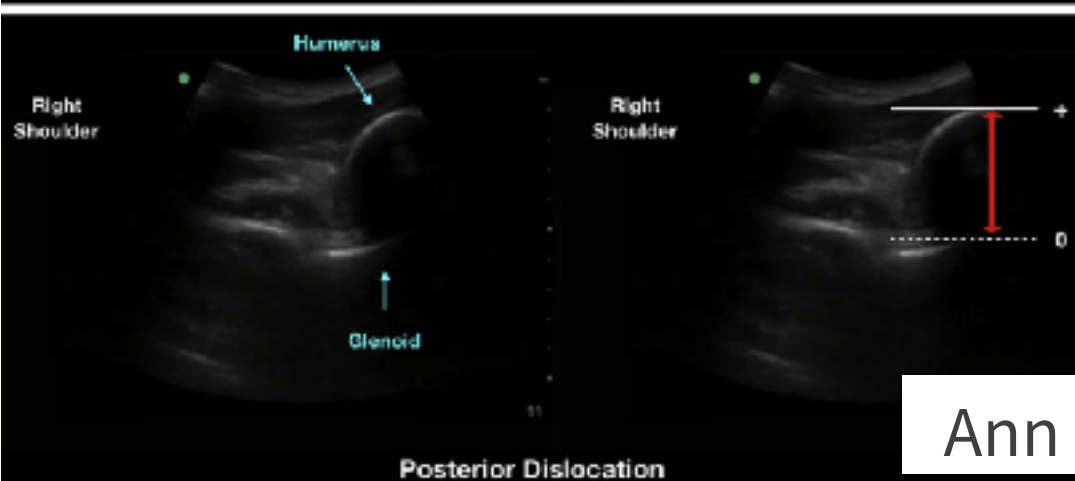
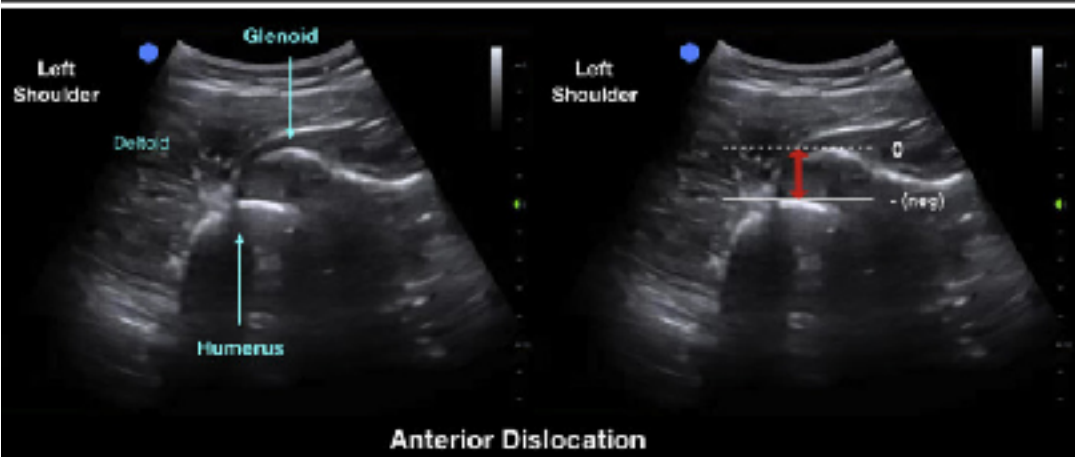
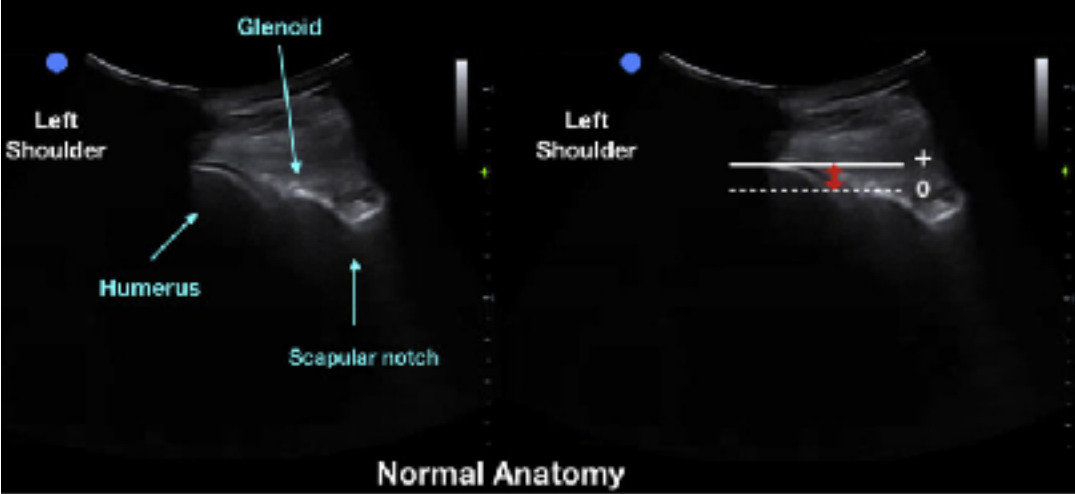
Multicenter
Prospective
Observational



65 patients

B





Sensitivity 100%
Specificity 100%

Sens (Fx) 92%
Spes (Fx) 100%

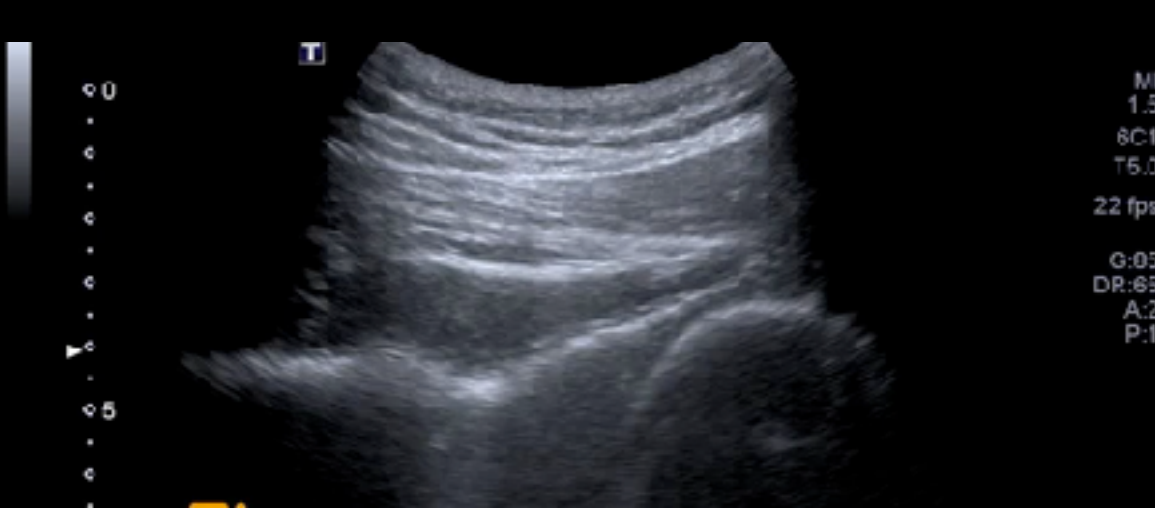
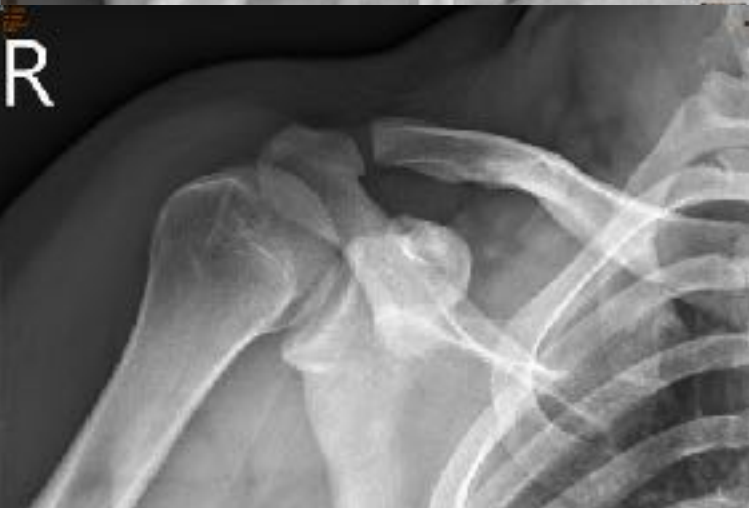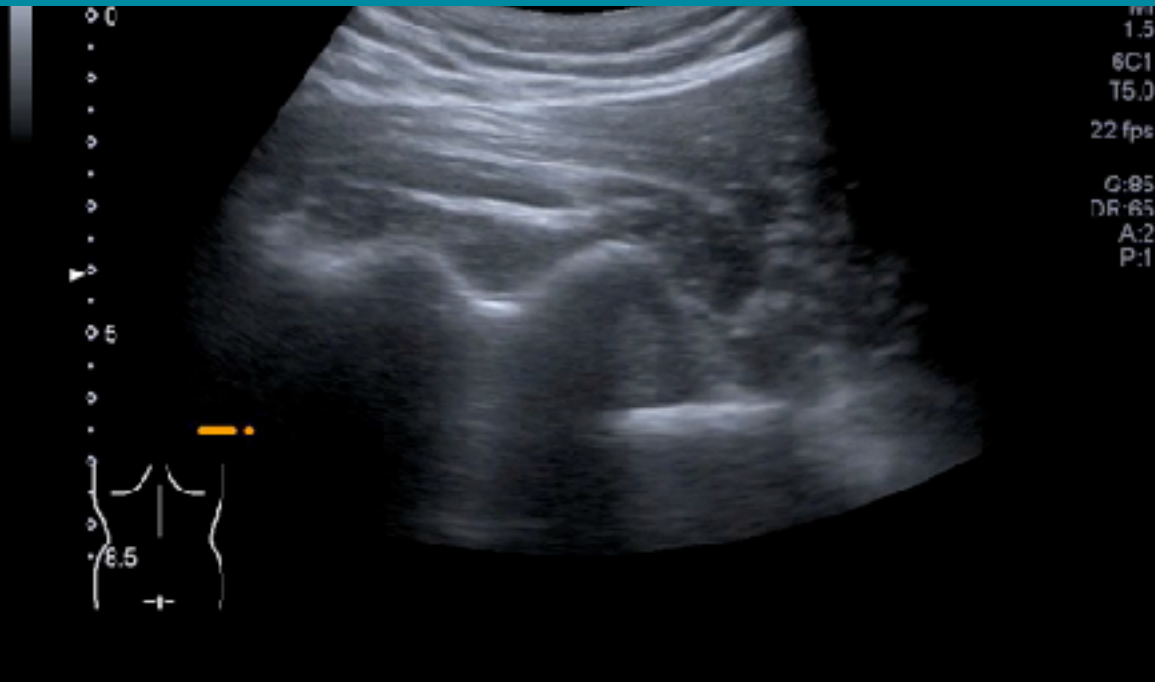
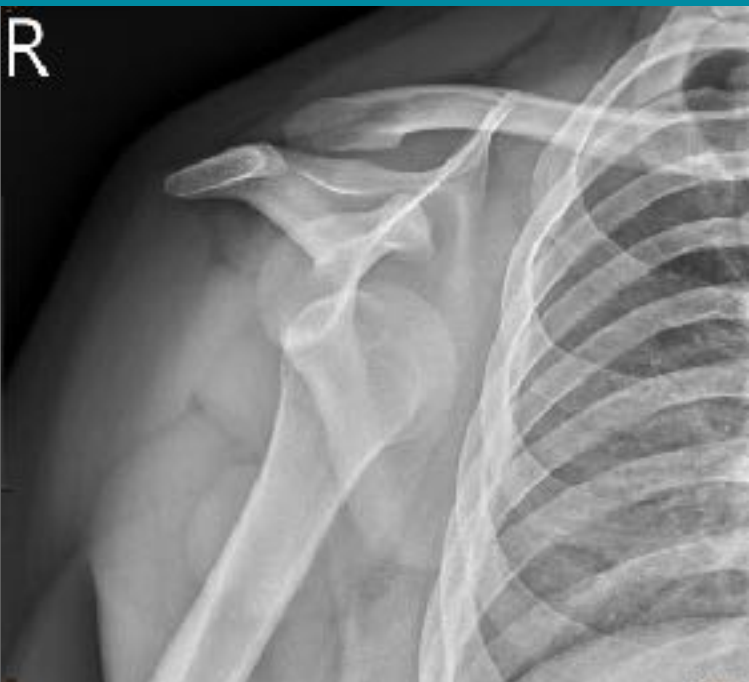Median 19s

GH(d-A) -1.83cm

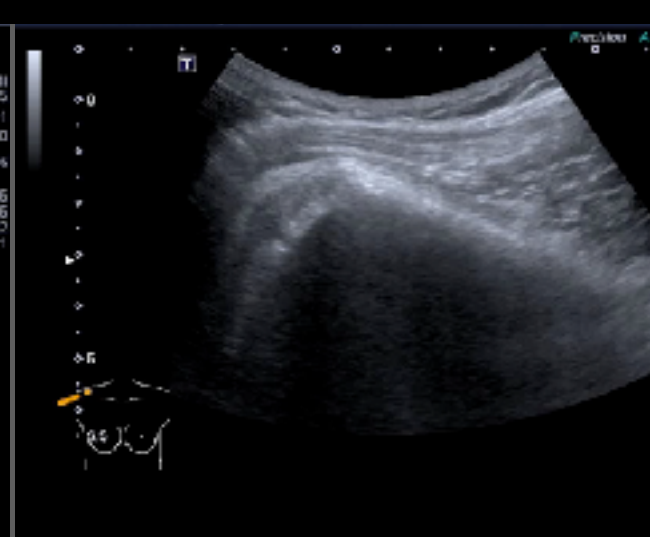
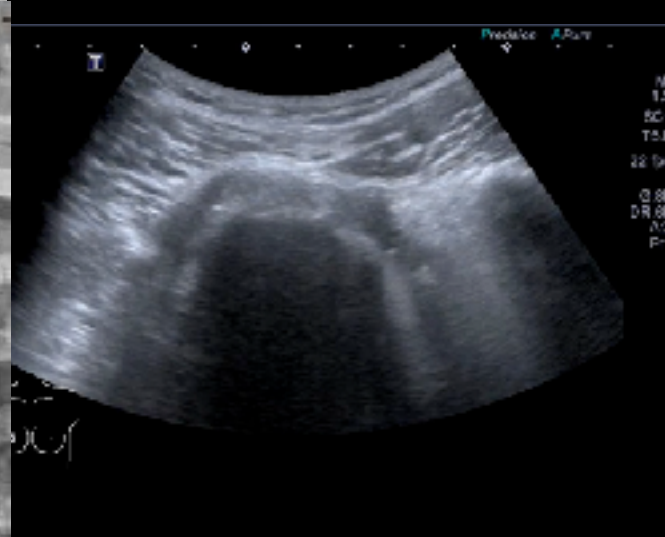
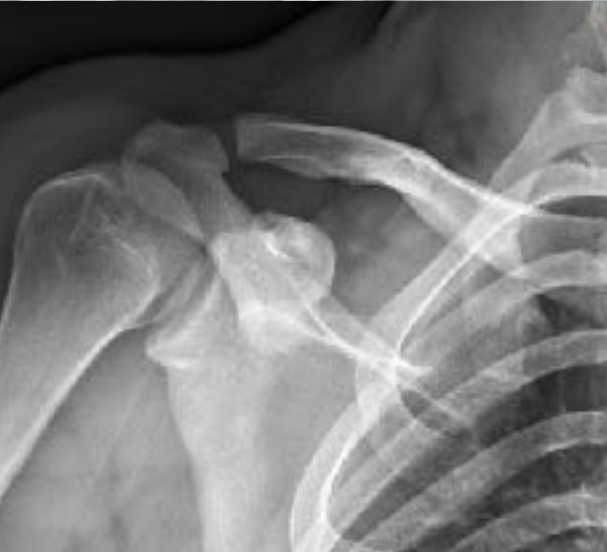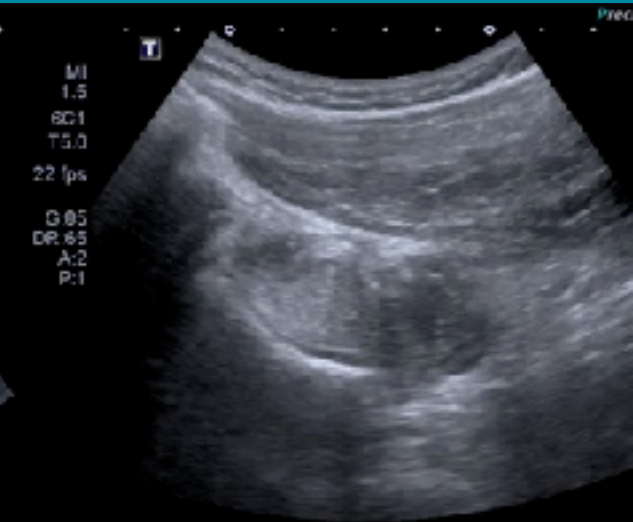
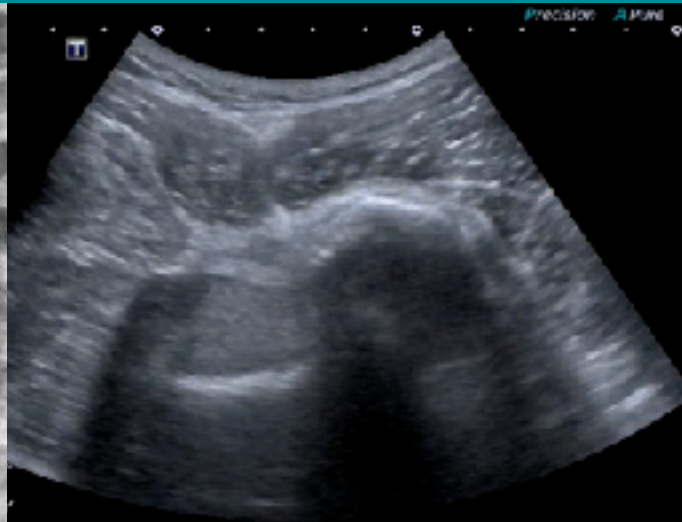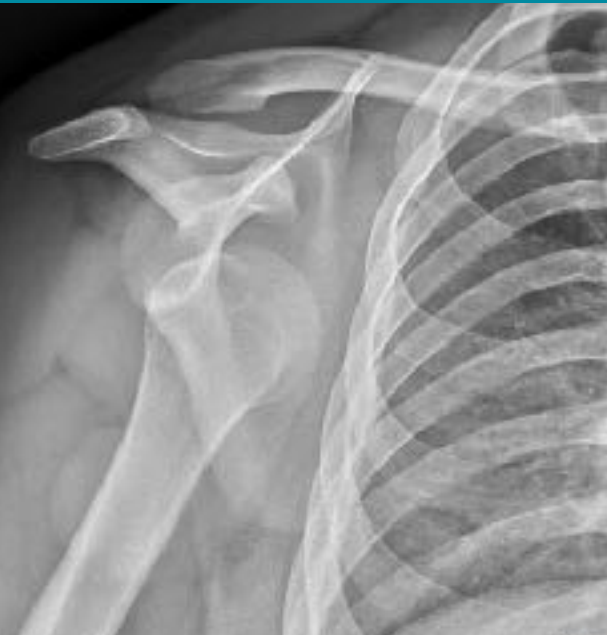GH(d-N) 0.22cm

GH(d-P) 3.3cm

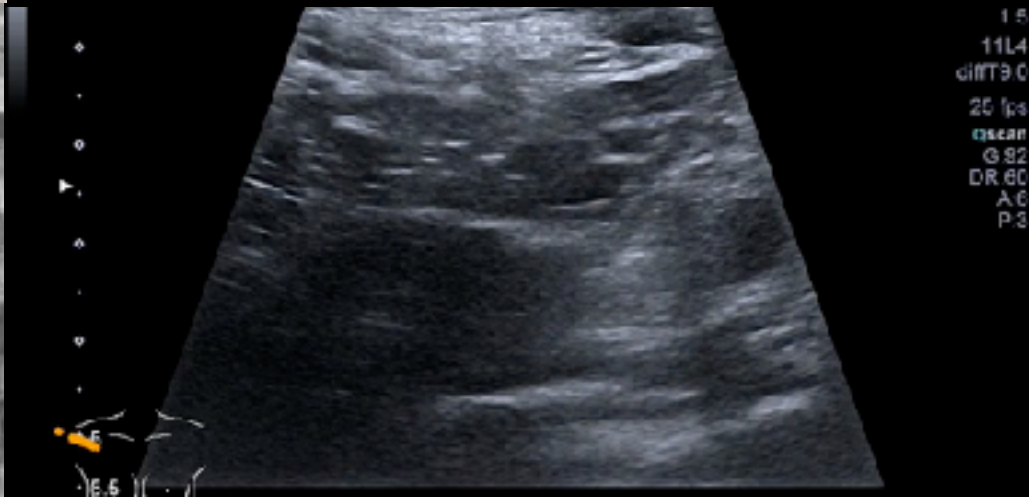
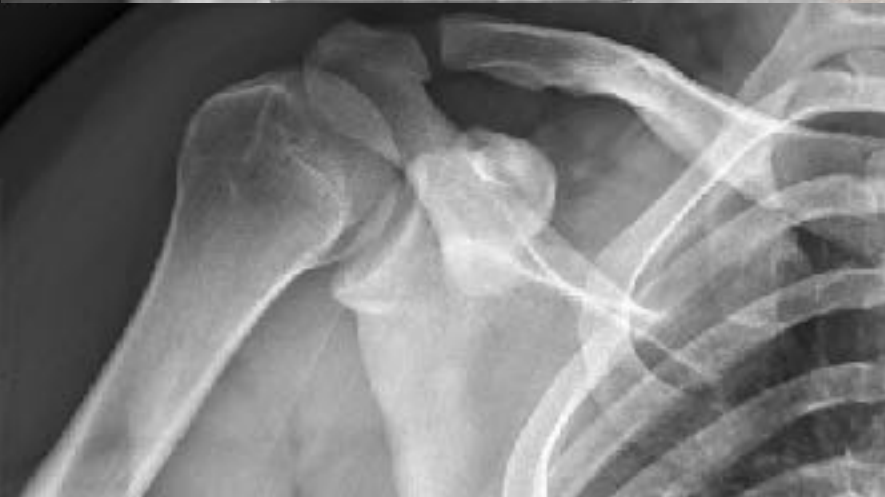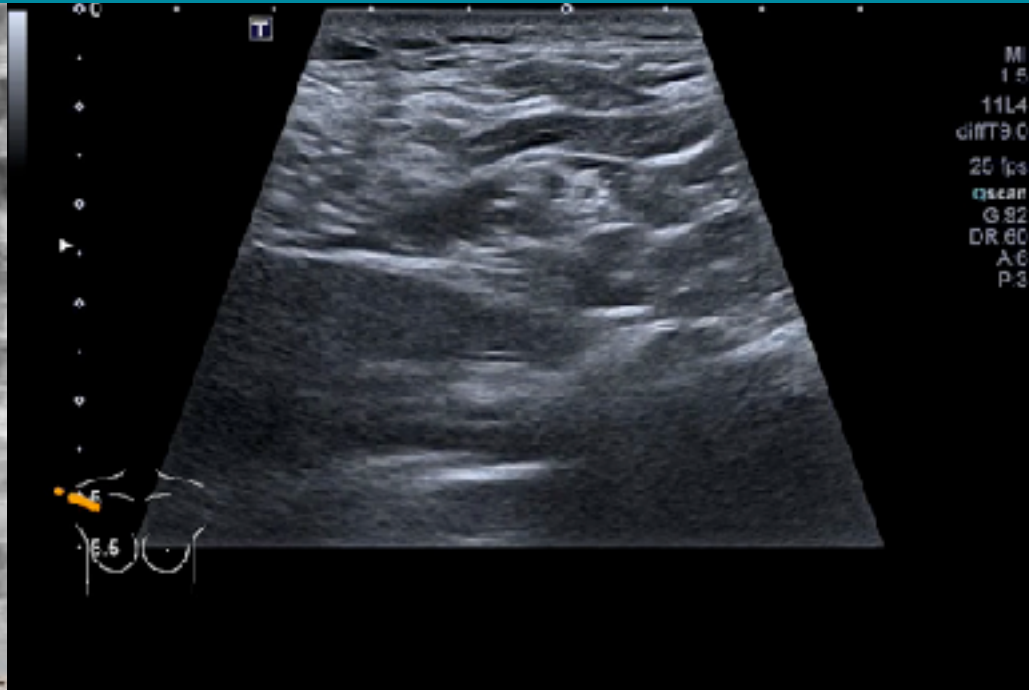
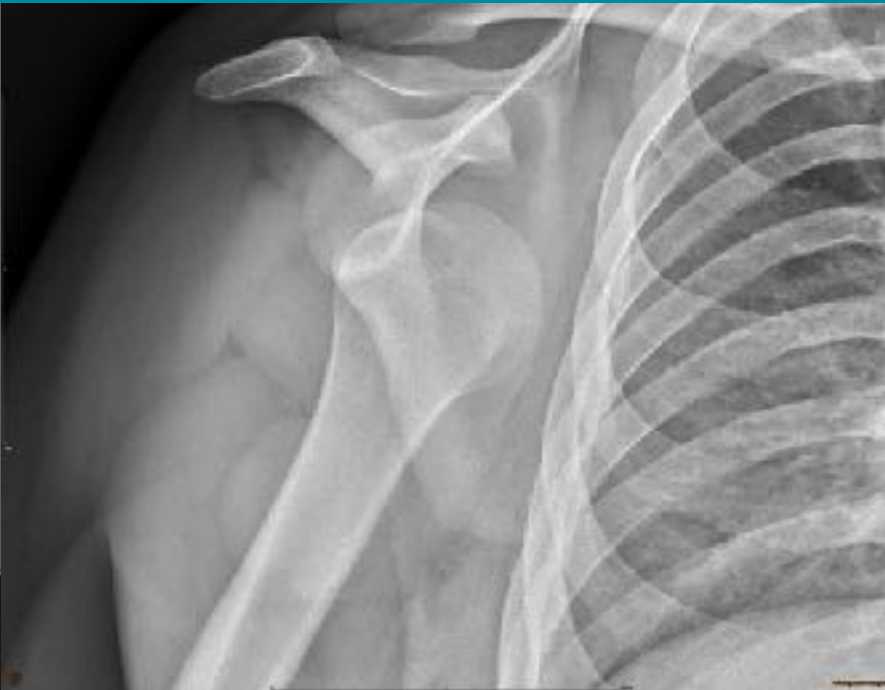M/20, 工作時從階梯滑下用手去抓致右肩脫位



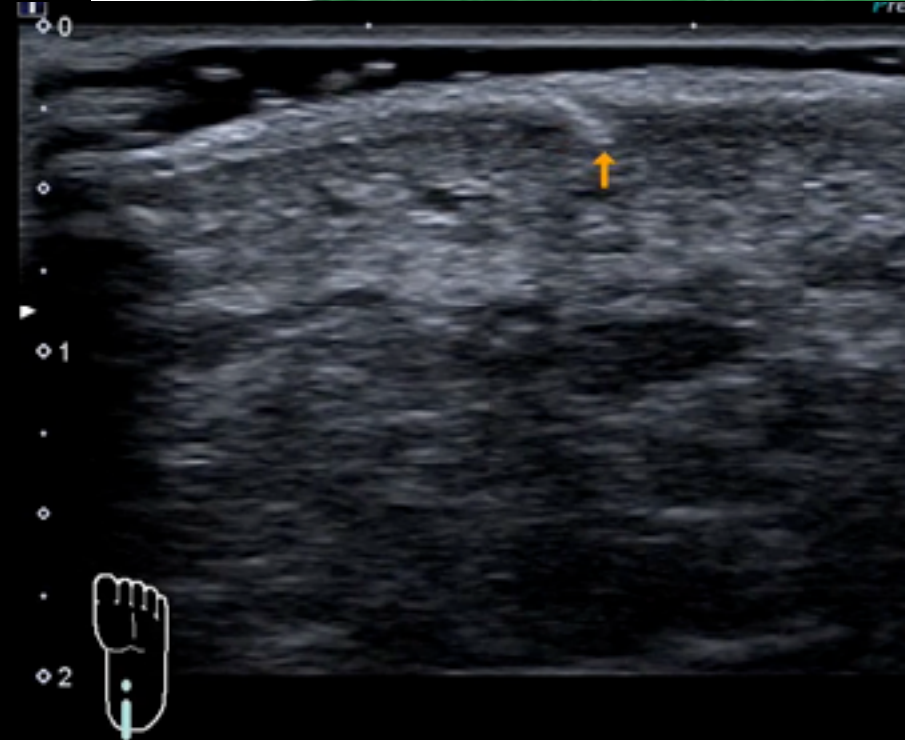
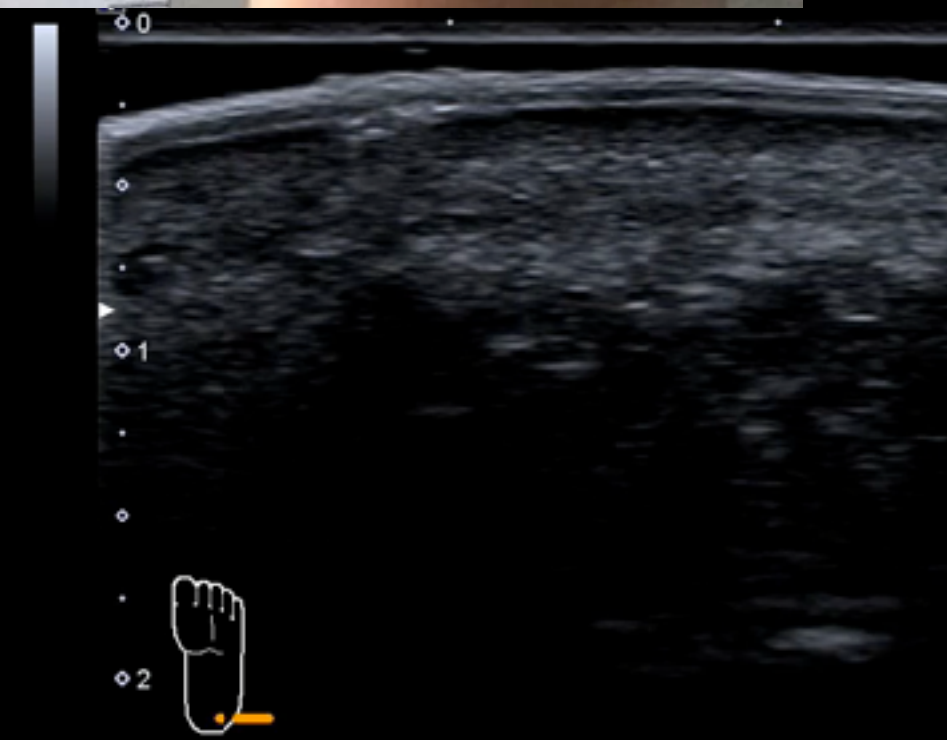
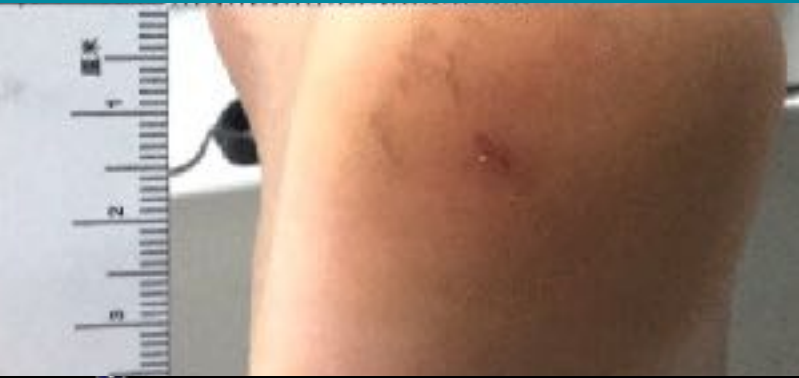Anterior approach for diagnosis, block & reduction

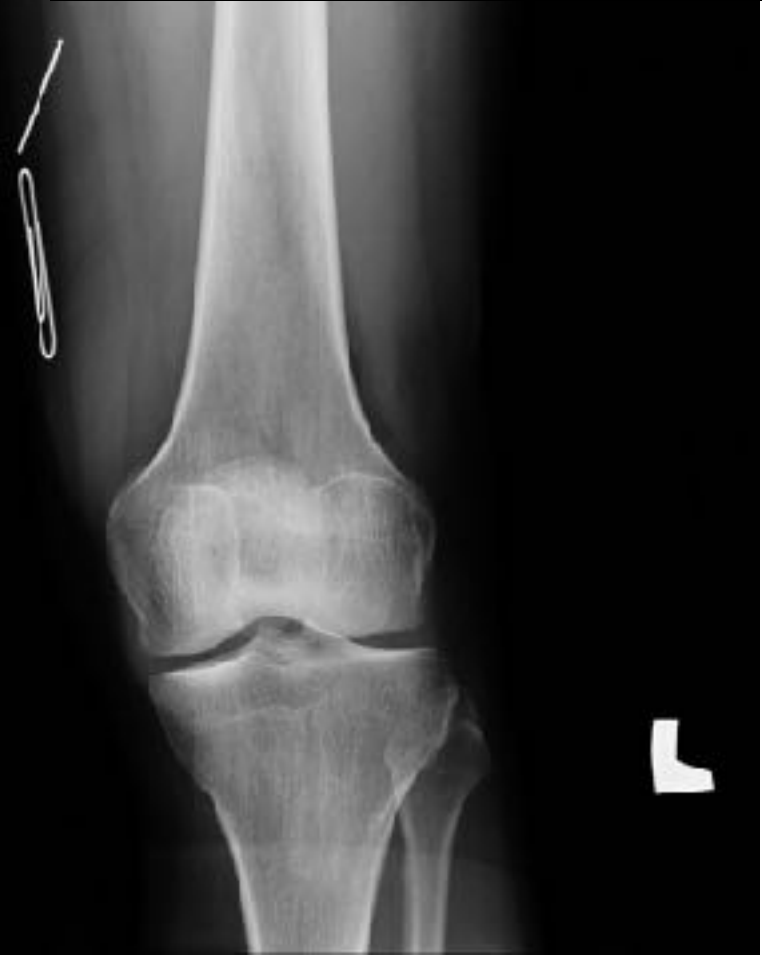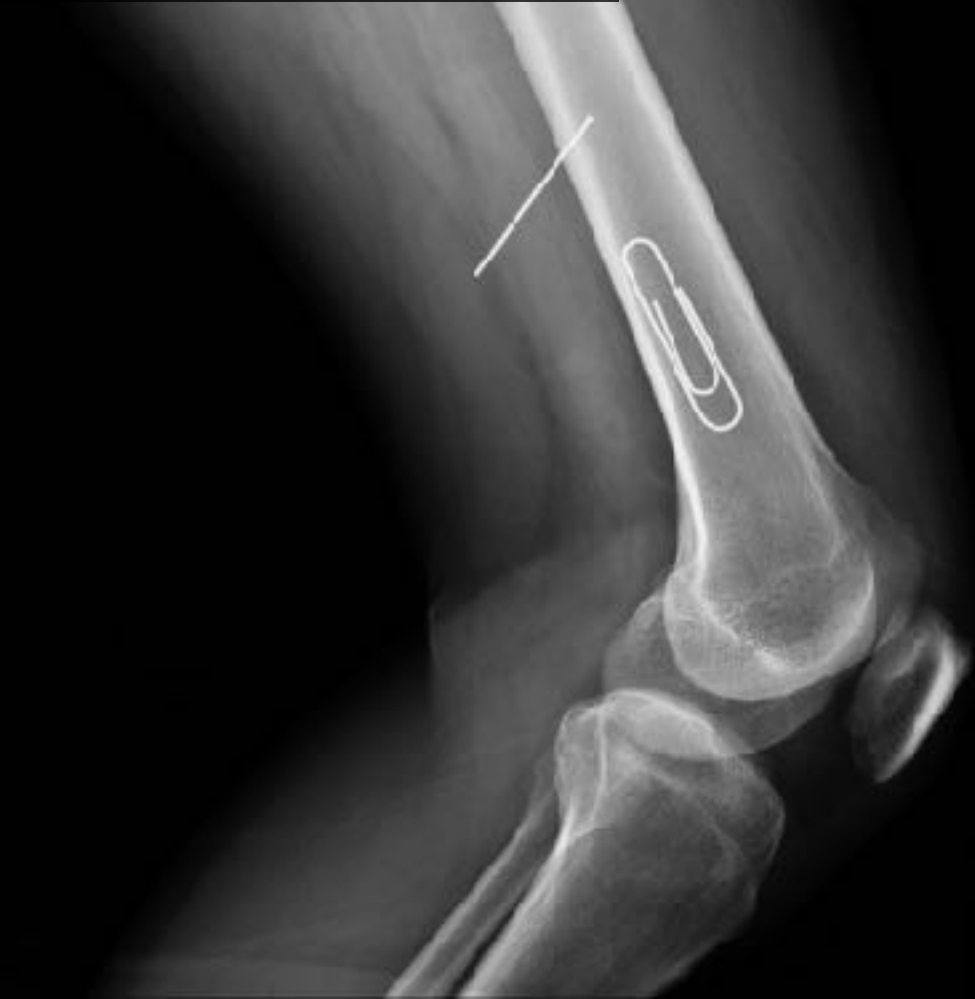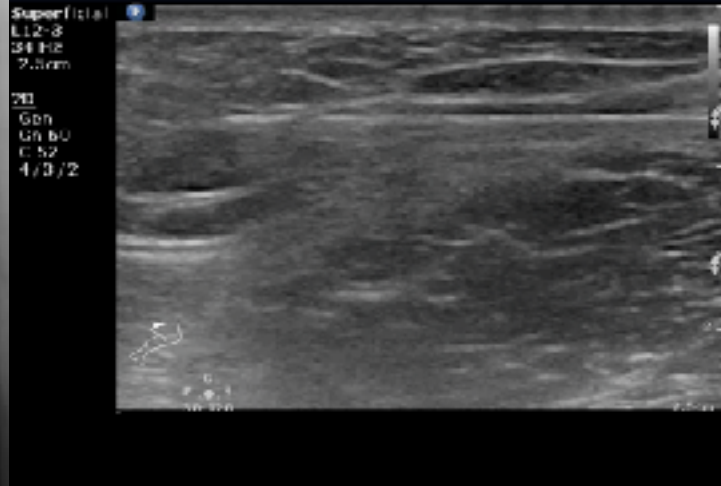
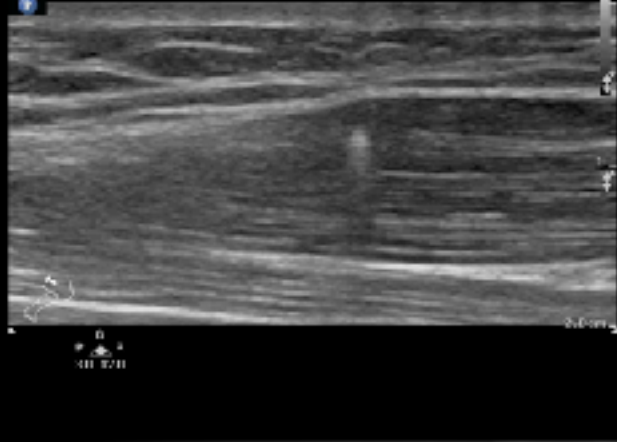


Supraclavicular brachial plexus block



踩到碎玻璃，覺得有異物



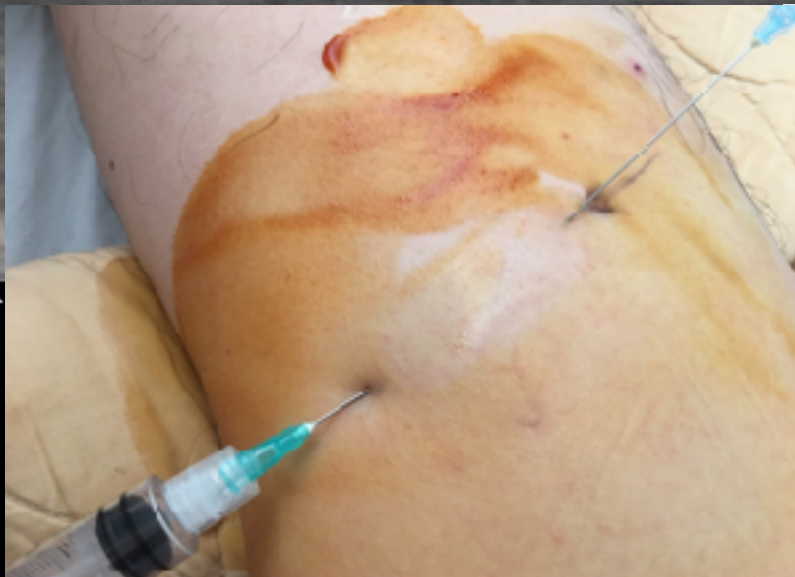
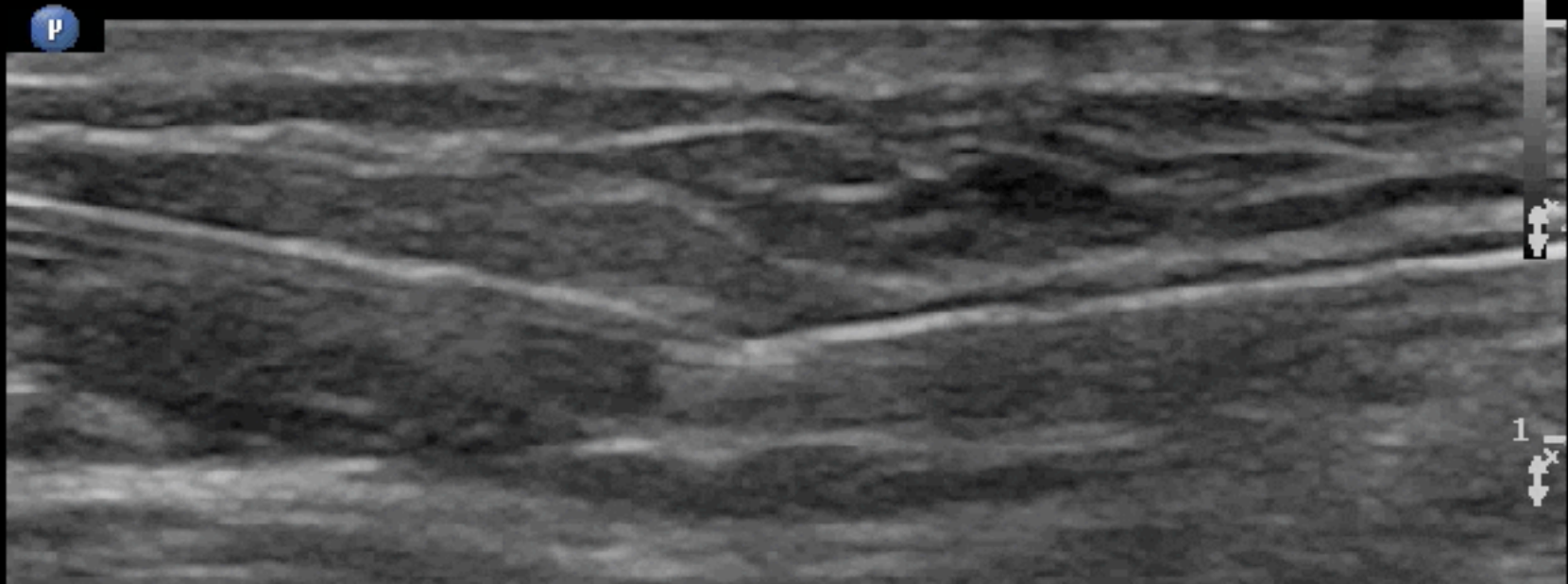

Localization

2 needle

Removal

17.5
34 Hz
2.0cm
D
Gen
Gn 60
C 52
4/3/2

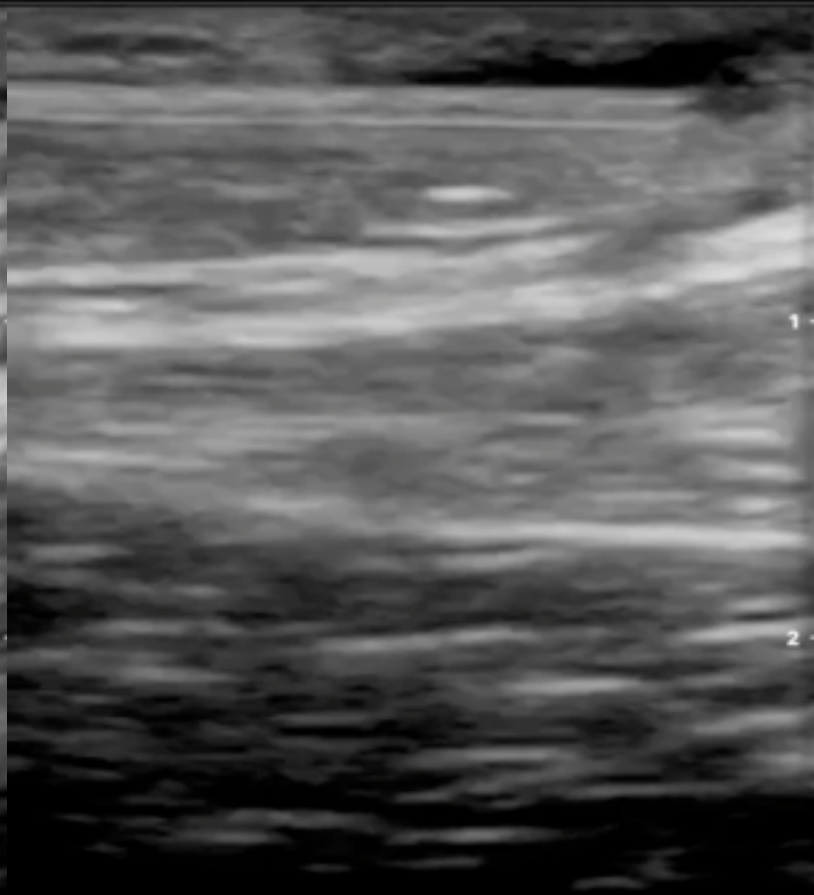
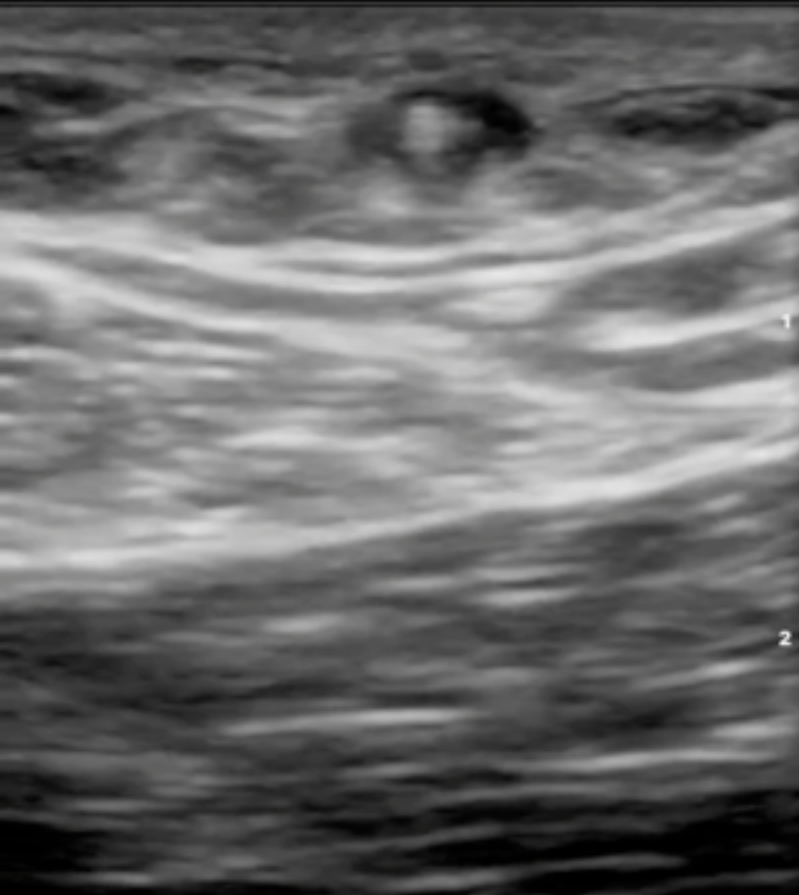


大腿痛和異物感

TIS: 0.01, MI: 0.26, Small Organ

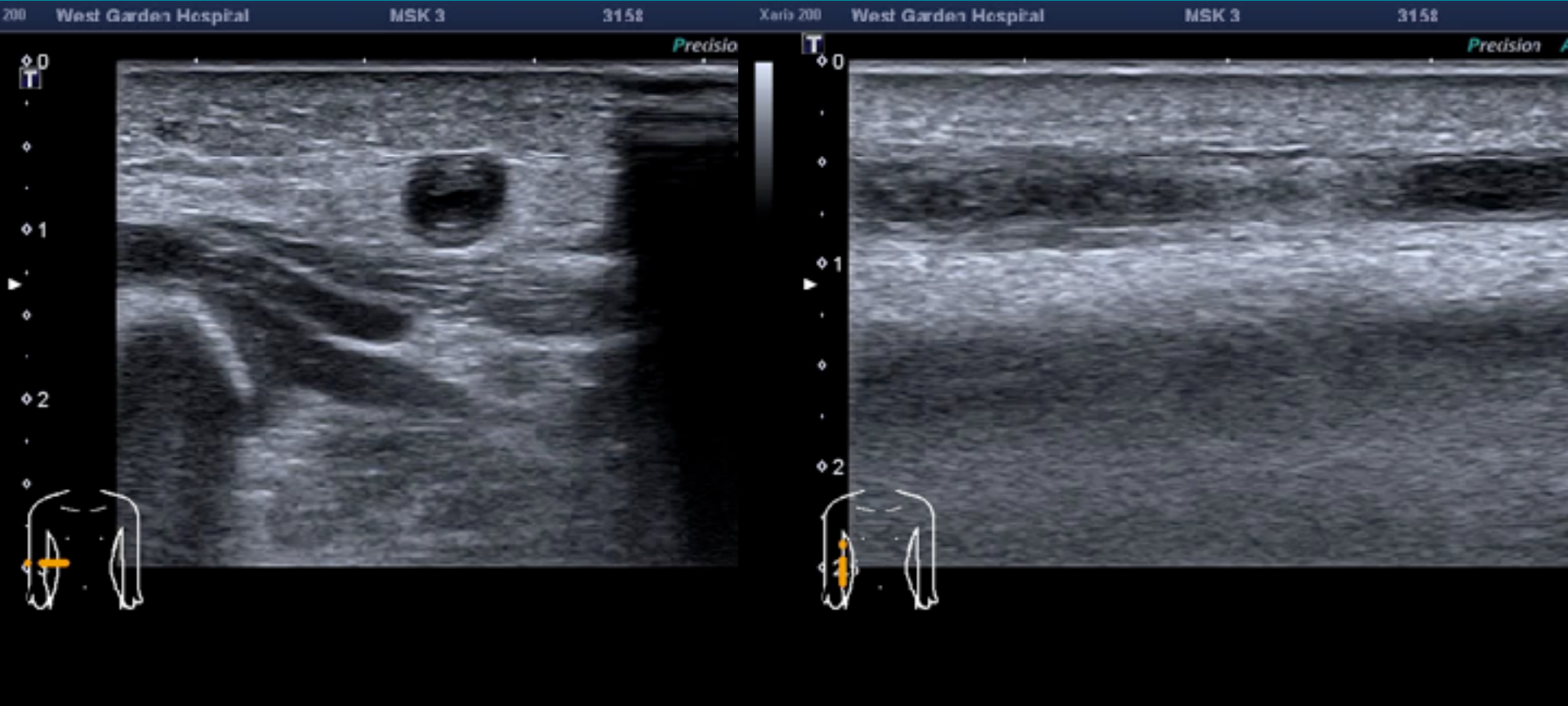
TIS: 0.01, MI: 0.26, Small Organ

Halo sign



54歲男，注射處腫痛

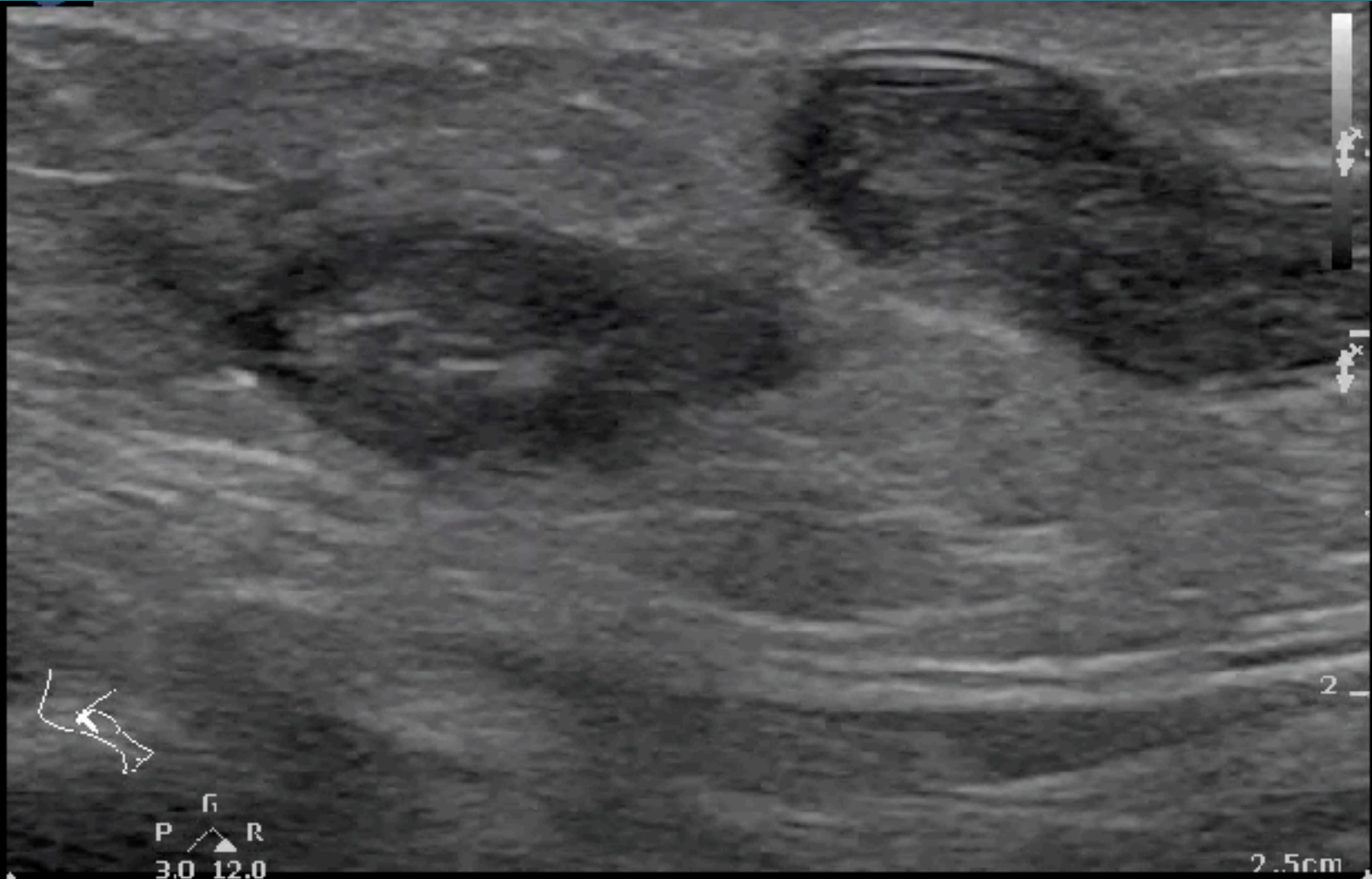
Superficial thrombophlebitis



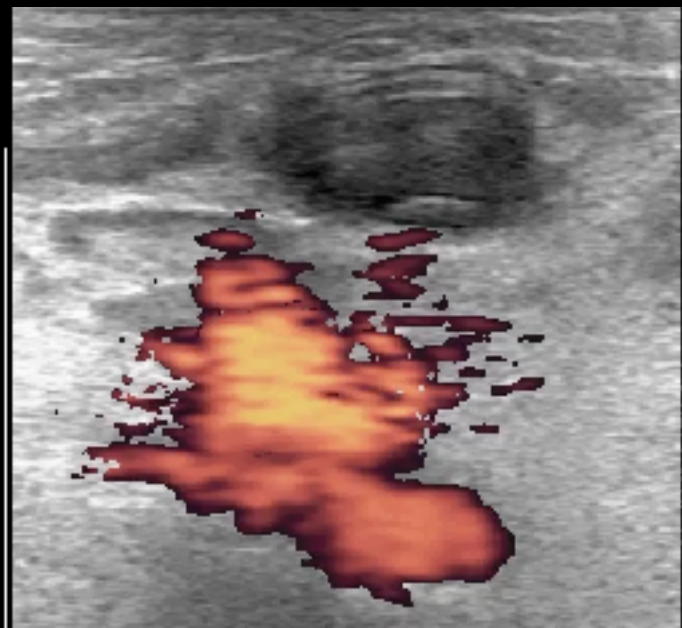
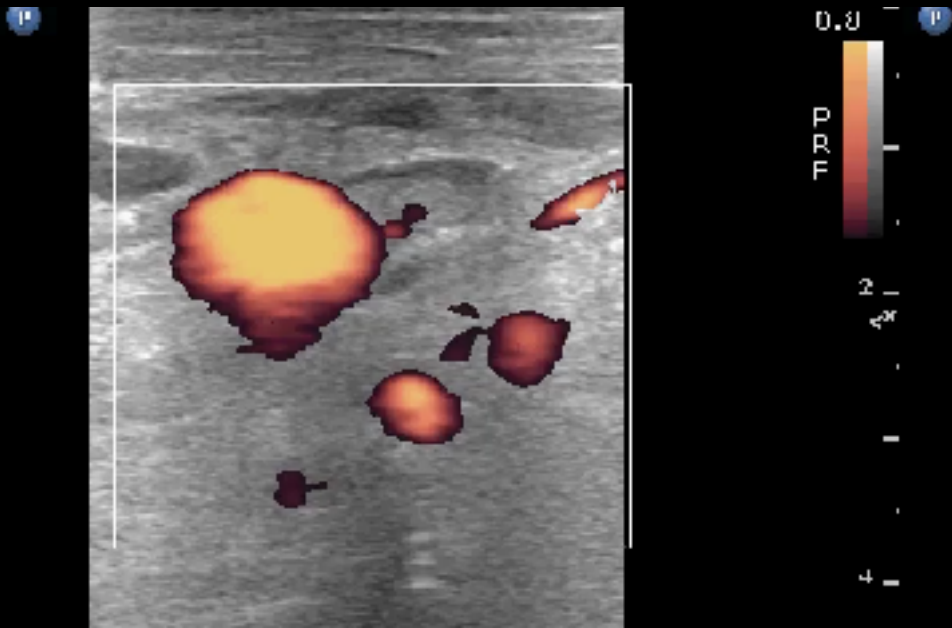
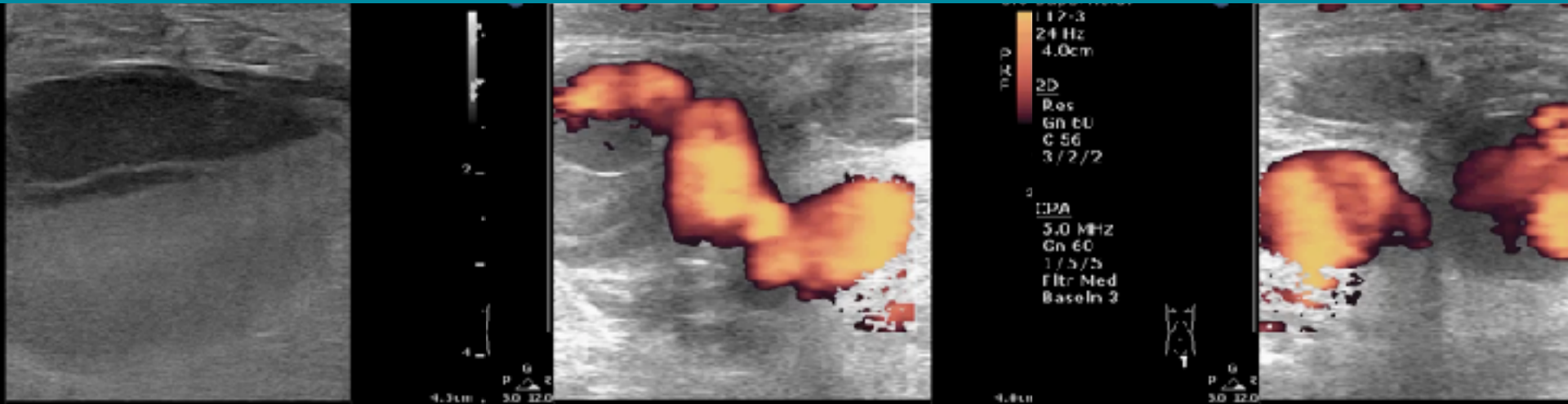
76F，小腿痛

L12-3
50 Hz
2.5cm

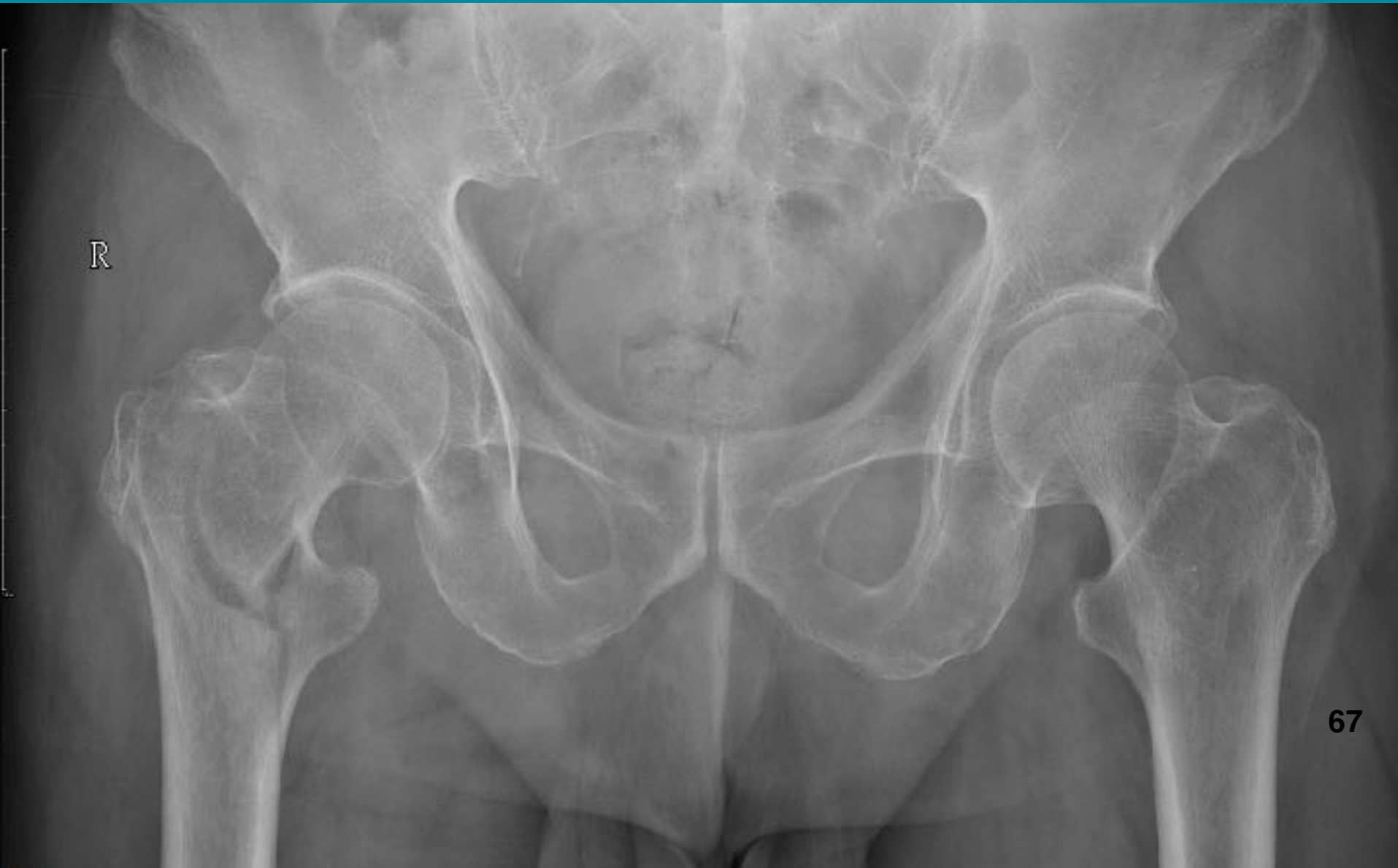2D
Res
Gn //
C. 56
3 / 2 / 1



Left femoral painful swelling

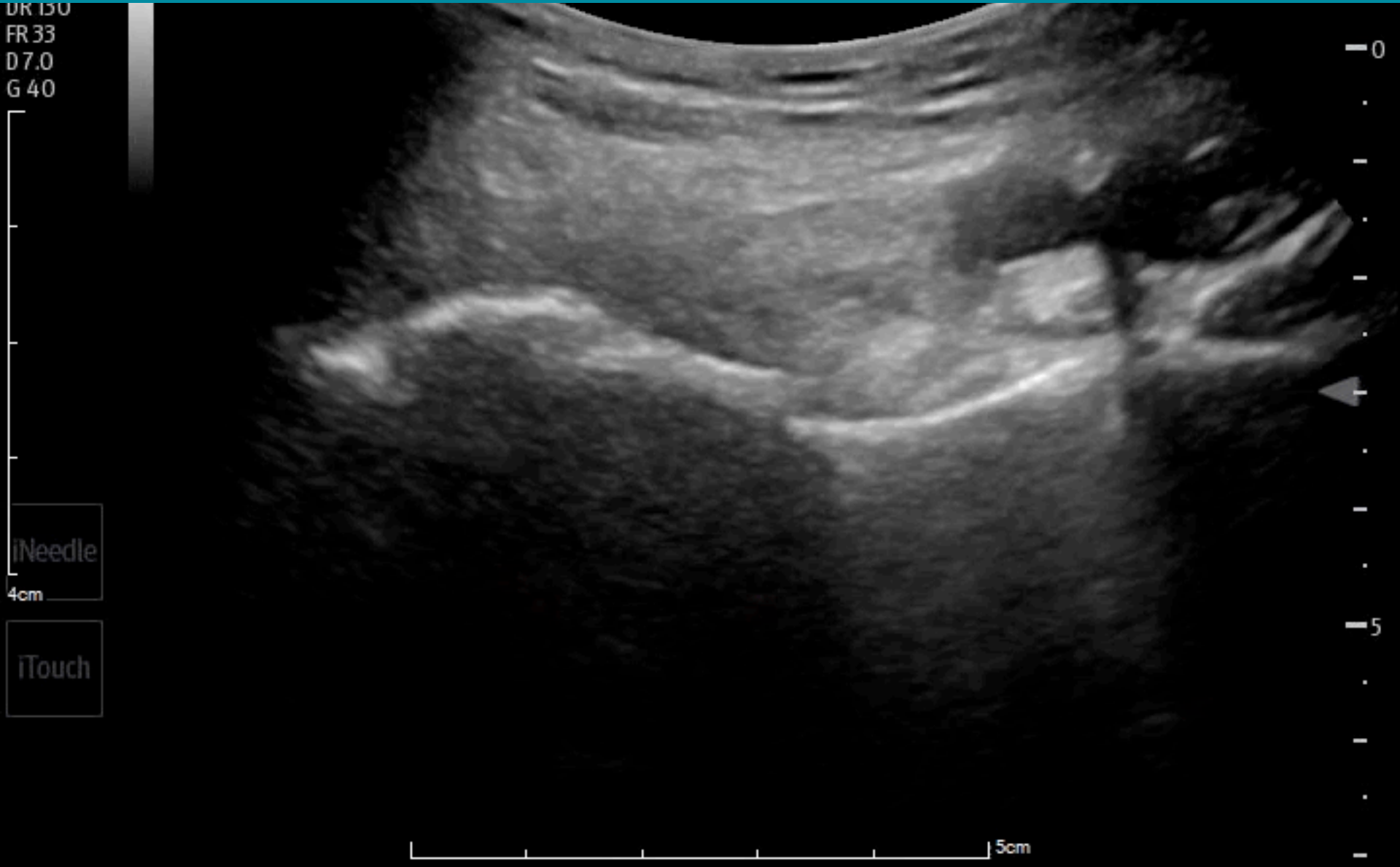

81F, NERVE BLOCK FOR ITC FRACTURE



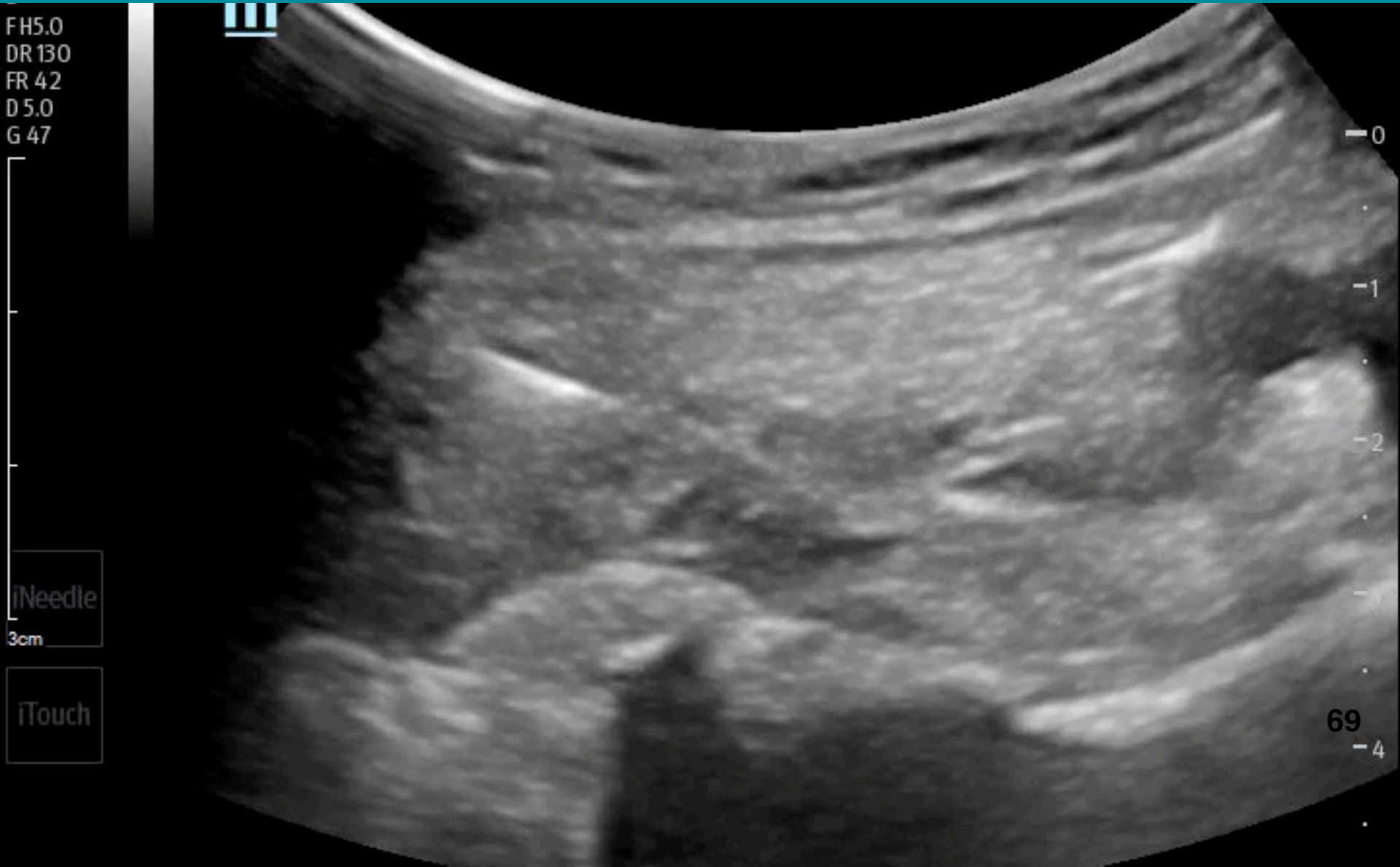PENG BLOCK

PEricapsular Nerve Group block



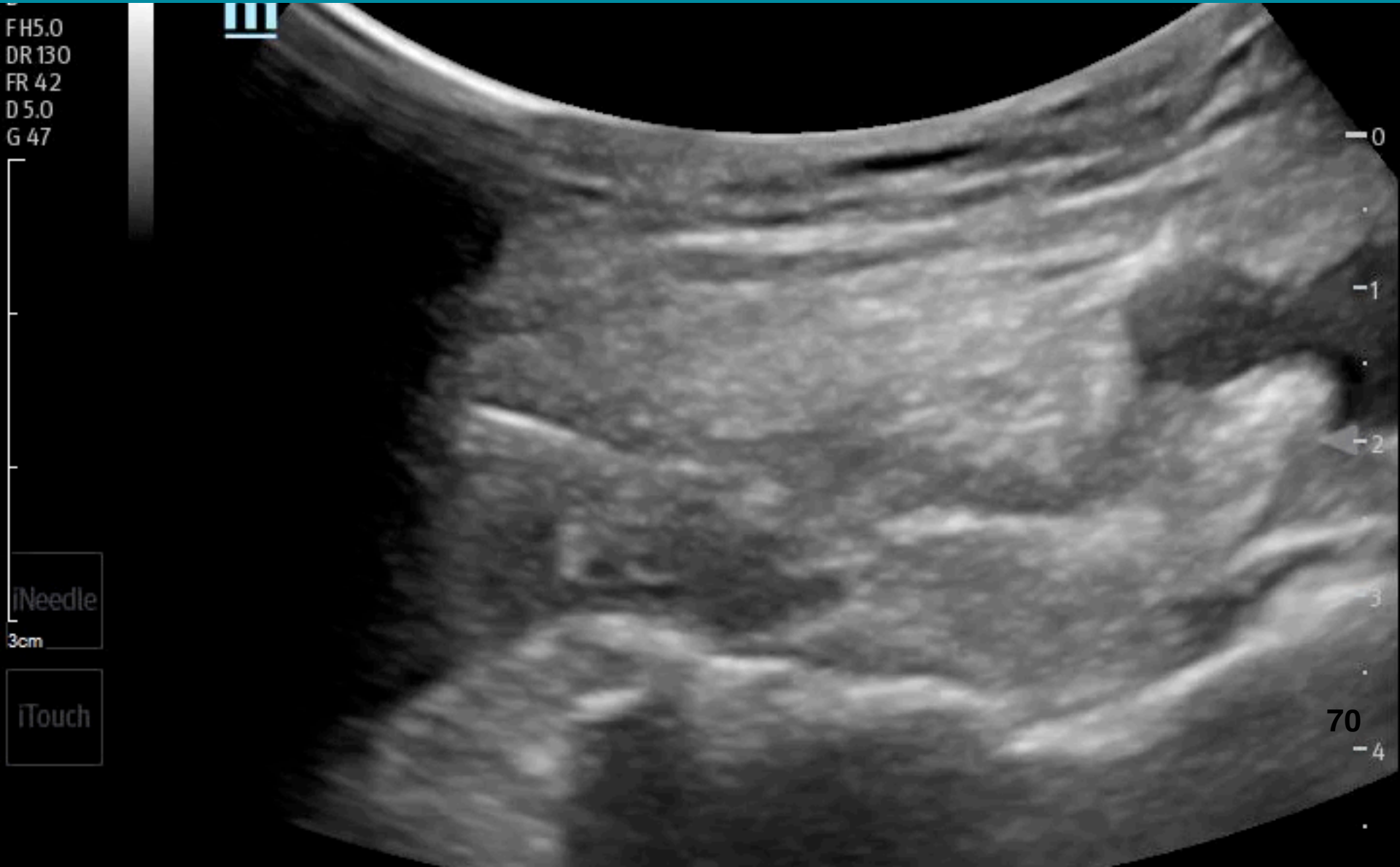
PENG BLOCK

PEricapsular Nerve Group block



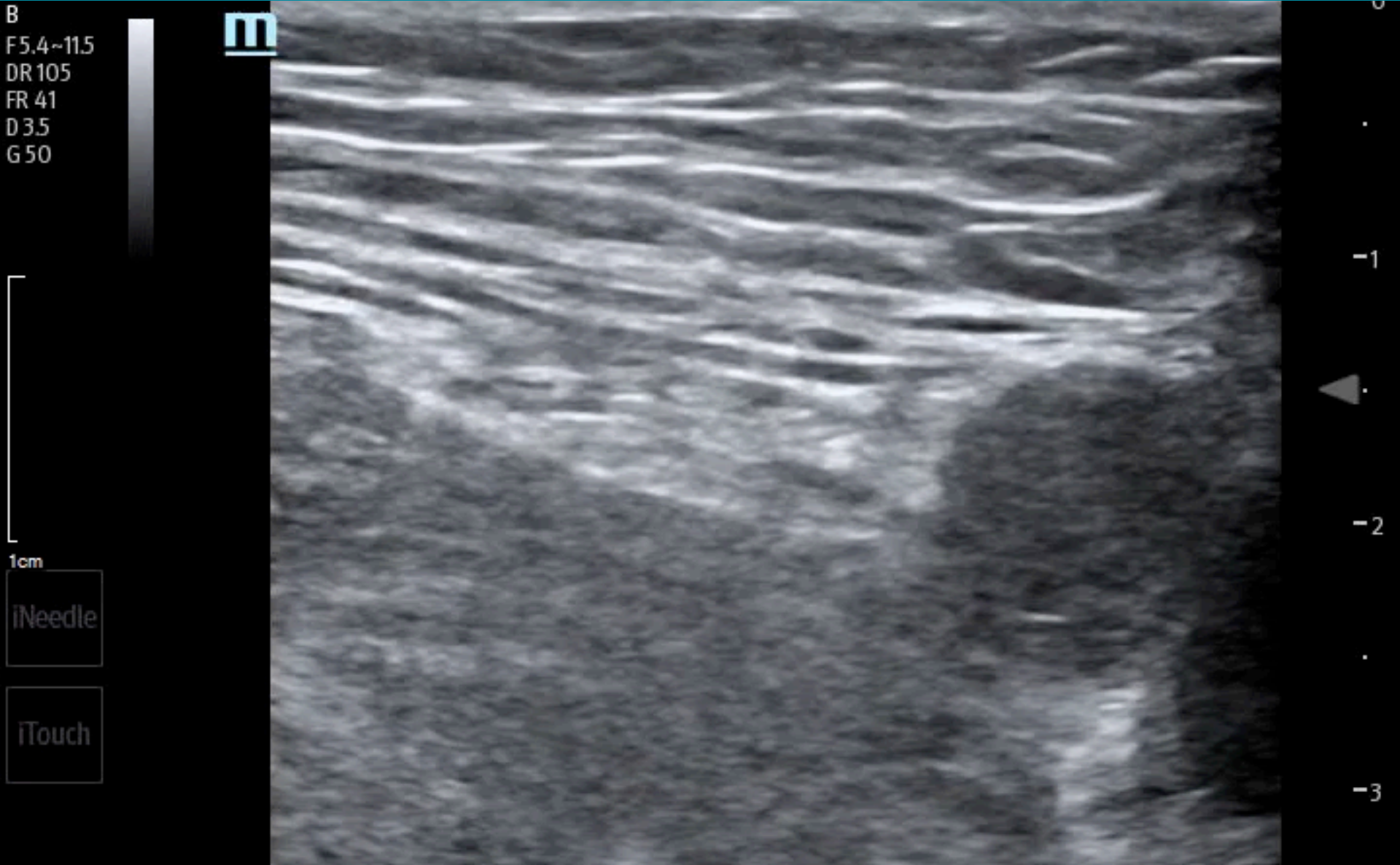
PENG BLOCK

PEricapsular Nerve Group block



ANISOTROPY

Femoral nerve



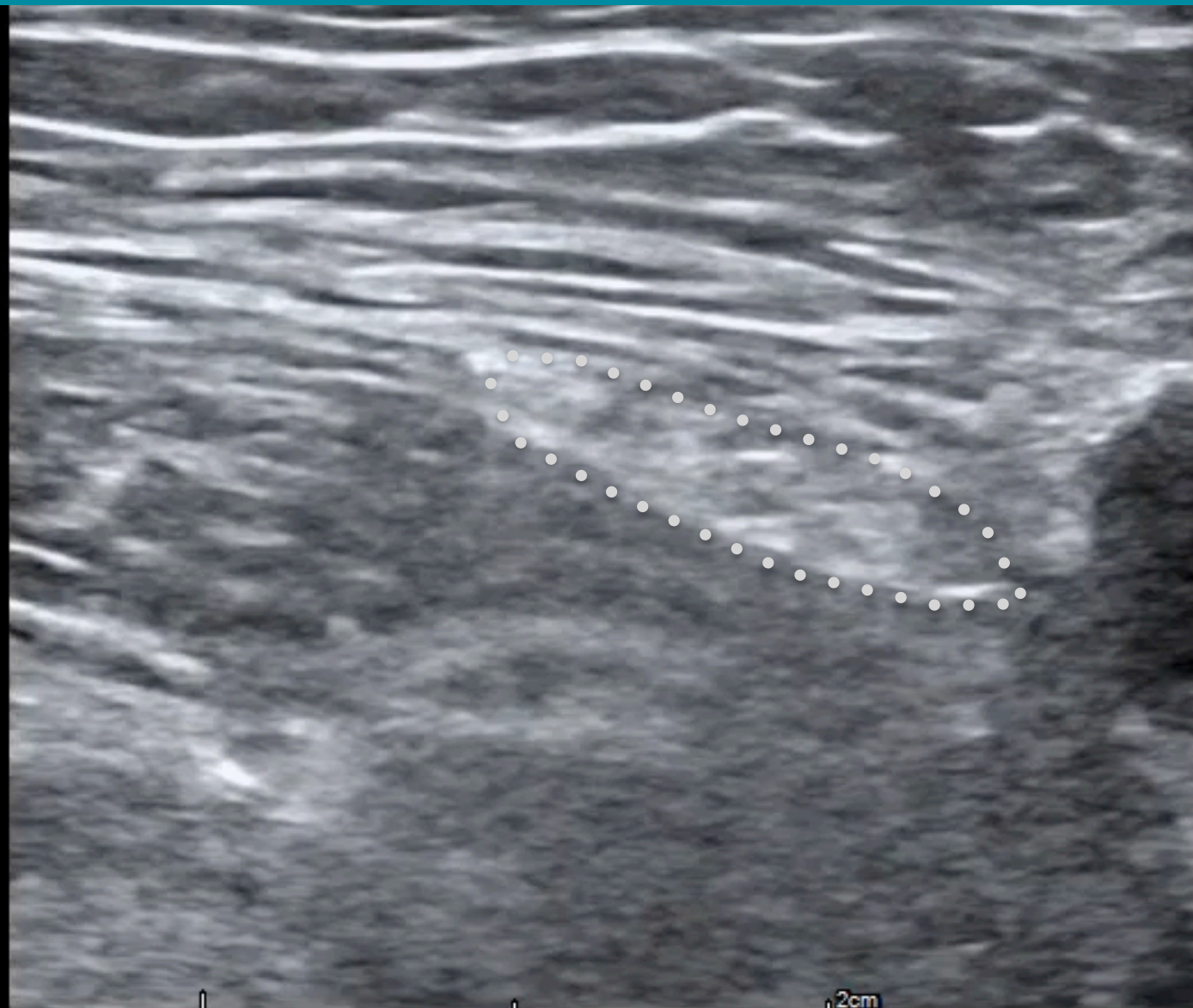
FEMORAL NERVE

DR 105
FR 41
D3.5
G50



iNeedle

iTouch



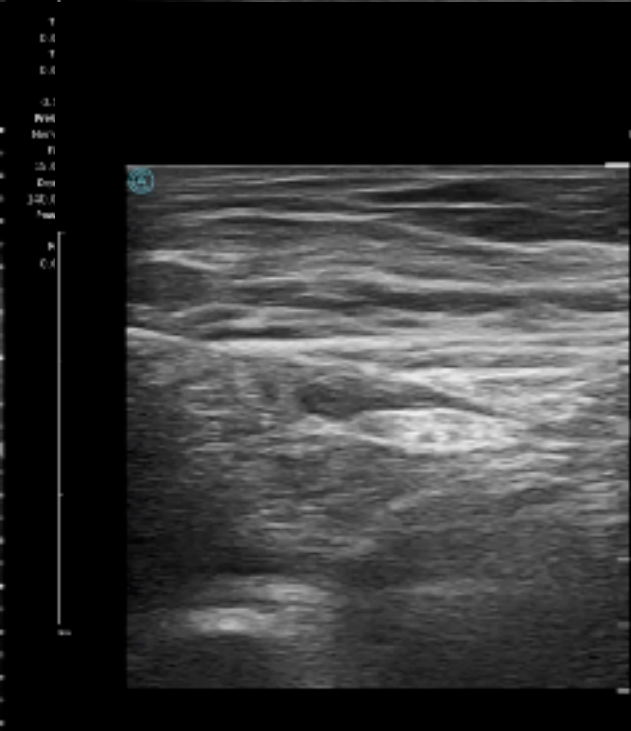
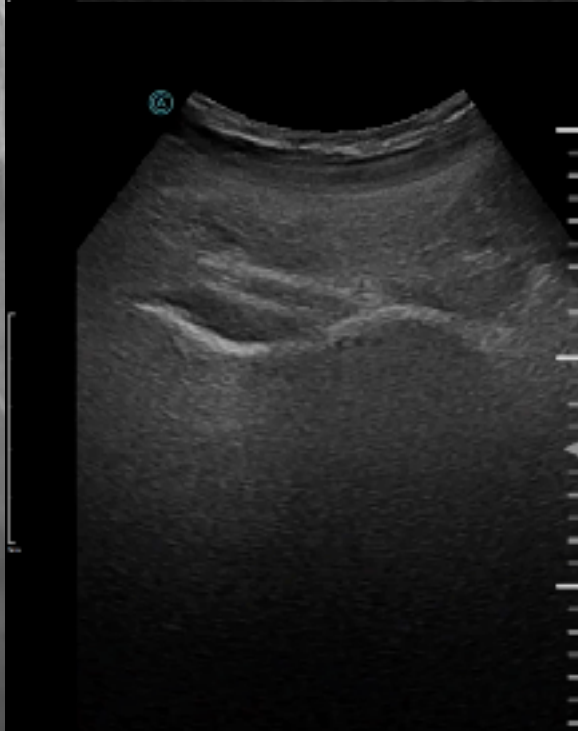
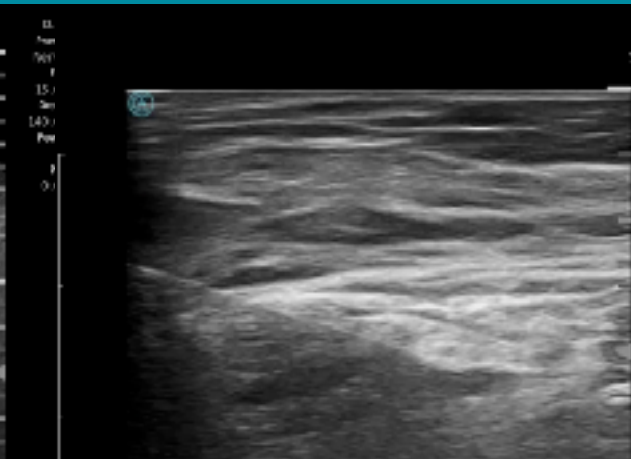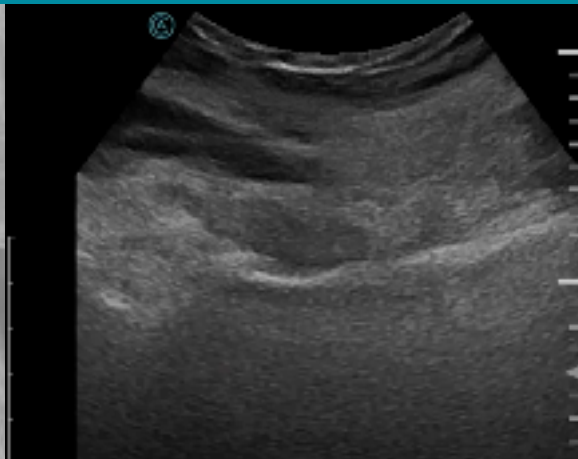
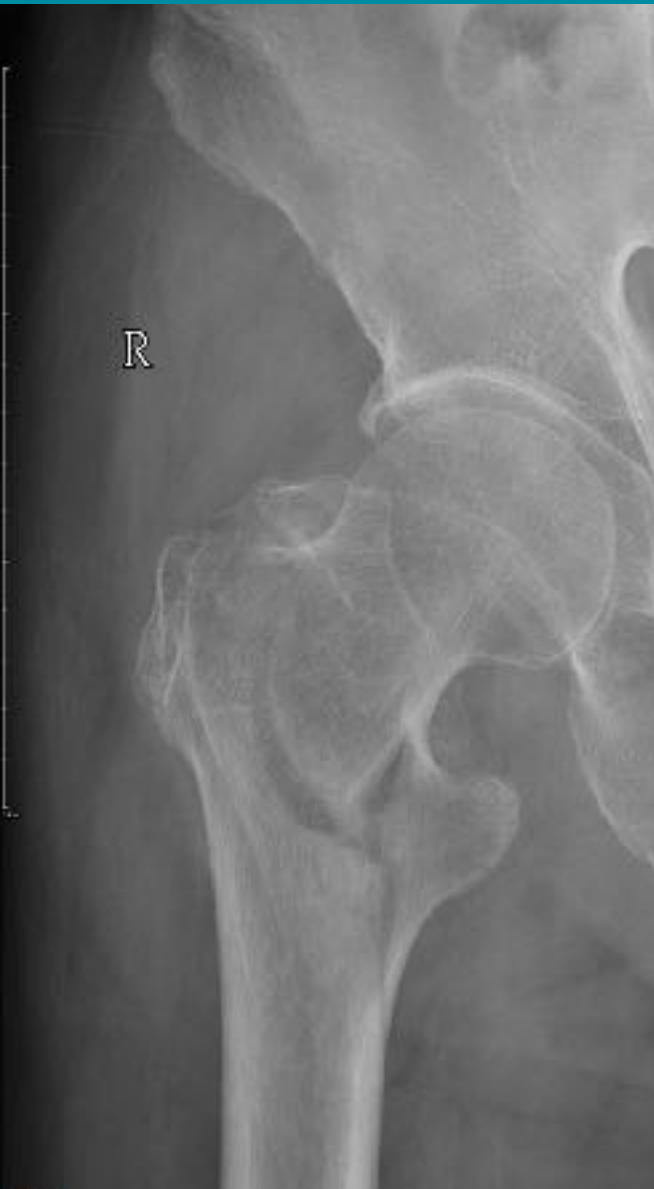-1

-2

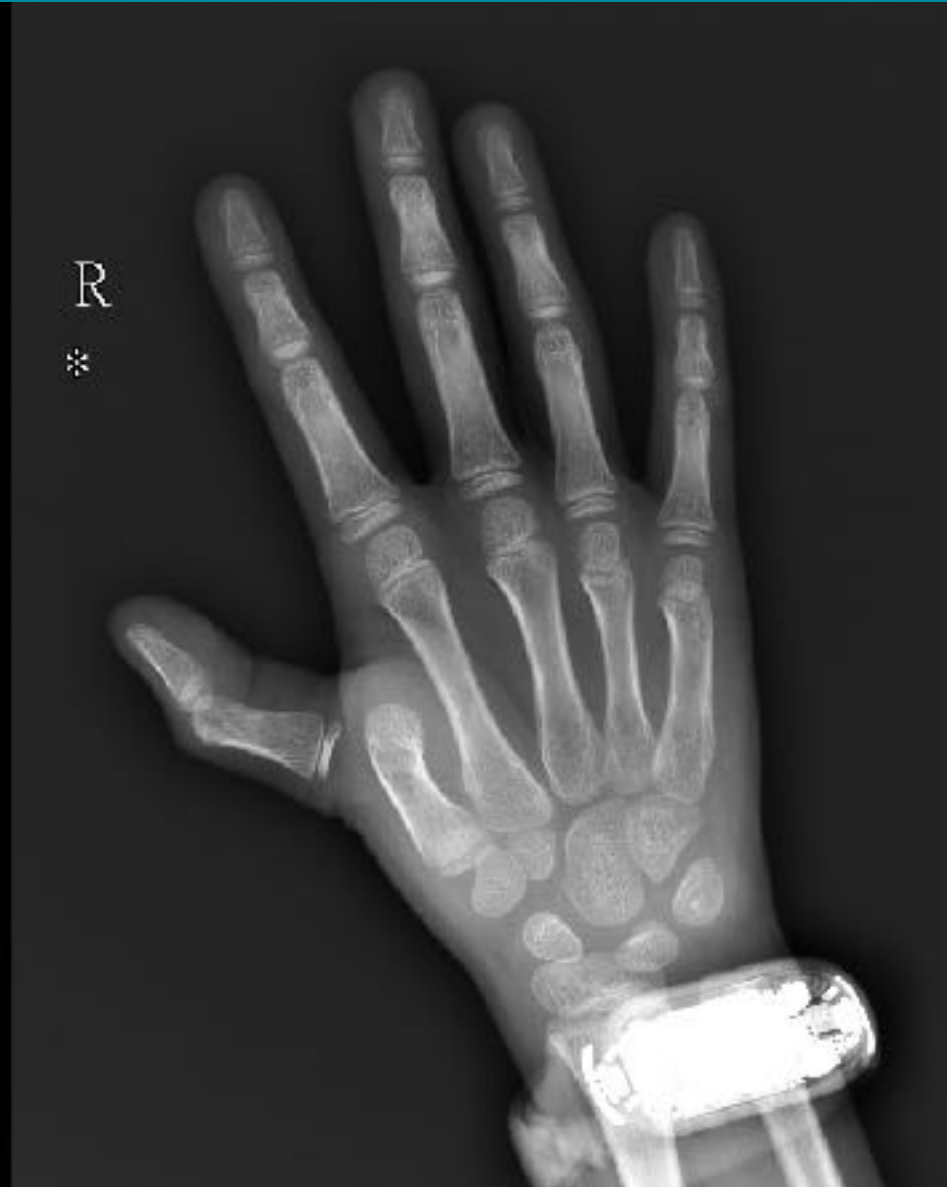-3

2cm

FEMORAL NERVE BLOCK

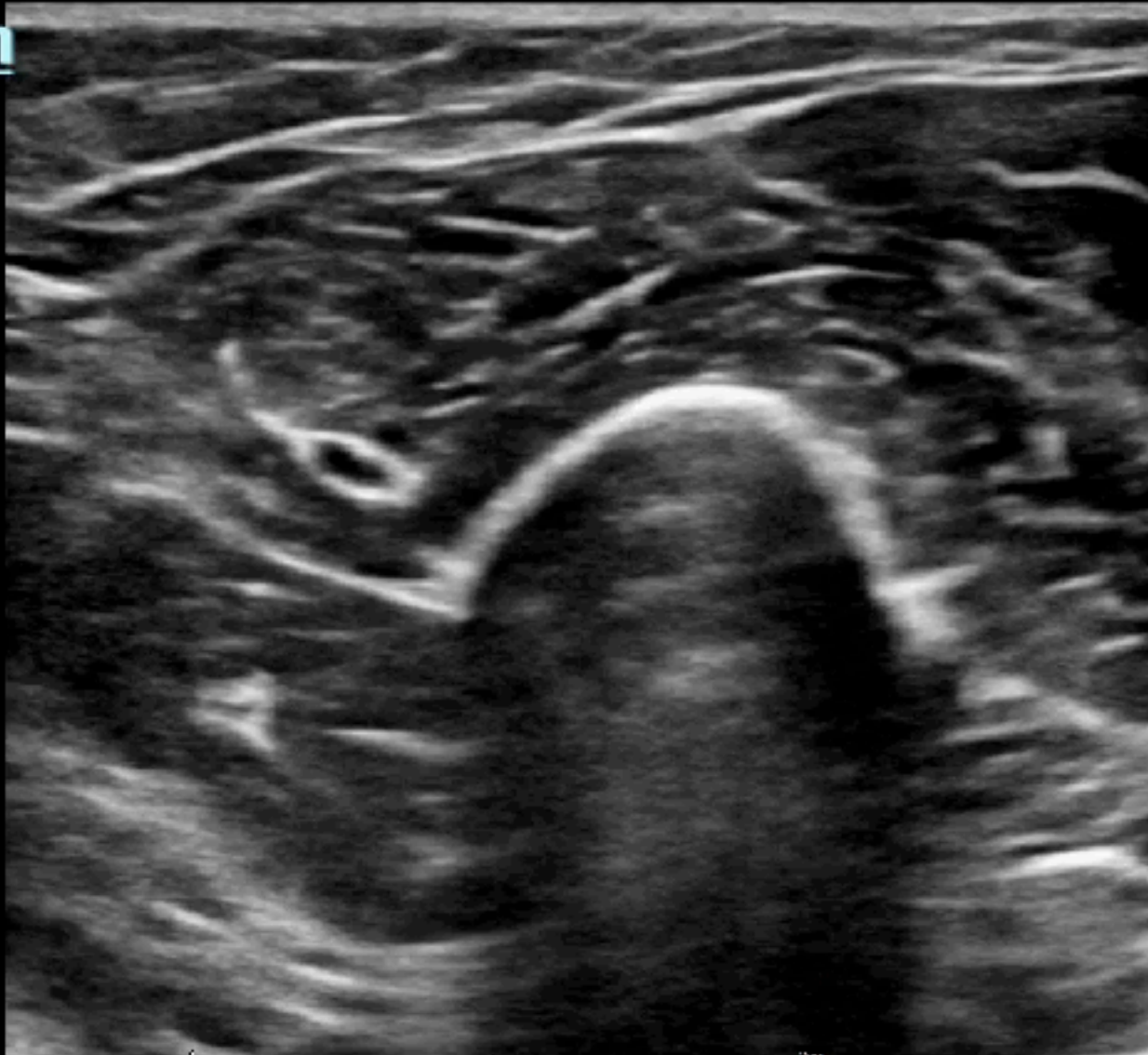

10M，右大拇指被足球踢到後變形



RADIAL NERVE ABOVE ELBOW

B
F 6.6-13.0
DR 115
FR 45
D 3.5
G 60



0

-1

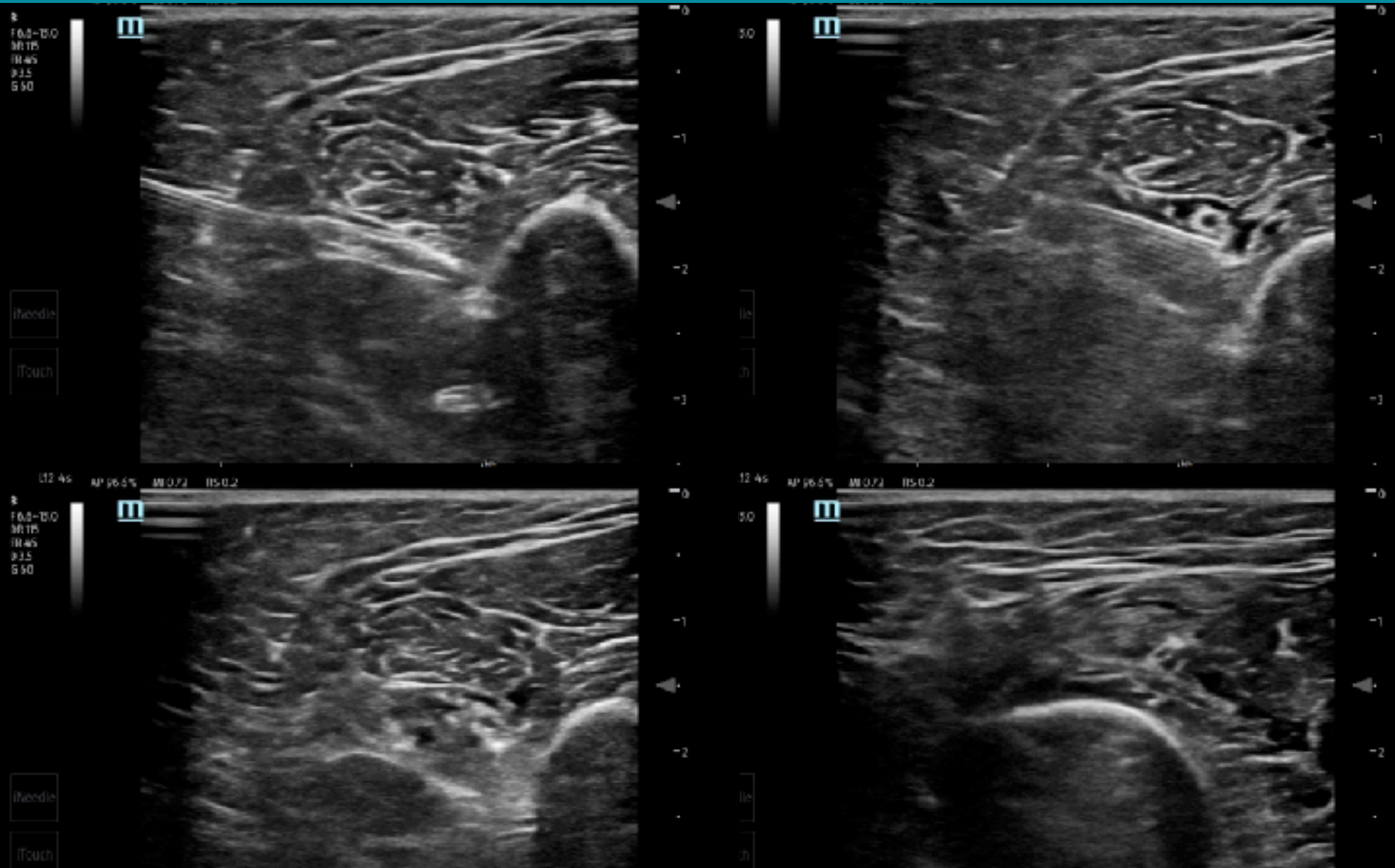
-2

-3

iNeedle

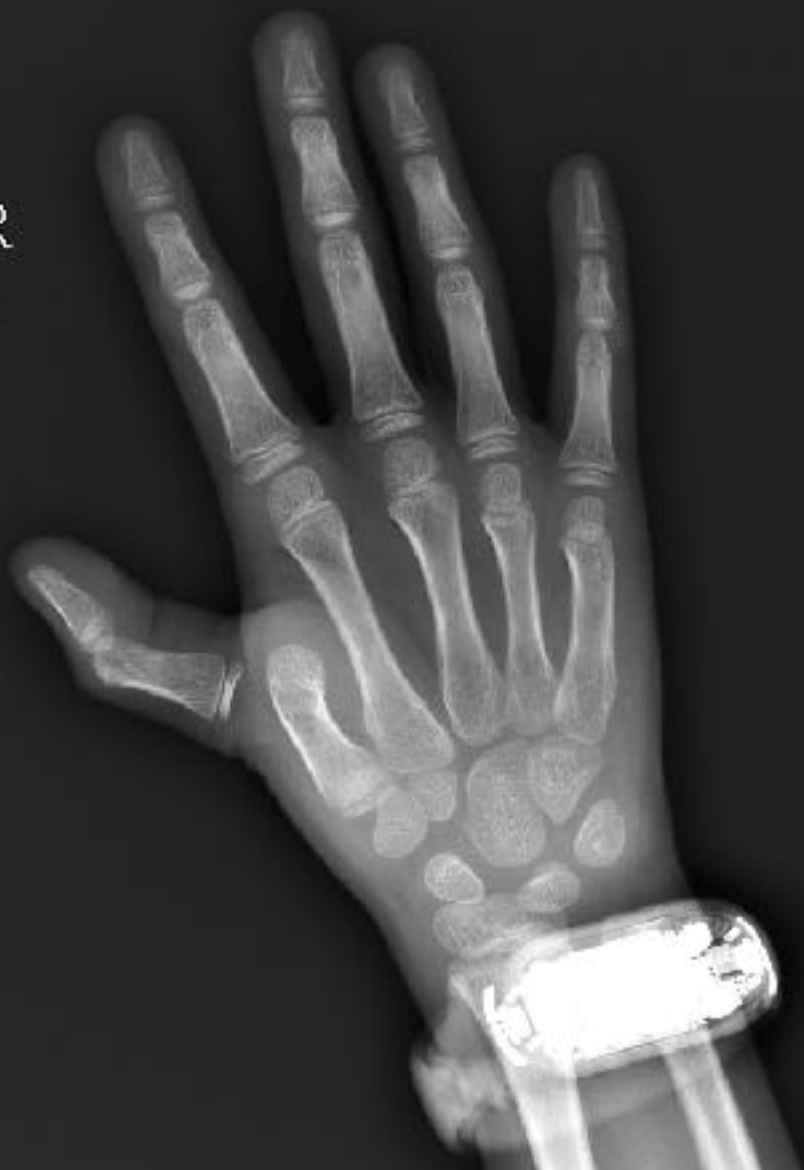iTouch

RADIAL NERVE BLOCK

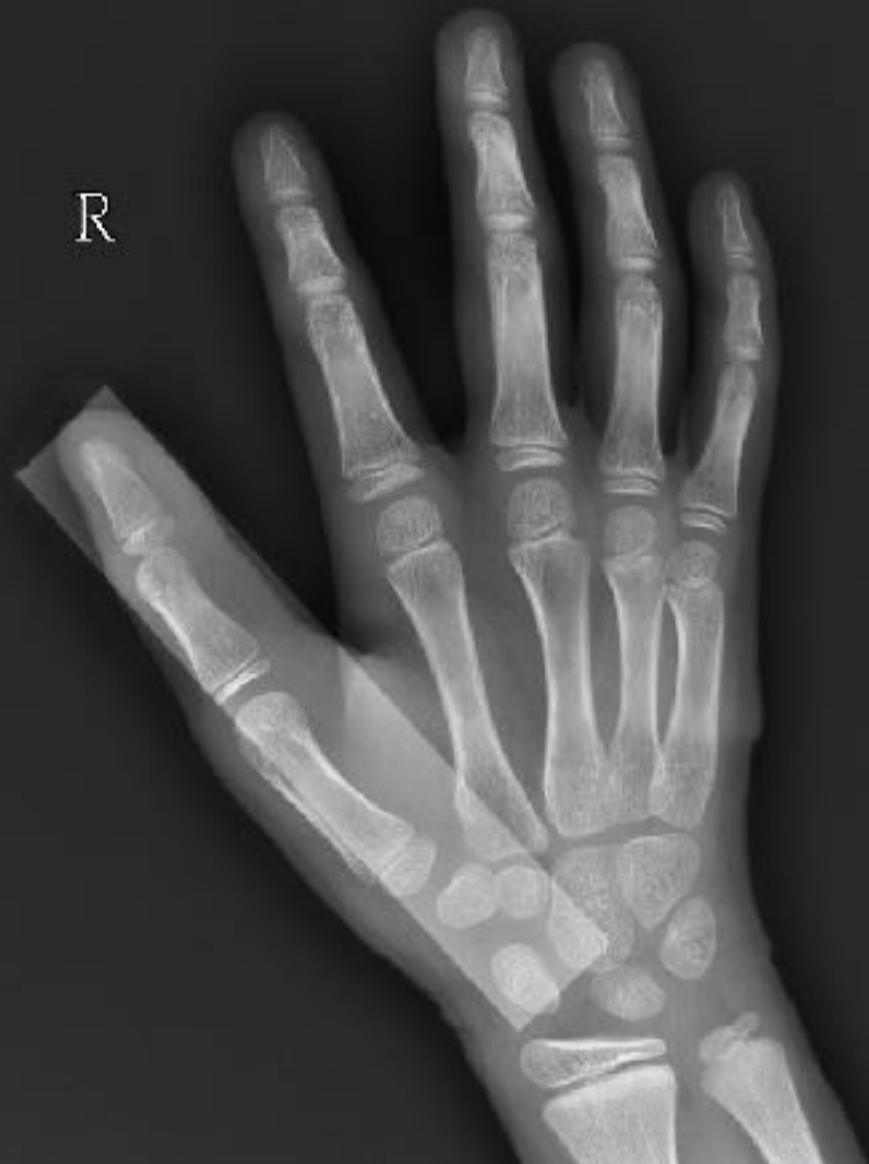

SUCCESSFUL REDUCTION AFTER RN BLOCK

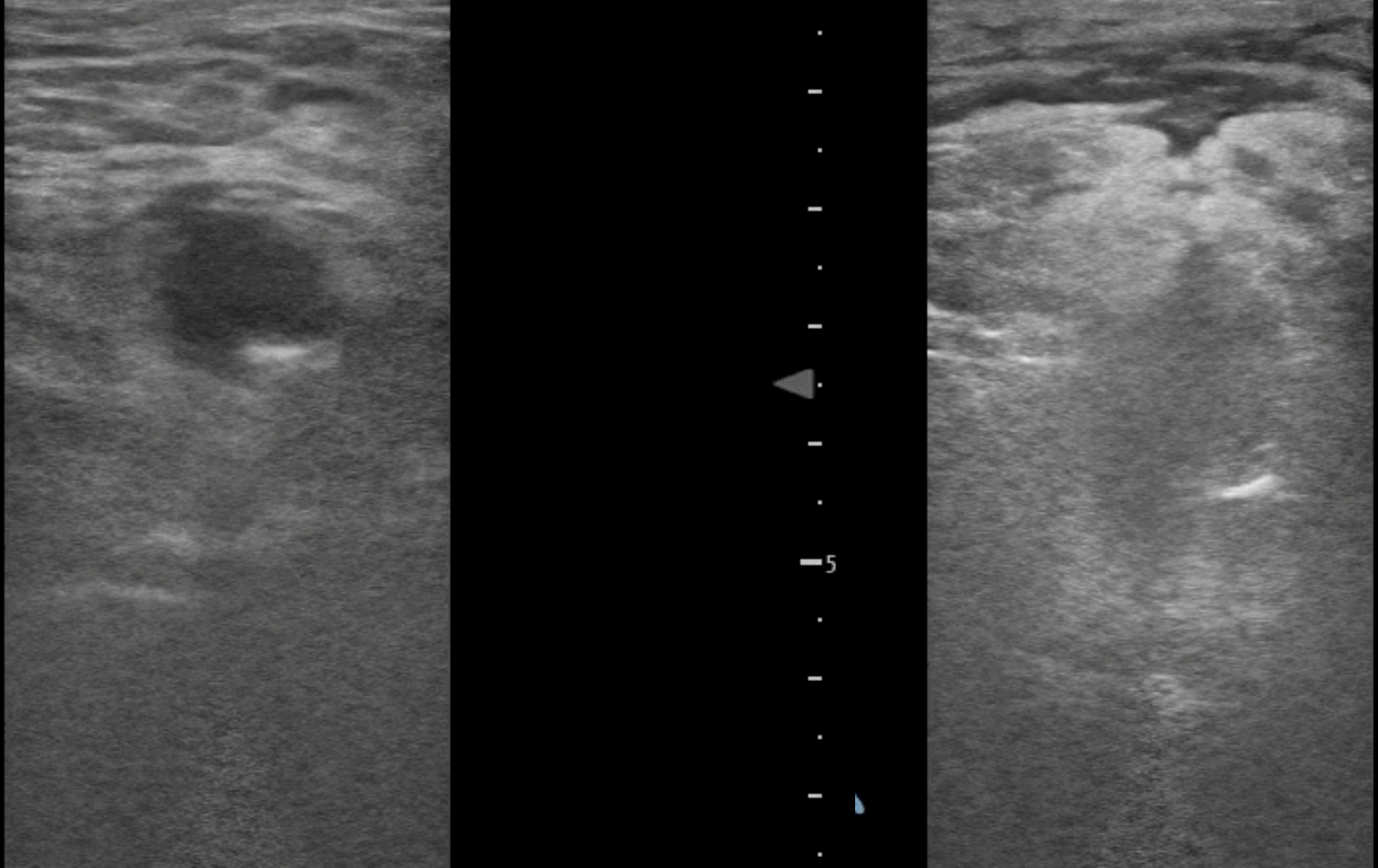
R
*



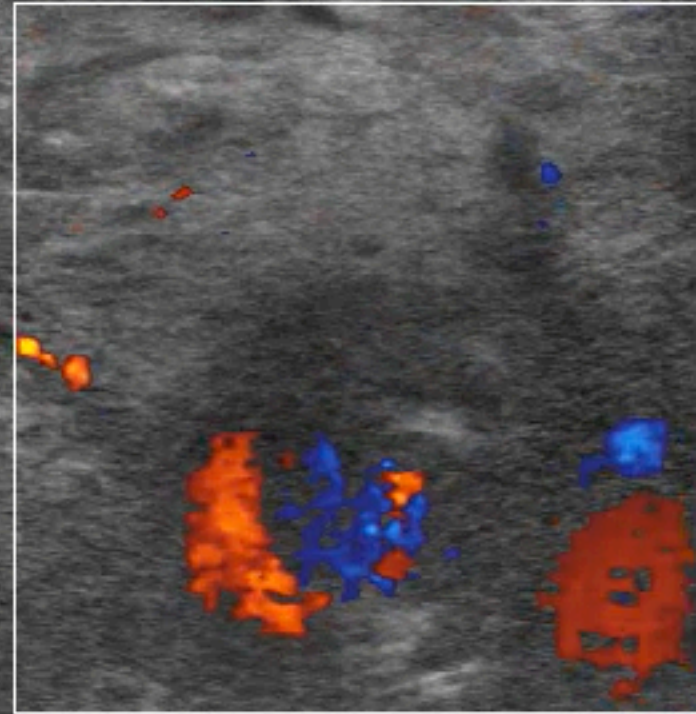
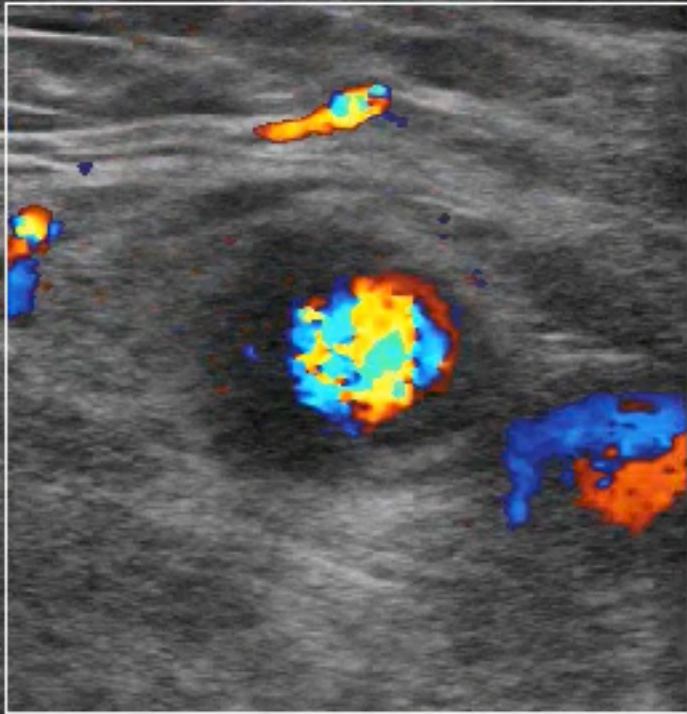
R



**65M, CVA WITH LEFT SIDE WEAKNESS
RIGHT INGUINAL CARBUNCLE & PUS DISCHARGE**

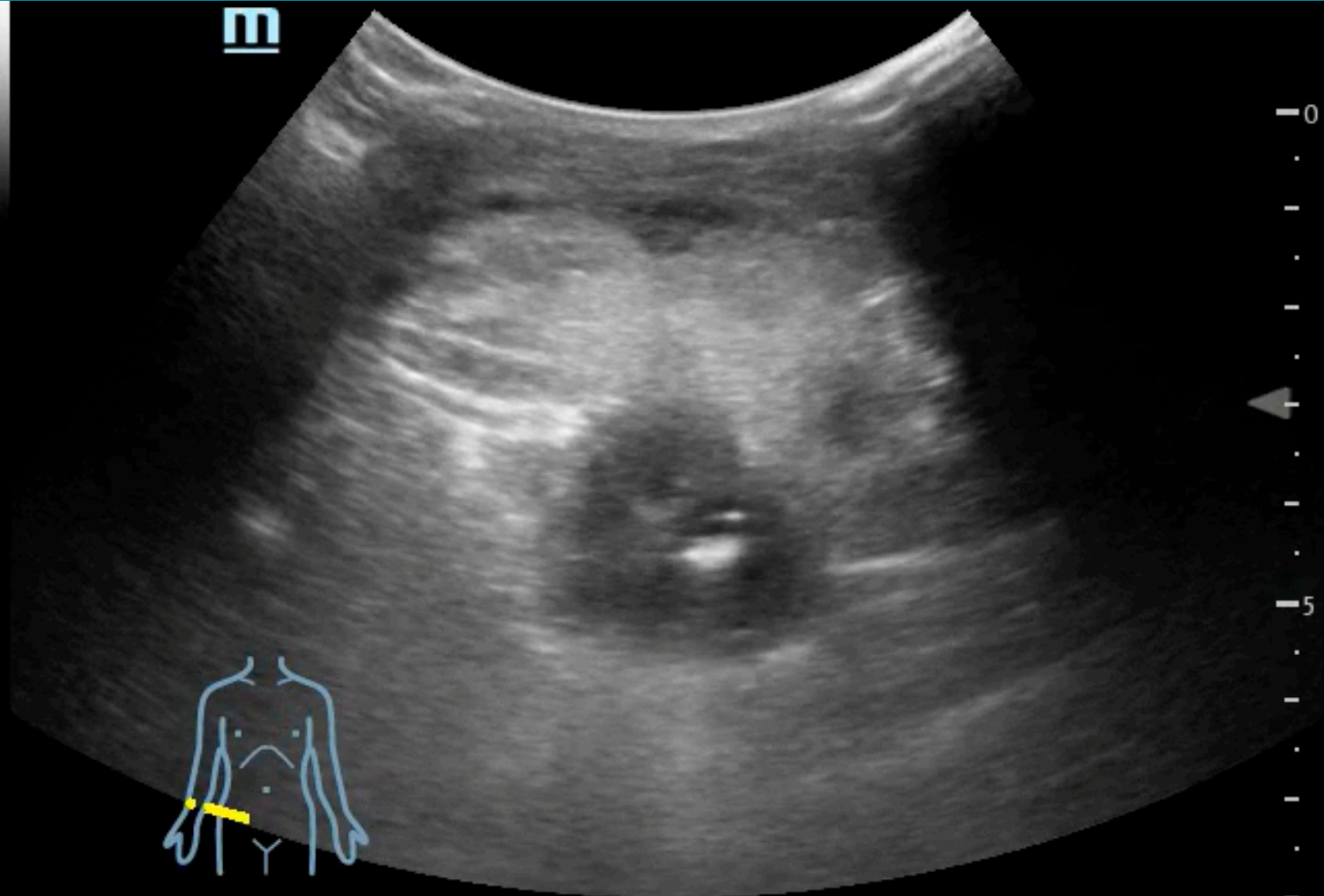


WBC 10050; CRP 12.55; GLU 237; PUS: KP



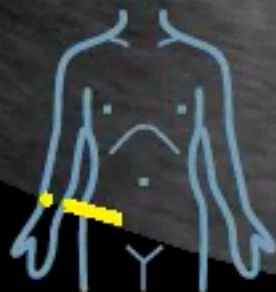WBC 10050; CRP 12.55; GLU 237; PUS: KP

FH5.0
DR 115
FR 25
D 8.0
G 63



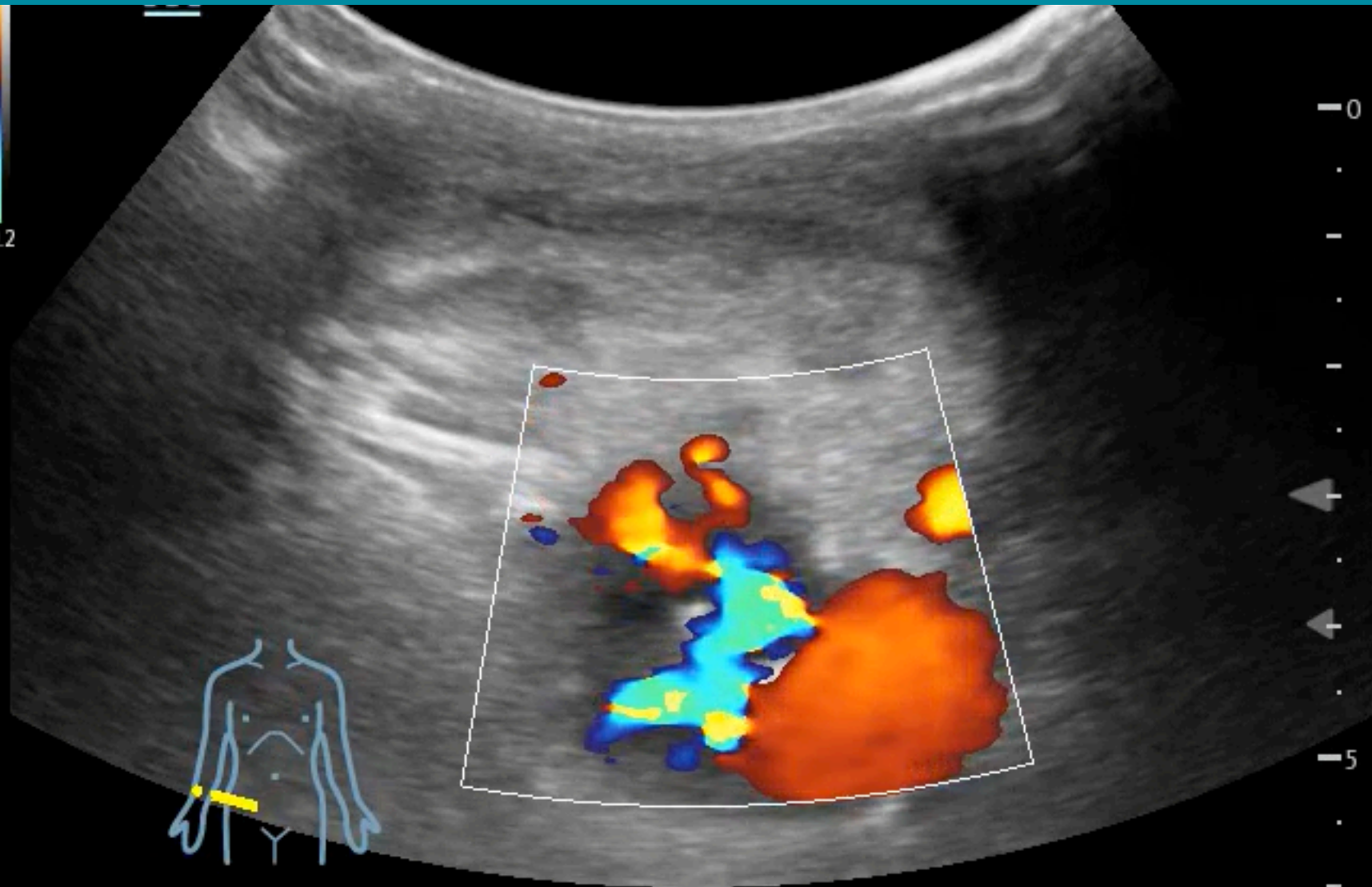
iNeedle

iTouch



WBC 10050; CRP 12.55; GLU 237; PUS: KP

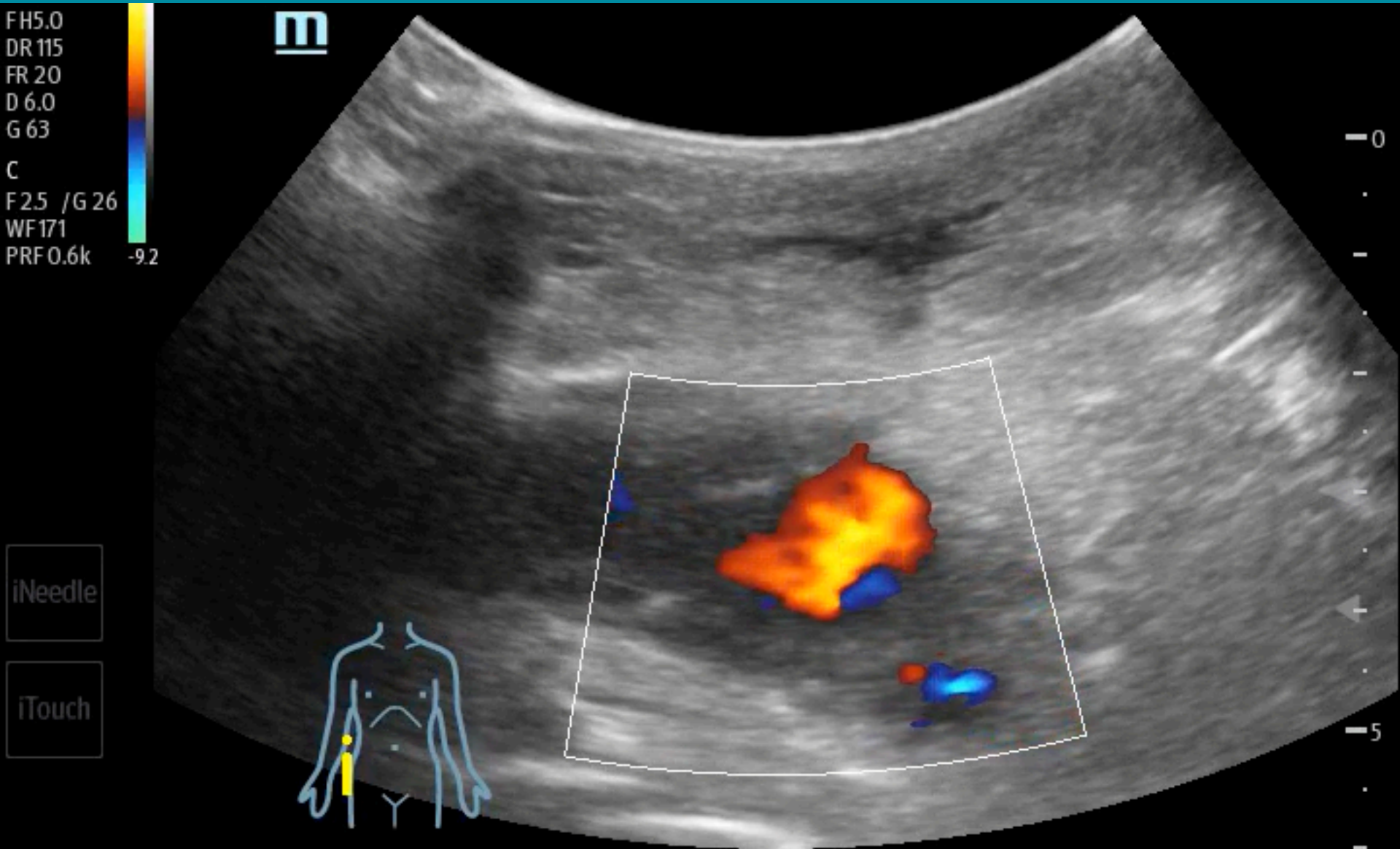
DR 115
FR 20
D 6.0
G 63
C
F2.5 /G30
WF171
PRF0.6k -9.2



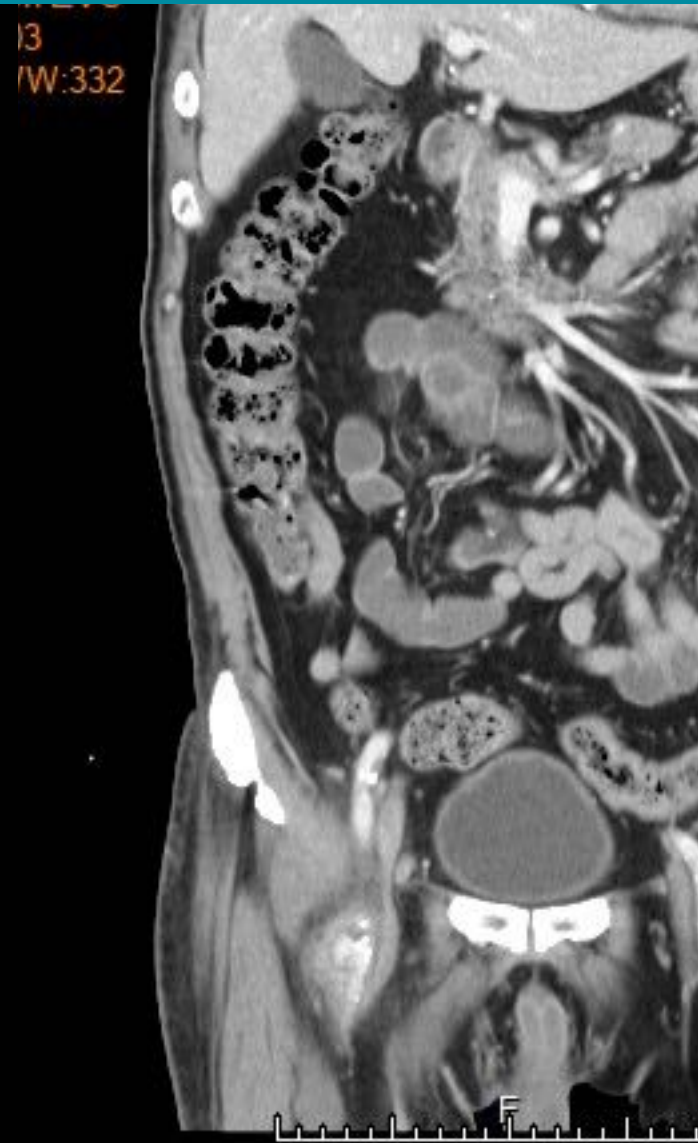
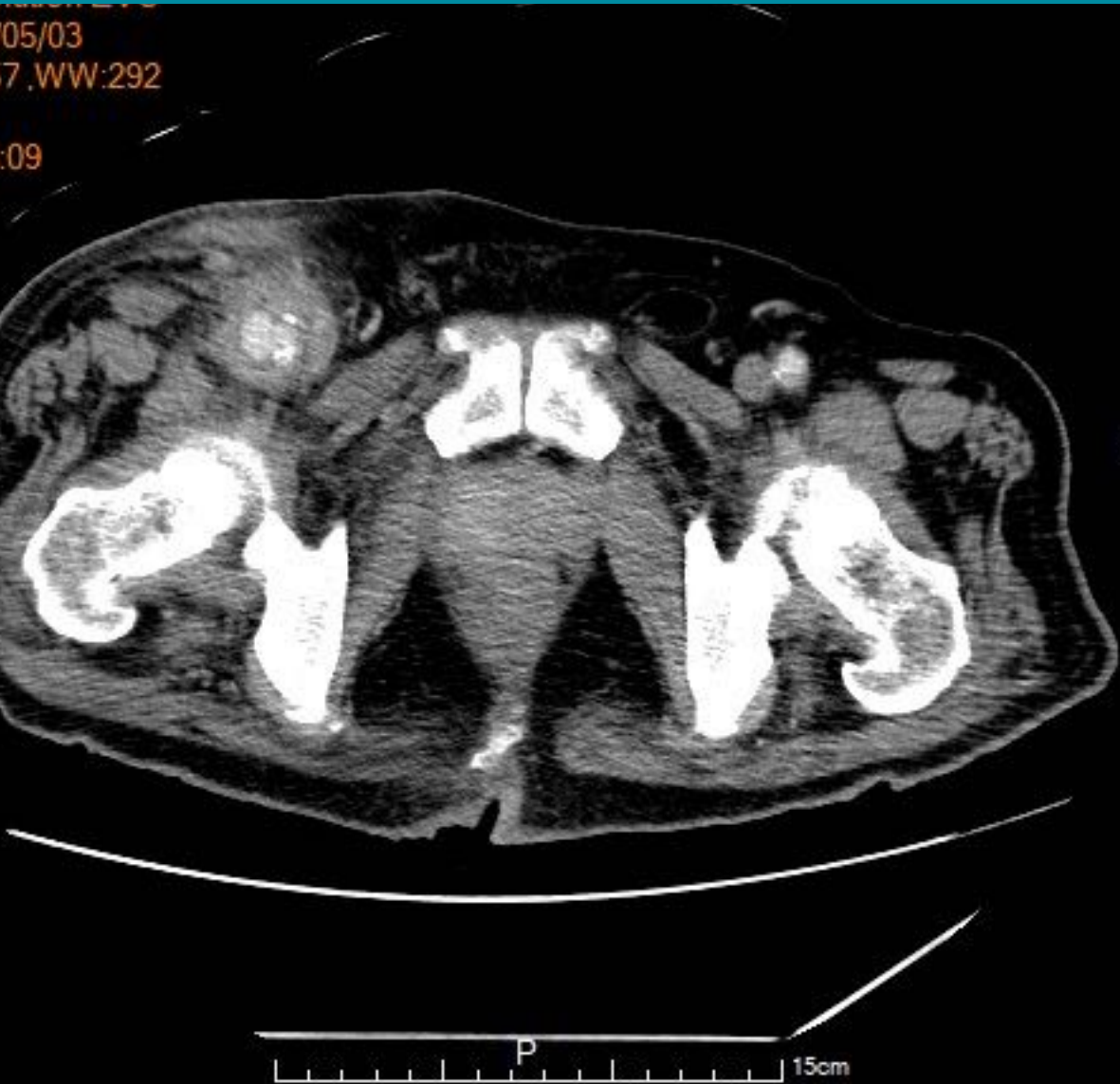iNeedle

iTouch

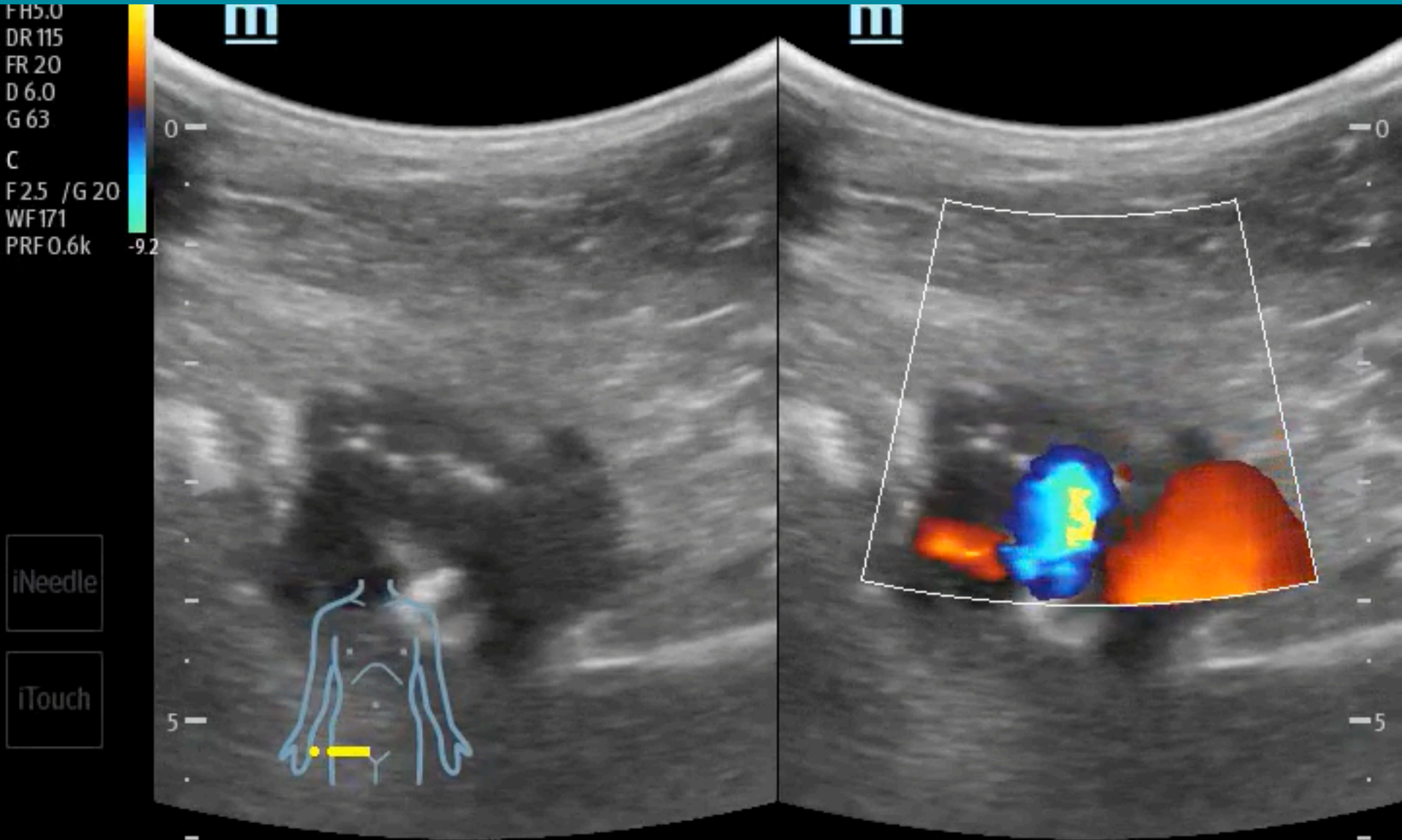
WBC 10050; CRP 12.55; GLU 237; PUS: KP

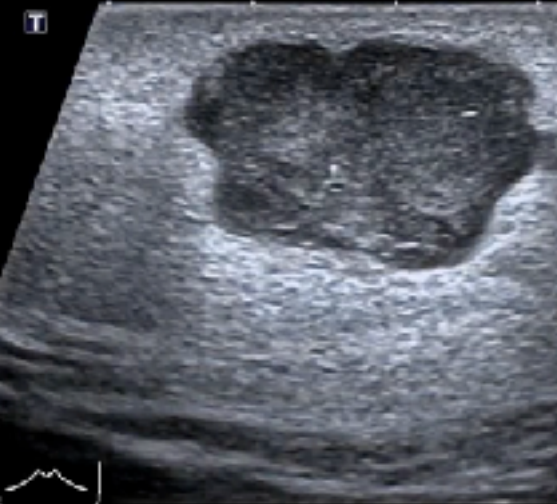


MYCOTIC ANEURYSM

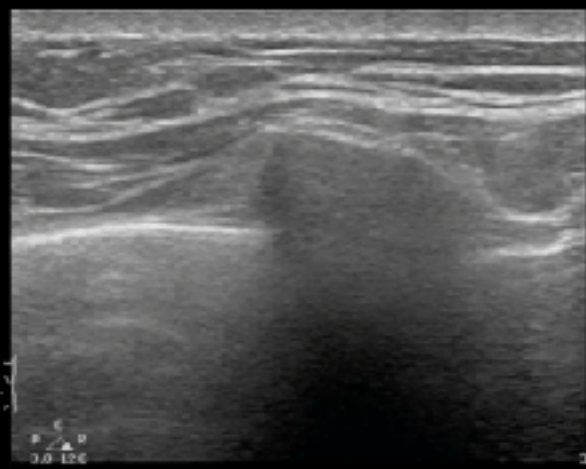


MYCOTIC ANEURYSM

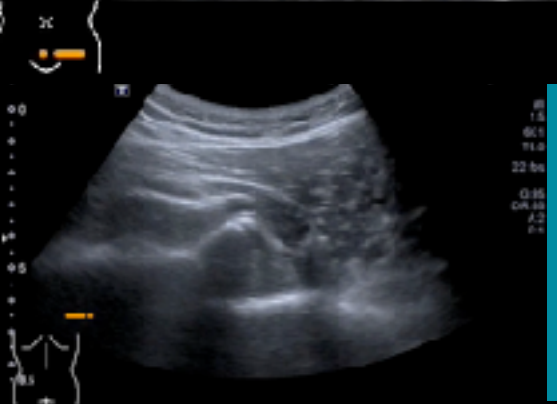
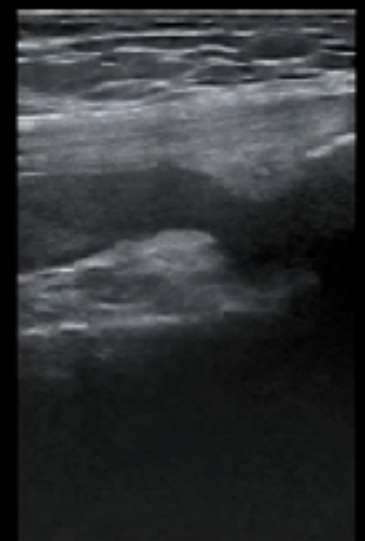




Superficial
L12-3
46 Hz
3.0cm
7D
Res
Gn 96
C 56
3/2/1



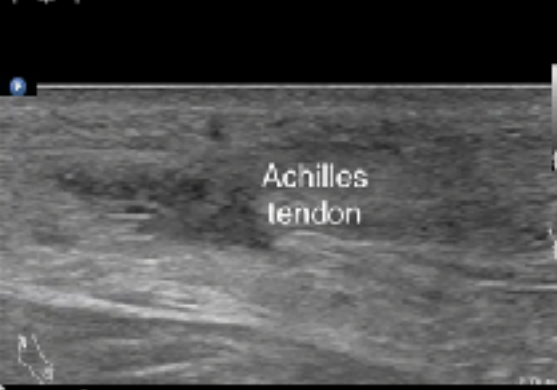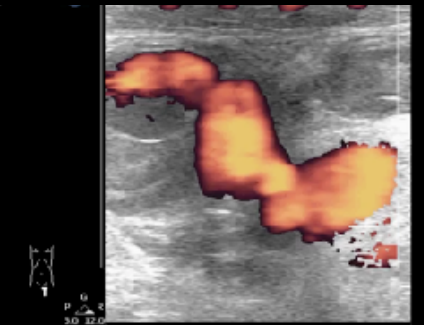
3.0cm
m
3/2/1



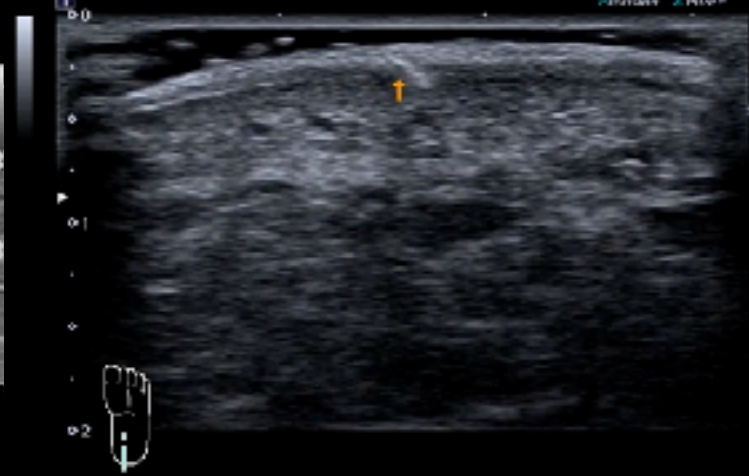
11.5
60
71.0
22.5
G:85
ON:30
A:2
P:1

MSK & ST US in ER

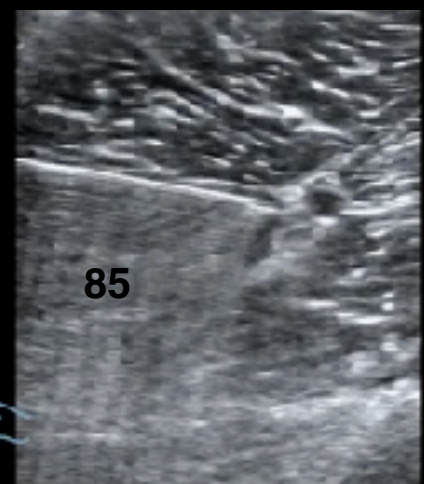
L12-3
24 Hz
4.0cm
2D
Res
Gn 60
C 56
3/2/2
EPA
5.0 MHz
Gn 60
1/5/5
Filt: Med
Baseln 2



Achilles tendon



M1
1.5
11 L1
dFT 9.0
30 fps
0.30
DTS:50
4-6
P:3



85

