



衛生福利部雙和醫院
(委託臺北醫學大學興建經營)
Taipei Medical University · Shuang Ho Hospital,
Ministry of Health and Welfare



US-guided procedures

Advanced procedures

陳國智醫師 雙和醫院急診醫學科

juice119@gmail.com

POCUSacademy.com

陳國智 醫師

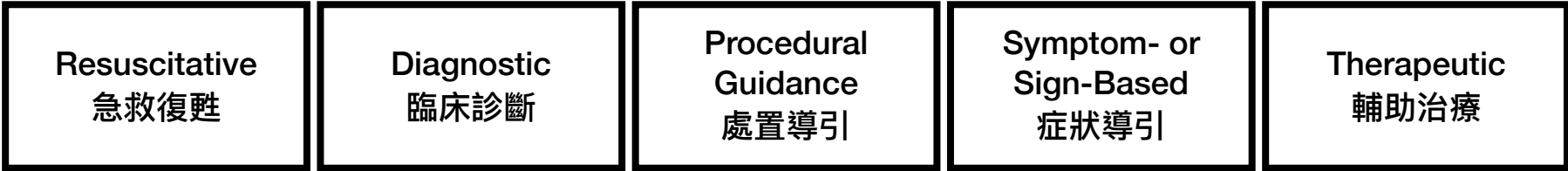

台灣疼痛醫學會專科醫師
急診超音波臨床評核醫師
醫用超音波學會指導醫師
WINFOCUS director / instructor
Certified Interventional Pain Sonologist

急診 / 重症 / 介入 / 急性疼痛

經歷

新光急診超音波訓練中心主任
西園醫院急診醫學科主任
急診醫學會超音波委員會主委
台灣疼痛醫學會大體模擬手術講師
急救加護醫學會重症超音波負責人



Core Applications (2023 ACEP Emergency Ultrasound Guidelines)
15項急診超音波核心應用

陳國智醫師

Aorta

DVT

Trauma

Thoracic/Airway

Cardia/HD assessment

Procedural Guidance

US-guided NB

Testicular

Ocular

Skin & Soft tissue

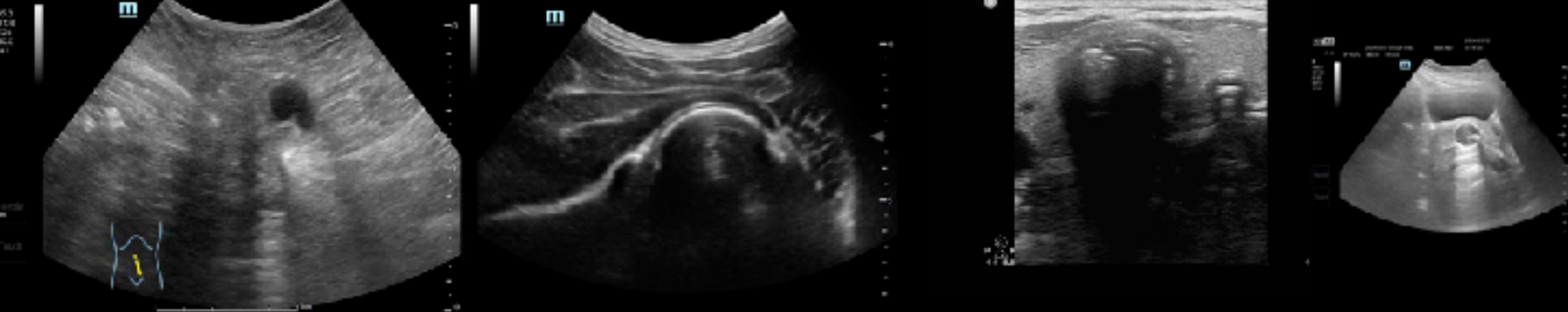
Hepatobiliary

Urinary tract

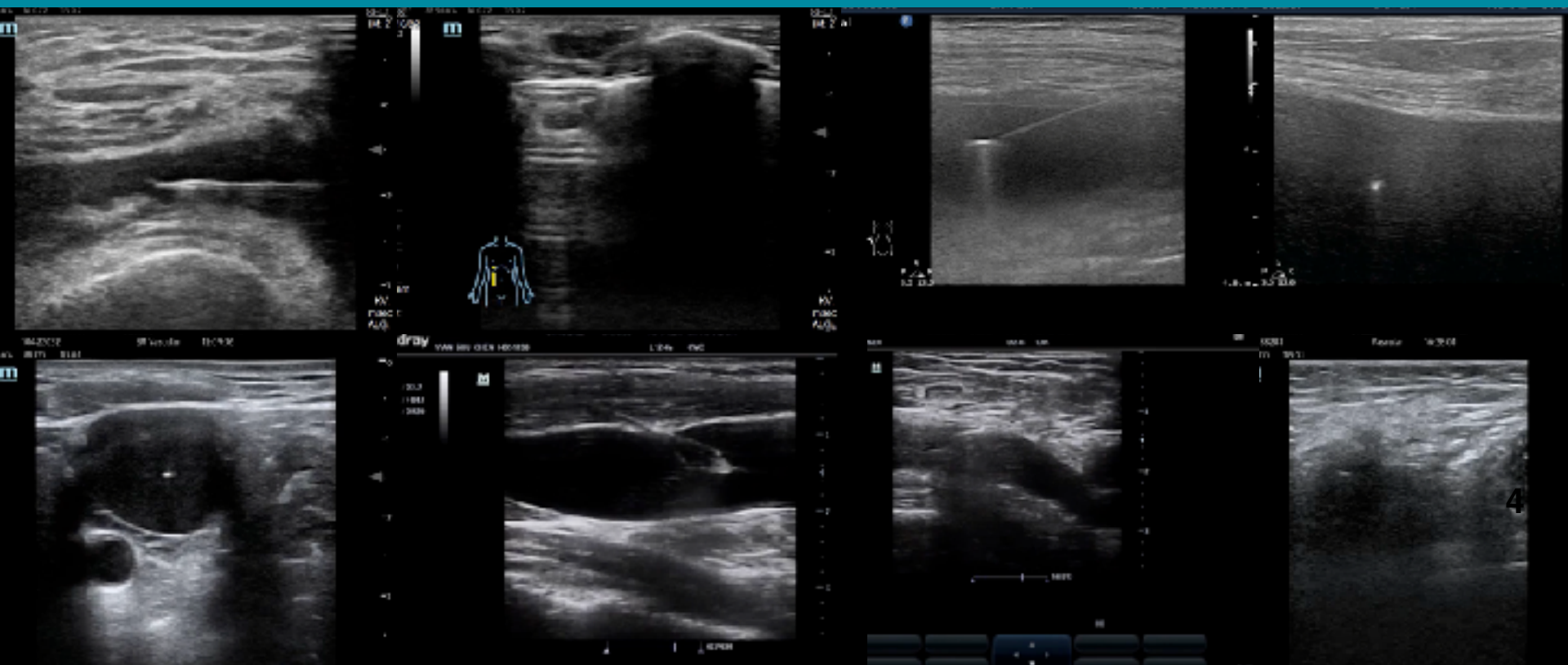
Pregnancy

Bowel

MSK



POCUS - Basic Procedures



探頭先走
要往回看
緊盯針尖

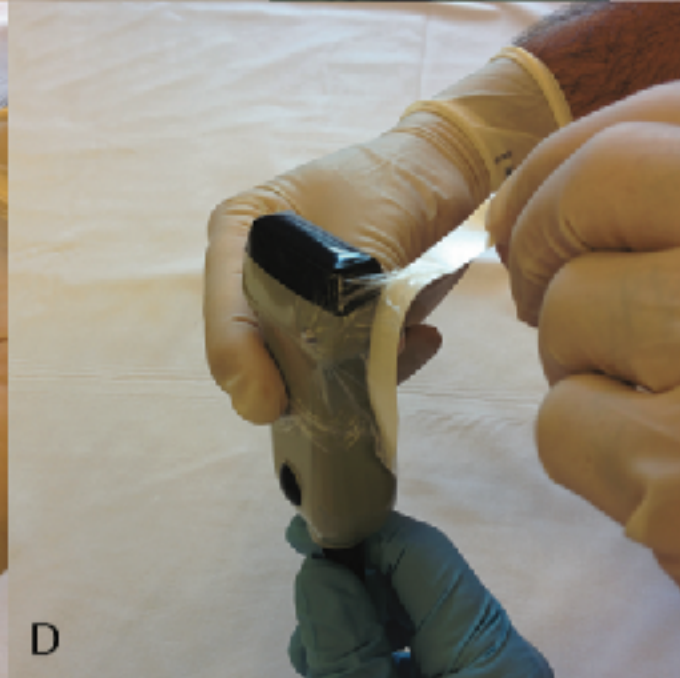
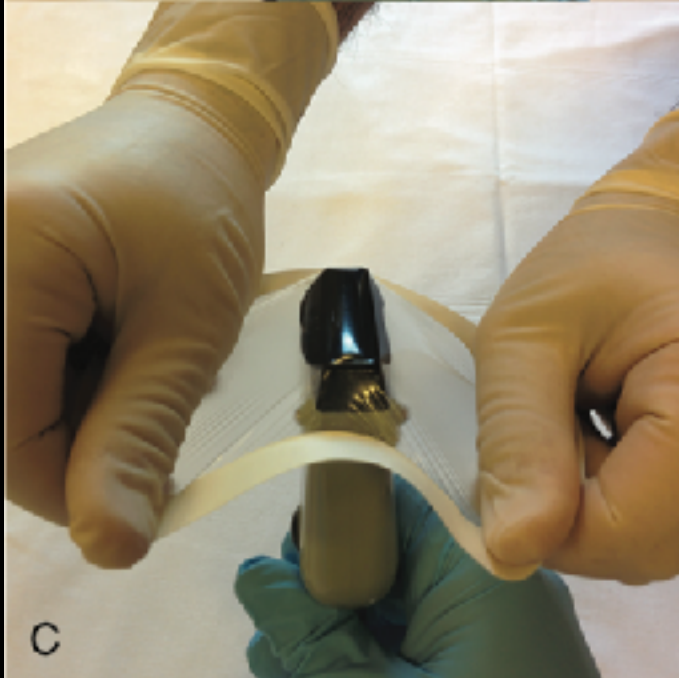
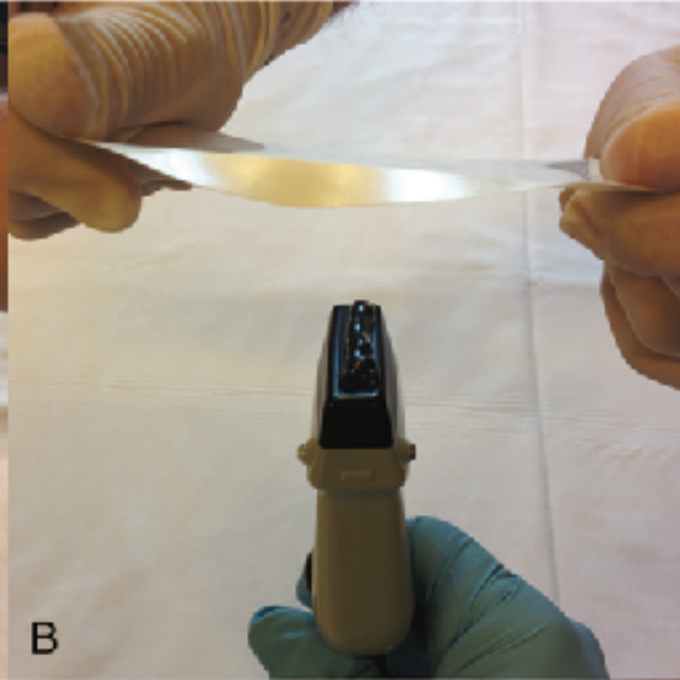
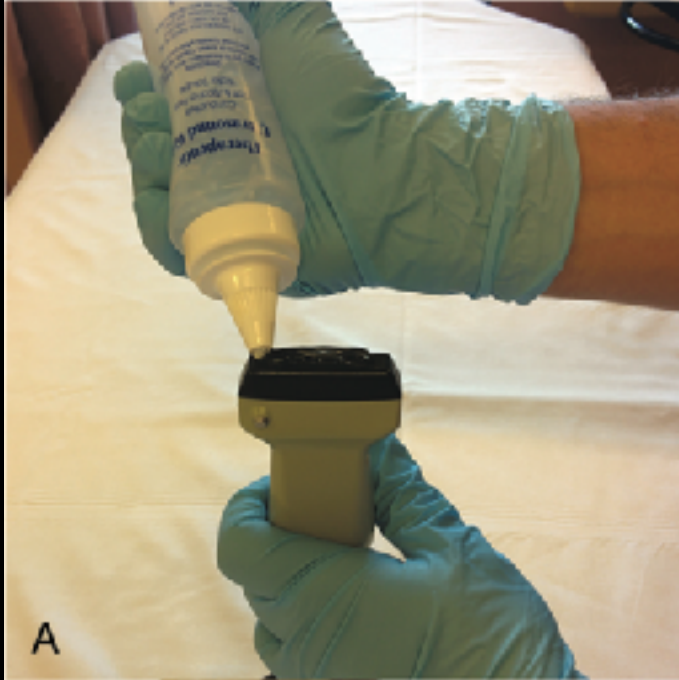


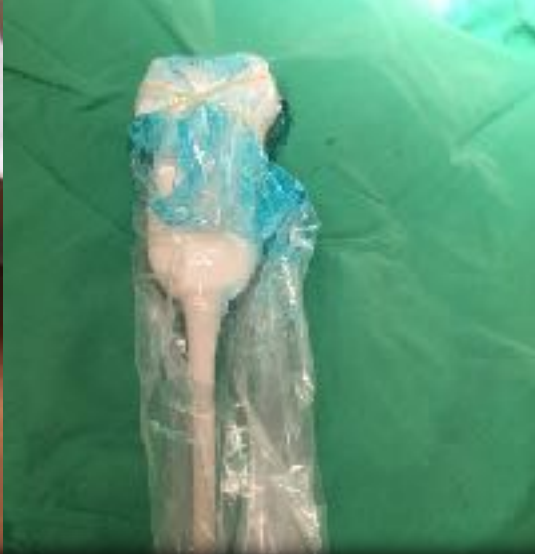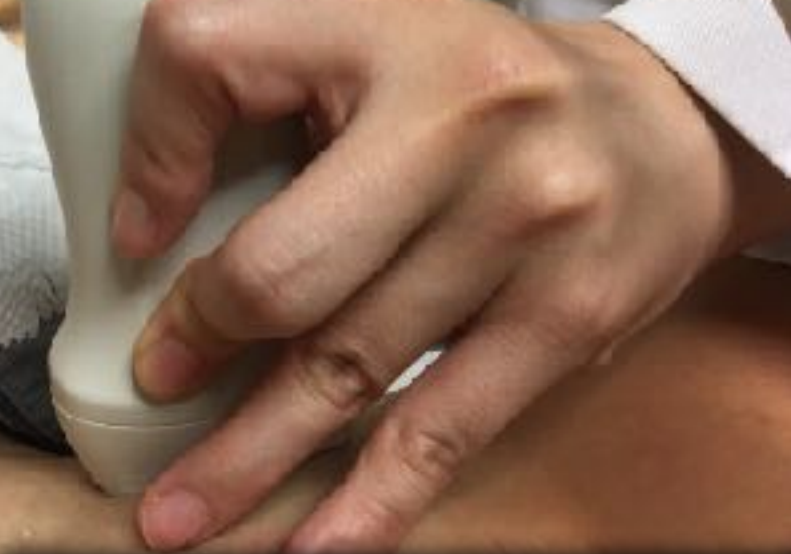探頭要正
目標不動
淺淺入針

MASTER NEEDLING

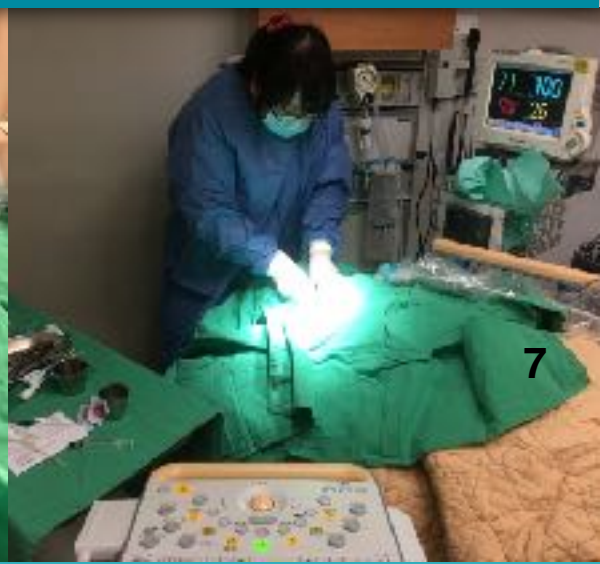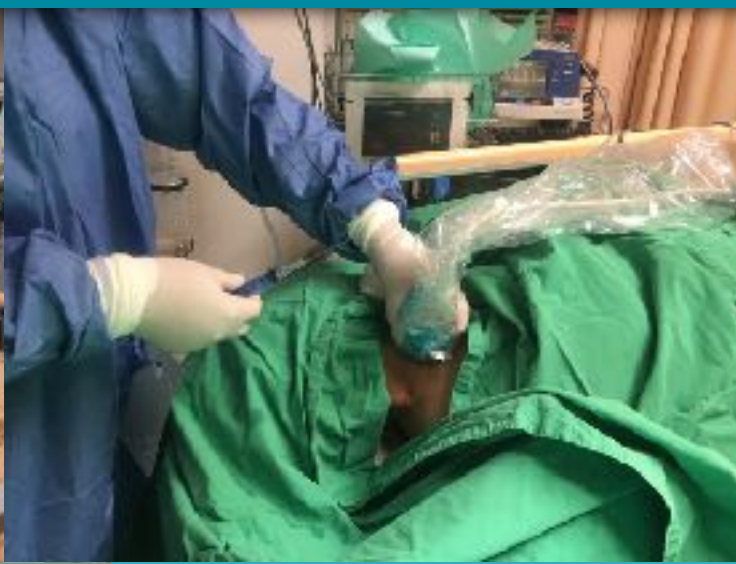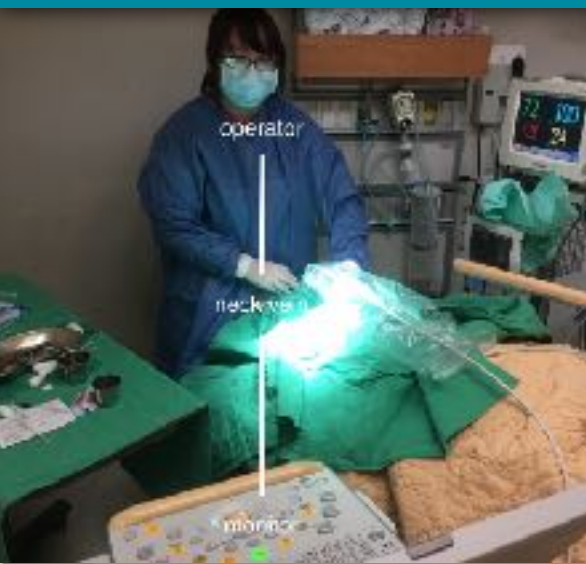Off-plane

In-plane

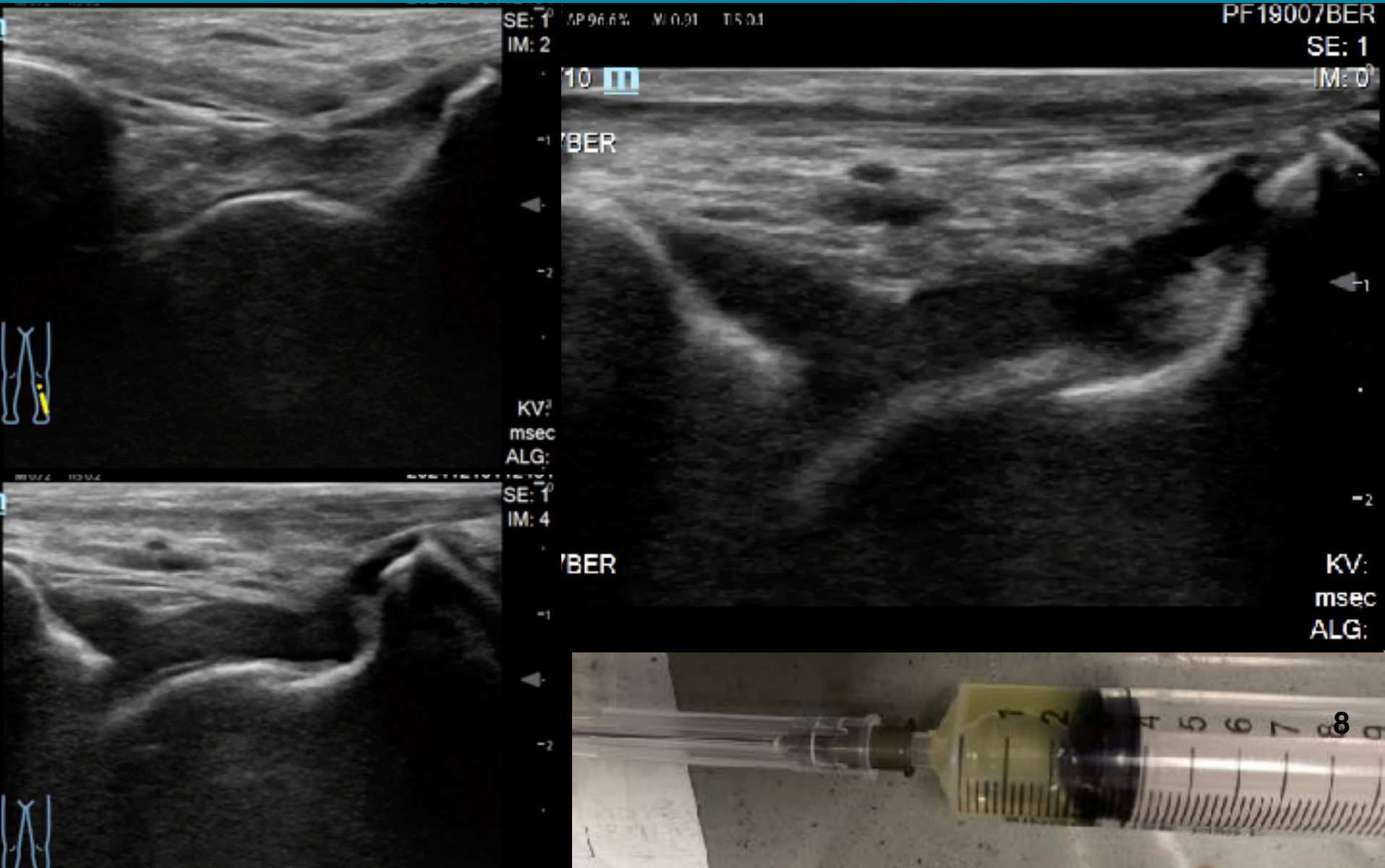




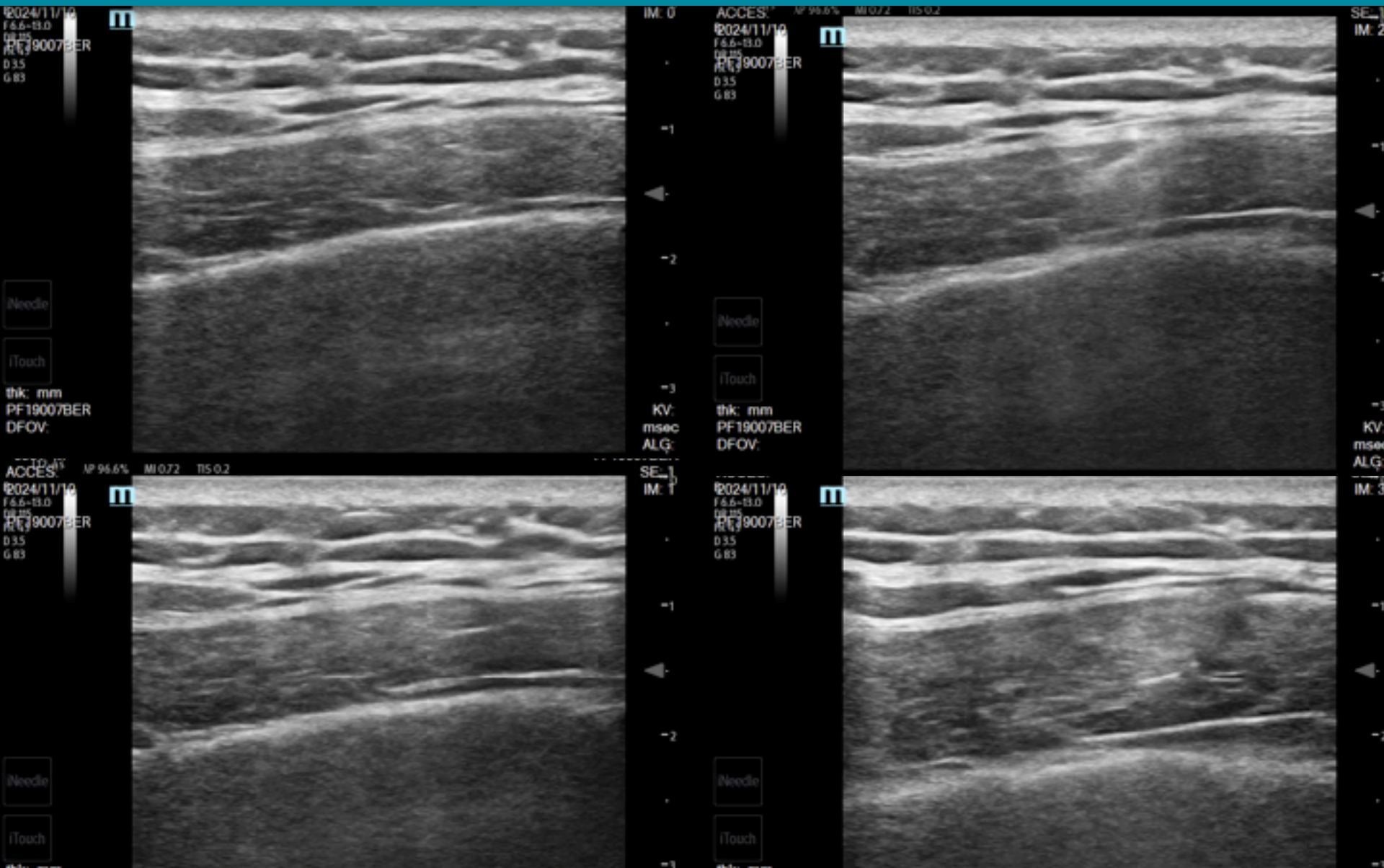
US-guided CVC



Arthrocentesis, ankle

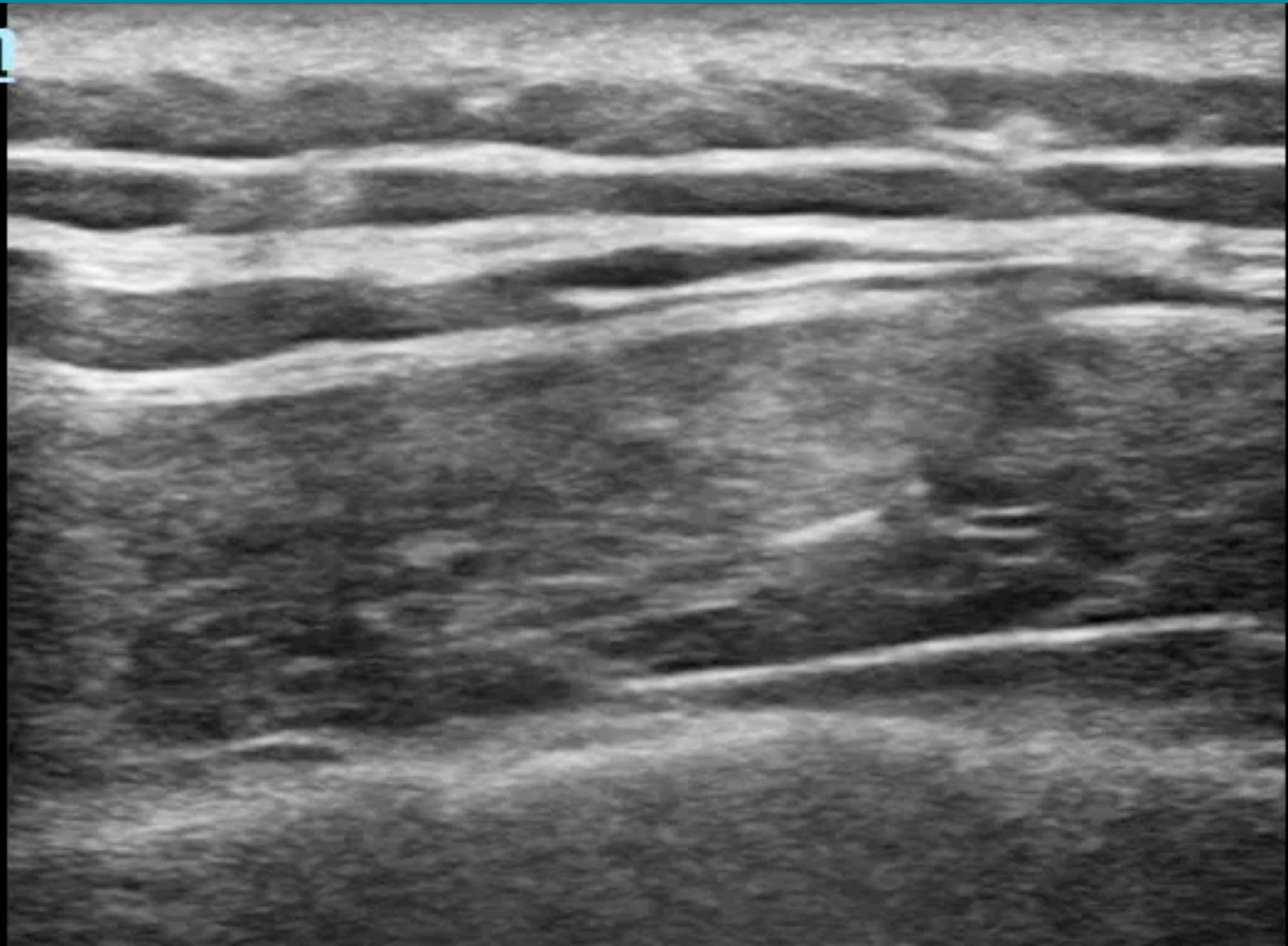


50M, right upper shoulder / back pain 1wk



Myofascial pain injection

2024/11/10
F 6.6~13.0
DB 115
PF19007BER
PR 49
D 3.5
G 83



IM: 3

-1



-2

-3

KV:

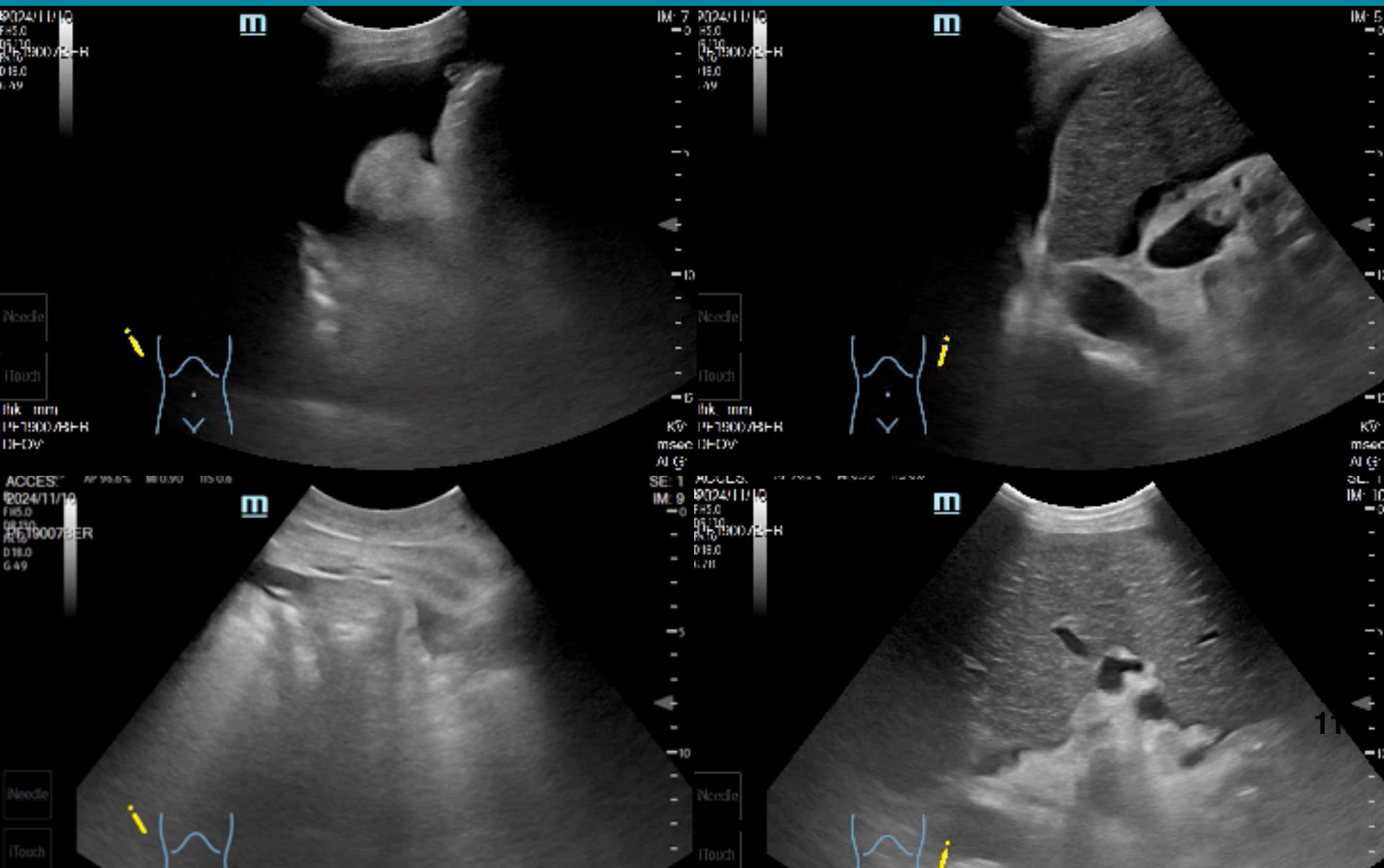
iNeedle

iTouch

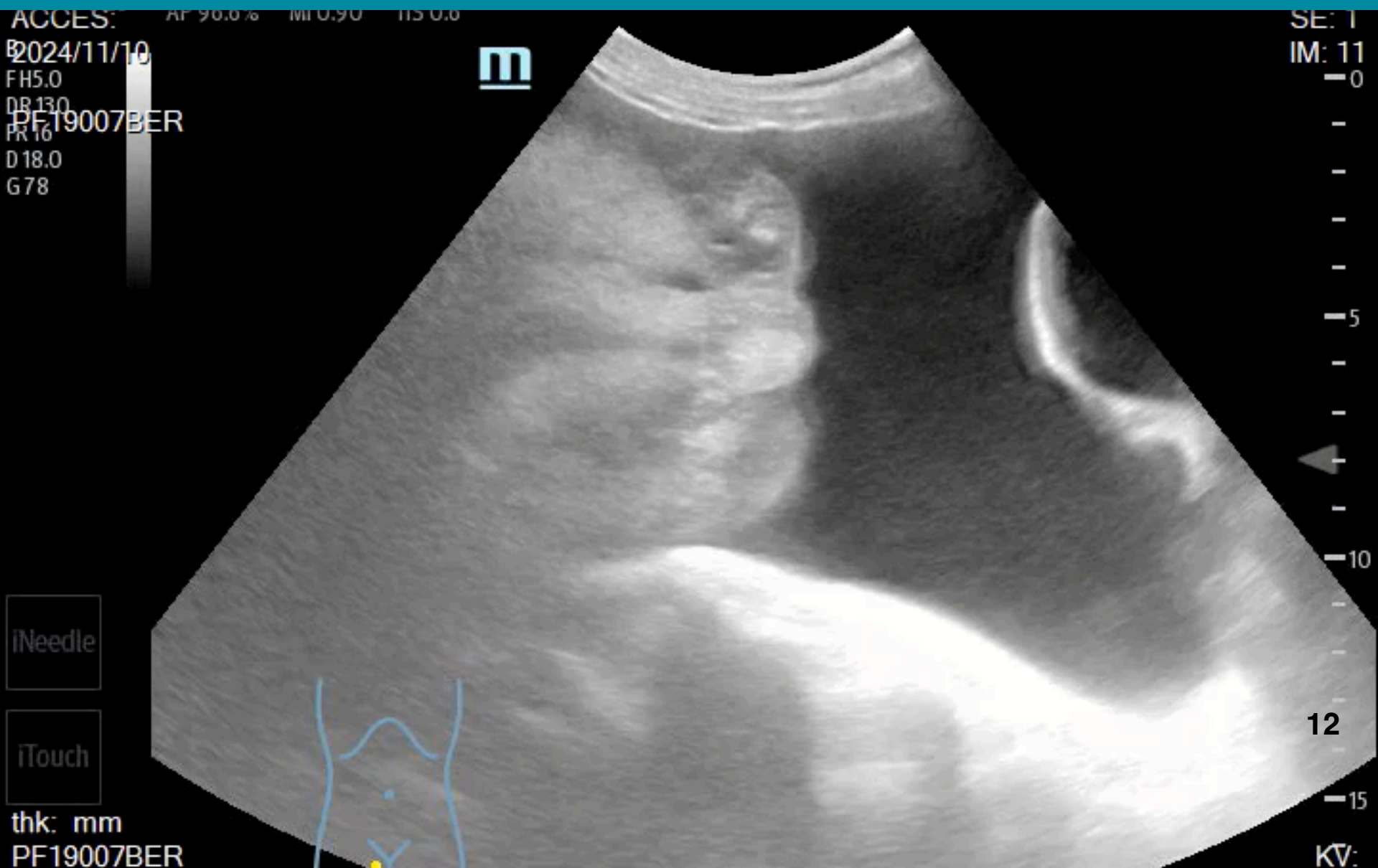
thk: mm
PF19007BER
DECV

Infraspinatus muscle injection
Shincort 1 ml / lidocaine 2% 3 ml

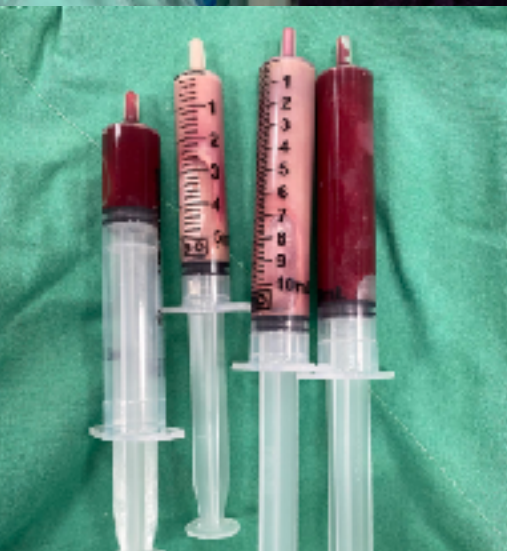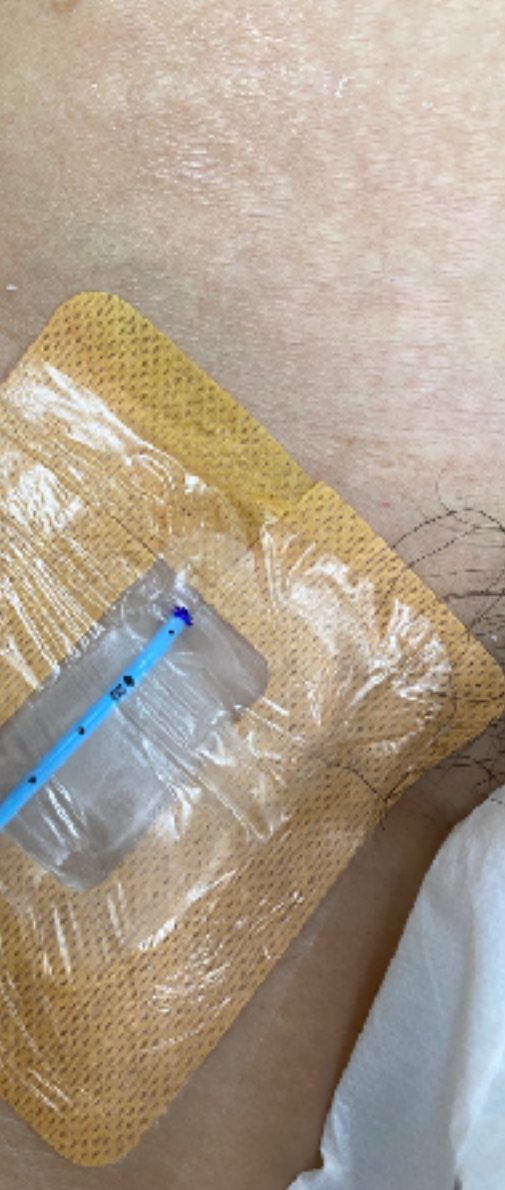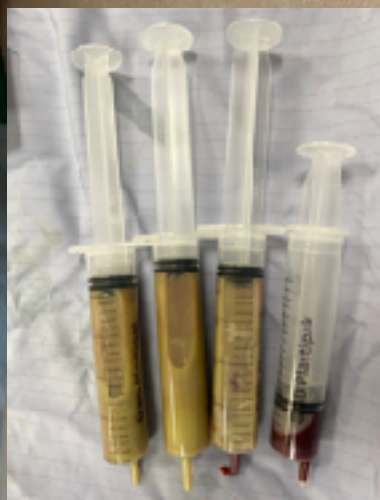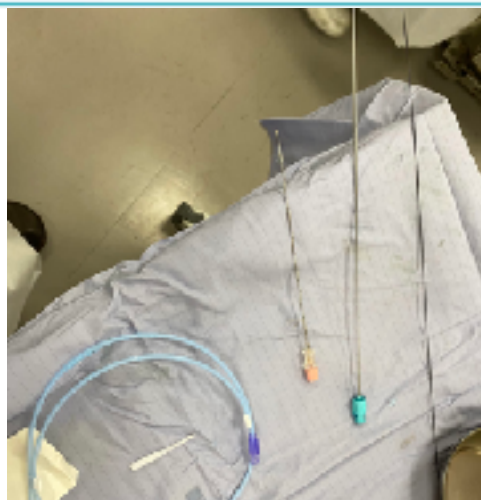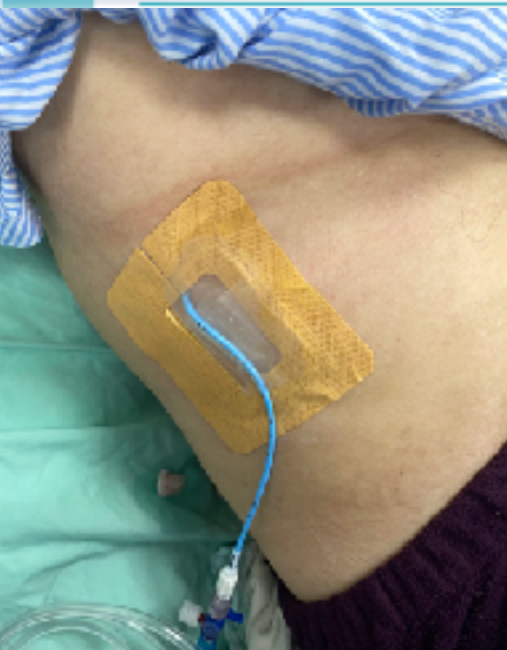72M, cirrhosis, difficult paracentesis



Suprapubic paracentesis 2000ml



超音波導引介入性引流治療



NEO-SOF
Hydrophilic Drainage Catheters

*和特®引流導管及穿刺導管系統

引流導管組
Drainage Catheter Kit

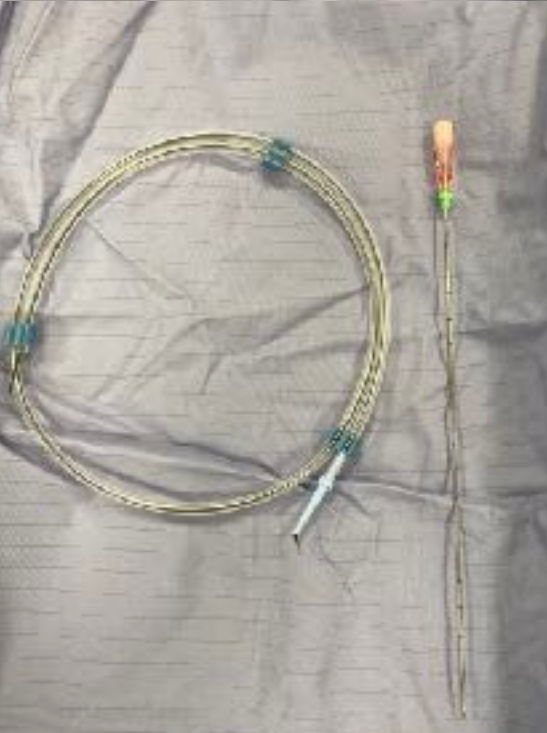
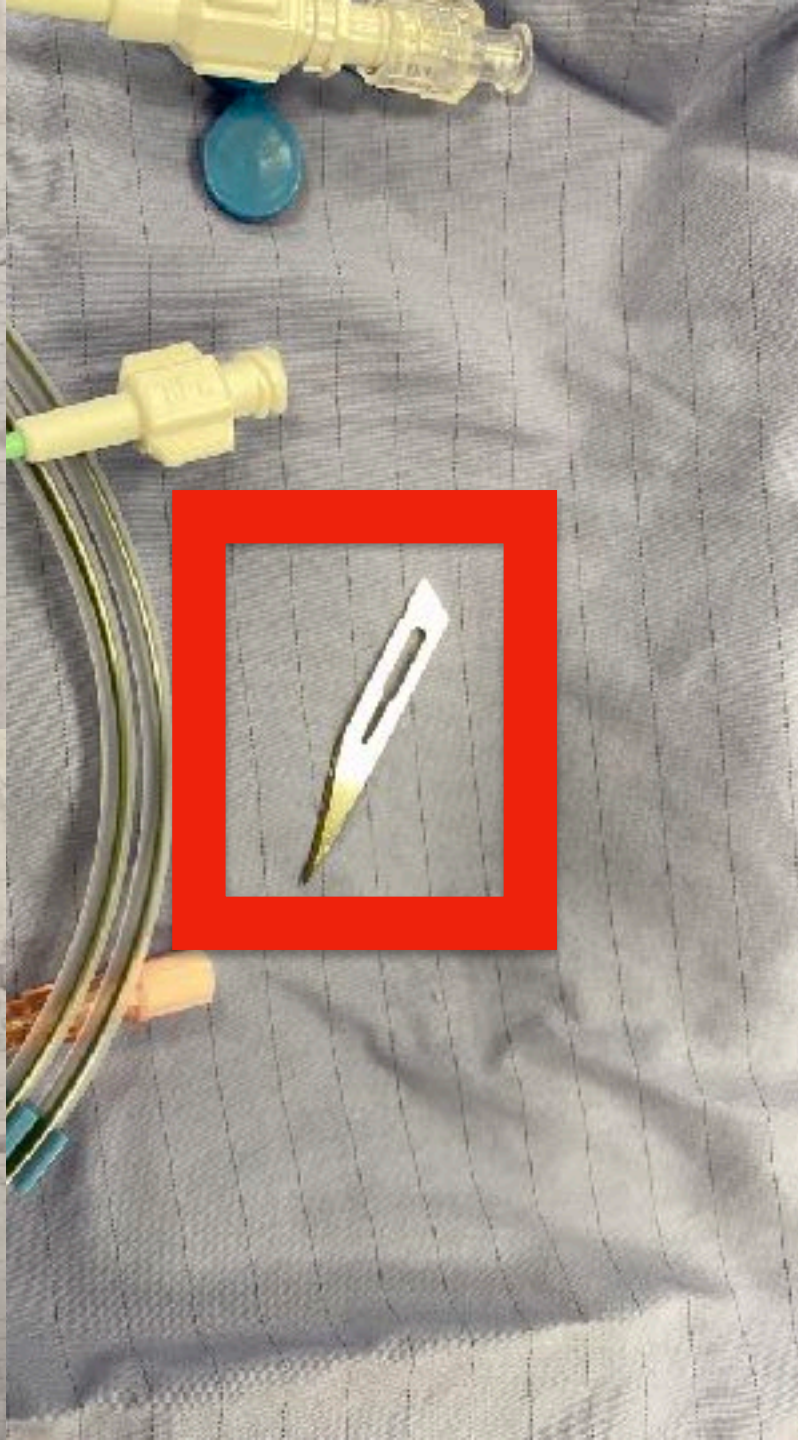
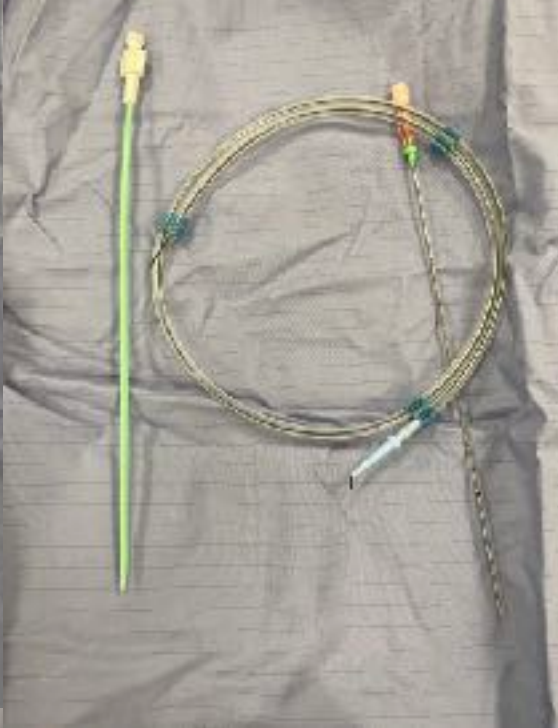規格：8FR - 帶線
表面親水性塗層設計
衛署醫器製字號00287D 號
藥商：邦特生物科技股份有限公司

8FR (2.85mm)
總長0.83M 帶線
A=30cm B=25cm

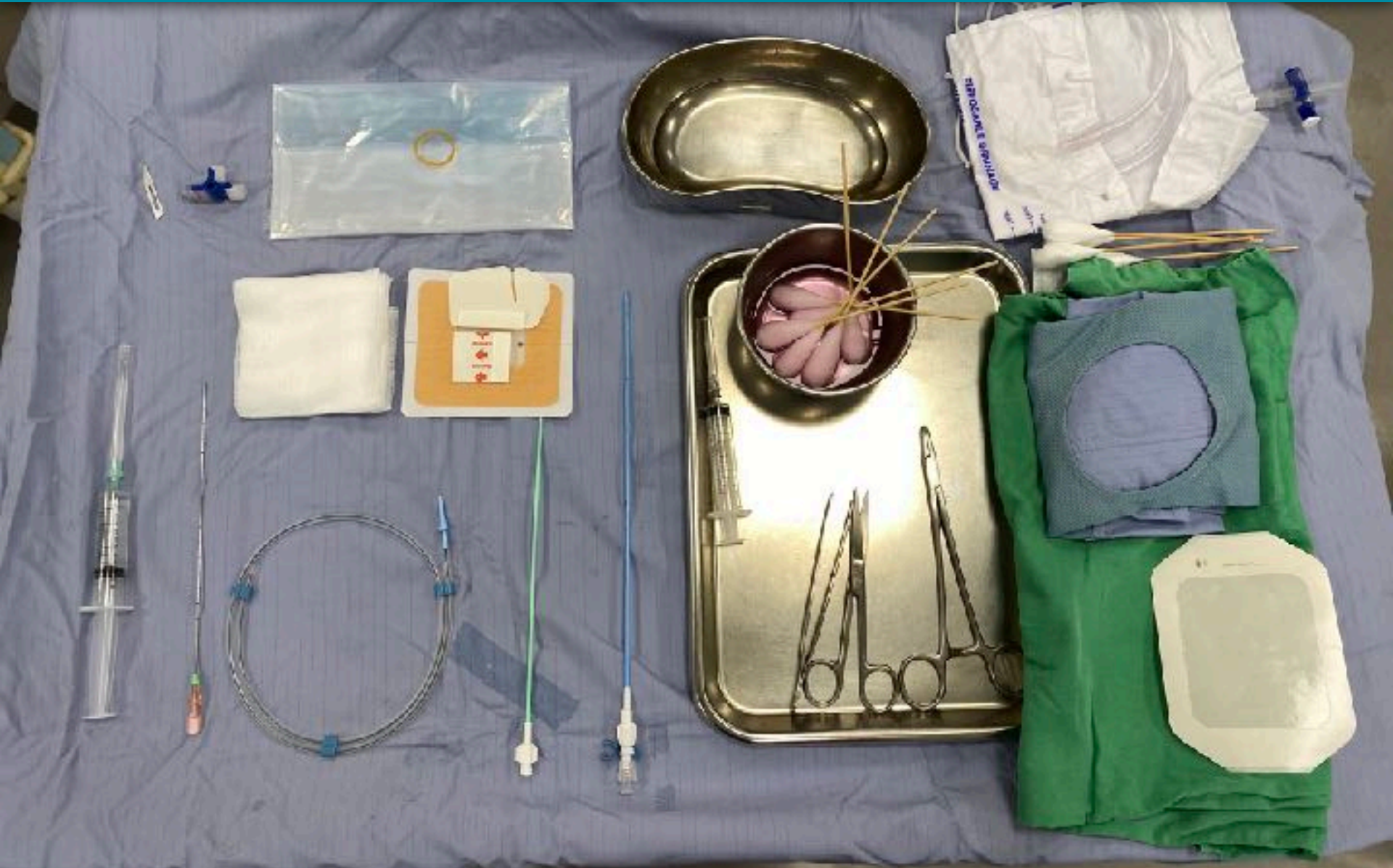內容物：

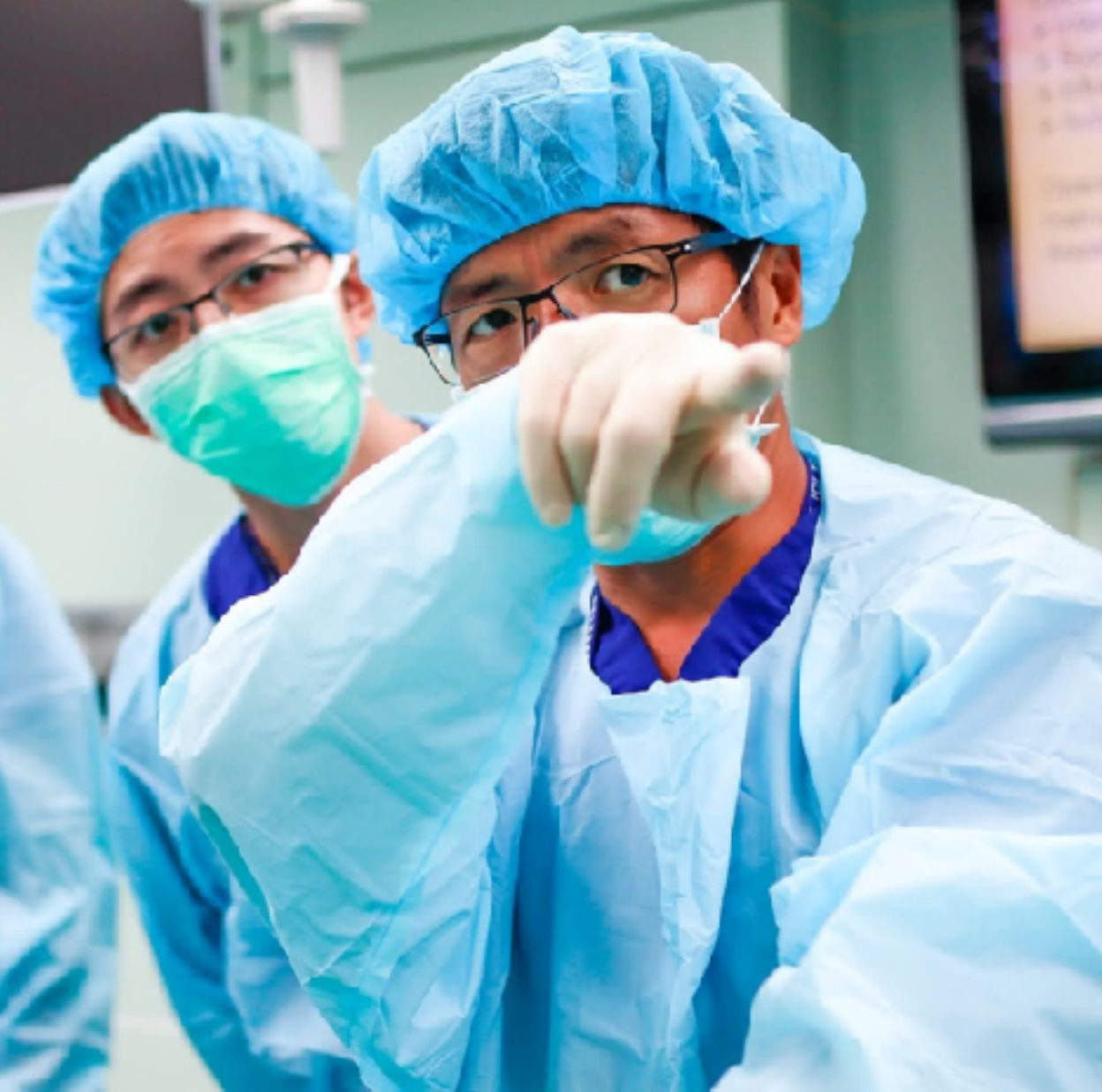(1) 導管	(1) 高壓面紗紗布
(1) 導管架	(1) 導尿管
(1) 穿刺架	(1) 手套袋
(1) 膠尿管 (1.5x20cm)	(1) 蓋轉圈
(1) 膠尿管 (1.5x10)	
(1) 引流鋼線 (0.037)	

0 561 5660 5630 0 010101 0100000

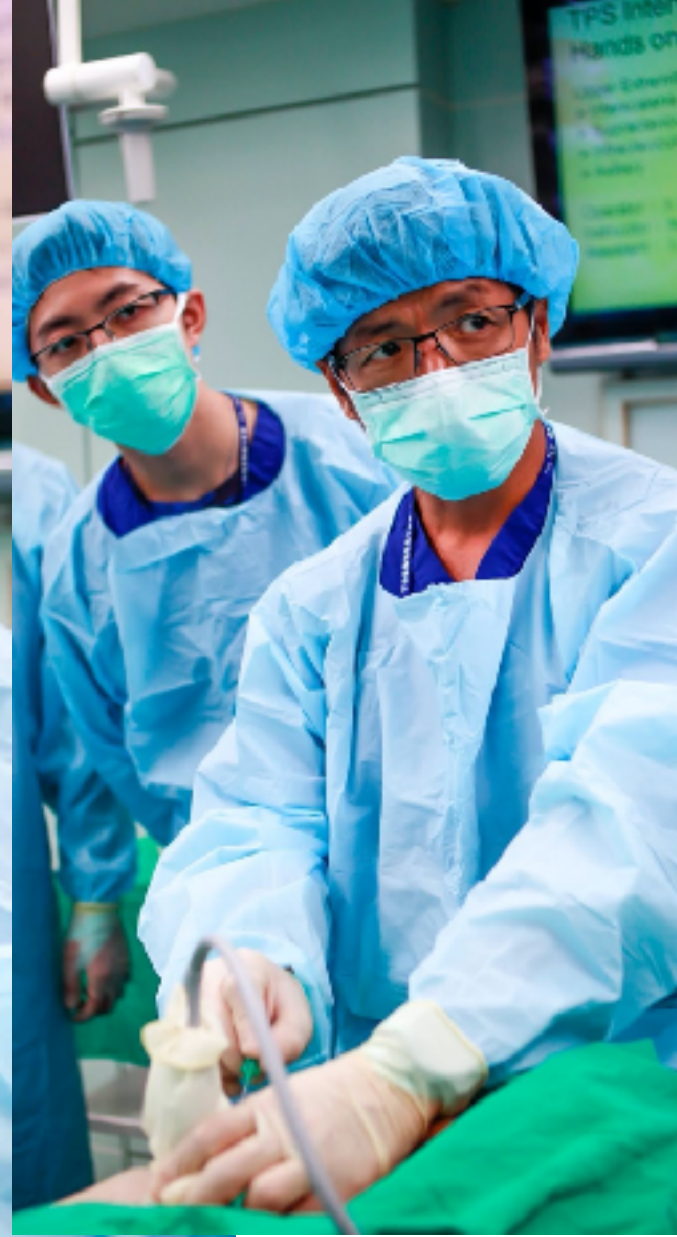

Be prepared !! Monitor / Pain control / PSA



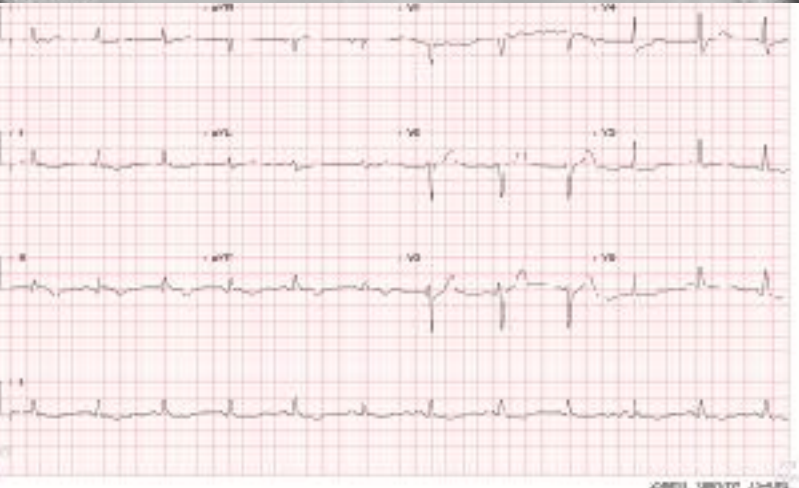
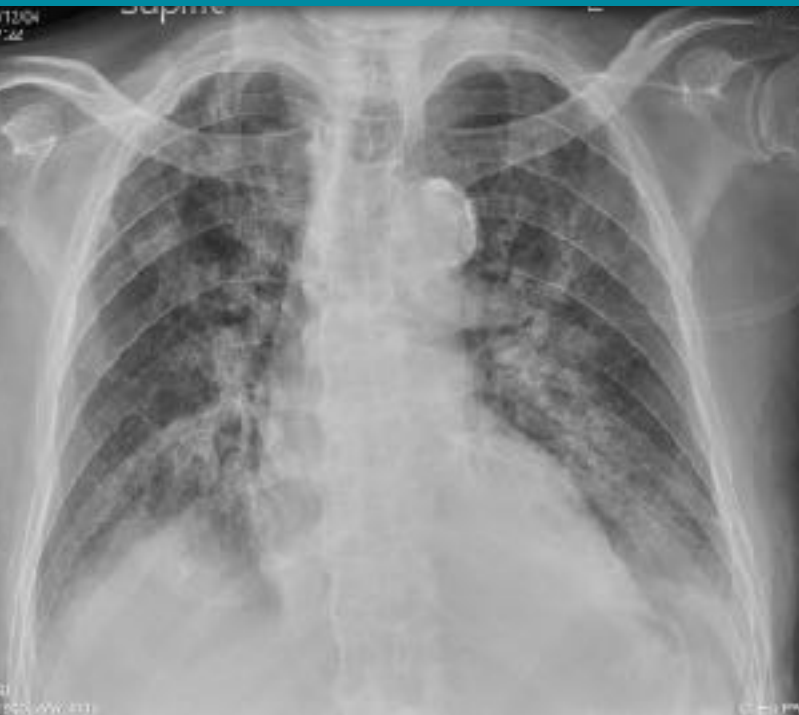

Diagnostician

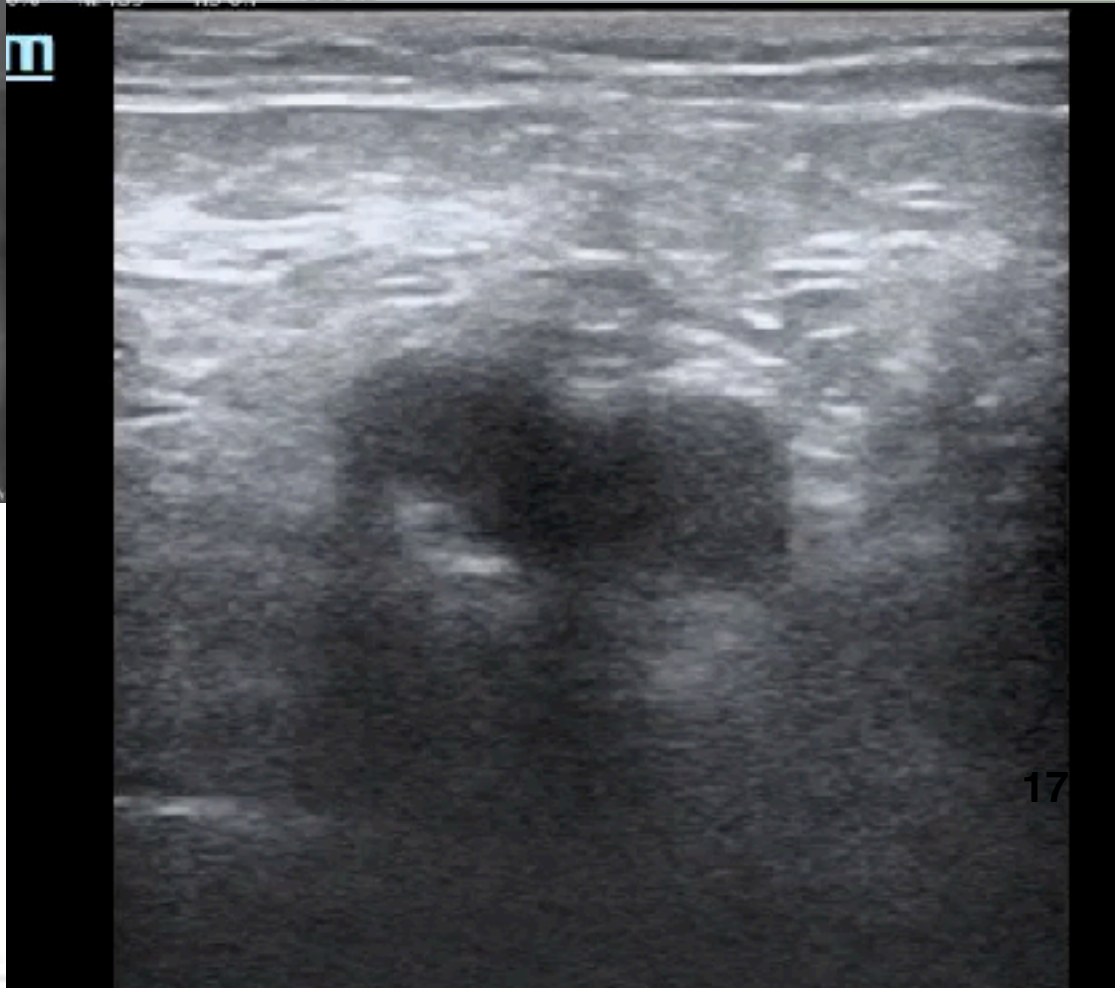


Interventionist

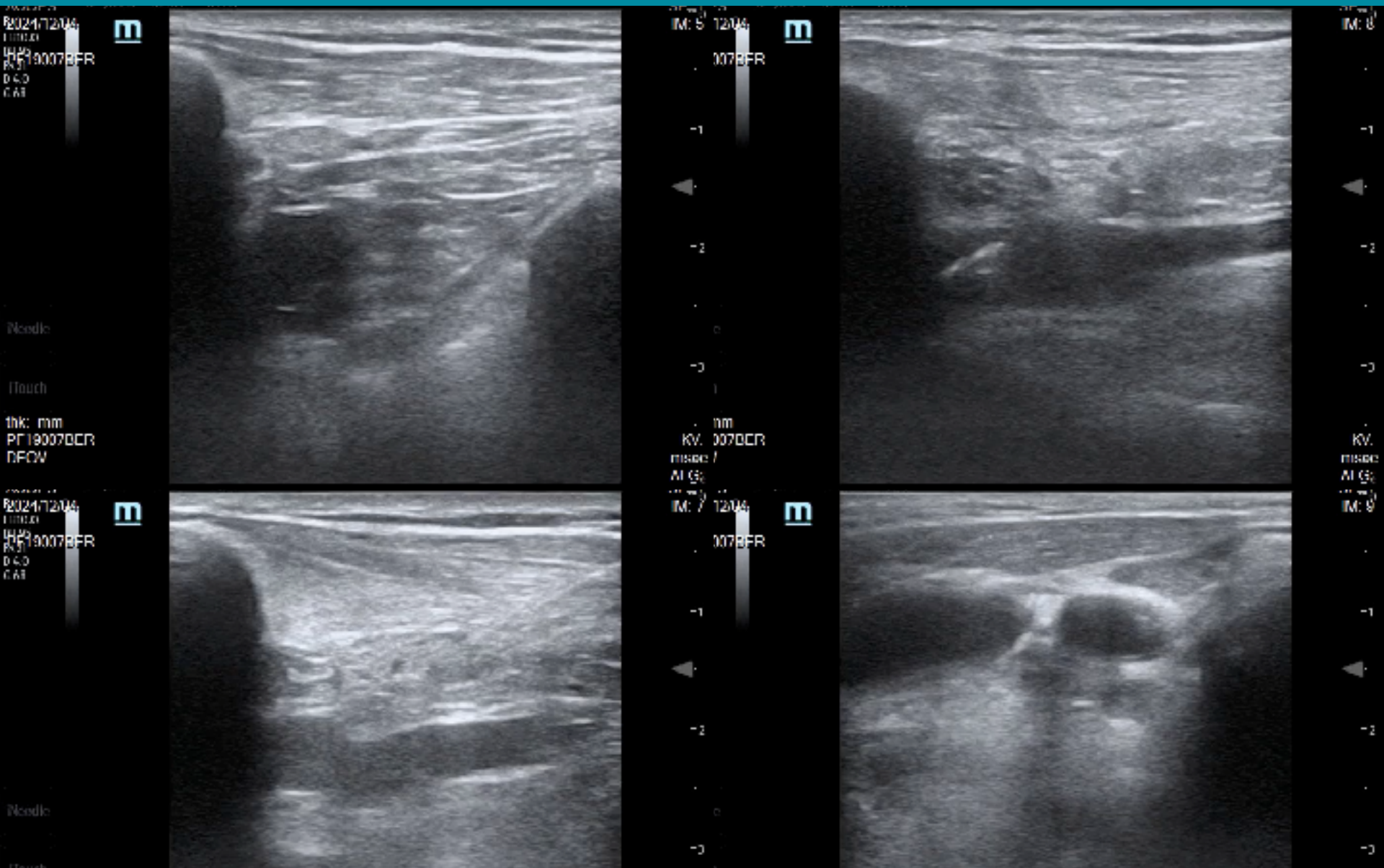
85F, uremic syndrome & metabolic acidosis (DL)



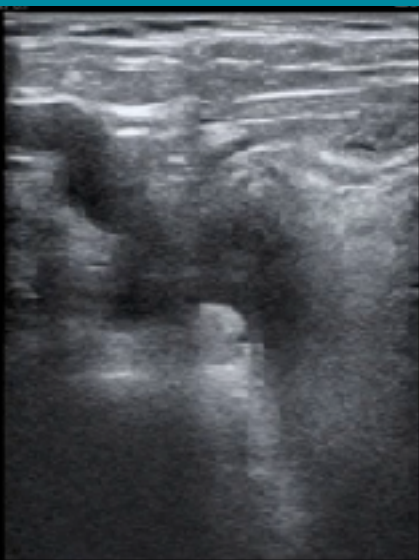
Urea N 10.0	Creatinine 7.8	BUN 7.1	Na 137	K 5.9	Cl 108	CO2 15.3	Lactate 12.9
Hemolysis 14	Blood grouping O+	Blood grouping O+	WBC 21.8	Hgb 7.6	HCT 22.7	MCV 104.1	
MCV 104.1	MCHC 24.5	RDW-CV 15.2	WBC 21.42	Neutrophil 91.0	Lymphocyte 0.3	Monocyte 5.5	
Eosinophil 0.0	Basophil 0.0	CRP 12.59	INR 1.70	PT 20.6	PT INR 1.59	MNPI 11.2	APTT 42.5
Troponin I 19404.1 *	BNP 12107.3	Blood gas pH 7.132	pCO2 20.6	pO2 45.3	SB 5.0	CO2Hb 65.0	
sO2 66.6	COHb 0.0	MetHb 0.8	HCO3 6.7	ABE 20.5	Glucose Random 249	Rh Type Positive	已檢驗
24389	Irregularantibody Screen Negative	血清尿酸濃度 1.6	other 已檢驗	已檢驗	24093		
WGR 0.0	Ca 8.1	P 4.3	GPT(ALT) 42	Cholesterol 132	TG 46	NCL 44	LDL 25
Uric acid 4.1	HbA1C 7.0	Glucose AC 55	Albumin 4.5	Recheck 已檢驗			



CVC for shock / NSTEMI



82F, Liver abscess, shock & MOF



SE: 1°
IM: 0



KV:
msec
ALG:

SE: 1
IM: 5°

-5

-10

-15

-20

-25

-30

KV:
msec

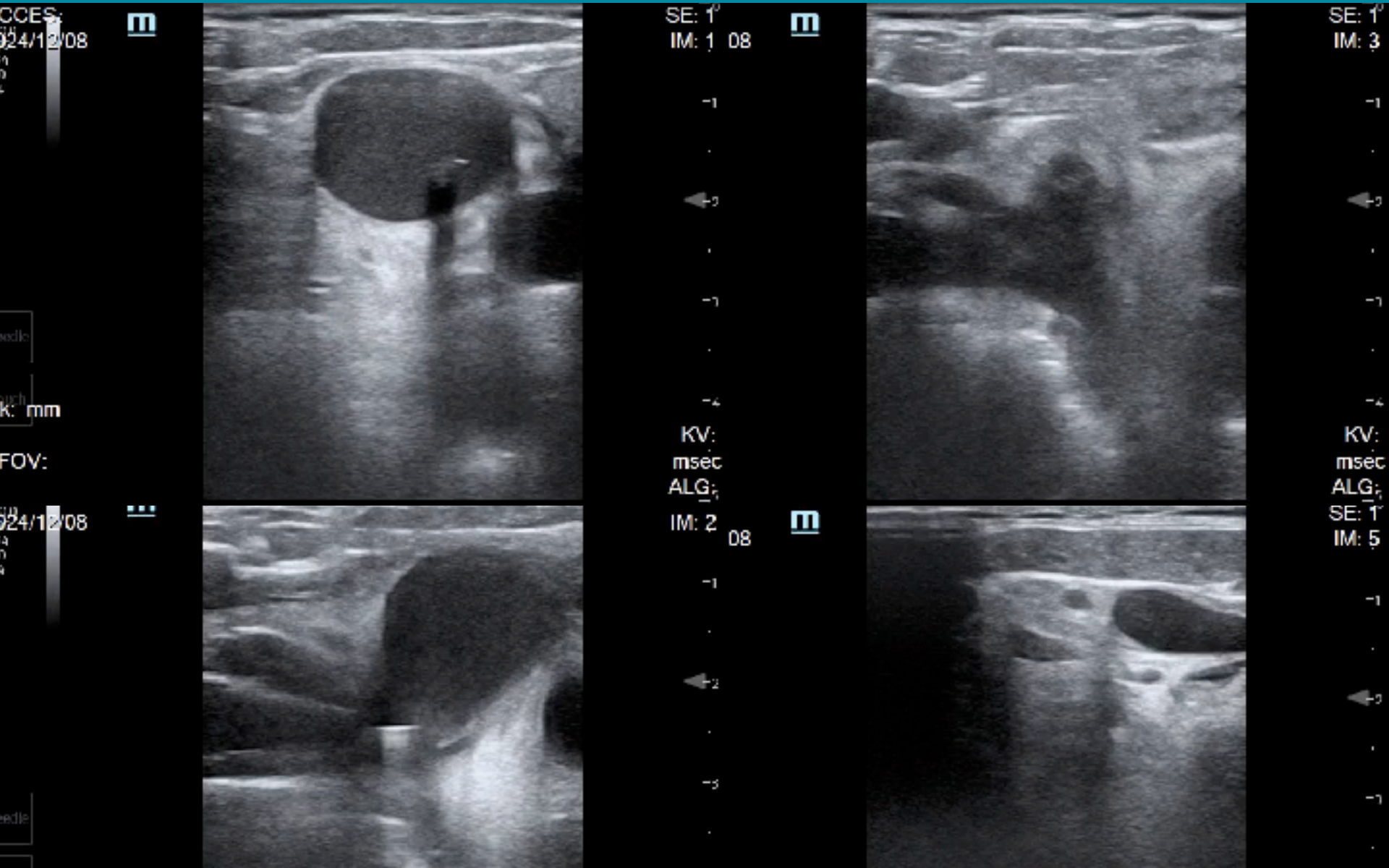
iNeedle

iTouch
thk: mm

PF19005CER

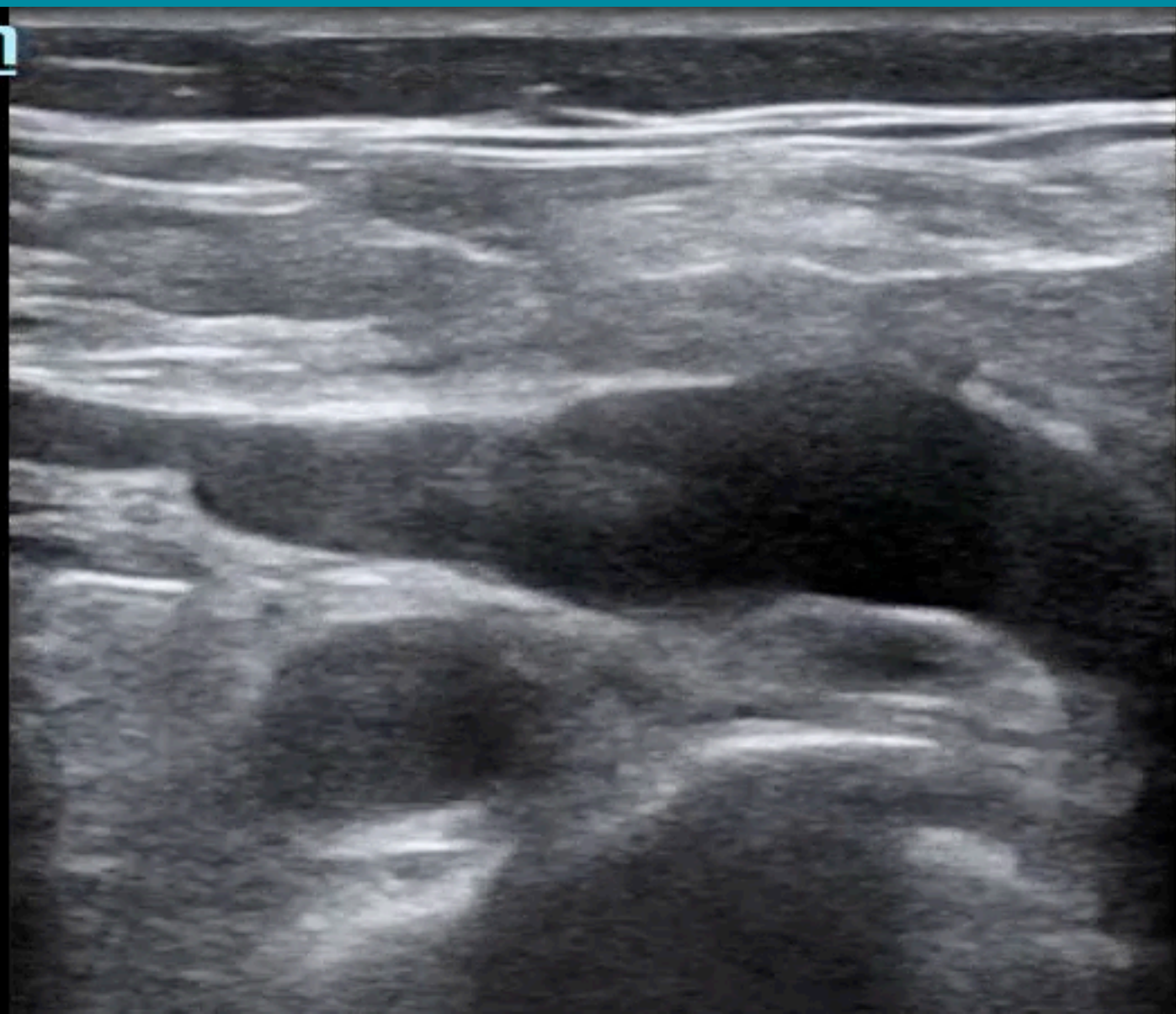
DFOV:

Redirect CVC (IJV to brachiocephalic vein)



65F, Urosepsis, shock, status epilepticus

2024/09/14
FH10.0
DB 95
PF19005CER
FR 51
D3.5
G50



IM: 0

-1



-2

-3

KV:

msec

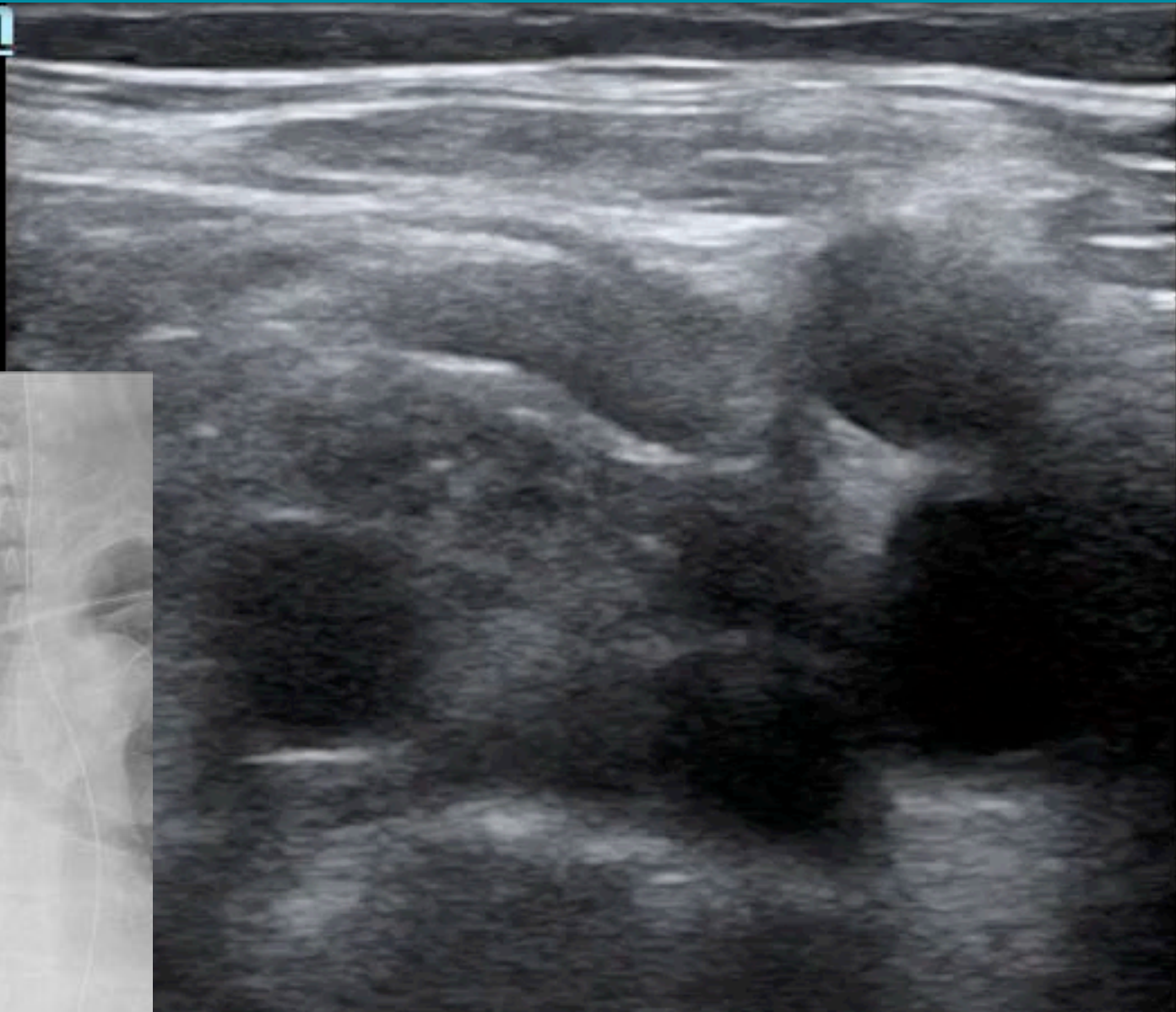
iNeedle

iTouch

thk: mm
PF19005CER
DEOV:

Supraclavicular CVC - SA / IP approach

2024/09/14
FH10.0
DR 95
DE19005CER
FR 51
D 3.5
G 50



IM: 1

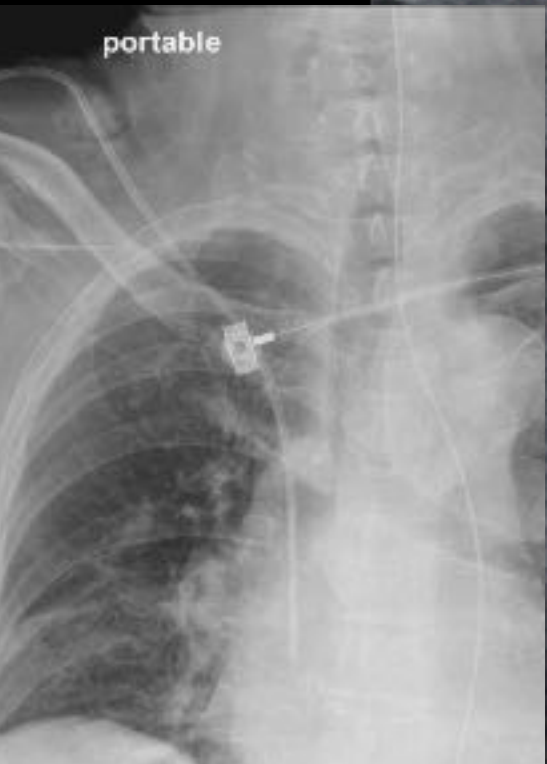-1



-2

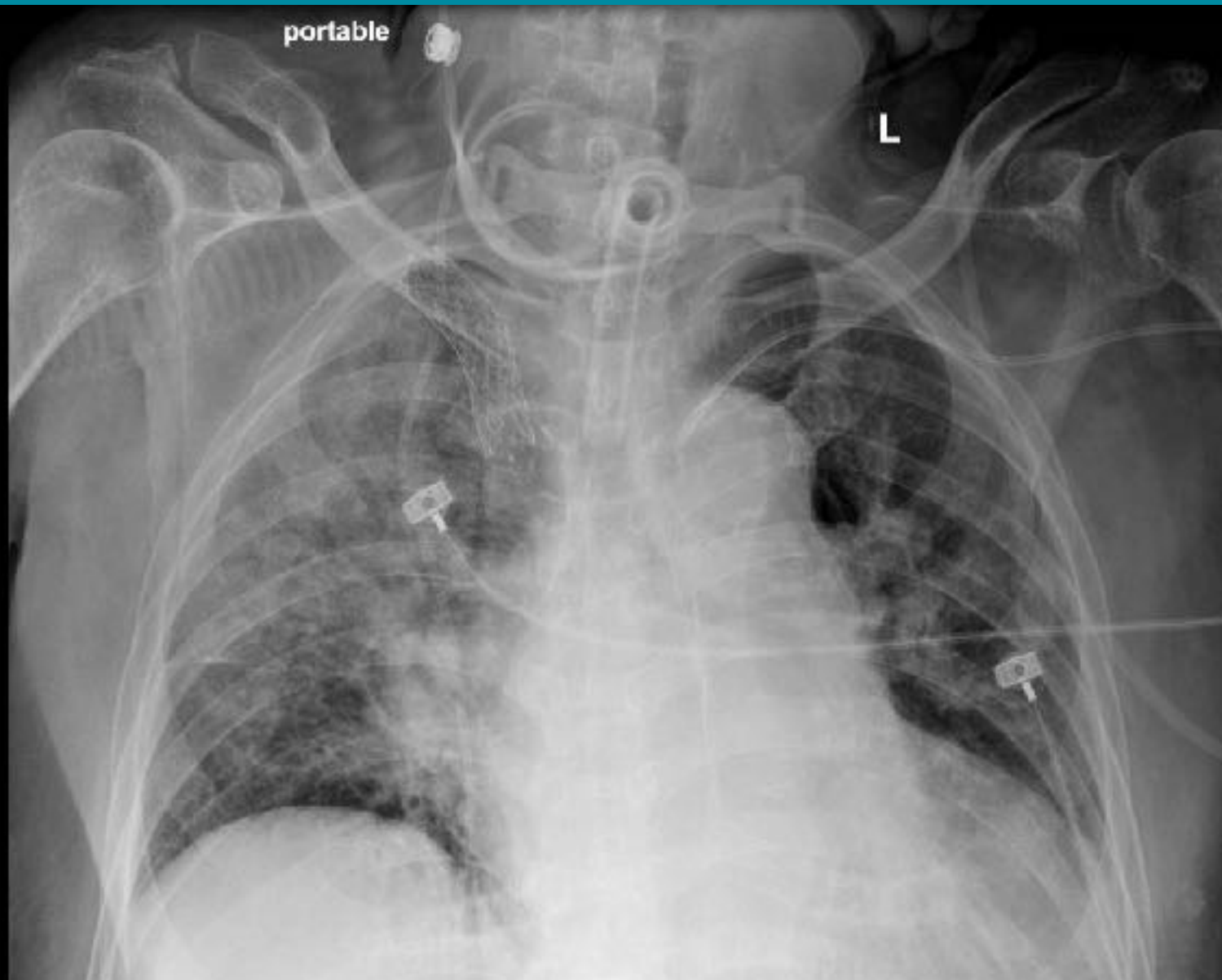-3

KV:
msec



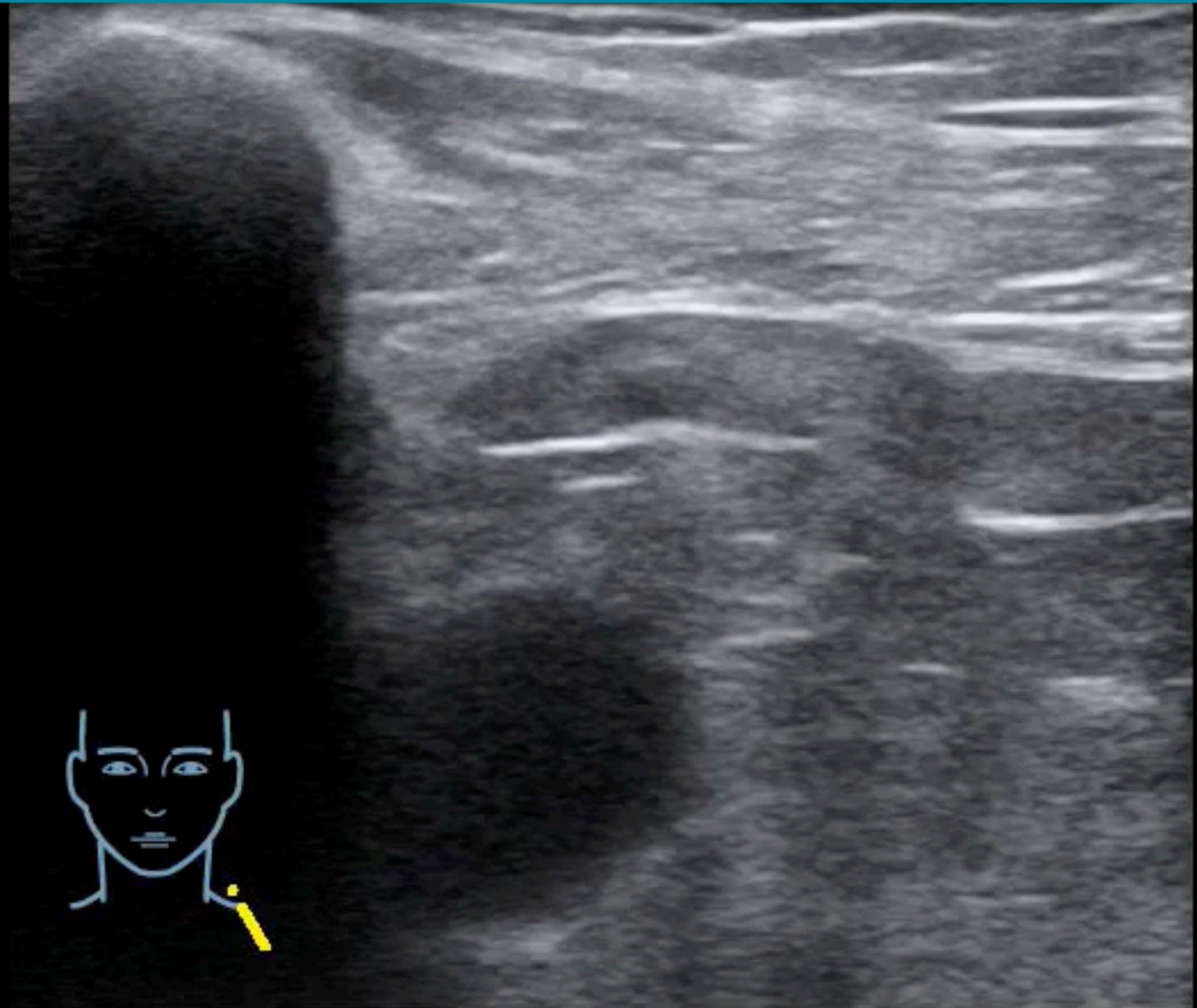
portable

76M, PN, Urosepsis, Shock, ESRD on HD



Axillary CVC

DR 95
PF19007BER
PR 51
D3.5
G50



-1

-2

-3

KV:
msec
ALG:

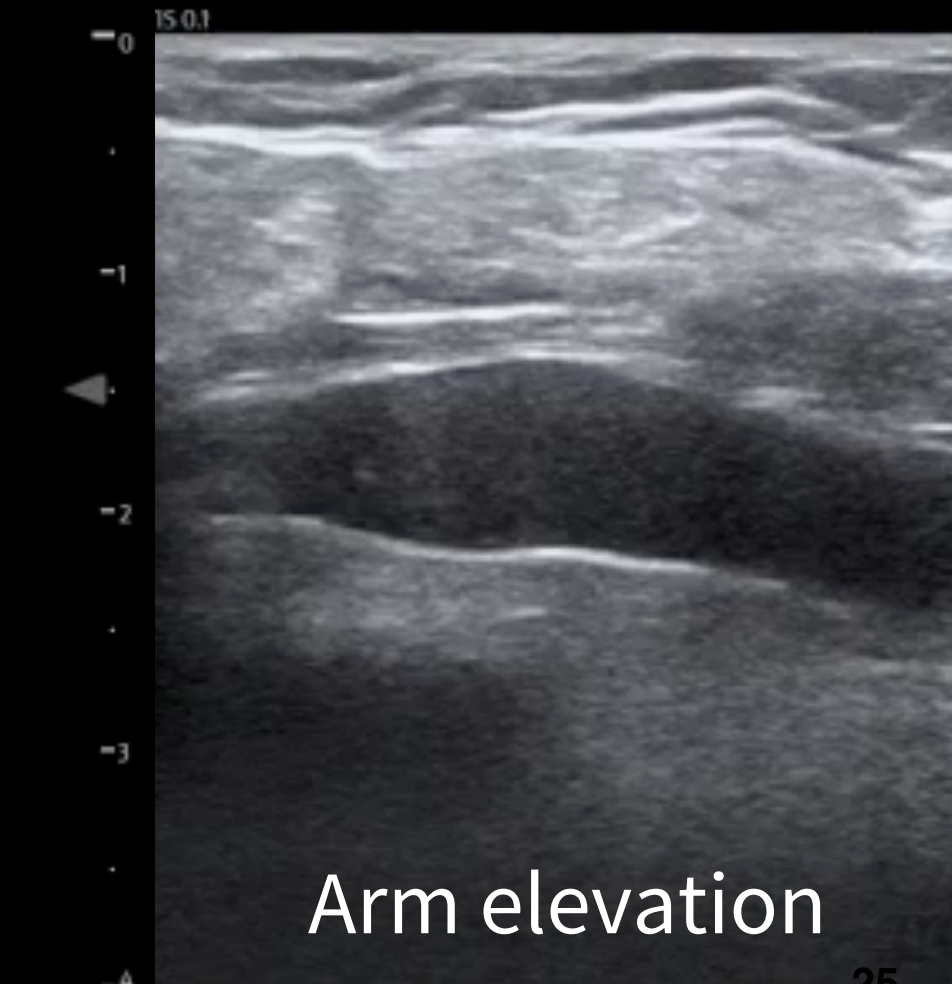
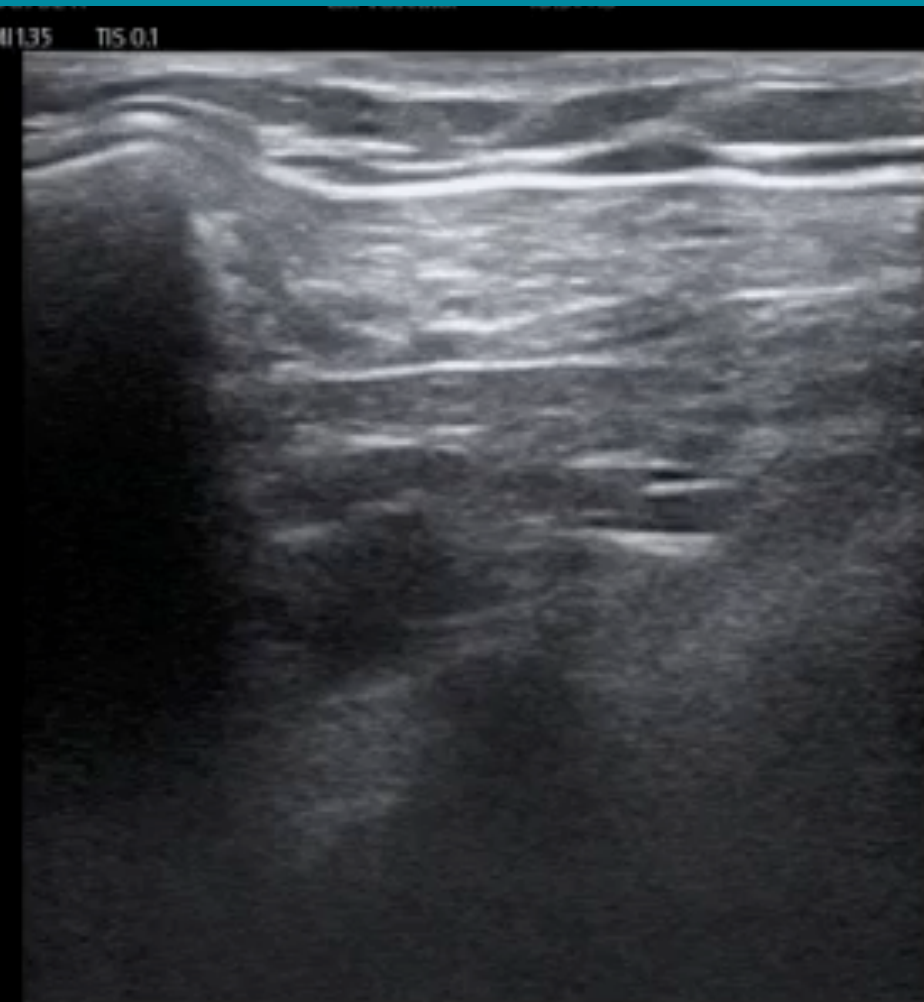
iNeedle

iTouch

thk: mm
PF19007BER
DFOV:

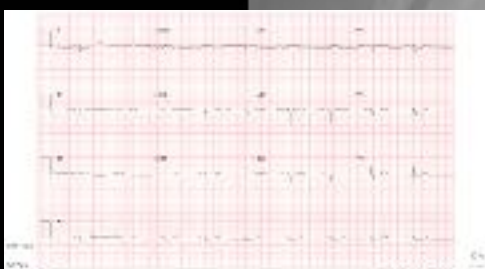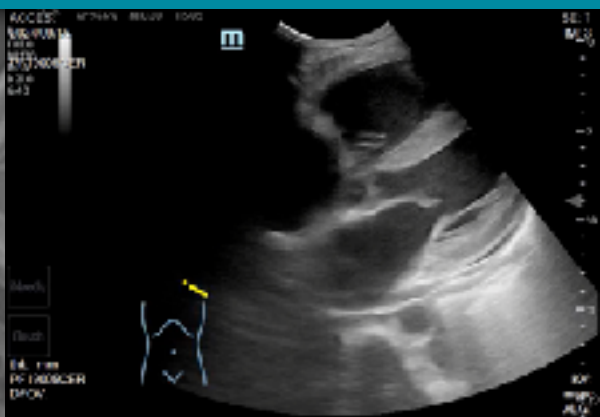
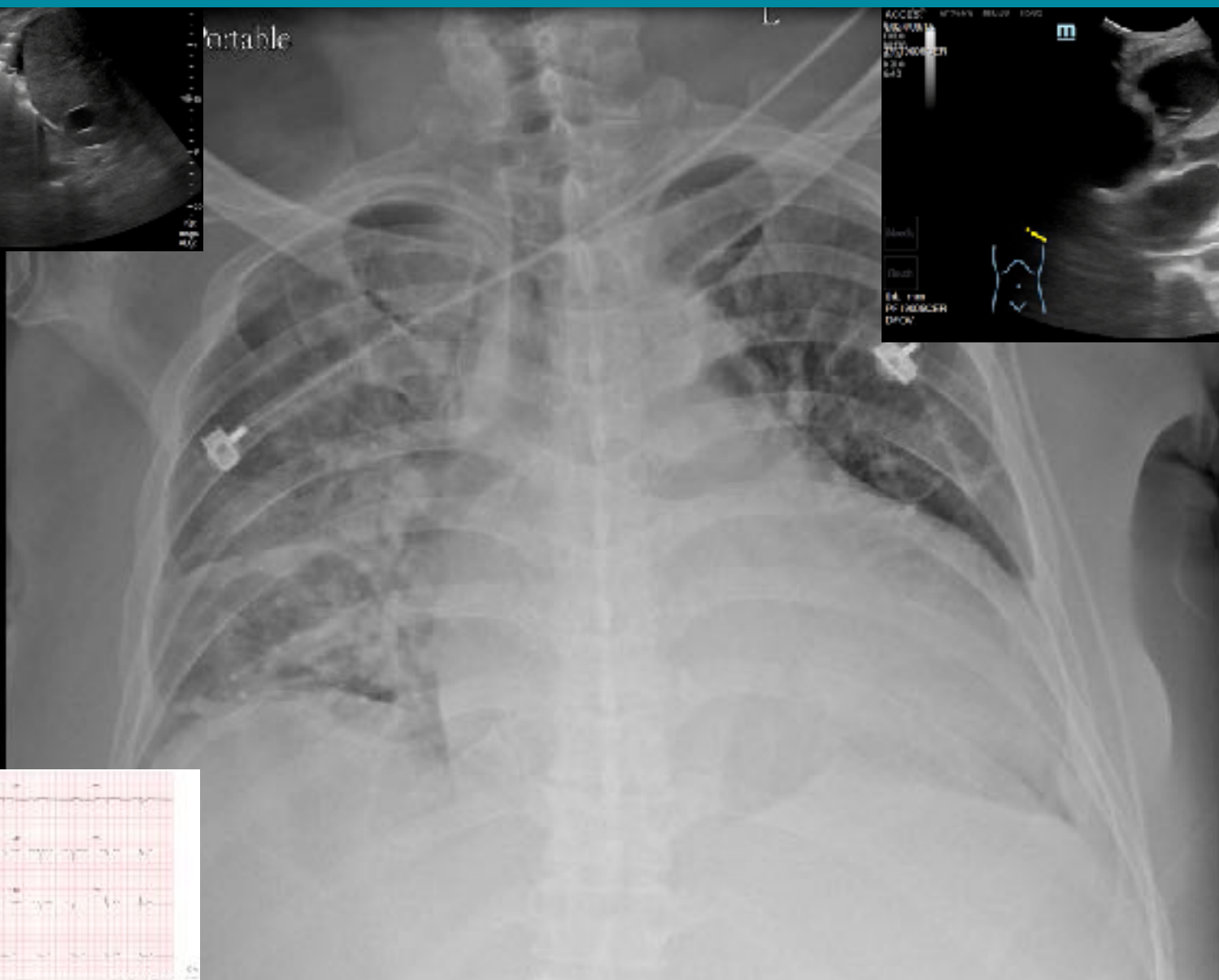
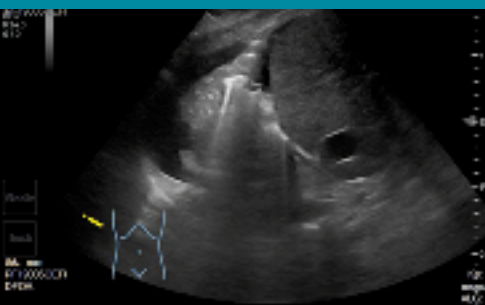


79F, Septic shock, HHS, acidosis

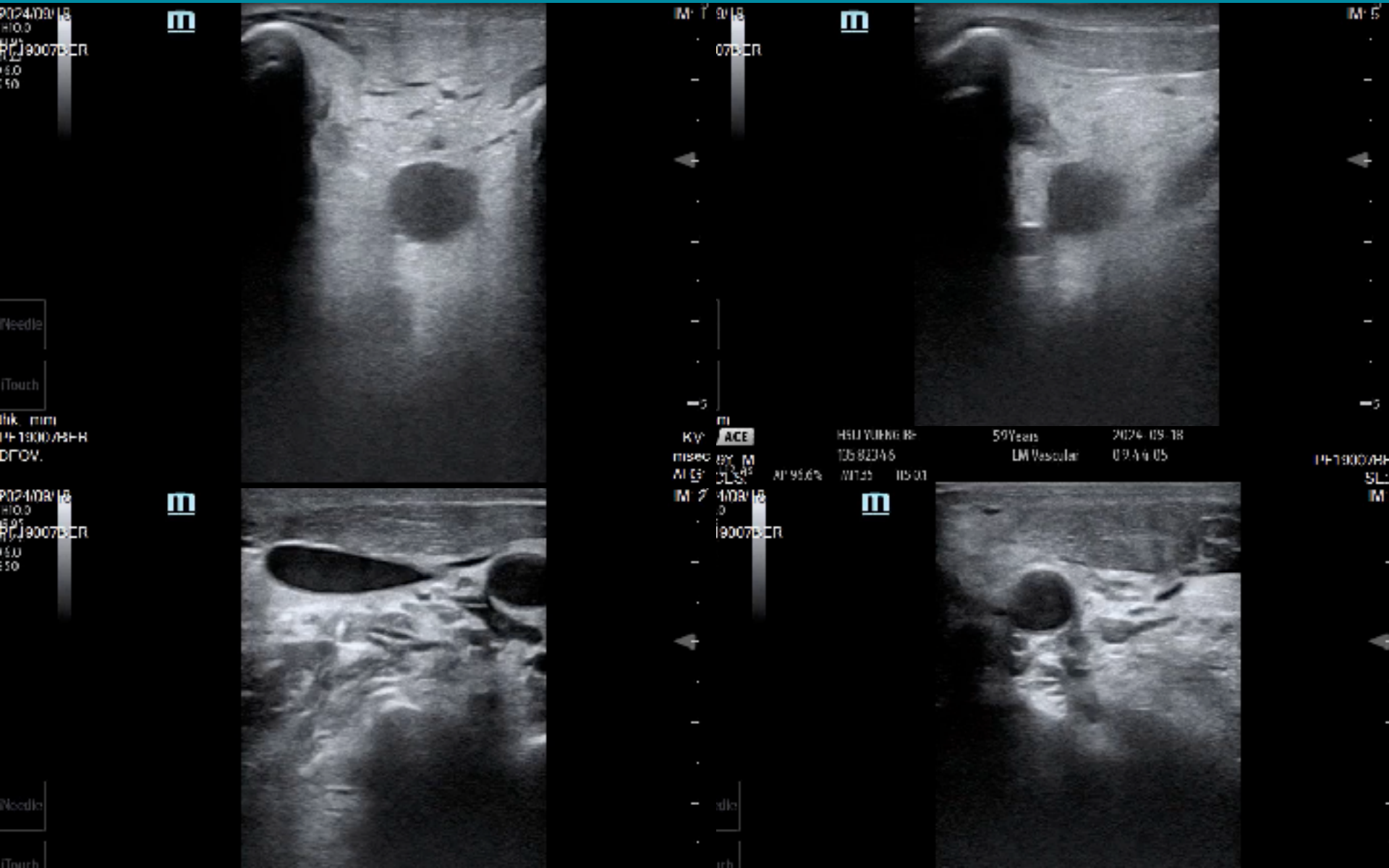


KV:
msec
ALG:

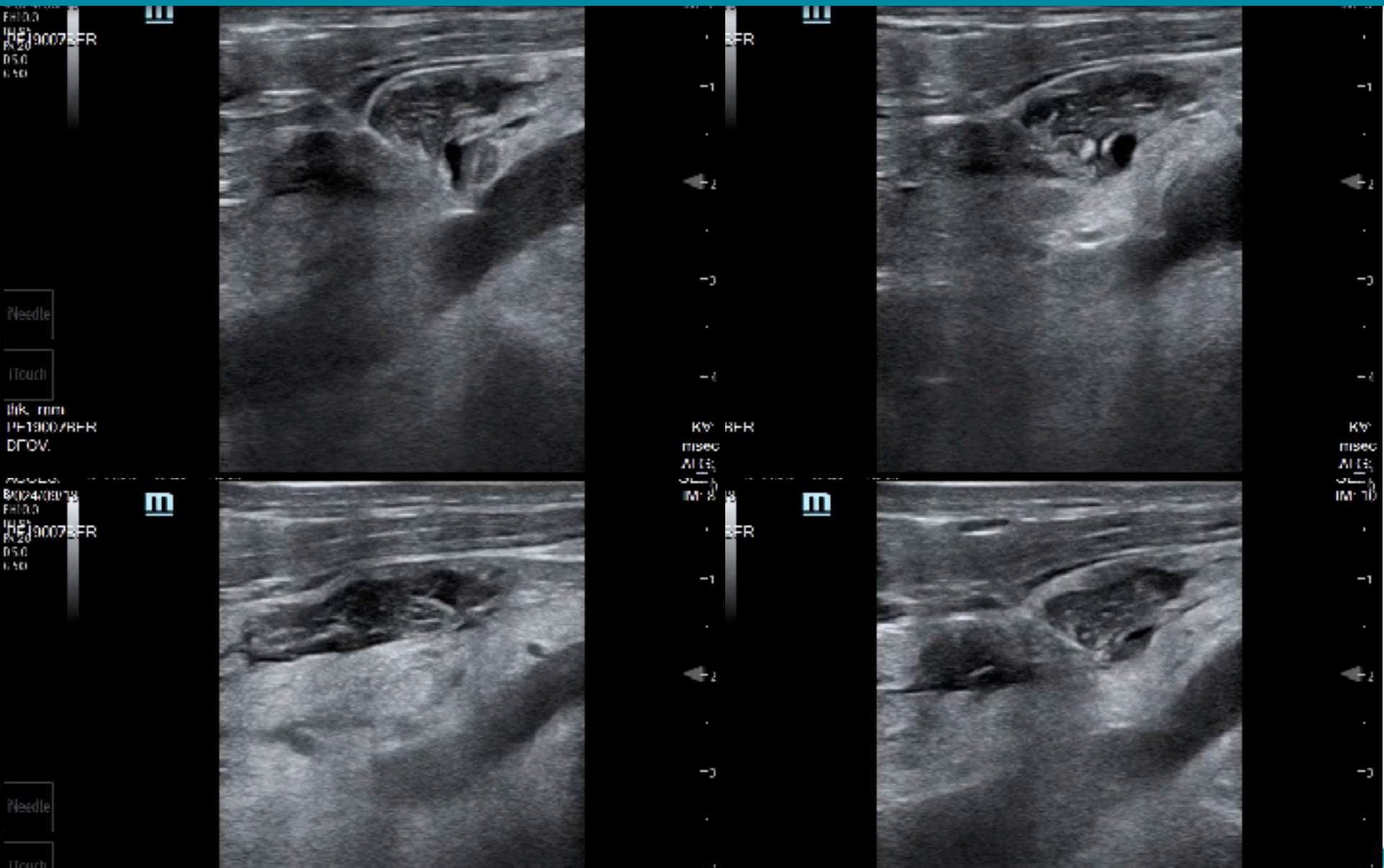
59M, Shock / AMS



59M, Shock / AMS, for CVC (R2 Huang)

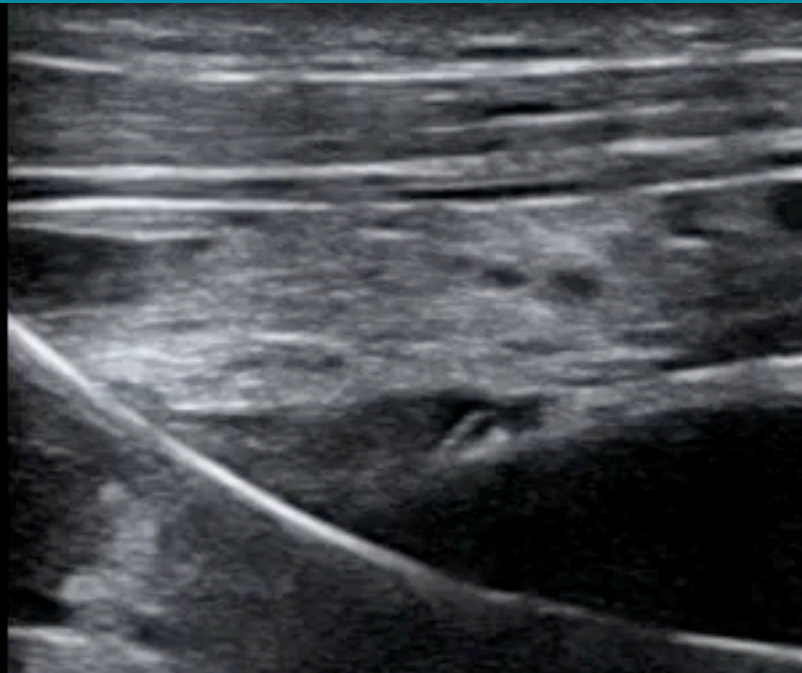

59M, Shock / AMS, for CVC (R2 Huang)

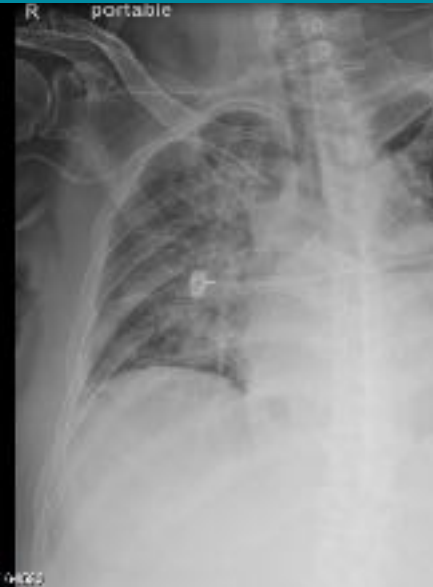

Guidewire confirmation

2024/09/18
FH10.0
DR 95
PF19007BER
FR 20
D 5.0
G 50



0501 M
PC:
ACC
STAT 178
13 34:08



KV: 51.88000
mAs: 3.6791 0.00000

iNeedle

iTouch

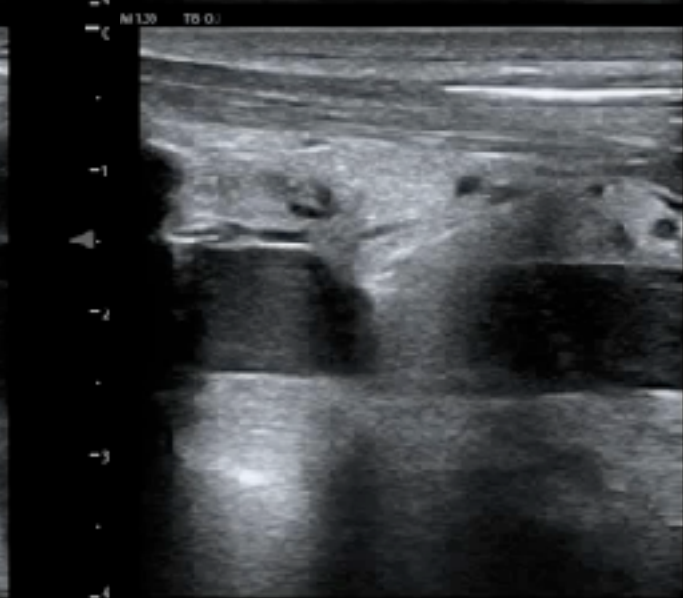
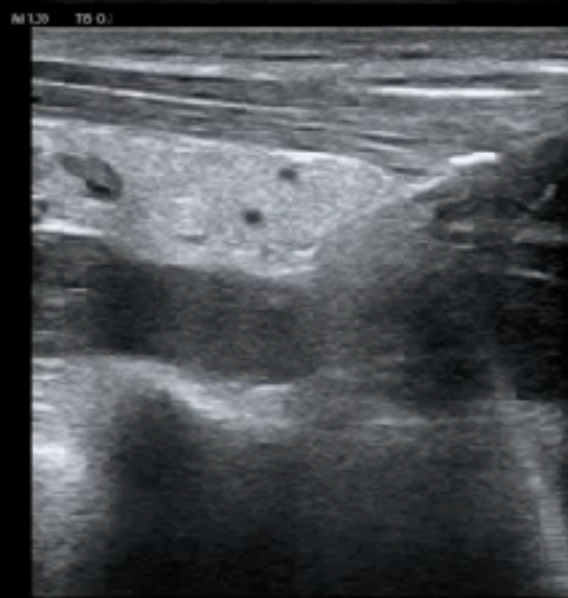
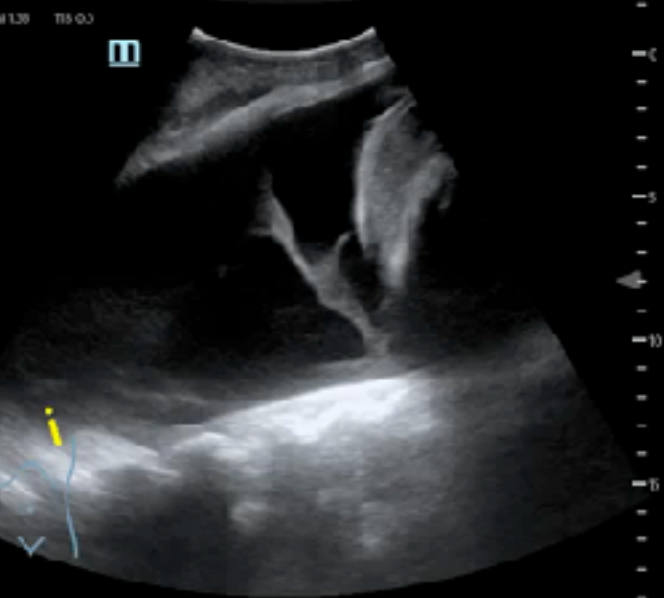
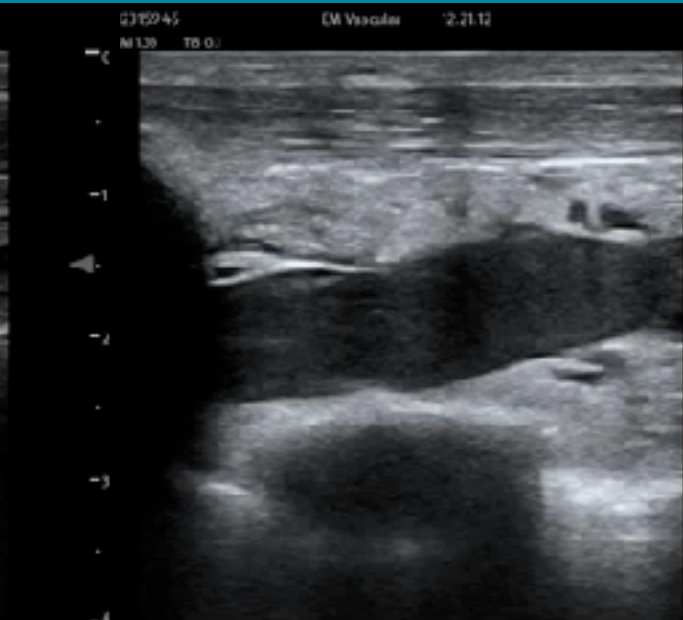
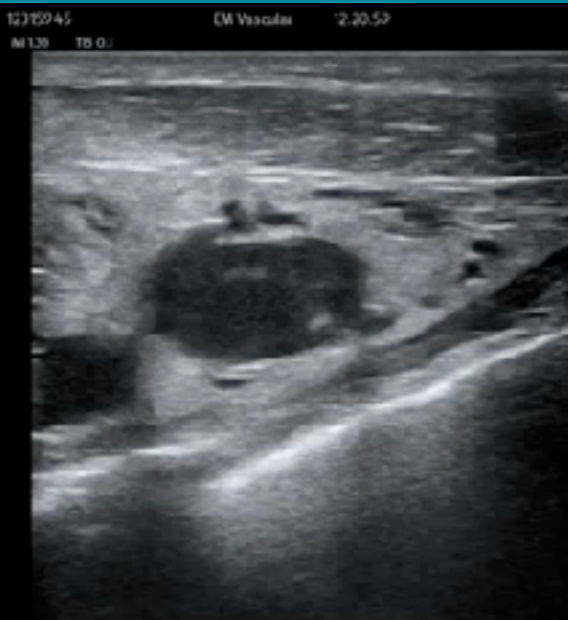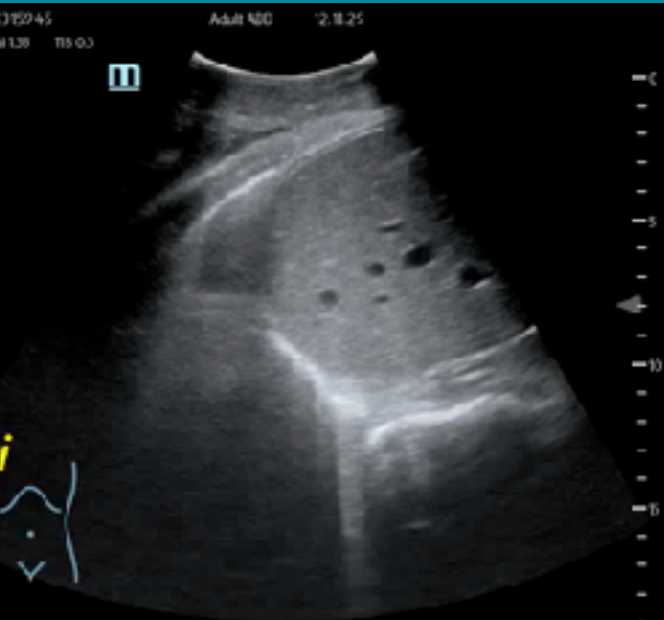
thk: mm
PF19007BER
DFOV:

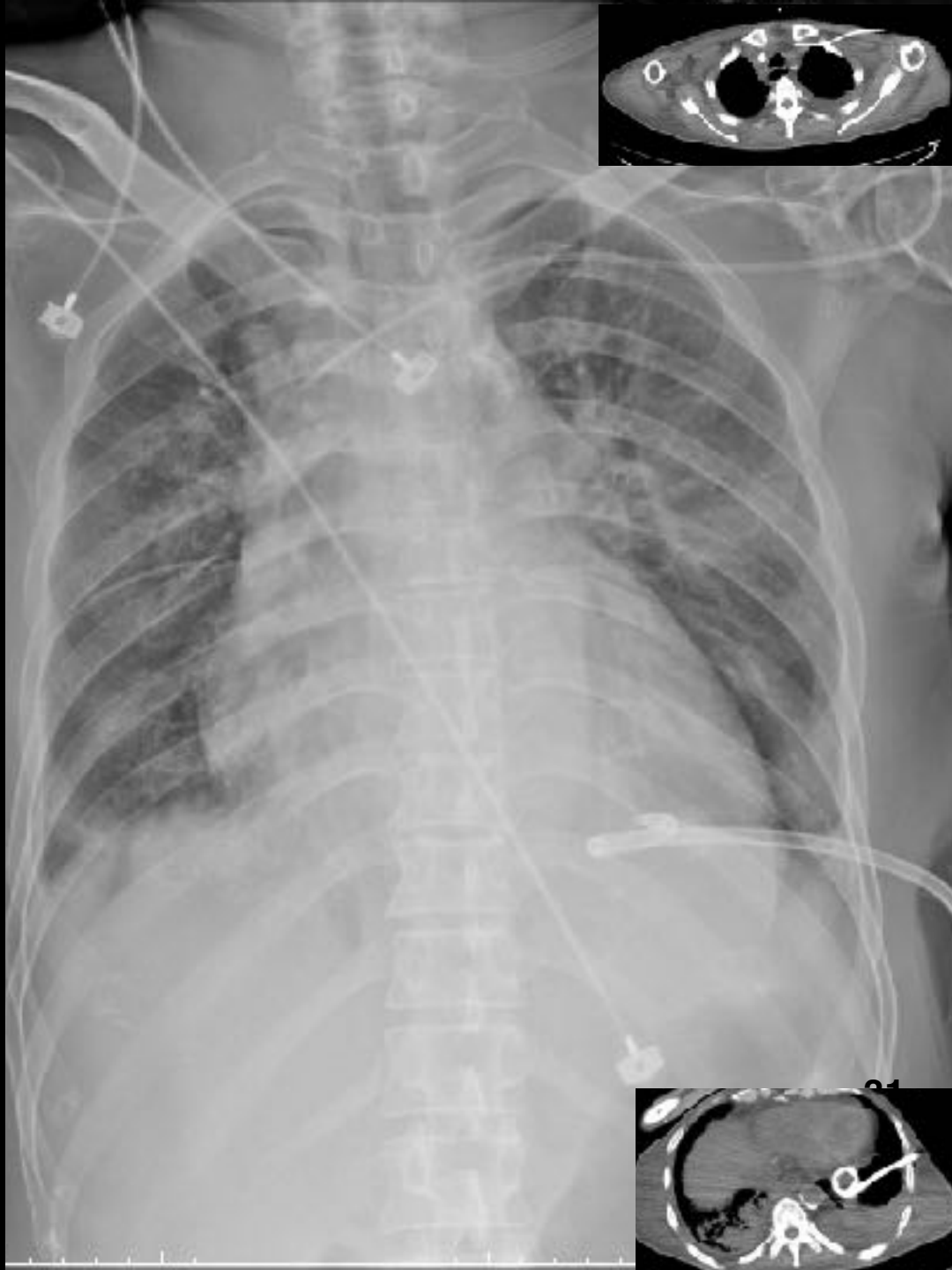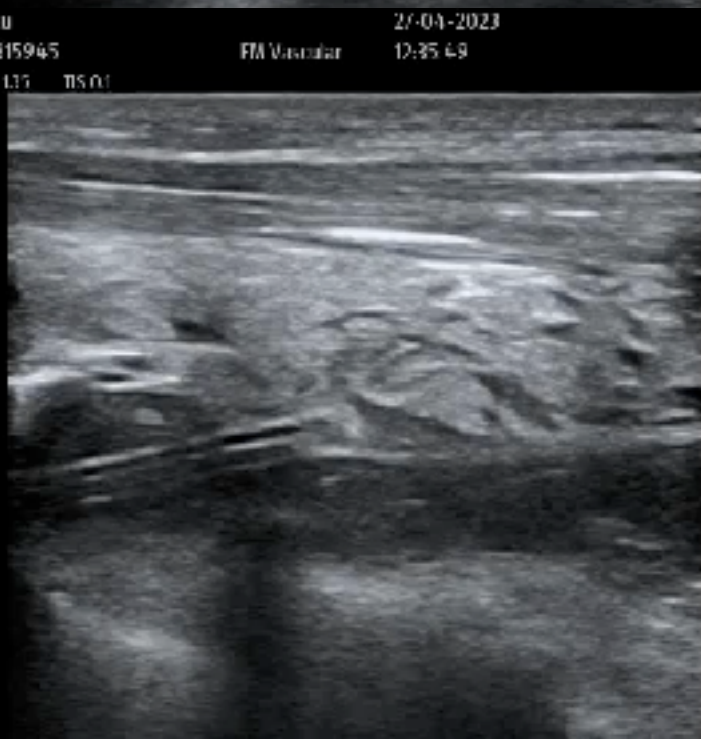
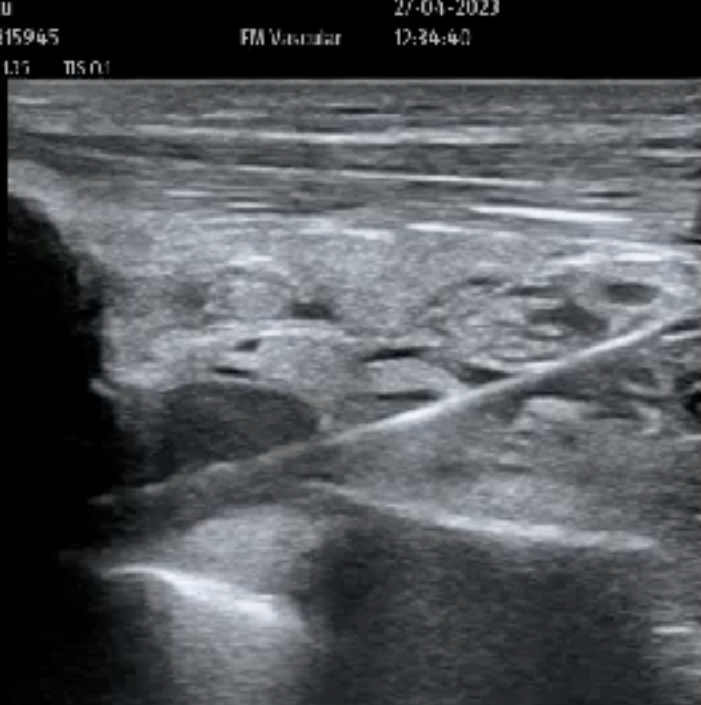-3

-4

KV:
msec

64M, 安中轉入，Shock & AMS





PIV: Basilic & Cephalic V



Landmark: humerus & brachial aretery

D-20170705165331

MI 1.1 7/5/2017

55331

SKH ER

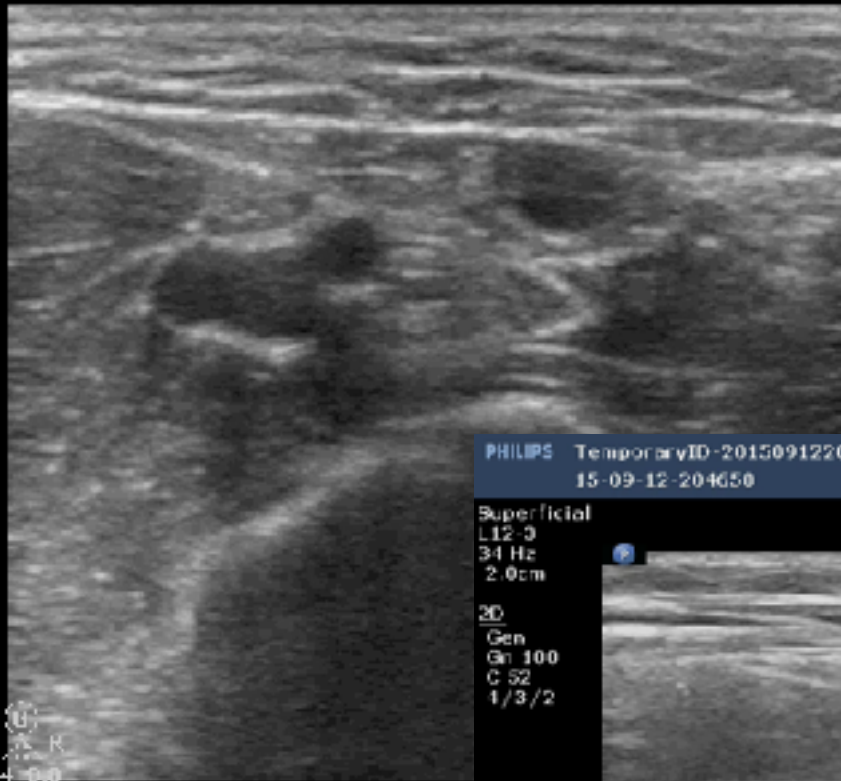
TIS 0.1 5:29:12 PM

Garden Hospital

MSK 3

3085

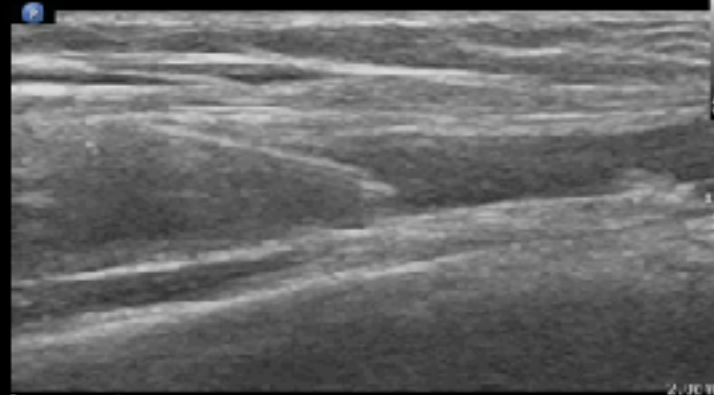
Precision

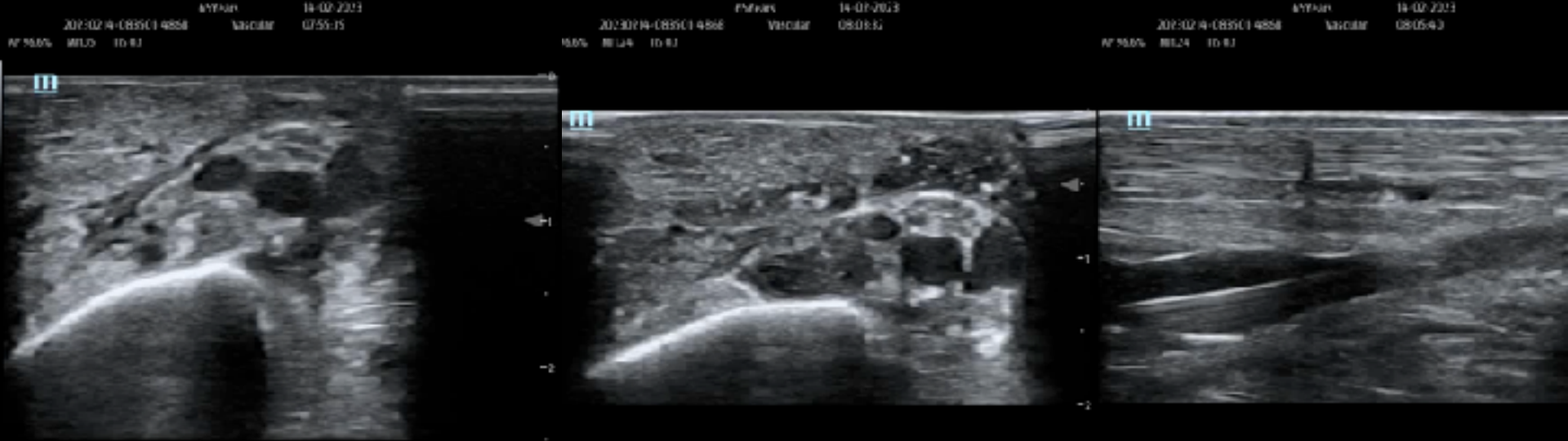

PHILIPS TemporaryID-20150912204658
15-09-12-204650 SKH ER

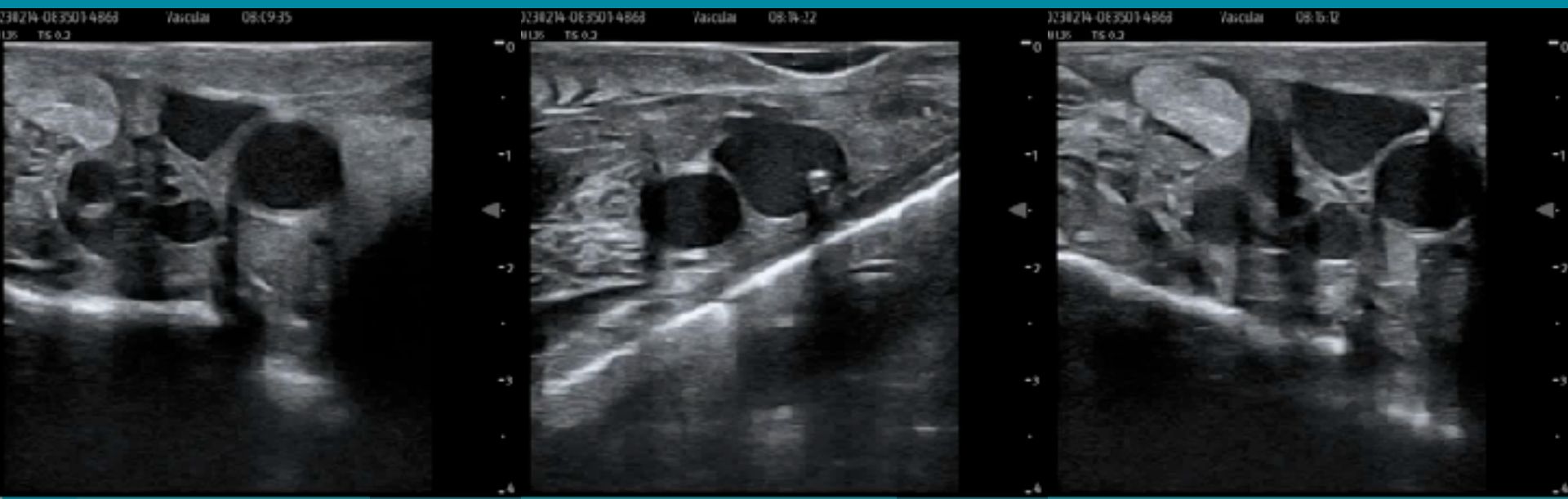
MI 0.7 9/12/2015
TIS 0.1 0:47:05 PM

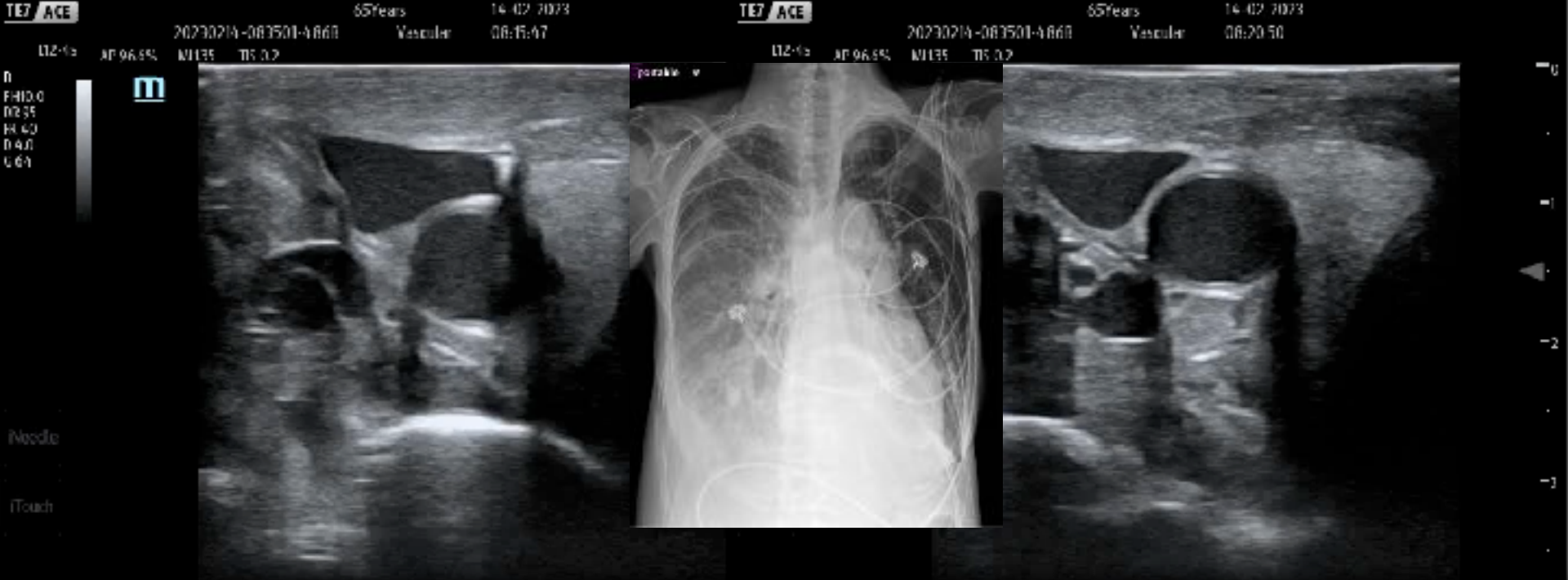Superficial
L12-0
34 Hz
2.0cm
2D
Gen
Gn 100
C 52
1/3/2



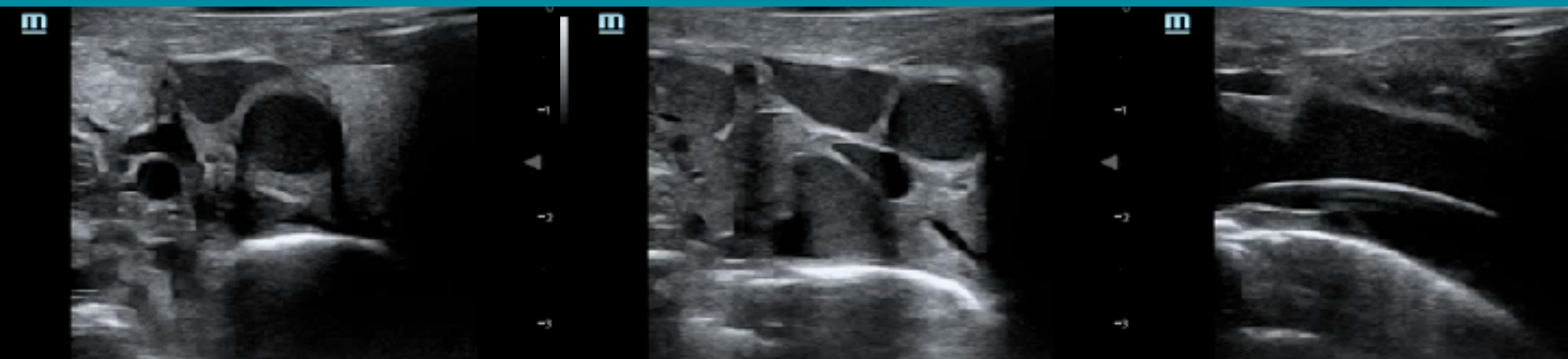


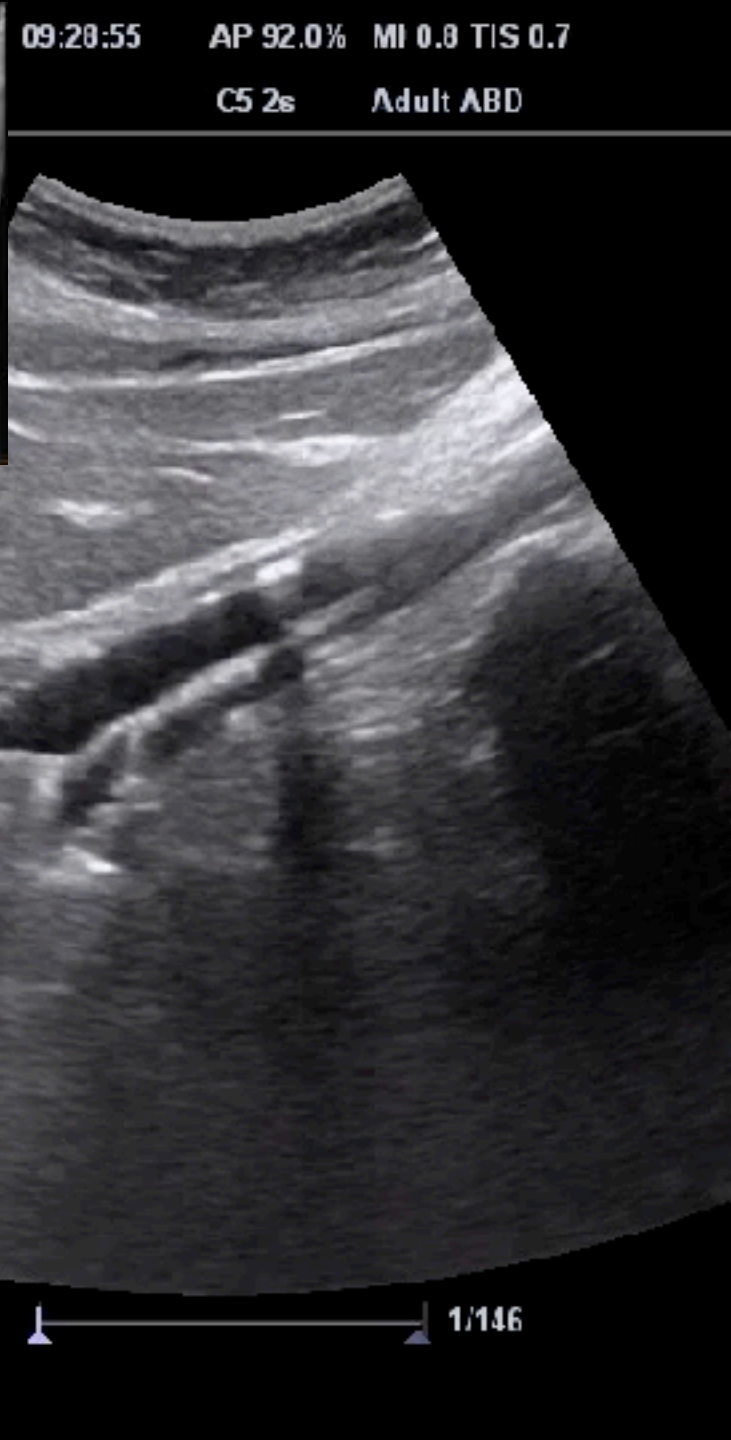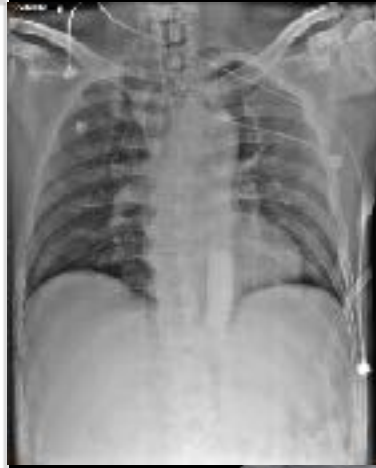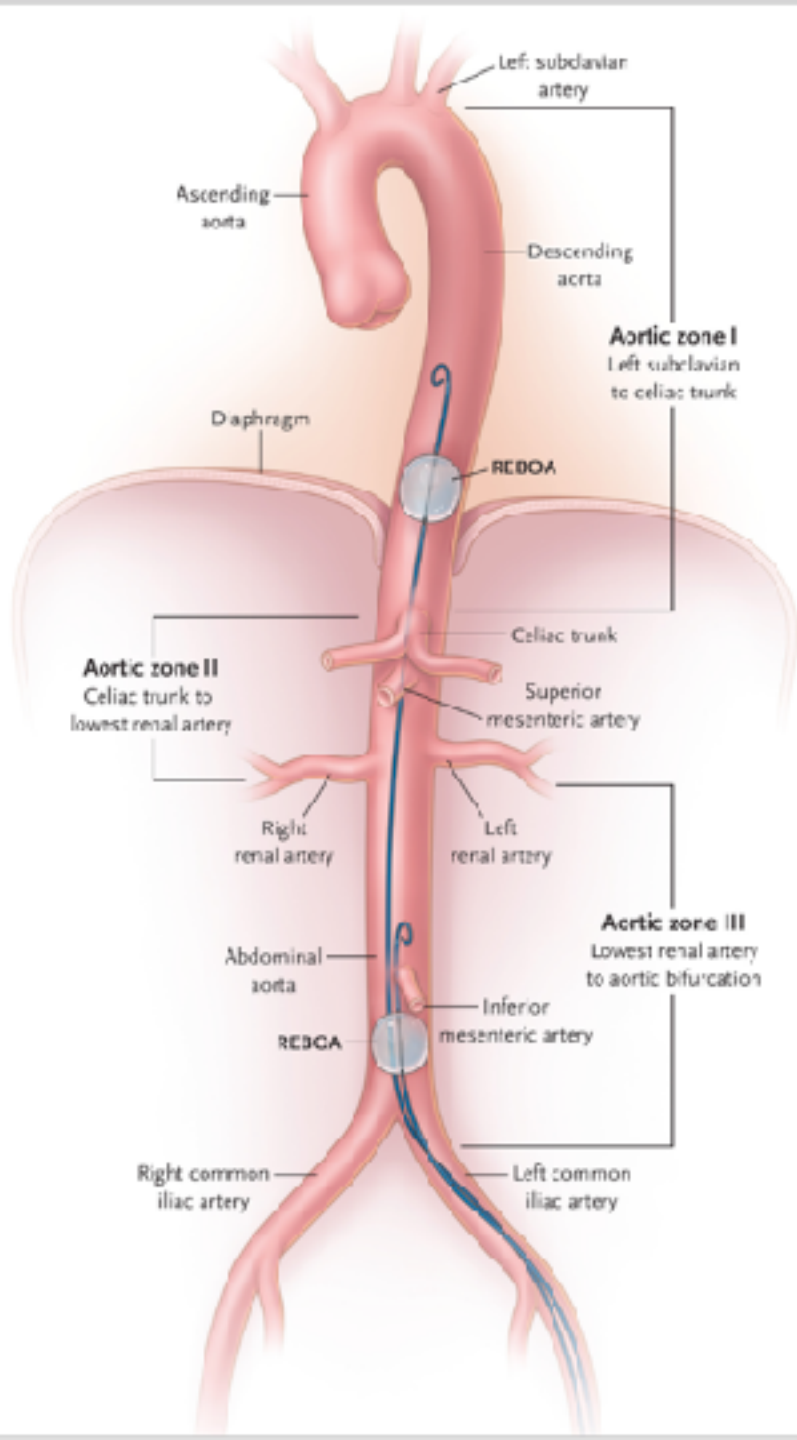
US-guided PICC





US-guided PICC



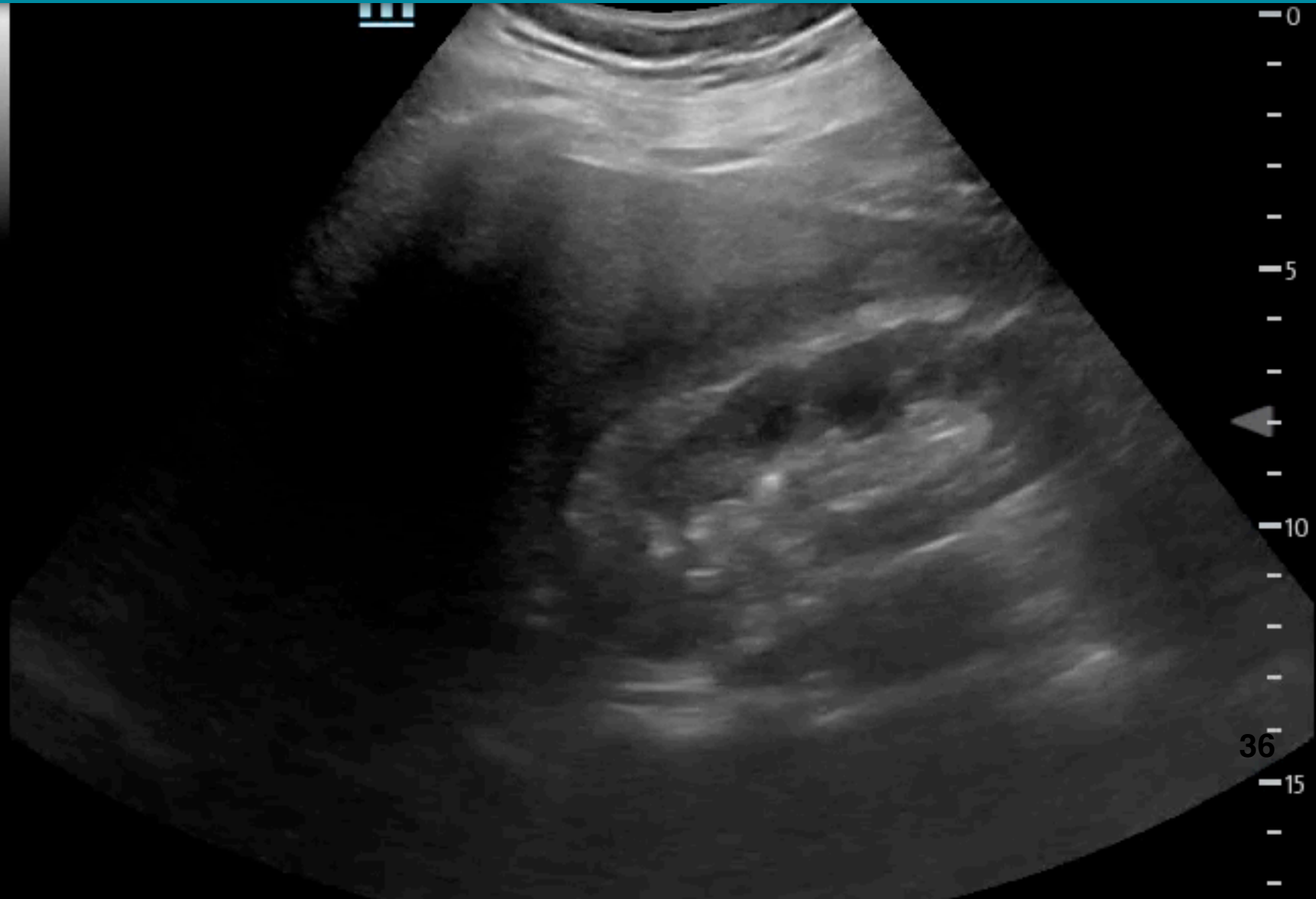

30M, MBA, ABD & Chest pain; 103/69

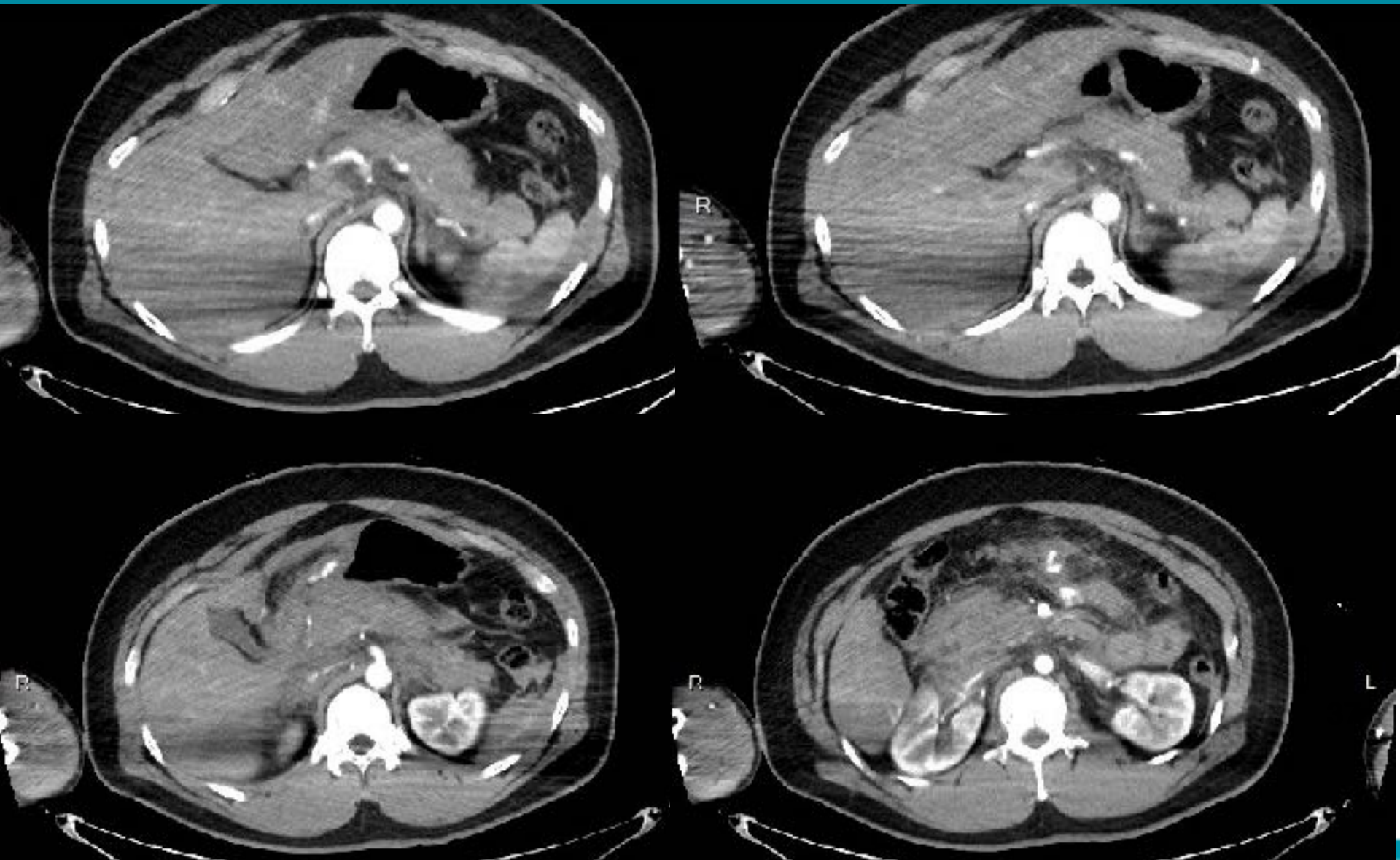
FH5.0
DR 130
FR 16
D 18.0
G 40

iNeedle

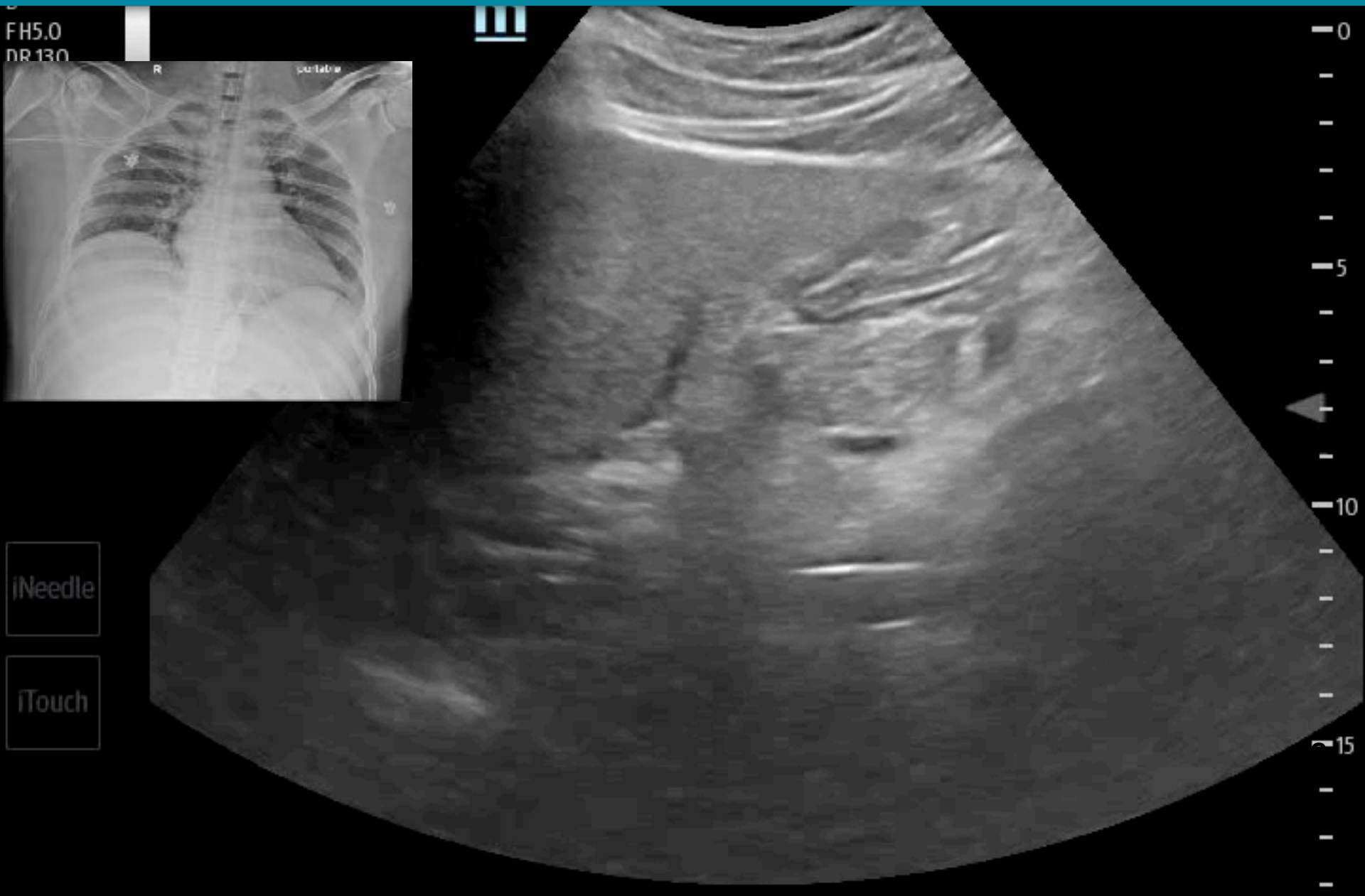
iTouch

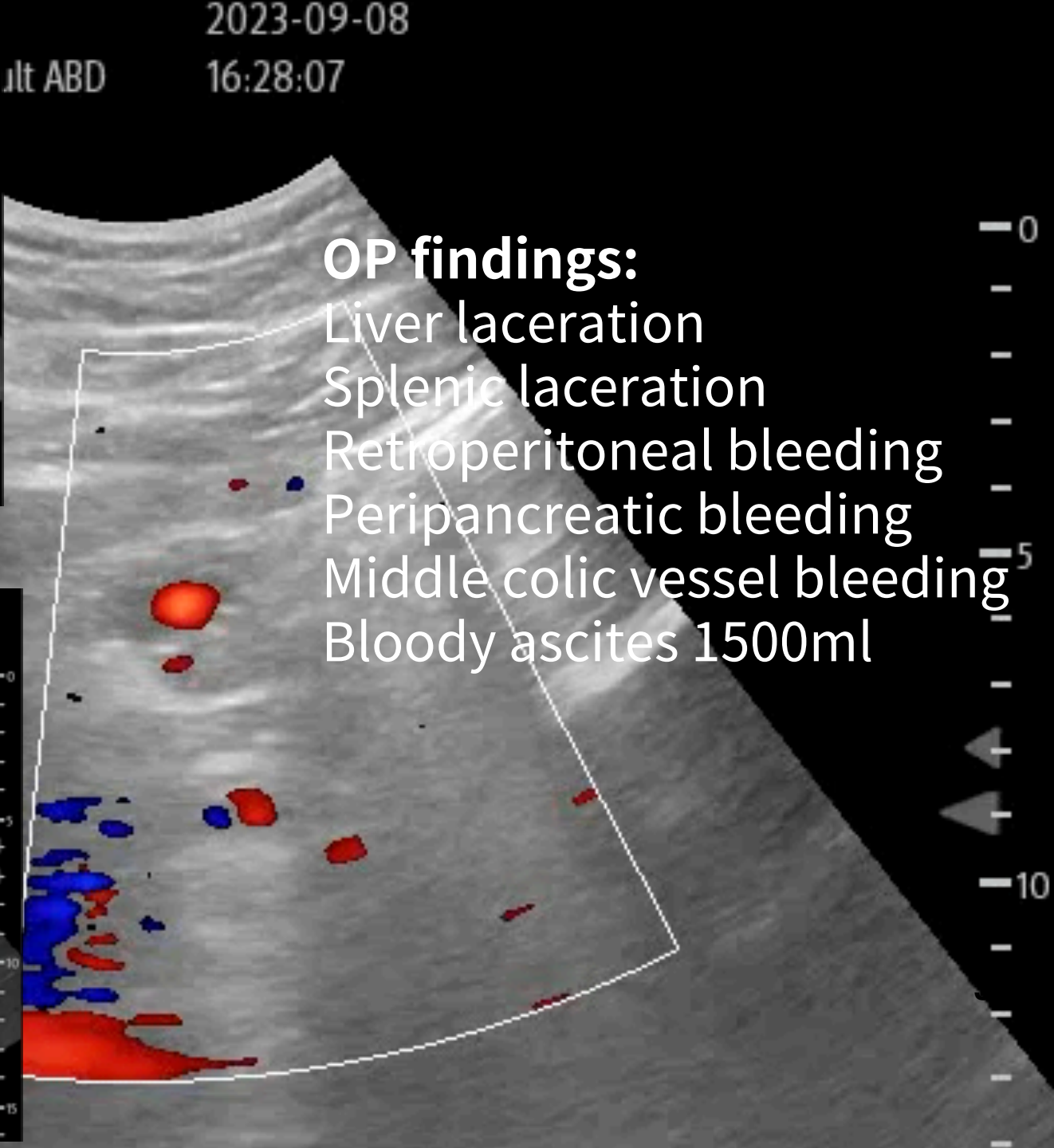
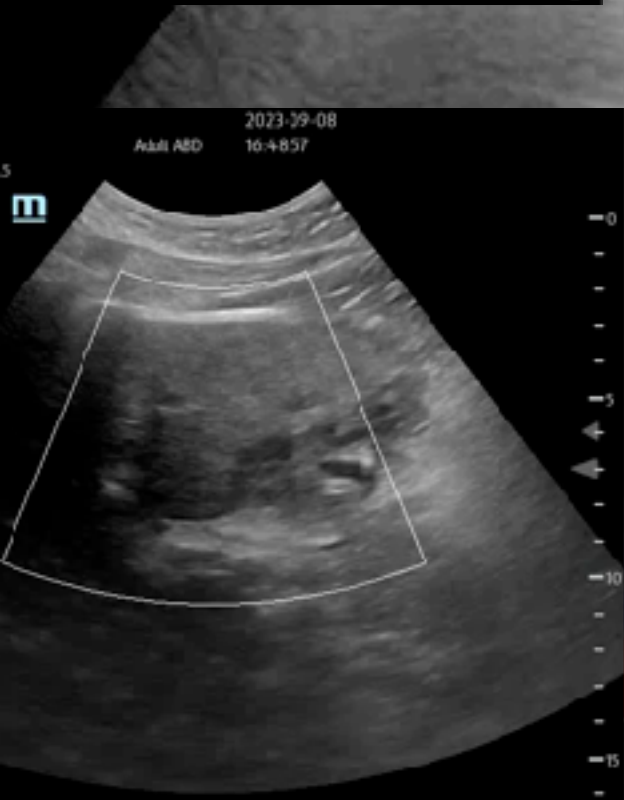
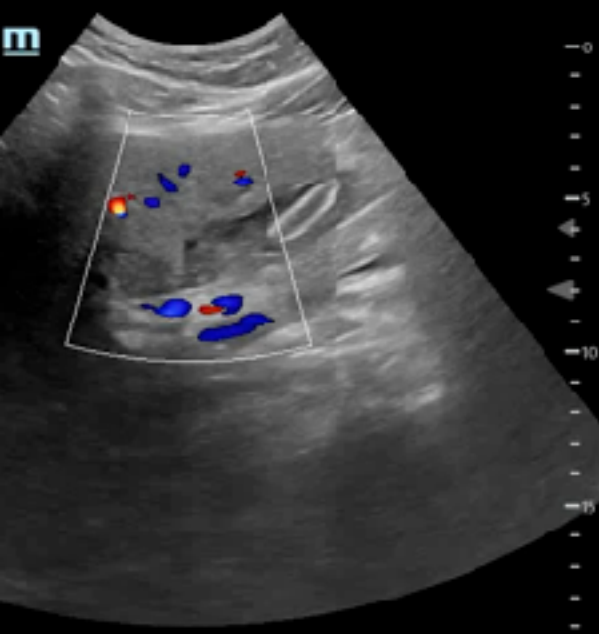


30M, MBA, ABD & Chest pain; 103/69



Profound hypotension after CT





OP findings:

Liver laceration

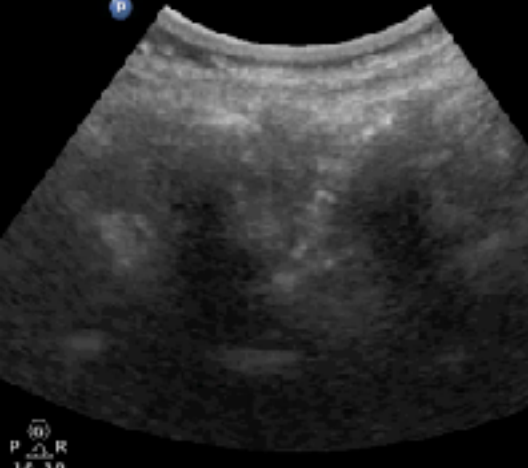Splenic laceration

Retroperitoneal bleeding

Peripancreatic bleeding

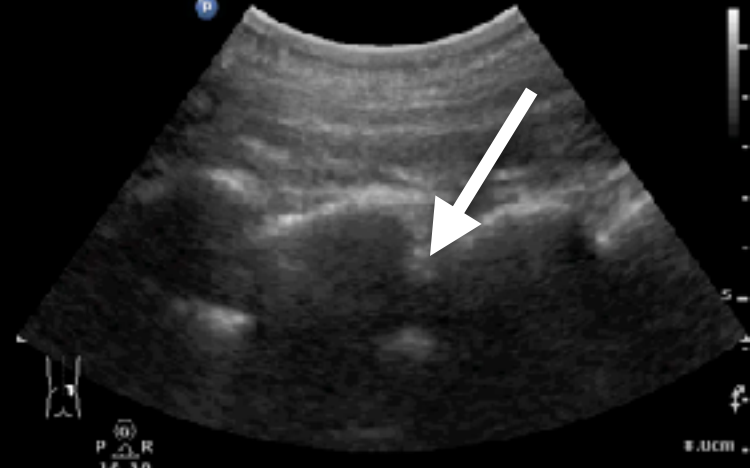Middle colic vessel bleeding

Bloody ascites 1500ml

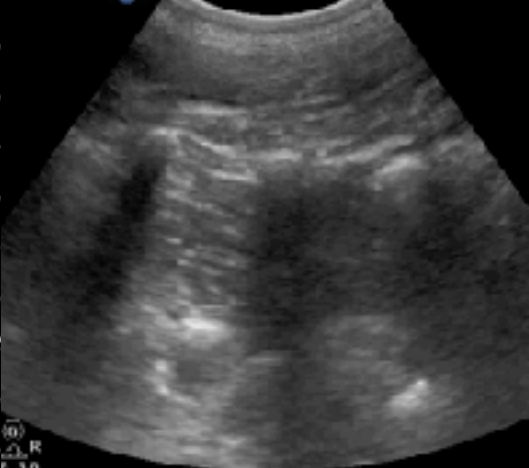

C5-1
51 Hz
0.0cm
HGen
16h 47
C 56
3/3/3

Spinal process

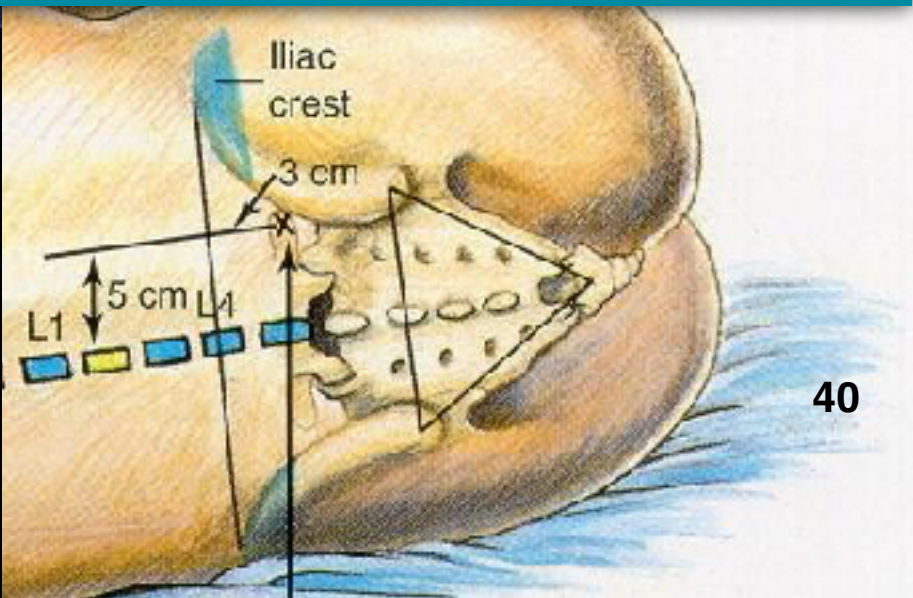
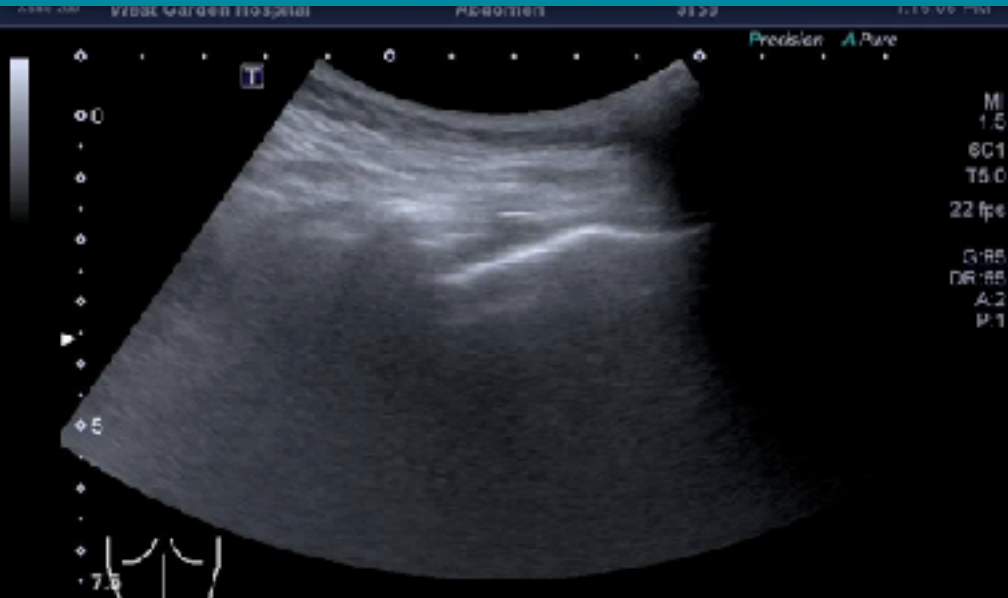

Lamina



Transverse process

Lumbar puncture

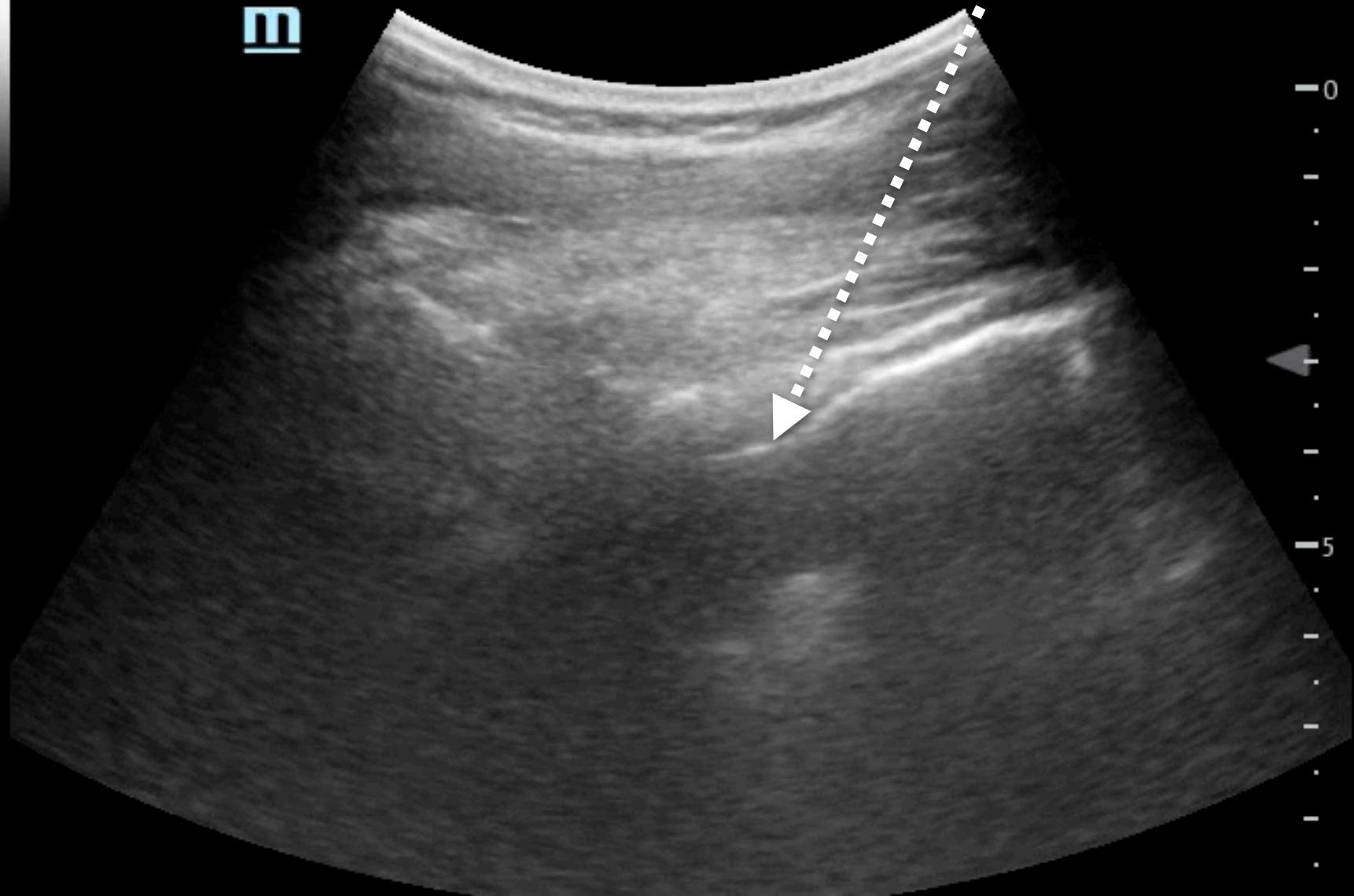


71M, Suspect CNS infection

Failed CSF attempts

B
FH5.0
DR 115
FR 23
D 9.0
G78

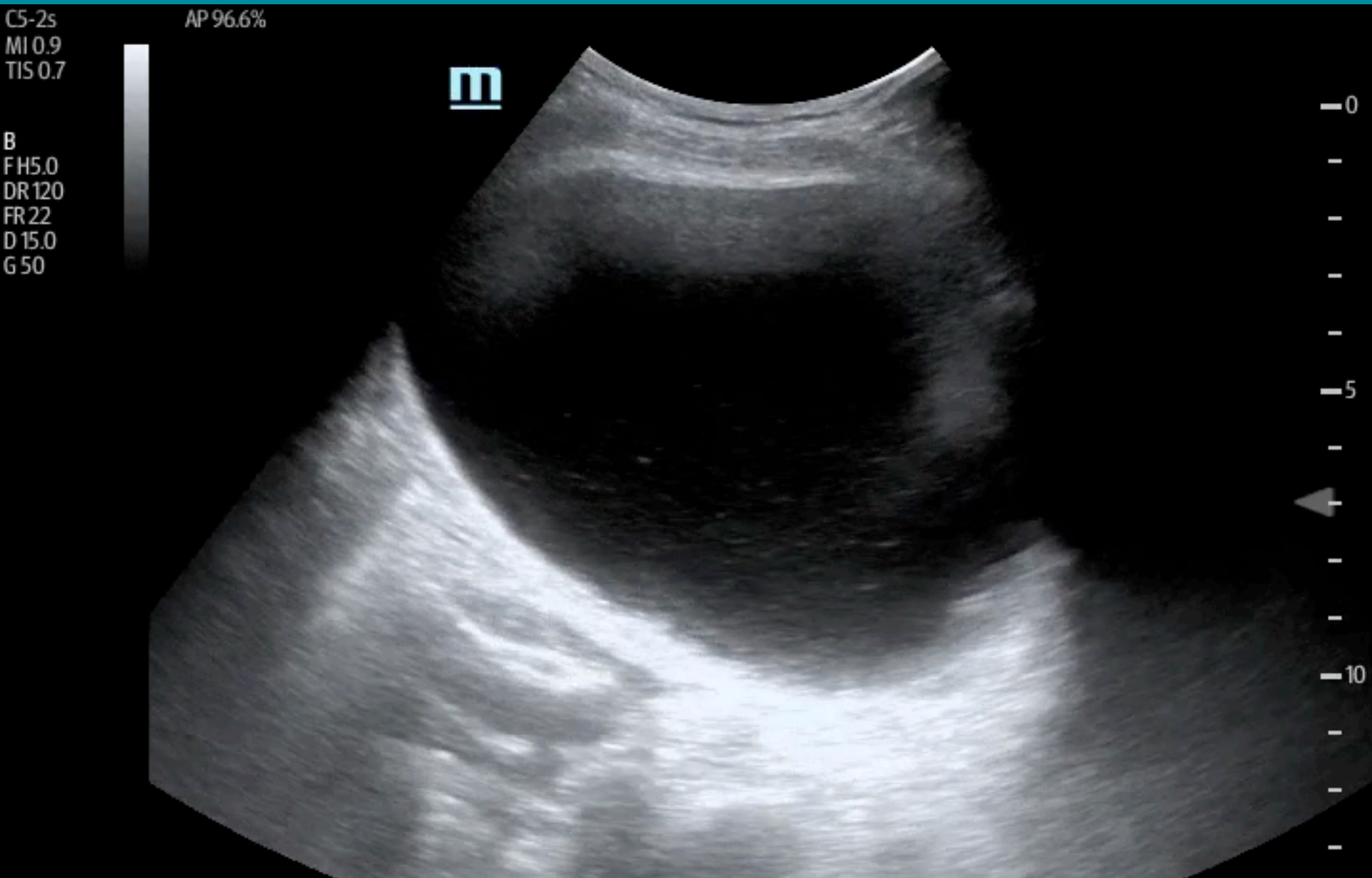
m



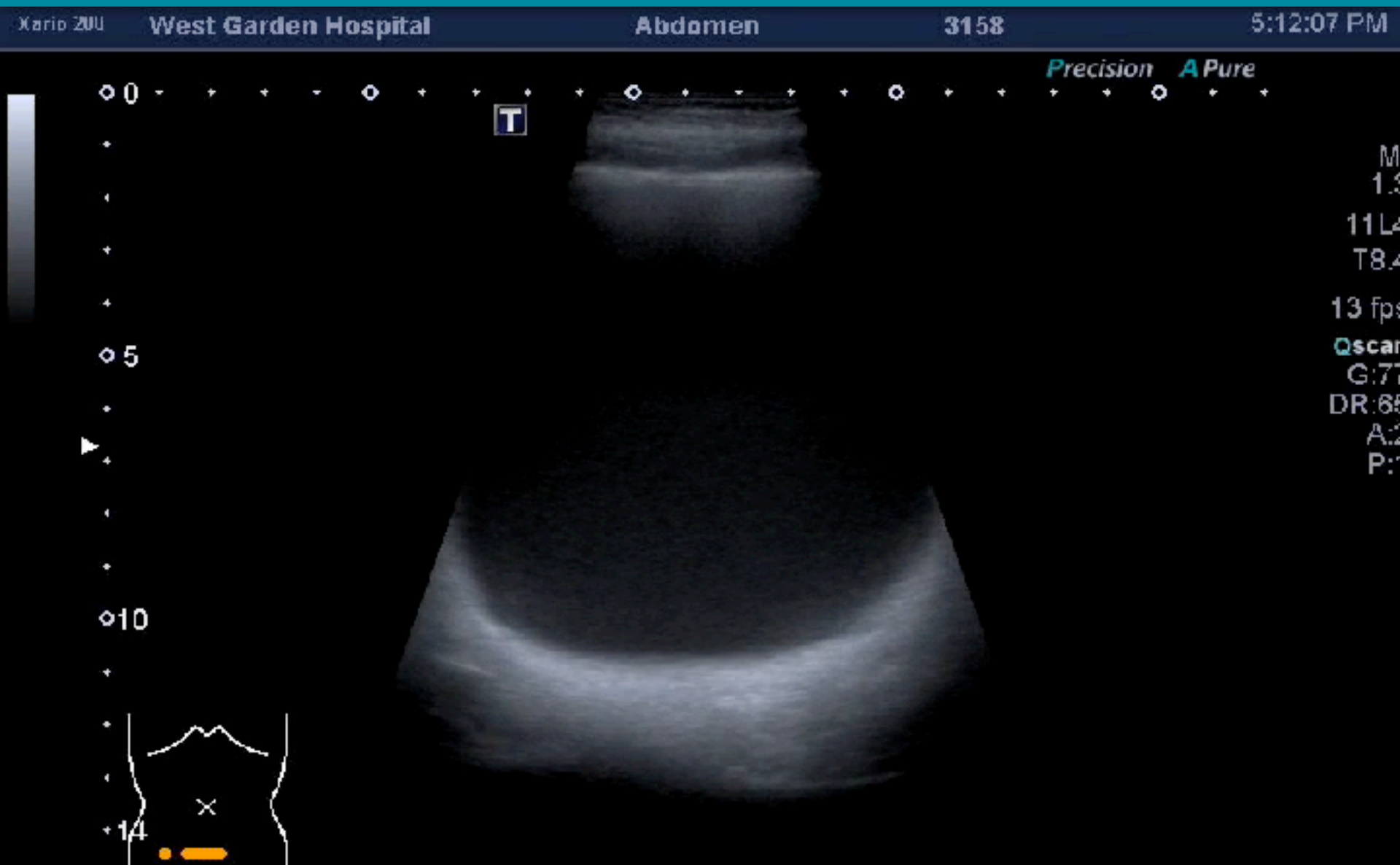
iNeedle

iTouch

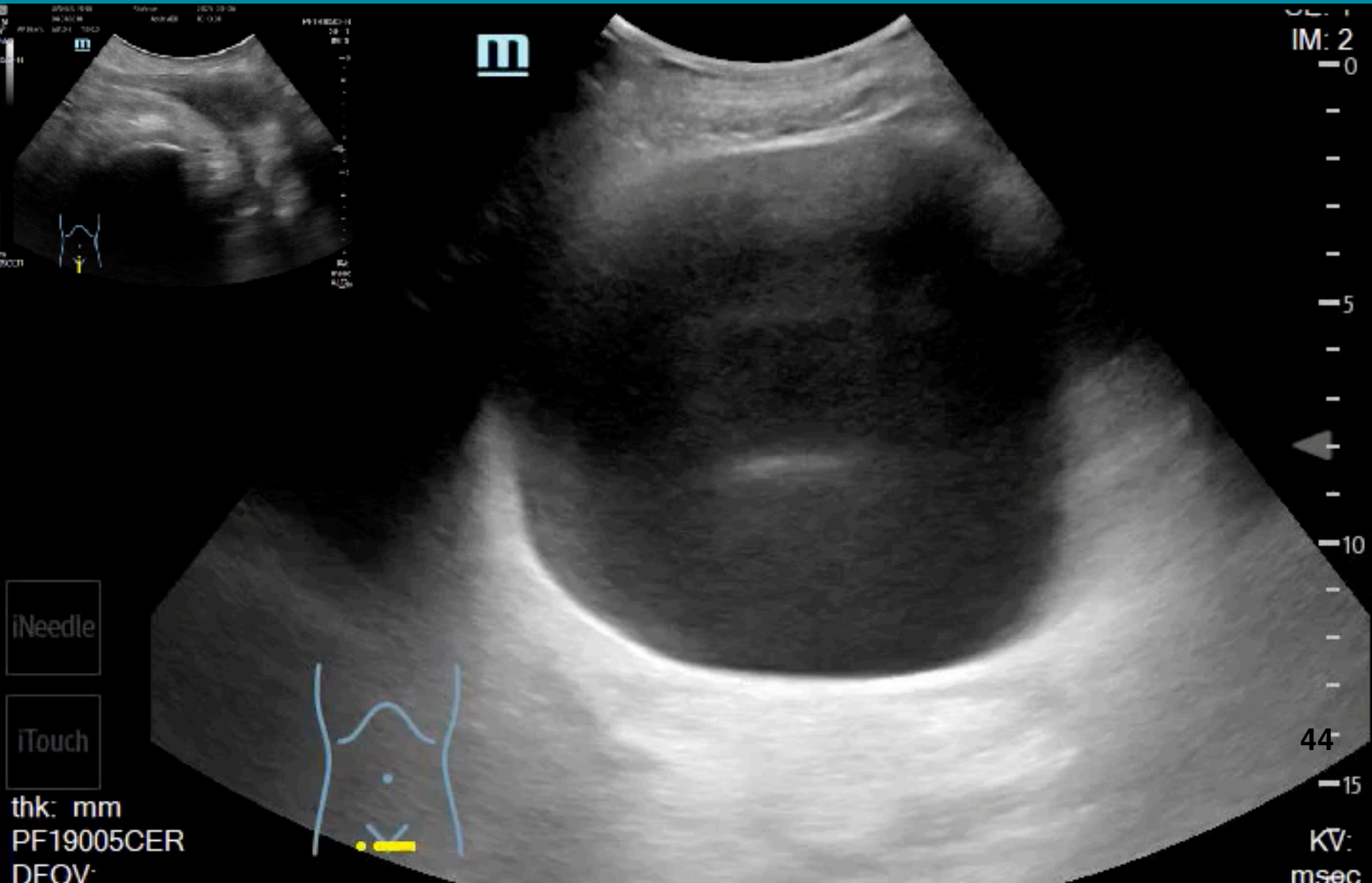
66M, AUR due to urethral stone obstruction



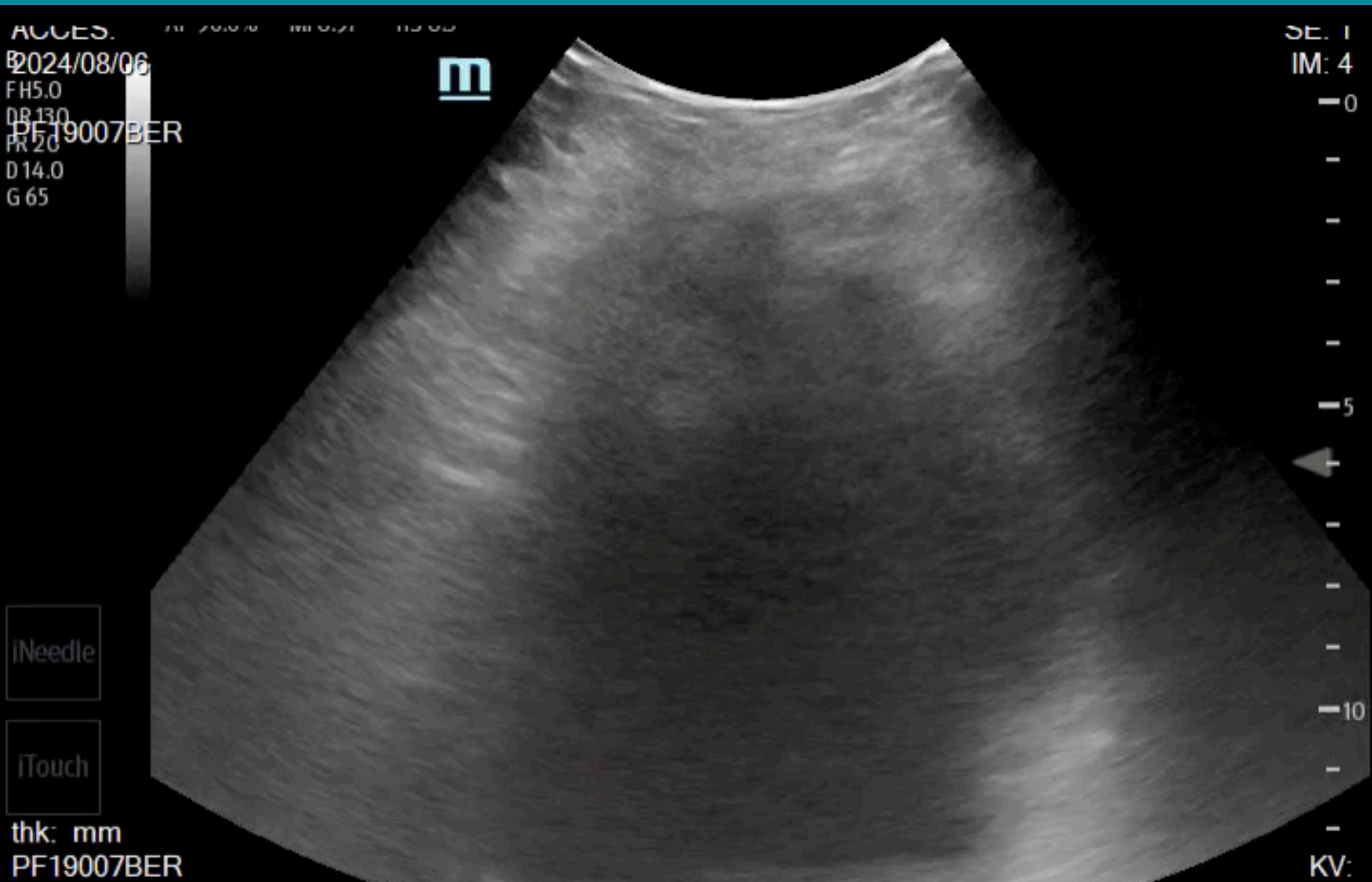
76M, AUR & urethral stricture



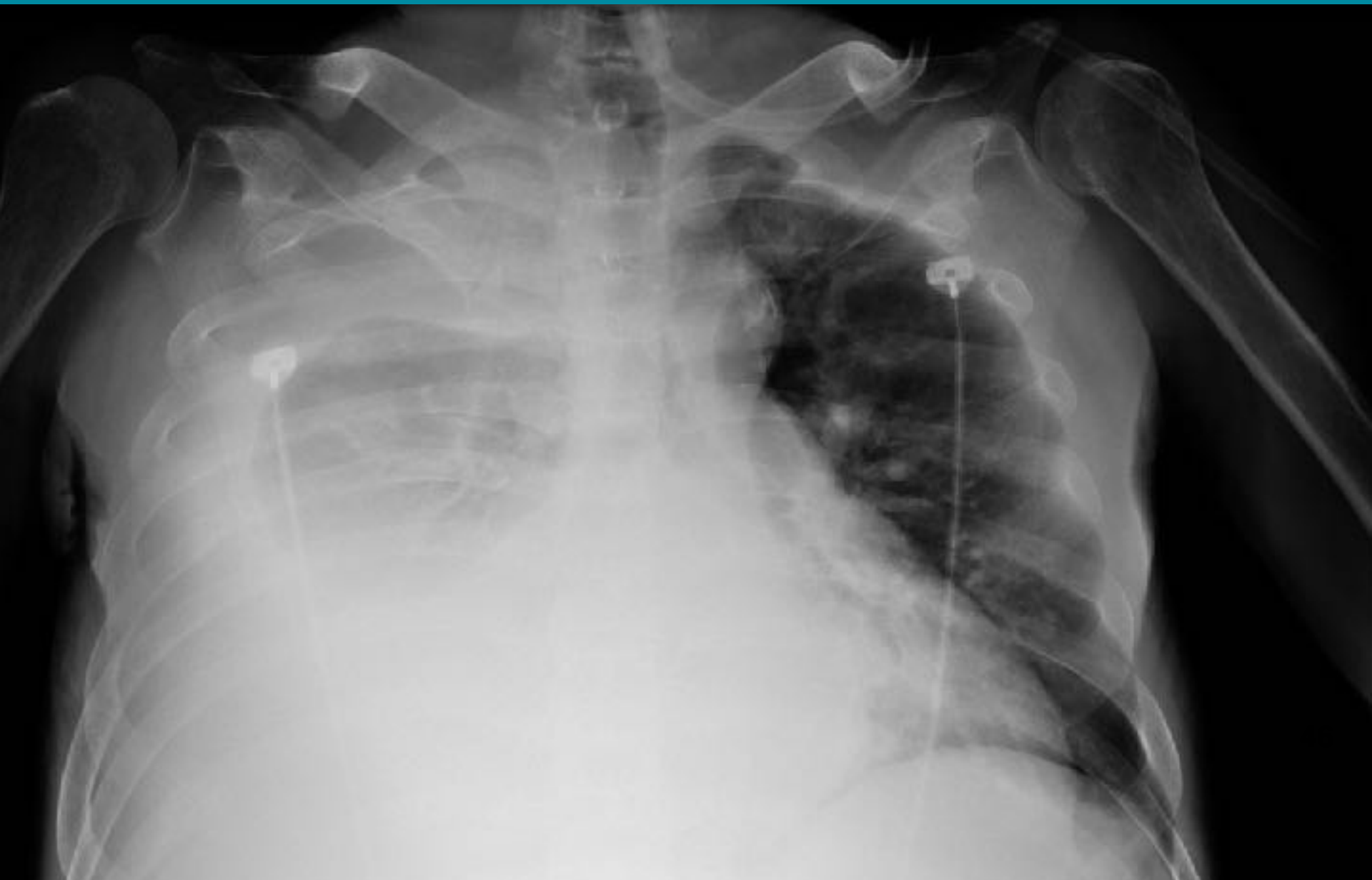56M, SZ, fever & unable to void , 尿管卡住



Suprapubic drainage (8Fr pigtail)



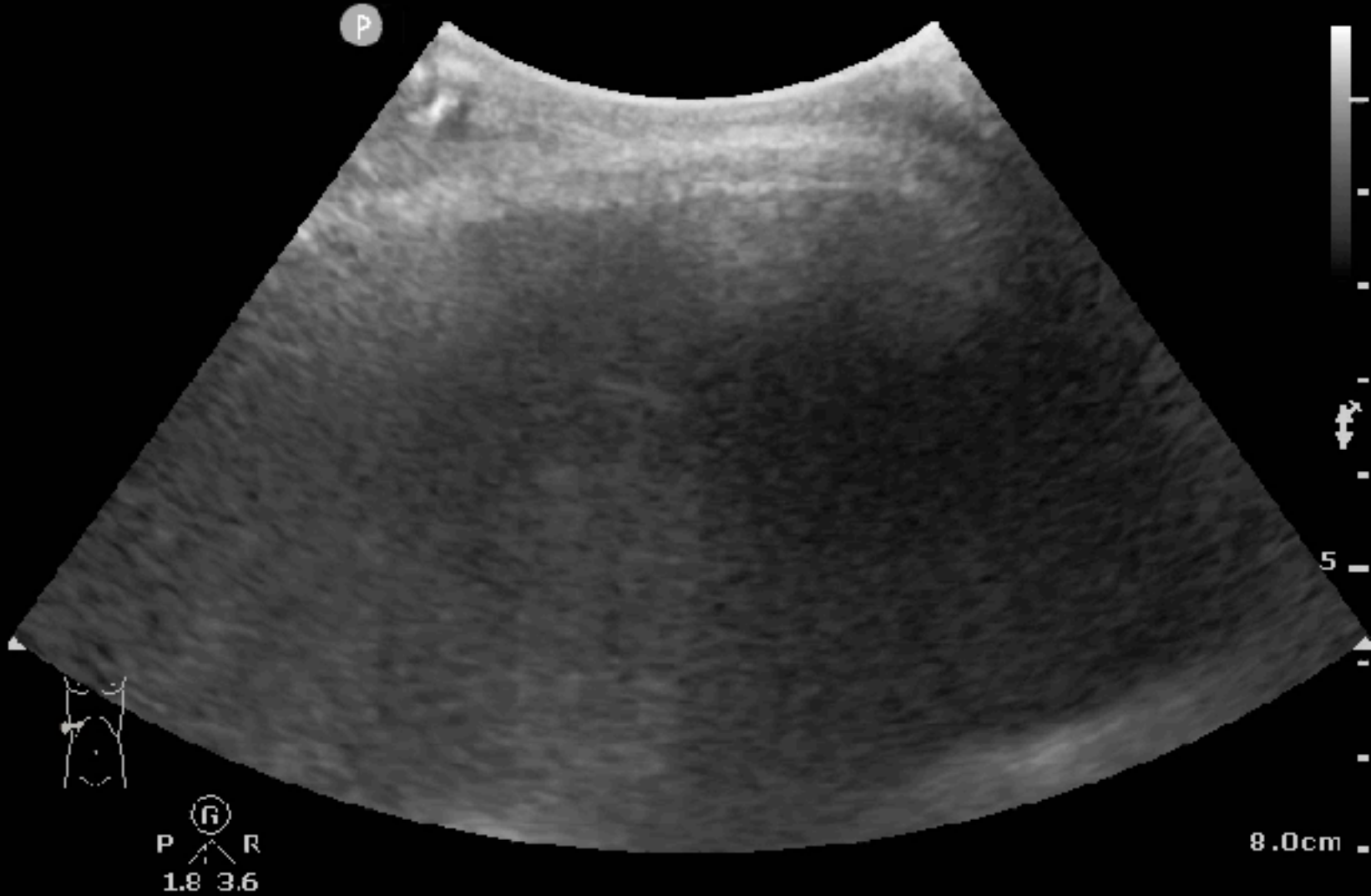53M, Massive PLE



Real-time LA prior to pigtail

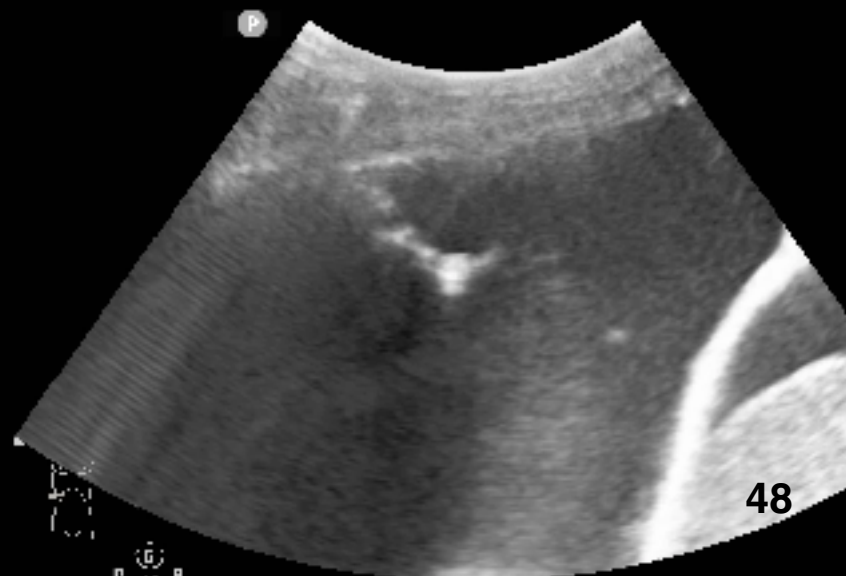
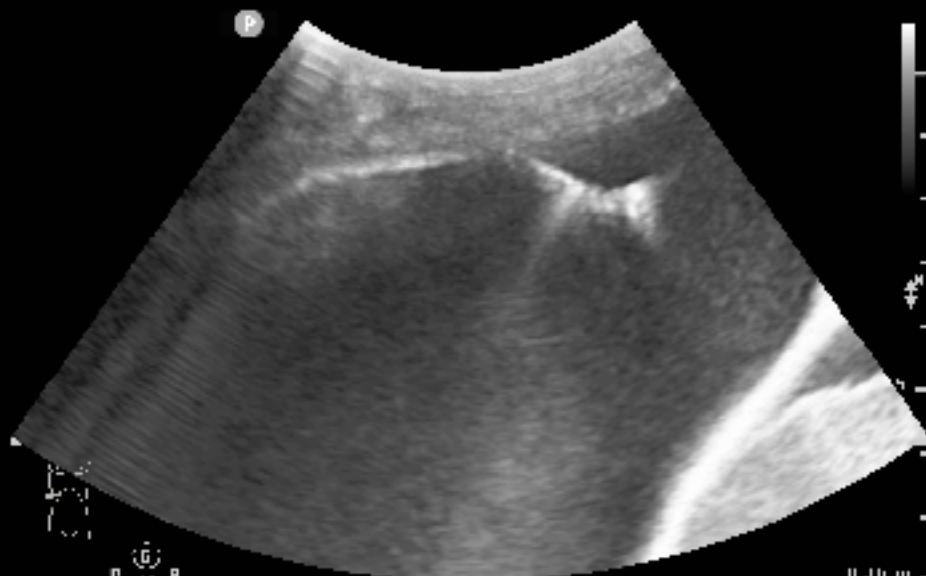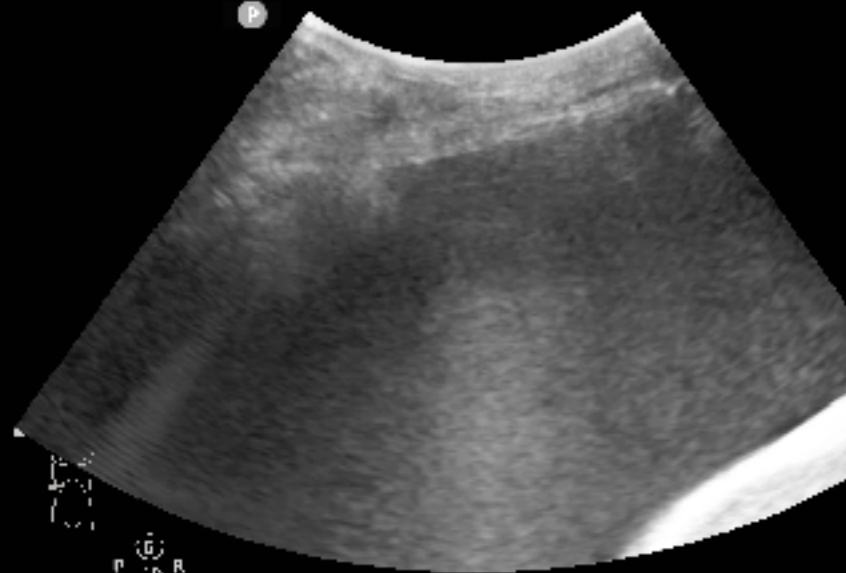
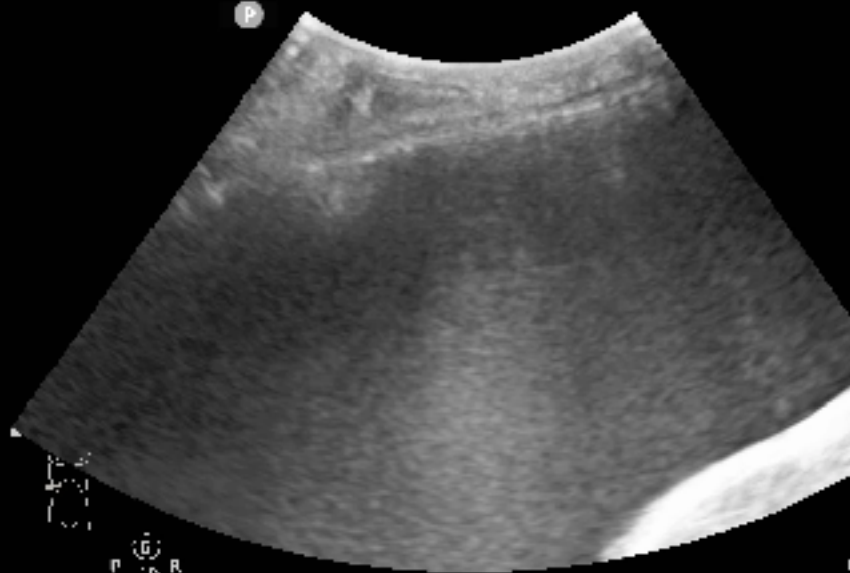
Abd Gen
C5-1
51 Hz
8.0cm

2D
HGen
Gn 100
C. 56
3/3/3



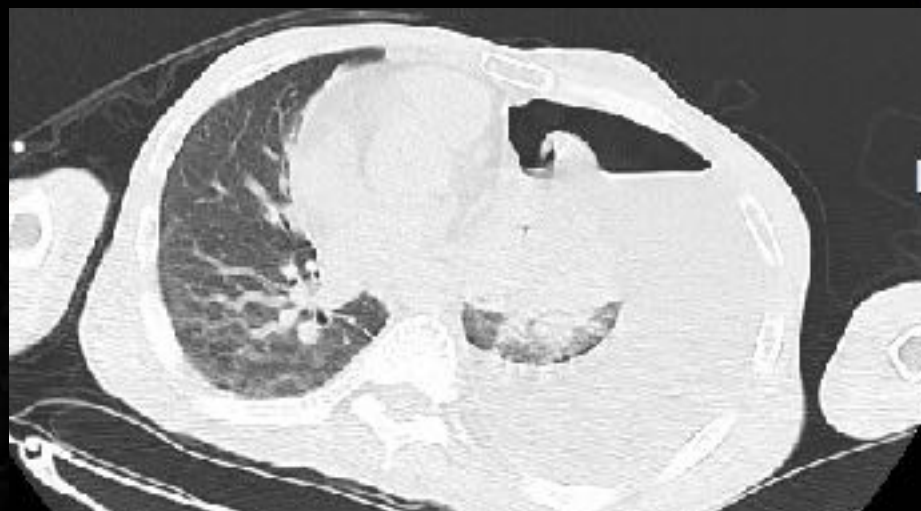
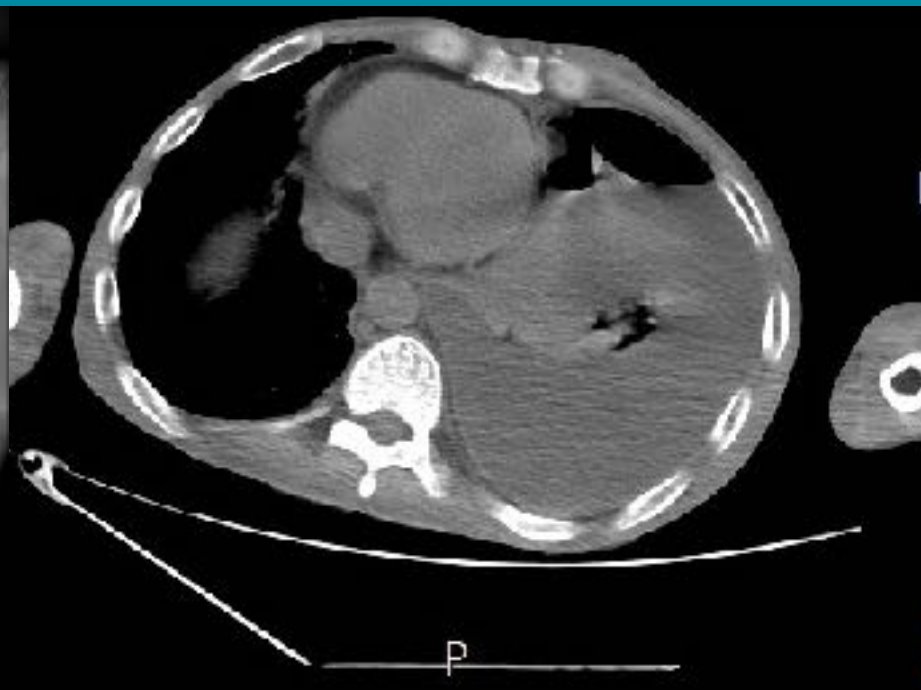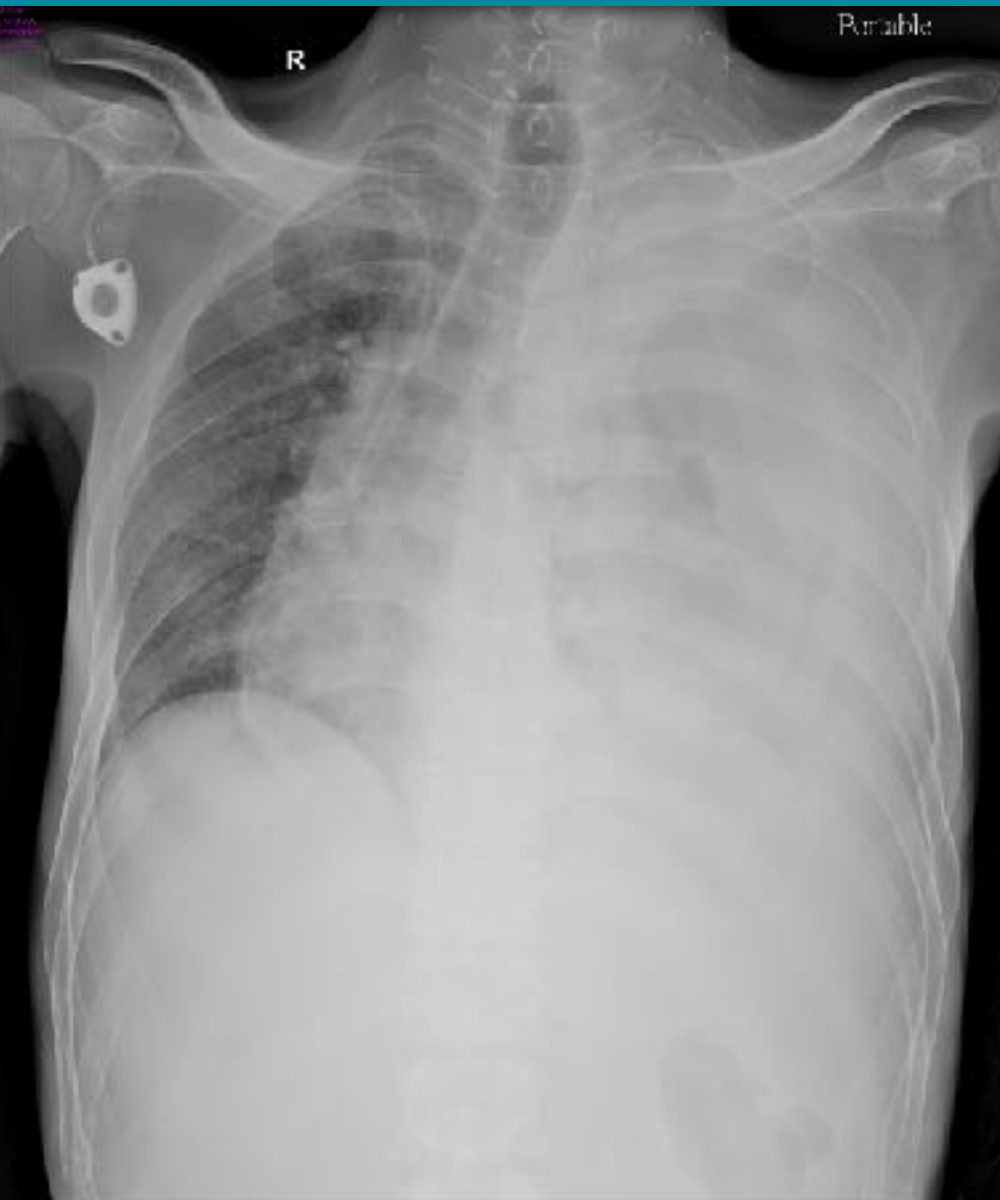Abd Gen
C5-1
51 Hz
0.0cm

2D
HGen
Gn 100
C 56
3/3/3

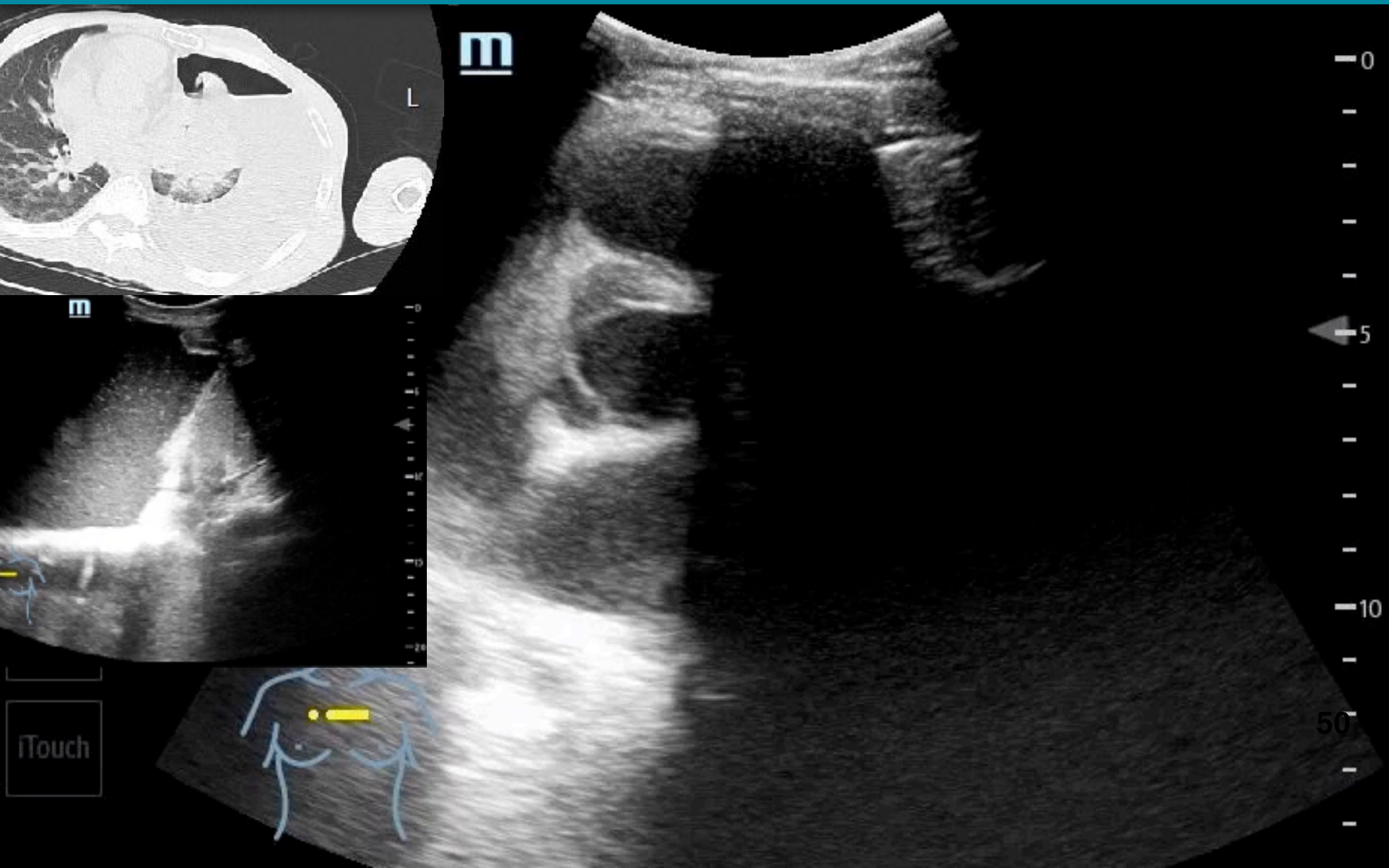


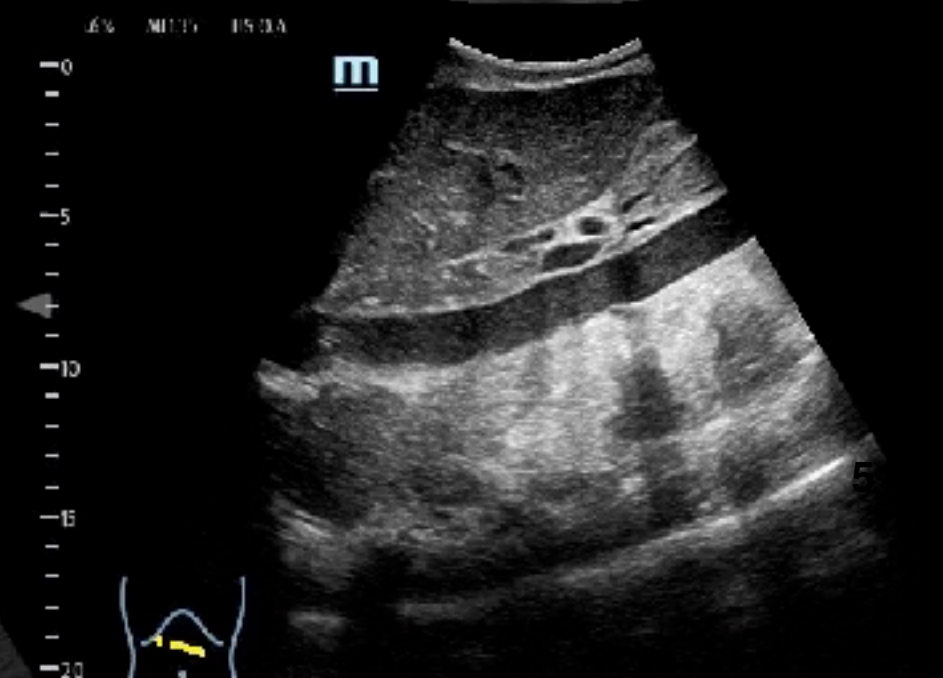
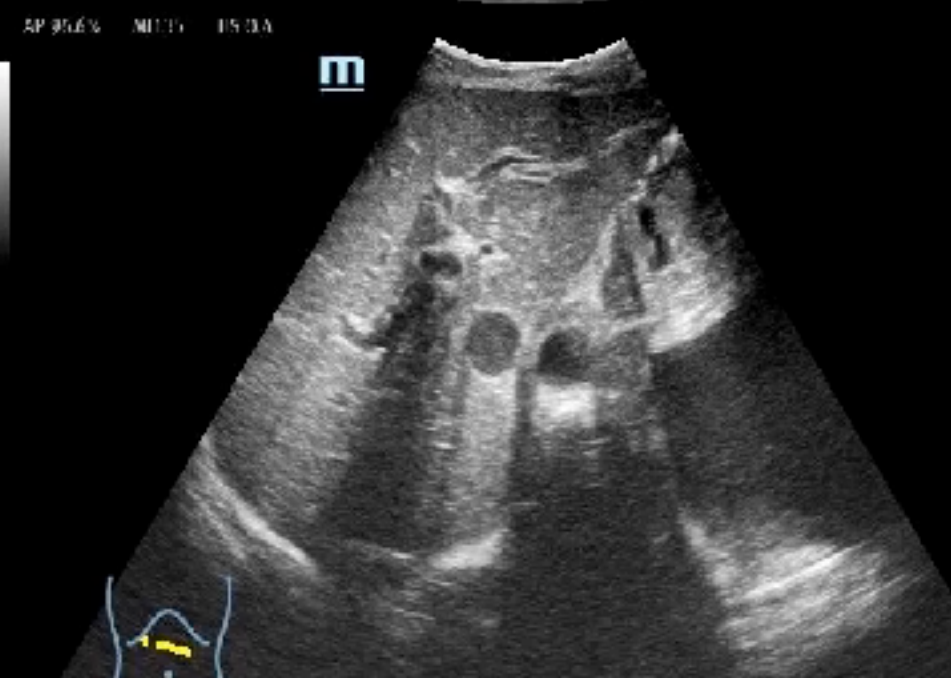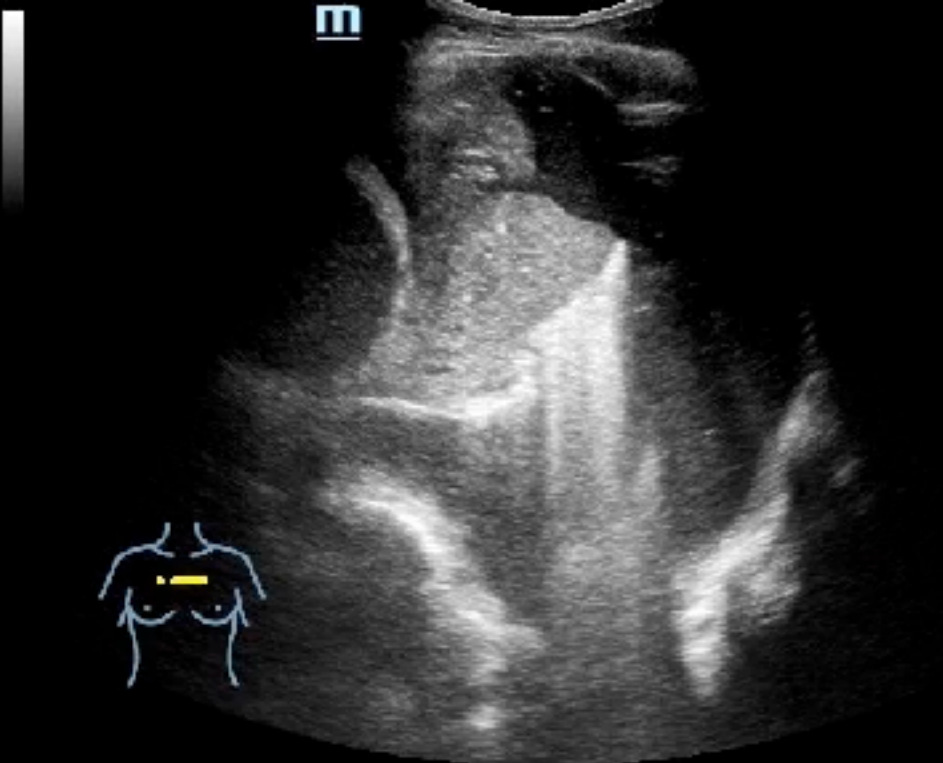
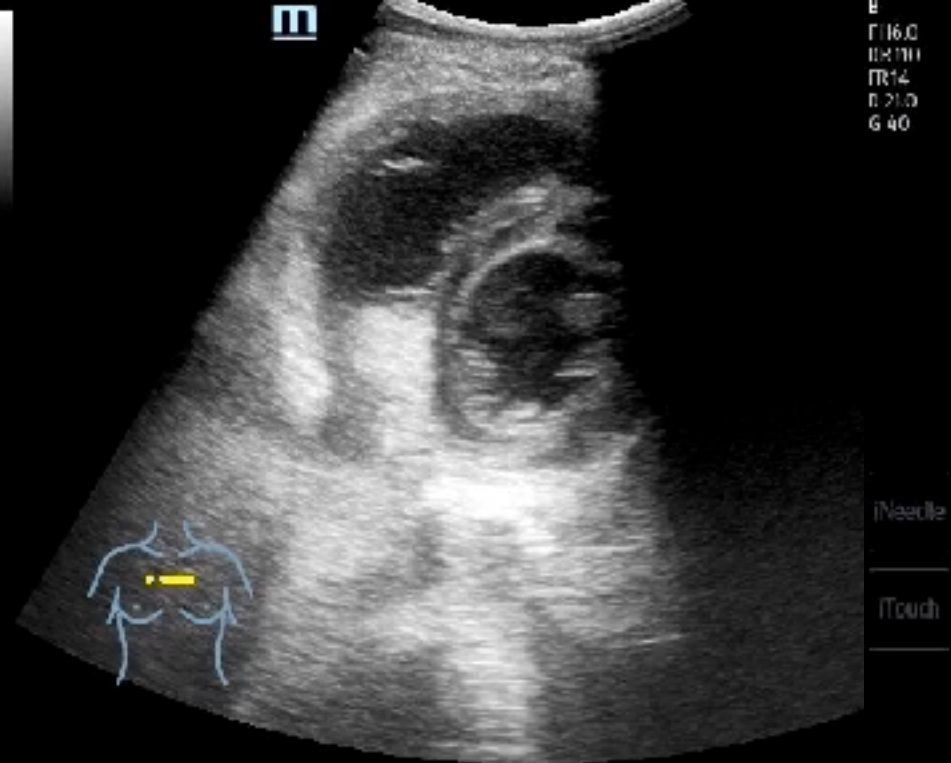
0
1
2
3
4
5
6
7
8
9
10
11
12
13
14
15
16
17
18
19
20
21
22
23
24
25
26
27
28
29
30
31
32
33
34
35
36
37
38
39
40
41
42
43
44
45
46
47
48
49
50
51
52
53
54
55
56
57
58
59
60
61
62
63
64
65
66
67
68
69
70
71
72
73
74
75
76
77
78
79
80
81
82
83
84
85
86
87
88
89
90
91
92
93
94
95
96
97
98
99
100

44M , Weak & shock; Hx of hypopharyngeal ca s/p

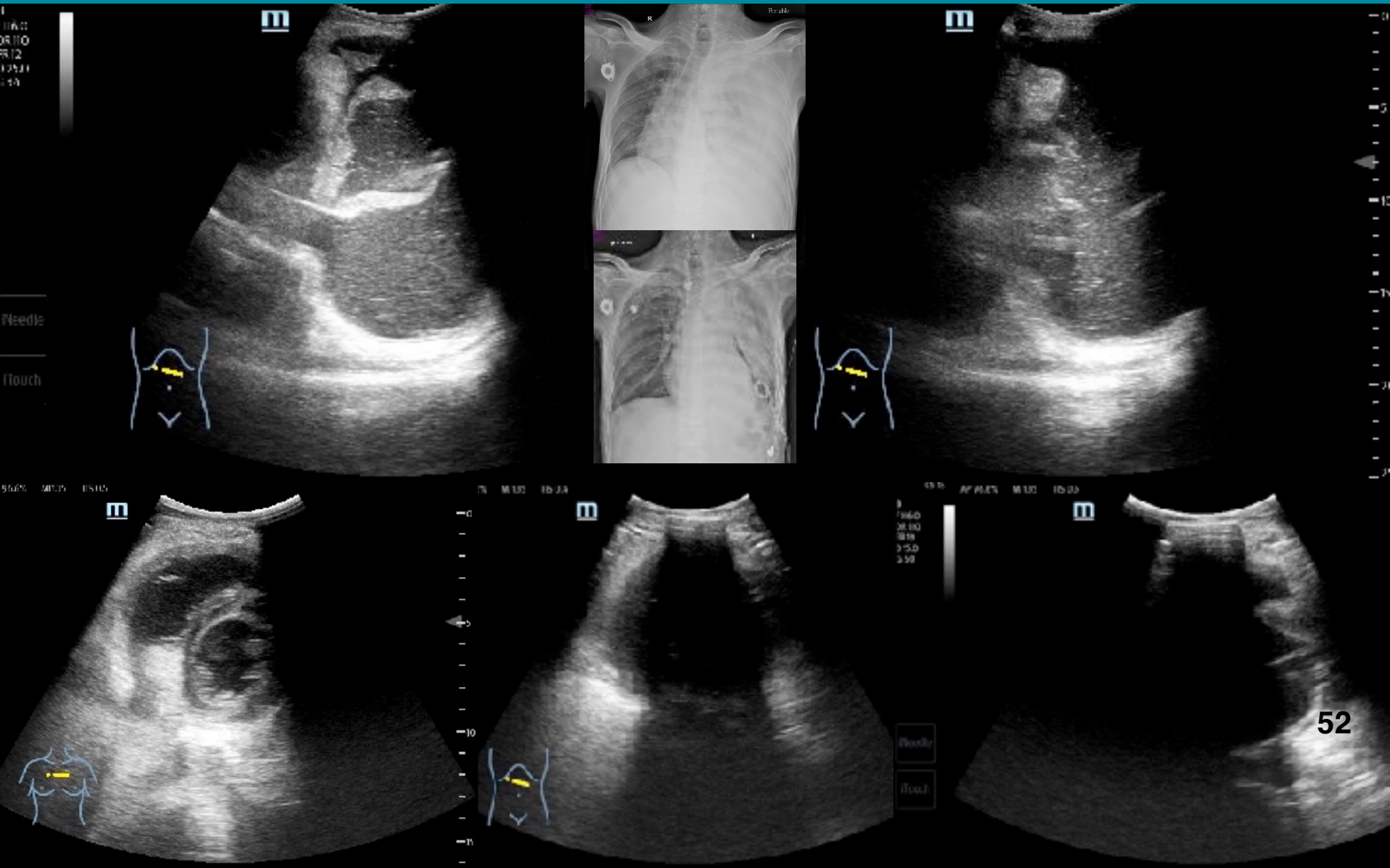


Tension pyopneumothorax

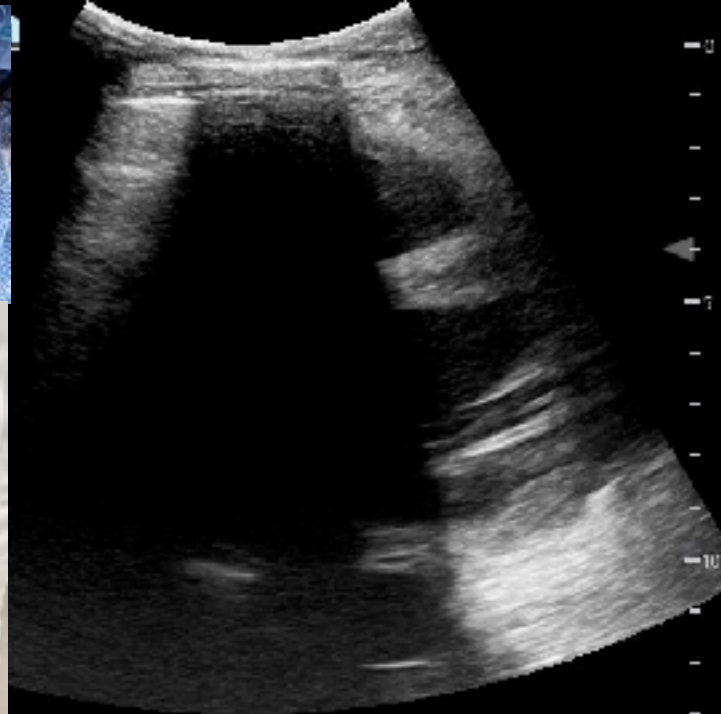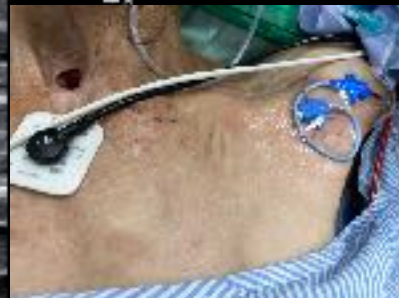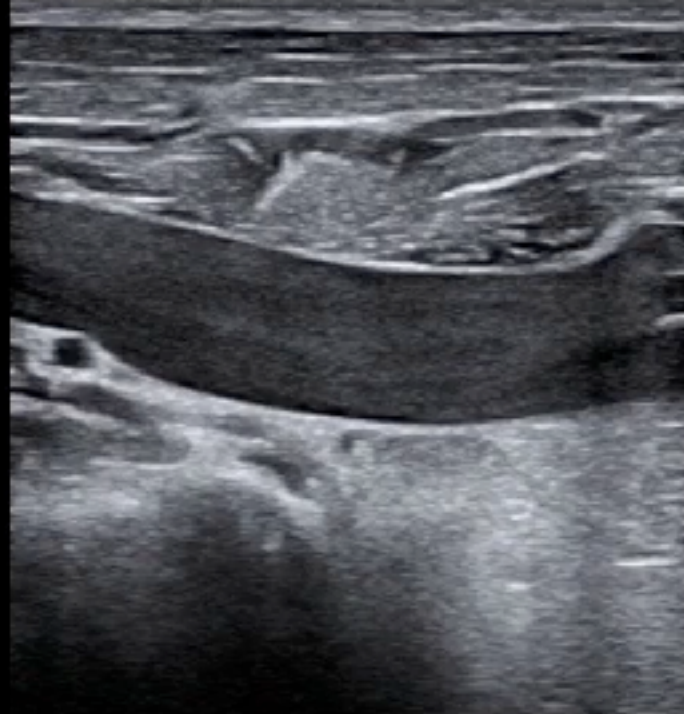




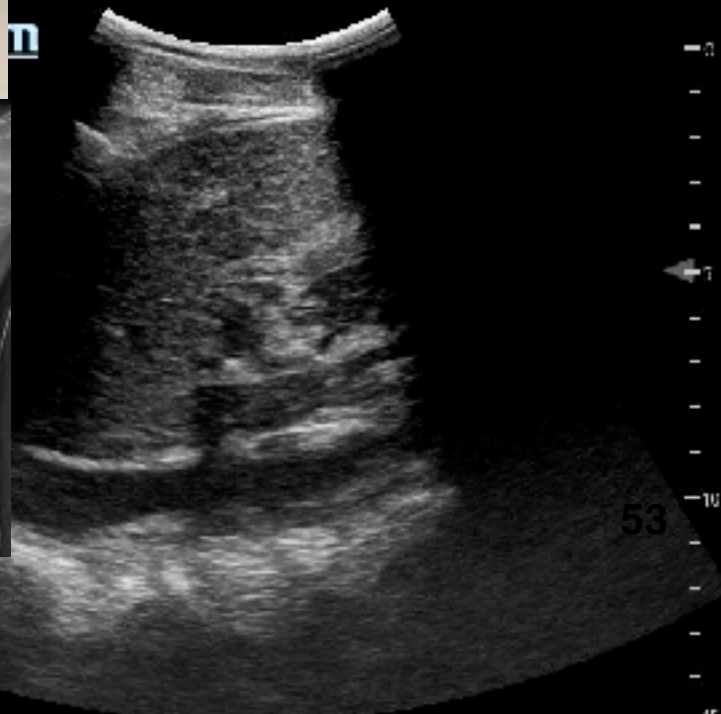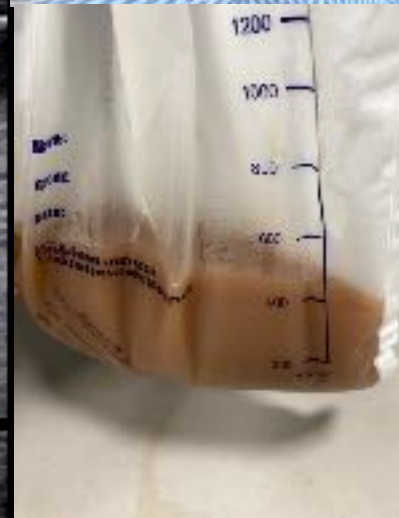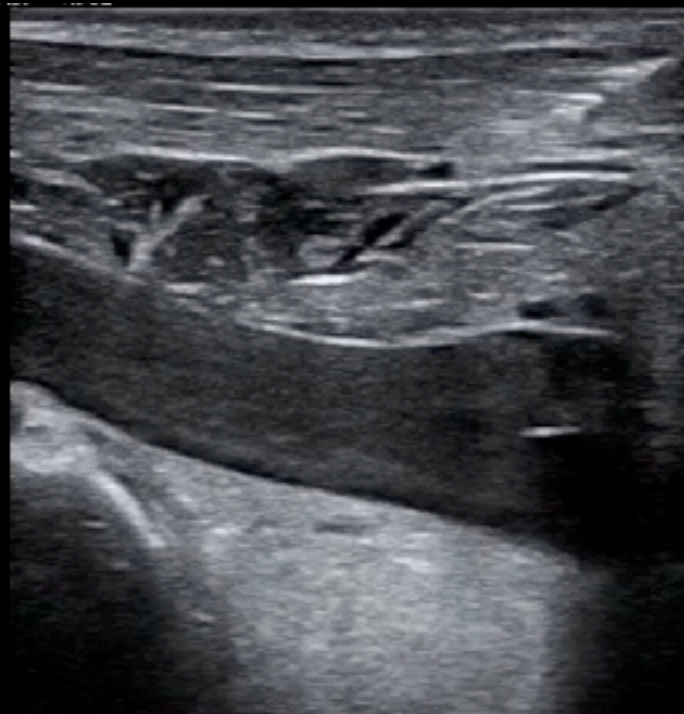14 Fr Pigtail insertion



m

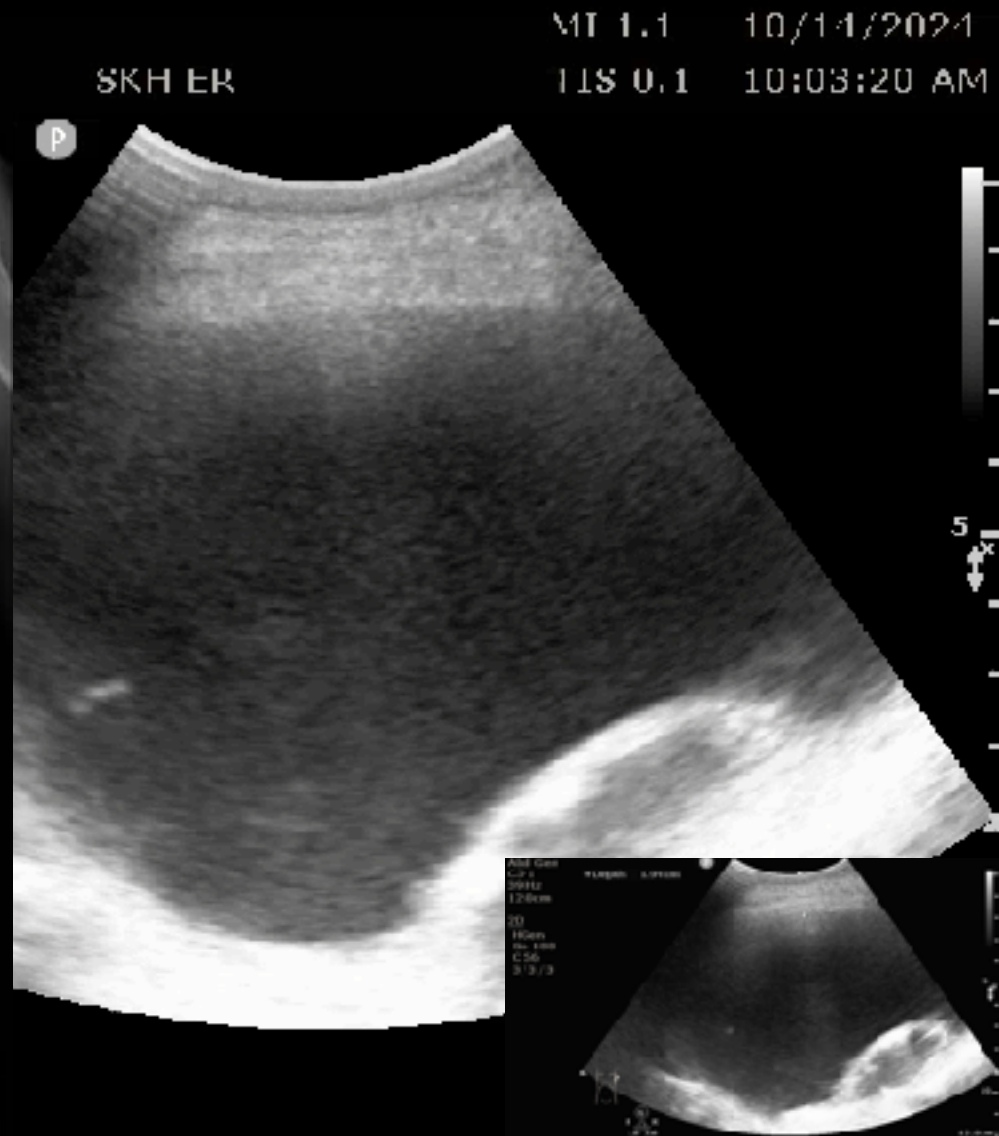
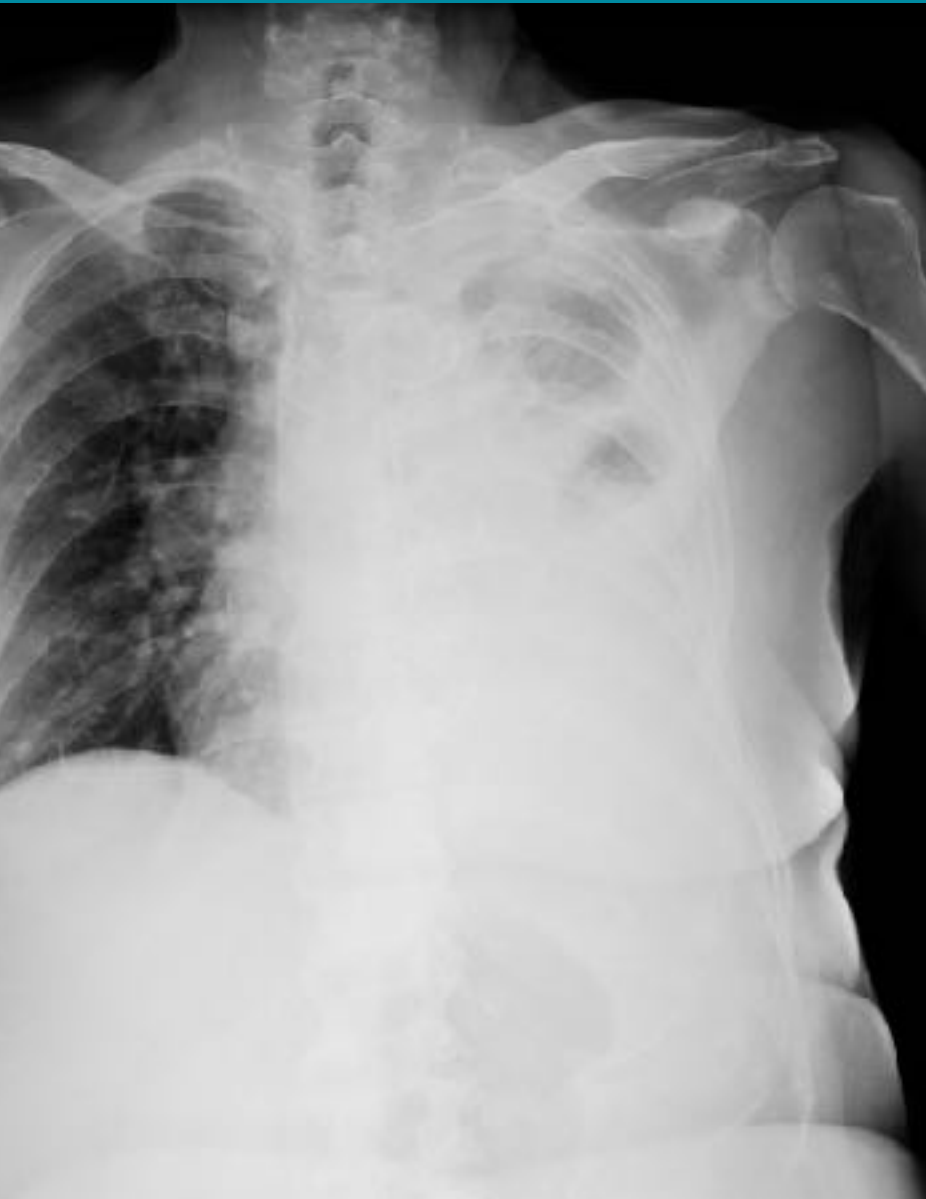

m



1600 ml

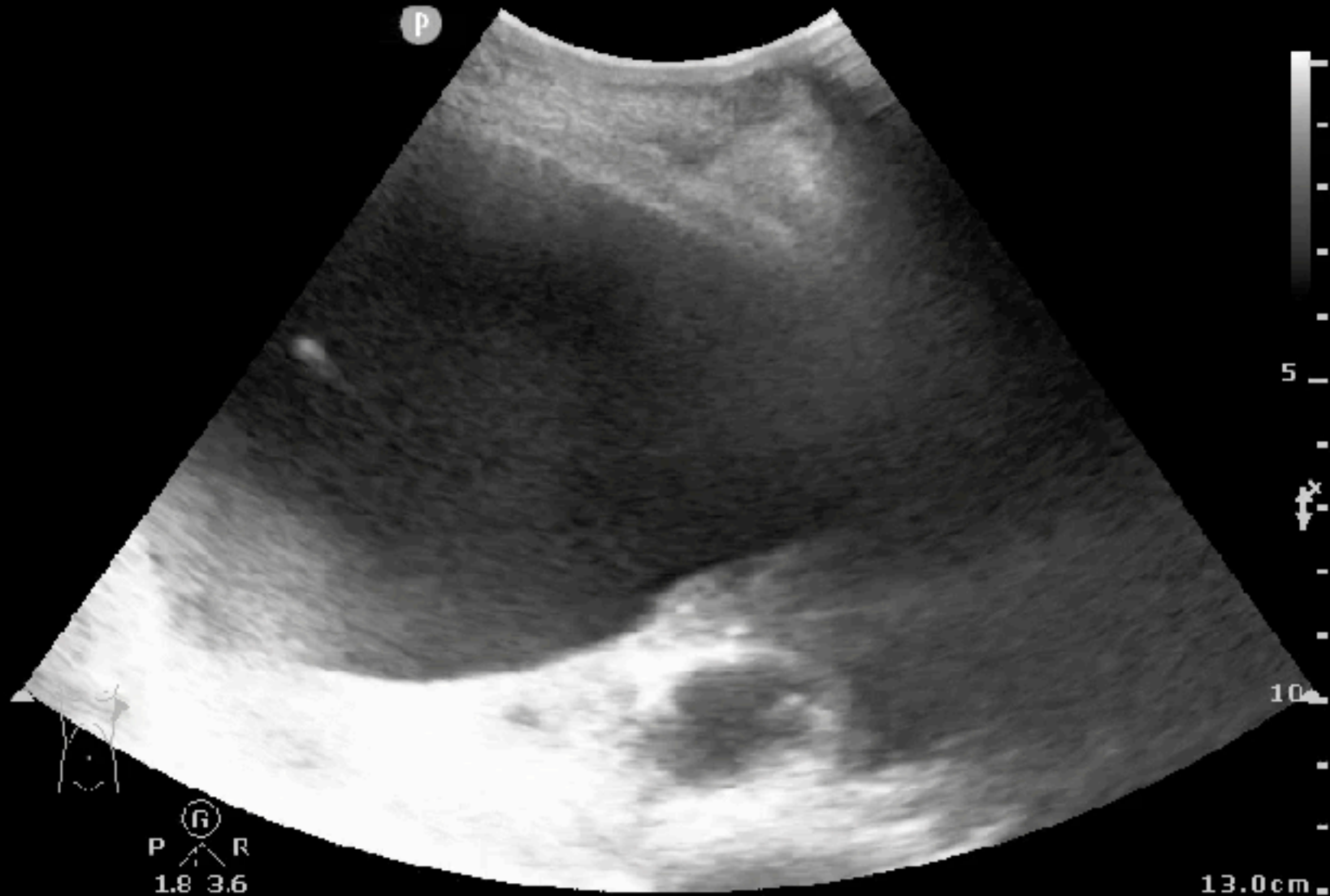73F, Lung ca with massive PLE



Pigtail for massive PLE

Abd Gen
C5-1
38 Hz
13.0cm

2D
HGen
Gn 100
C. 56
3/3/3



Pigtail with guidewire for massive PLE

Rescue plane

Informed consent

Coagulation profiles

Monitor

Pre-scan

Positioning

Preparation

Pain control / PSA

Guiding needle

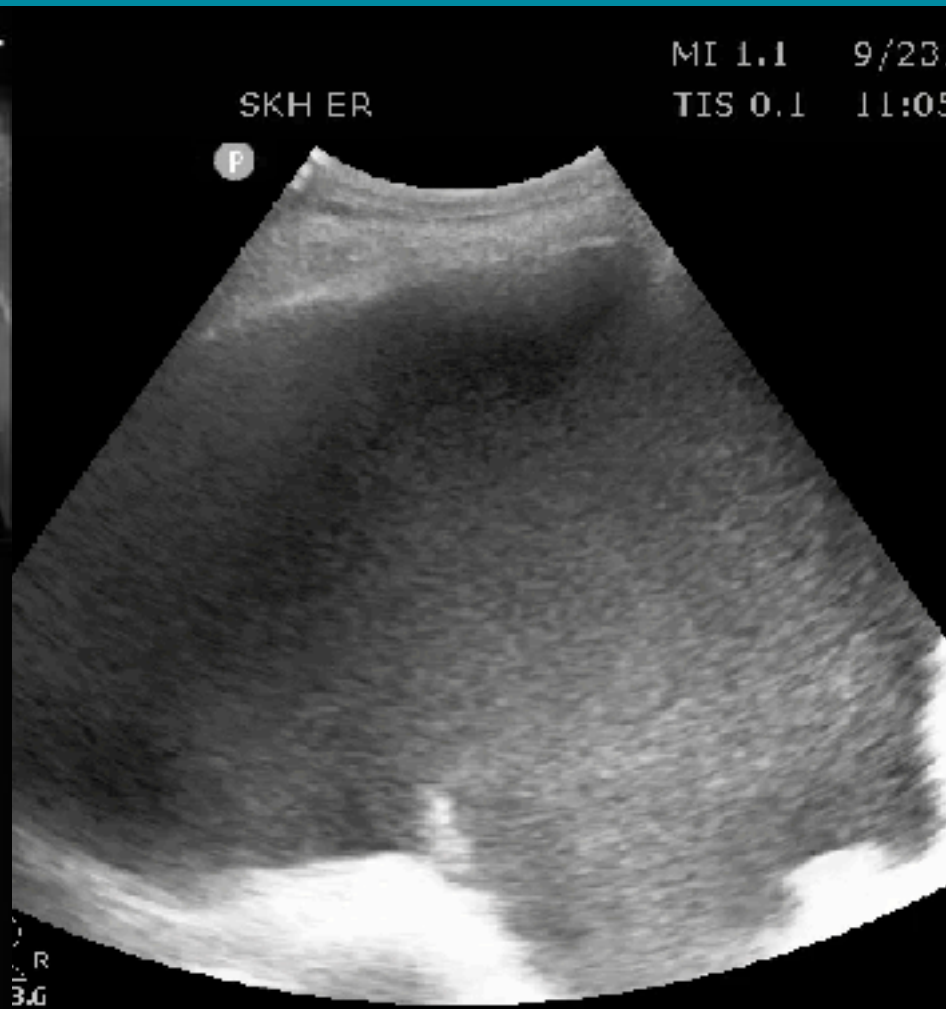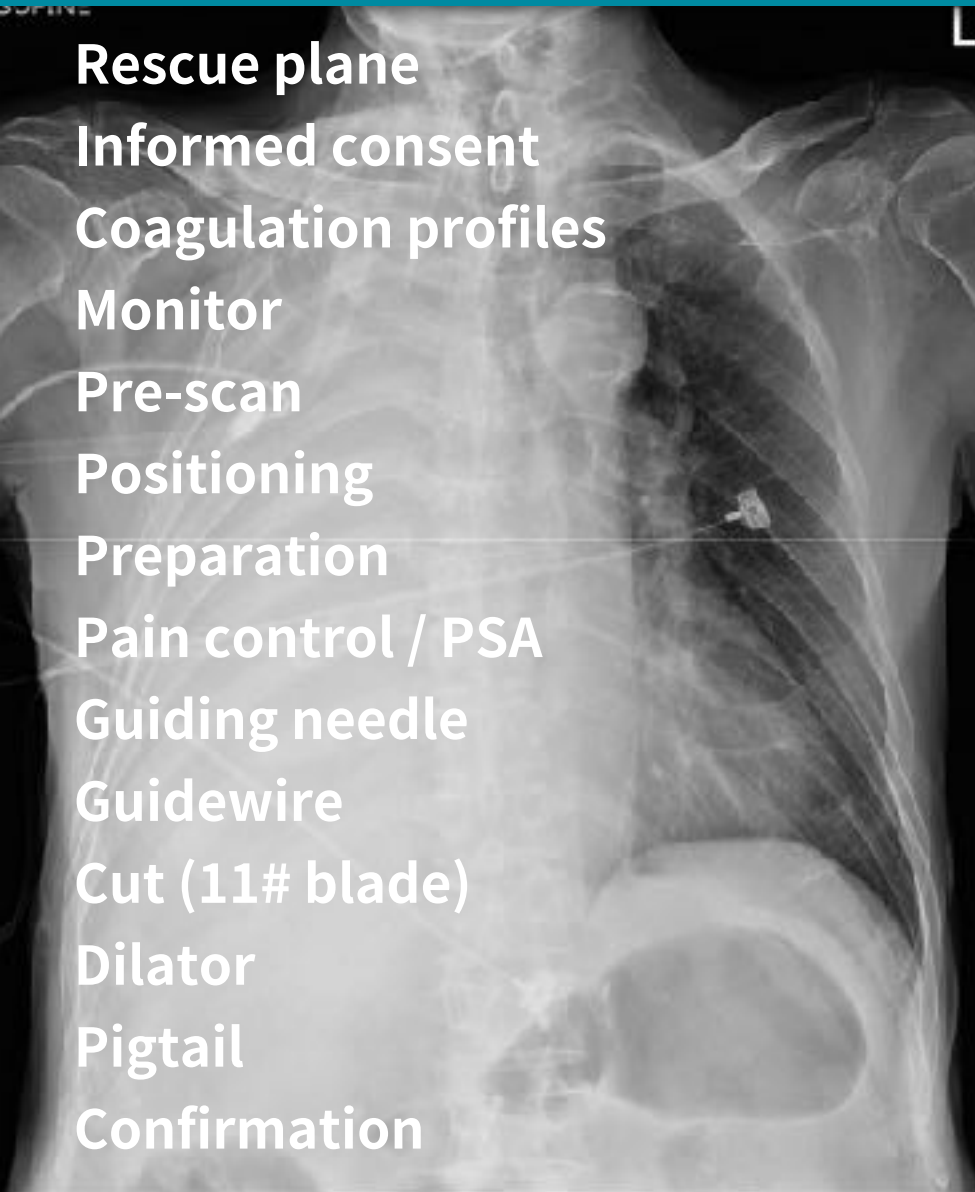Guidewire

Cut (11# blade)

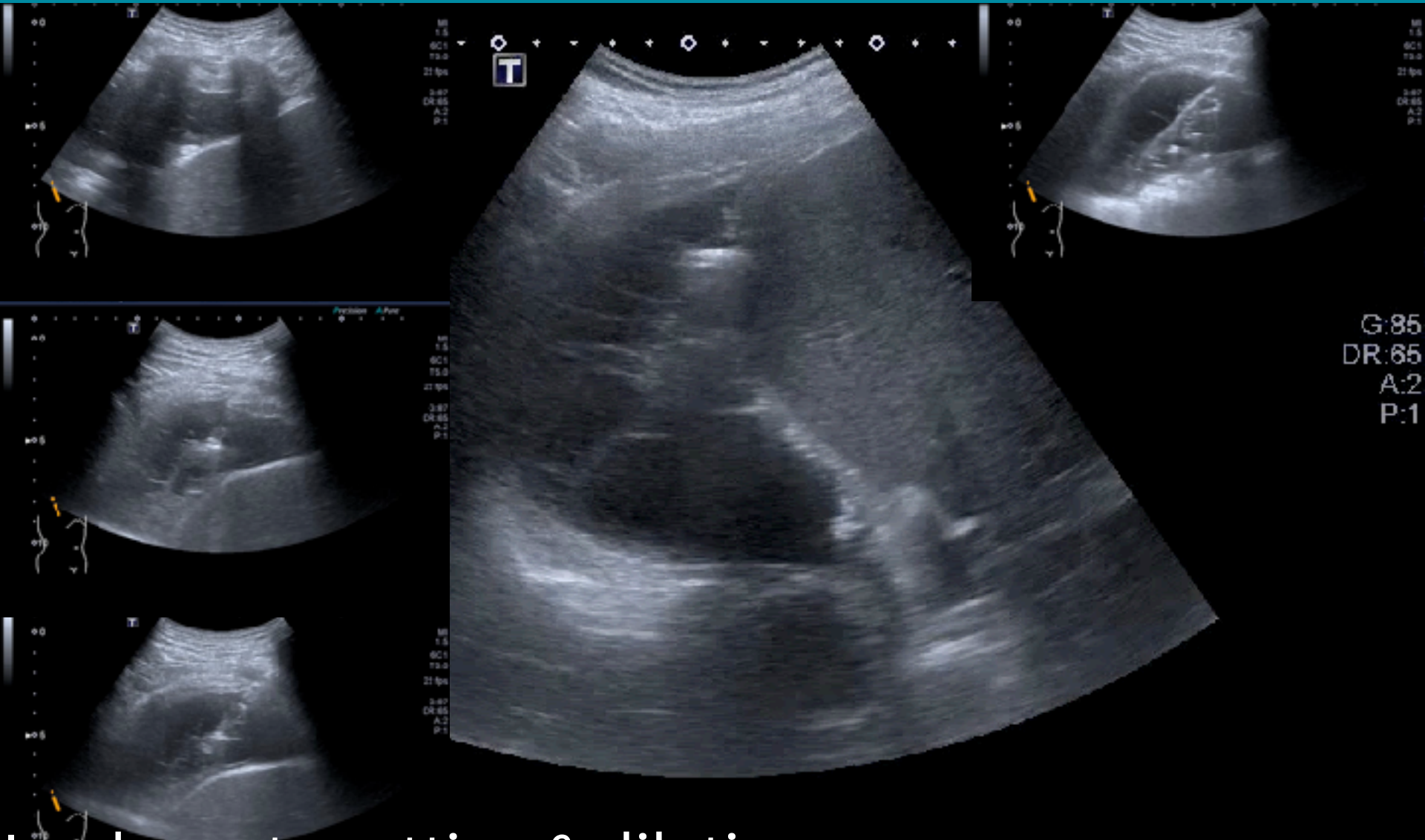
Dilator

Pigtail

Confirmation



Empyema

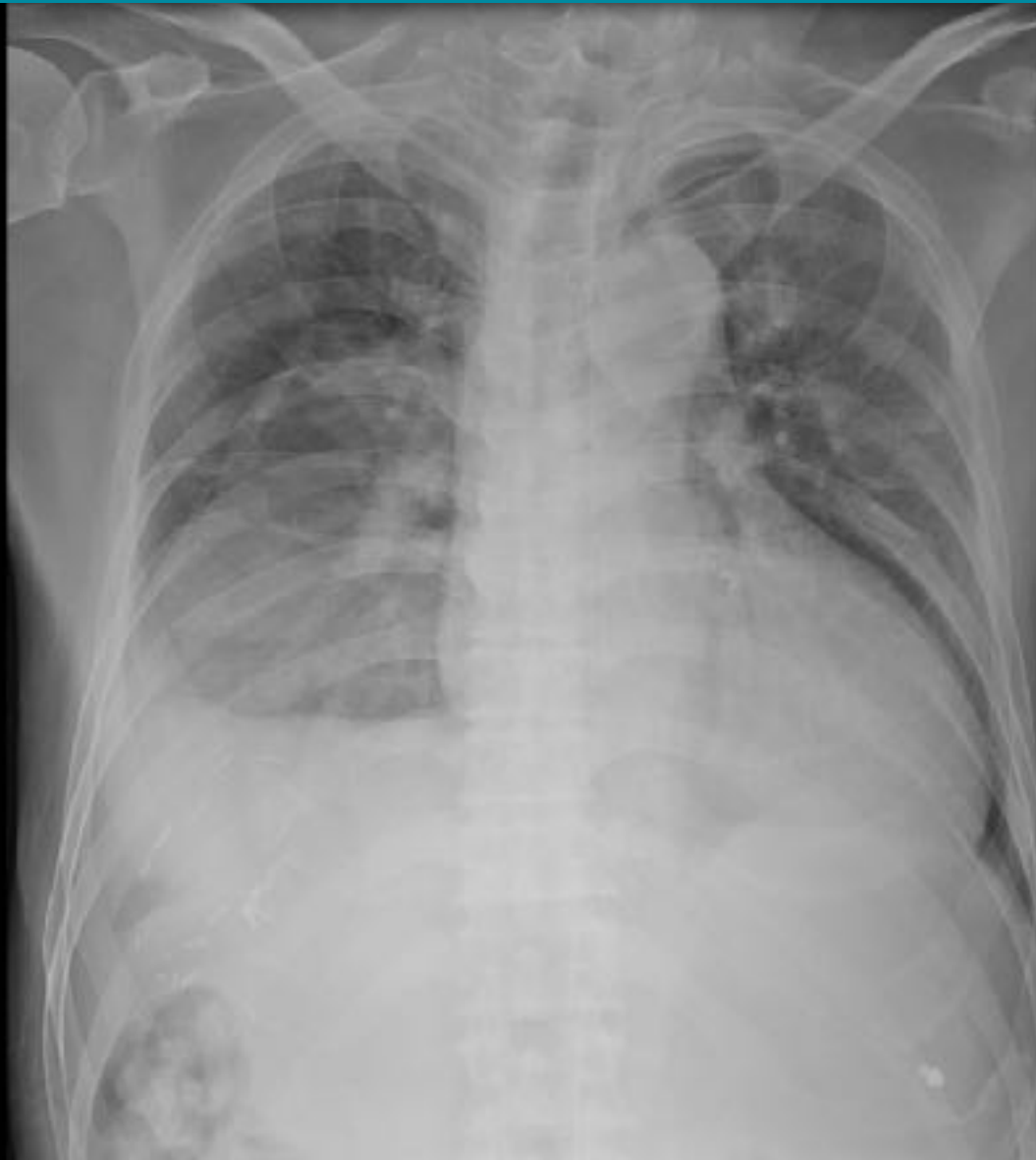

Inadequate cutting & dilating

66M, RLL PN with PLE

ACC:
2024/09/18
15:29:28

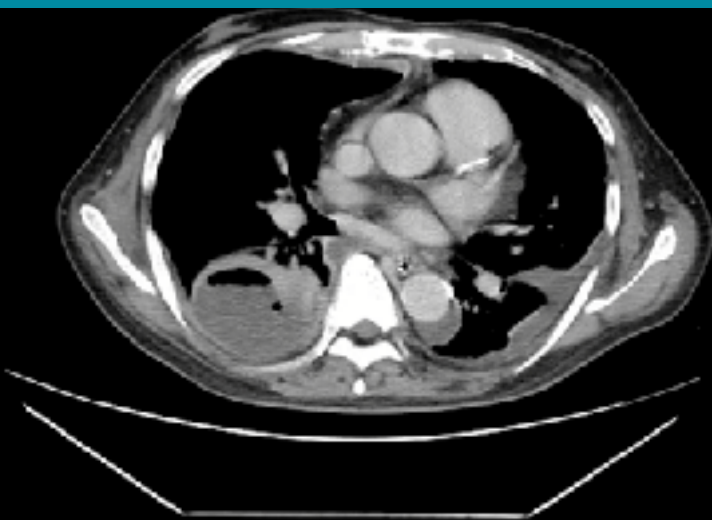IIW: 2



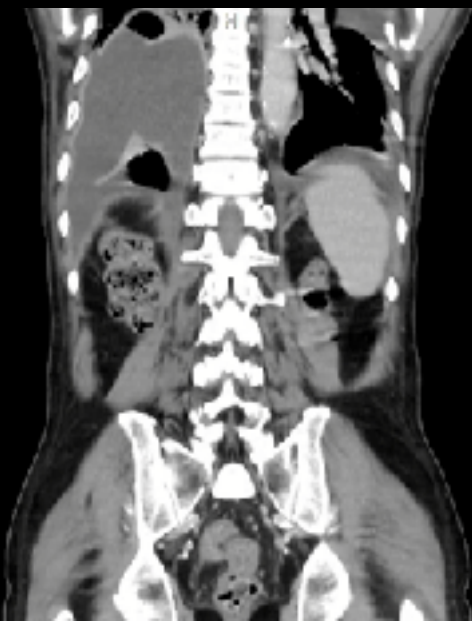KV:
WC:1813 ,WW:3842

AP
Chest PA

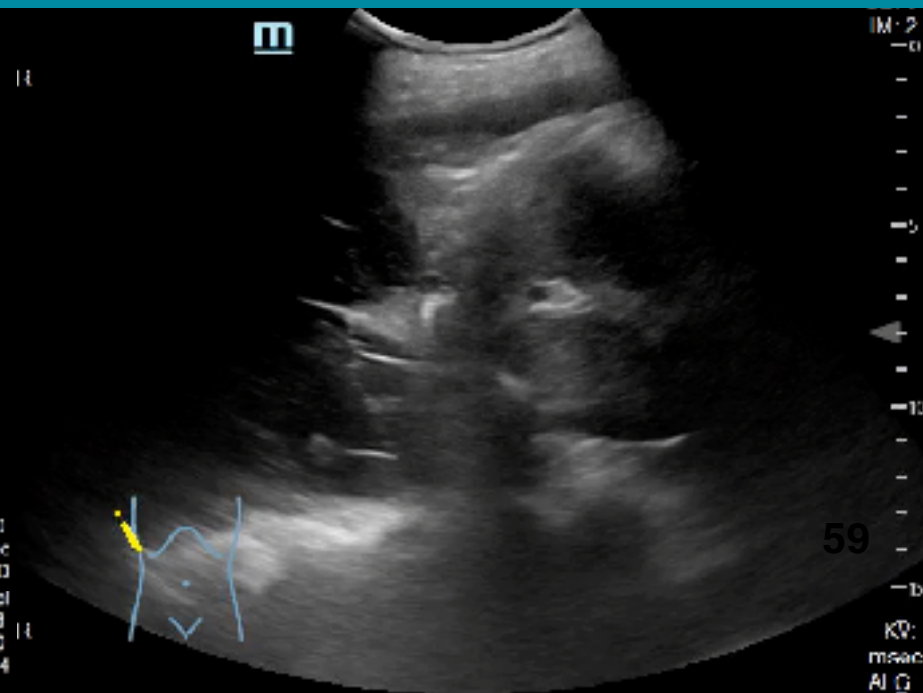
66M, lung abscess



0
CT(-C, IC)

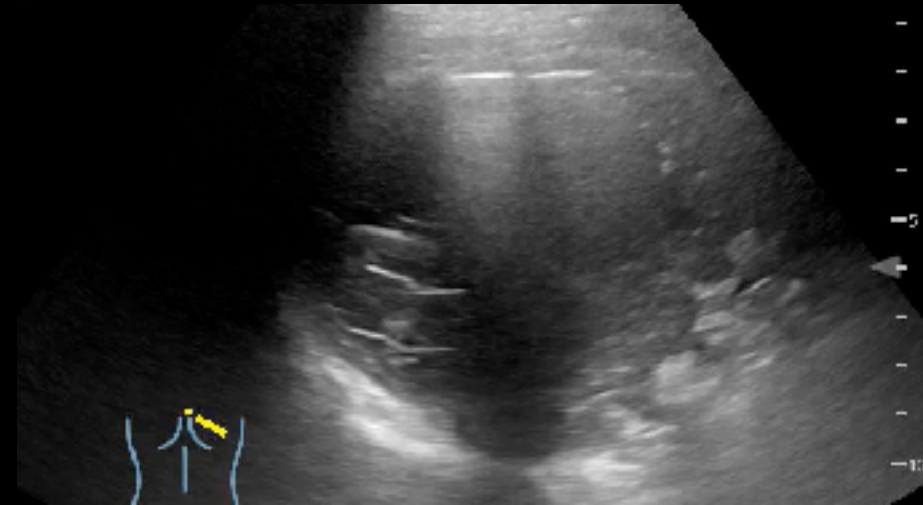


KV: 120
500 msec
ALG: STANDARD
Shuang Ho Hospital
27963
SE: 400
IM: 34

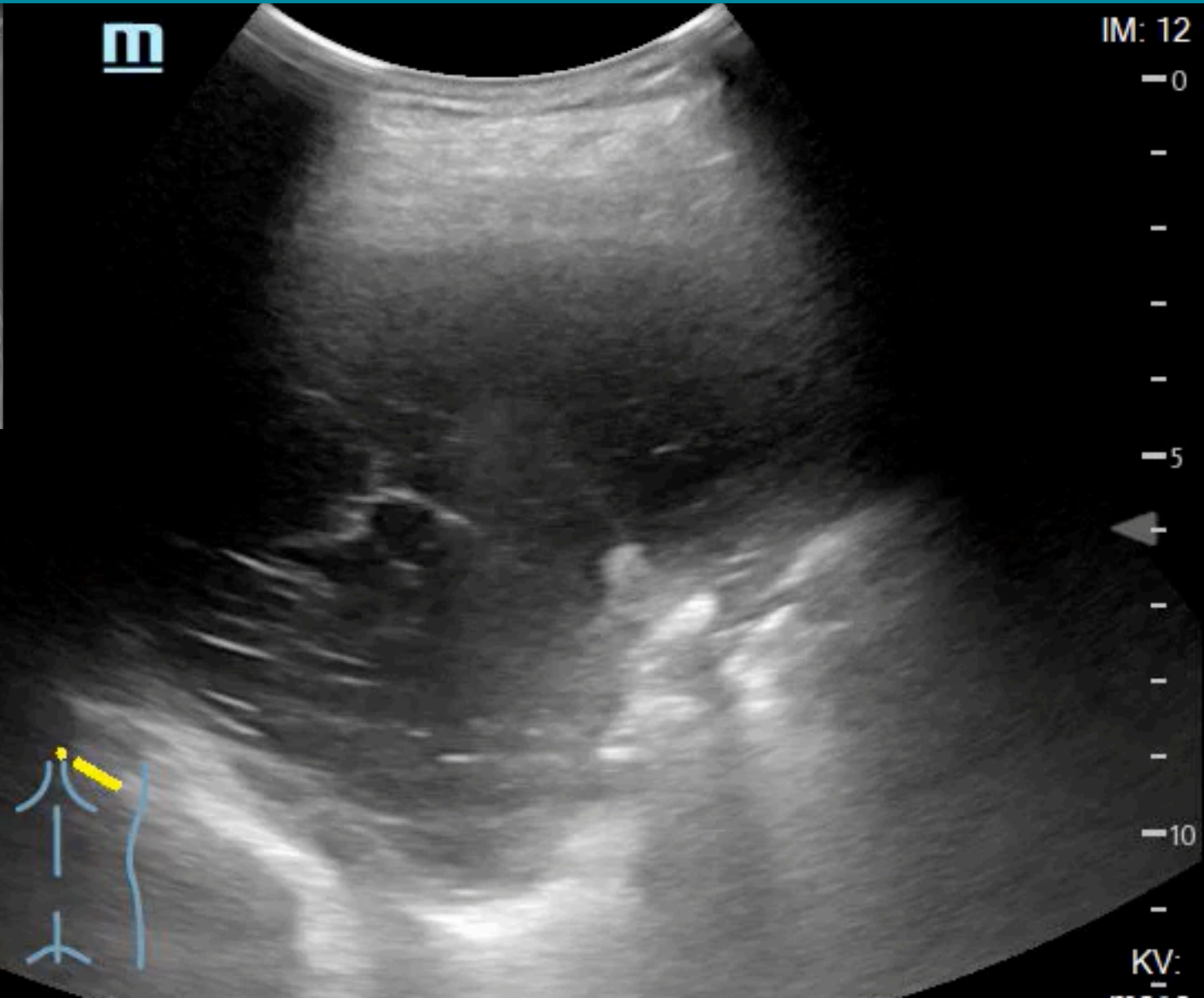
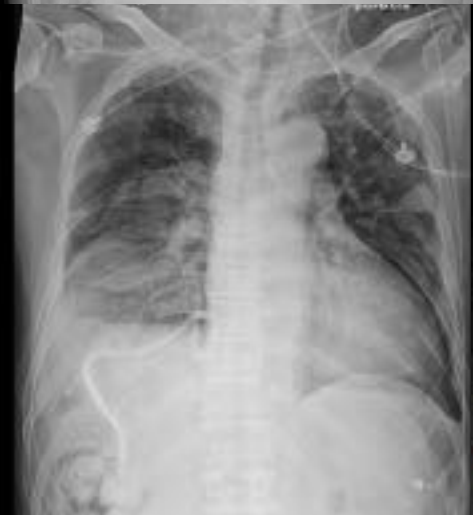
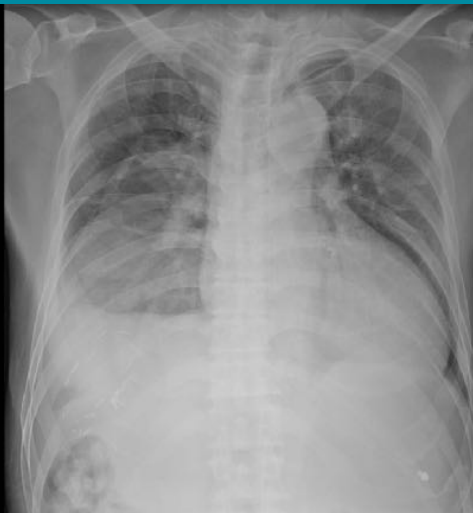
59

IM: 2
-0
-5
-10
-15
-20
-25
-30
-35
-40
-45
-50
-55
-60
KV:
msec
ALG

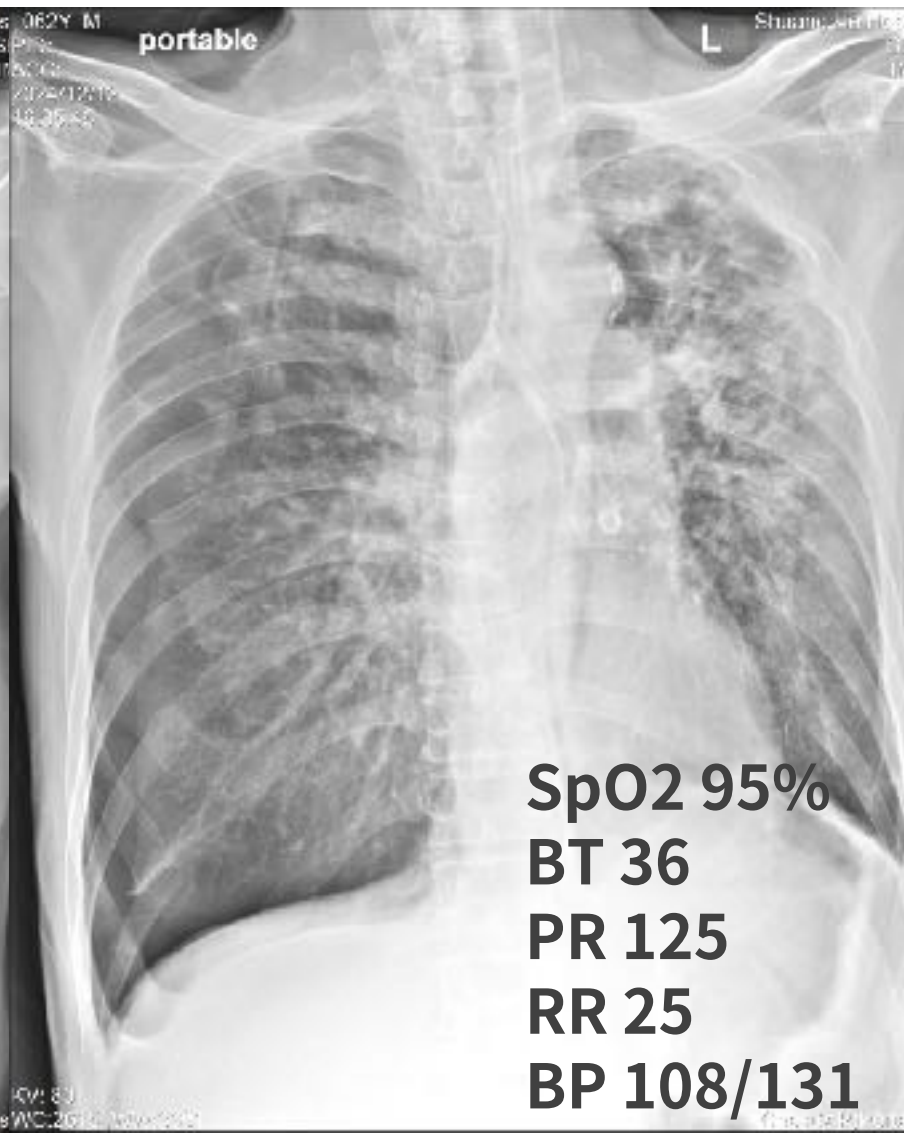
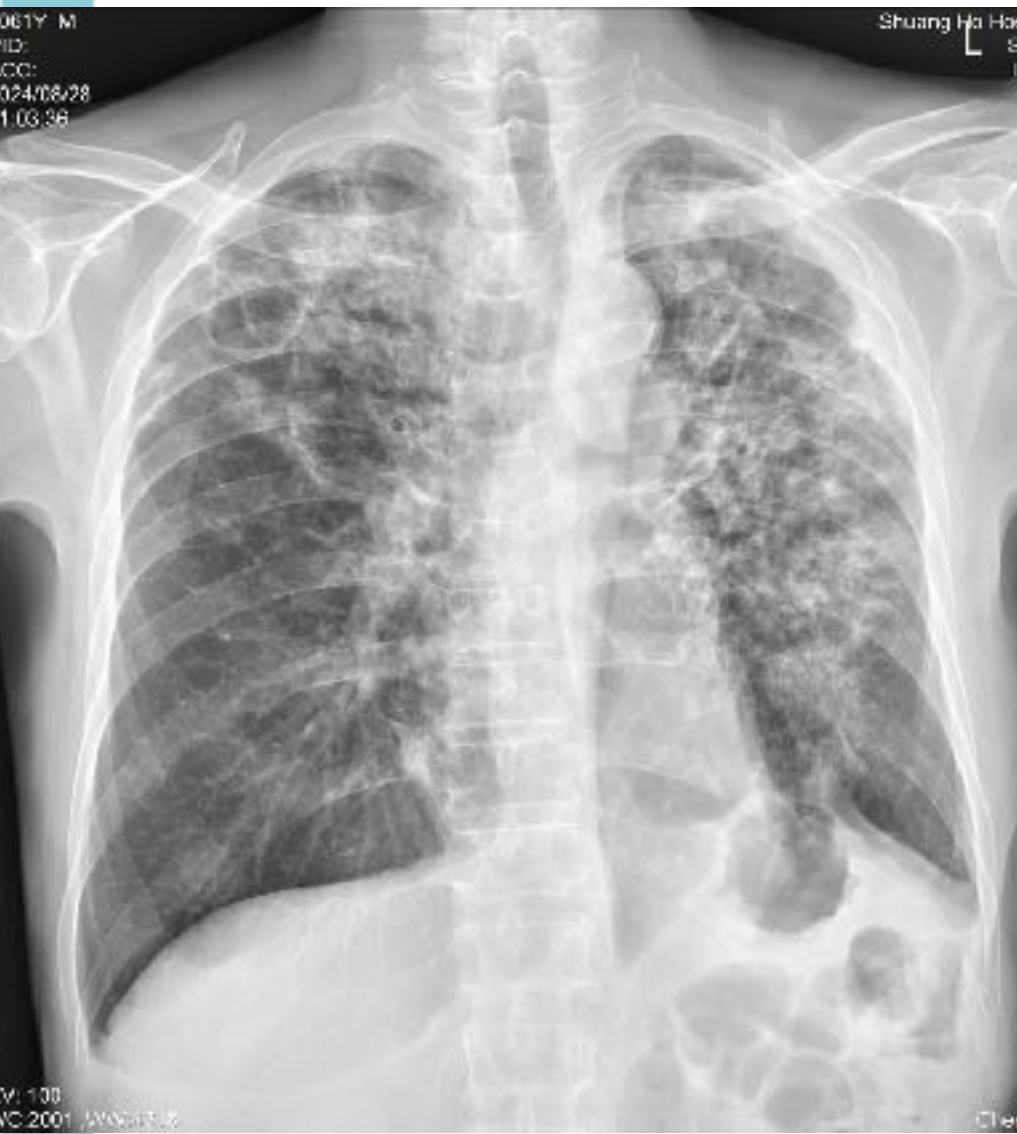

Pigtail for lung abscess

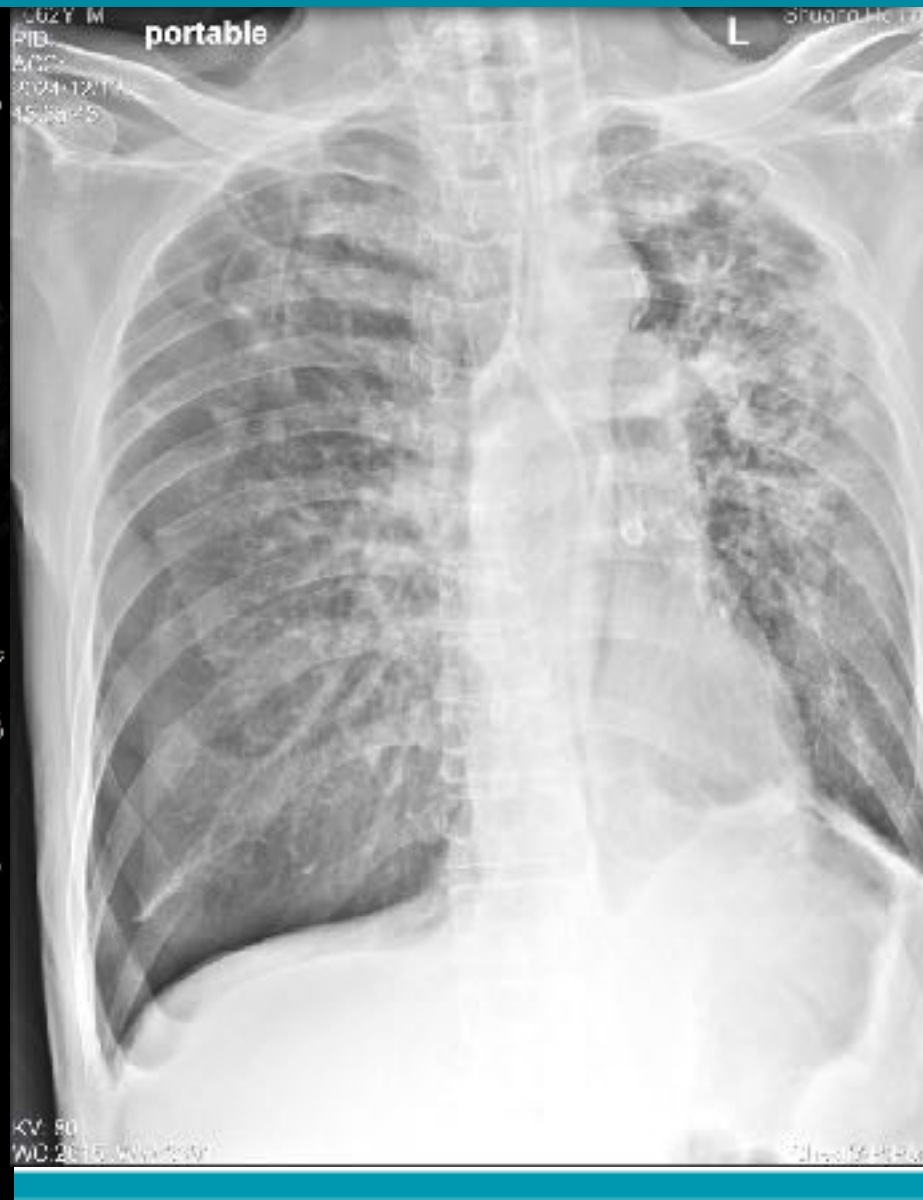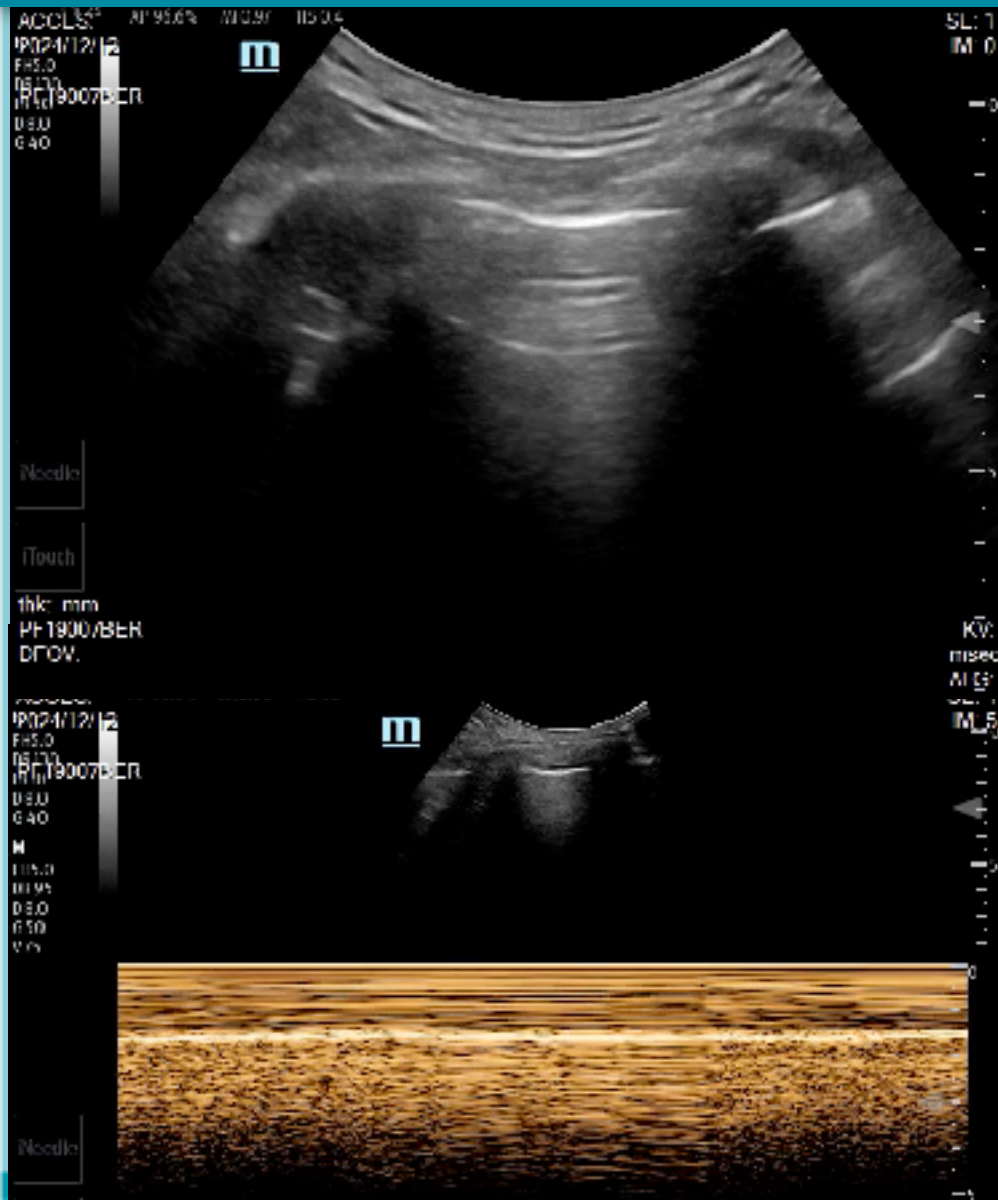


thk: mm
PF19007BER
DEOV:

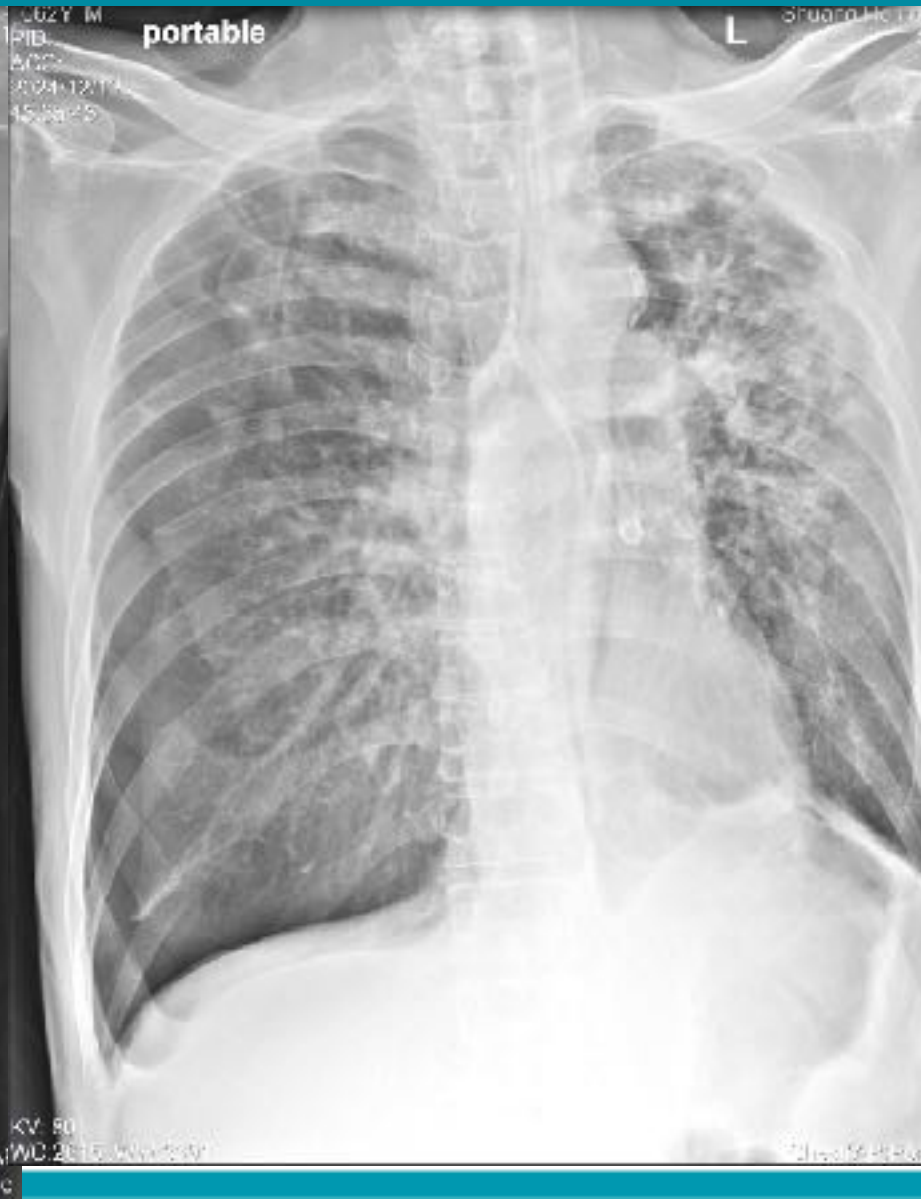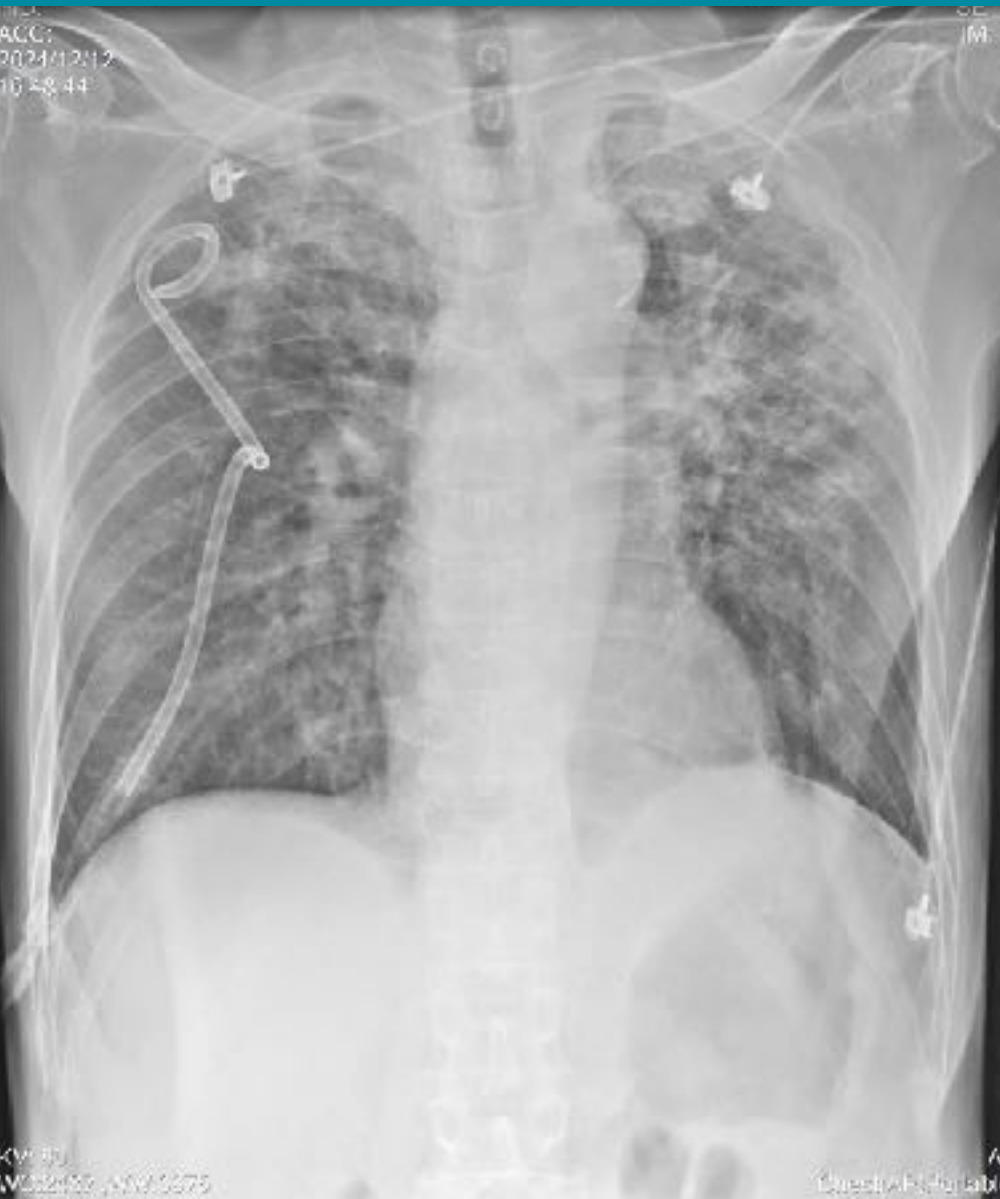62M, Pul TB under treatment, SOB for 30 mins 16:16



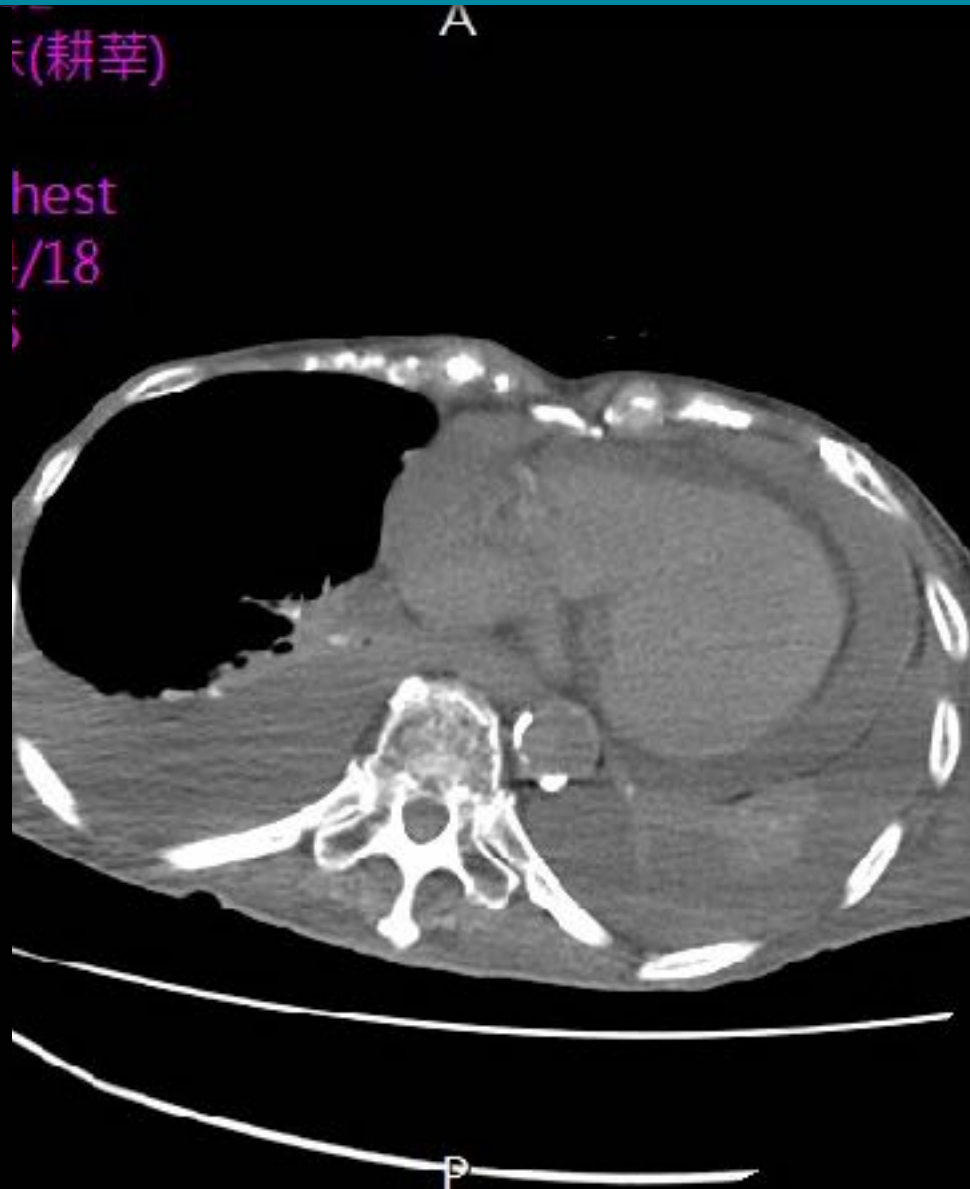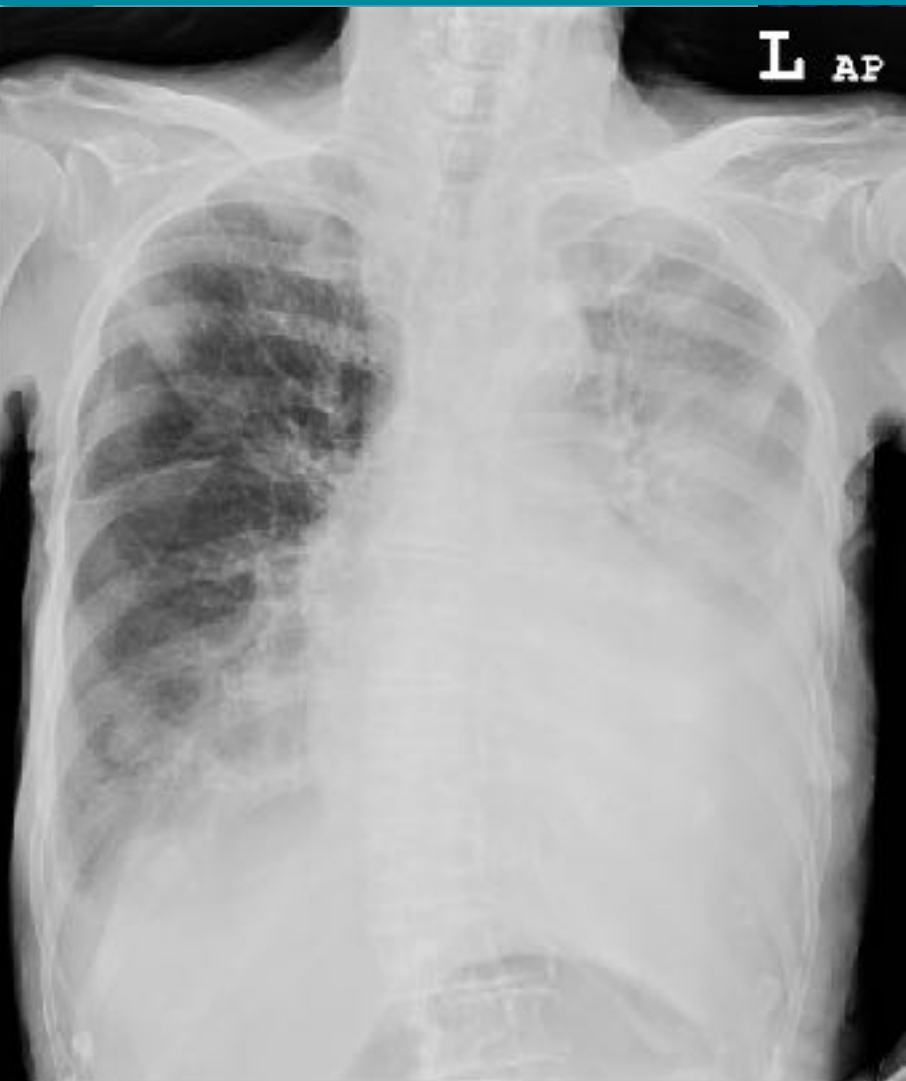AMS / SpO2 78% after portable

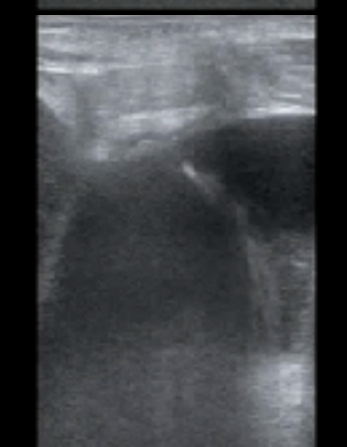
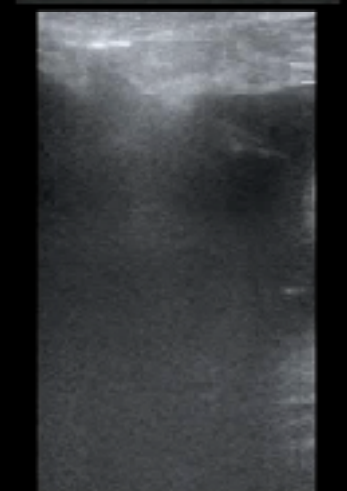
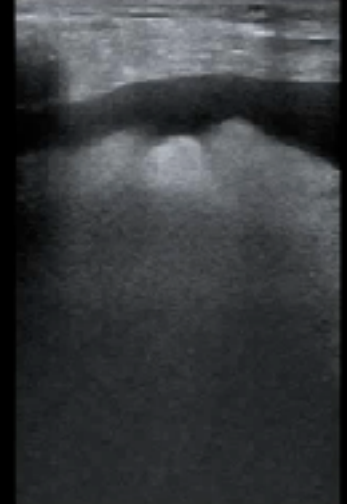
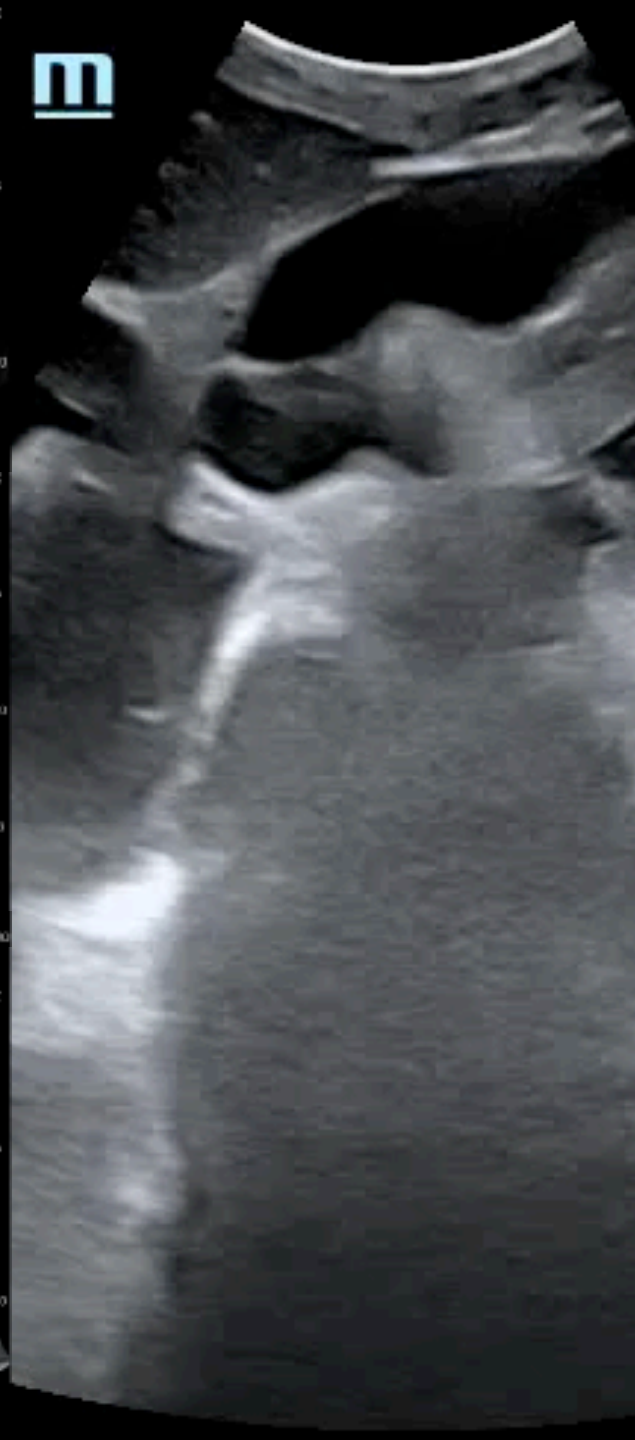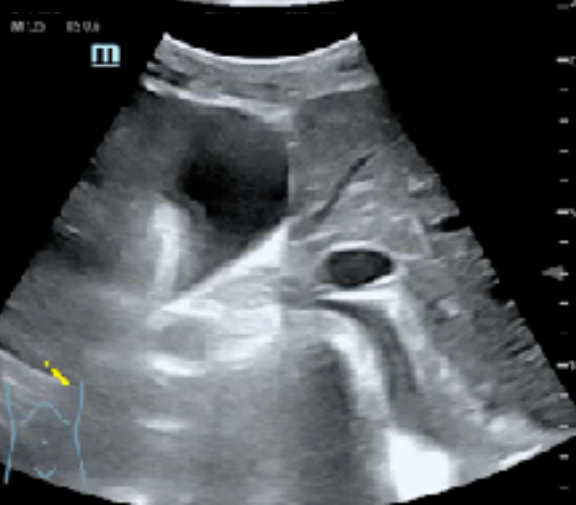

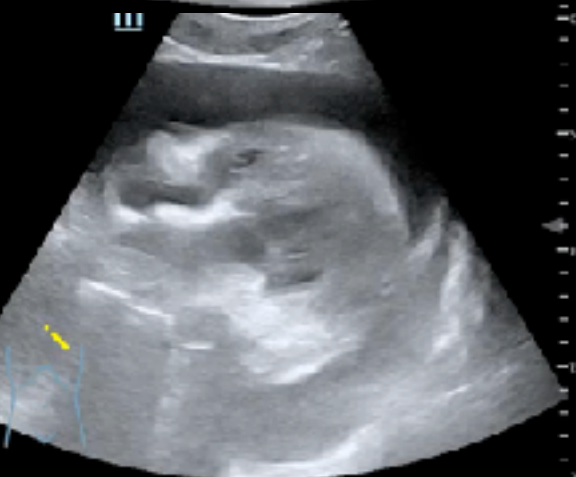
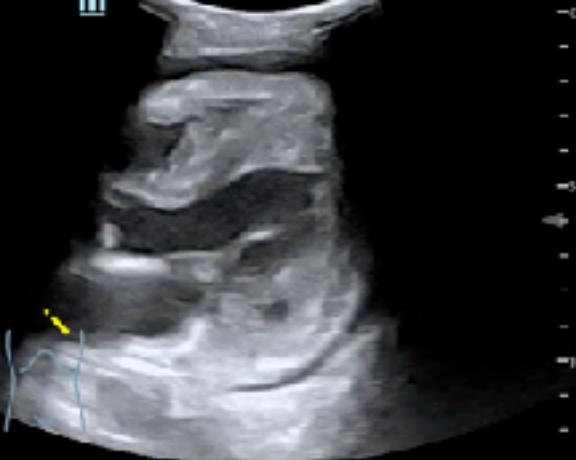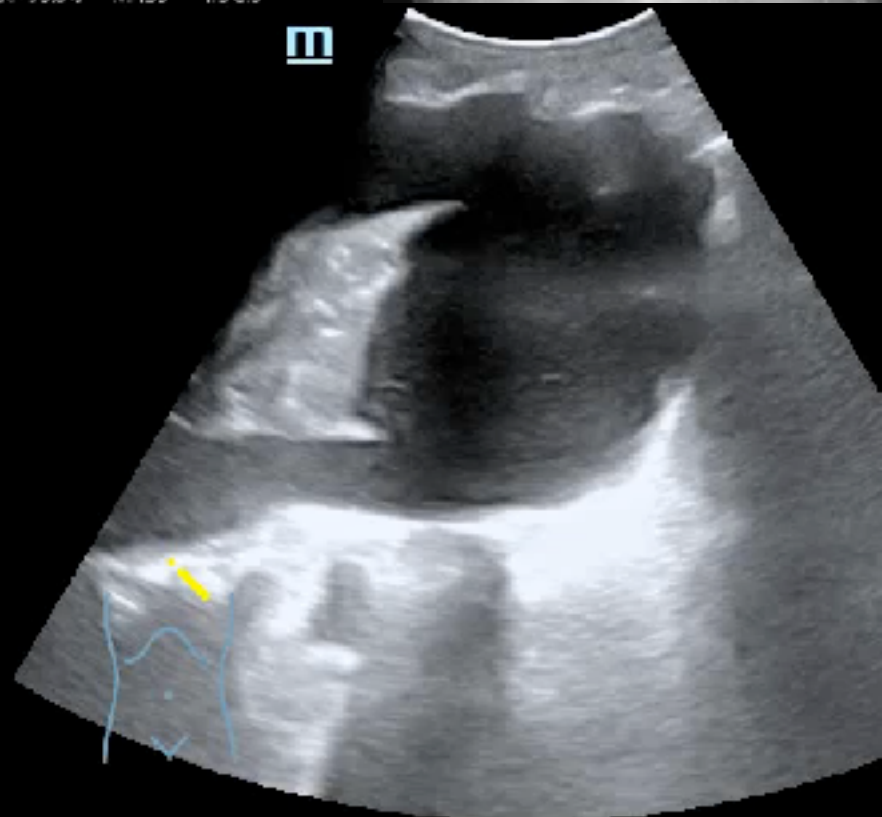
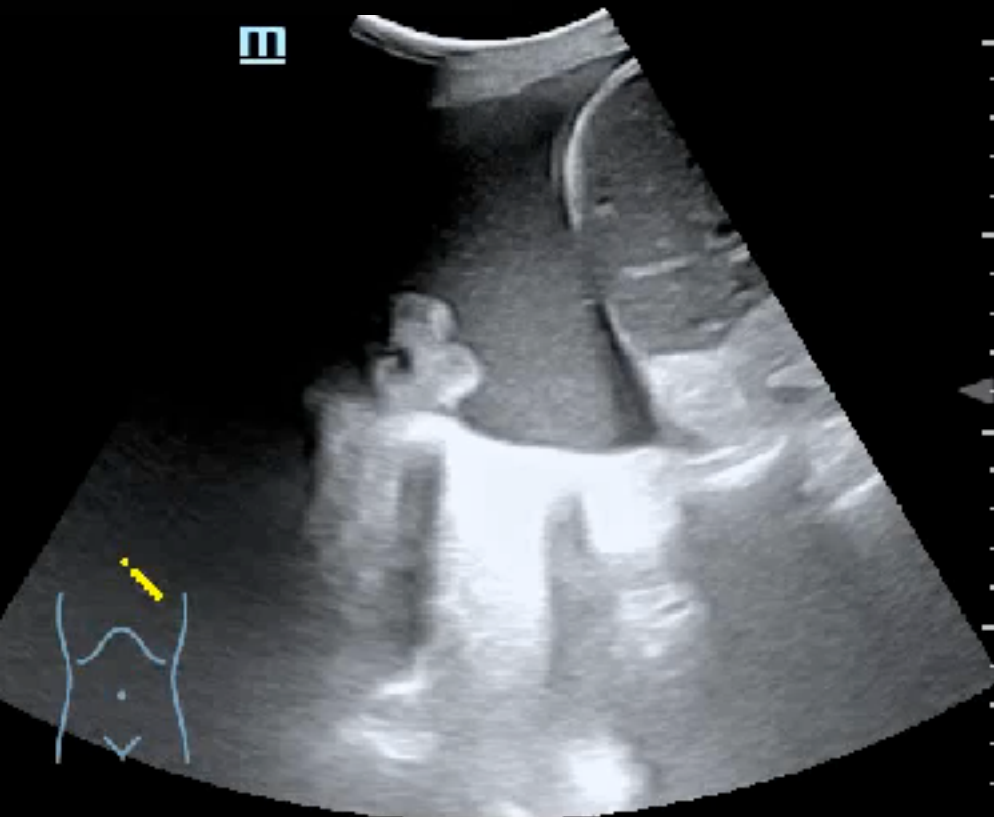
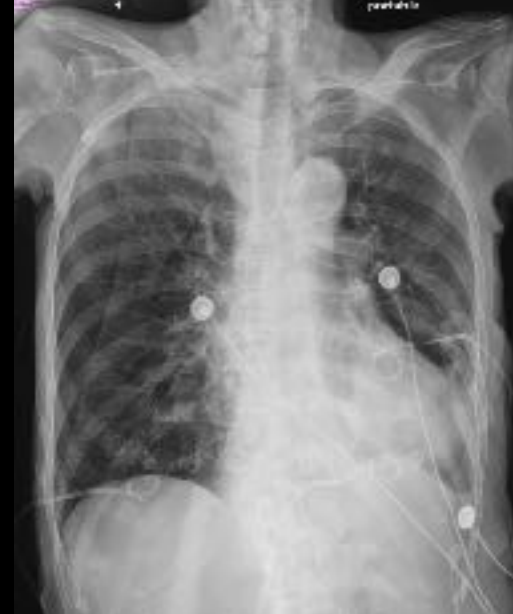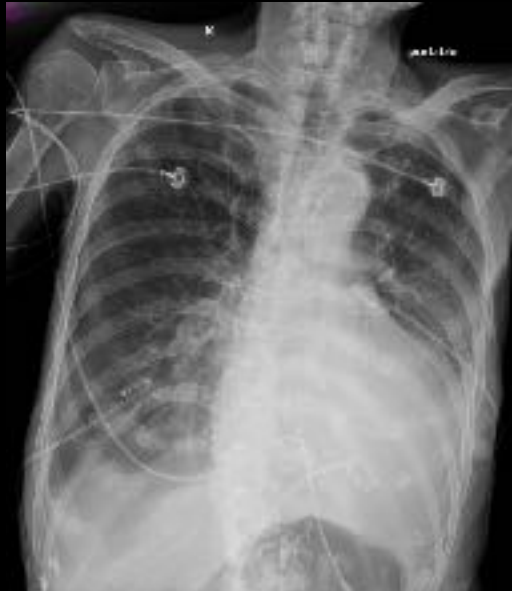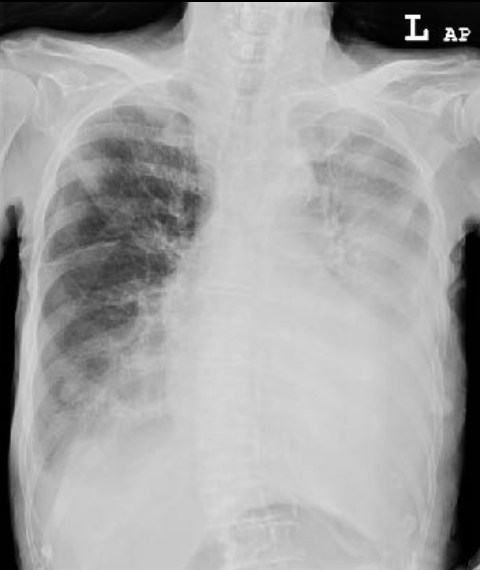Tension pneumothorax s/p pigtail drainage

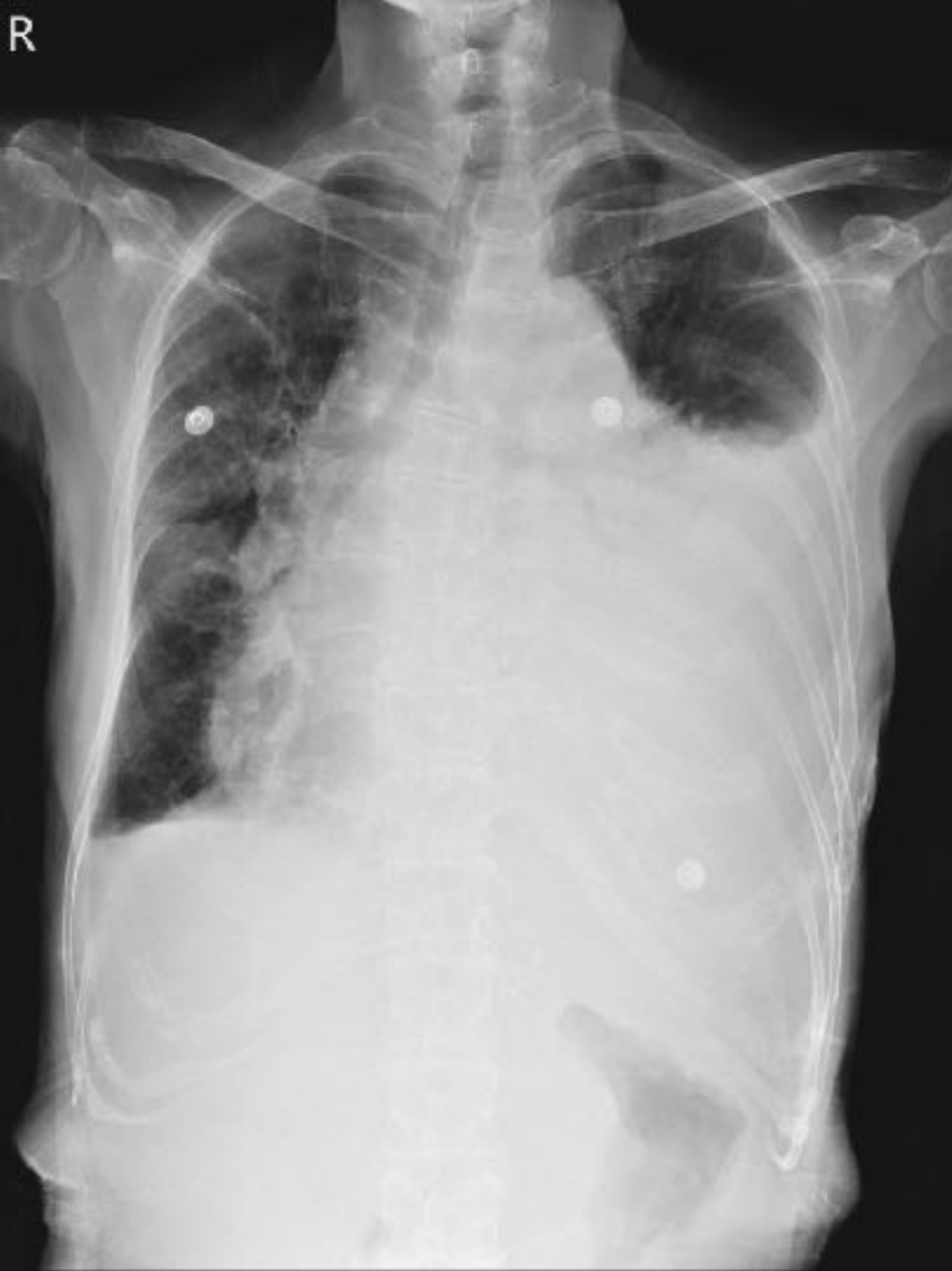

85M, AMS with shock, 外院轉入









個案

62F

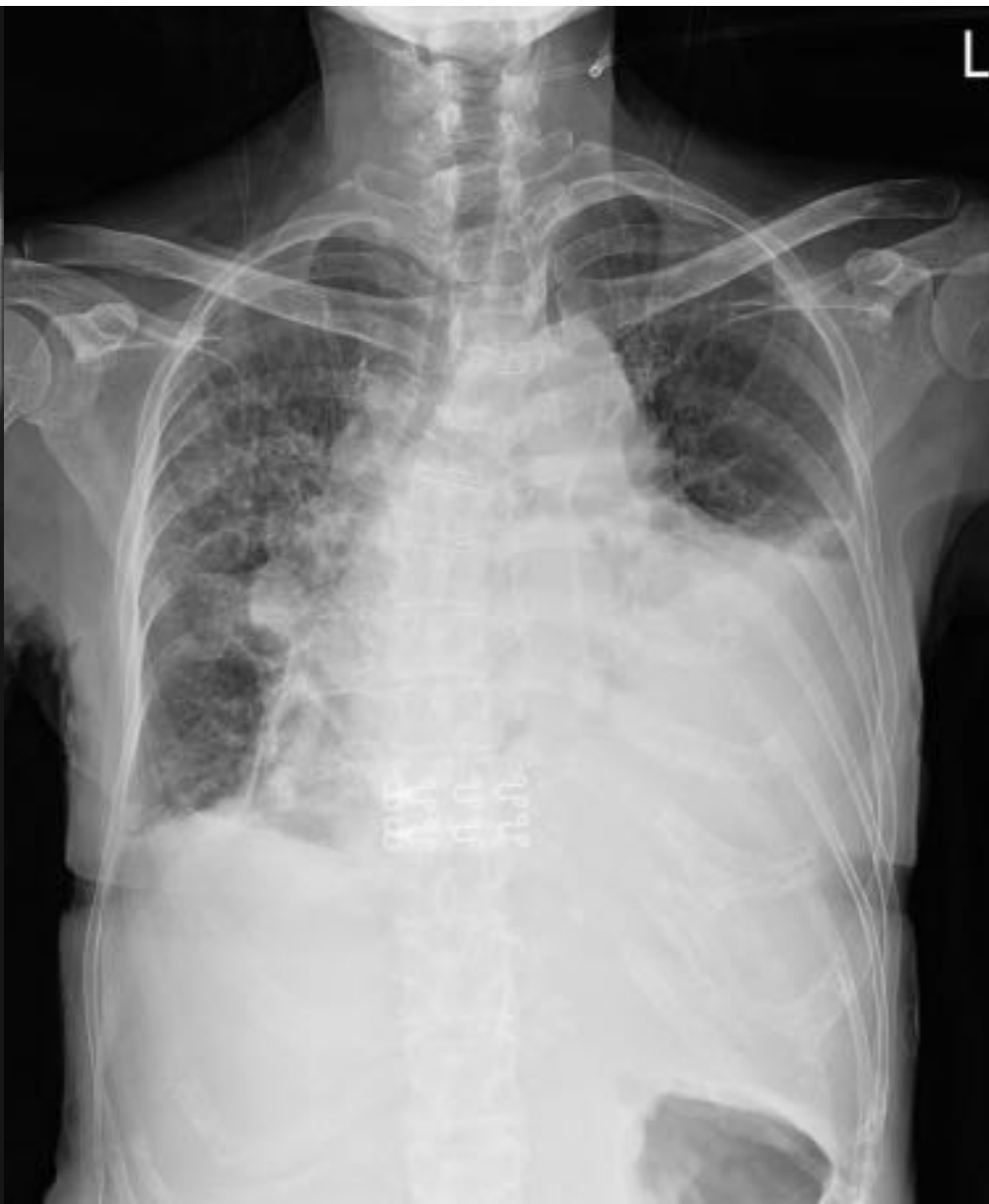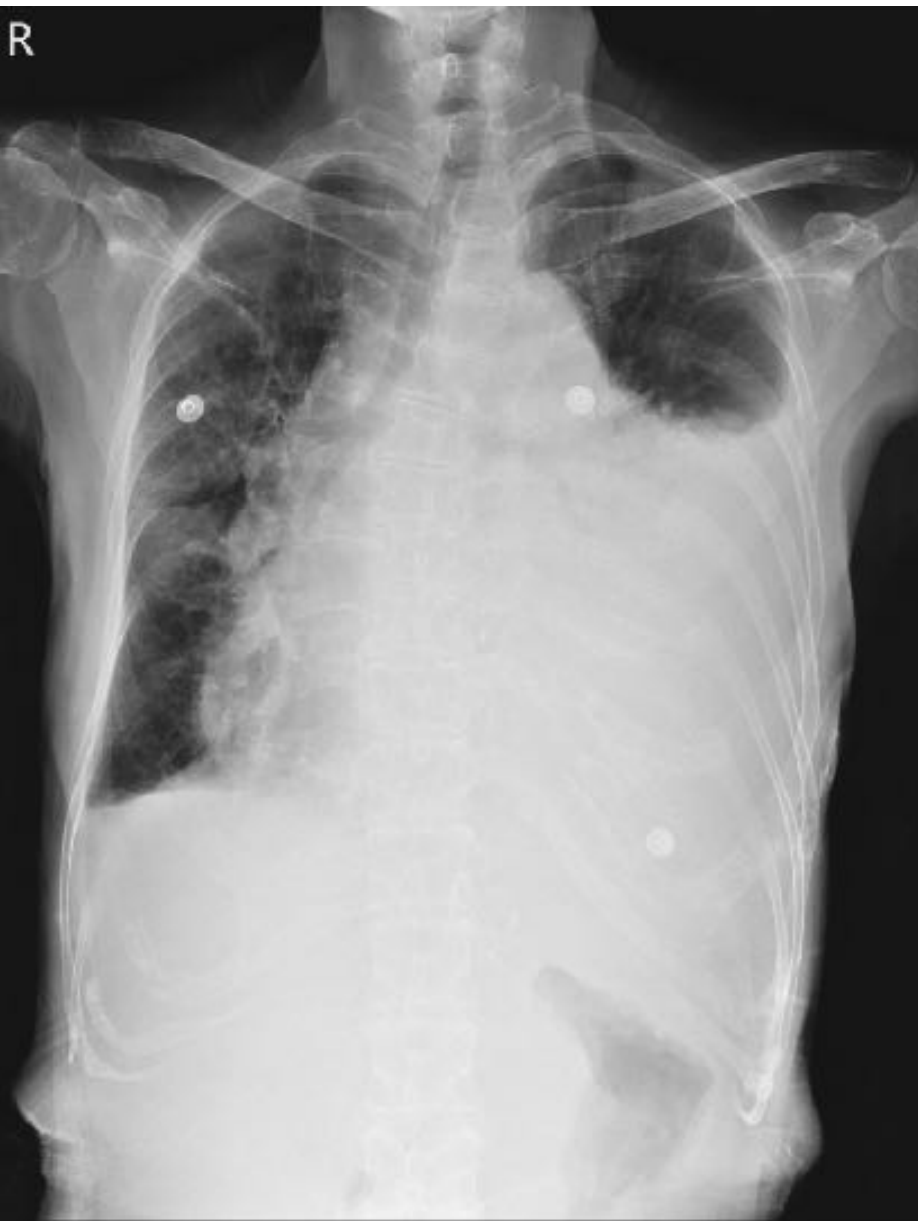Hx of breast cancer

4天前於急診進行
Pleural effusion
tapping 600 ml

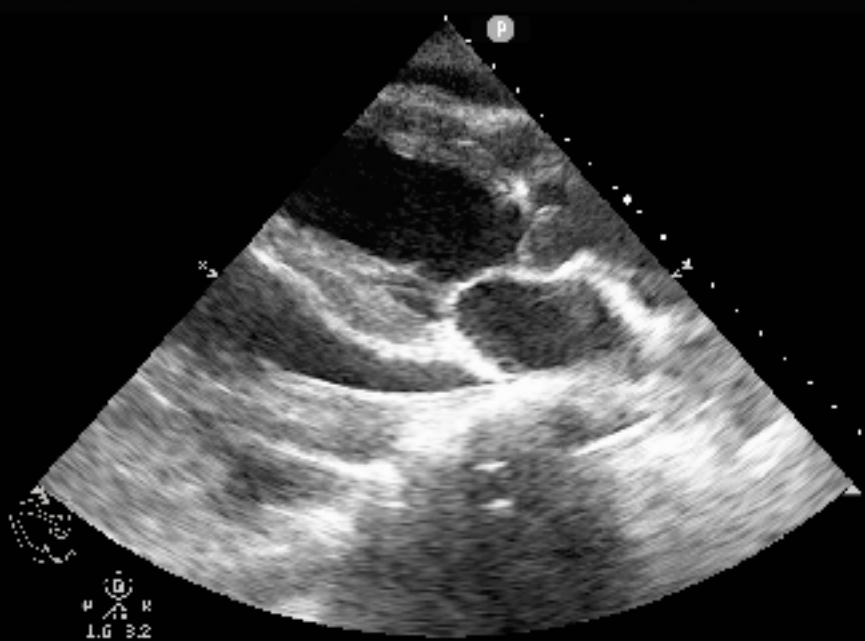
主訴:
呼吸困難 &
心博過速

4天前

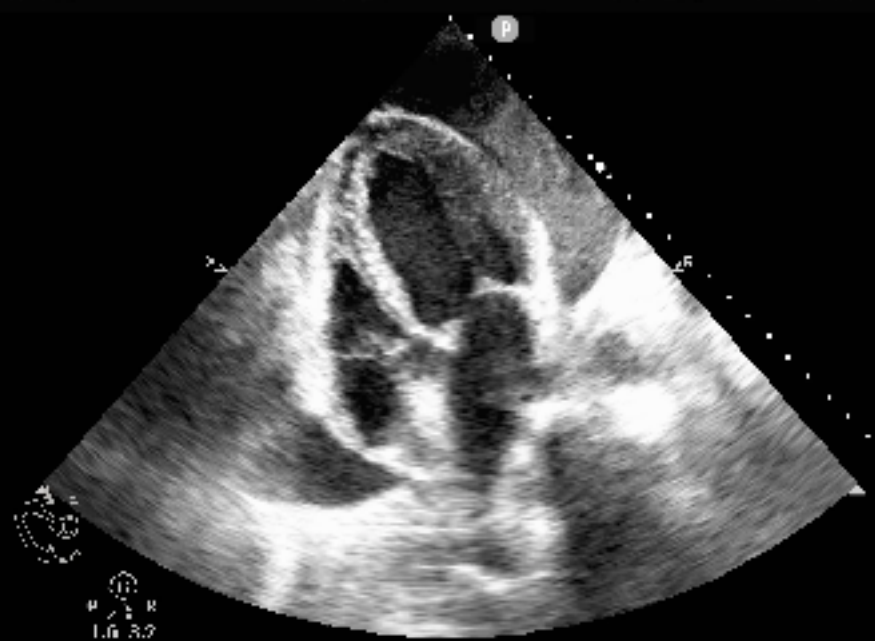就診日



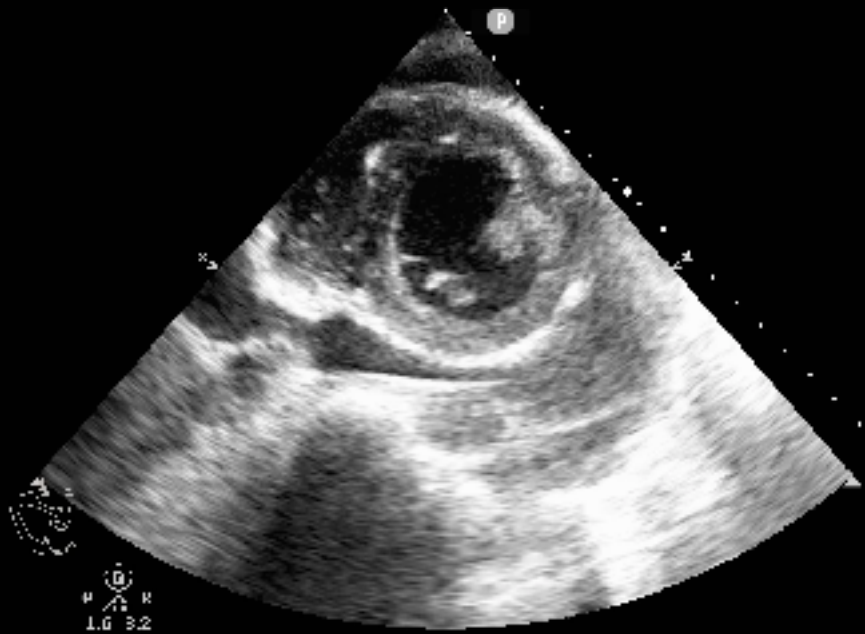cho



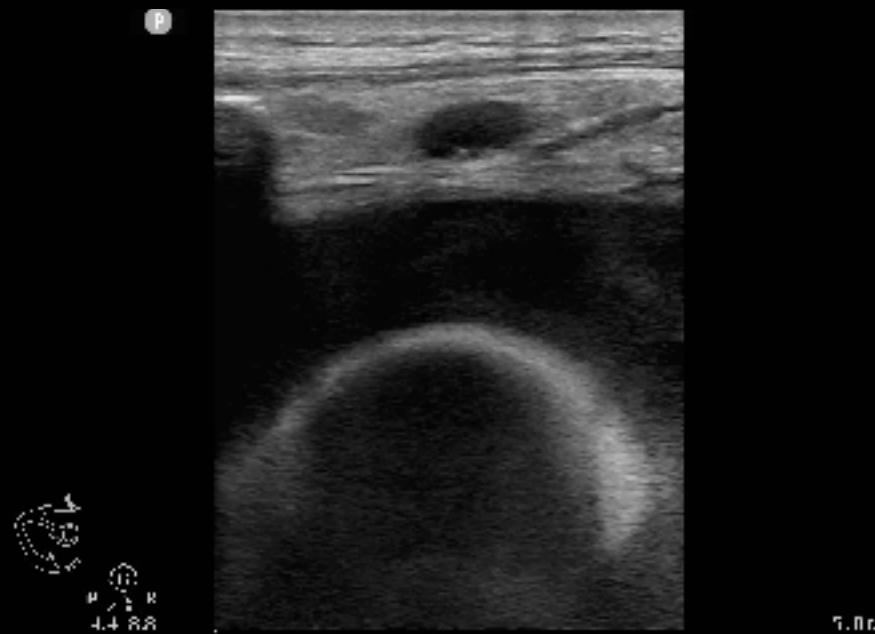
0



cho



0



5.0 cm

Step-by-step drainage

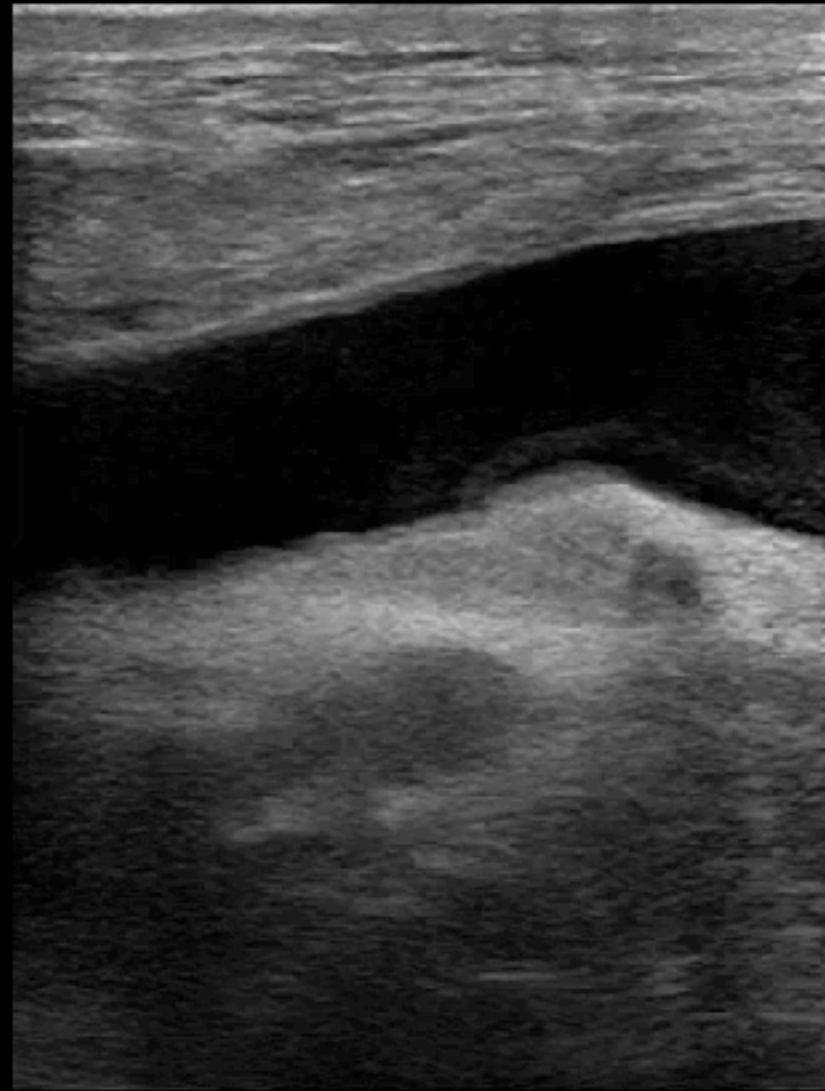
20187856

SKH ER

TIS 0.2 3:54:32 PM

Arterial
L12-3
34 Hz
5.0cm

P



2D

HGen
Gn 66
C. 41
3/3/2



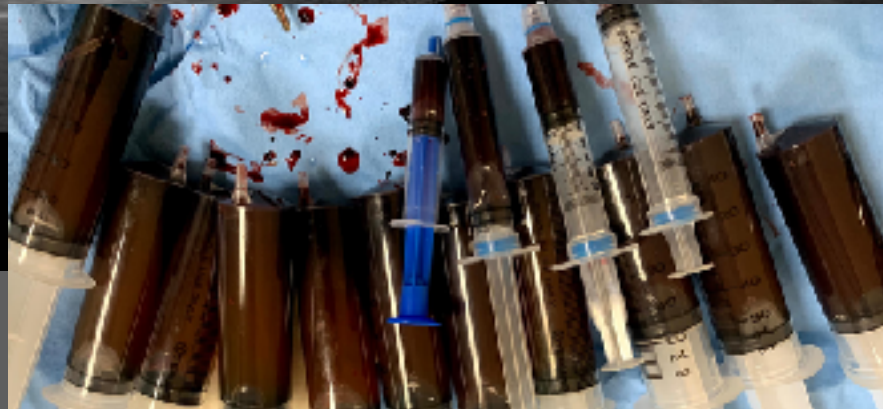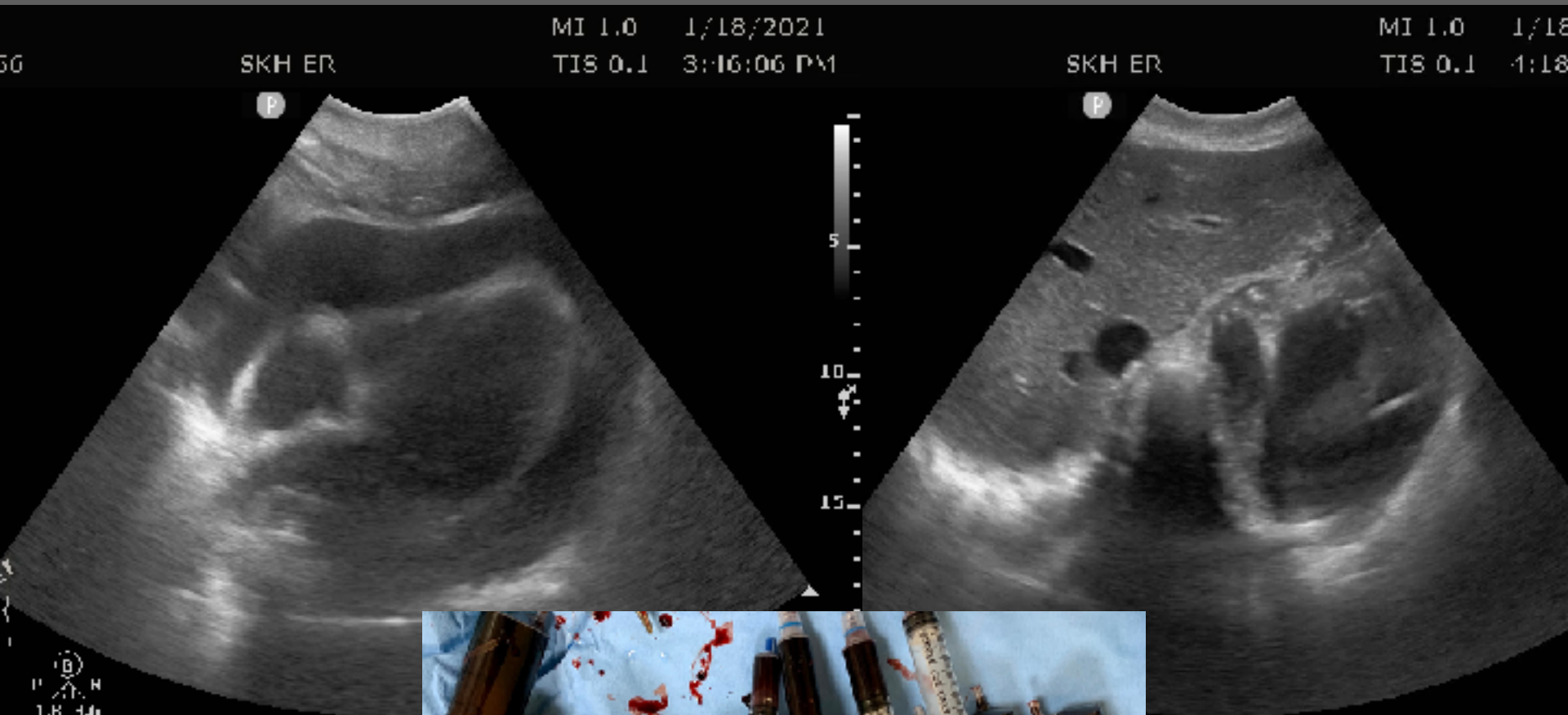
P
G
R
1.1 8.8

2

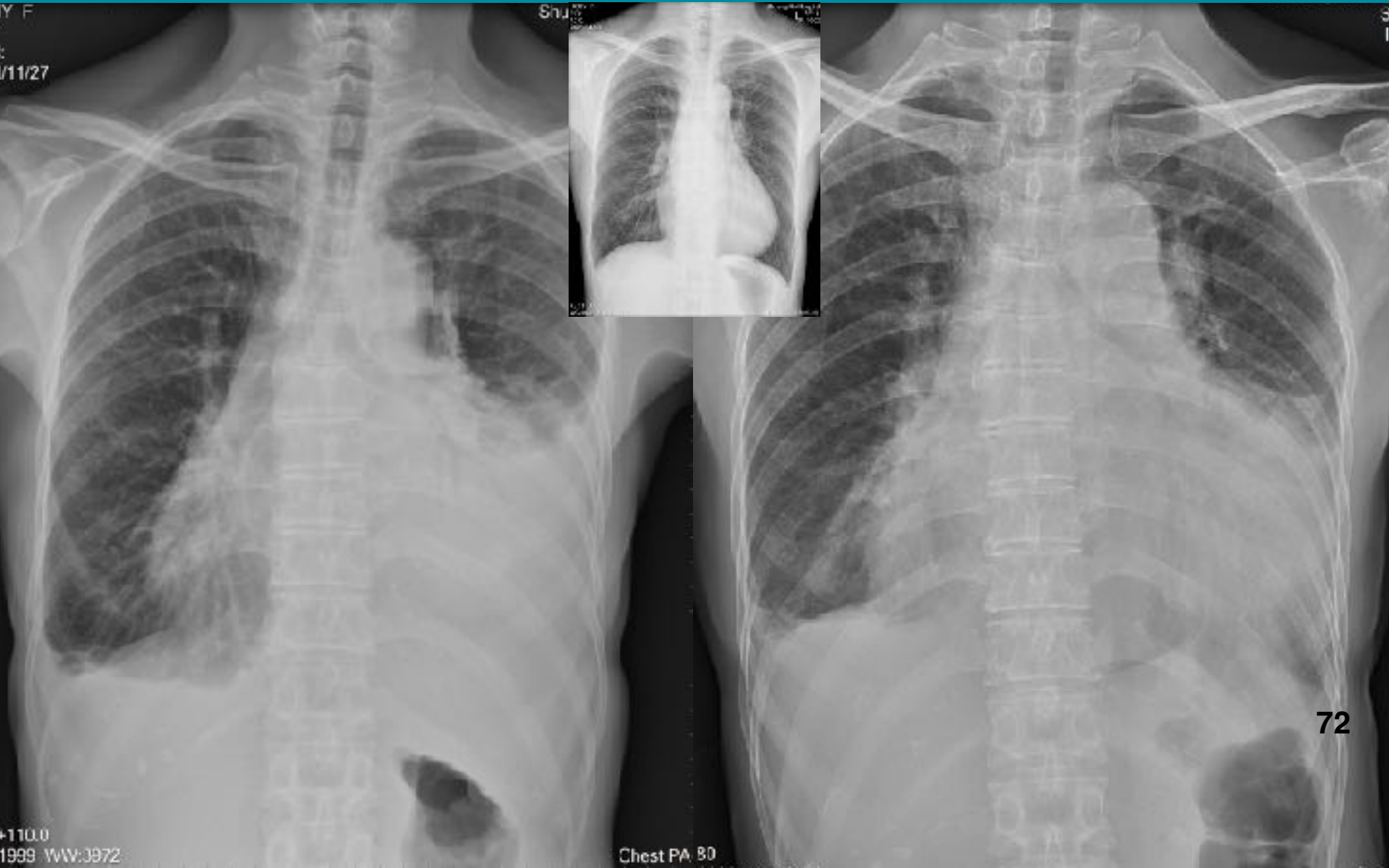1

5.0cm

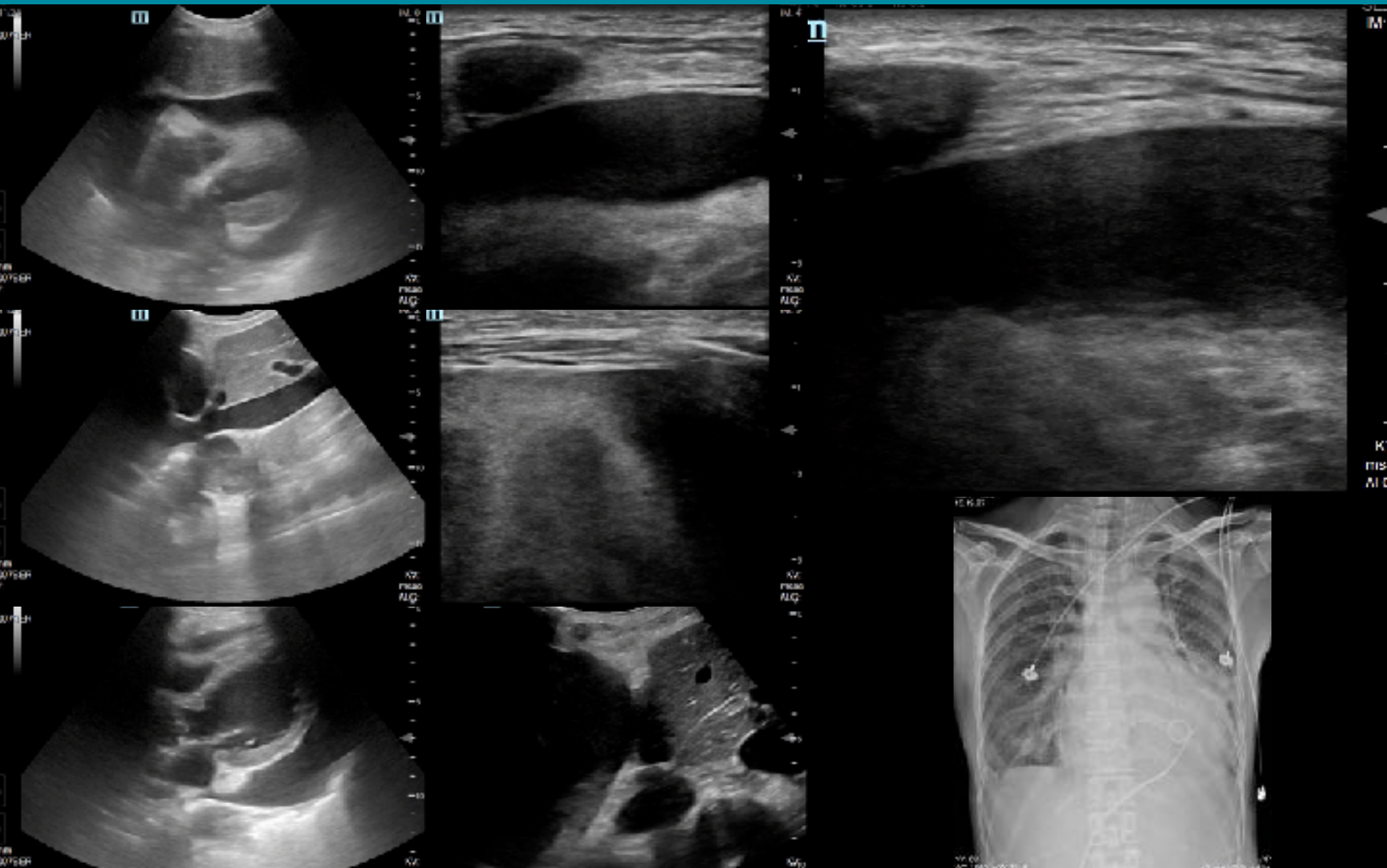
Monitor after drainage



64F, SOB 2wks, referred from OPD due to L PLE



Pigtail drainage - subcostal approach



77F, PN / CVA

檢傷

到院時間: 20240926 110802

檢傷級數: 2

意識狀態: E4_V5_M6

體重: 52Kg 體溫: 37.1°C

脈搏: 95 呼吸次數: 20

血壓: 147/90

SP02: 97

到院方式:

過敏史: 無

主述: 樂生醫院AAD, 因肺炎, 右上肢無力(9/20)住院, MRI/CVA, 表示認識張志誠醫師而轉入, 已告知急診無

TOCC:

診斷

代碼

I18.9

I63.9

I31.4

C34.00

檢驗、檢查、放射

類別	日期
檢查	1130926_11325
檢查	1130926_11123
檢查	1130926_12083
檢查	1130926_13005
檢驗	1130926_11123

處置、衛材、敘述

類別	日期
處置	1130926_11123
處置	1130926_11123
處置	1130926_13005

○ 新增

● 1130926 1

存成範本

Chief Complaints

cough for days

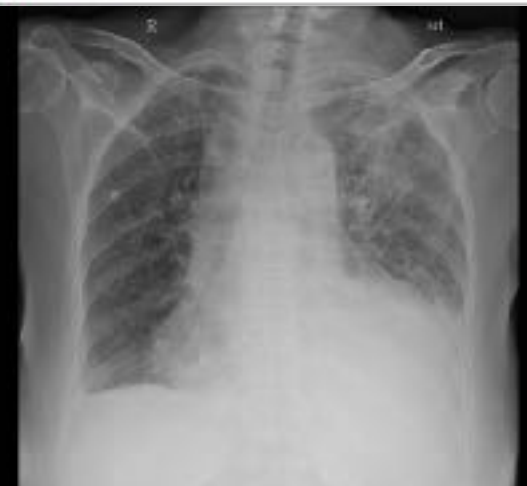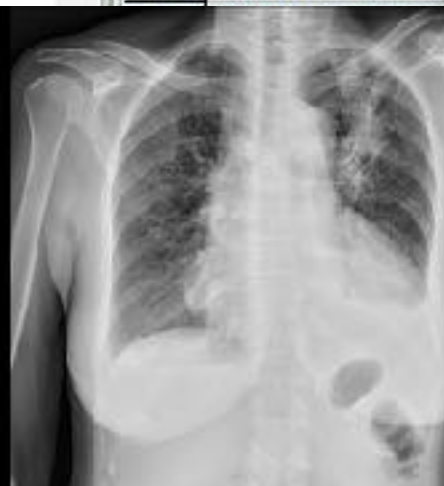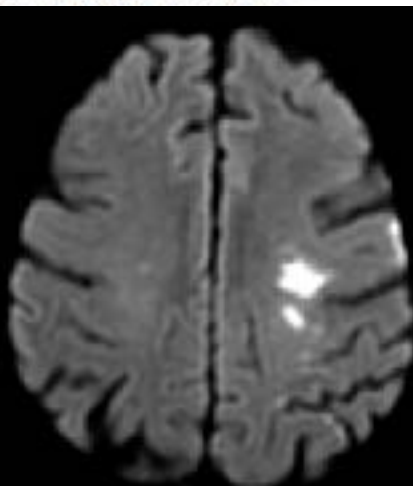
left upper arm weakness since last Friday

Present Illness

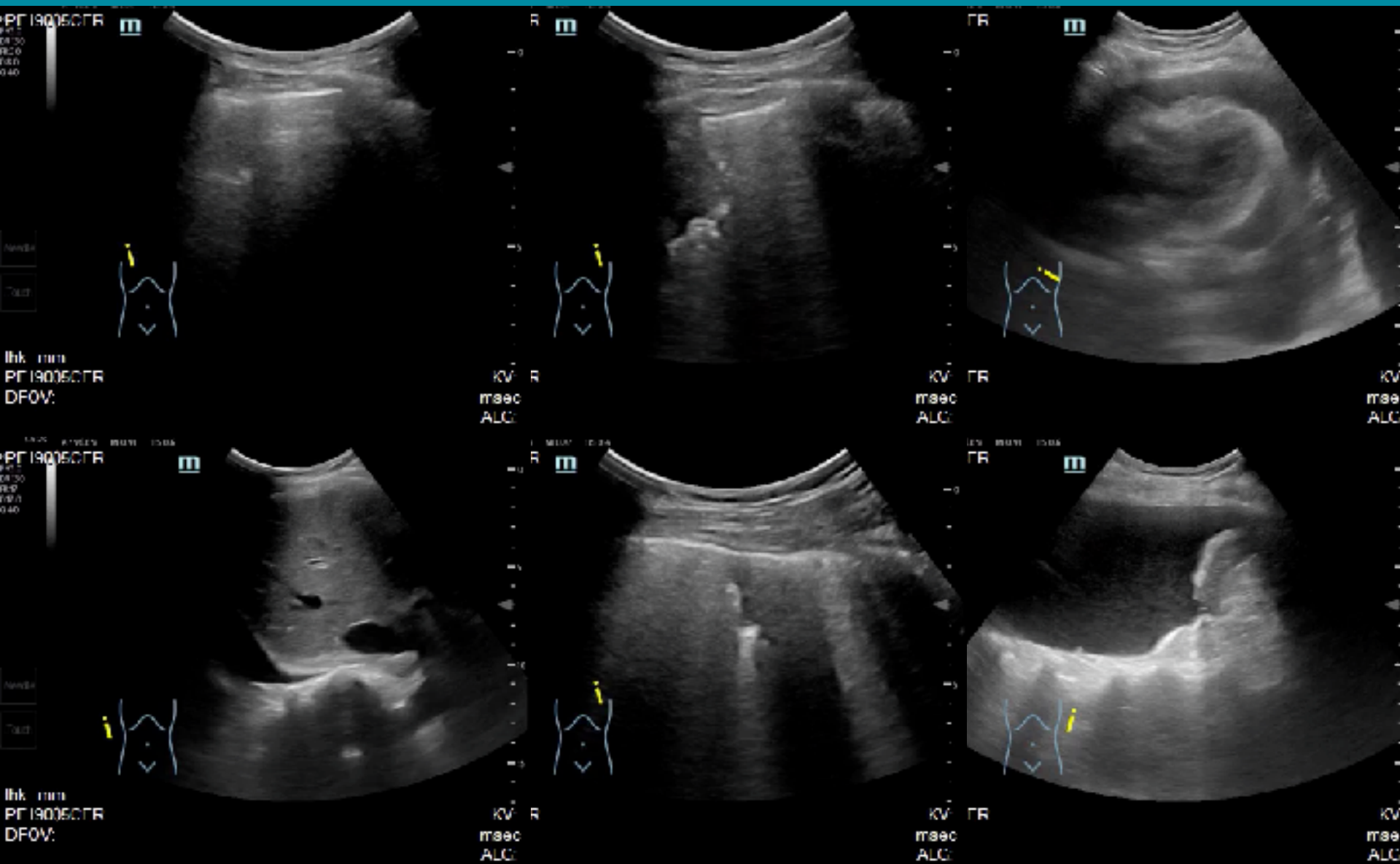
treat at 樂生醫院

- left upper lung pneumonia

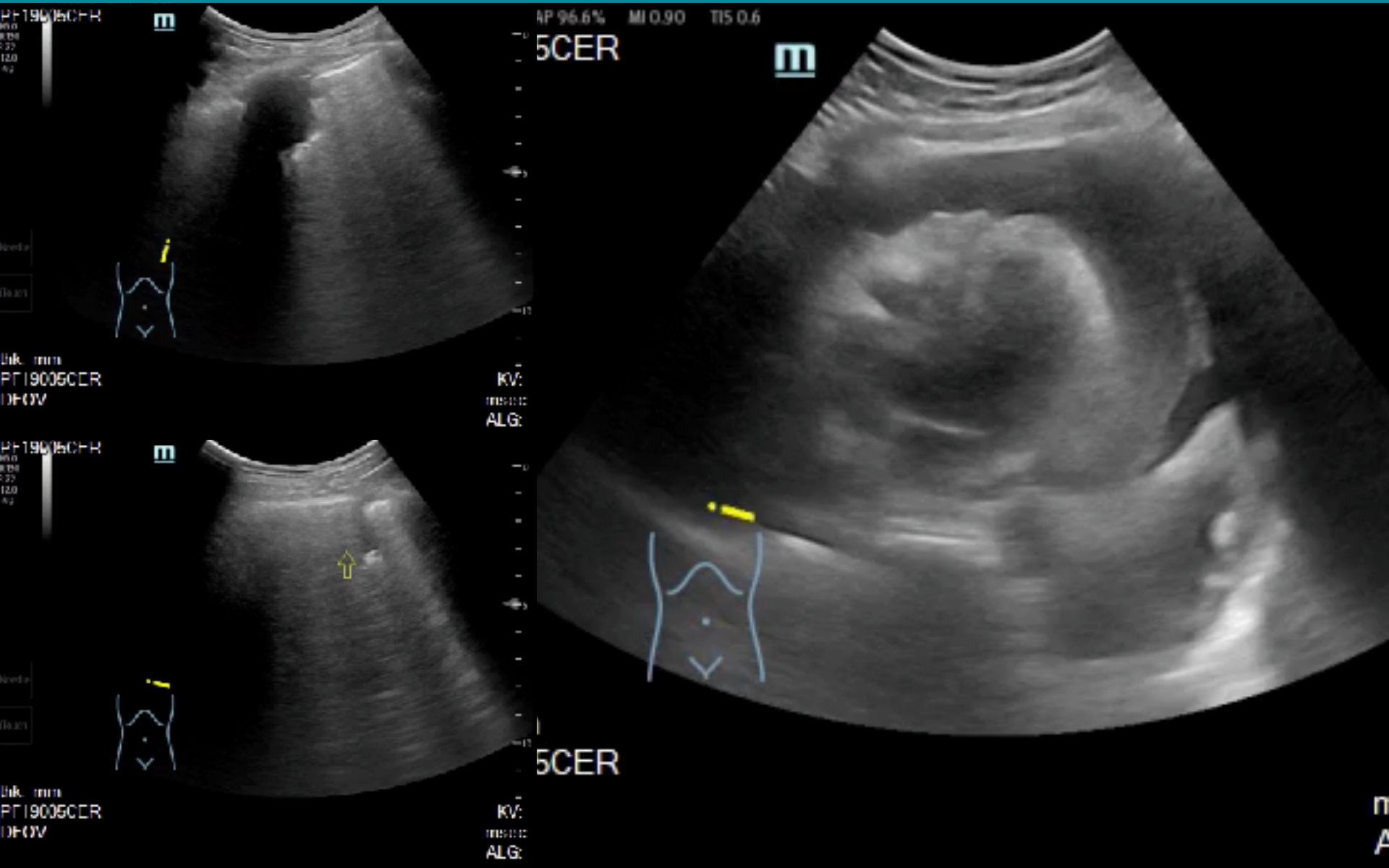
- CVA with right side weakness



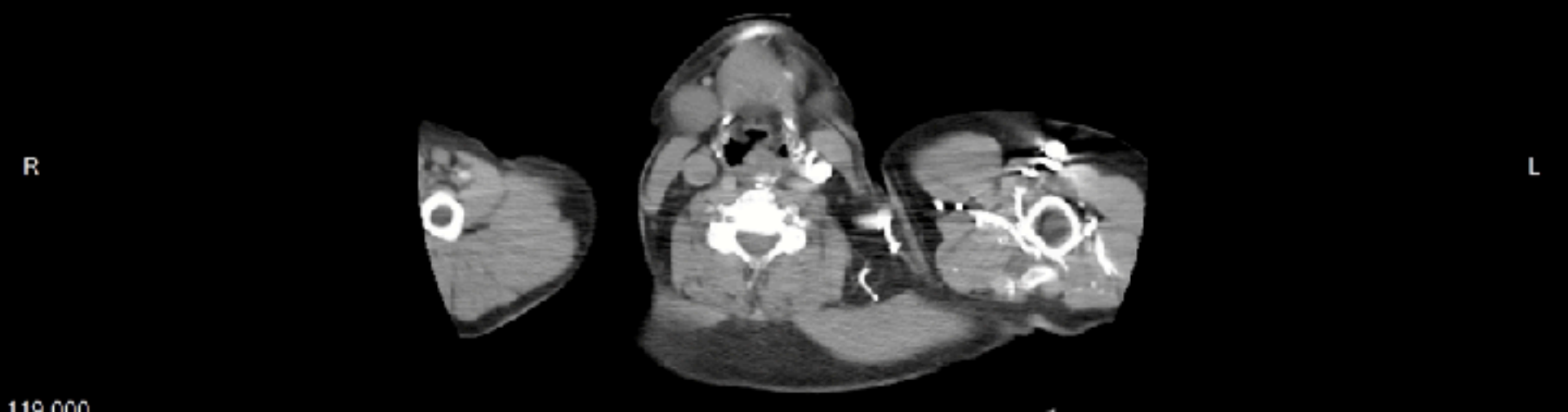
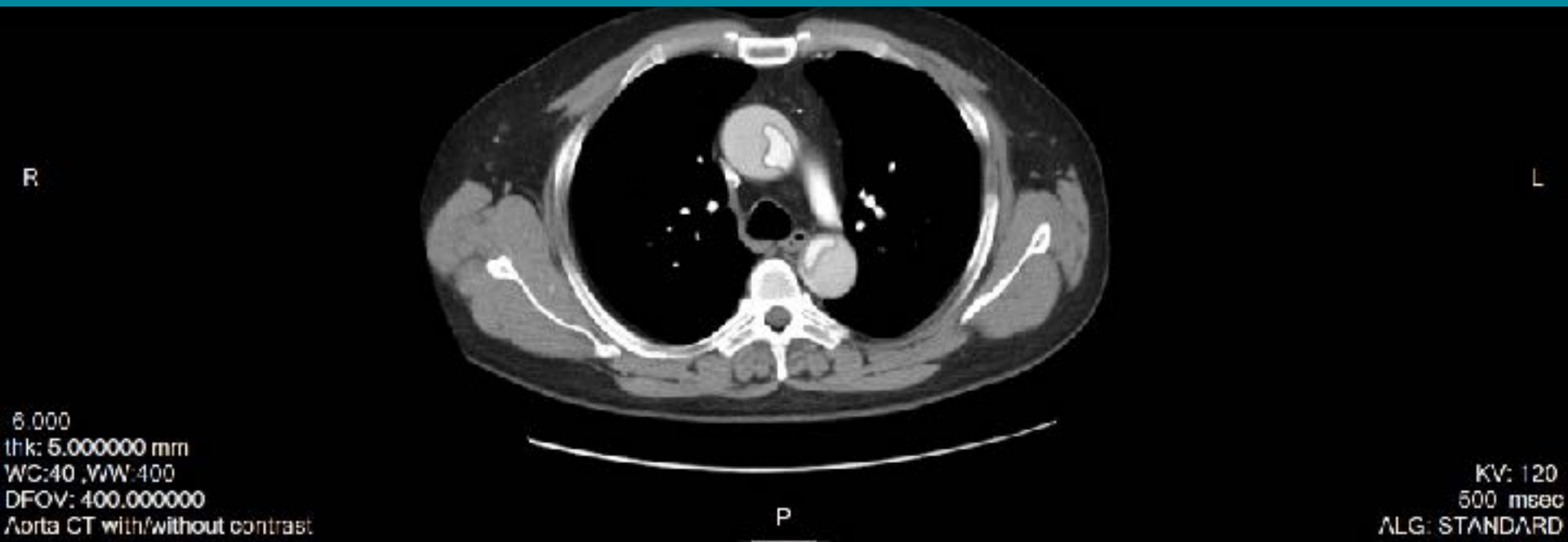
POCUS



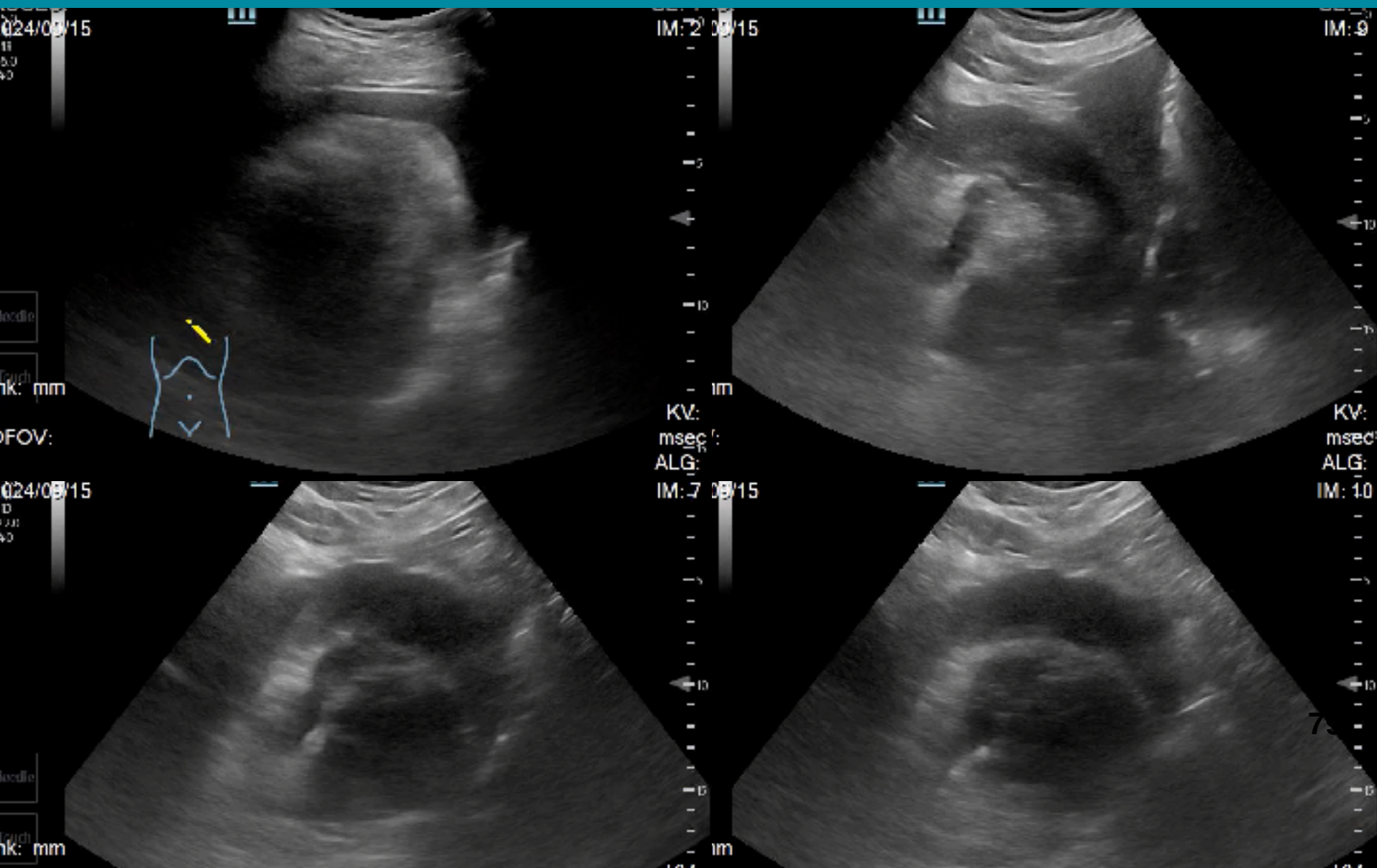
Favor lung cancer with PLE/ PE



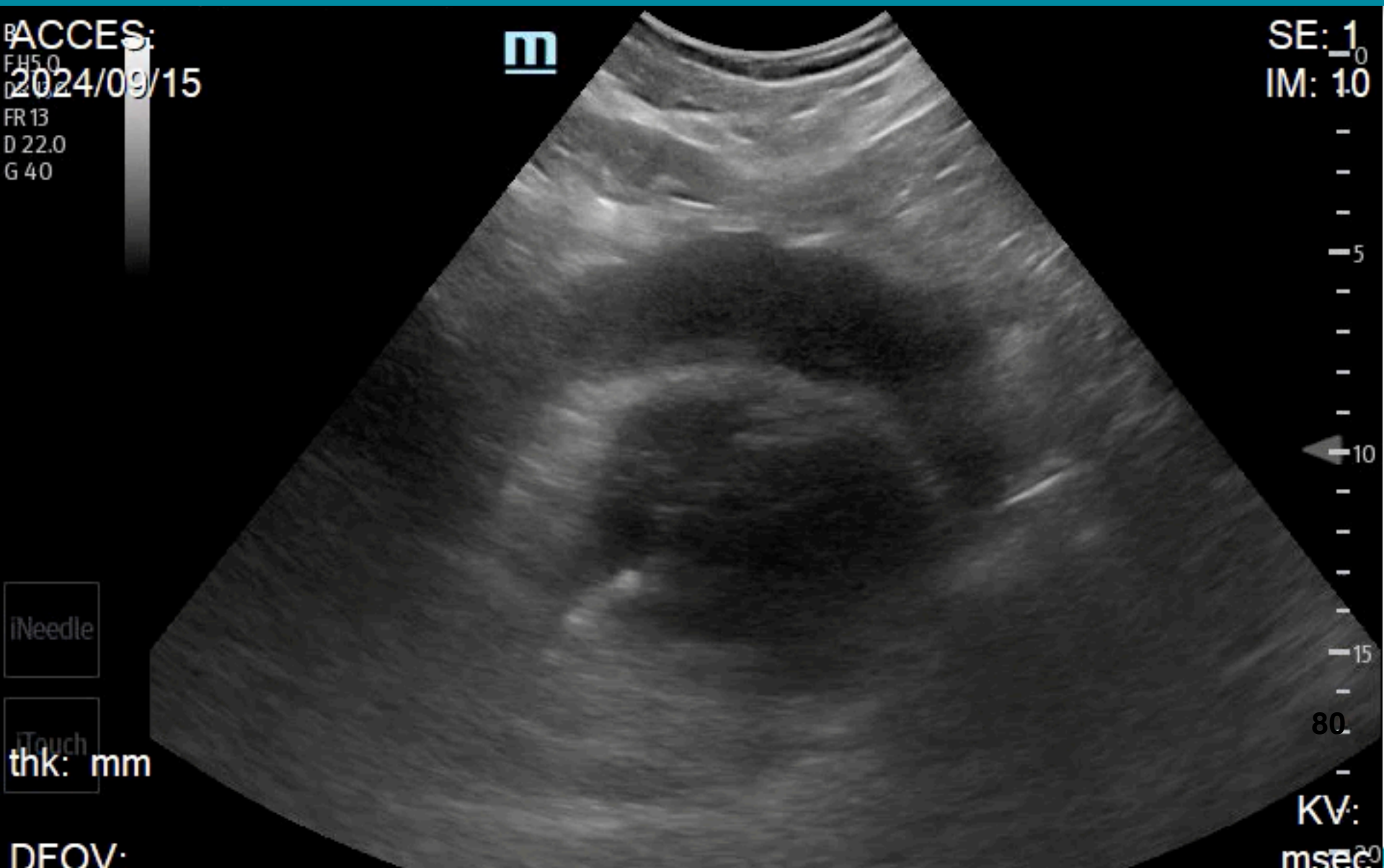
AD, type A, 宏仁轉入，Pulseless



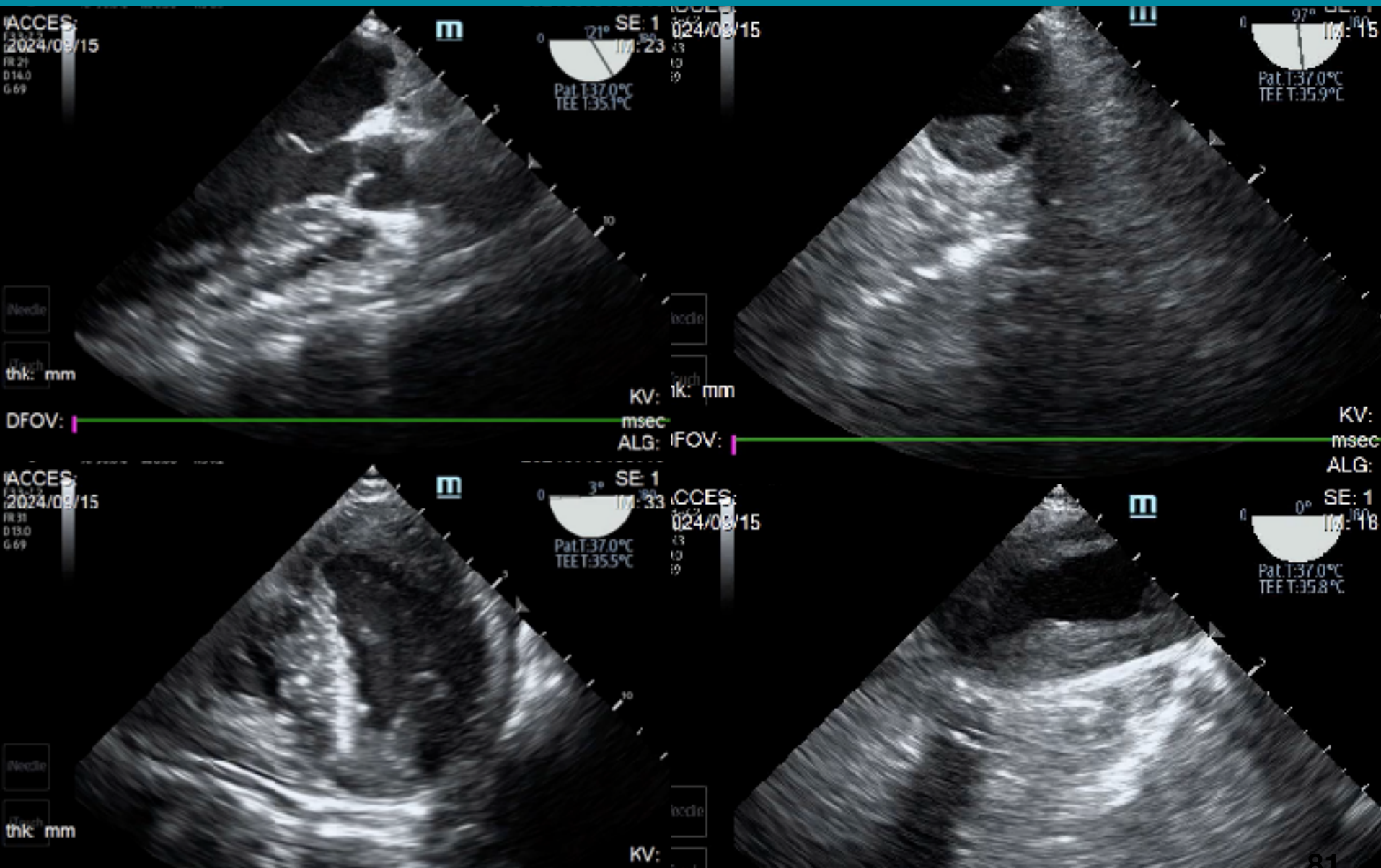
Hemopericardium



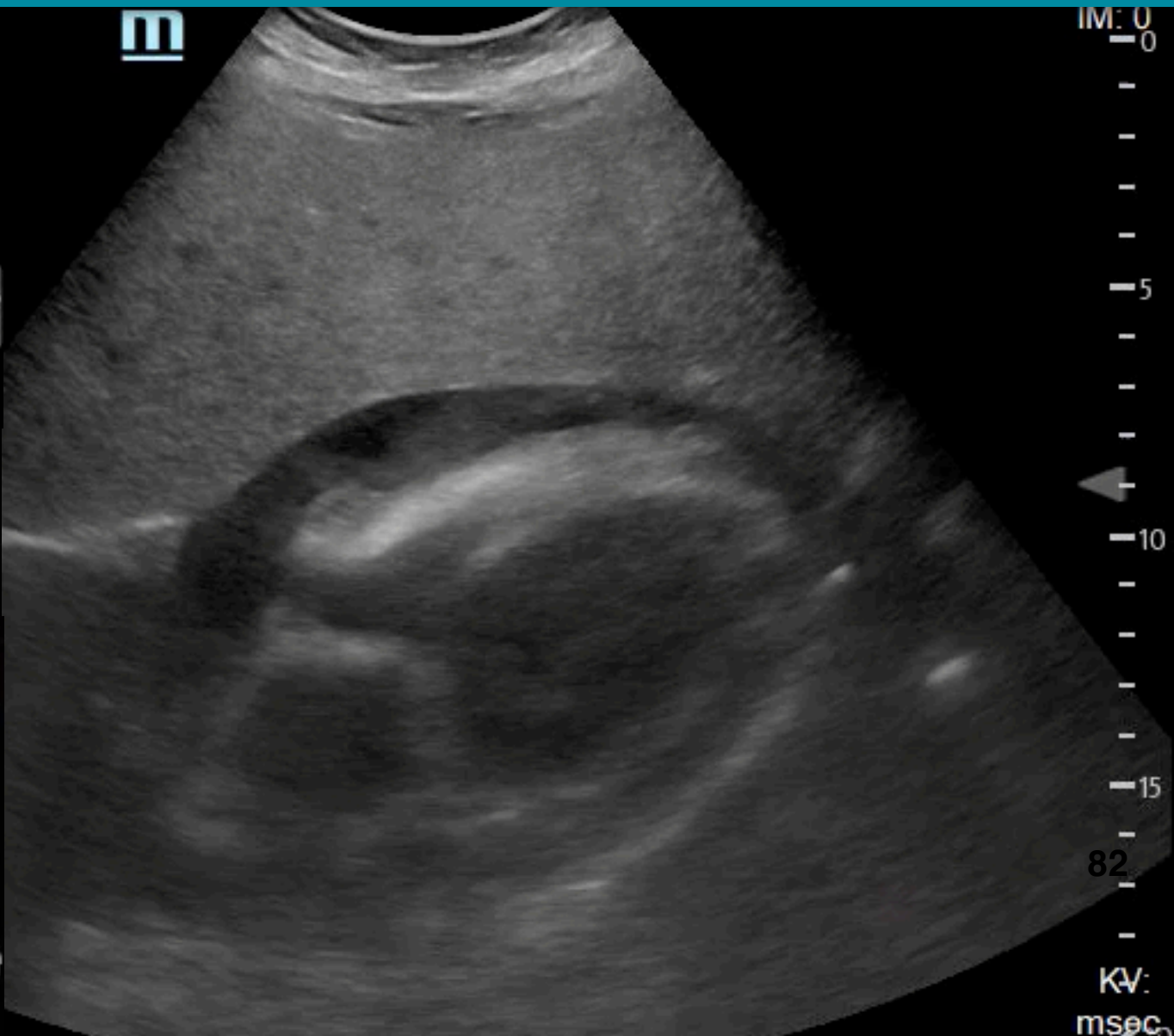
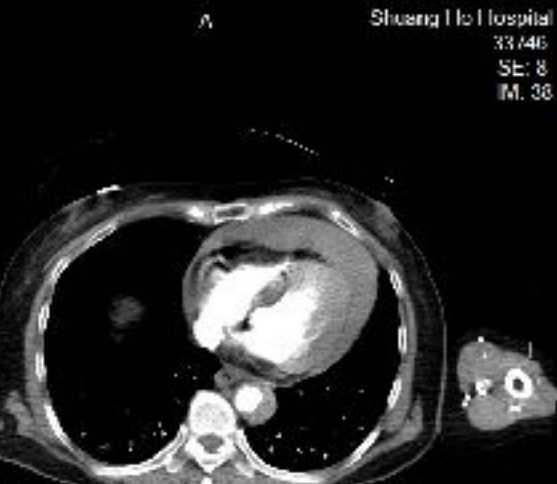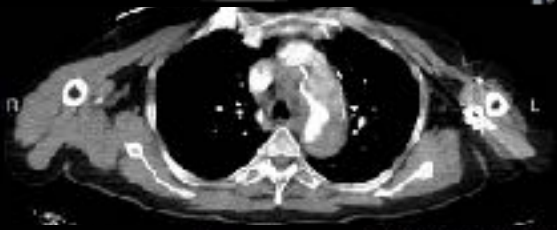
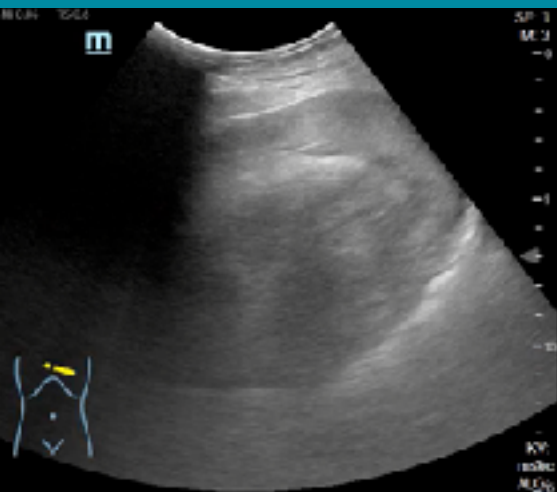
Pericardial window



Resuscitation monitoring

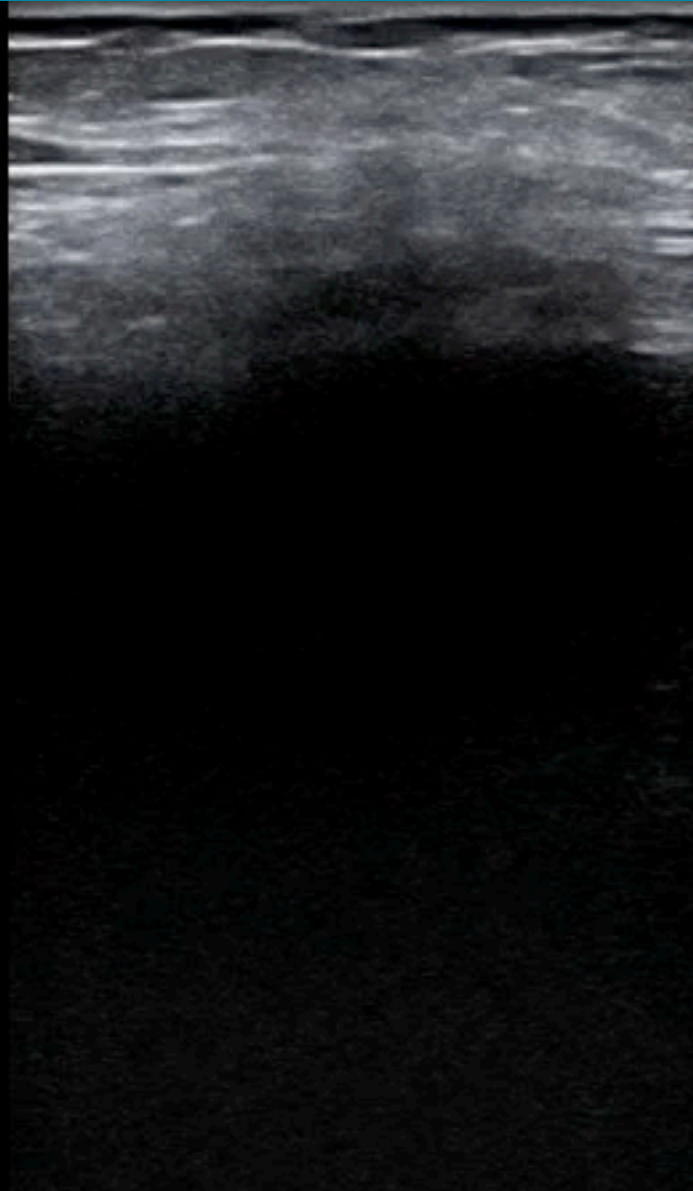


64M, 頭暈後倒地, GCS 3, BP 78/52 mmHg



14Fr pigtail with stylet (parasternal approach)

2024/11/27
FH10.0
DR 95
FR 21
D 7.0
G 40



IM: 0



iNeedle

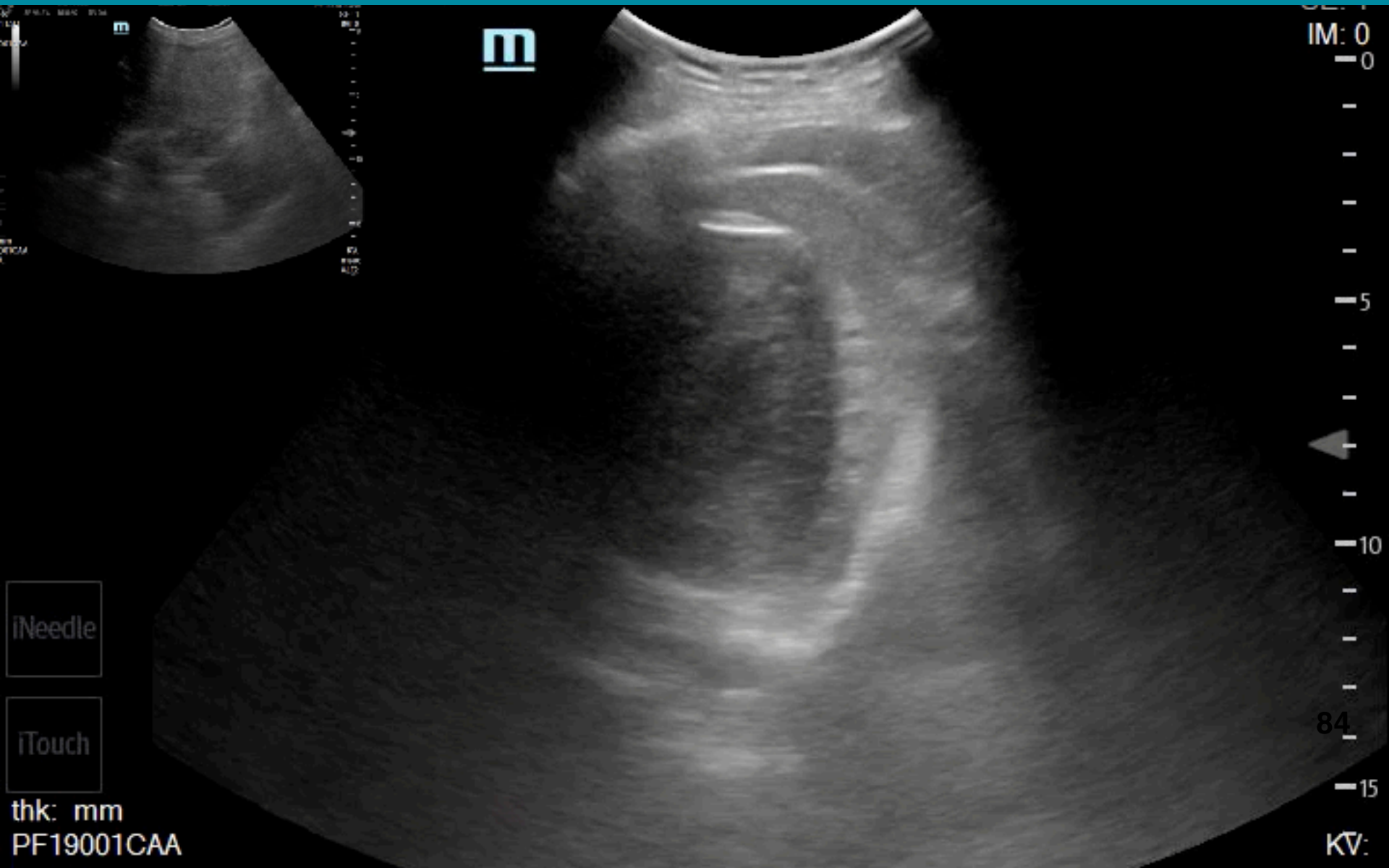
iTouch

thk: mm

DEOV:

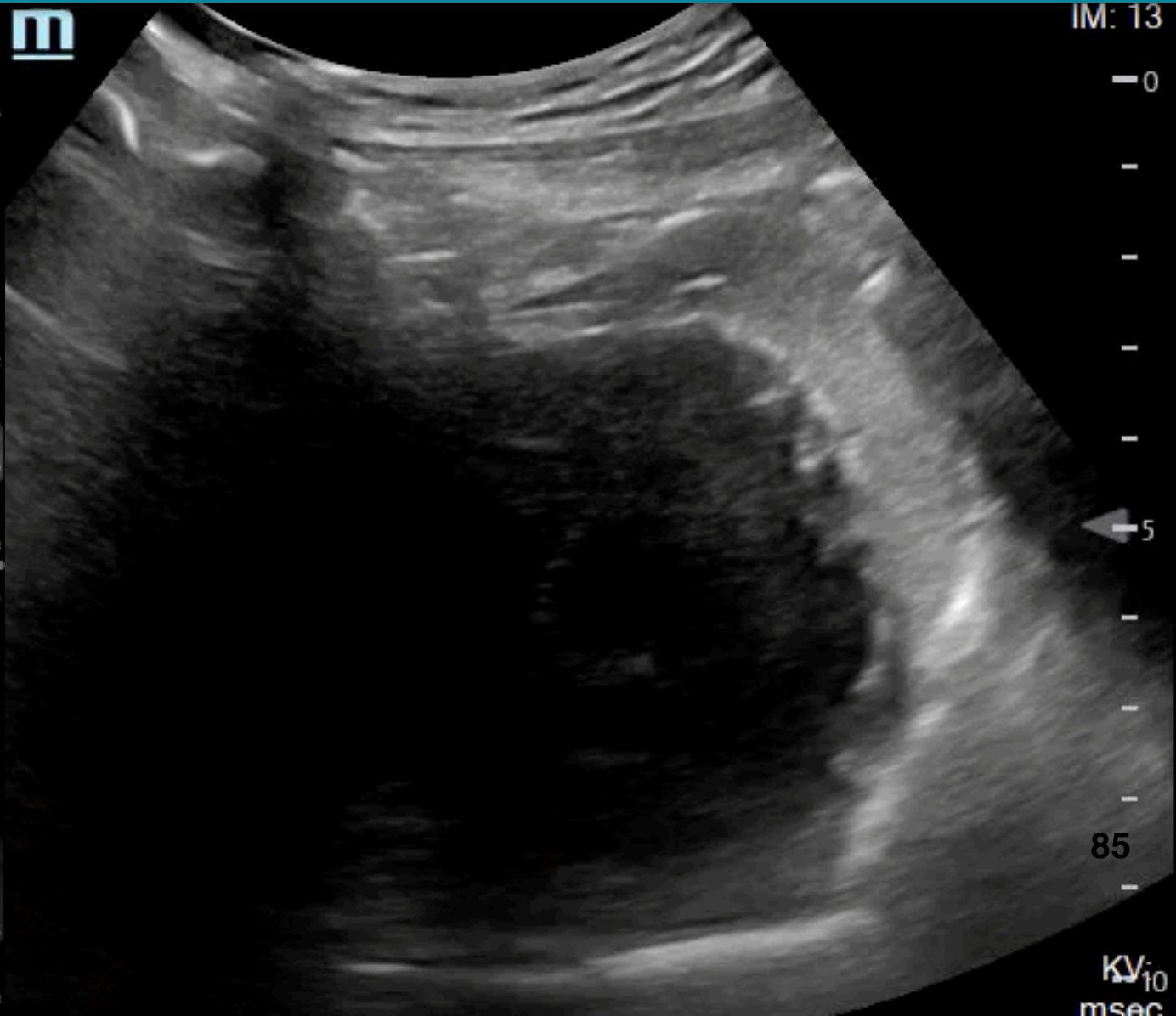
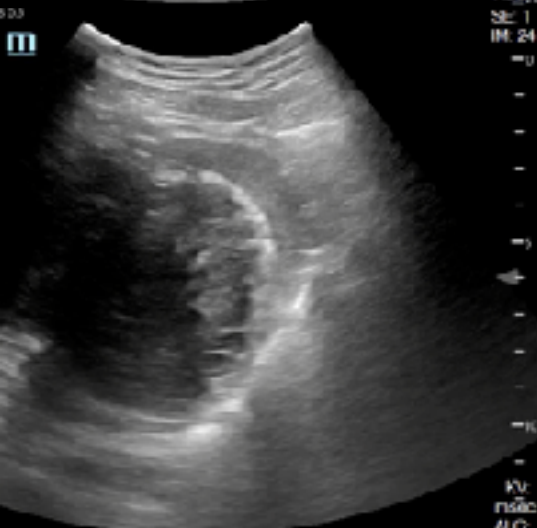
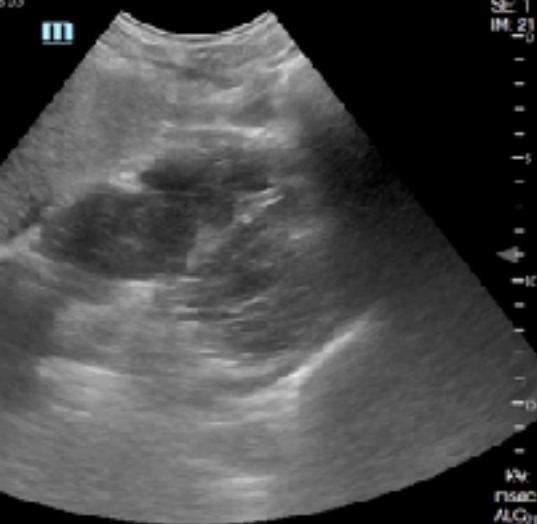
KV:

Trauma arrest



Pigtail with stylet, 14Fr (R3 Lin)

2024/11/27
FH5.0
ND 130
HP 1AW
AL Tran
Acut ABD
2024-11-27
18:349



IM: 13

0

5

85

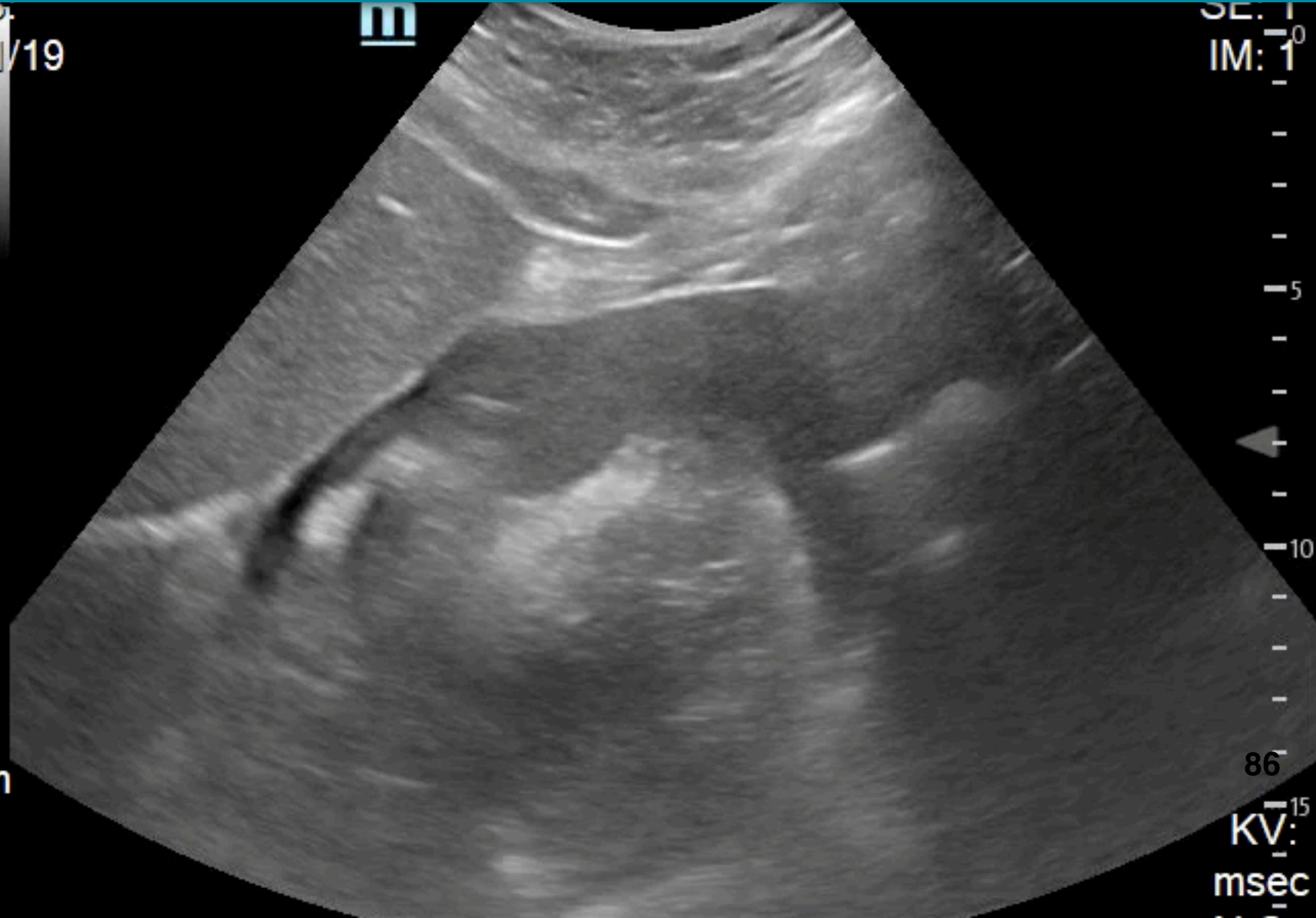
KV: 10
msec

61F, Chest pain 2D, visited OPD collapsed at X-ray, IHCA

ACCESS:
FH5.0
2024/11/19
FR 16
D 18.0
G 58



SE: 1
IM: 1



5

10

86

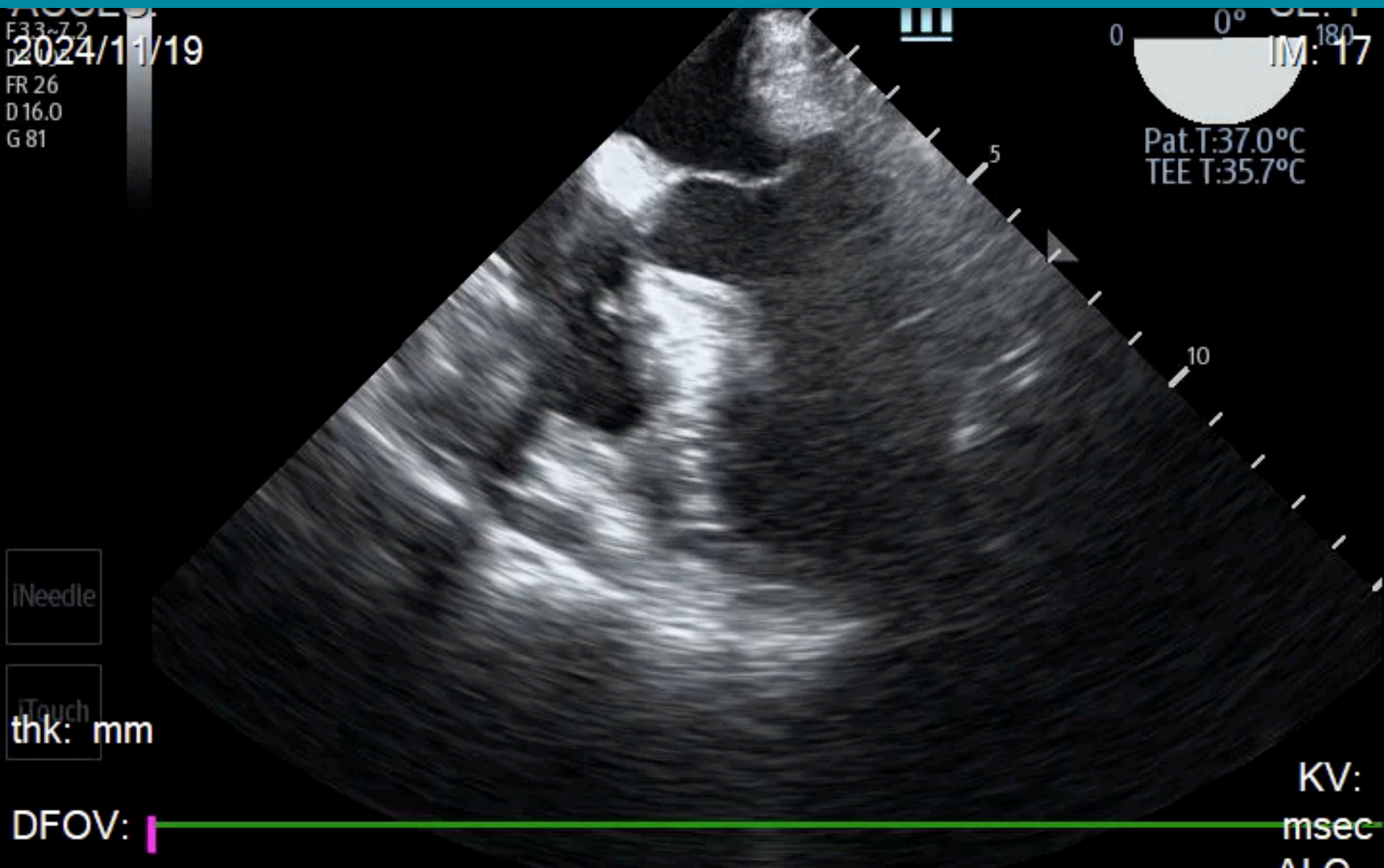
KV: 15
msec

iNeedle

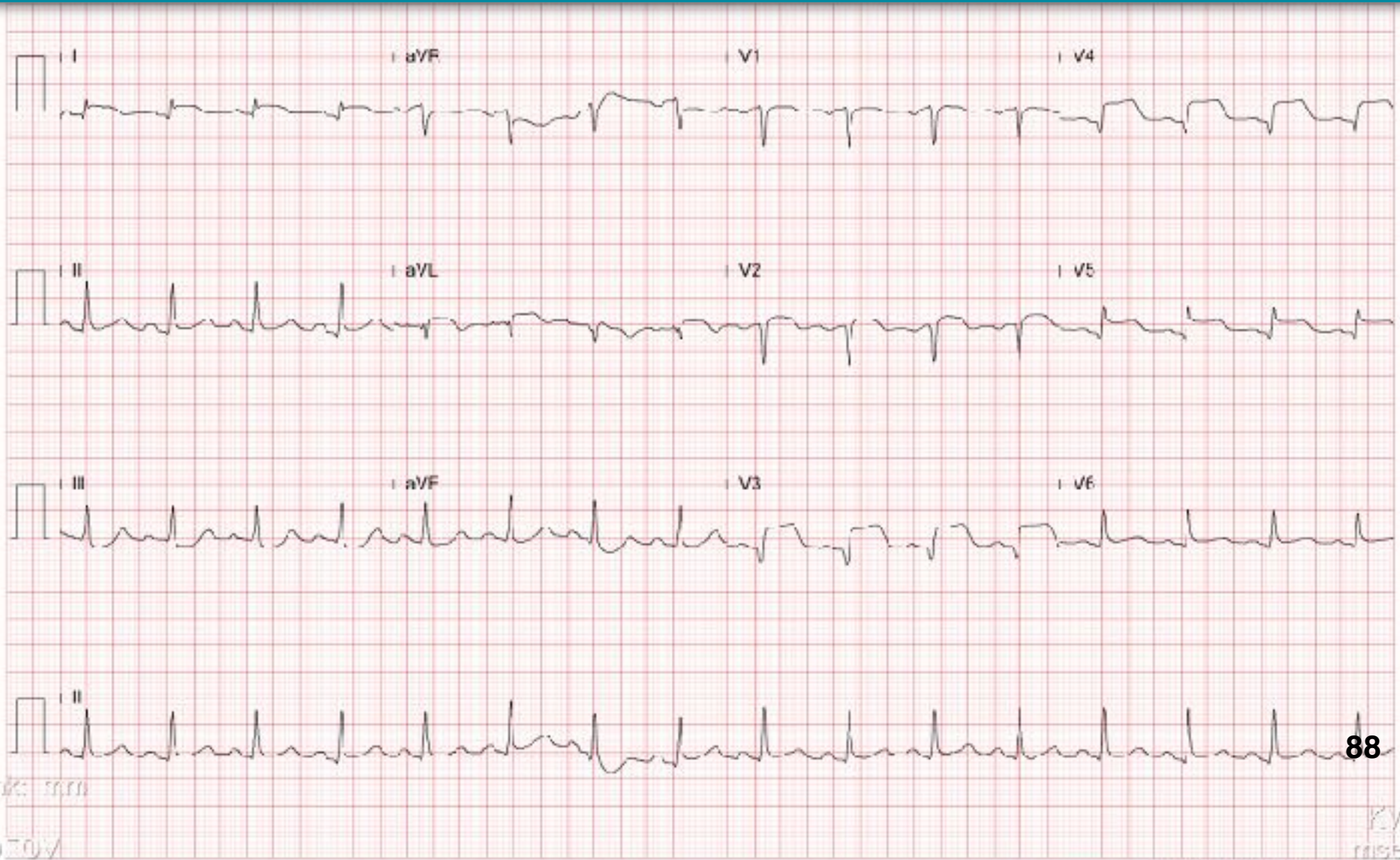
iTouch
thk: mm

DFOV:

Pericardial widow then chest tube drainage



STE

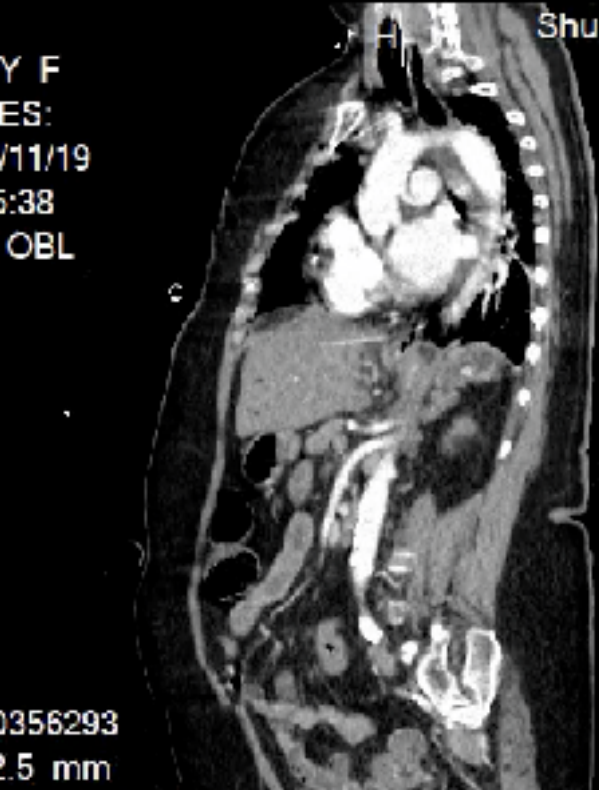
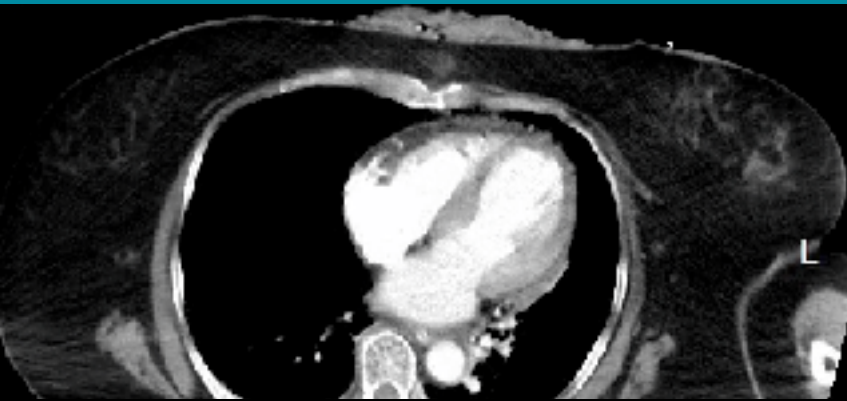


88

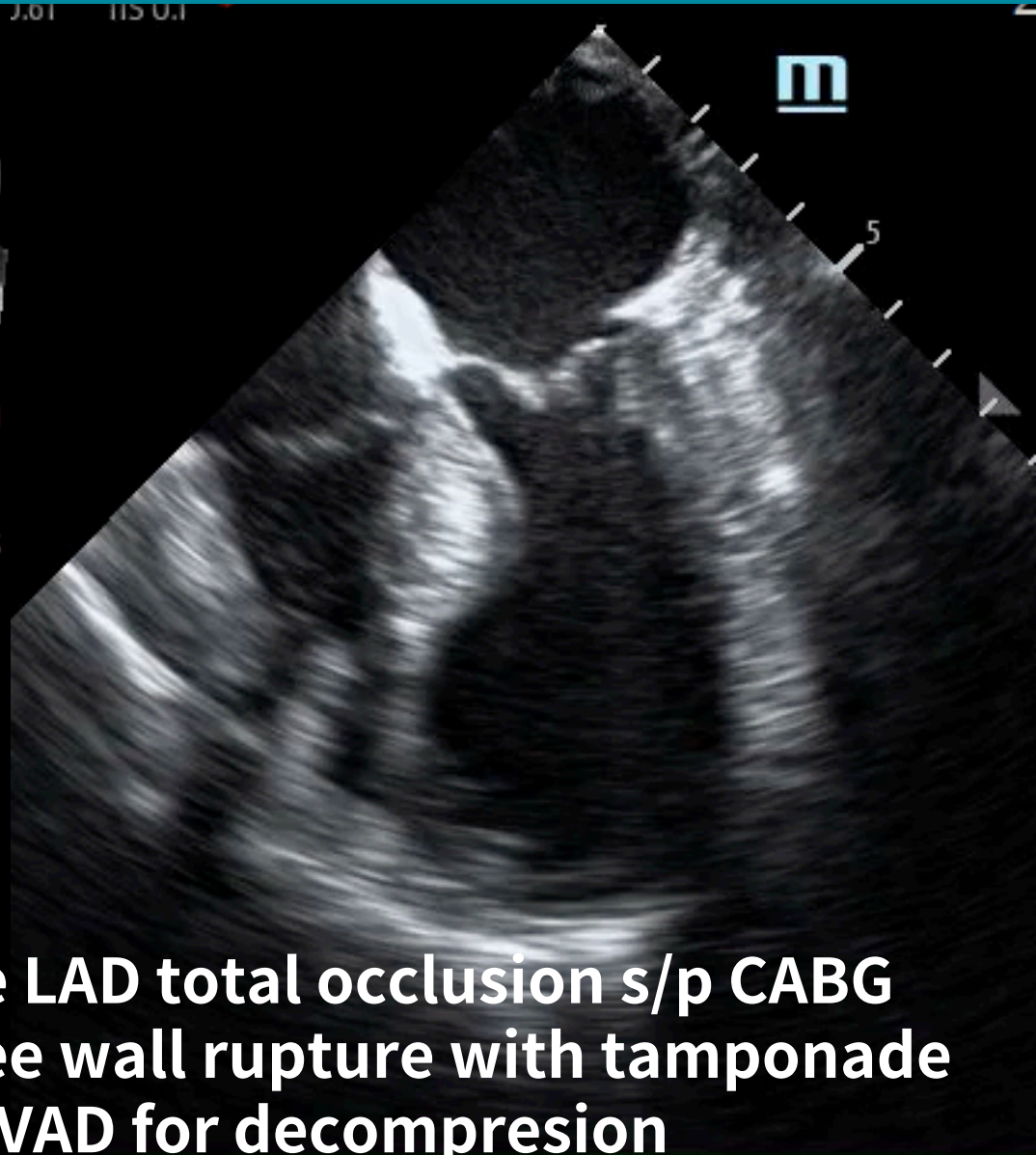
thru: rrrrr
D.T.O.V

25mm/s 10mm/mV 0.5-10Hz
KY:
r1526
ALG:

Troponin-I 19412



Shuang Ho Hospital
33075
SE: 402
IM: 46



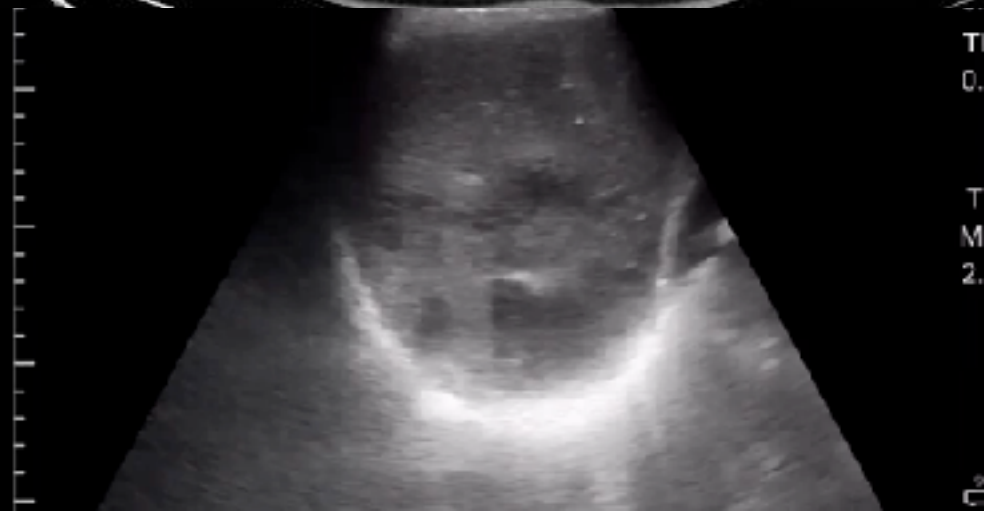
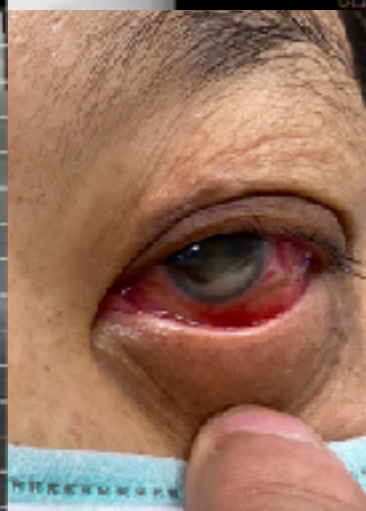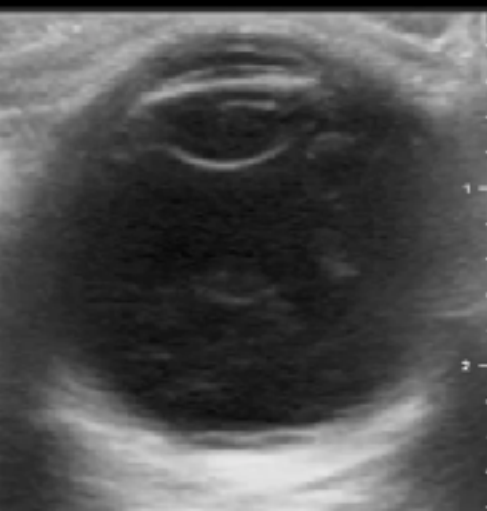
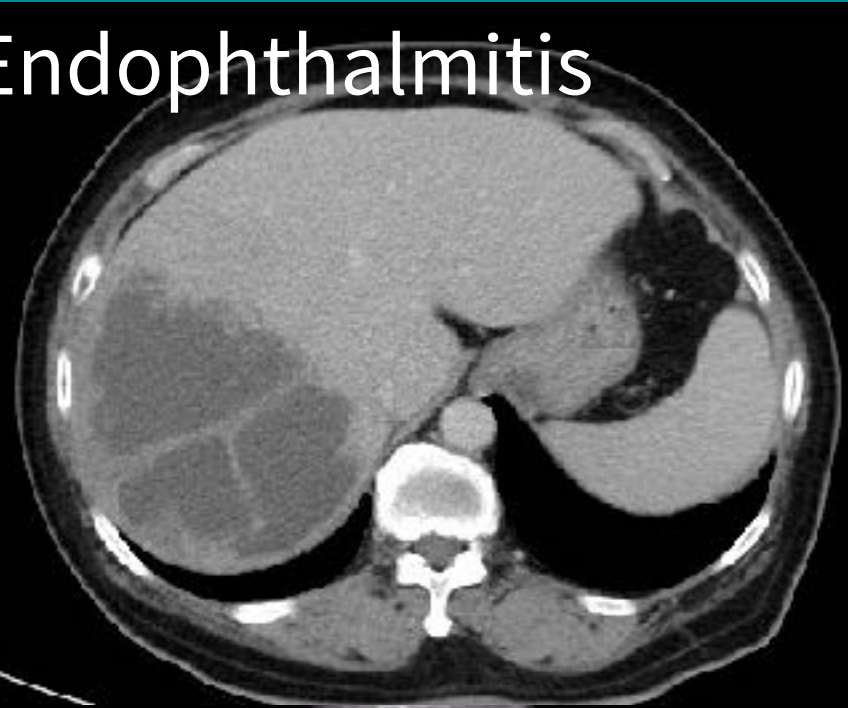
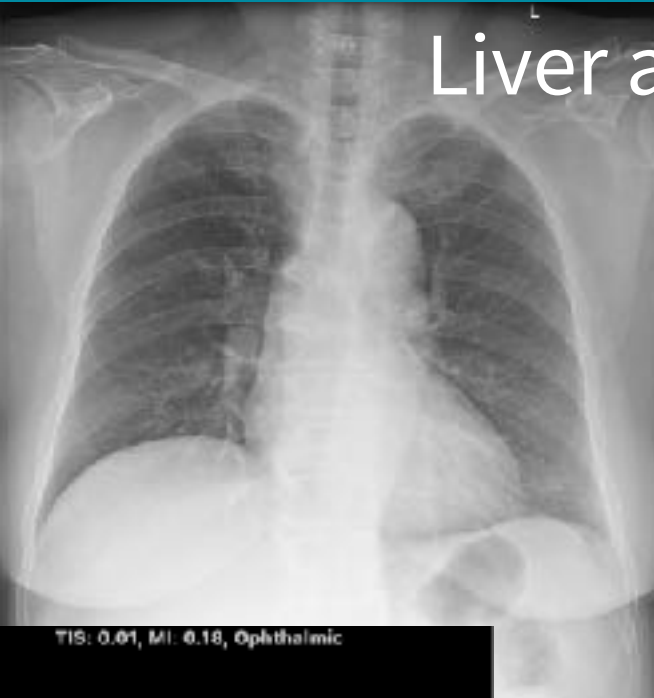三總

Acute LAD total occlusion s/p CABG
LV free wall rupture with tamponade
On L-VAD for decompression

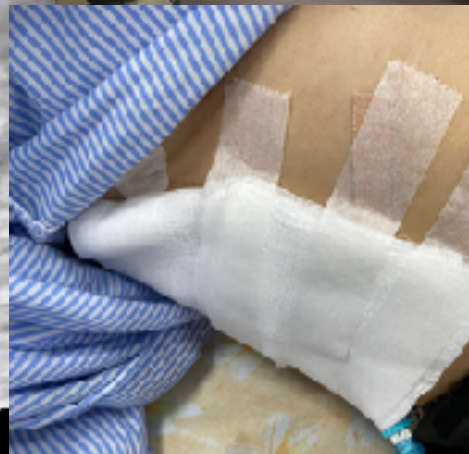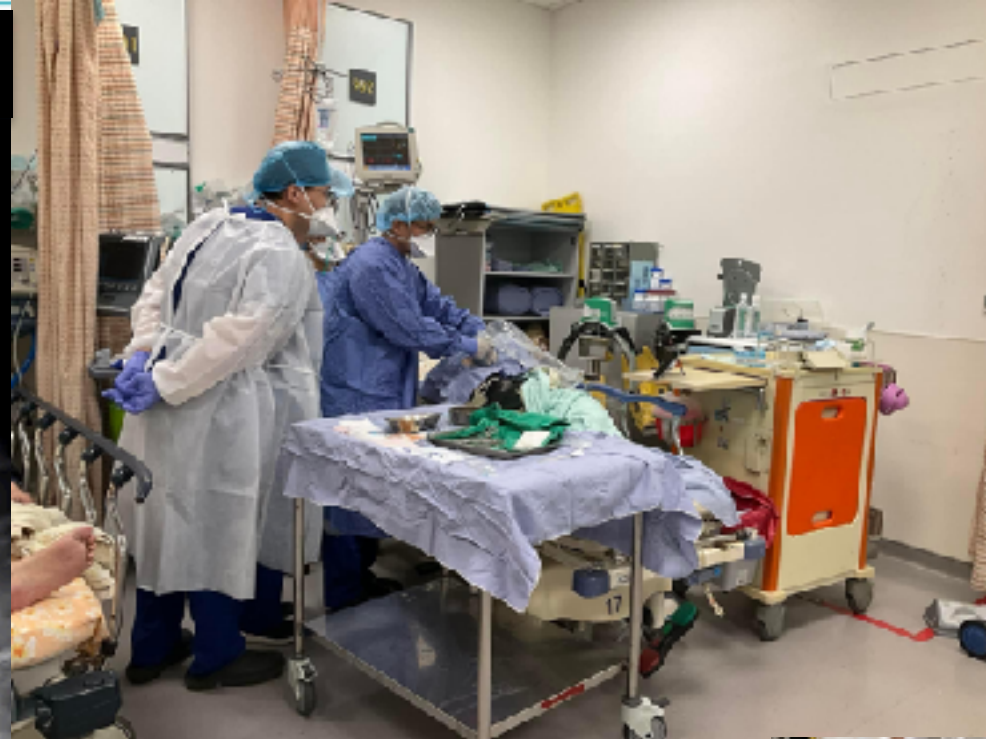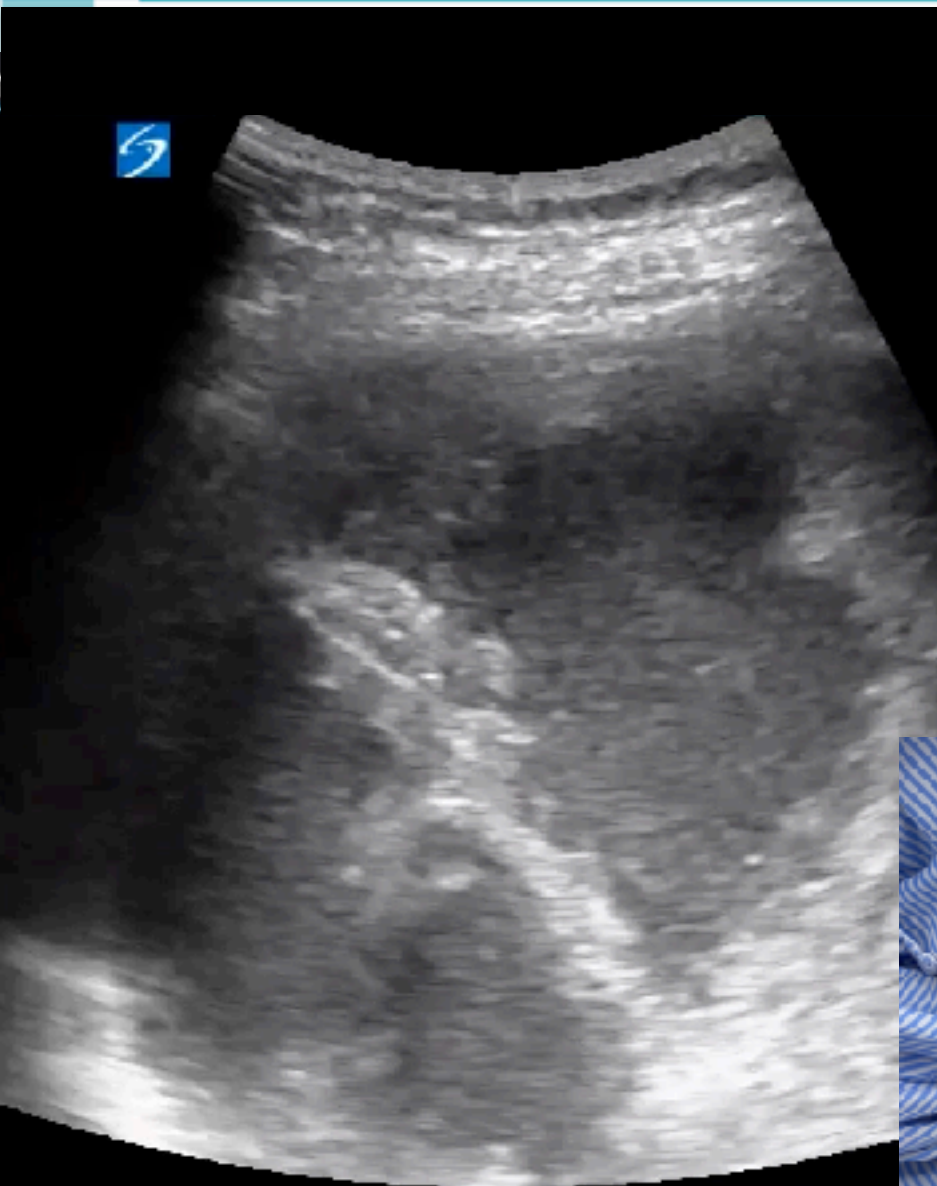
0356293
2.5 mm

65F, left eye redness, pain; R chest pain

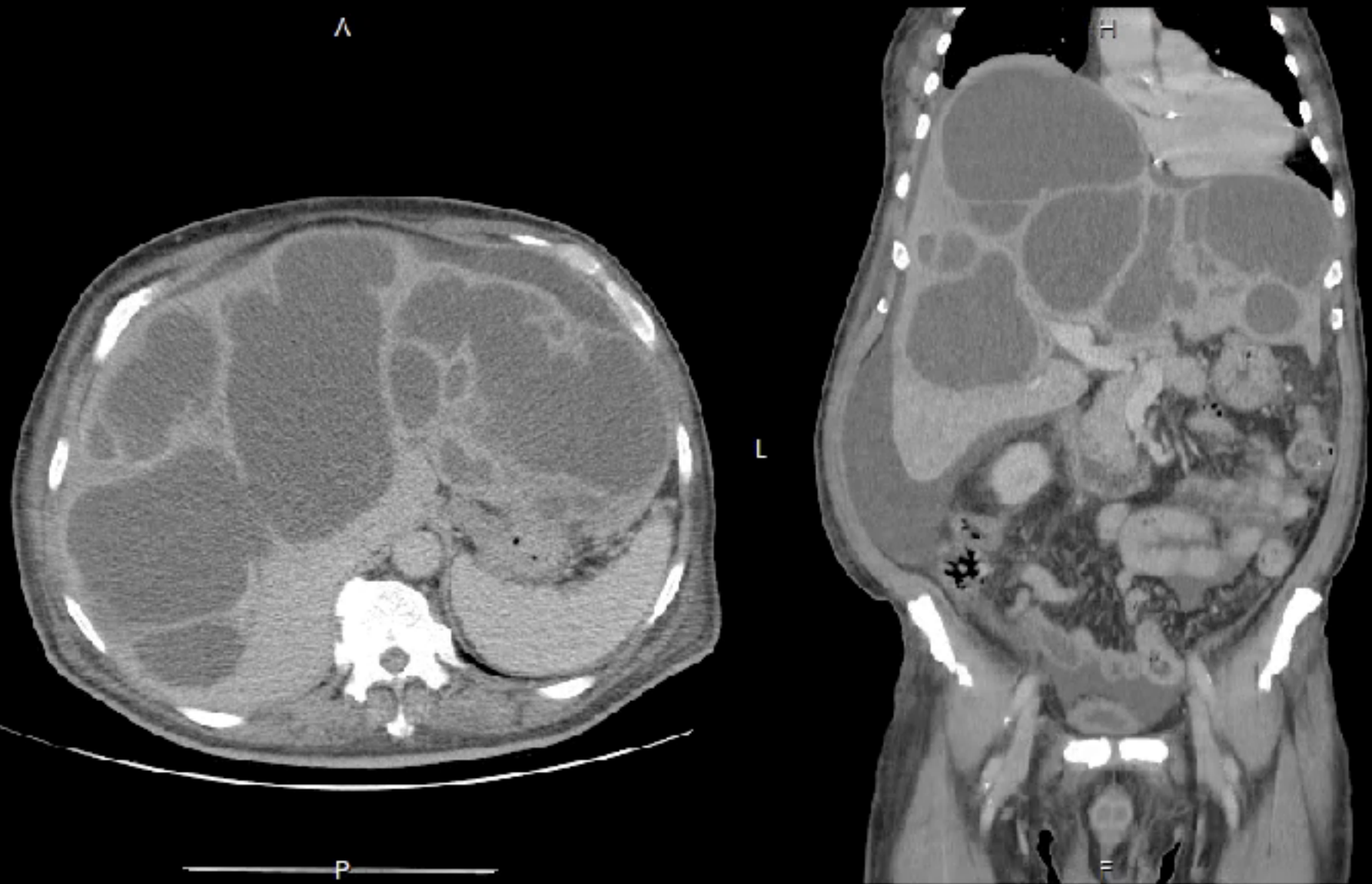
Liver abscess / Endophthalmitis



Pigtail for liver abscess drainage

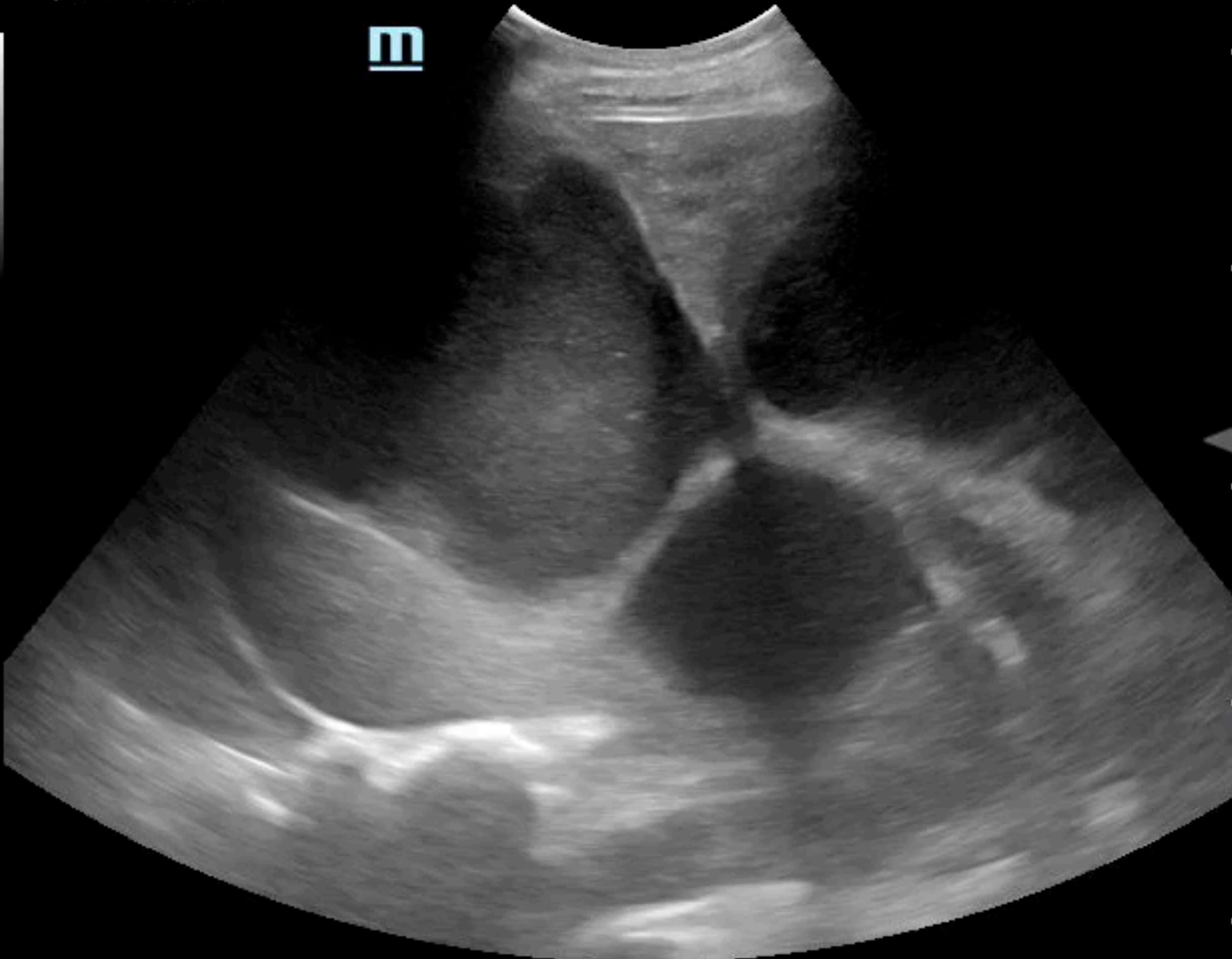


64M, right abdominal pain



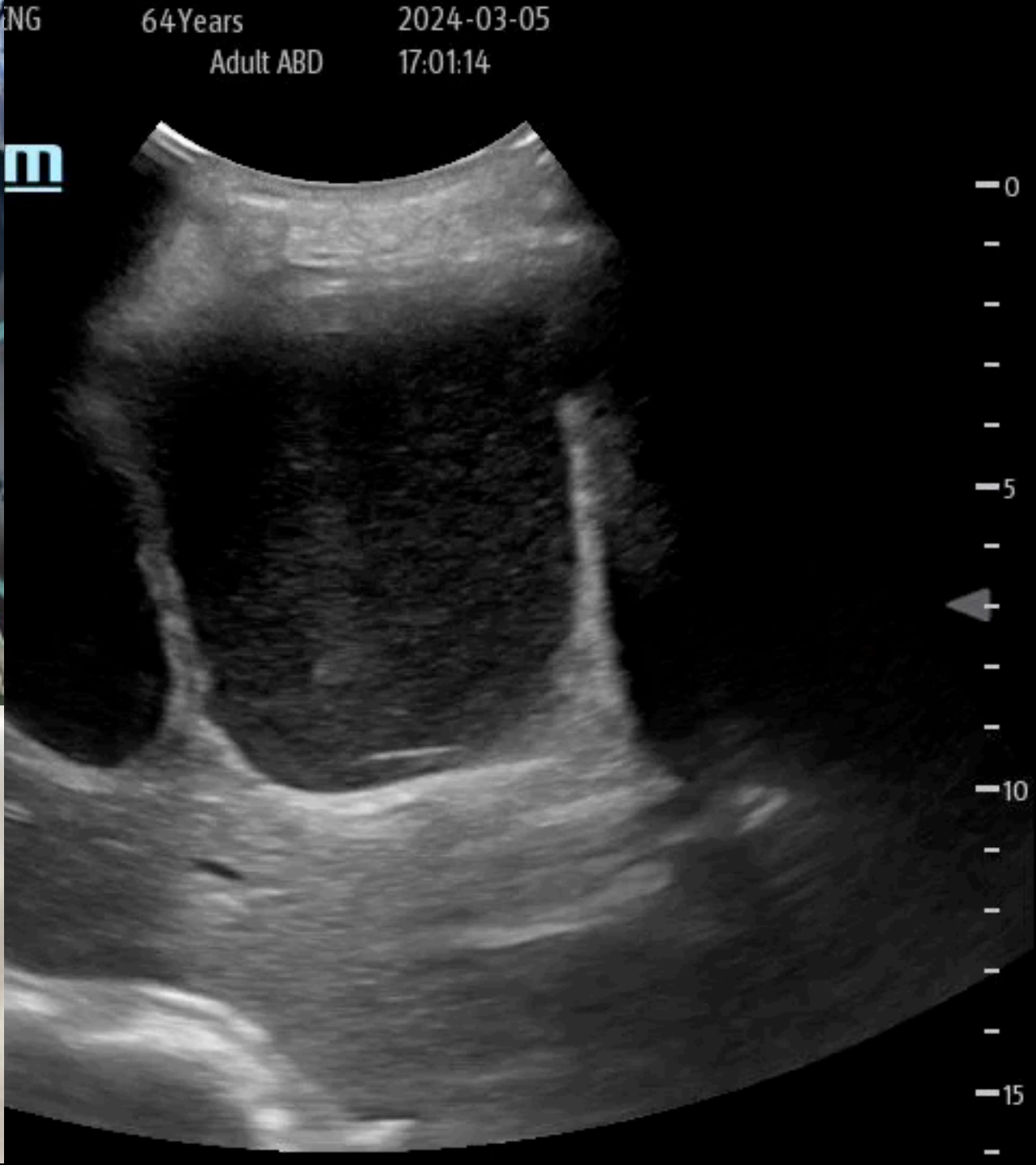
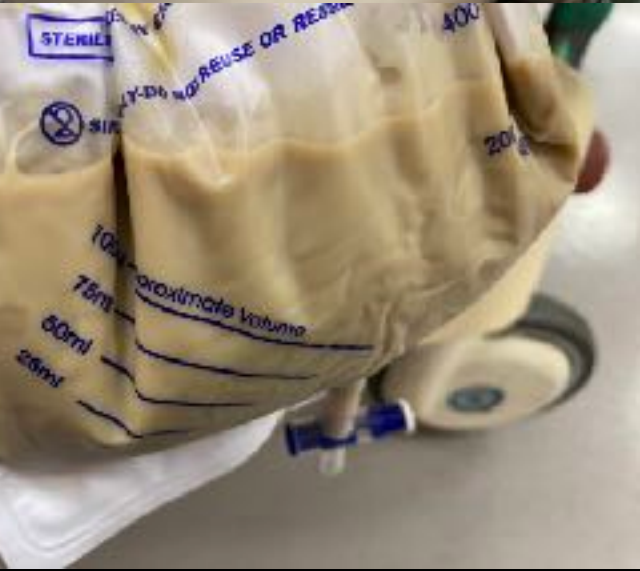
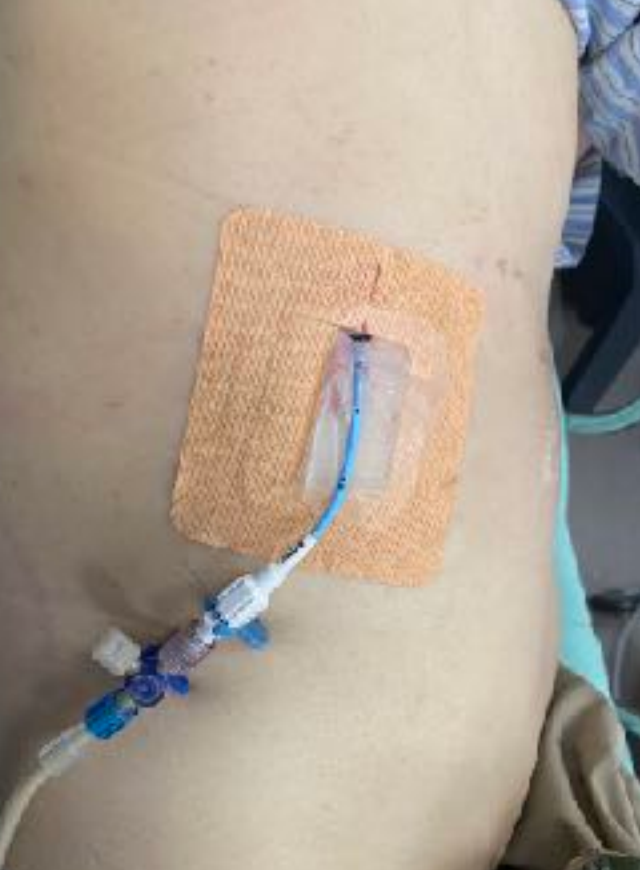
0
0
0

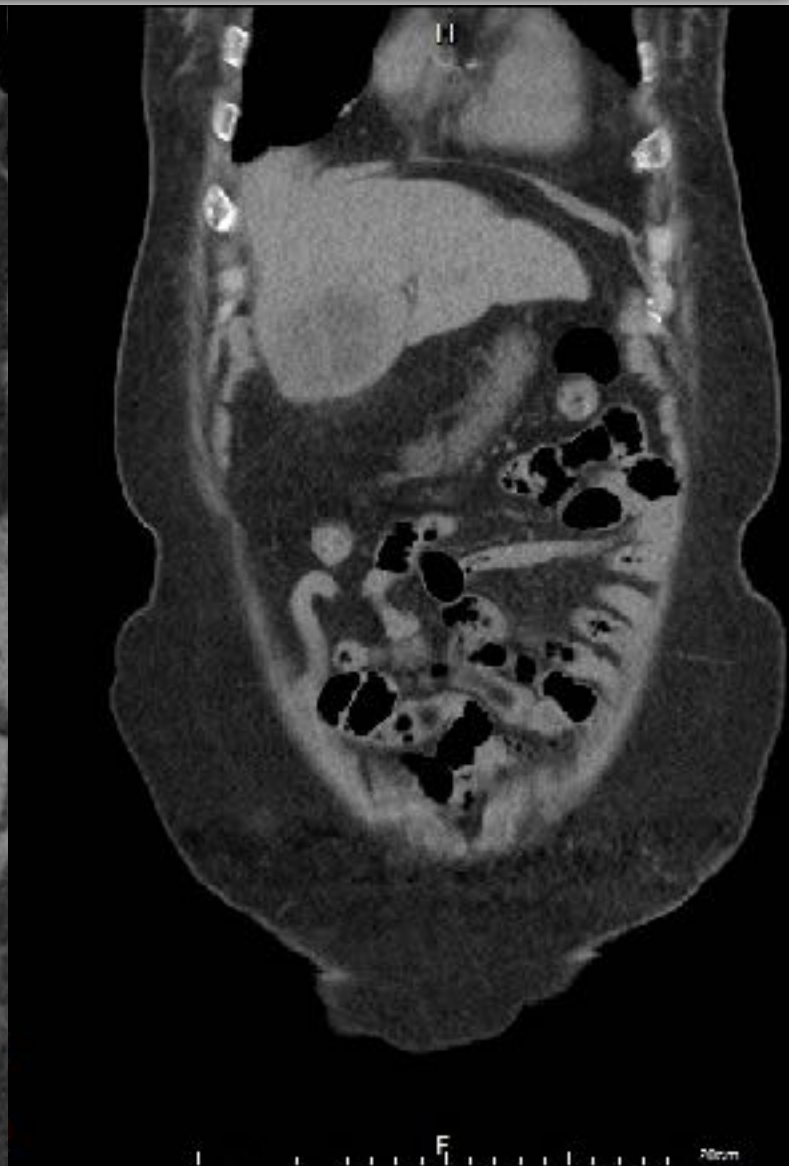
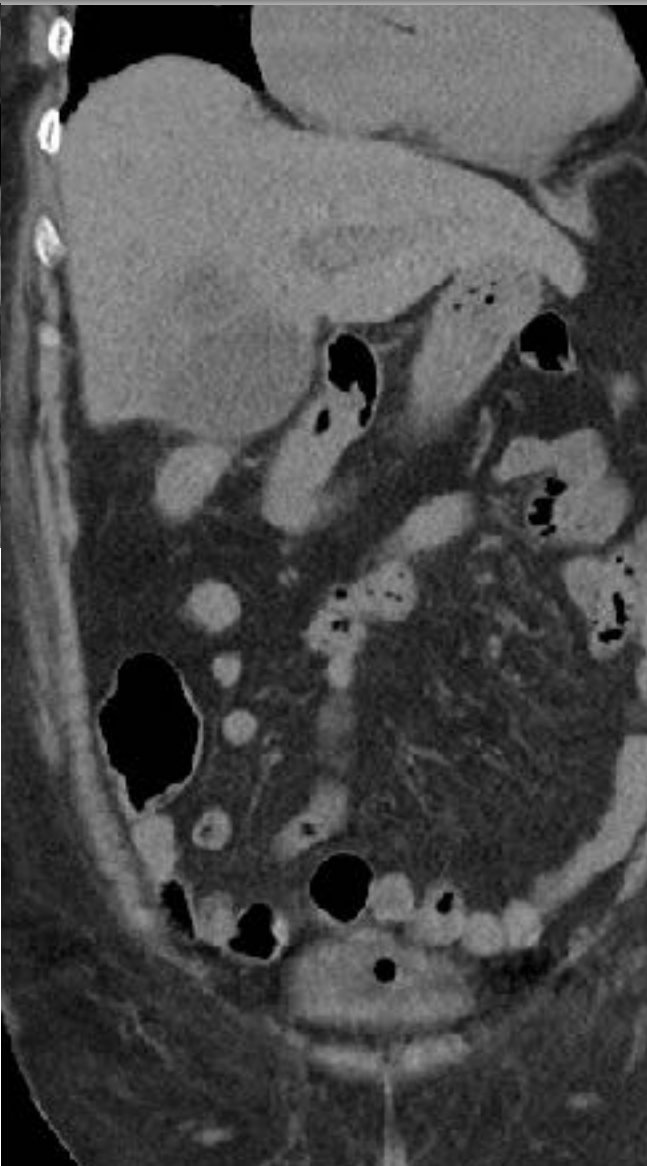
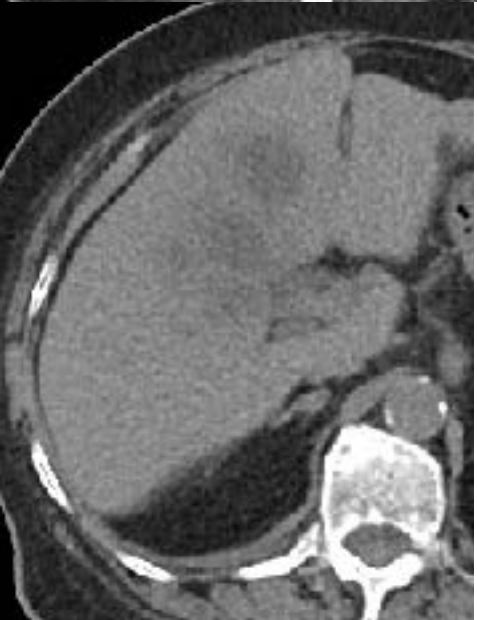
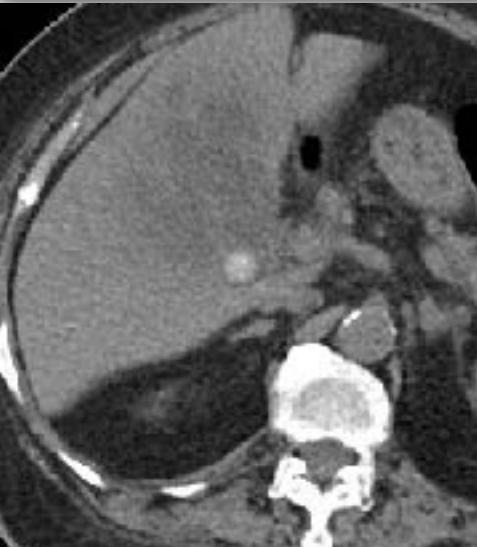
edle

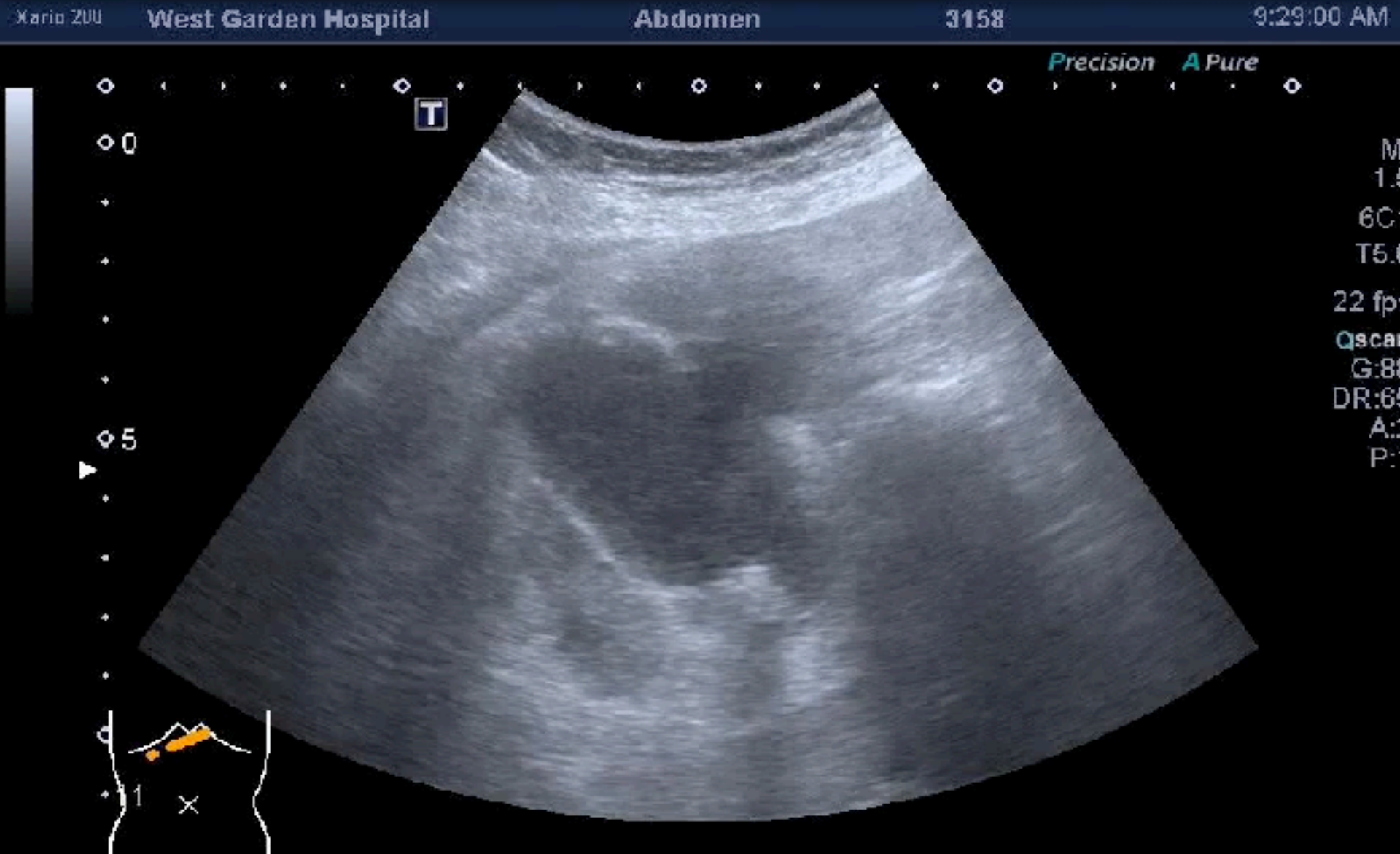uch



94F, right abdominal pain with fever



GB empyema with rupture



GB empyema with rupture

Xaru 200

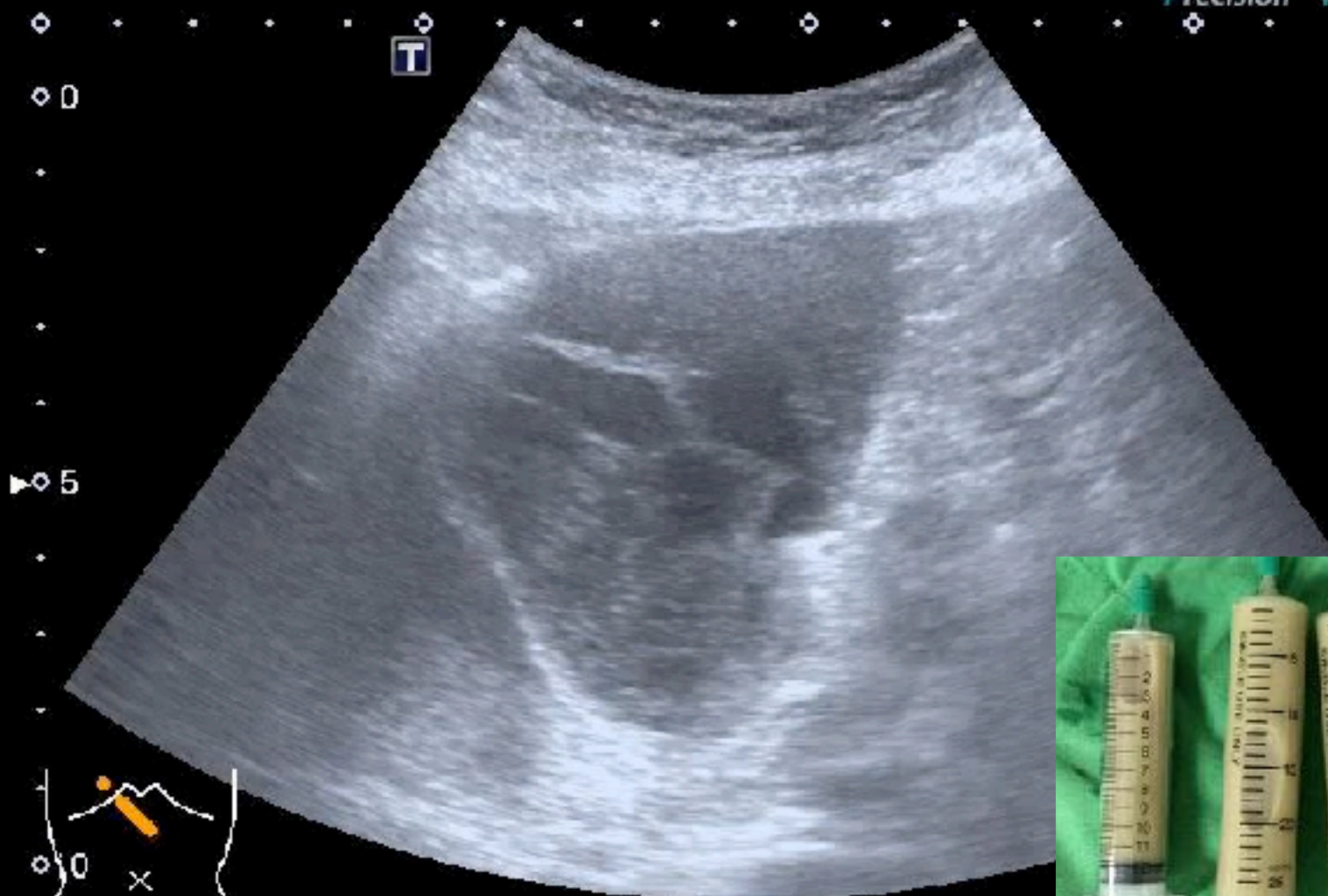
West Garden Hospital

Abdomen

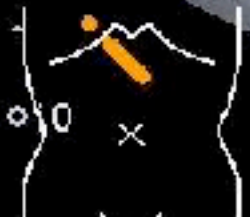3158

10:01:00 AM

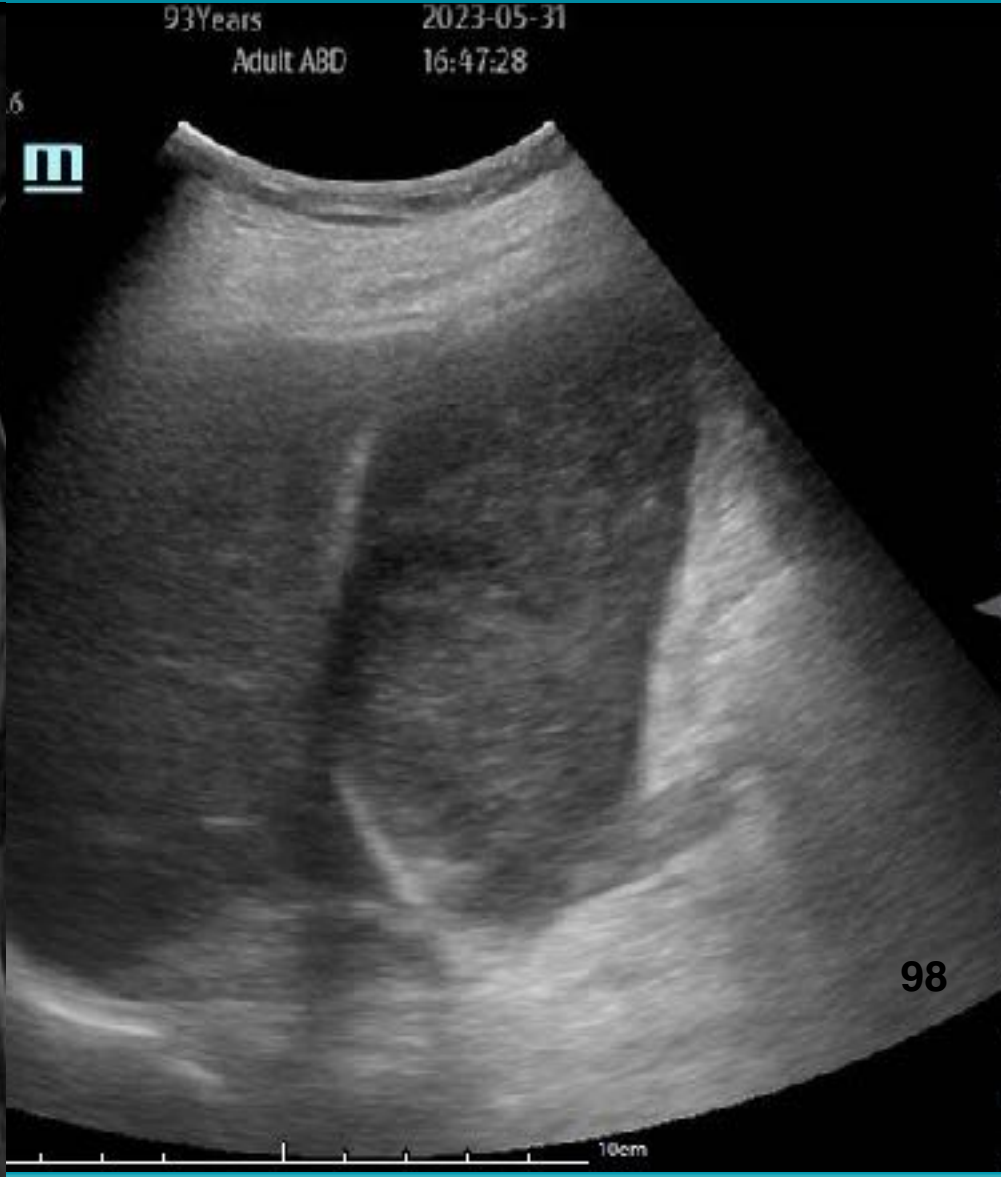
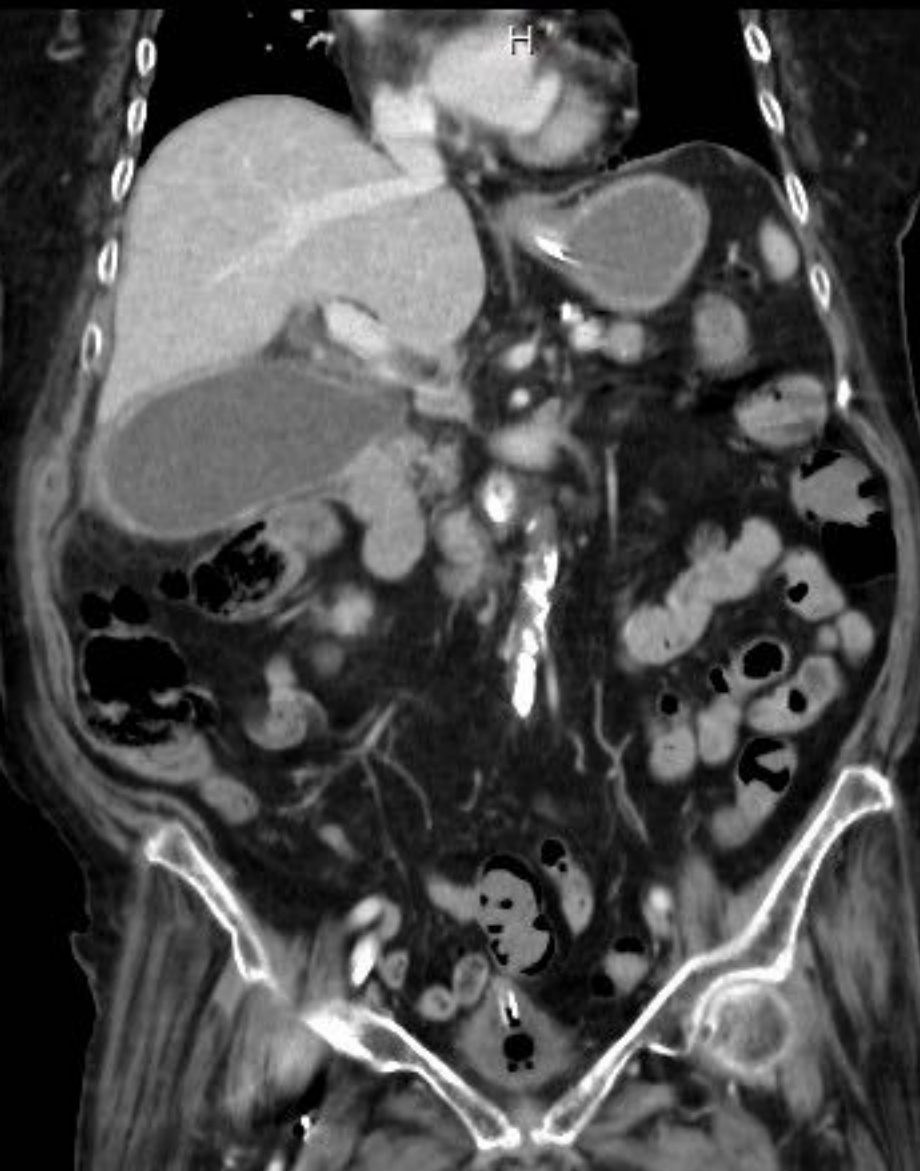
Precision APure



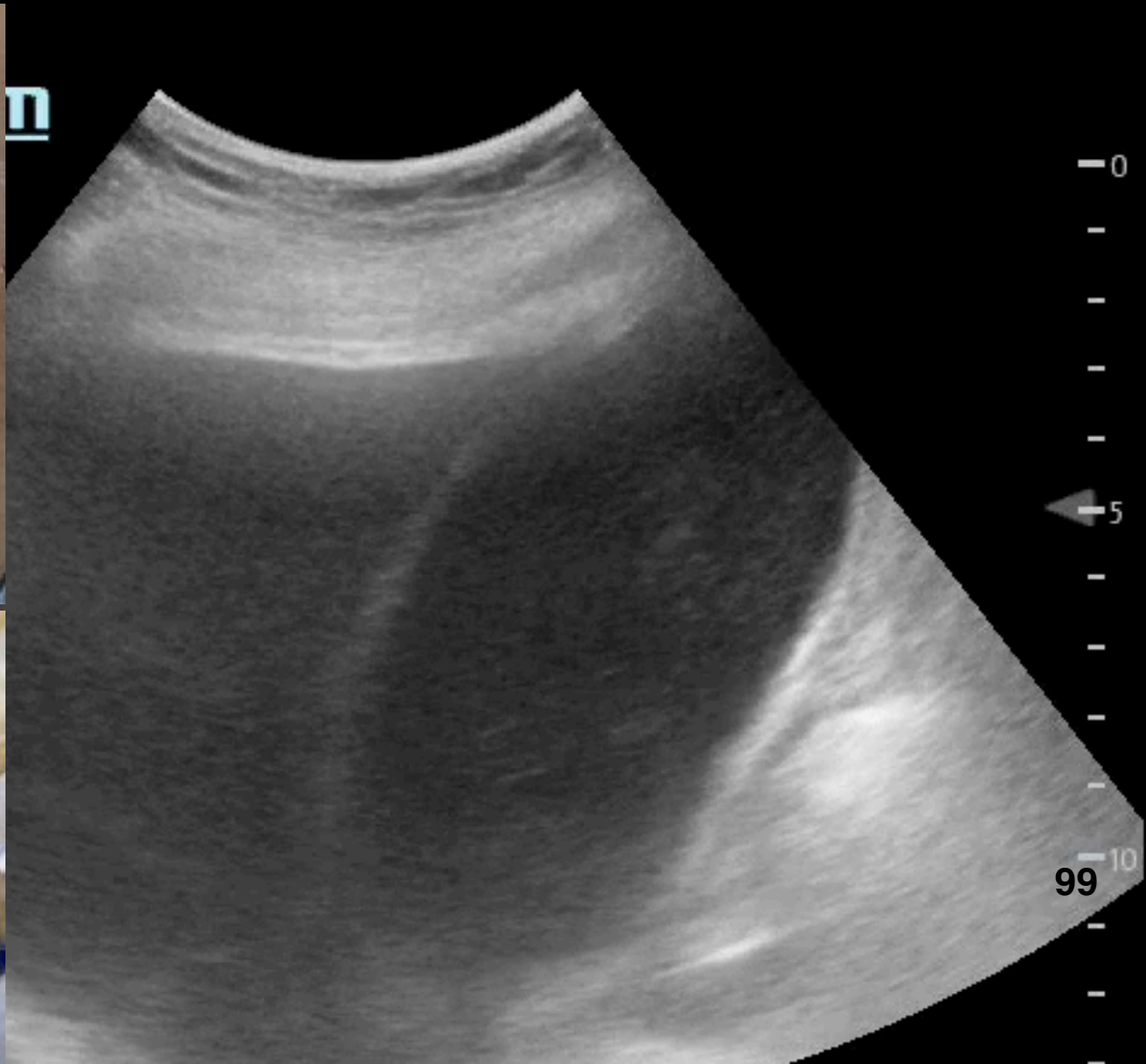
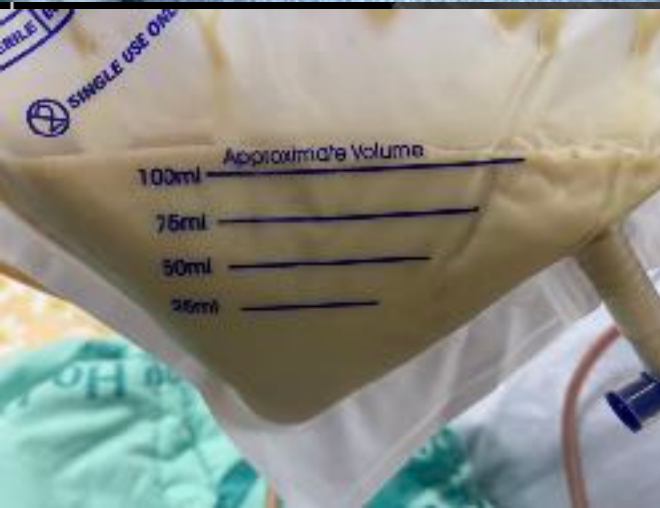
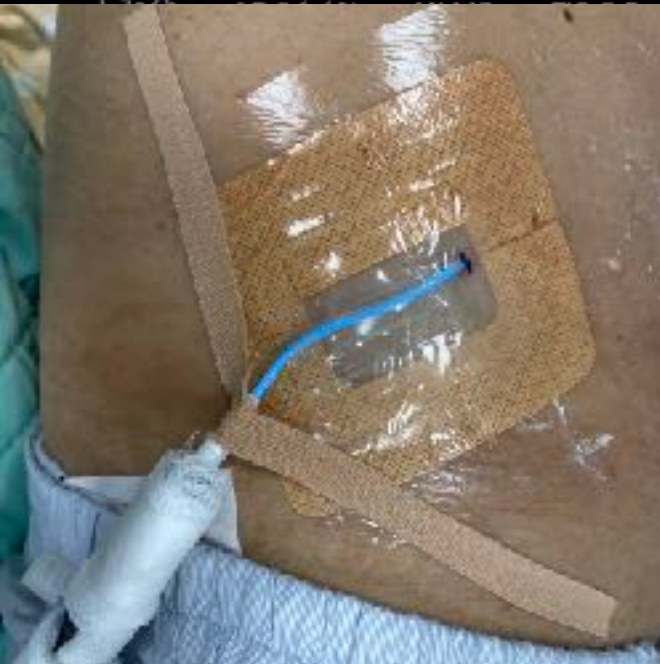M
1.5
6C1
T5.0
22 fps
Qscan
G:93
DR:65
A:2
P:1

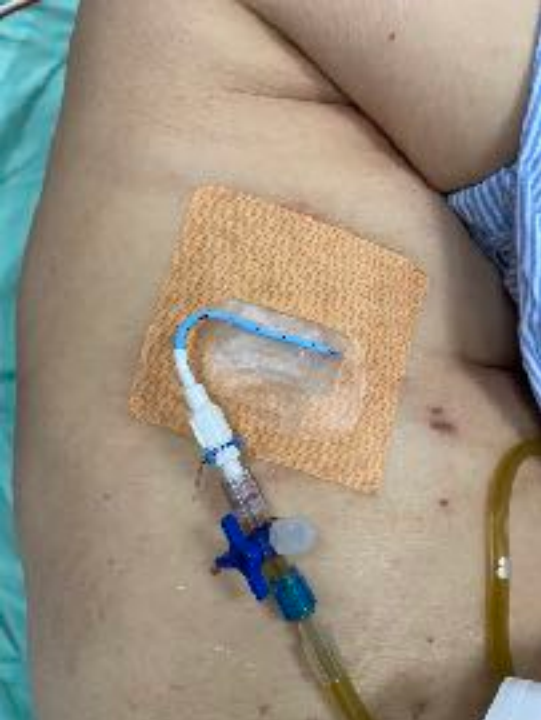

93M, Dementia & high fever



93M, Dementia & high fever

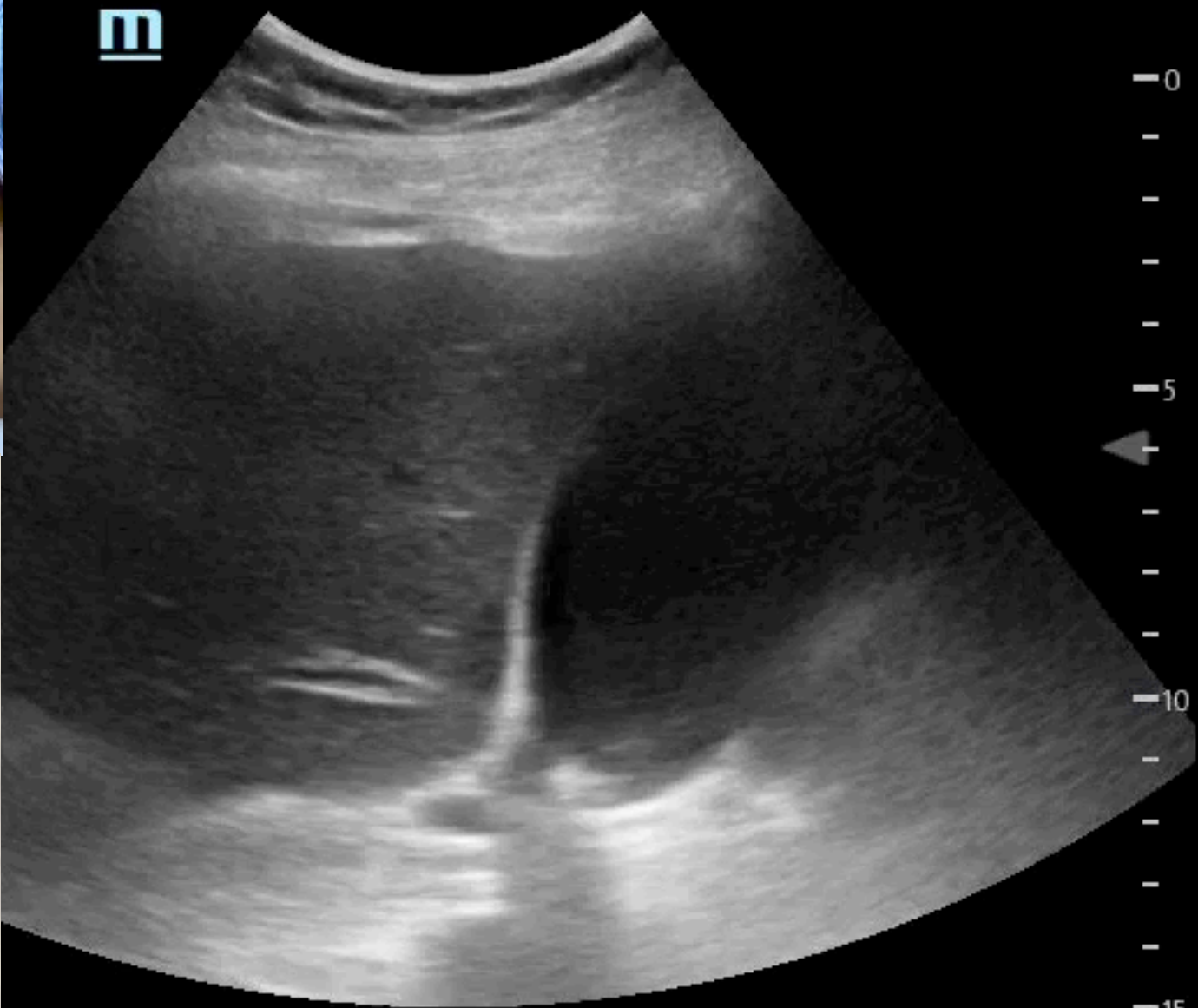




EH 89Years 2024-03-16
Neuromuscular 19:02:07

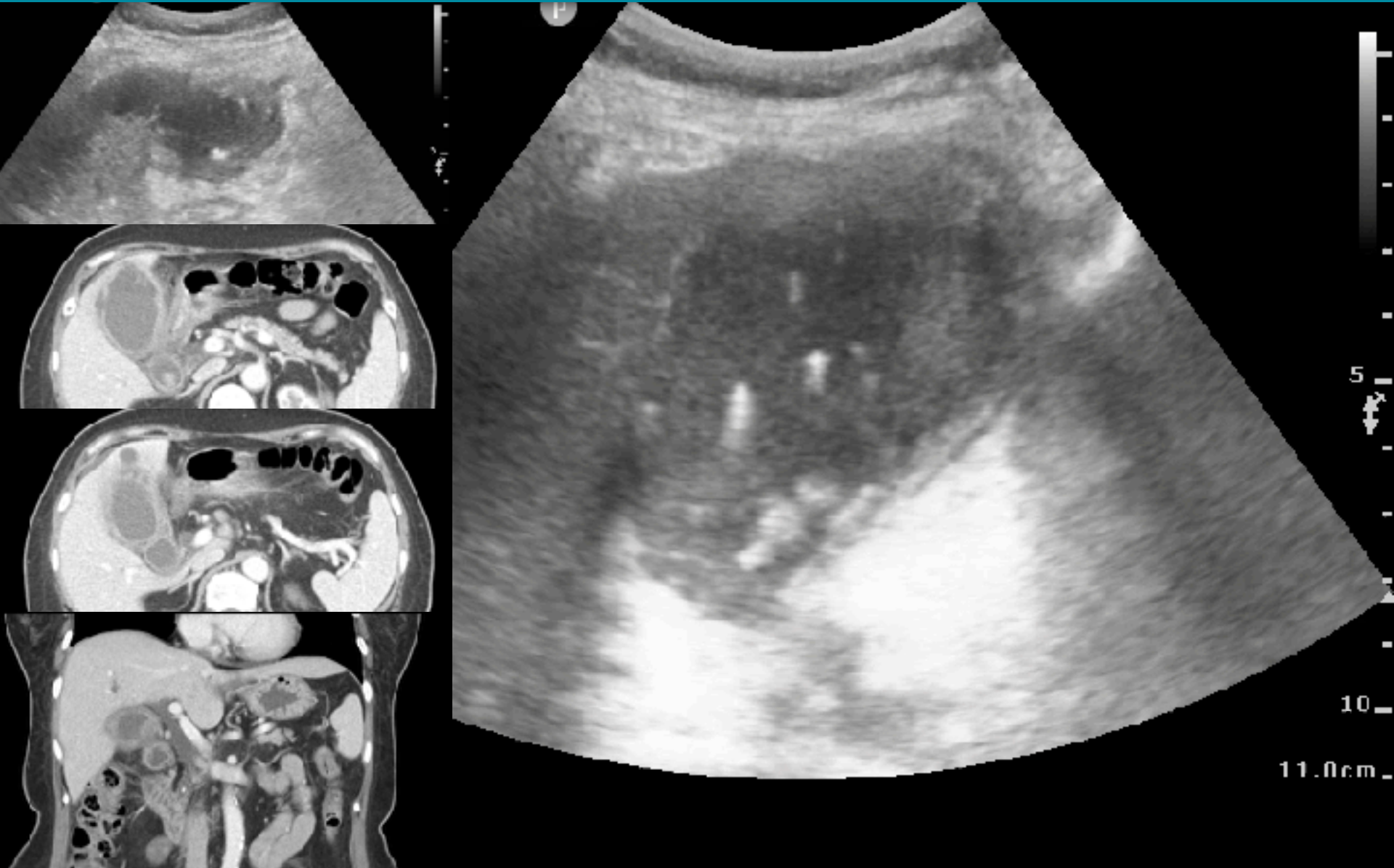
TIS 0.5

m

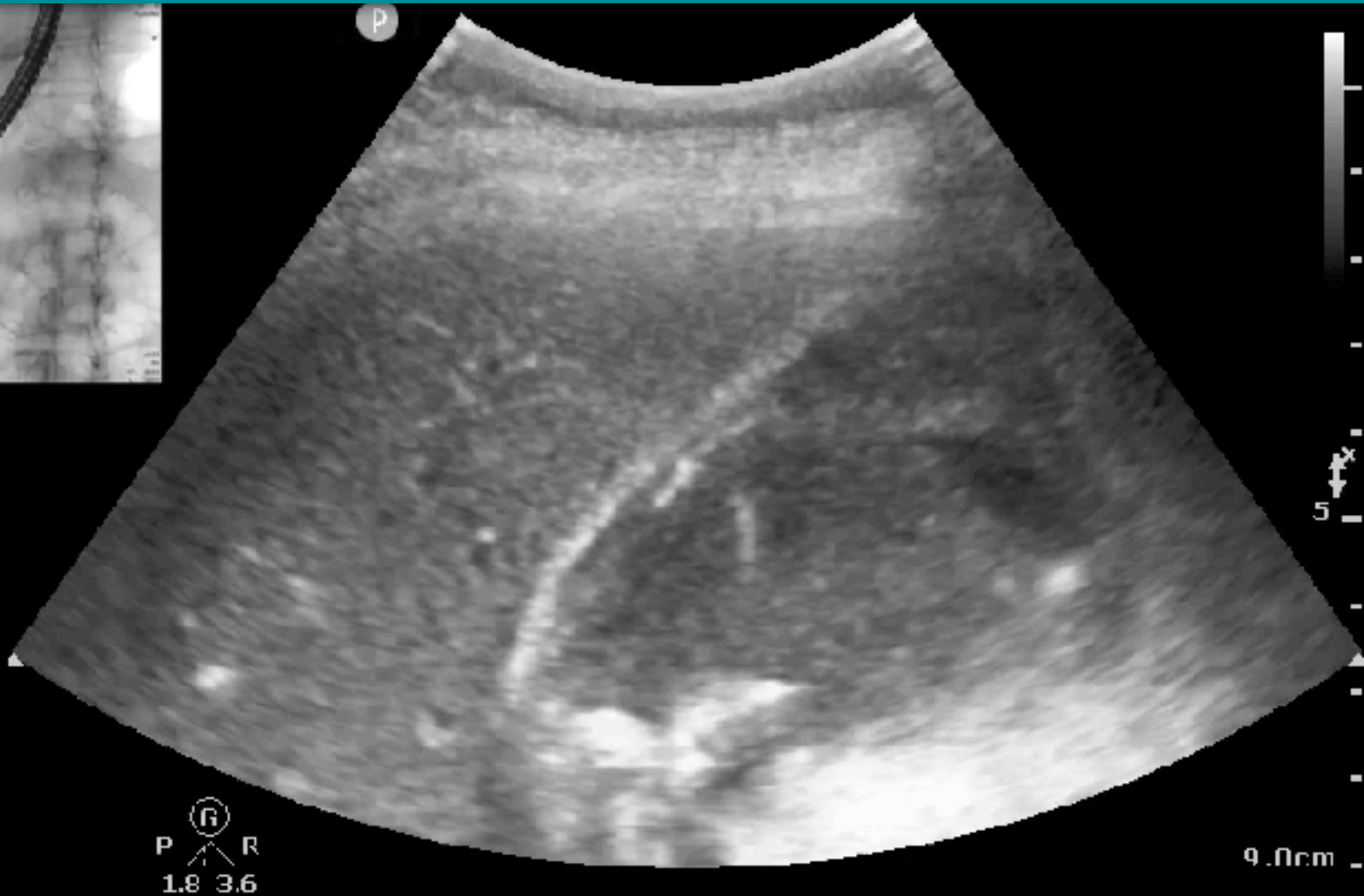
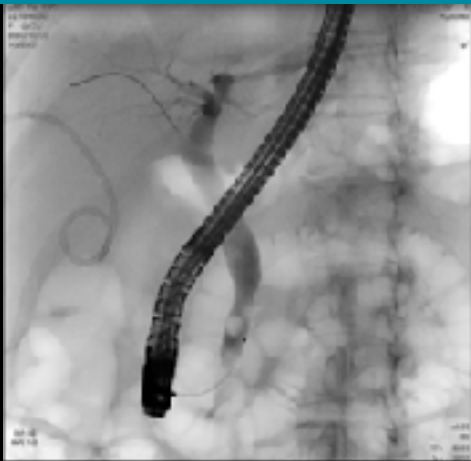

10cm

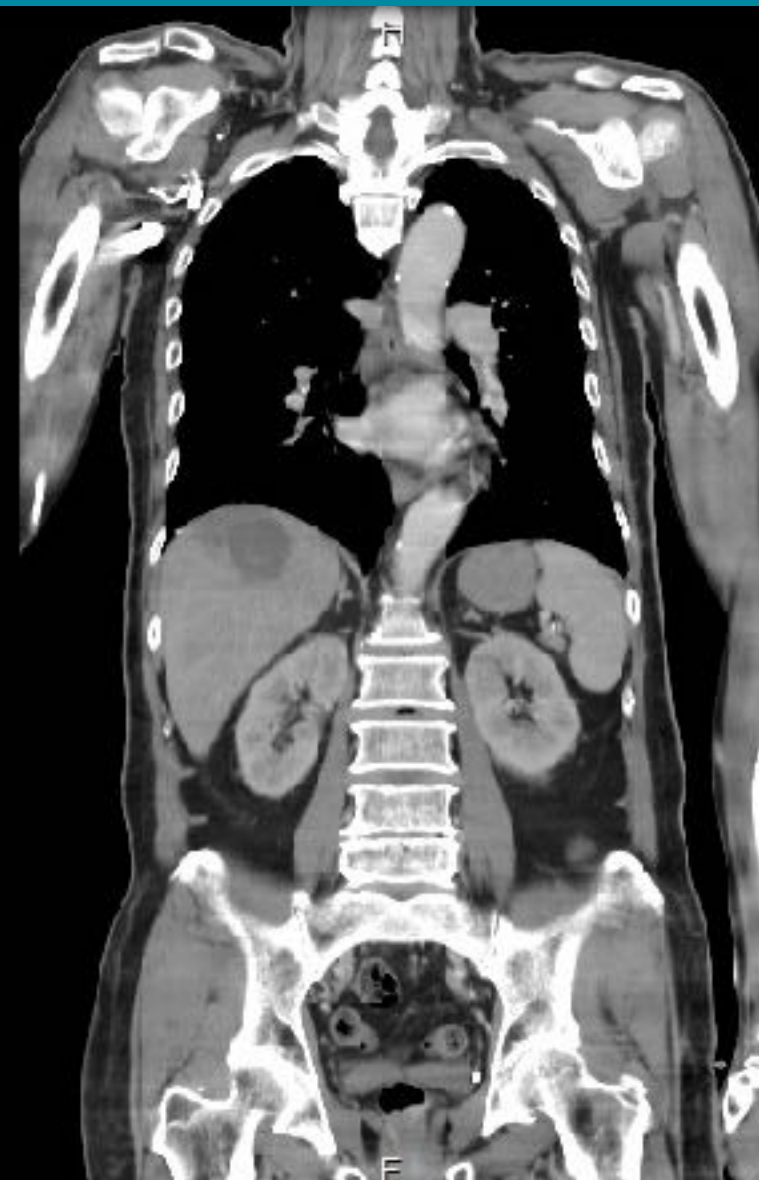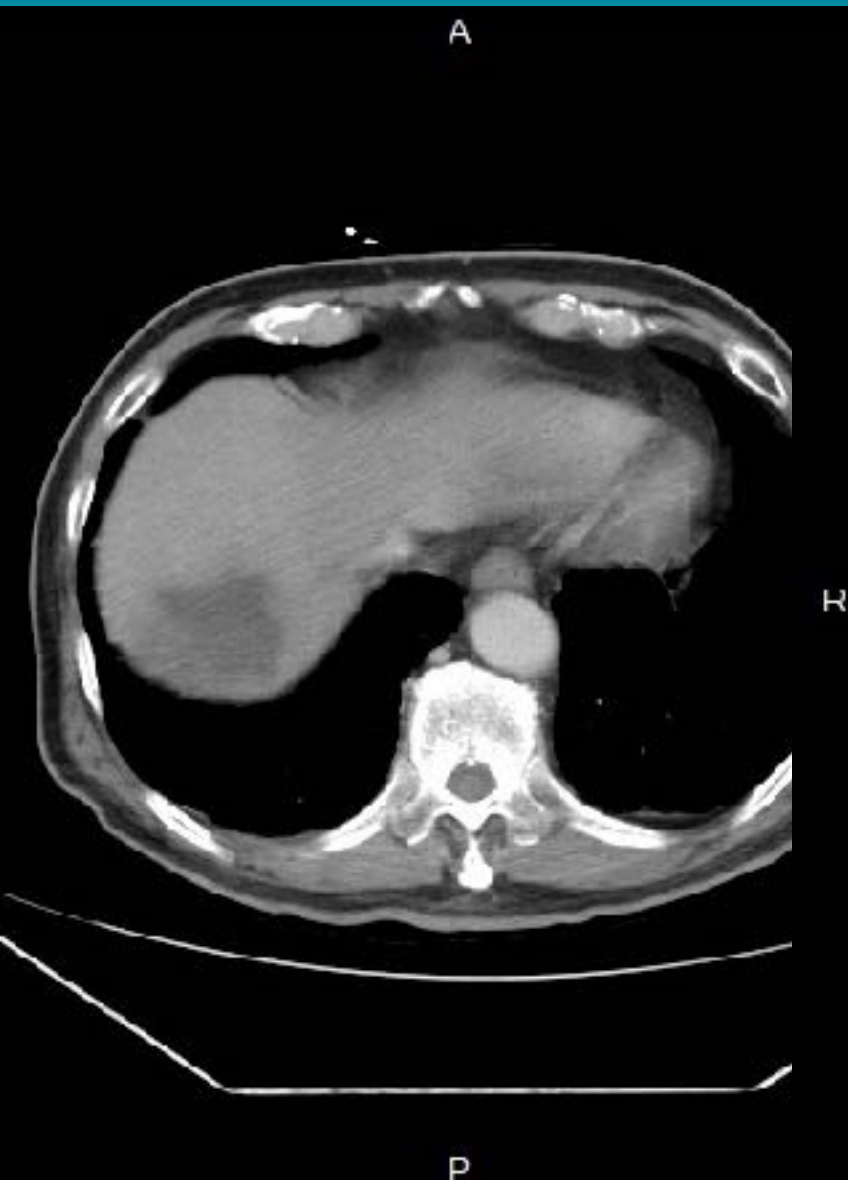67F, epigastric pain



PTGBD before ERCP & LC



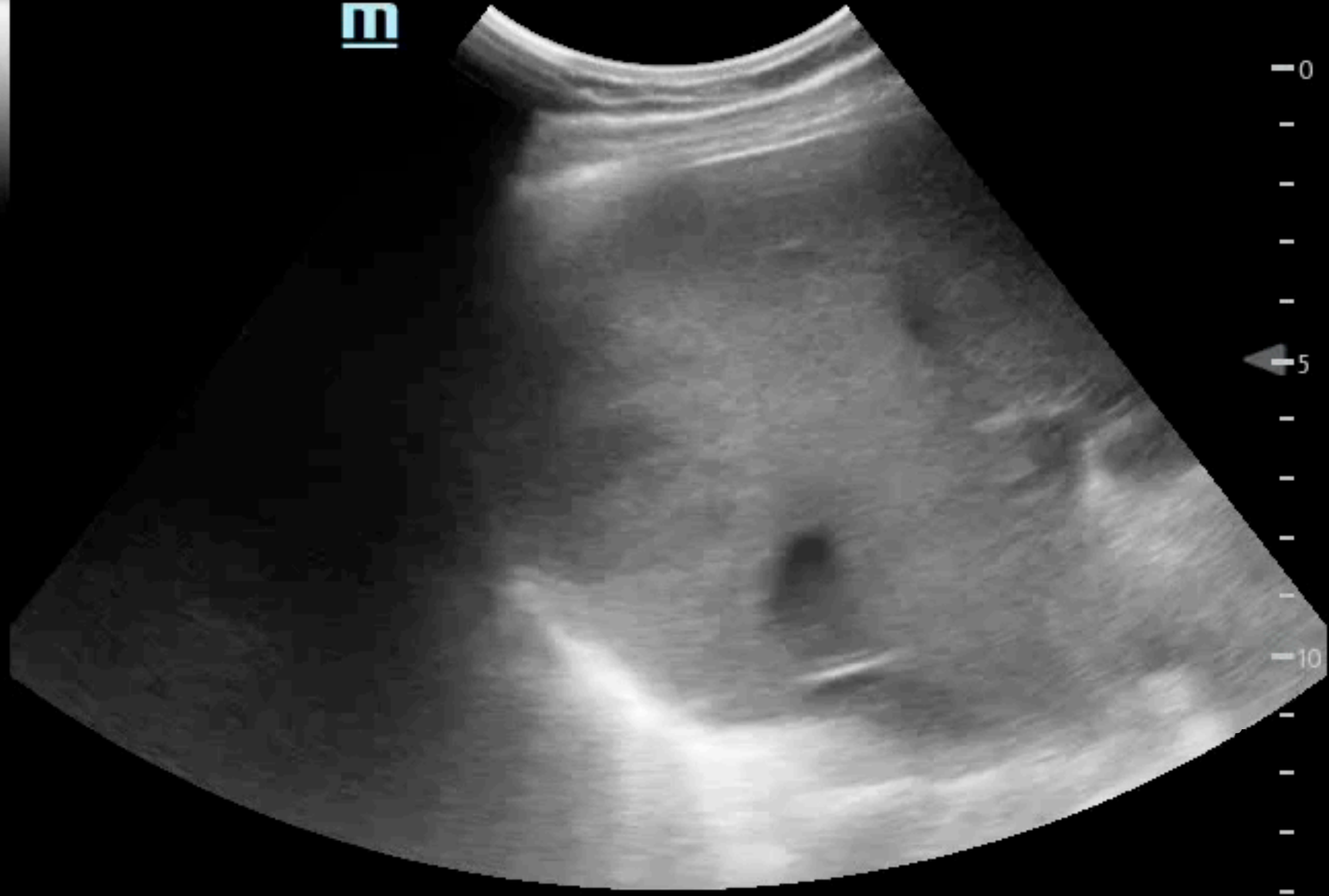80M, liver abscess / shock



80M, liver abscess / shock

FH5.0
DR 115
FR 16
D 14.0
G 71

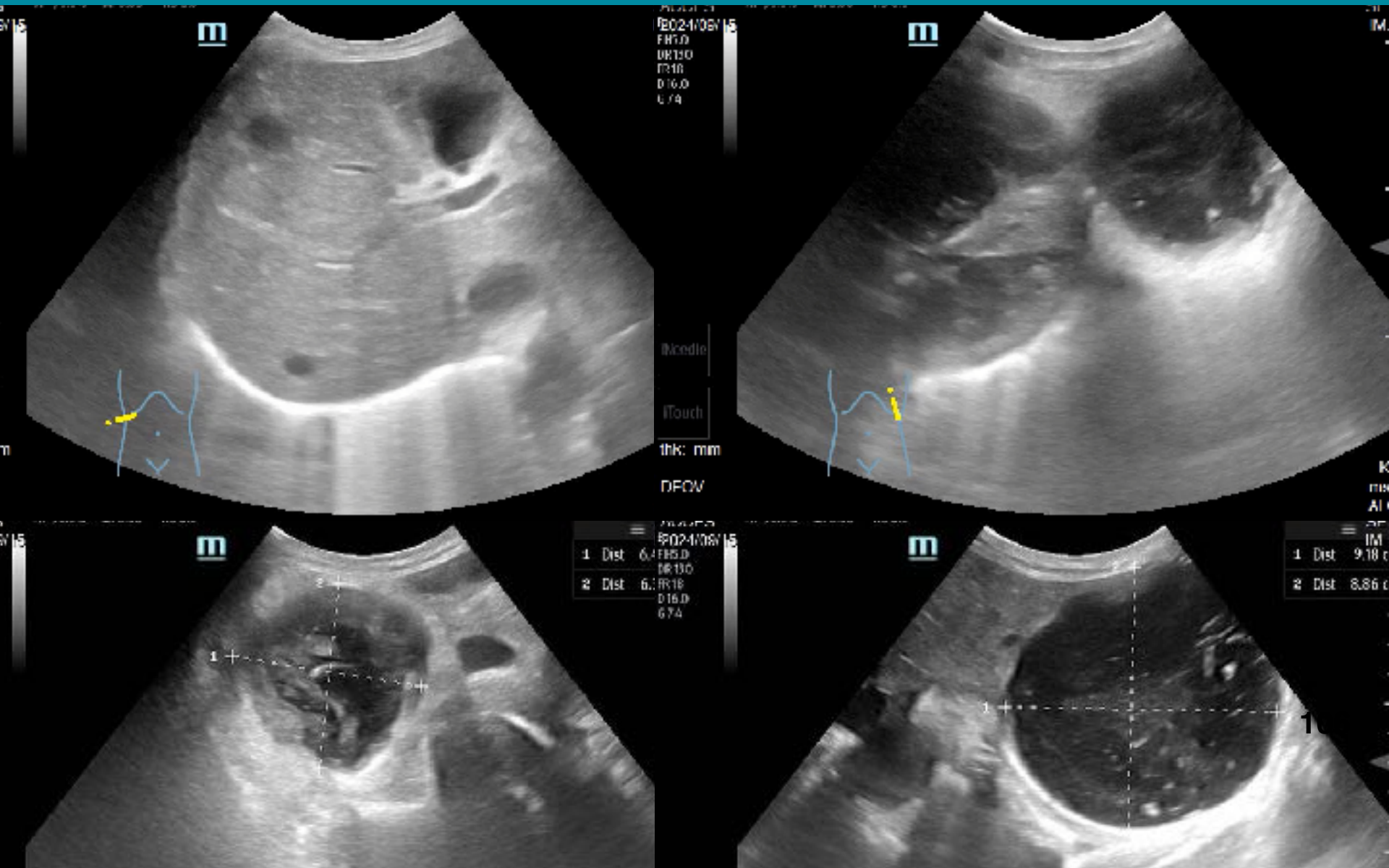
m



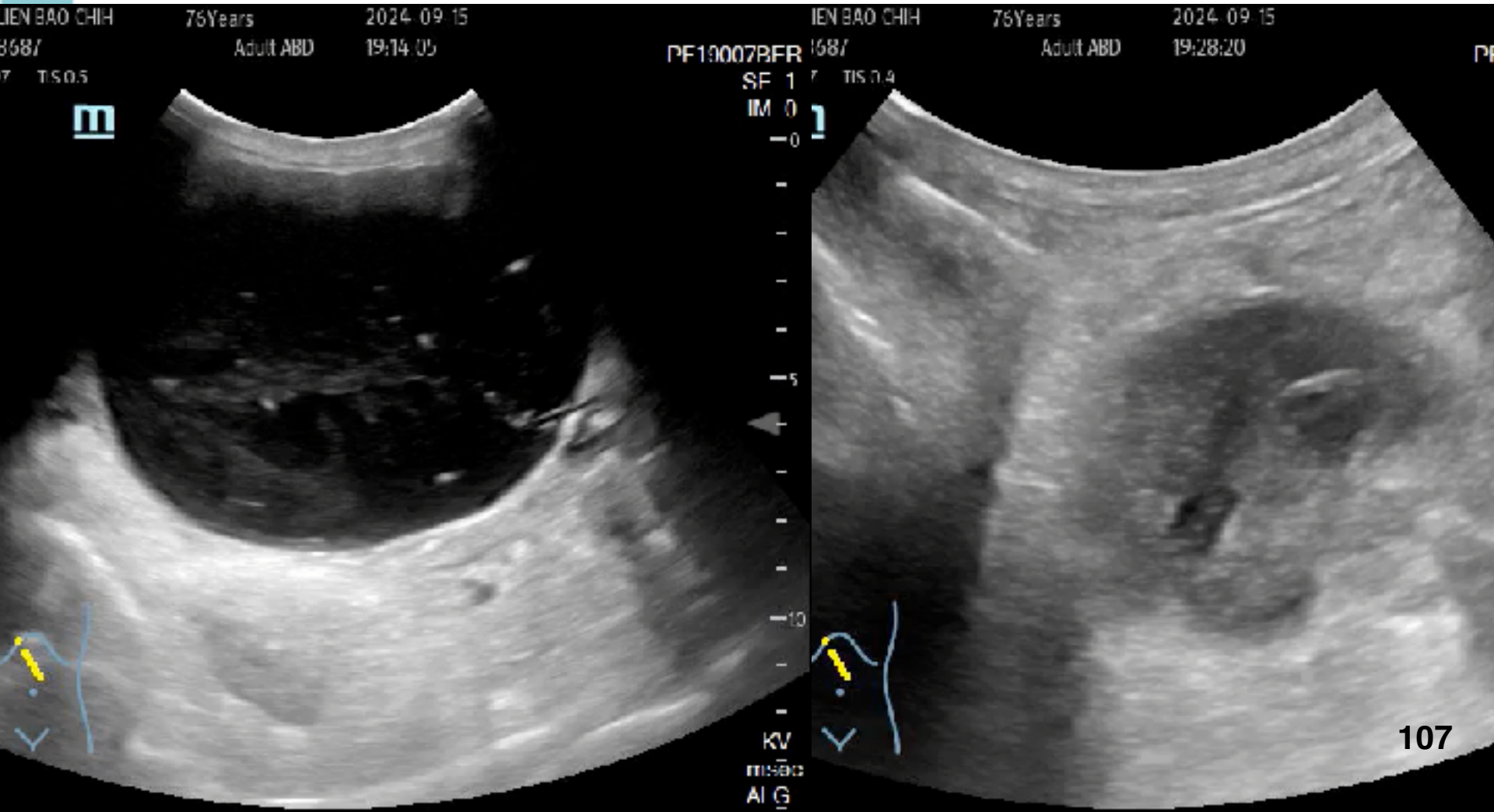
iNeedle

iTouch

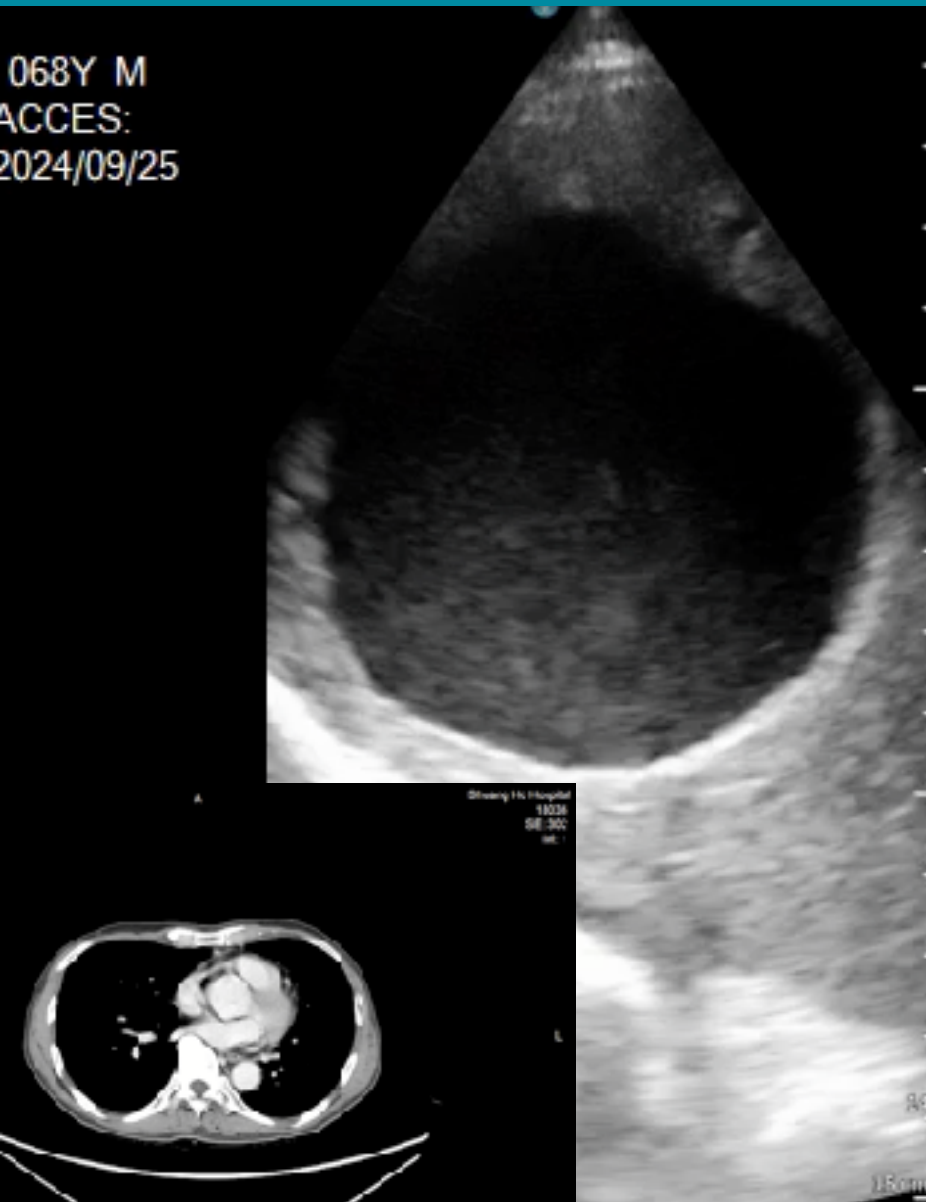Abscess - RK / Liver



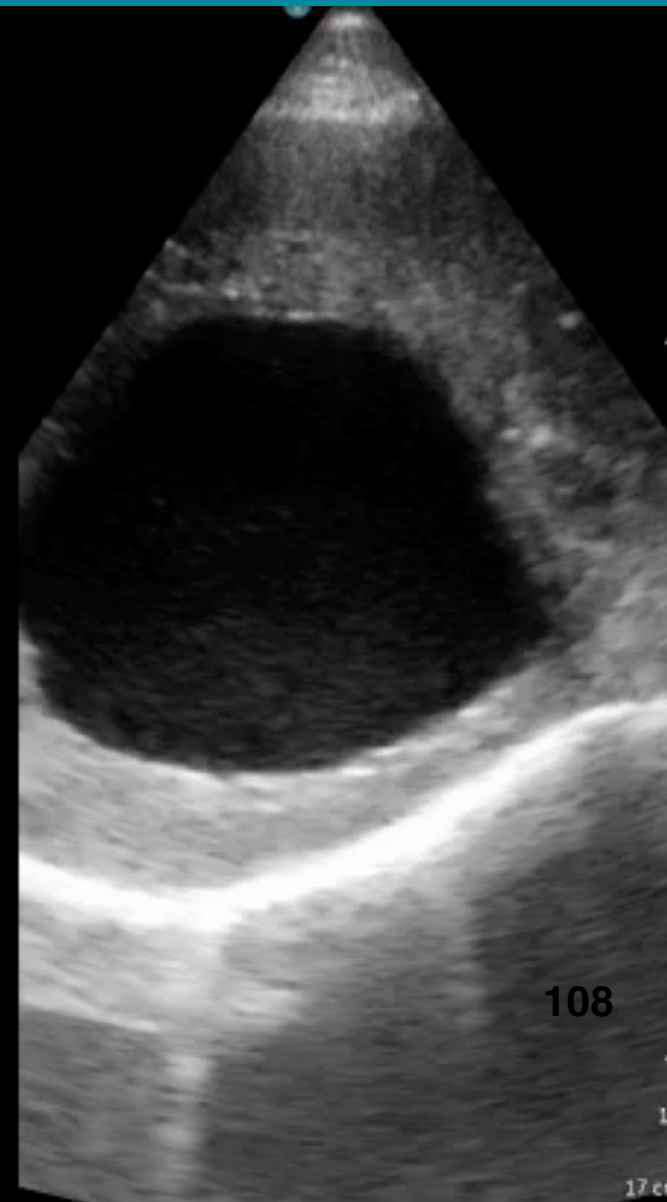
Pigtail drainage



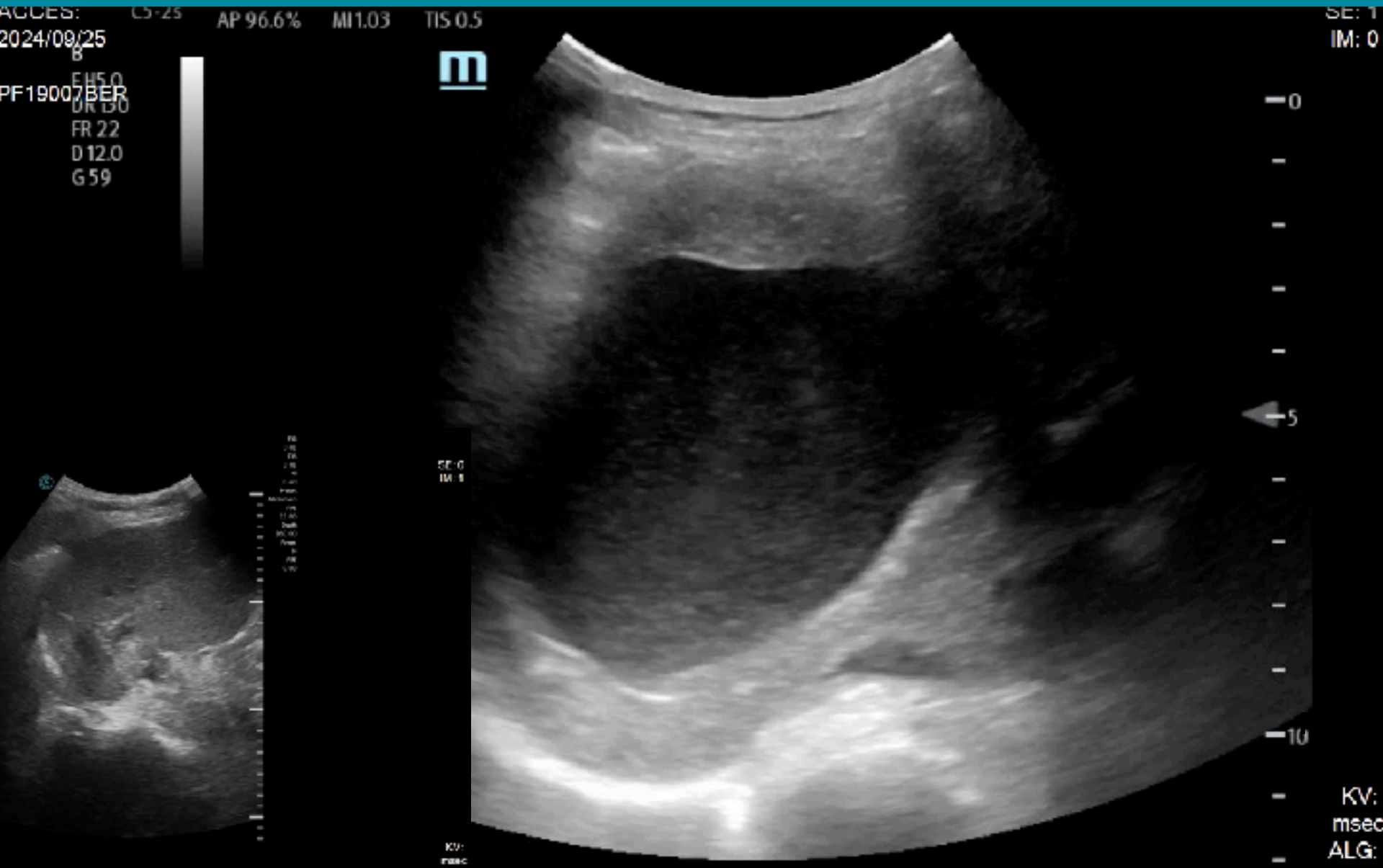
68M, fever one month



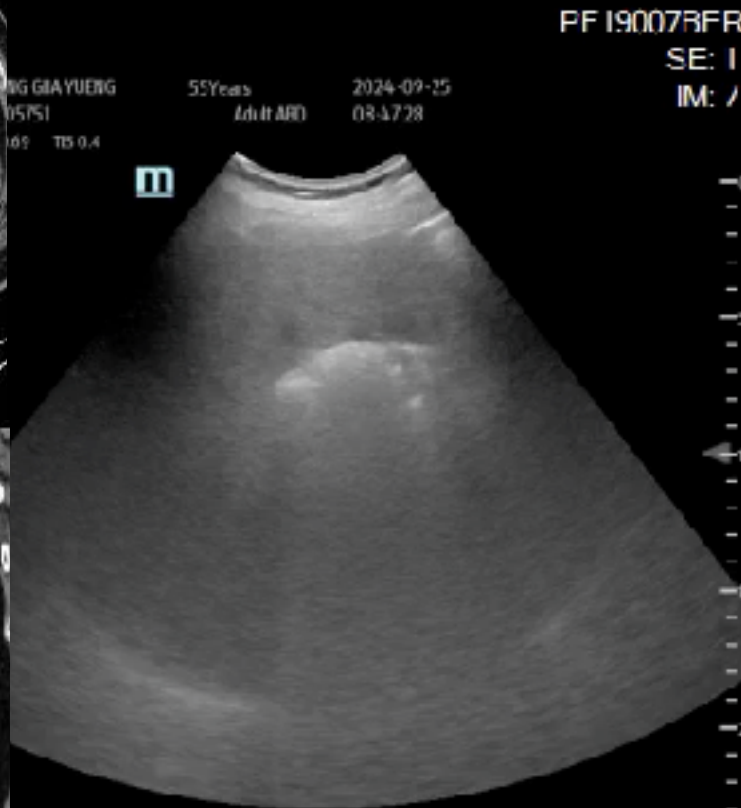
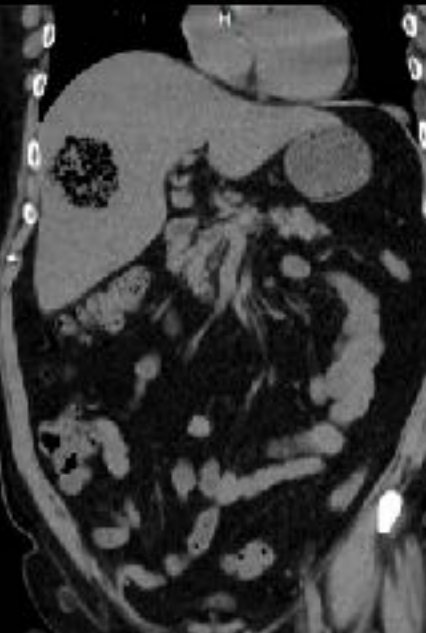
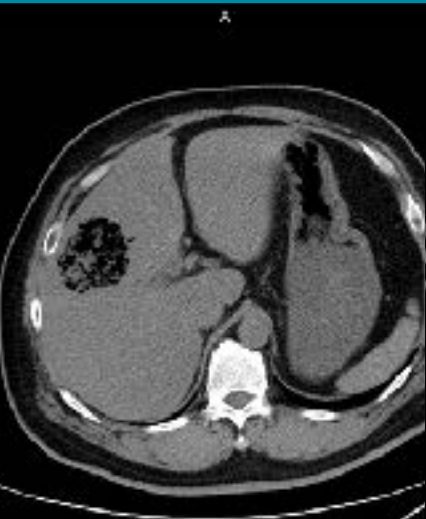
65
SE: 1
IM: 1



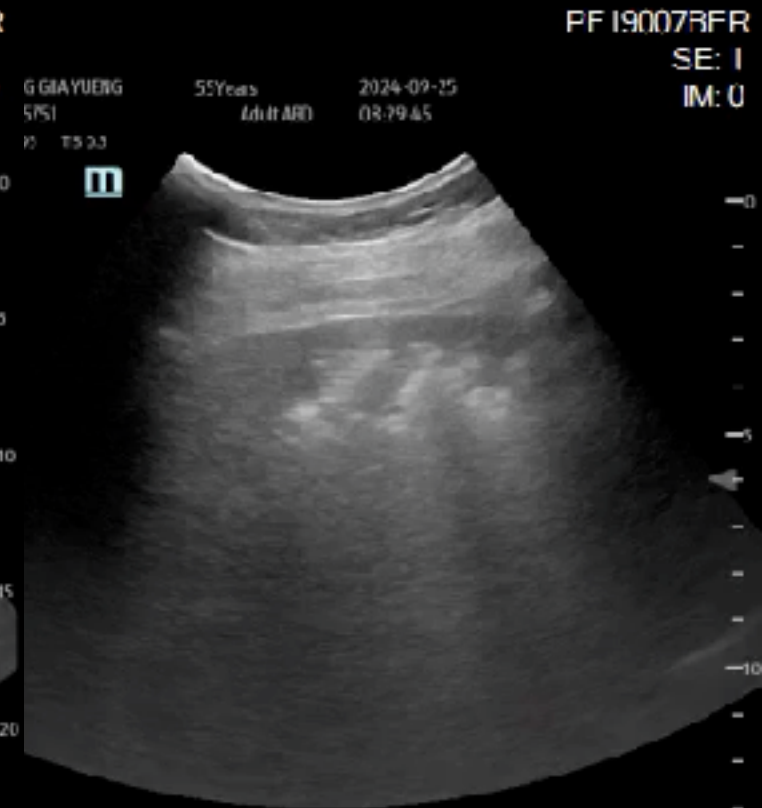
Pigtail - liver abscess



Pigtail drainage - liver abscess

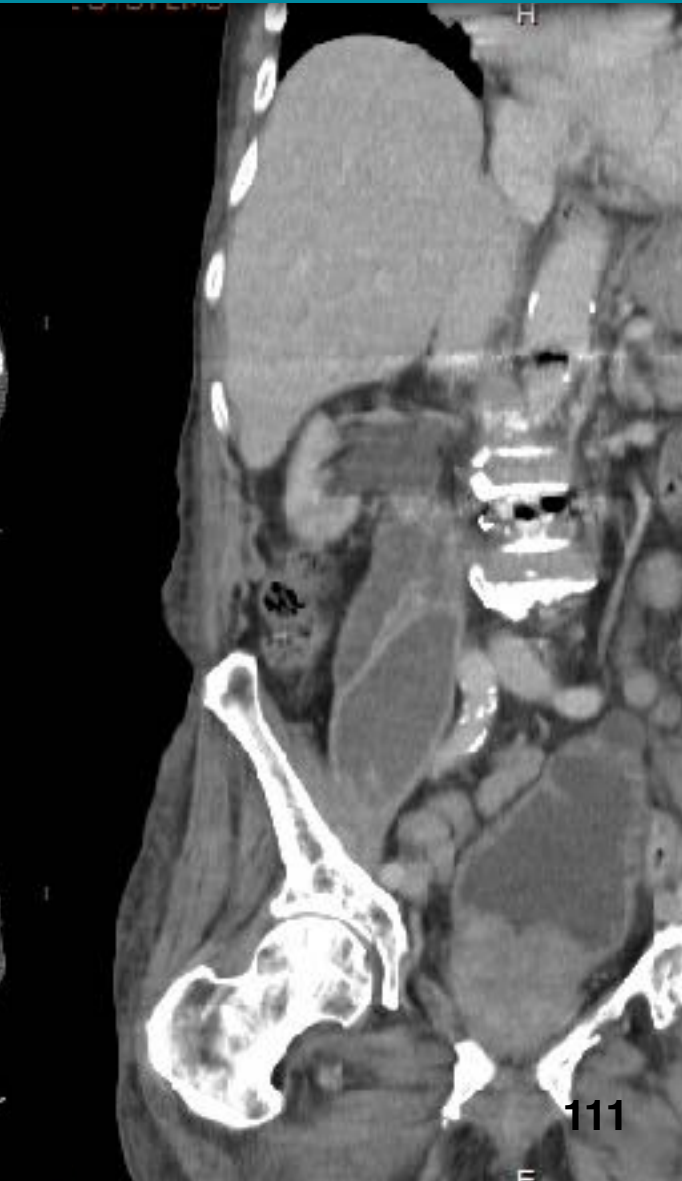
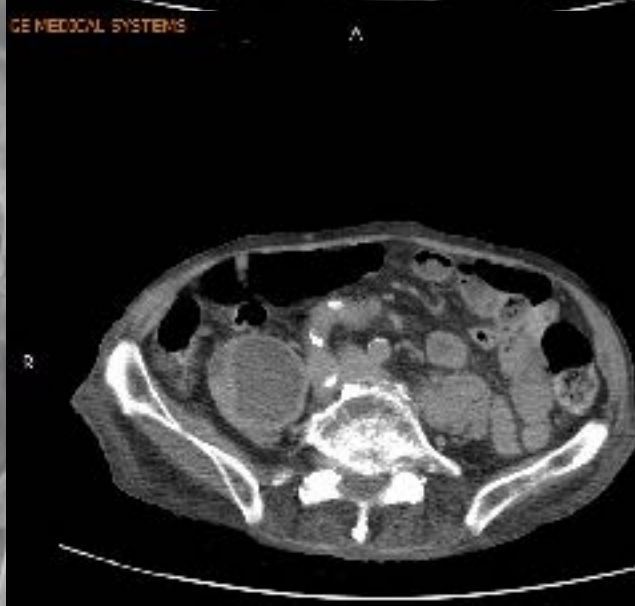
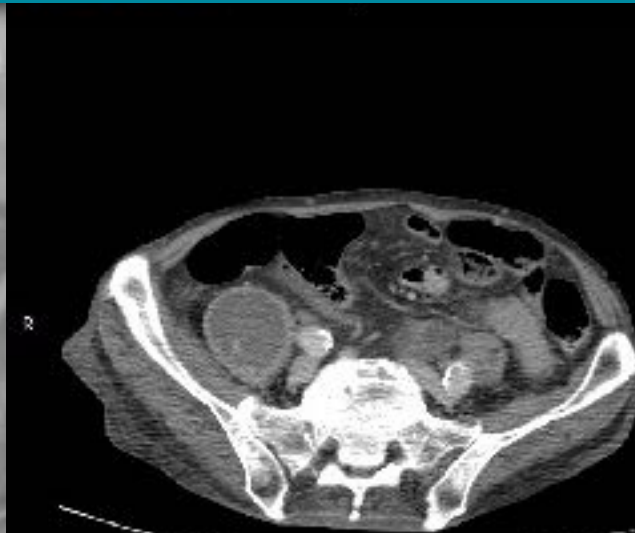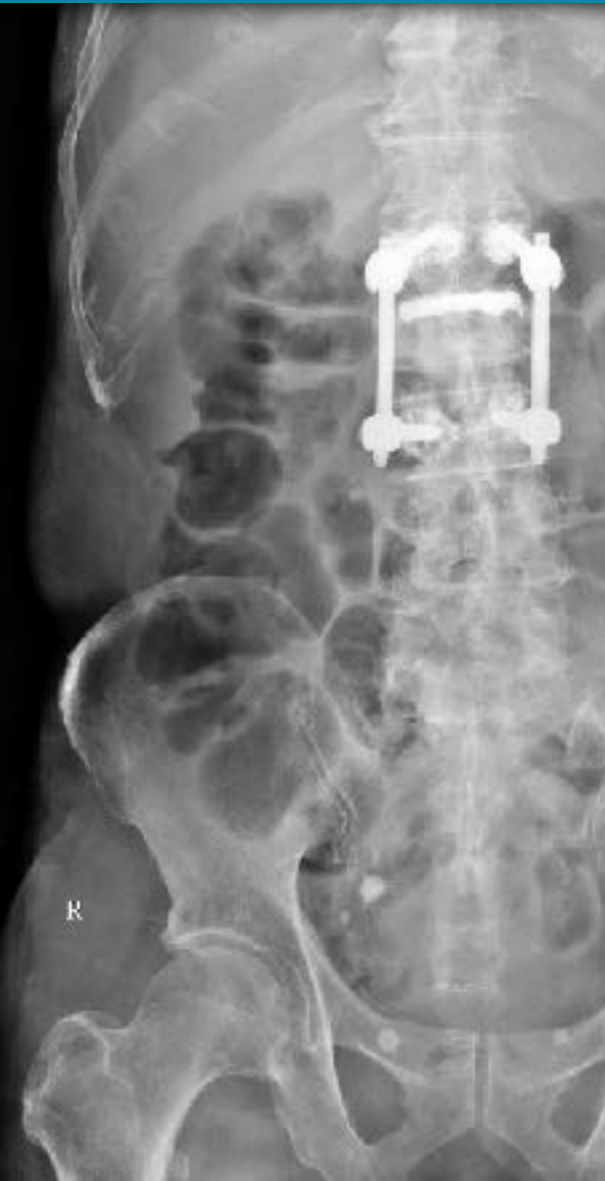KV.
msec
AI G:

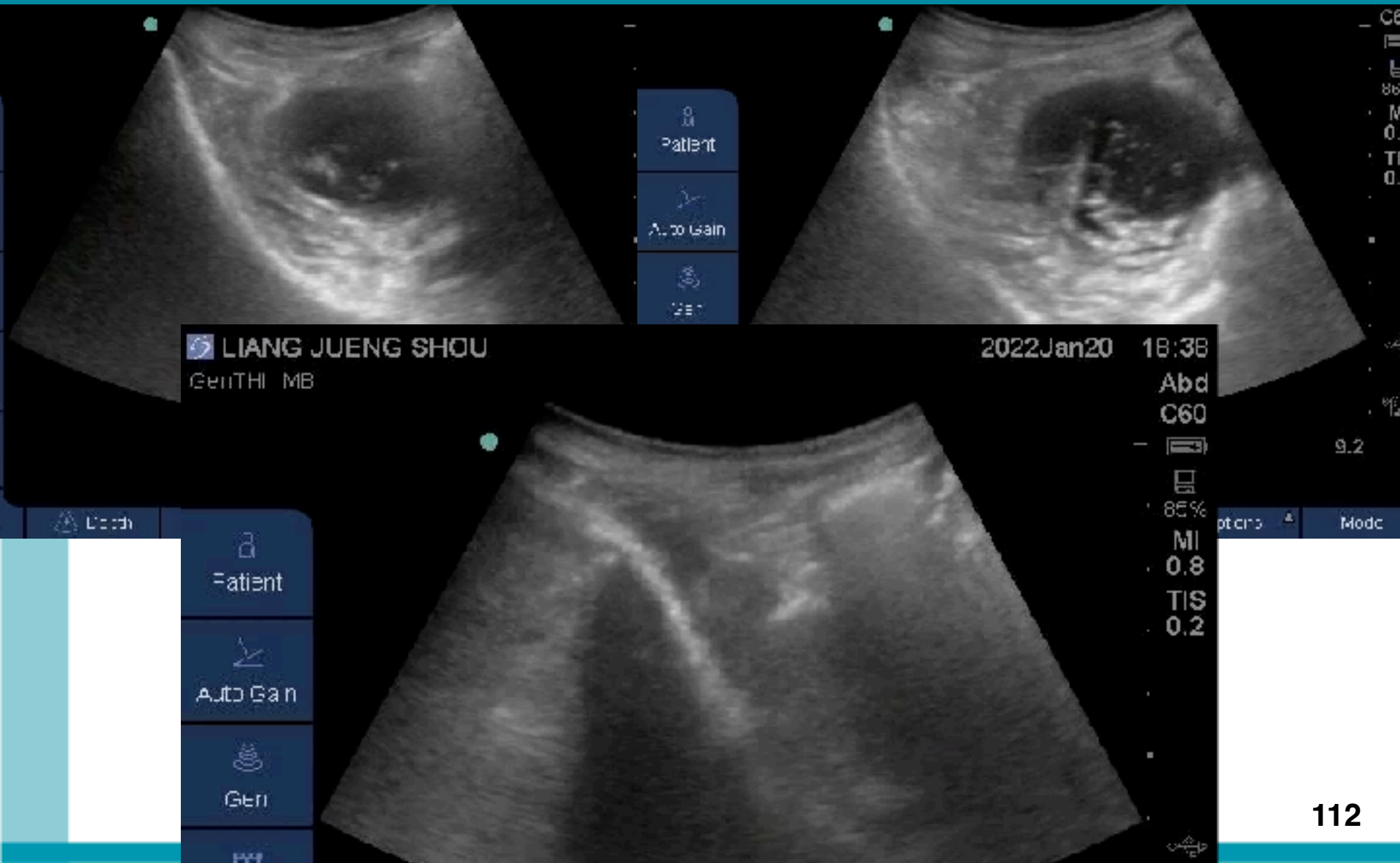


KV.
n:sec
AI G:

85, Psoas muscle abscess

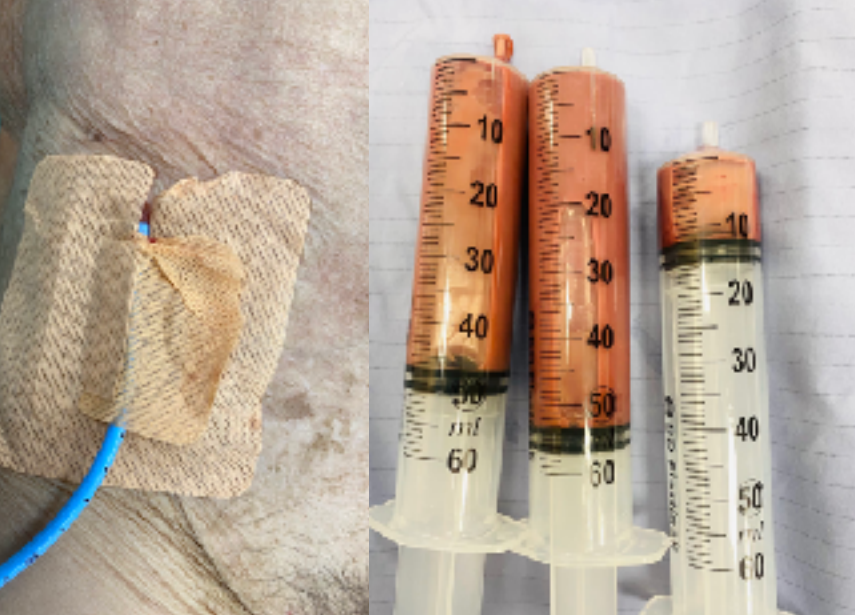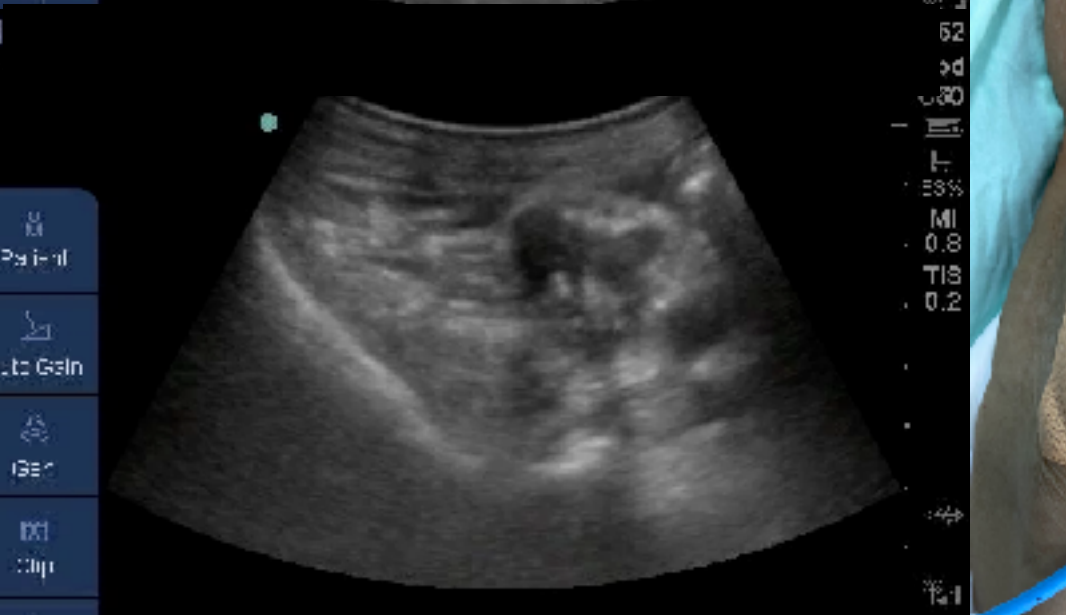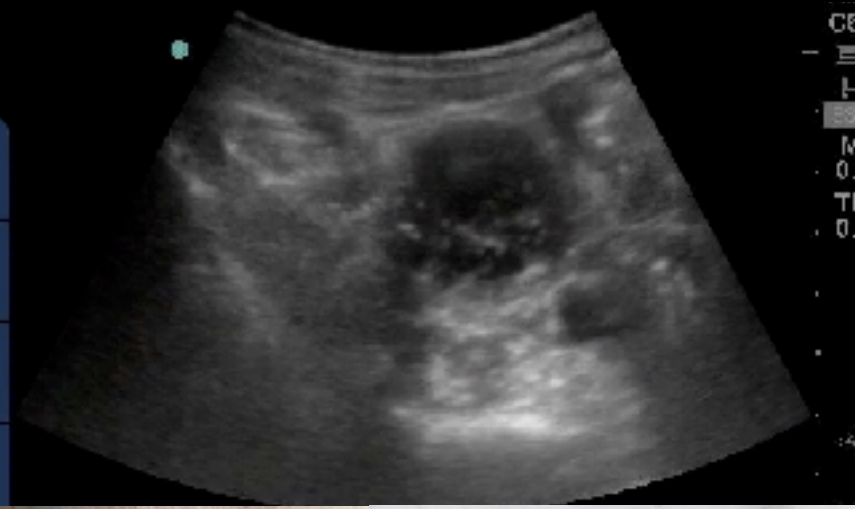


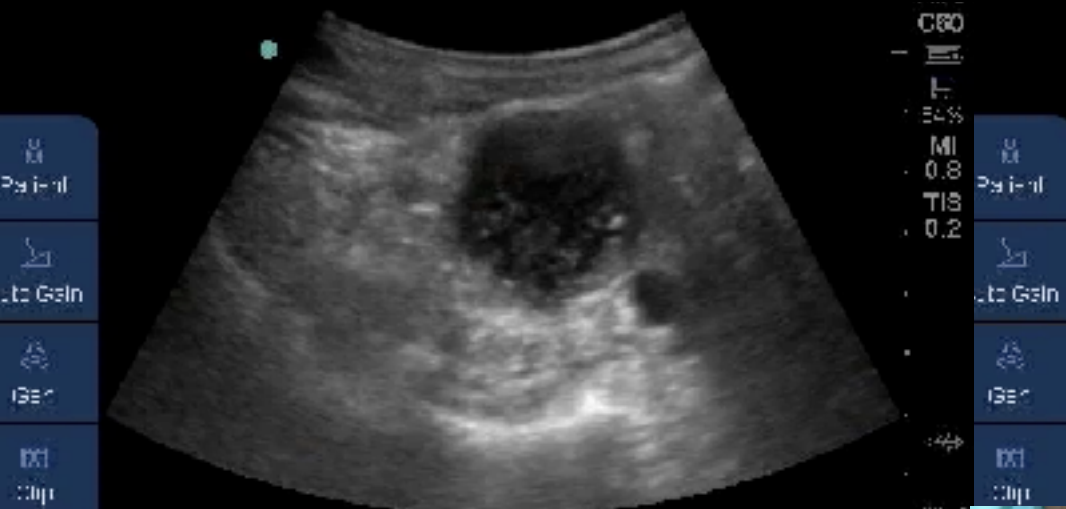85, Psoas muscle abscess

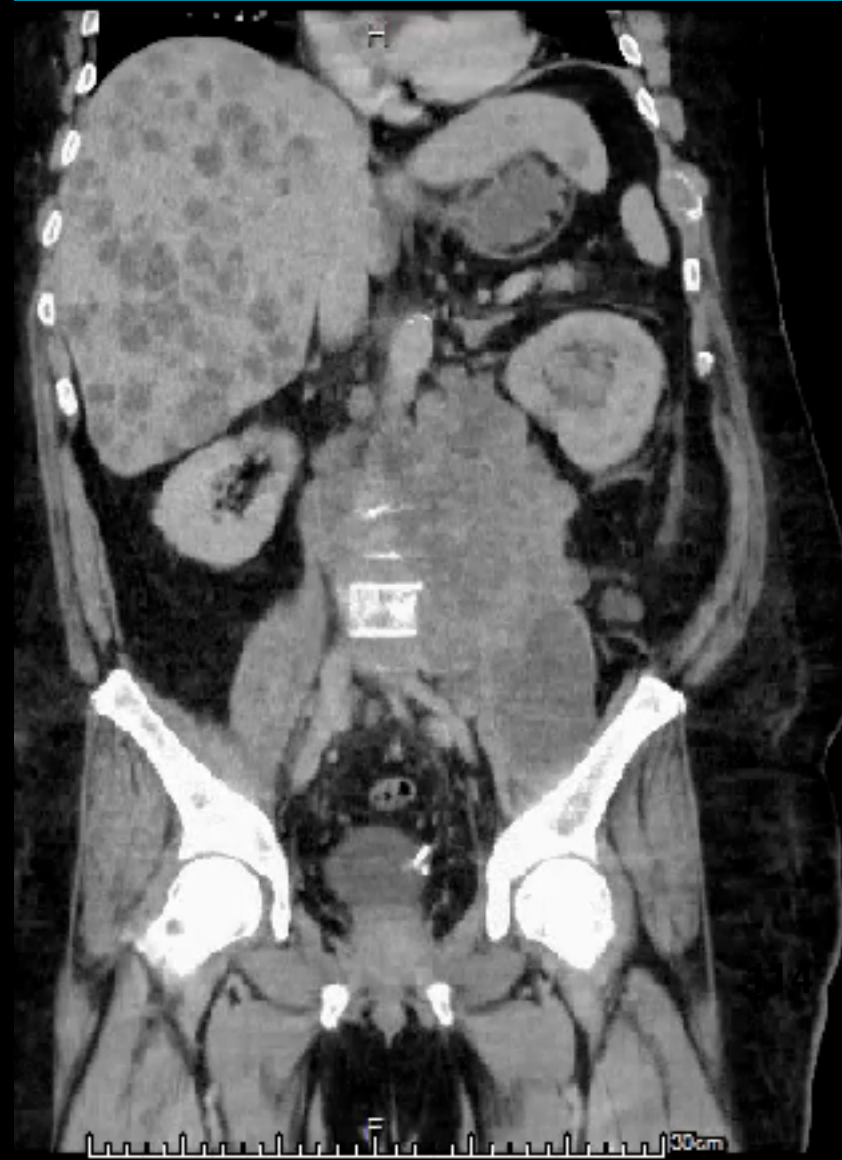
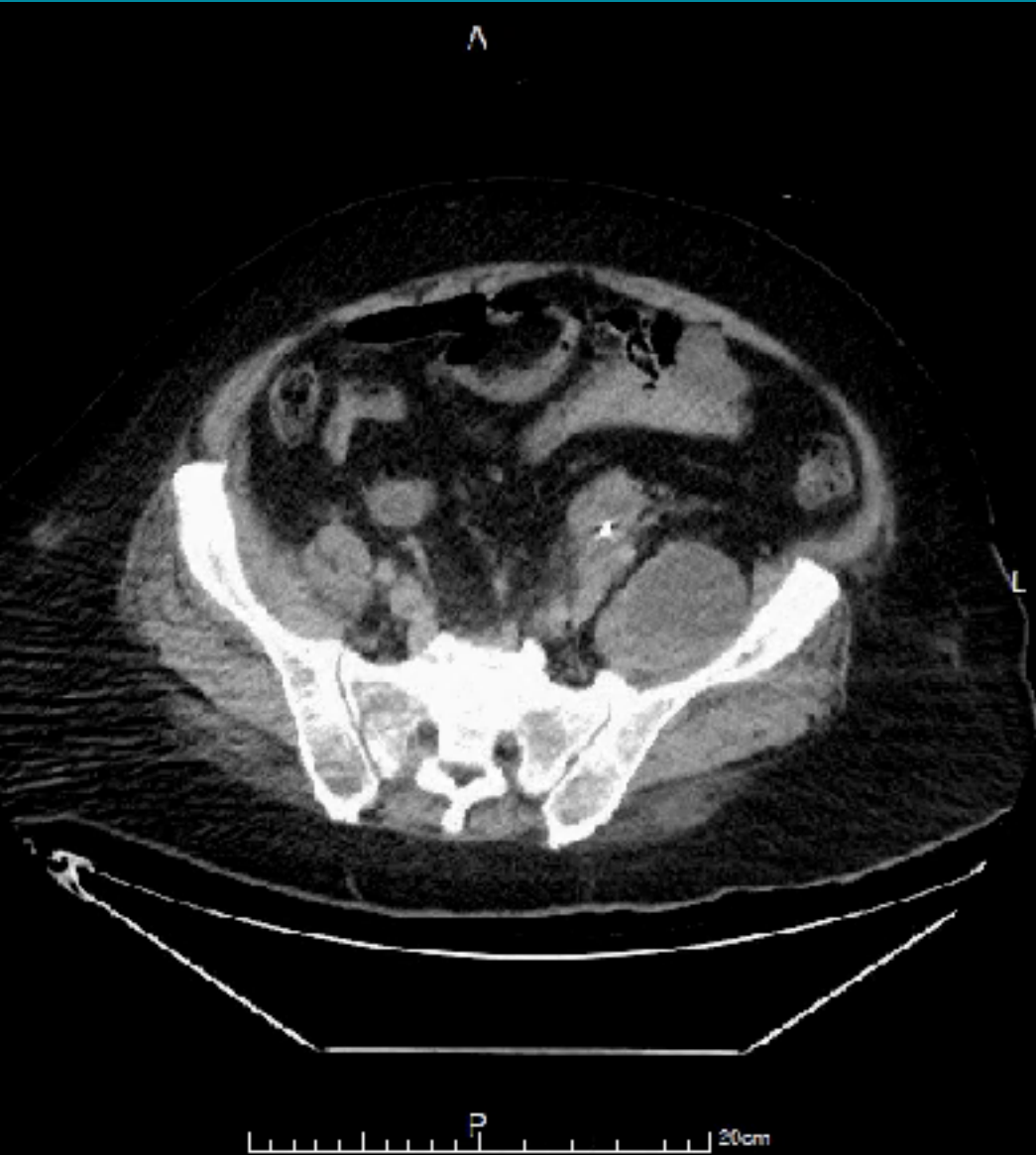
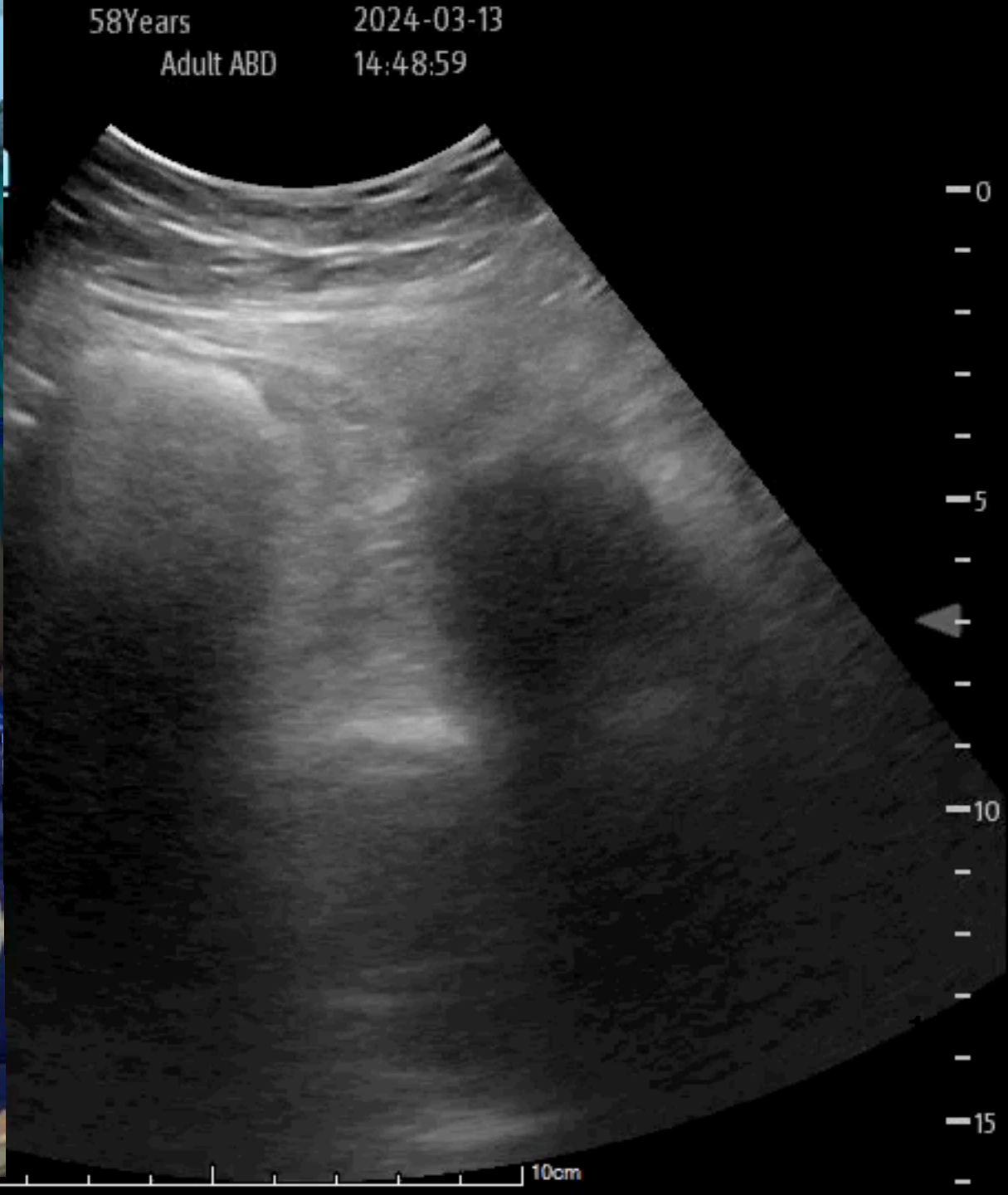


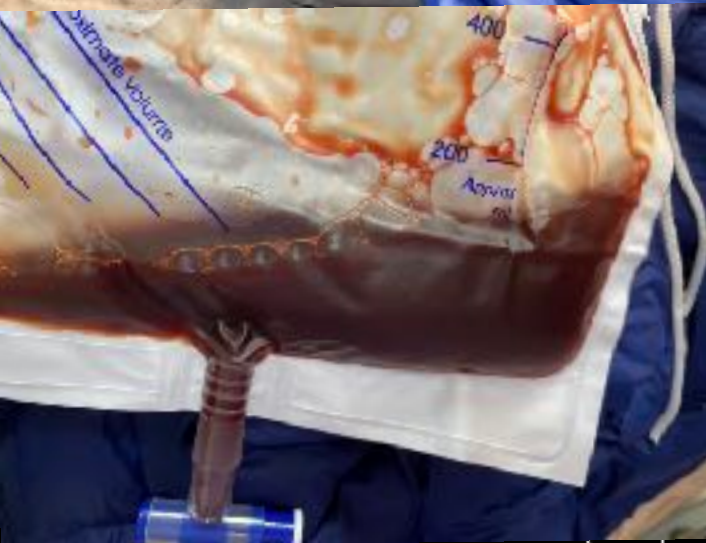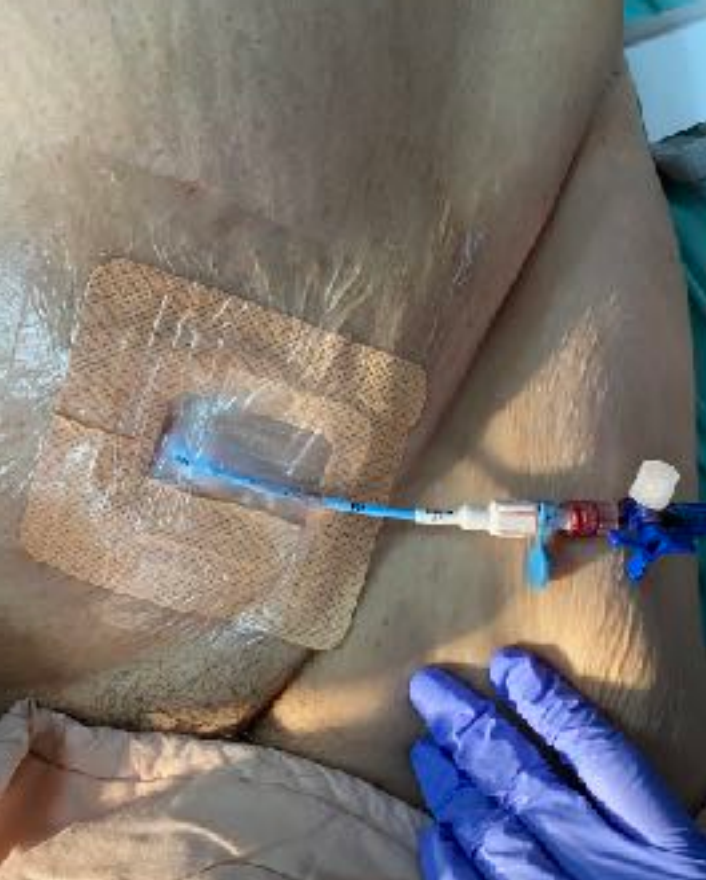14F pigtail with stylet

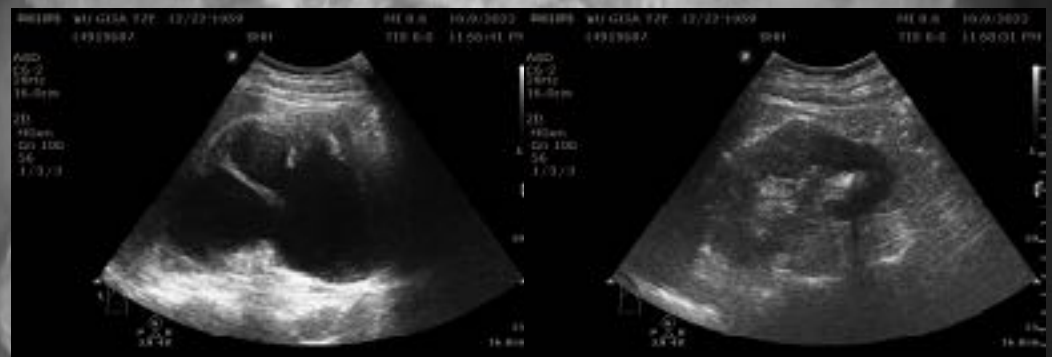
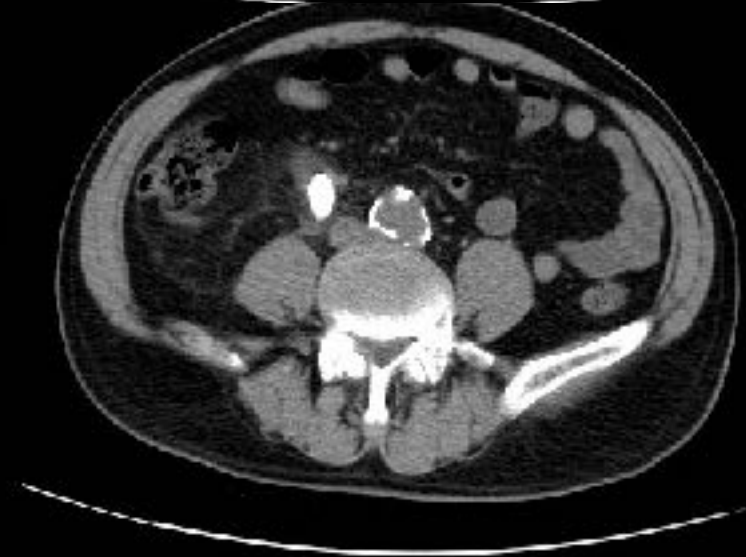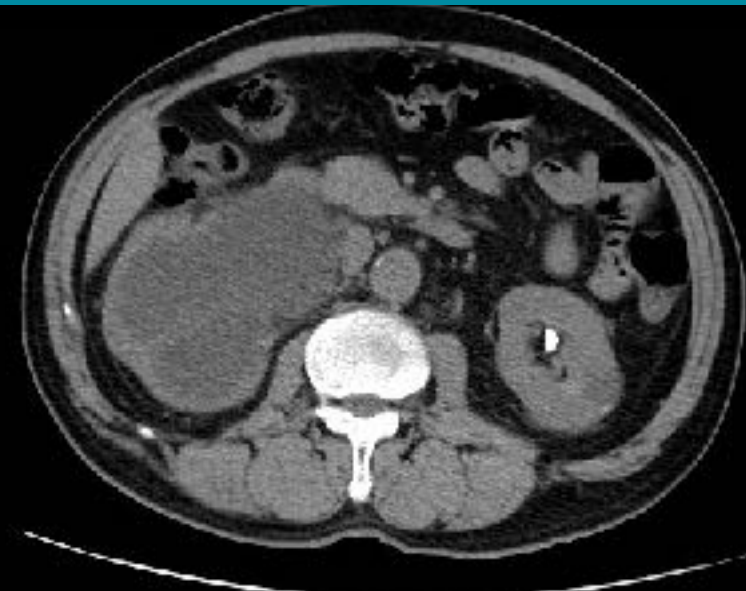

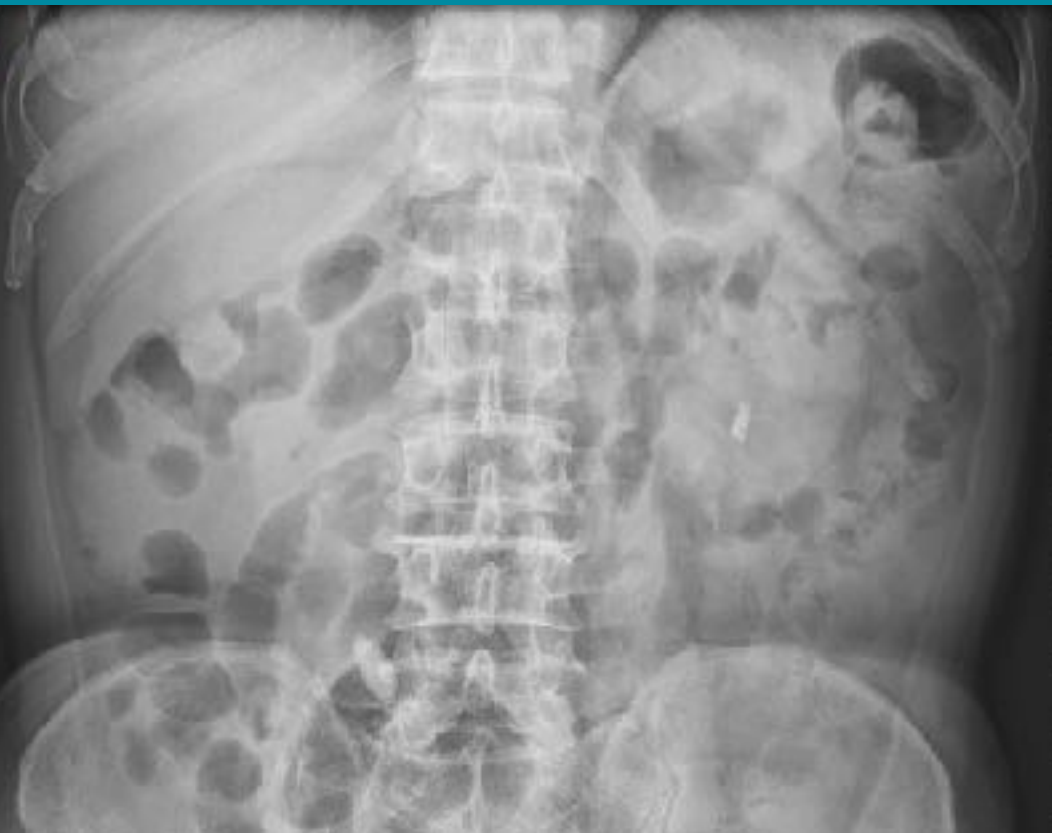
50M, left retroperitoneal lesion

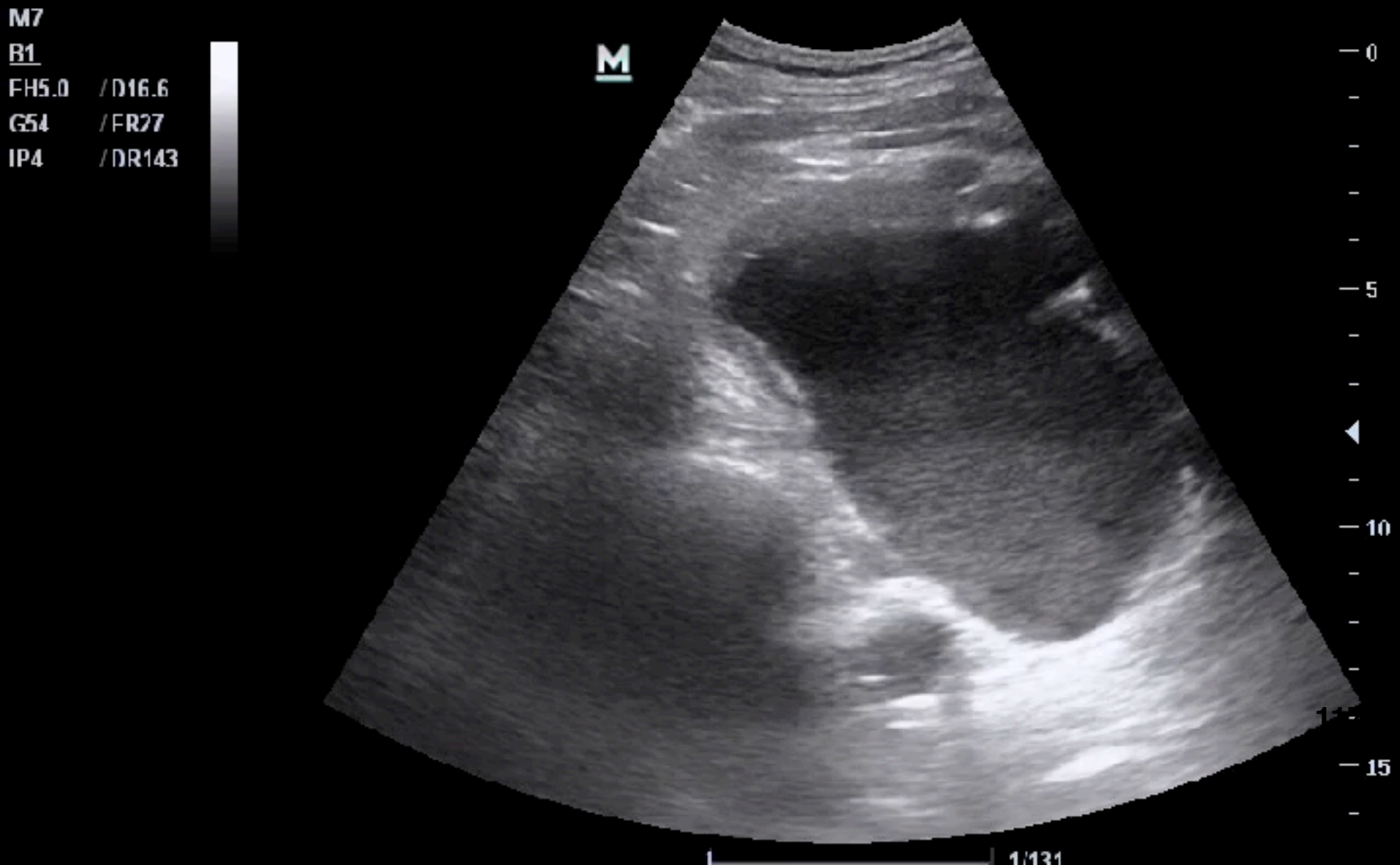


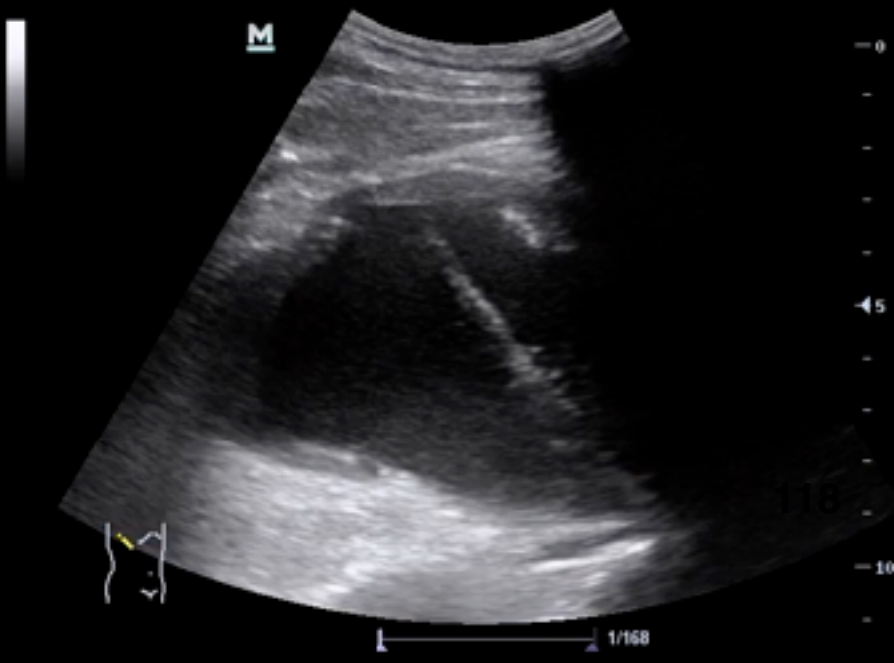
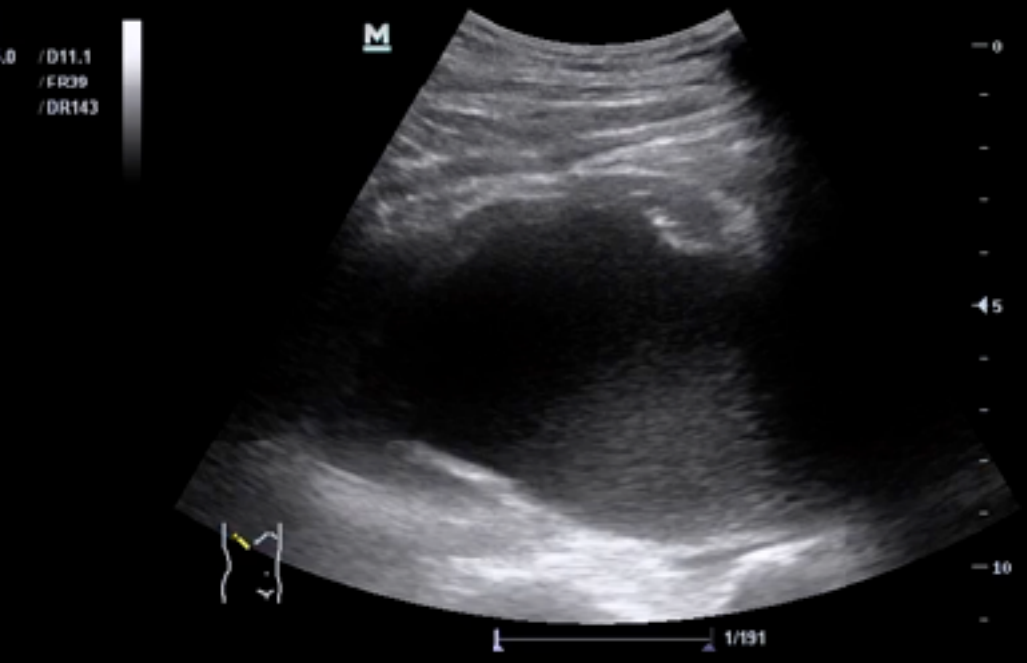
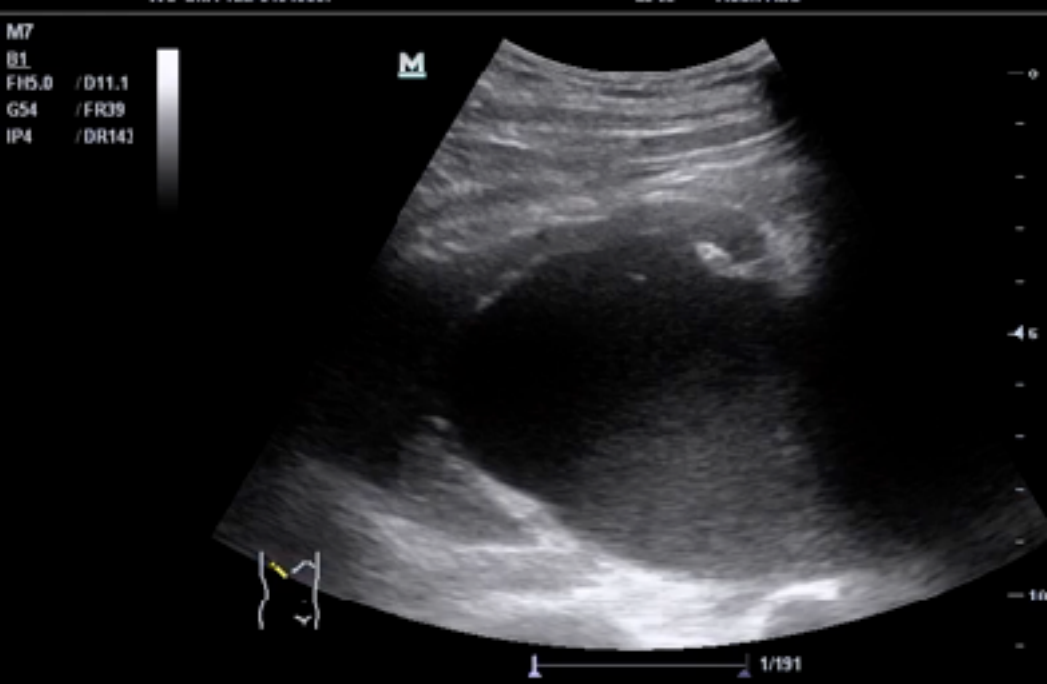
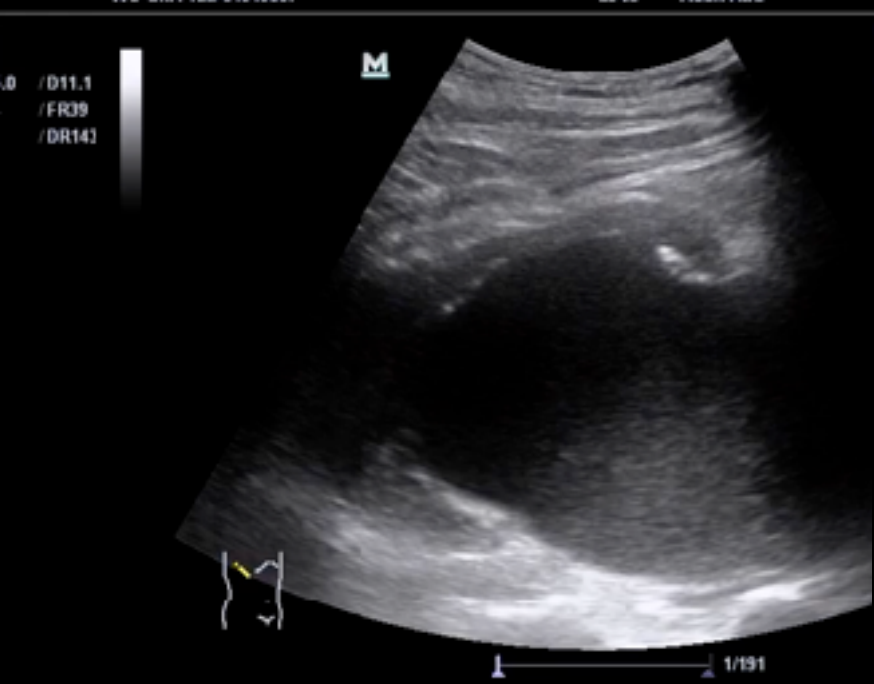


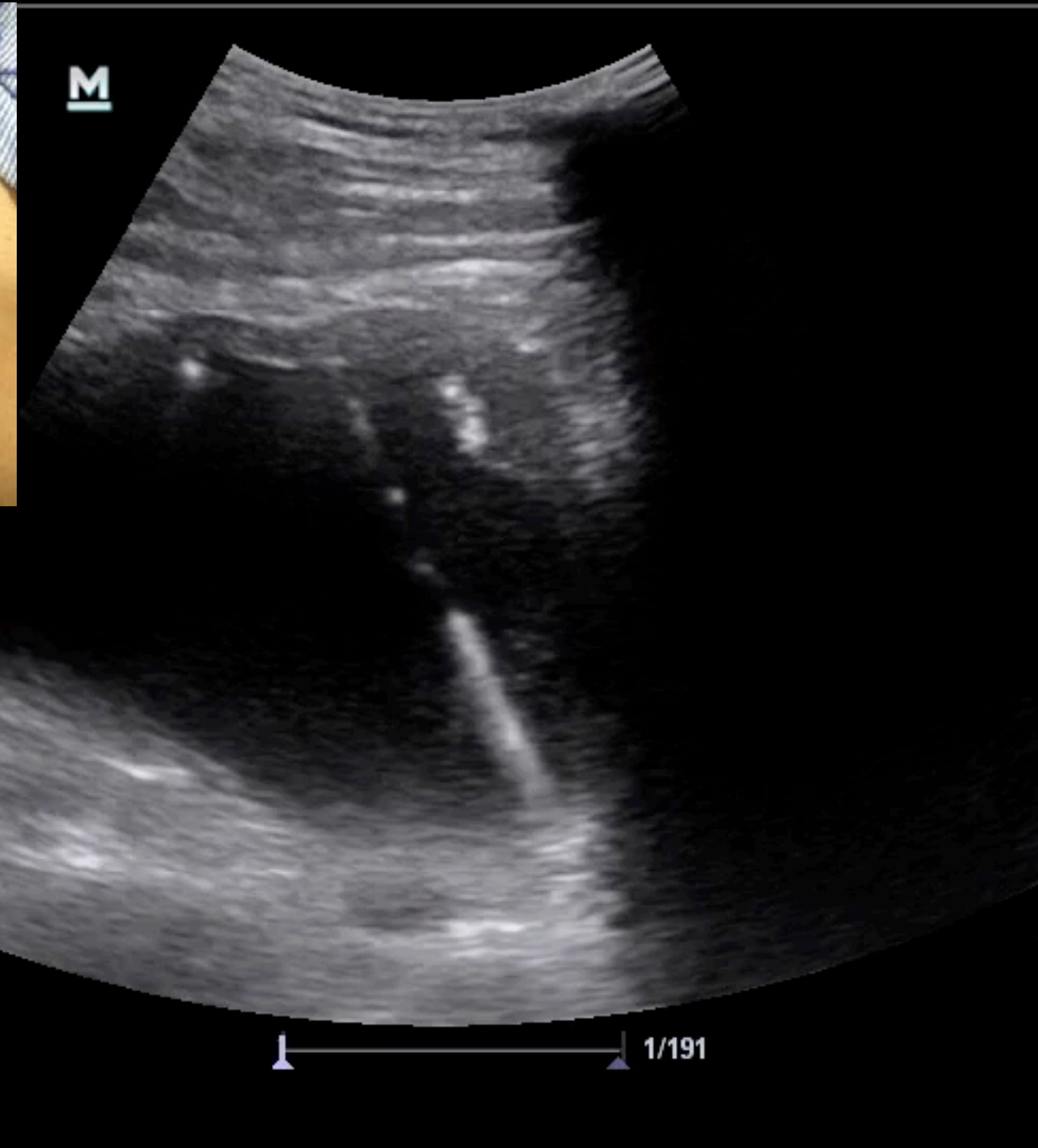
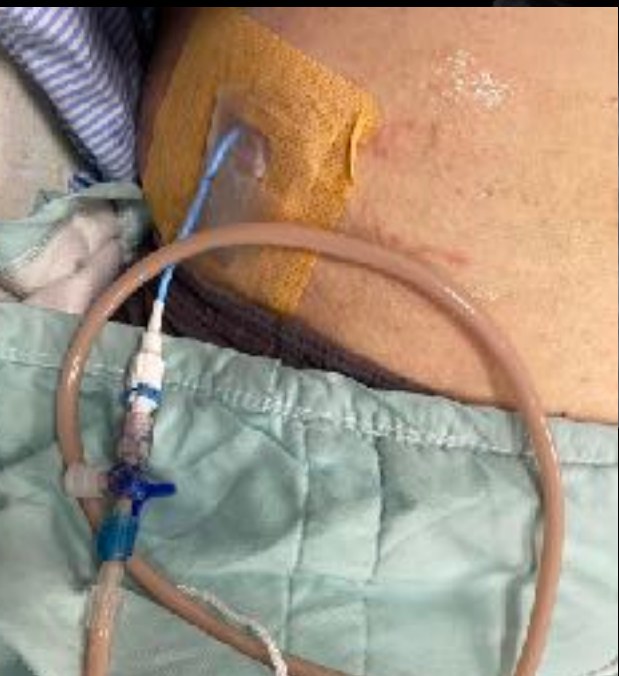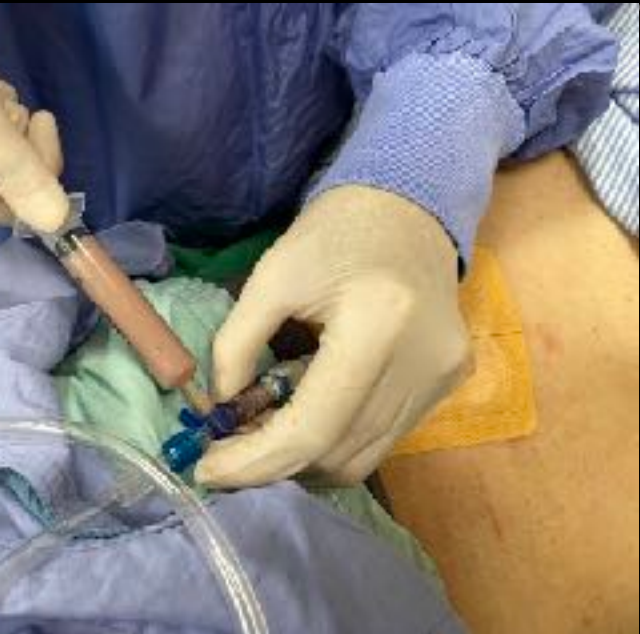62M, 腹痛



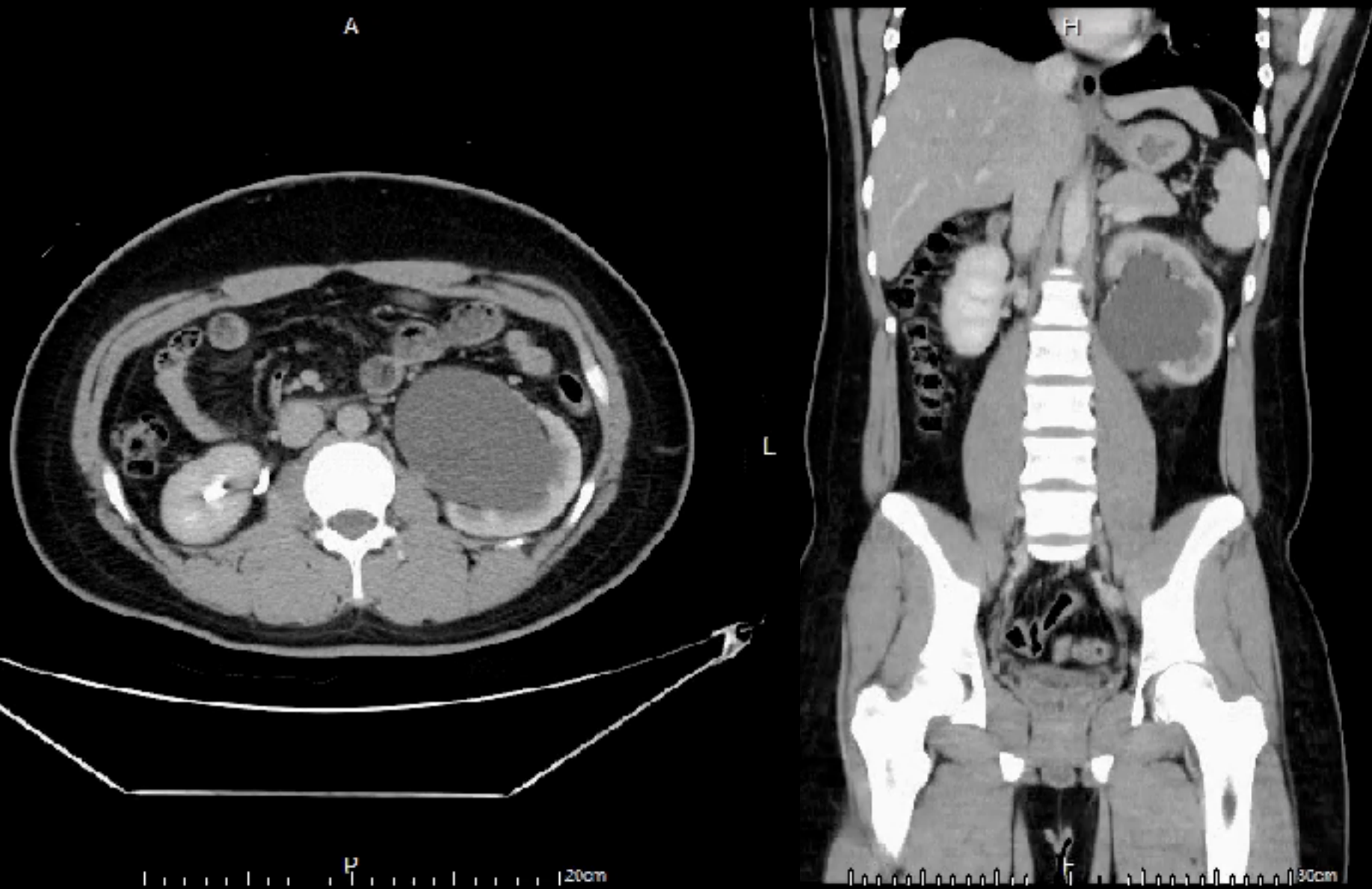
PCN for severe pyonephrosis







17M, L hydronephrosis



C5-2s AP 96.6% MI 0.88 TIS 0.6

0
30
3
0
0

m

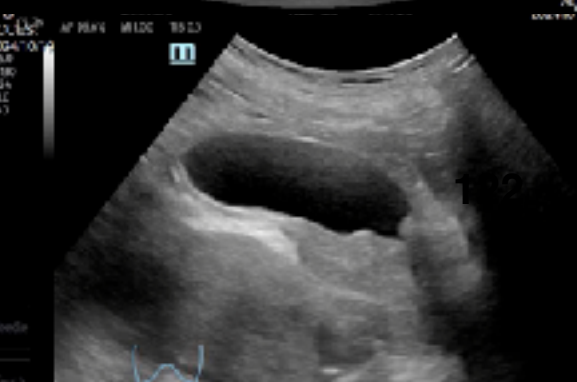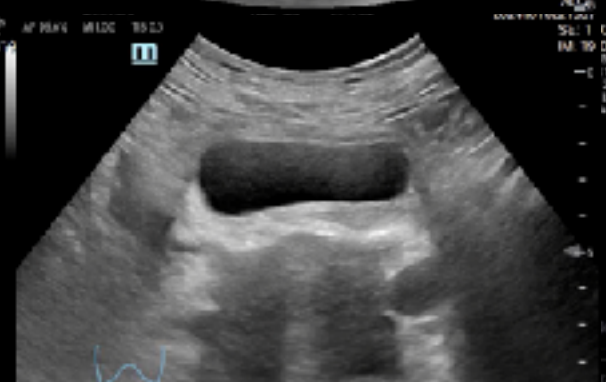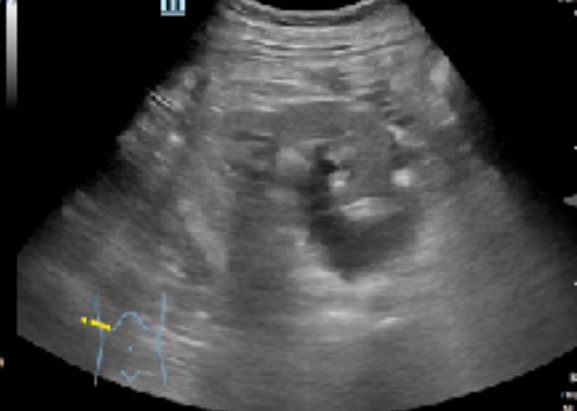
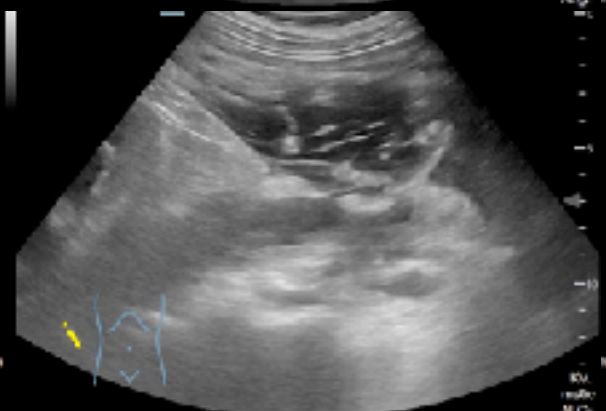
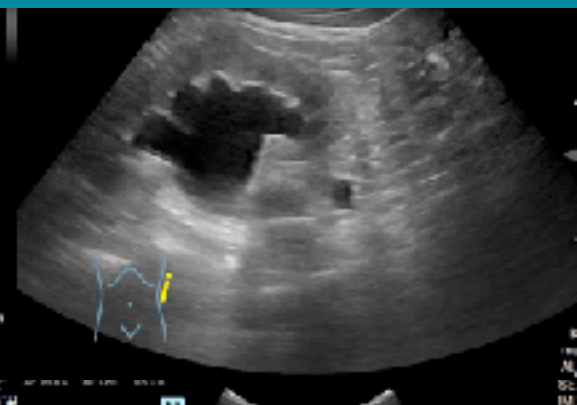
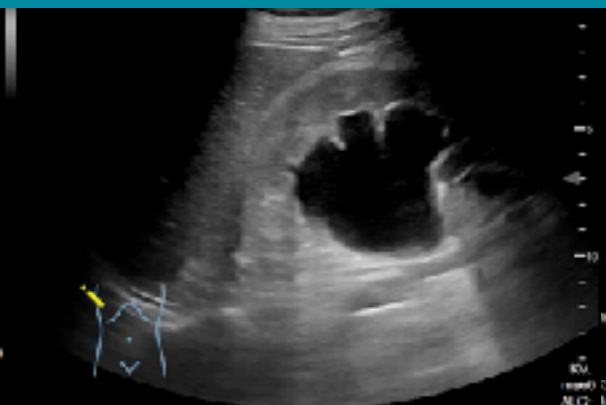
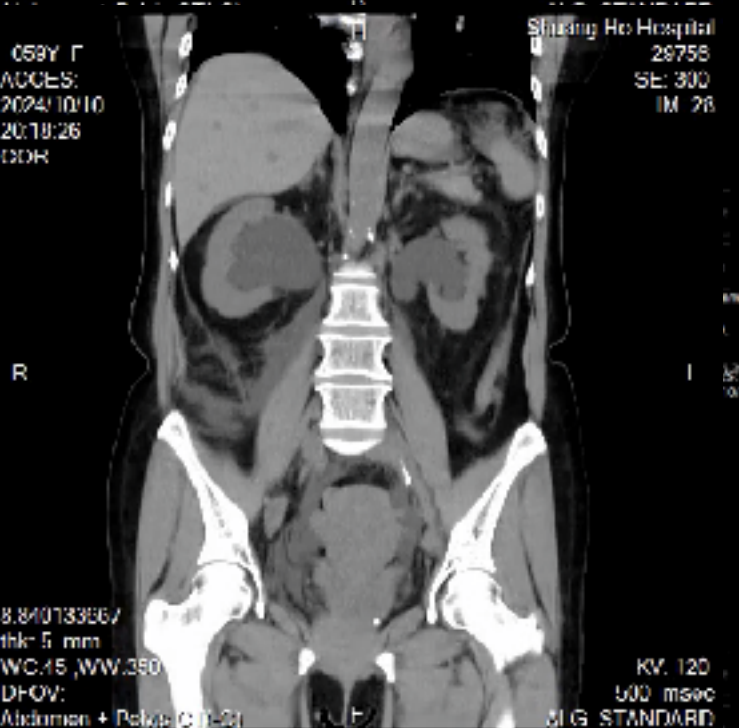
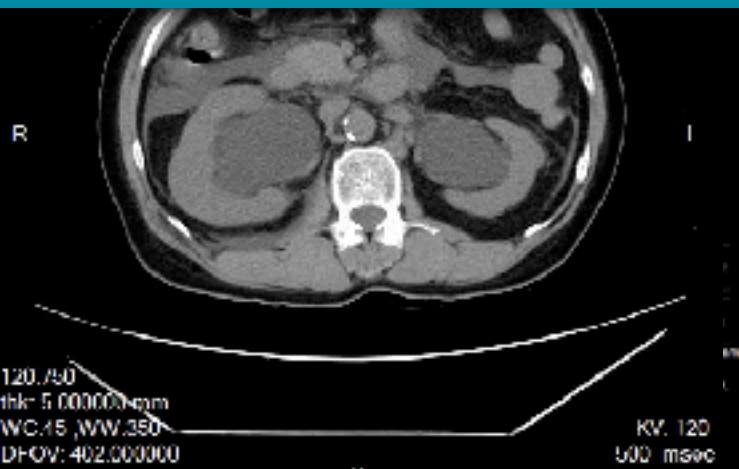
needle

touch



10cm

59F, RLQ pain & difficult voiding



Bilateral PCN

[Blood]

(10/12) Creatinine 4.02

(10/10) Creatinine 9.32

2024/10/10
FH5.0
DB 130
PF19007BER
FR 20
D14.0
G 40



IM: 0

-0

-

-

-

-

-5



-

-

-

-10

123

-

KV:

mAs

iNeedle

iTouch

thk: mm
PF19007BER
DEOV:



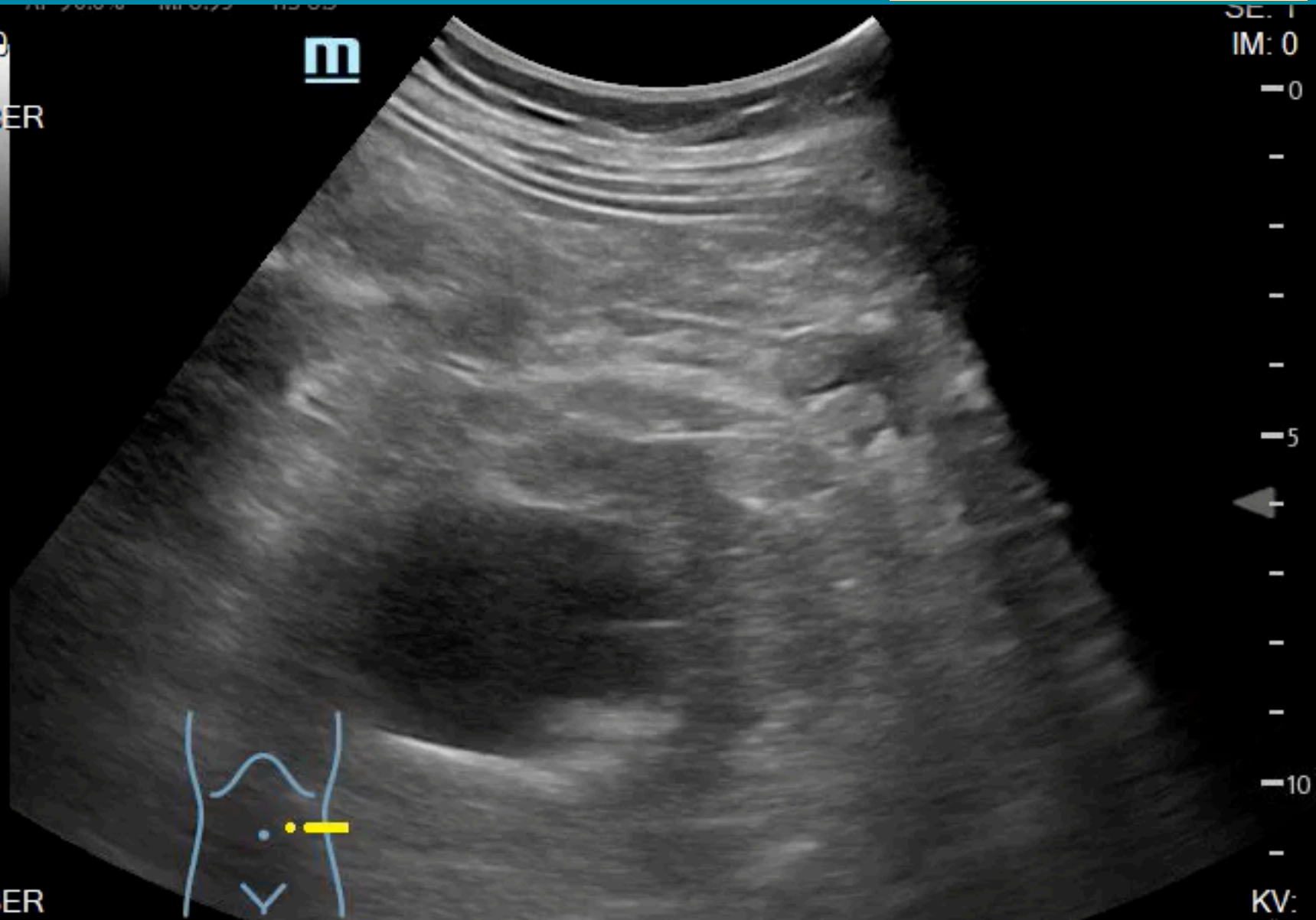
Bilateral PCN

[Blood]

(10/12) Creatinine 4.02

(10/10) Creatinine 9.32

ACCES.
2024/10/10
FH5.0
DB 130
PF19007BER
PR 21
D 13.0
G 40



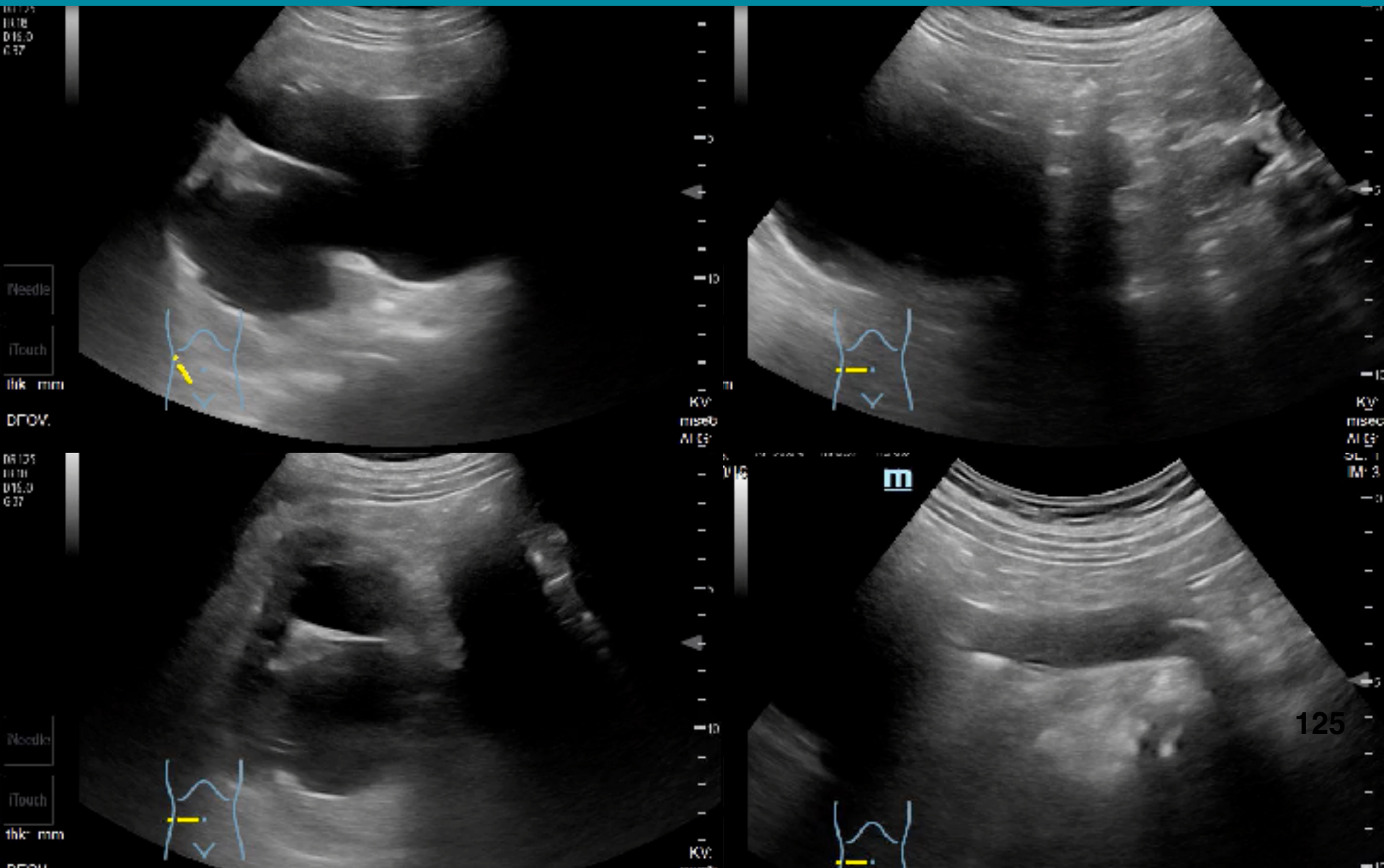
iNeedle

iTouch

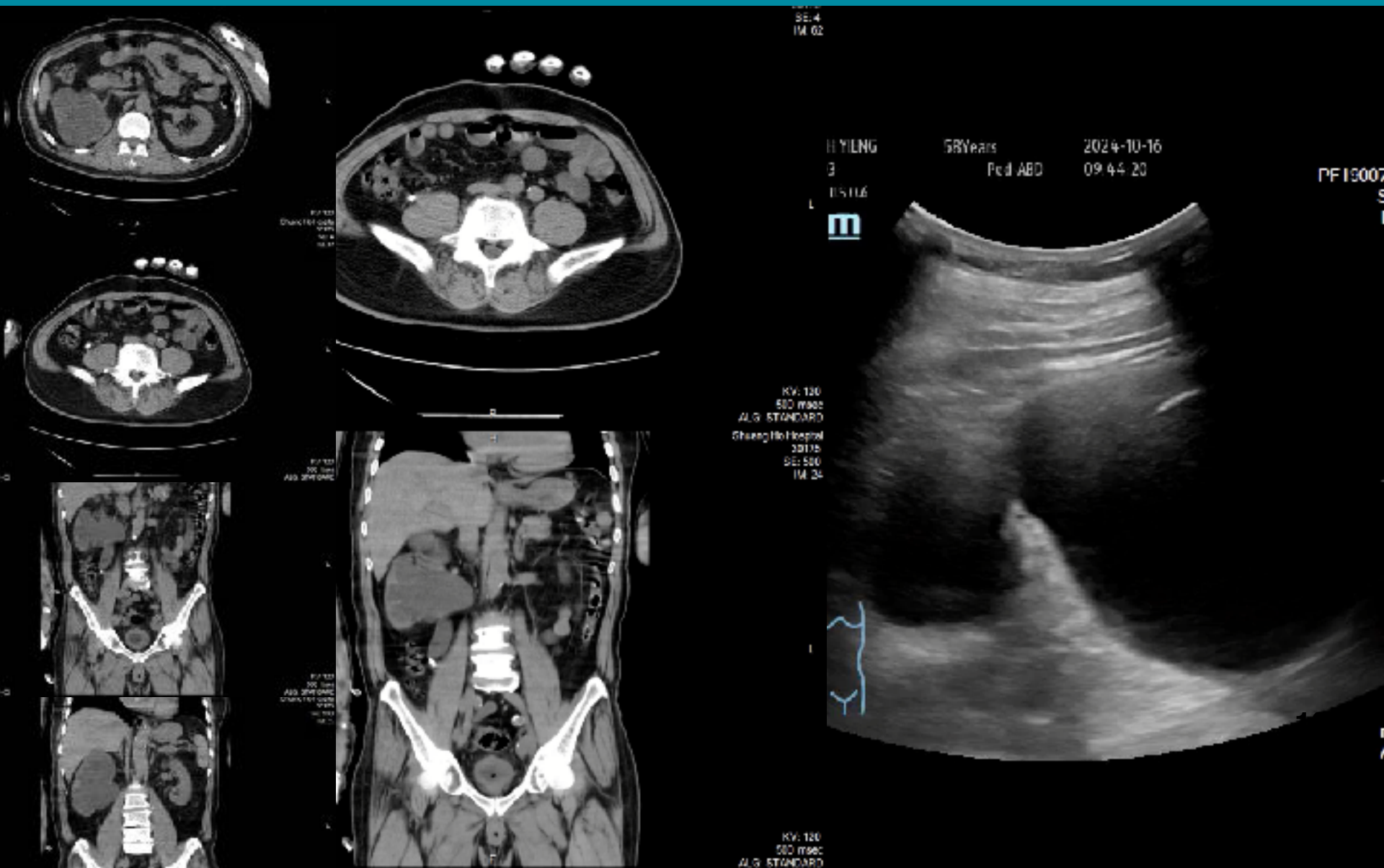
thk: mm
PF19007BER

KV:


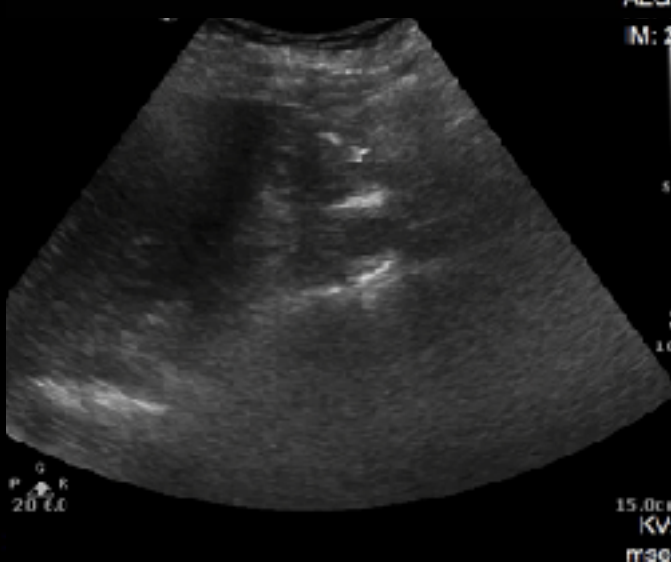
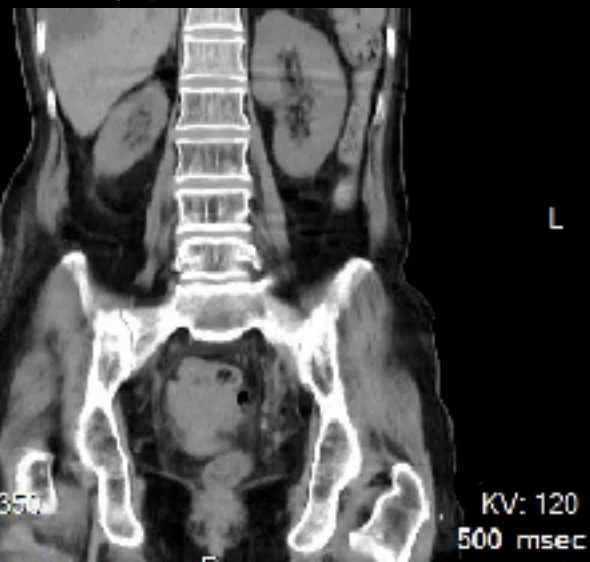
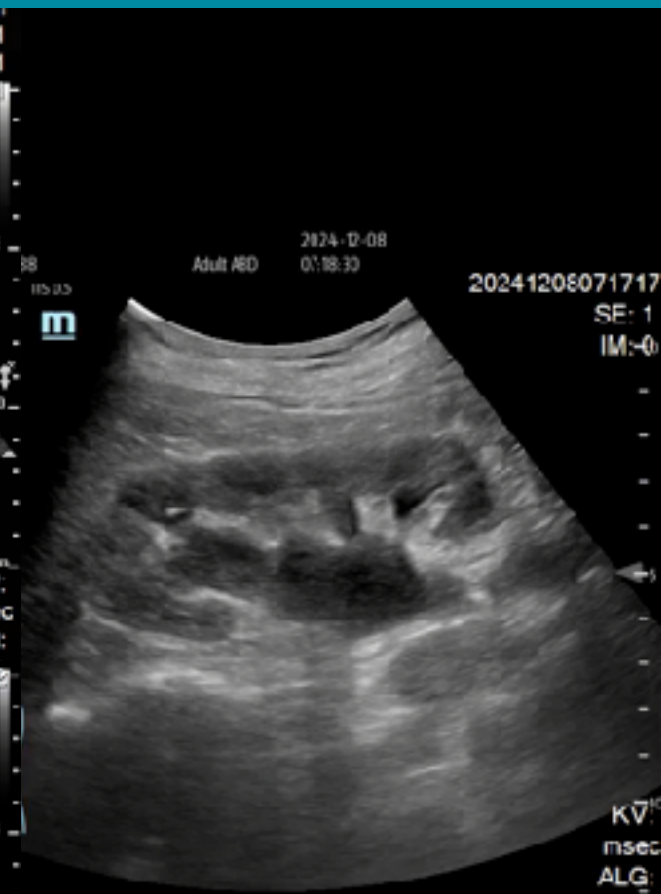
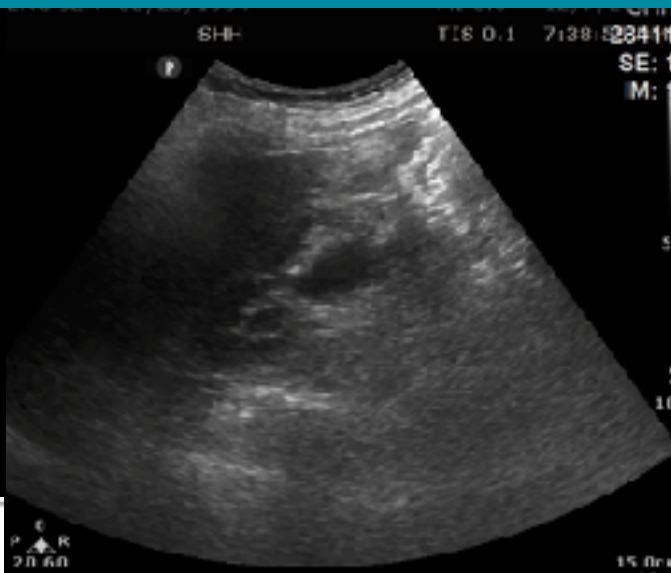
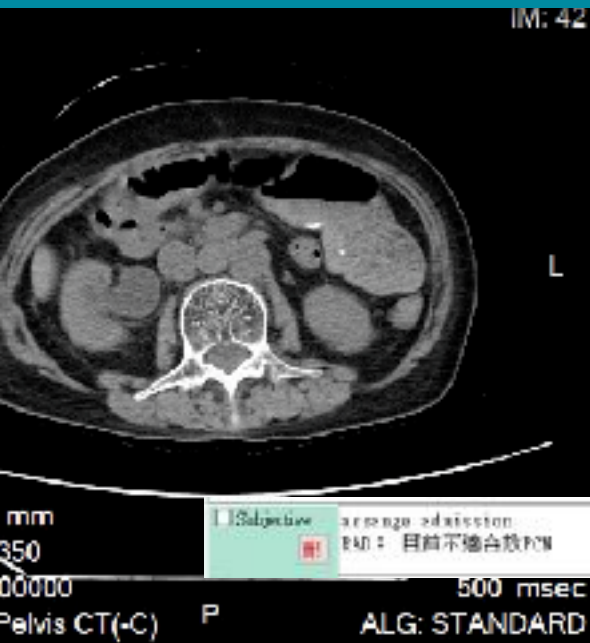
58F, nursing home, BT 40



UPJ stone with obstructive uropathy



70F, PCN夾到車門後滑脫



PCN by CR Lu then discharge

ACCESS:
FH5.0
2024/12/08
FR 24
D 11.0
PF19007BER



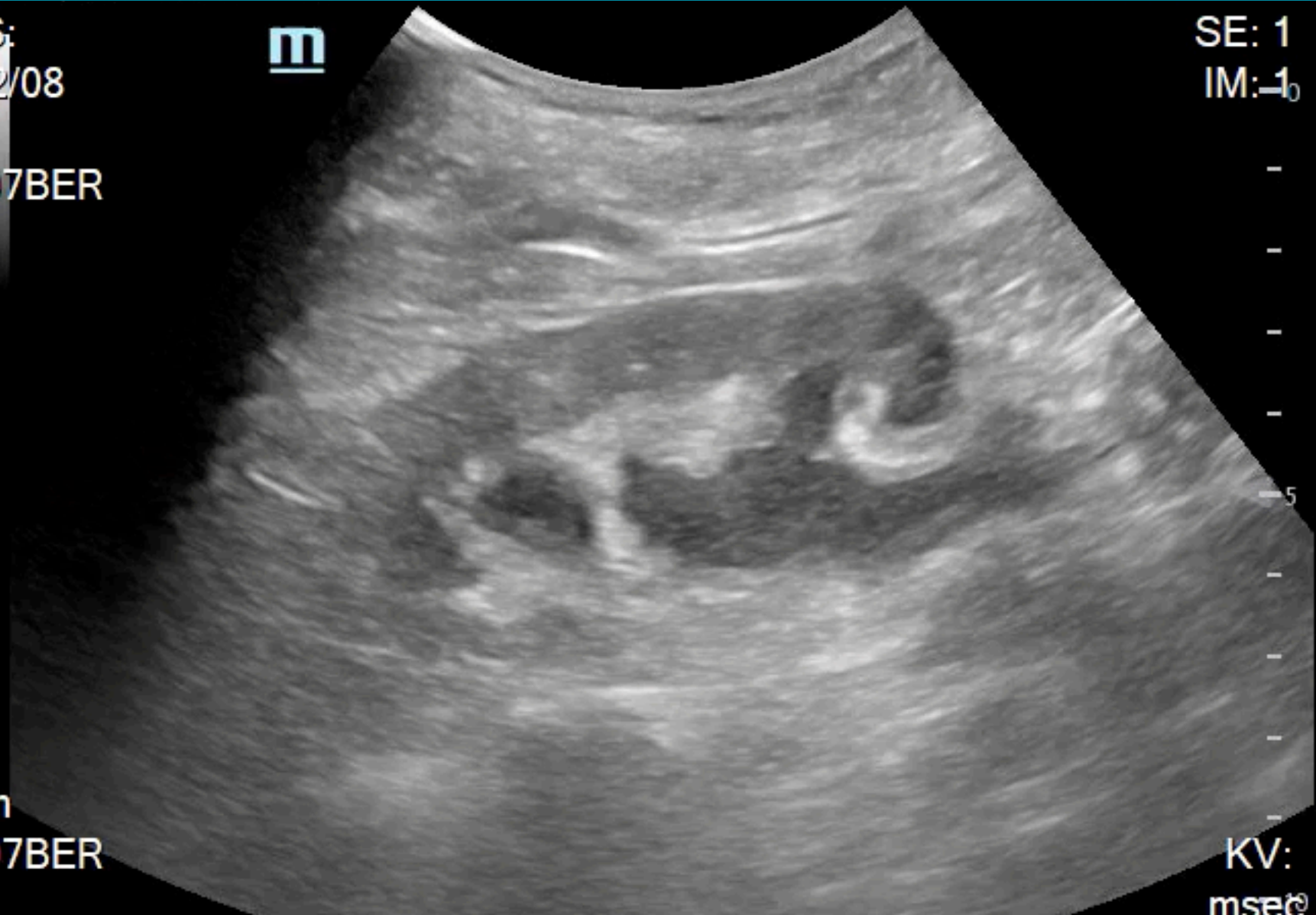
SE: 1
IM: 10

iNeedle

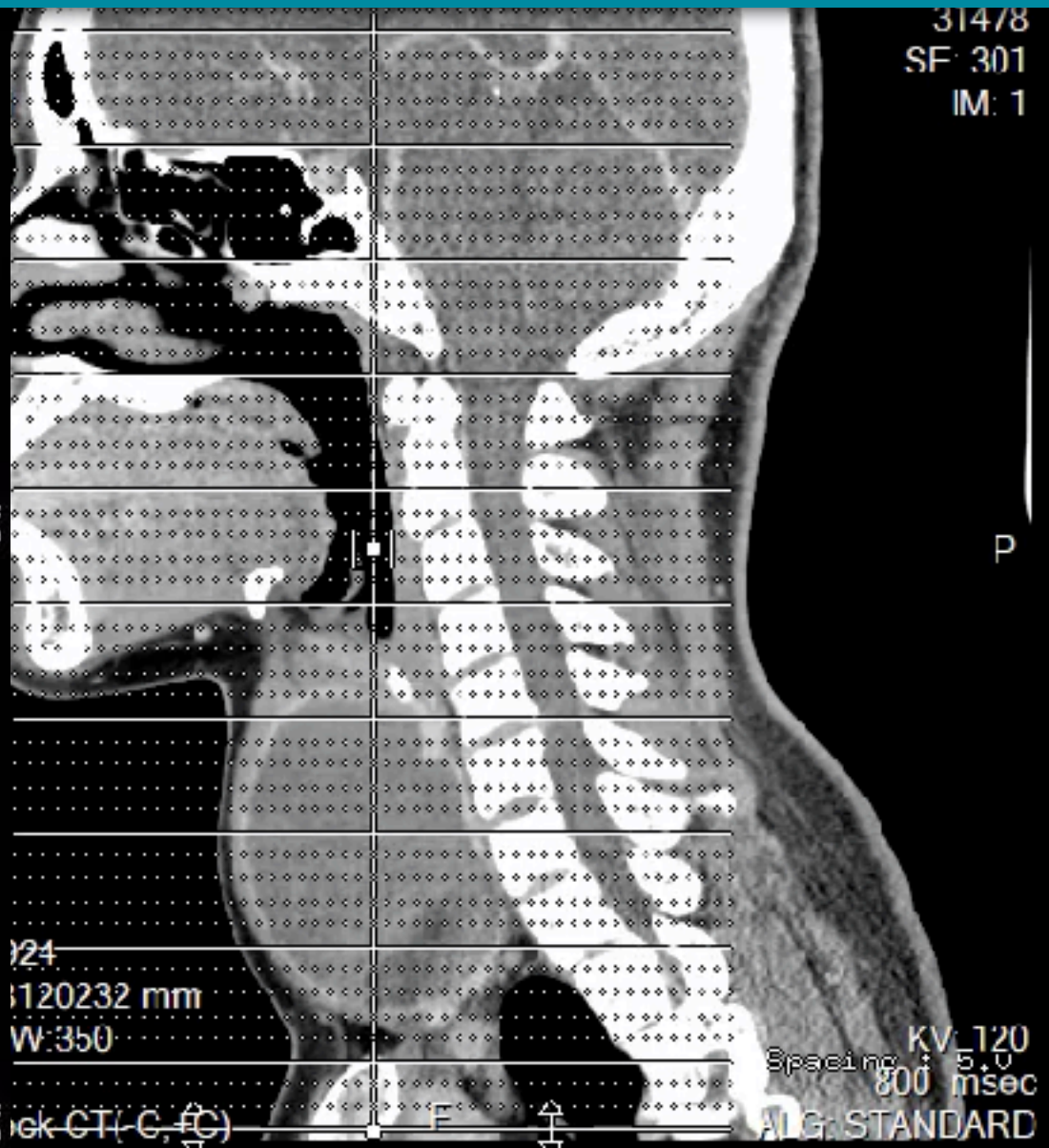
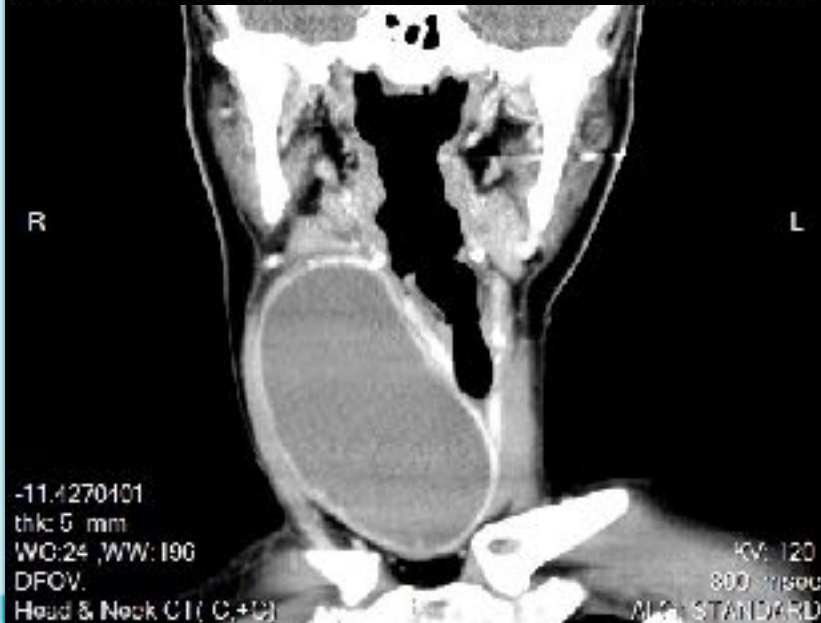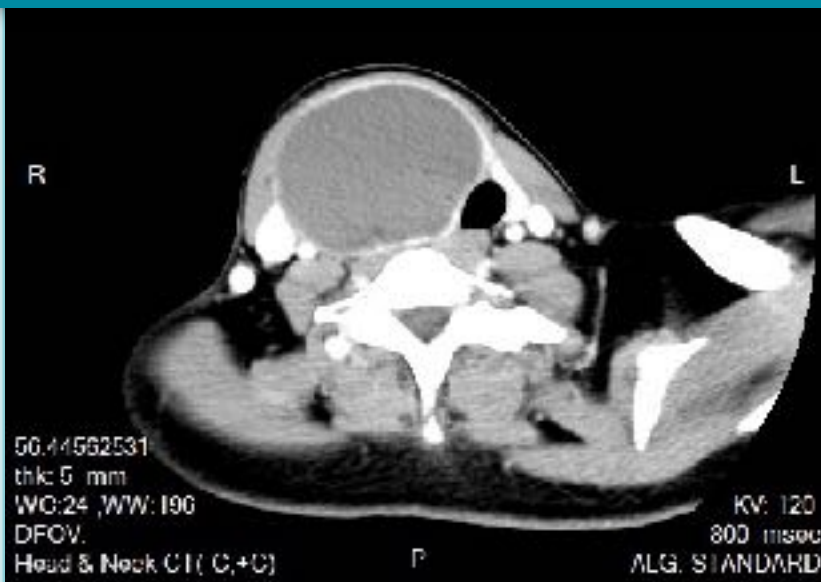iTouch

thk: mm
PF19007BER
DFOV:

KV:
msec®

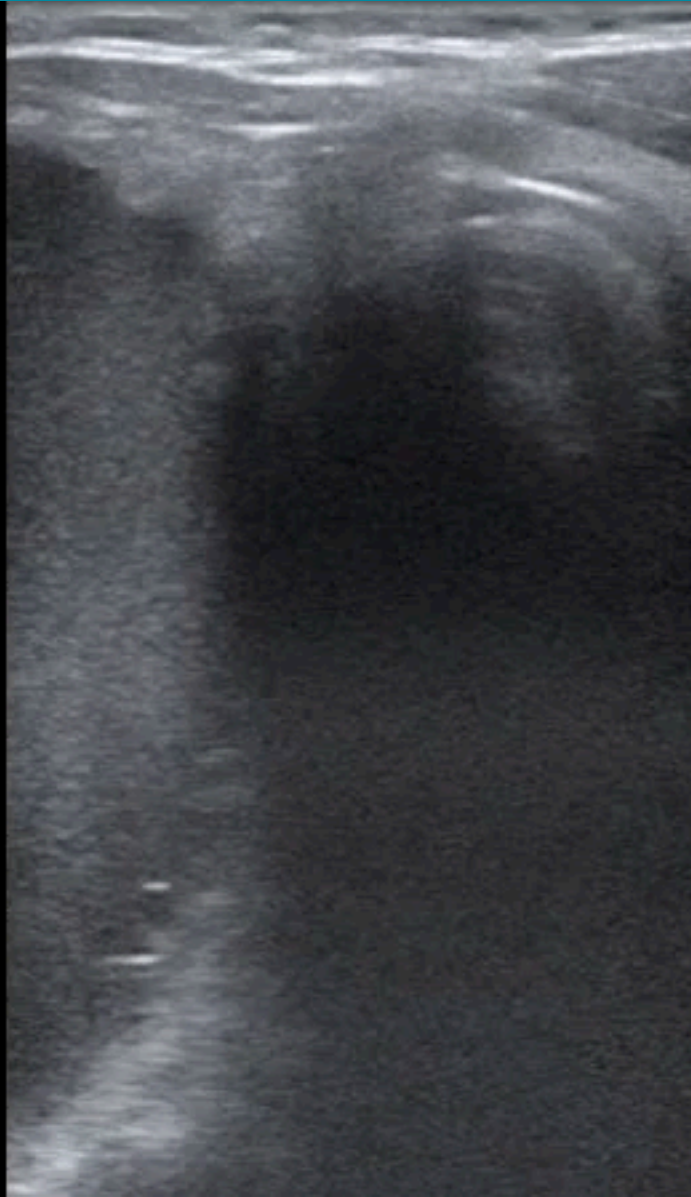


31F, Thyroid cyst hx, neck swelling & dyspnea



Right thyroid huge cyst

2024/10/31
FH9.0
DB 105
PF19005CER
FR 21
D7.0
G 68



IM: 6



iNeedle

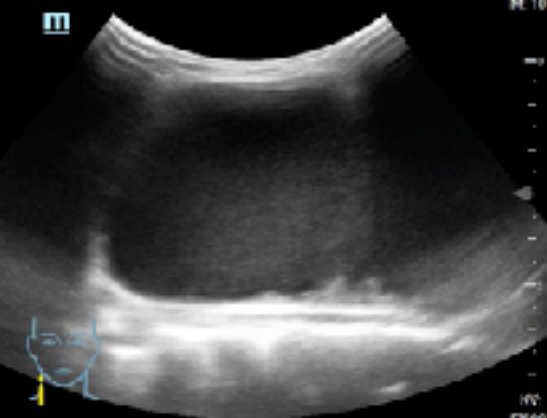
iTouch

thk: mm
PF19005CER
DEOV:



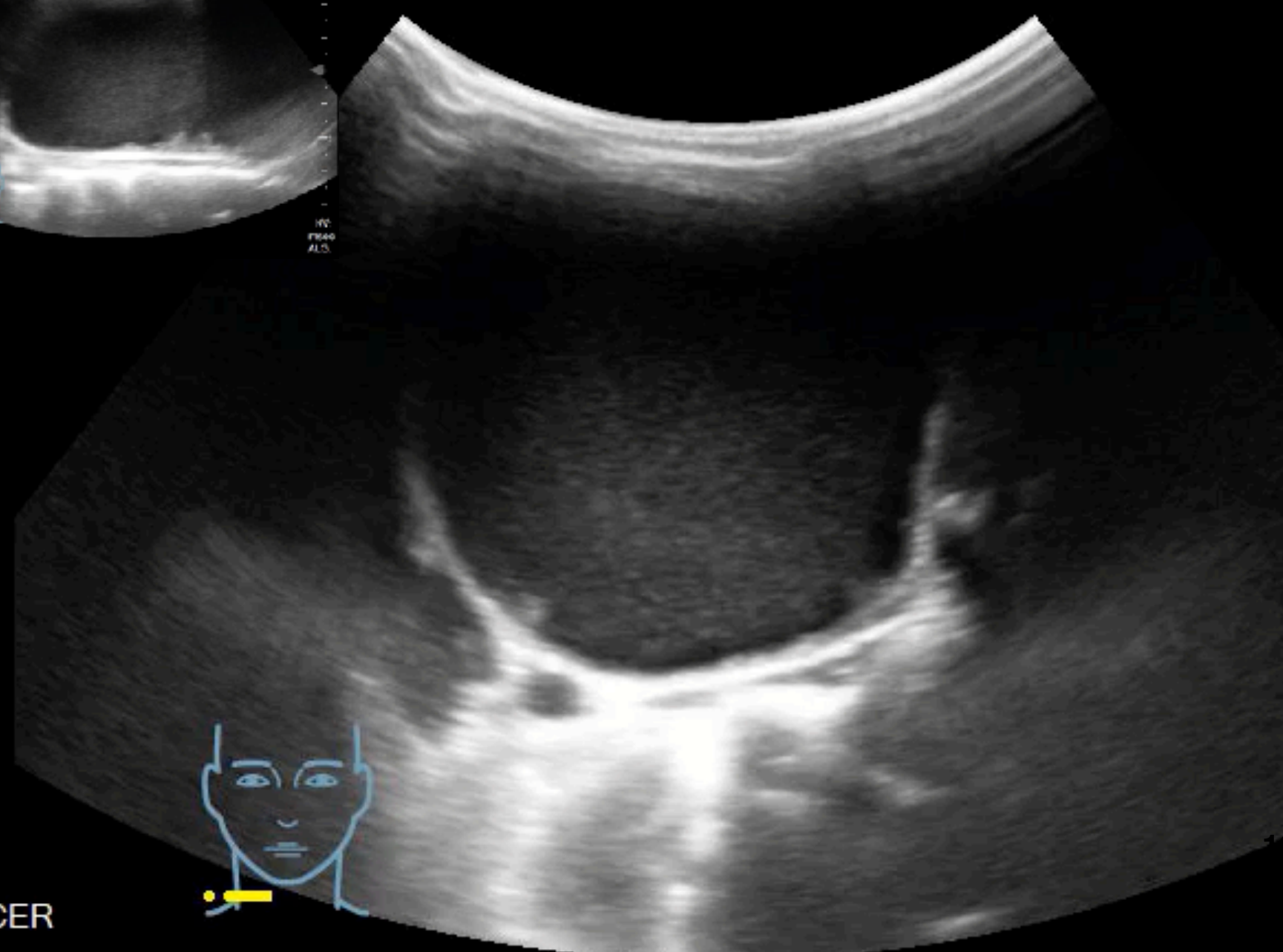
-5

KV:
msec



0.4

100
cm
AL5



le

h

mm
005CER
V:

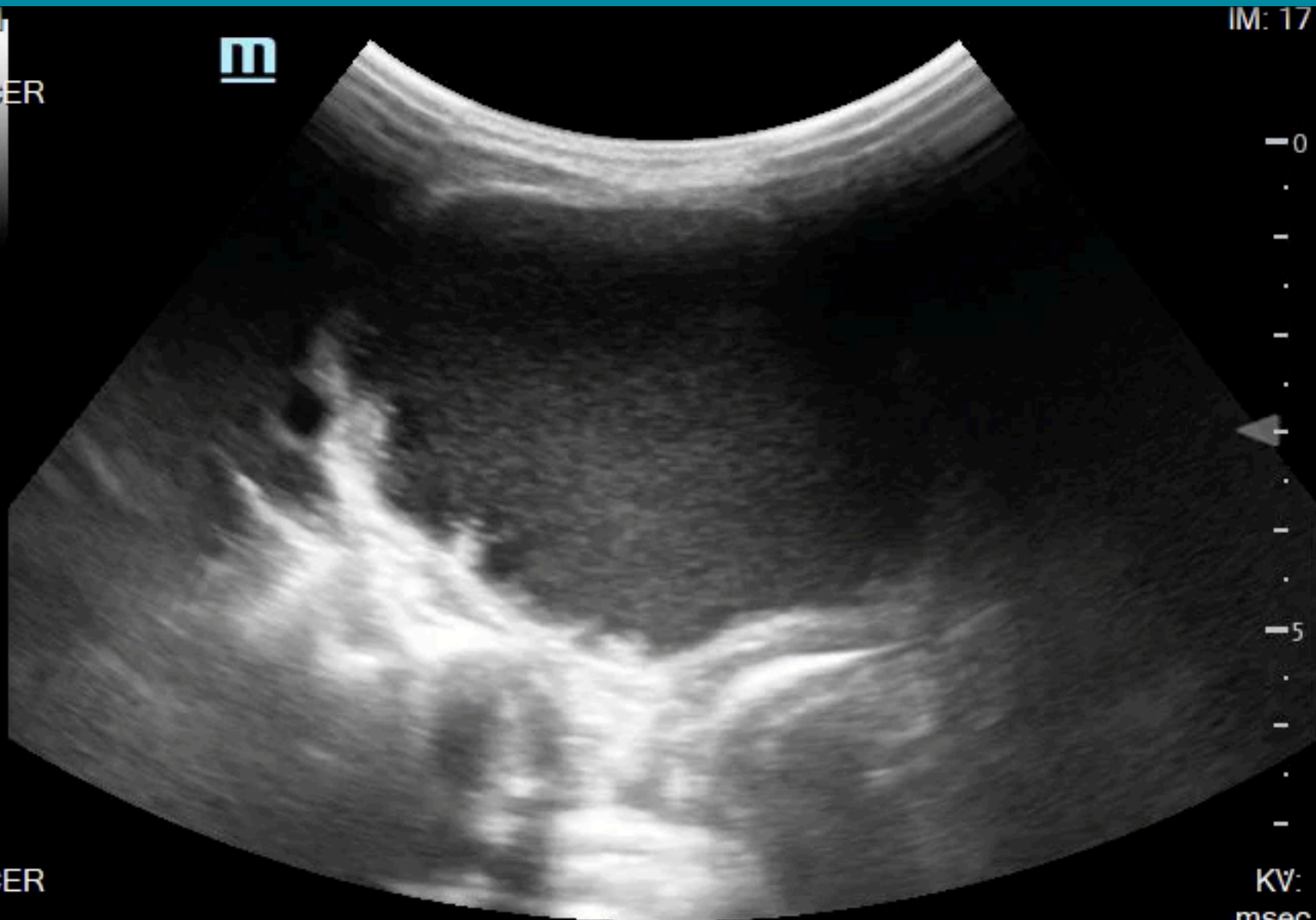
SE
IN

m
A

Trachea deviation

2024/10/31
FH5.0
DB 115
PF19005CER
FR 23
D 8.0
G 86

IM: 17



0
.
-
.
-
.
-
5
.
-
.
-

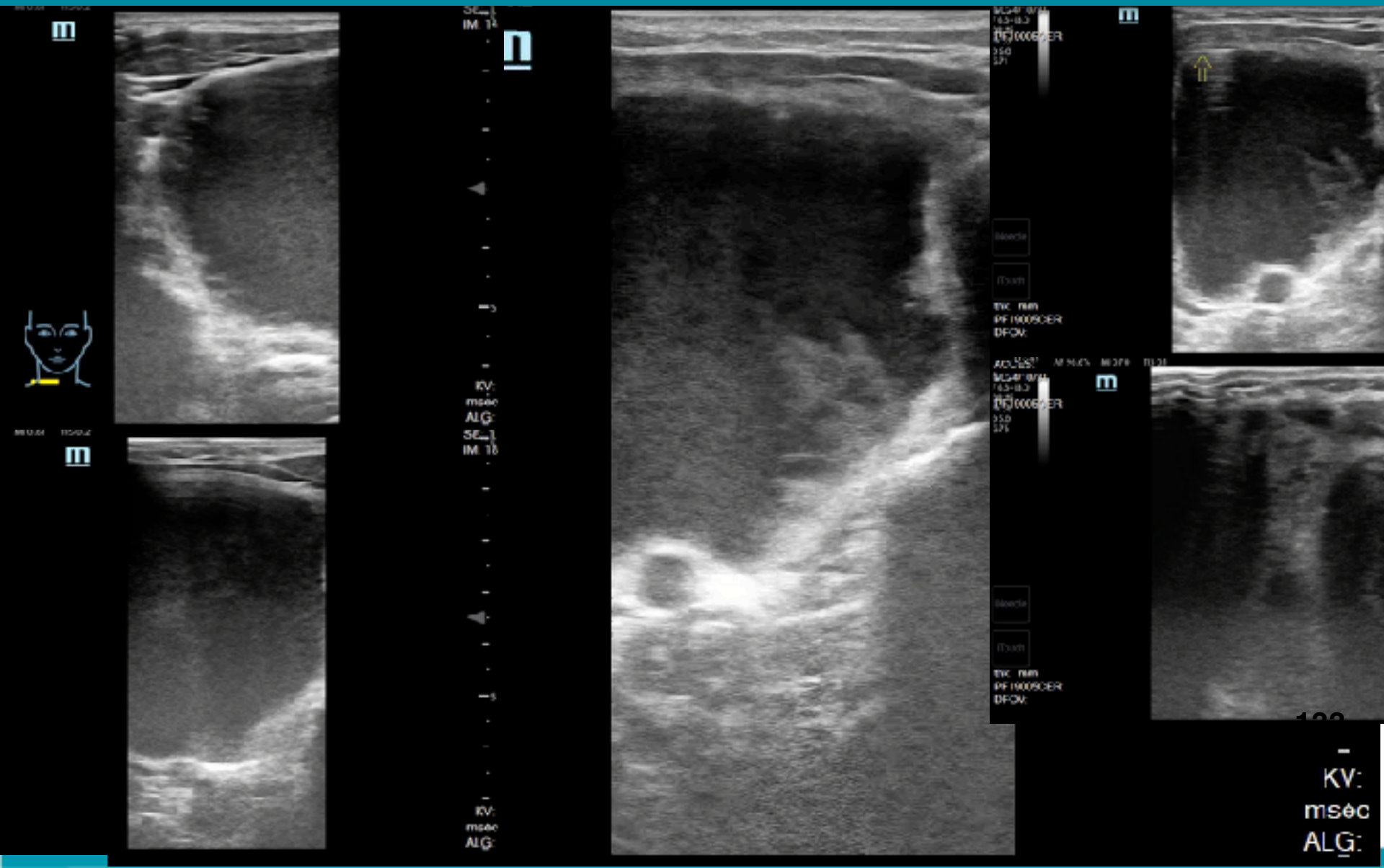
iNeedle

iTouch

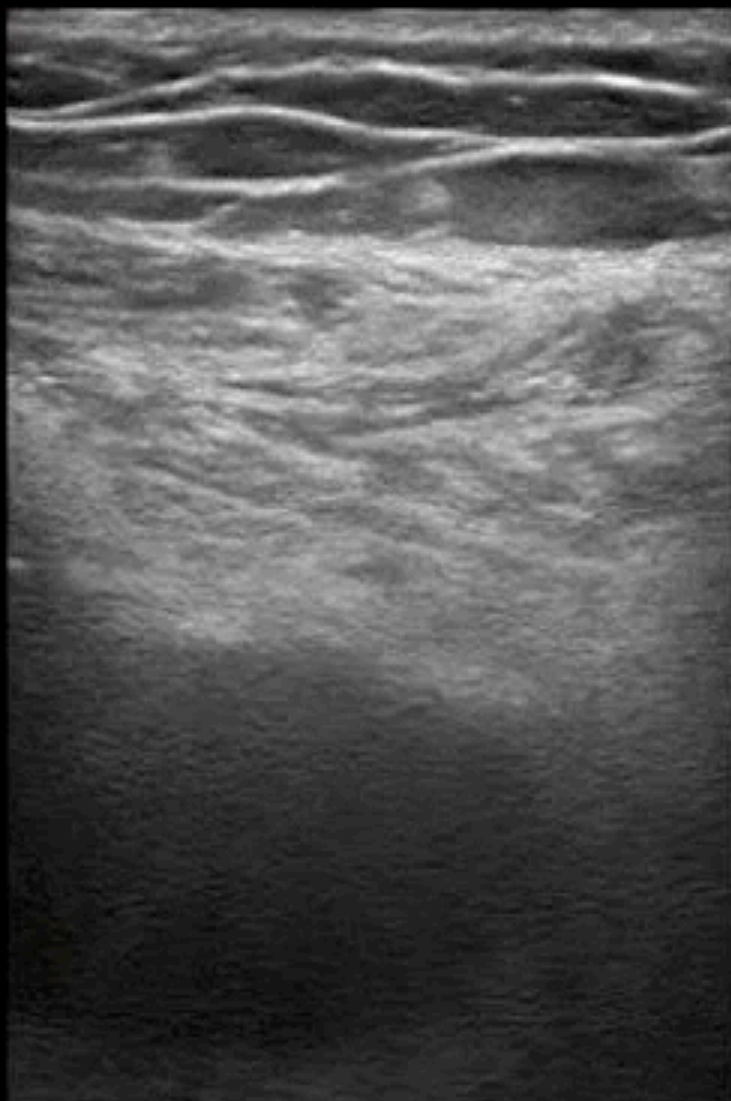
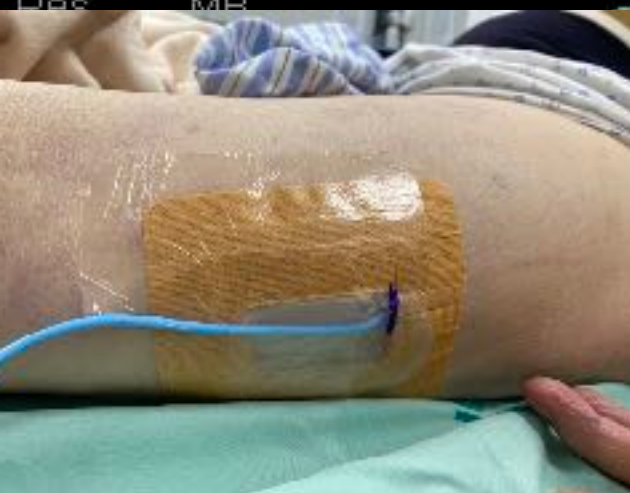thk: mm
PF19005CER
DEOV:

KV:
msec

Echo-guided aspiration



Pigtail for thigh abscess



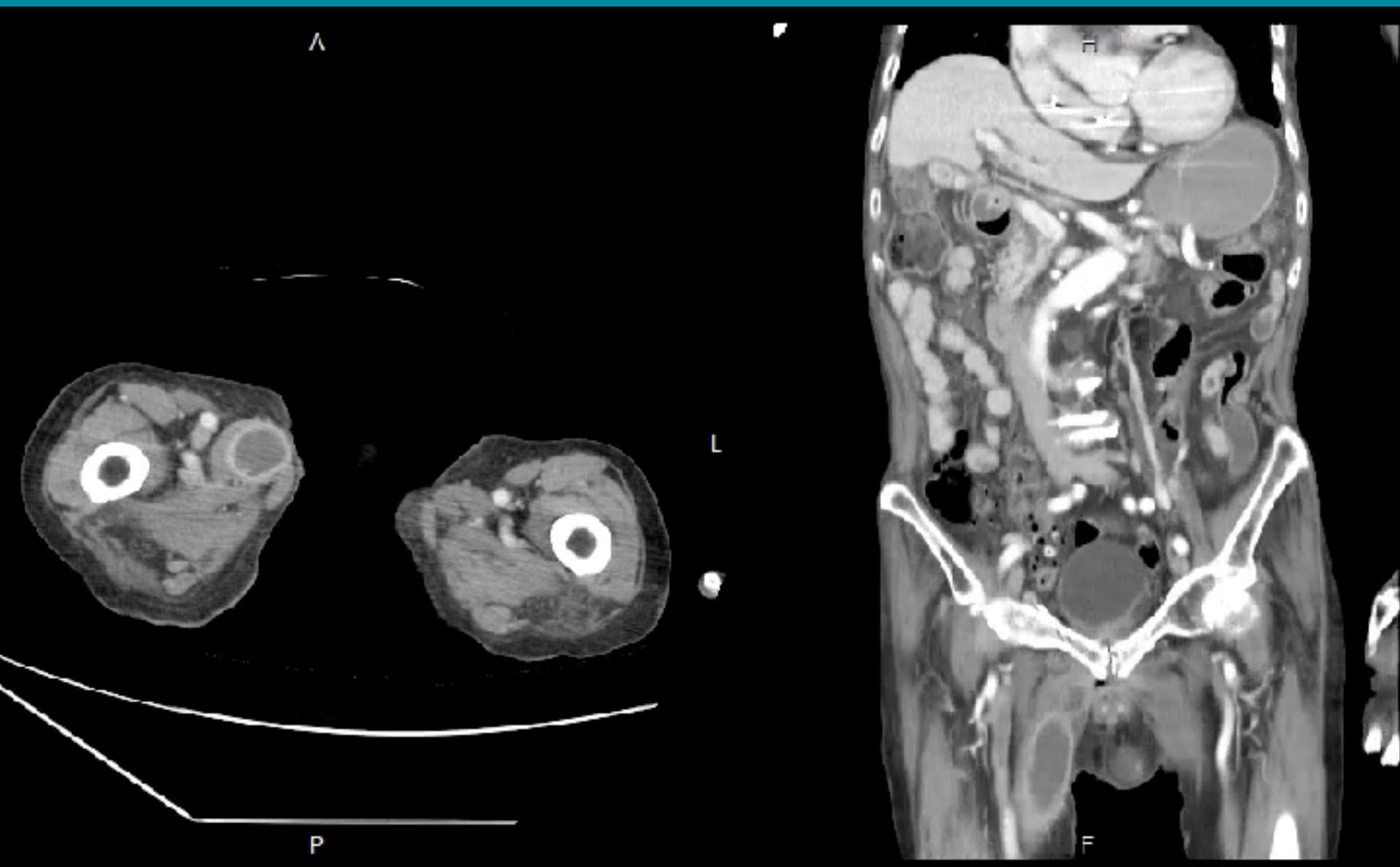Auto Gain



Msk
HFL
93%
MI
0.6
TIS
0.1

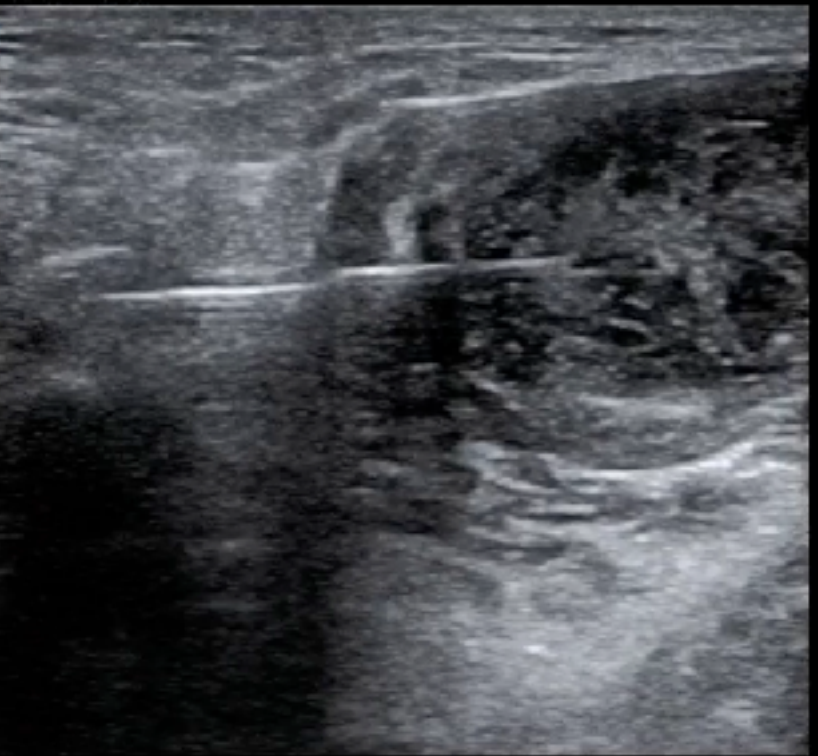
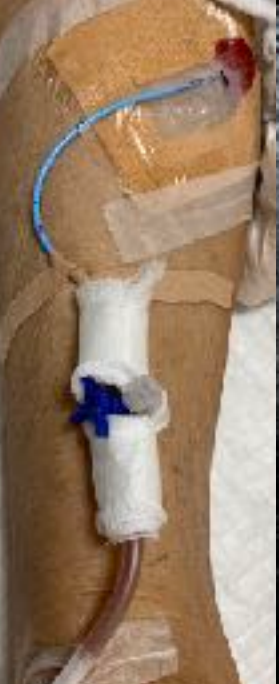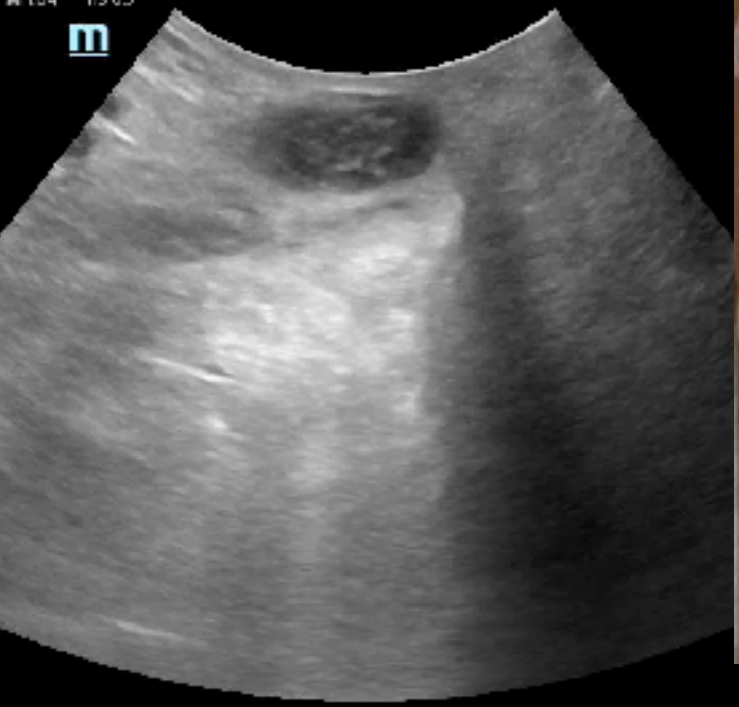


98M with adductor muscle abscess

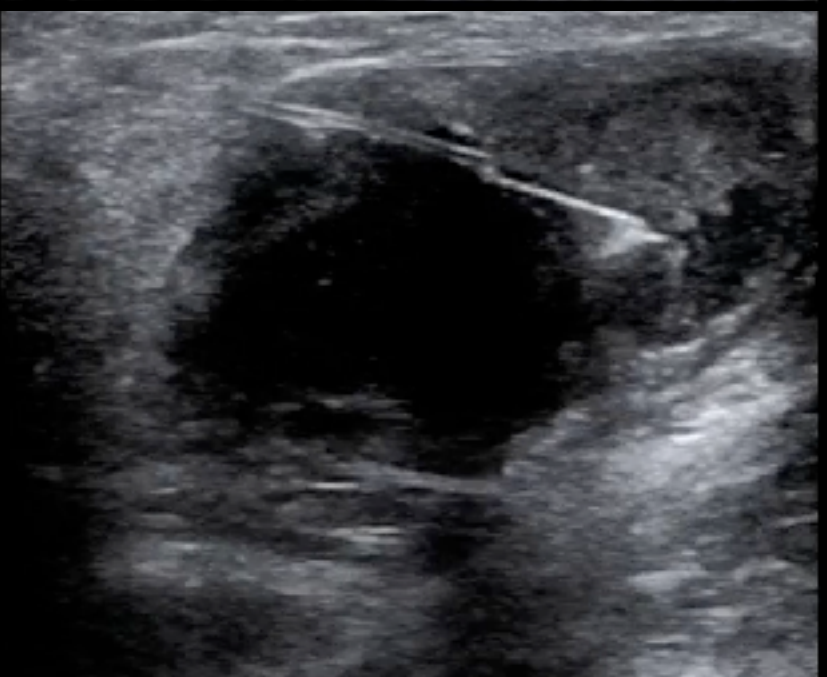
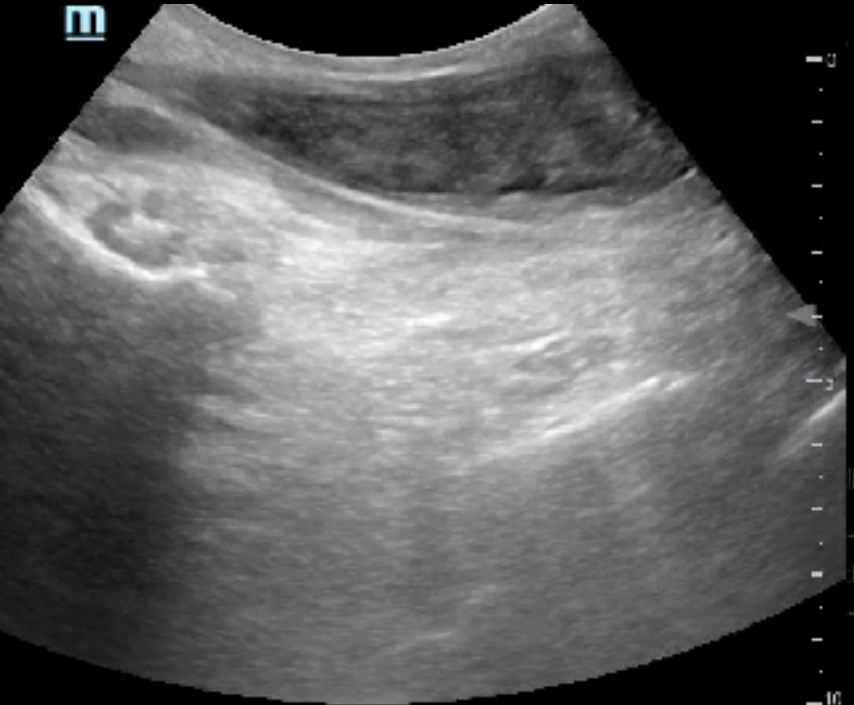

M 109 15 05

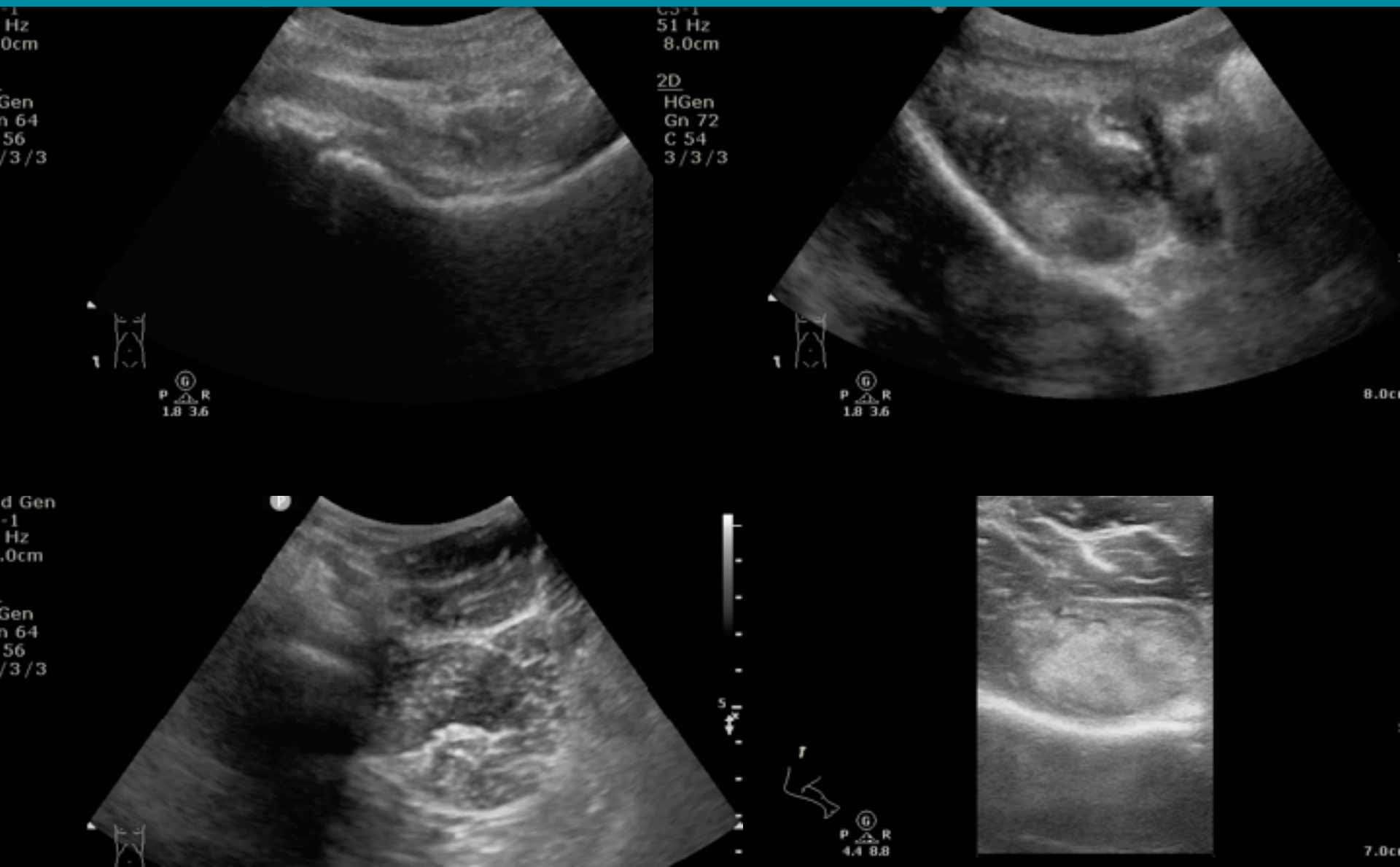
m



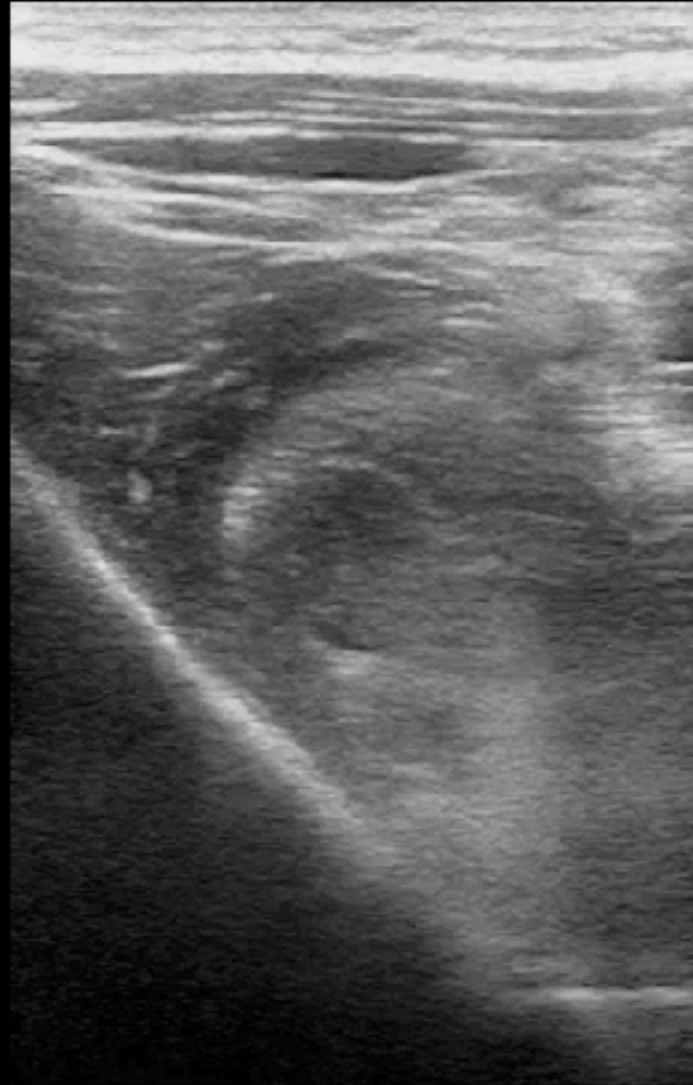
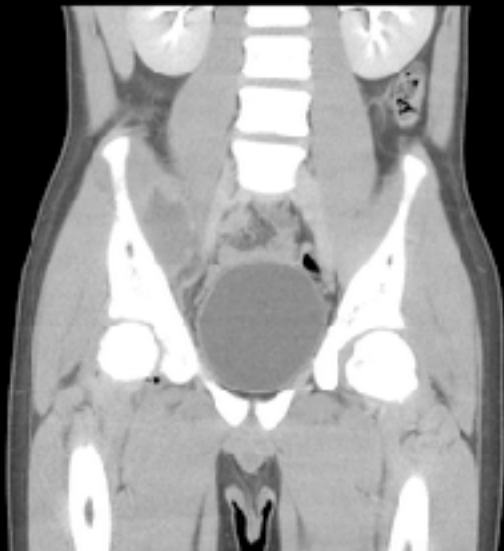
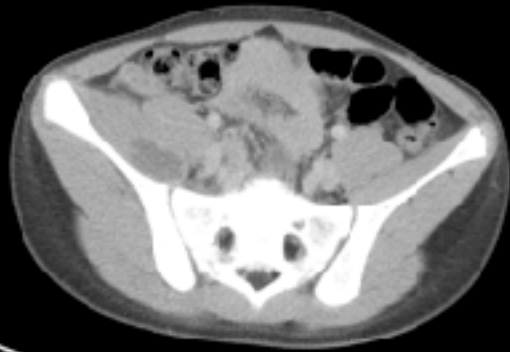
m



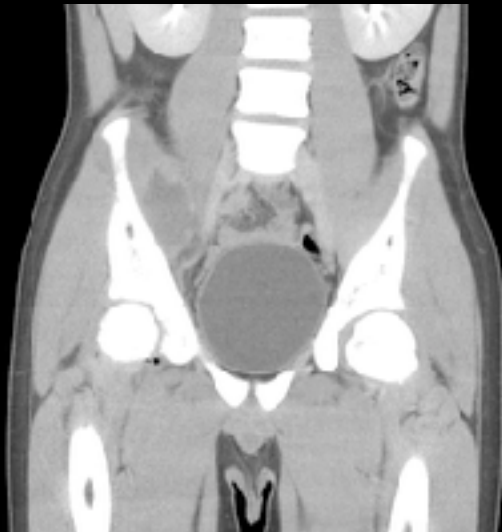
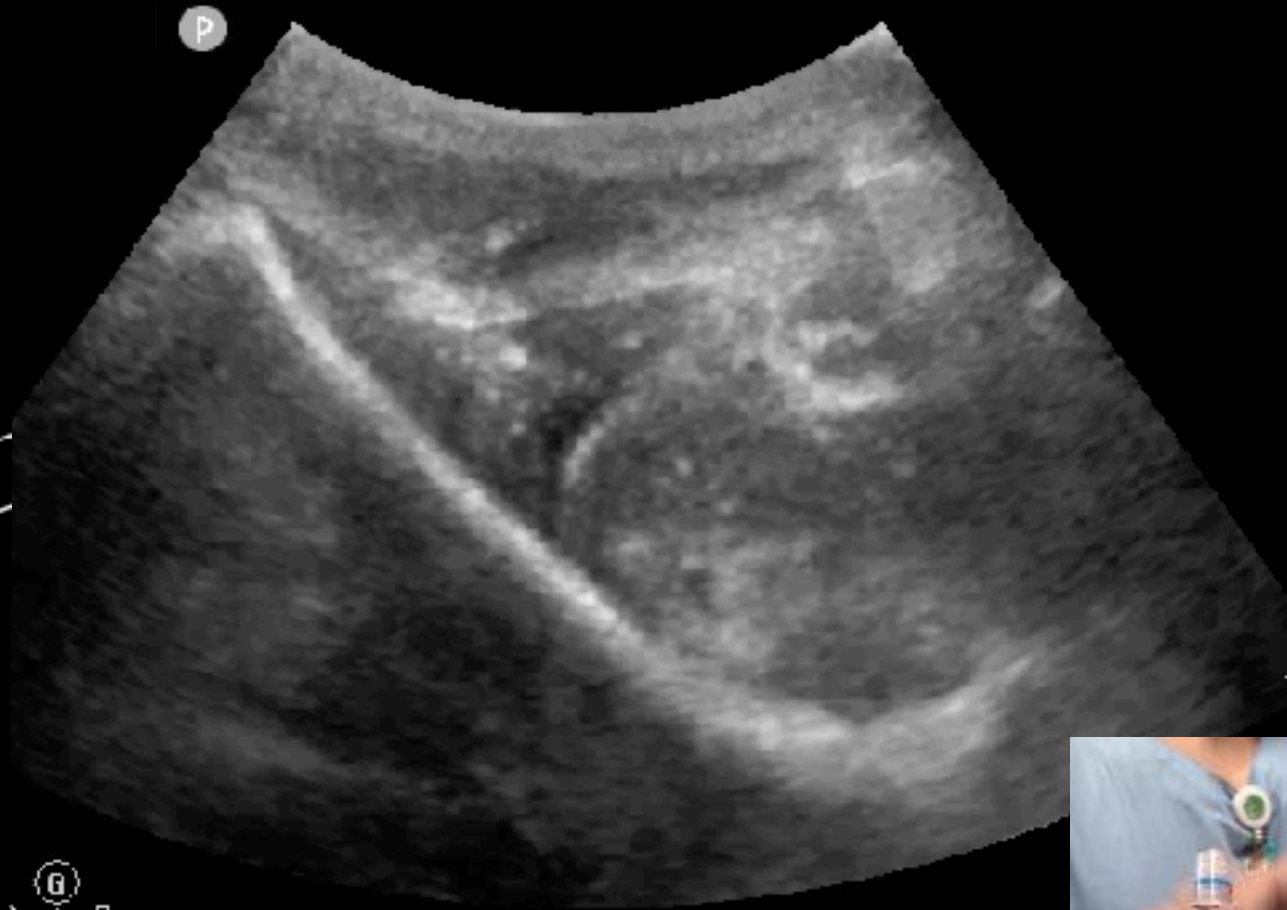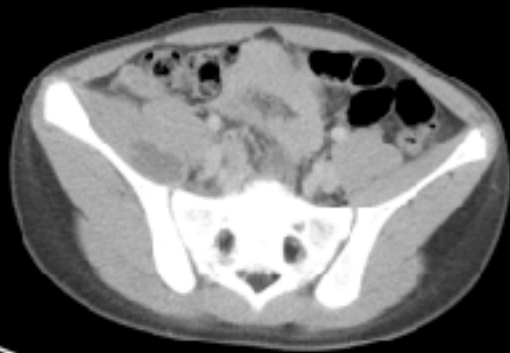12M, right hip pain for 2 weeks



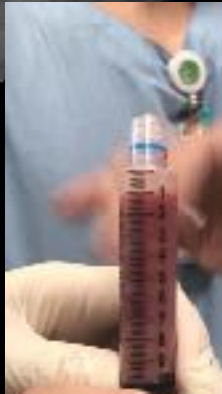12M, right hip pain for 2 weeks



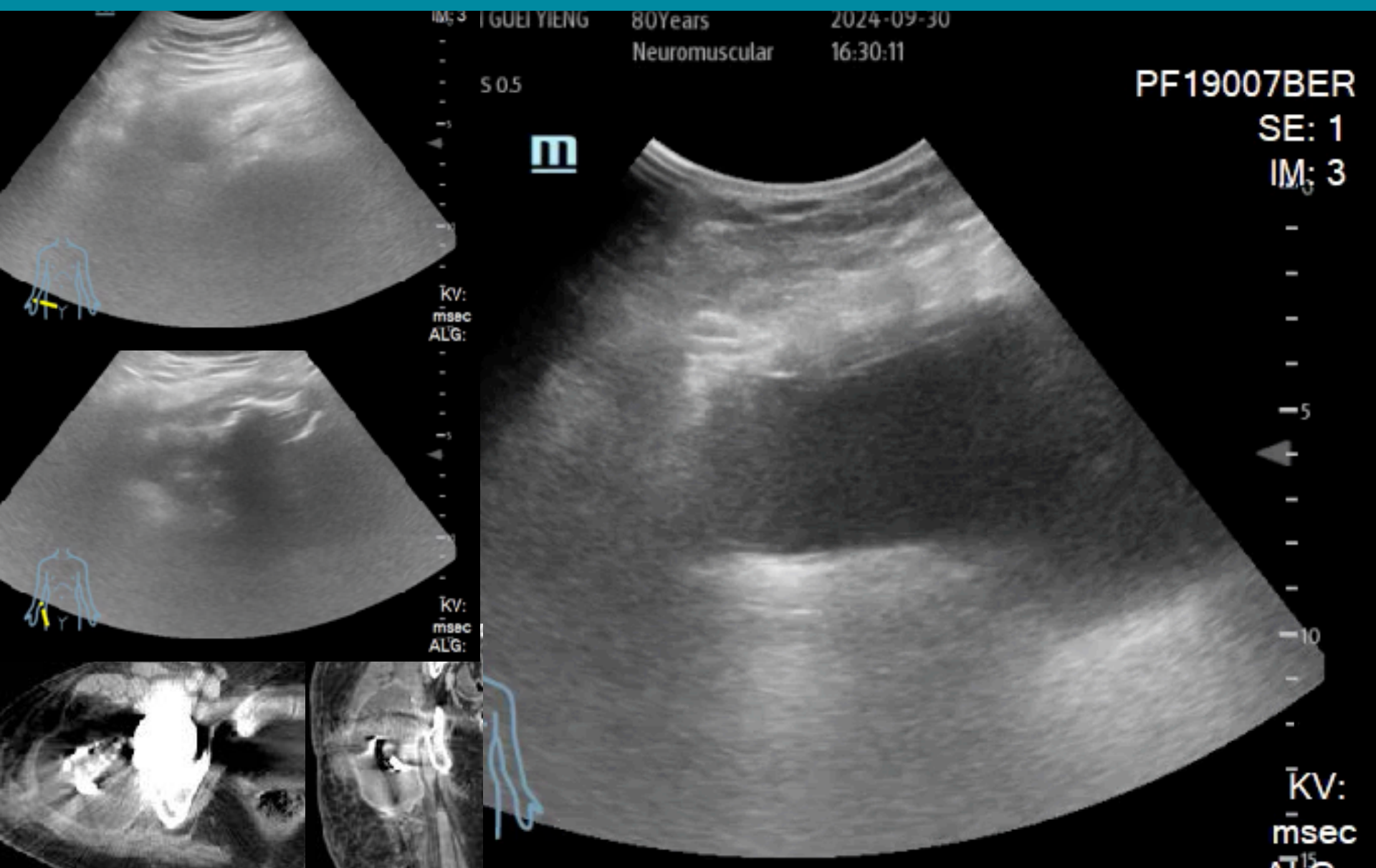
12M, right hip pain for 2 weeks



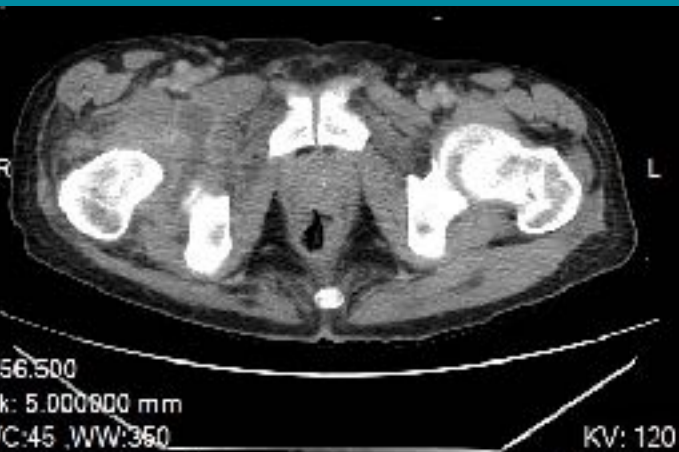1.8 3.6



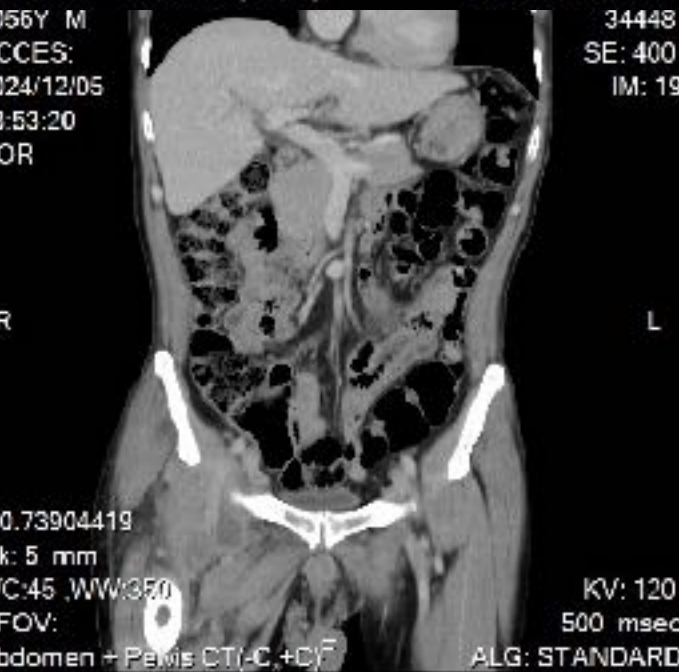Pigtail drainage for peri-prosthetic abscess



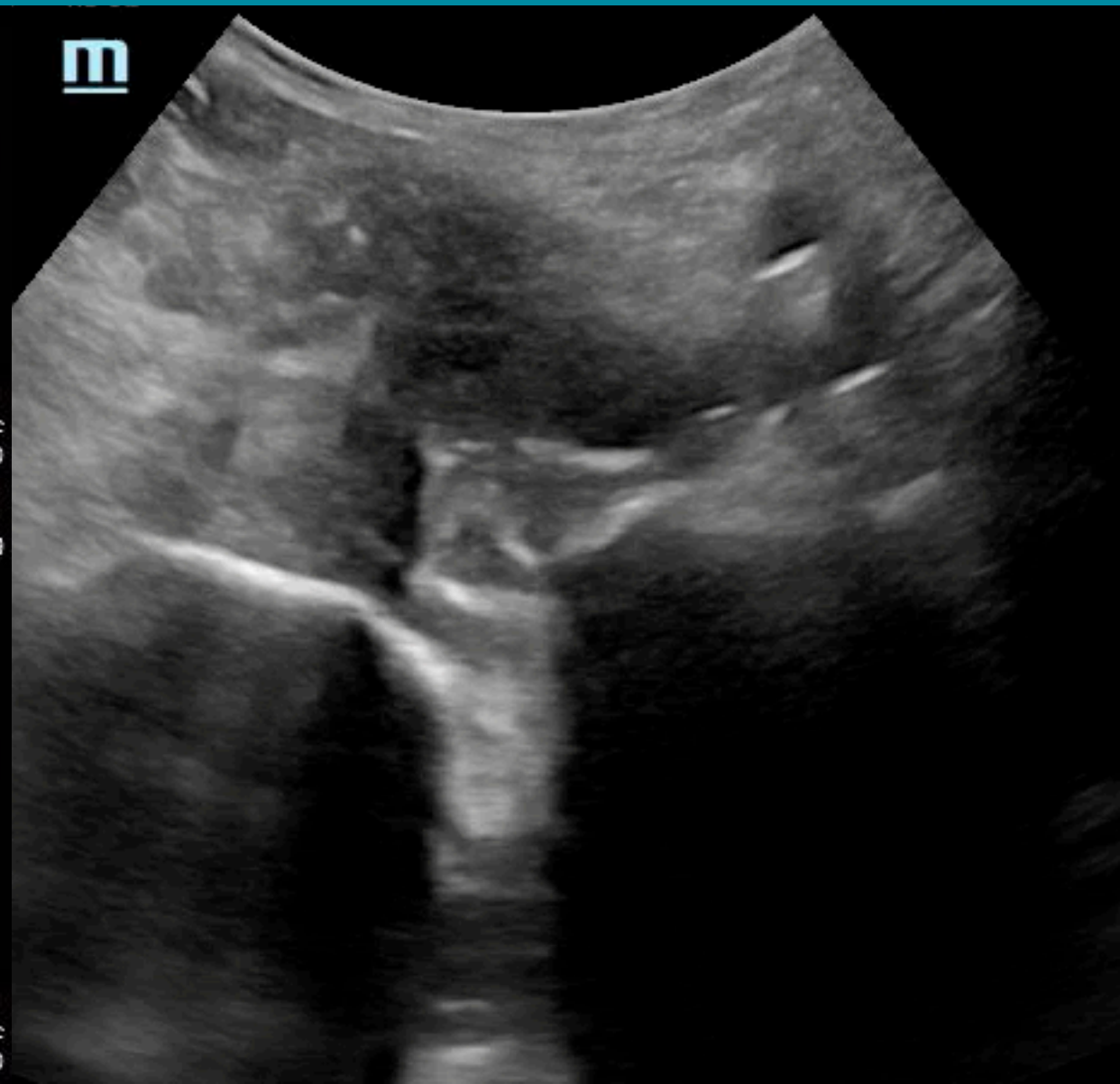
56M, R hip pain 1month, hx of hip abscess



KV: 120
500 msec
ALG: STANDARD
34448
SE: 400
IM: 19



KV: 120
500 msec
ALG: STANDARD



Pigtail - deep hip abscess

ACCESS:
FH5.0
2024/12/08
FR 26
D10.0
PF19007BER

m

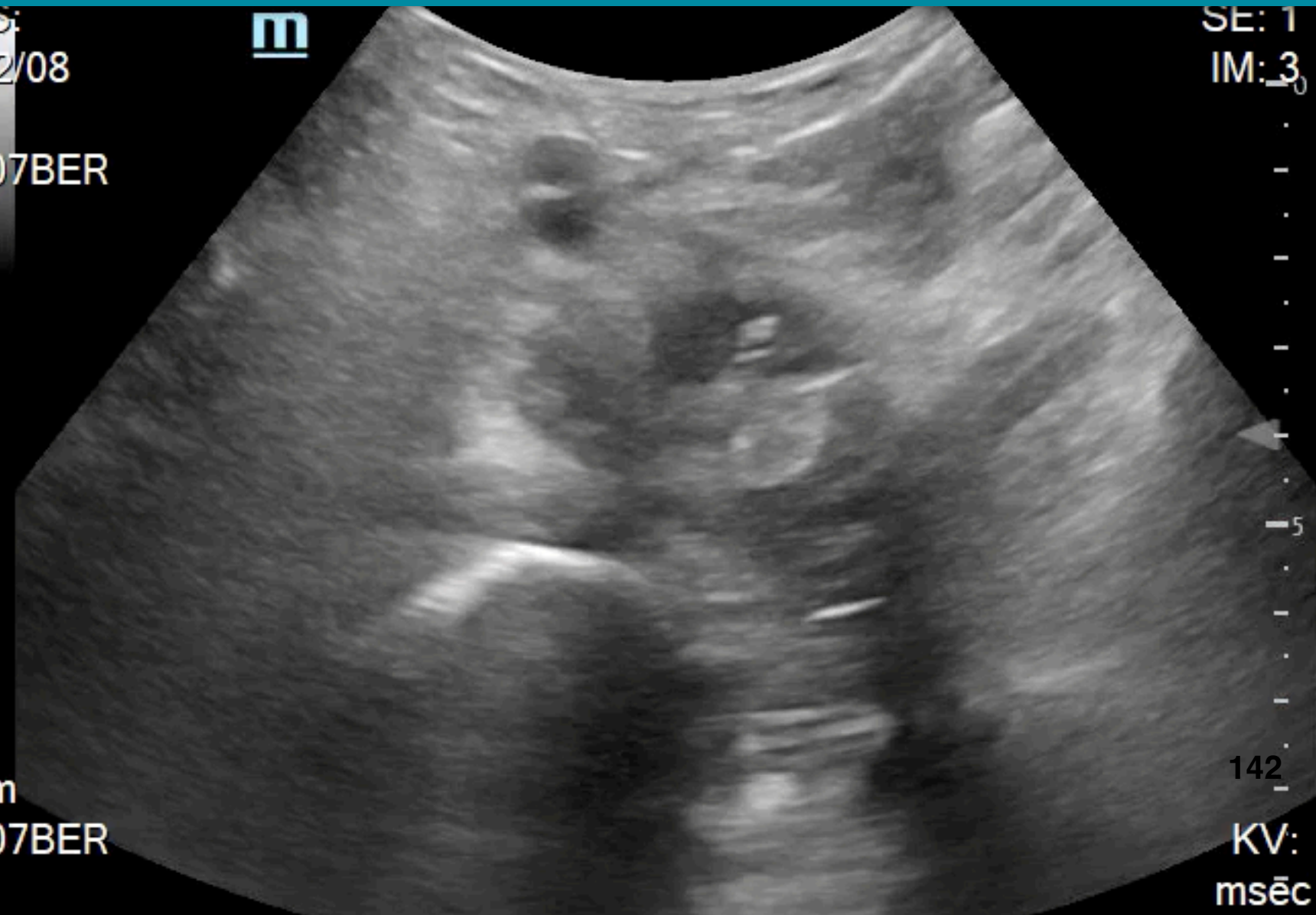
SE: 1
IM: 3

iNeedle

iTouch

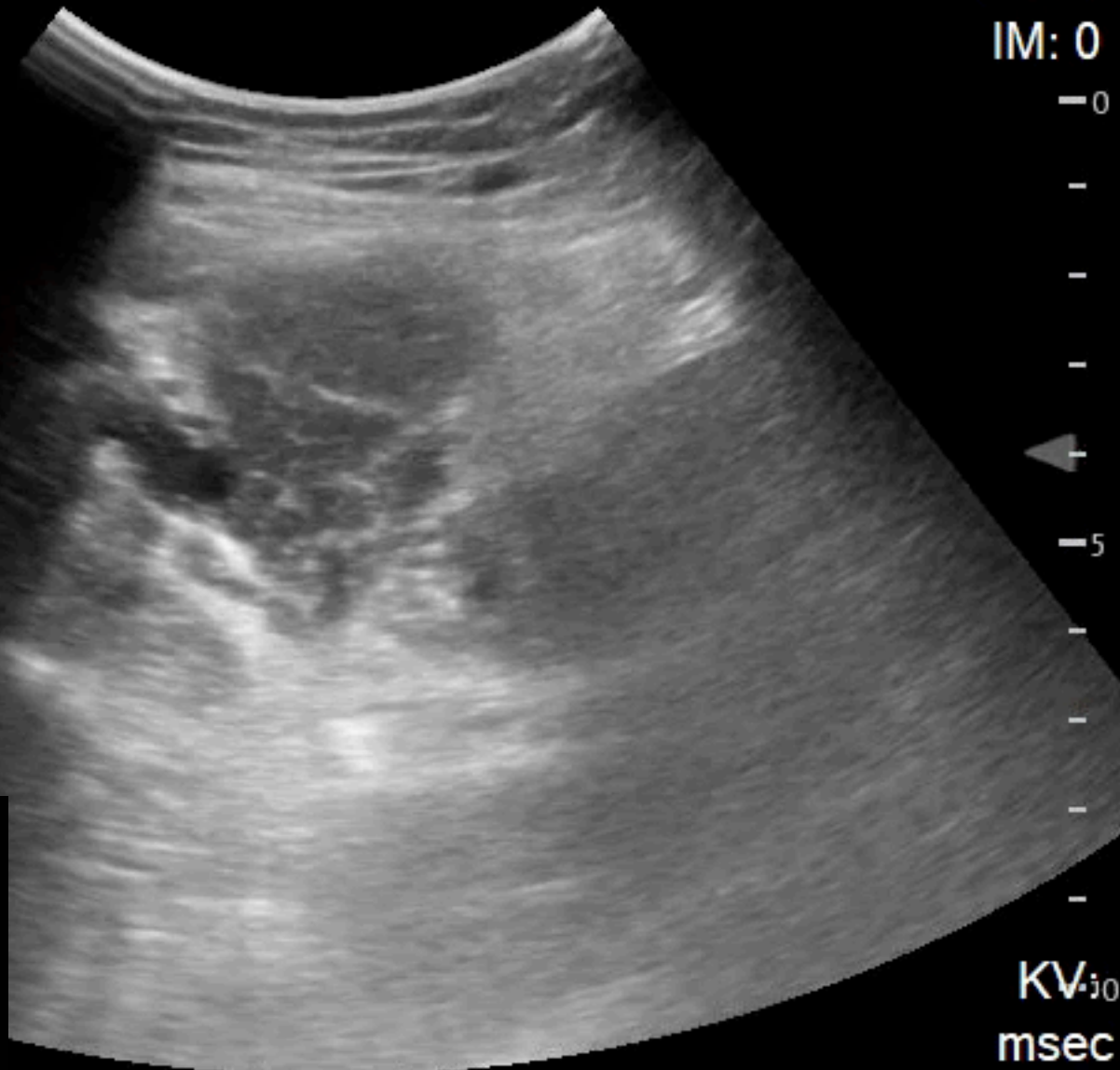
thk: mm
PF19007BER
DFOV:

142
KV:
msēc

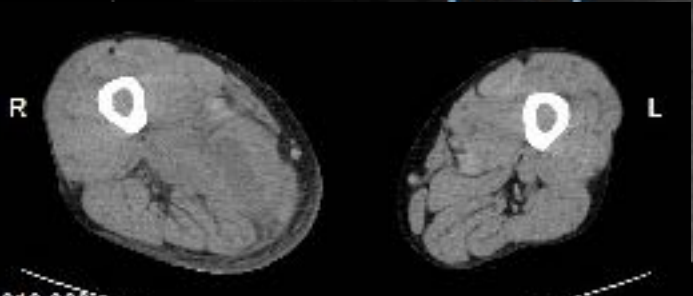


45M, fever & right thigh pain for 4 days

2024/08/07
FR 19
D 11.0
G 50



iNeedle



IM: 0

0

-

-

-

-

-

-

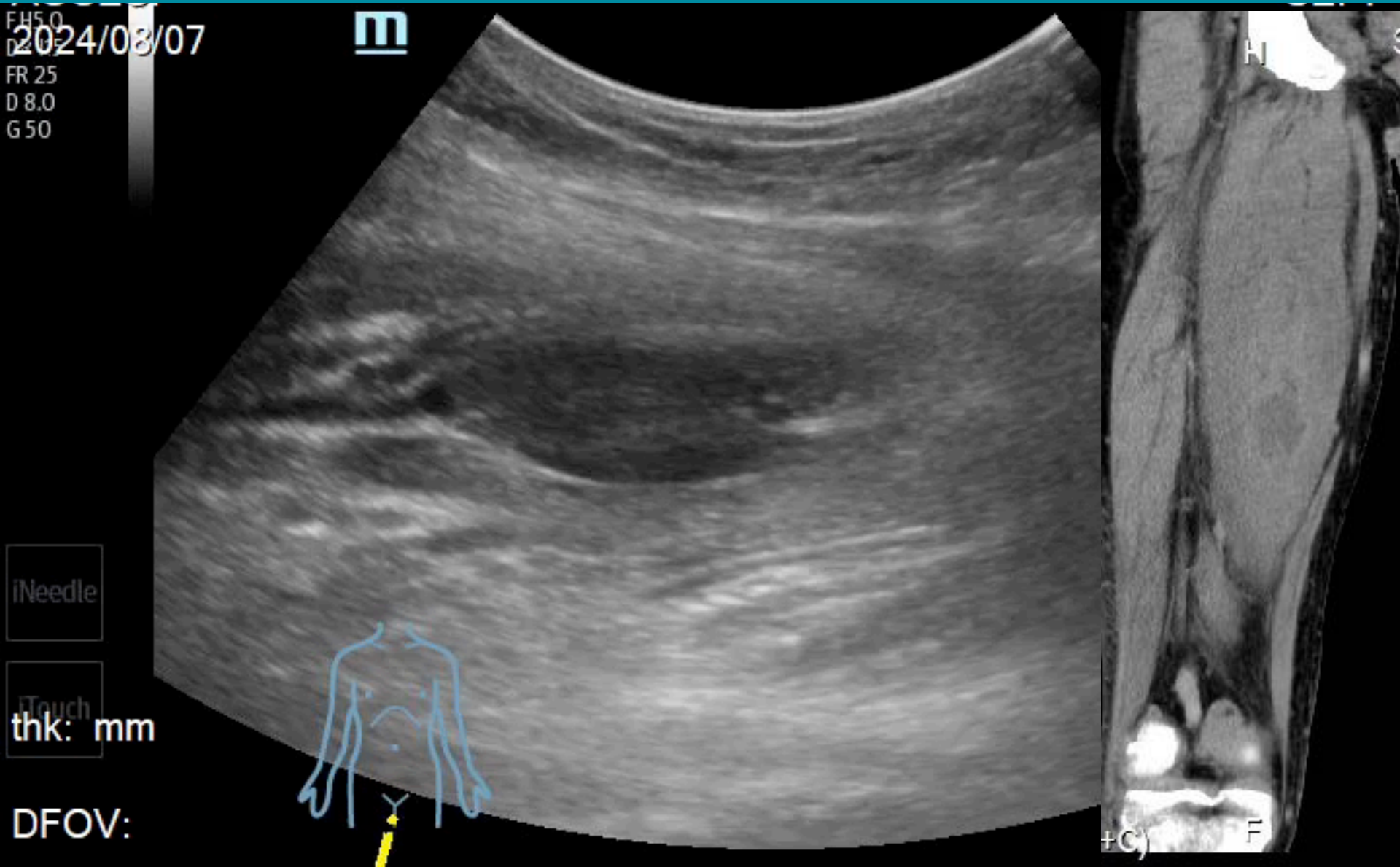
-

-

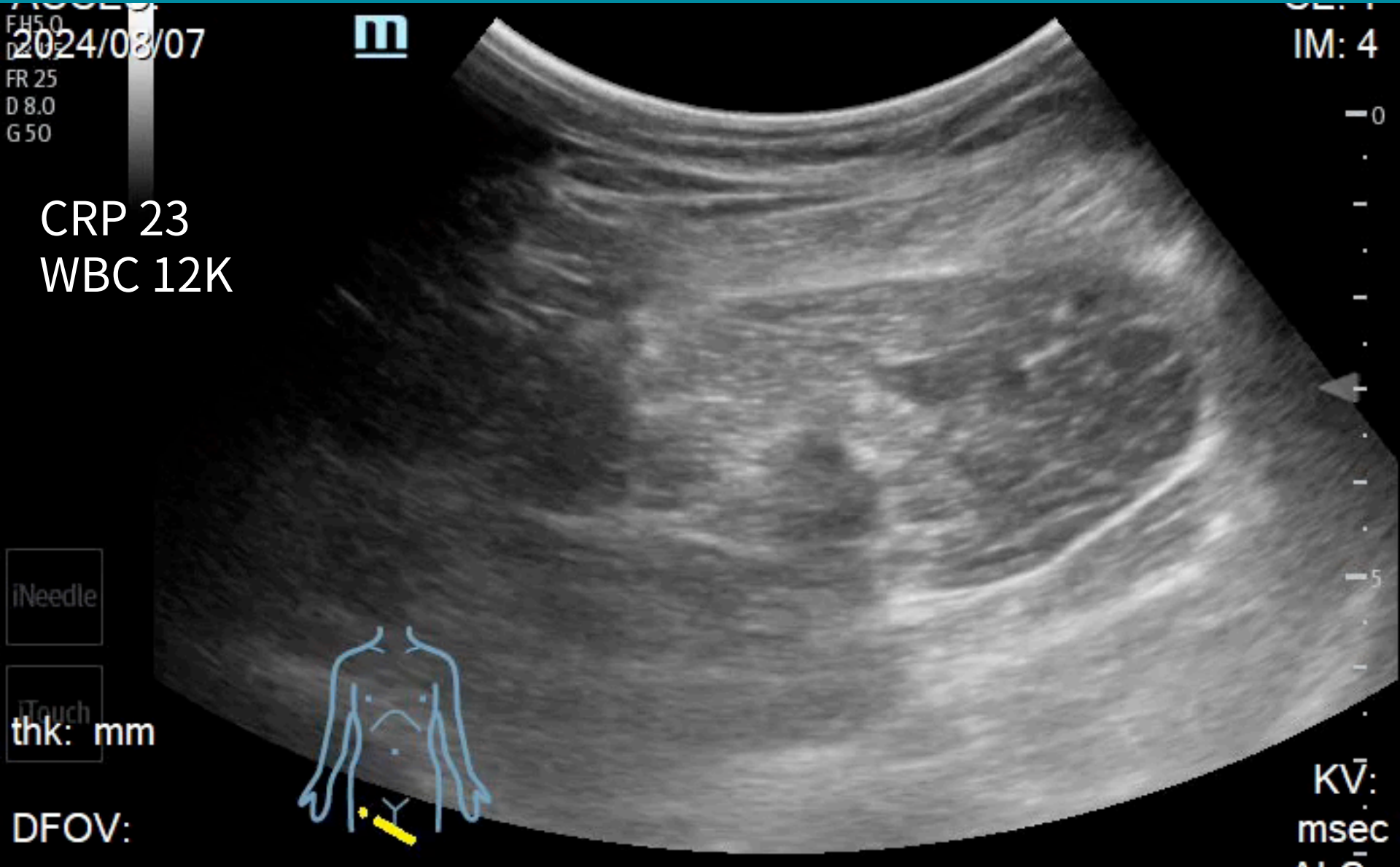
-

KV: 30
msec

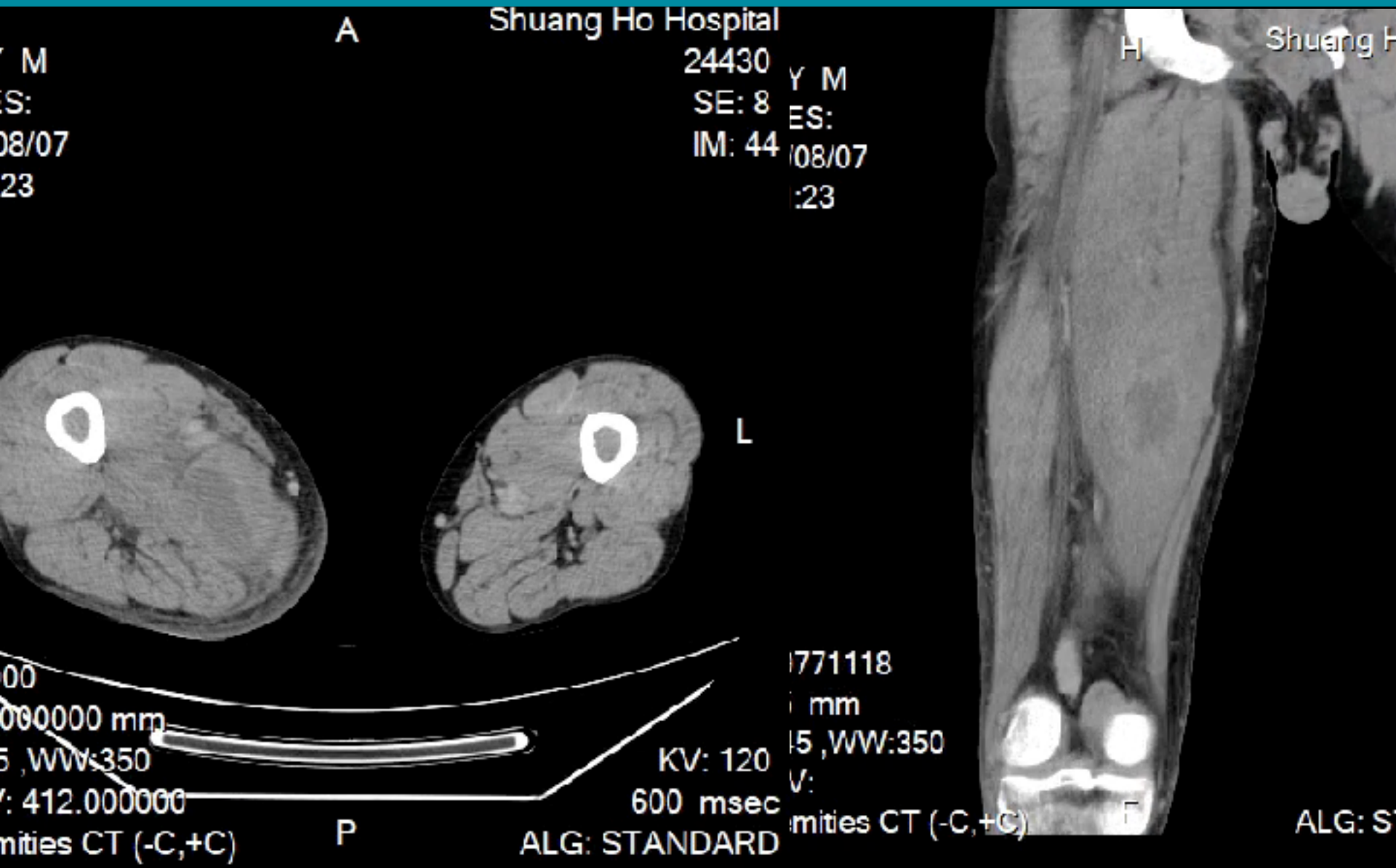
45M, fever & right thigh pain for 4 days



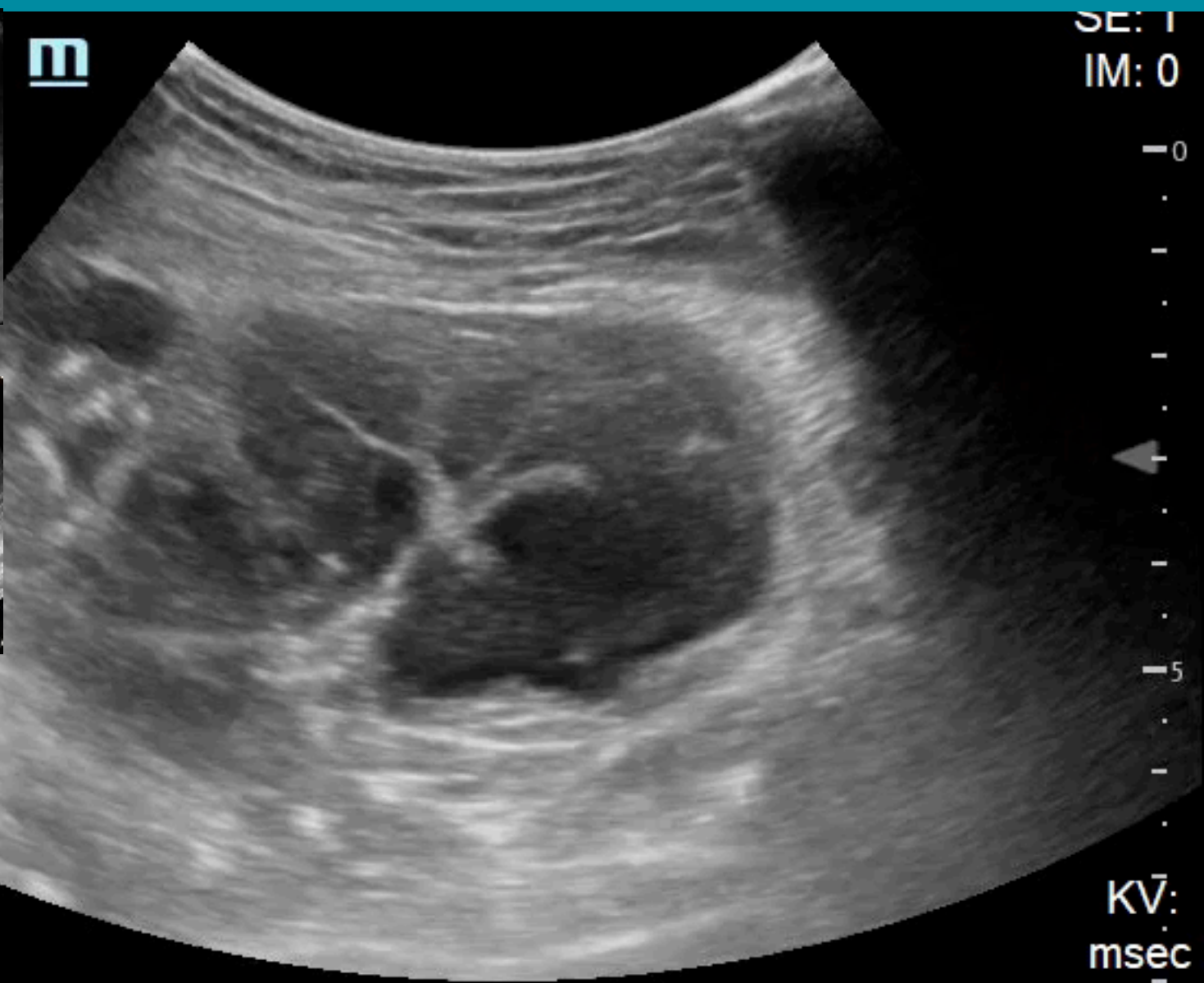
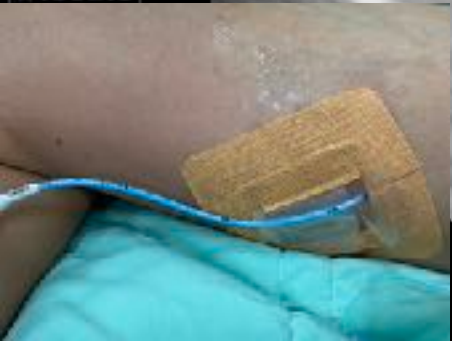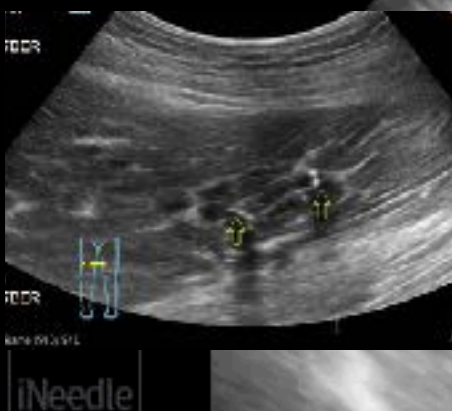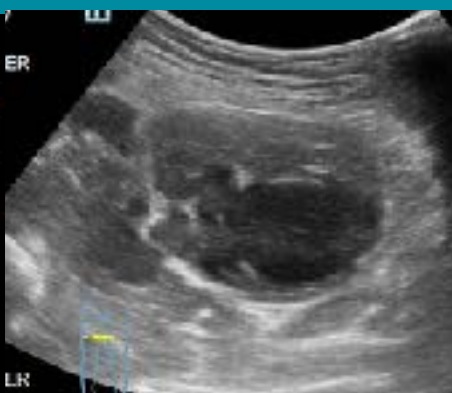Pyomyositis & abscess formation



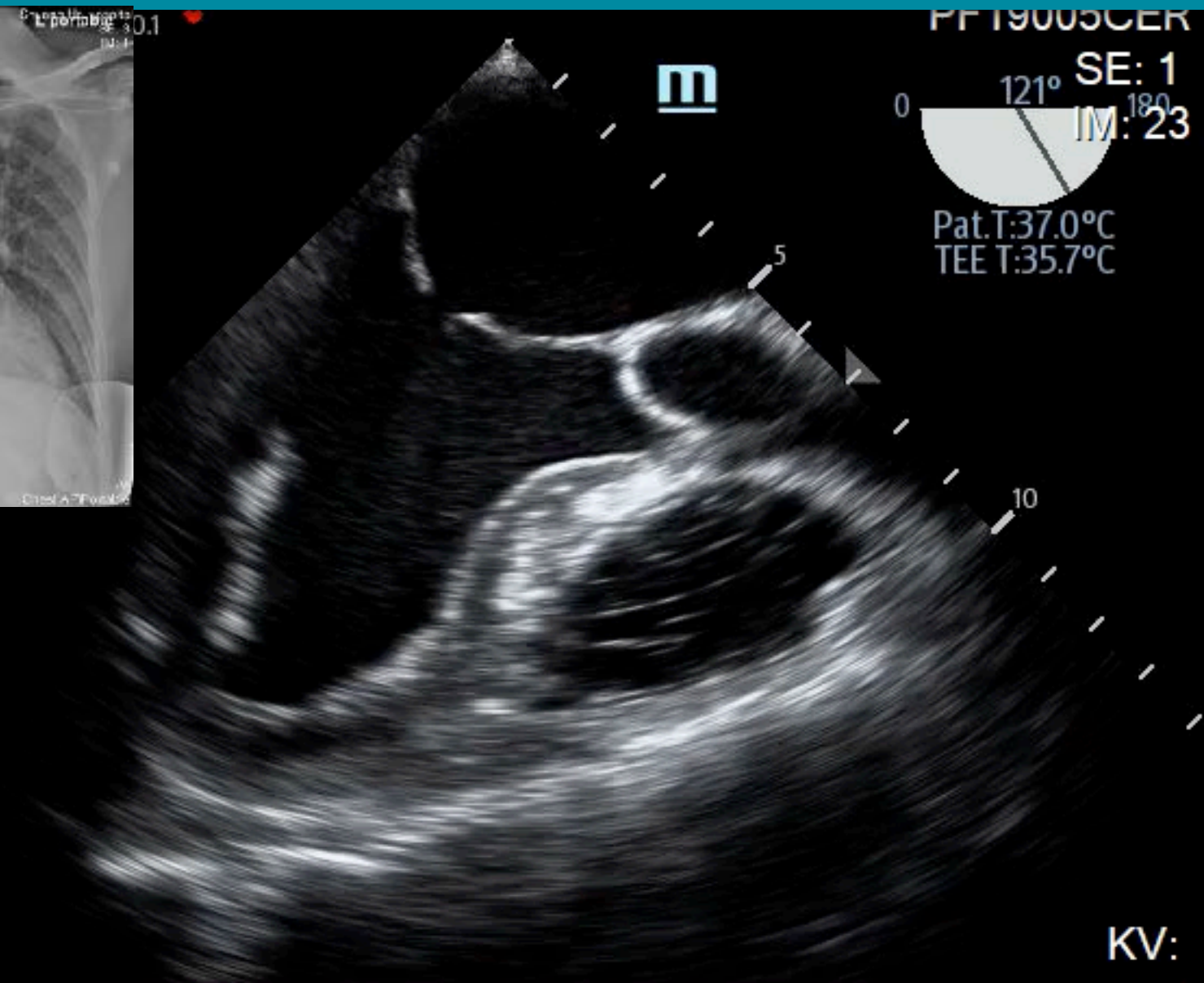
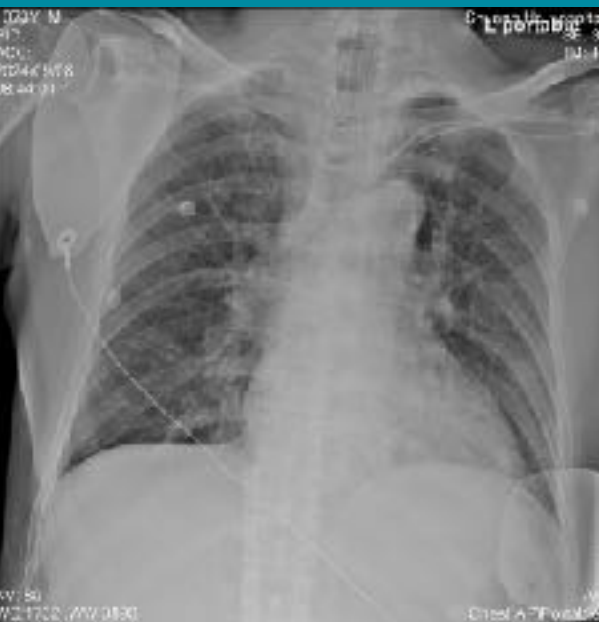Adductor muscle pyomyositis & abscess formation



UG-pigtail drainage



73M, AMS, Dyspnea, BP 70/39 > IHCA



iNeedle

iTouch

thk: mm

PF19005CER

KV:

VF with DC shock

ACCES:

F33~7.2
2024/09/08

FR 28

D 15.0

PF19005CER

m

SE: 1
120° IM: 26

Pat.T:37.0°C
TEE T:36.2°C

iNeedle

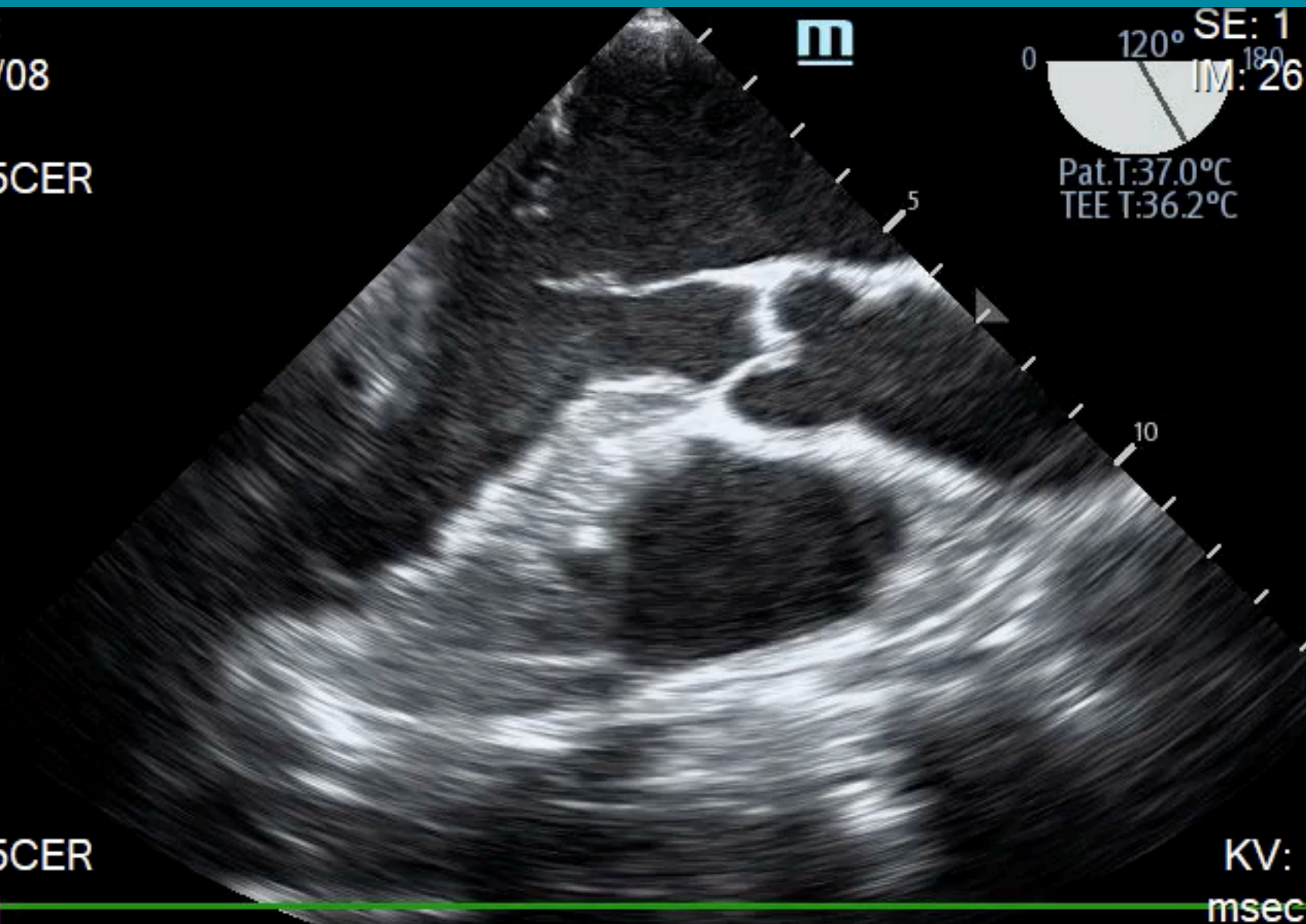
thk: mm

PF19005CER

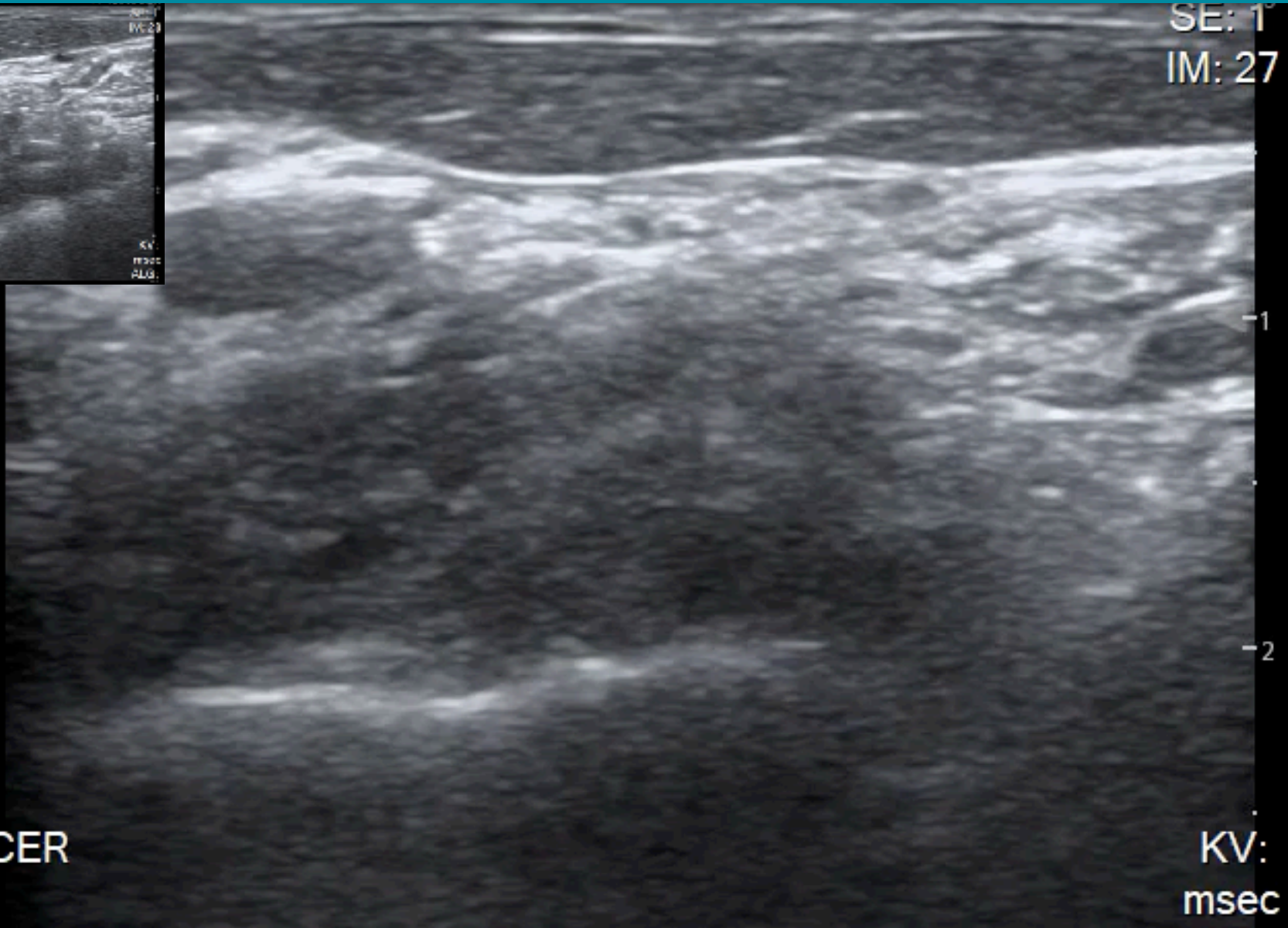
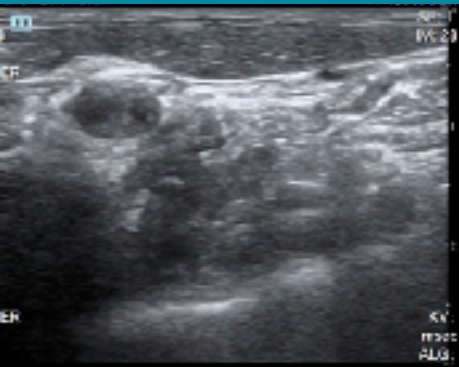
DFOV:

KV:

msec



Stellate ganglion block during CPR



iNeedle

iTouch

thk: mm

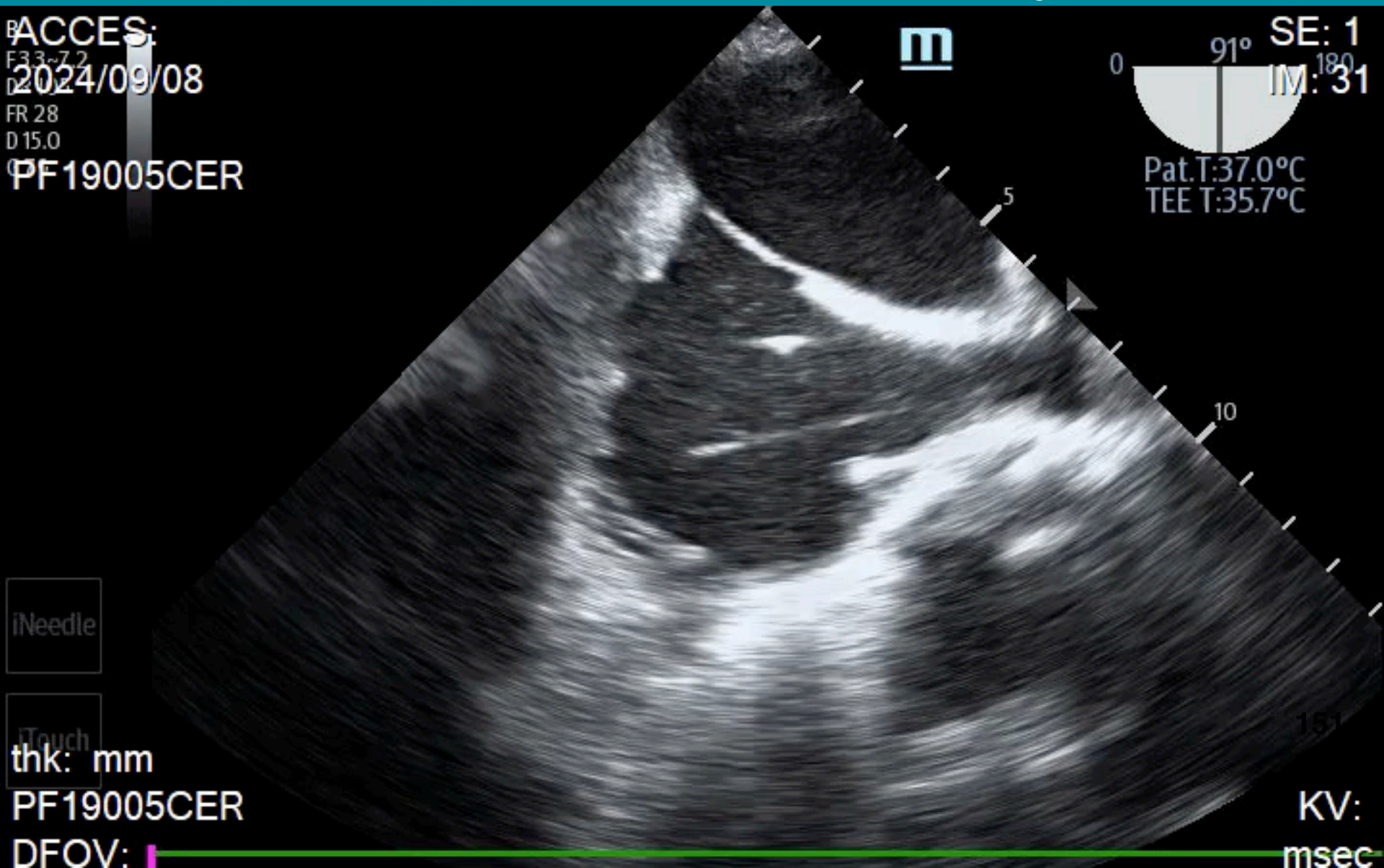
PF19005CER

DFOV:

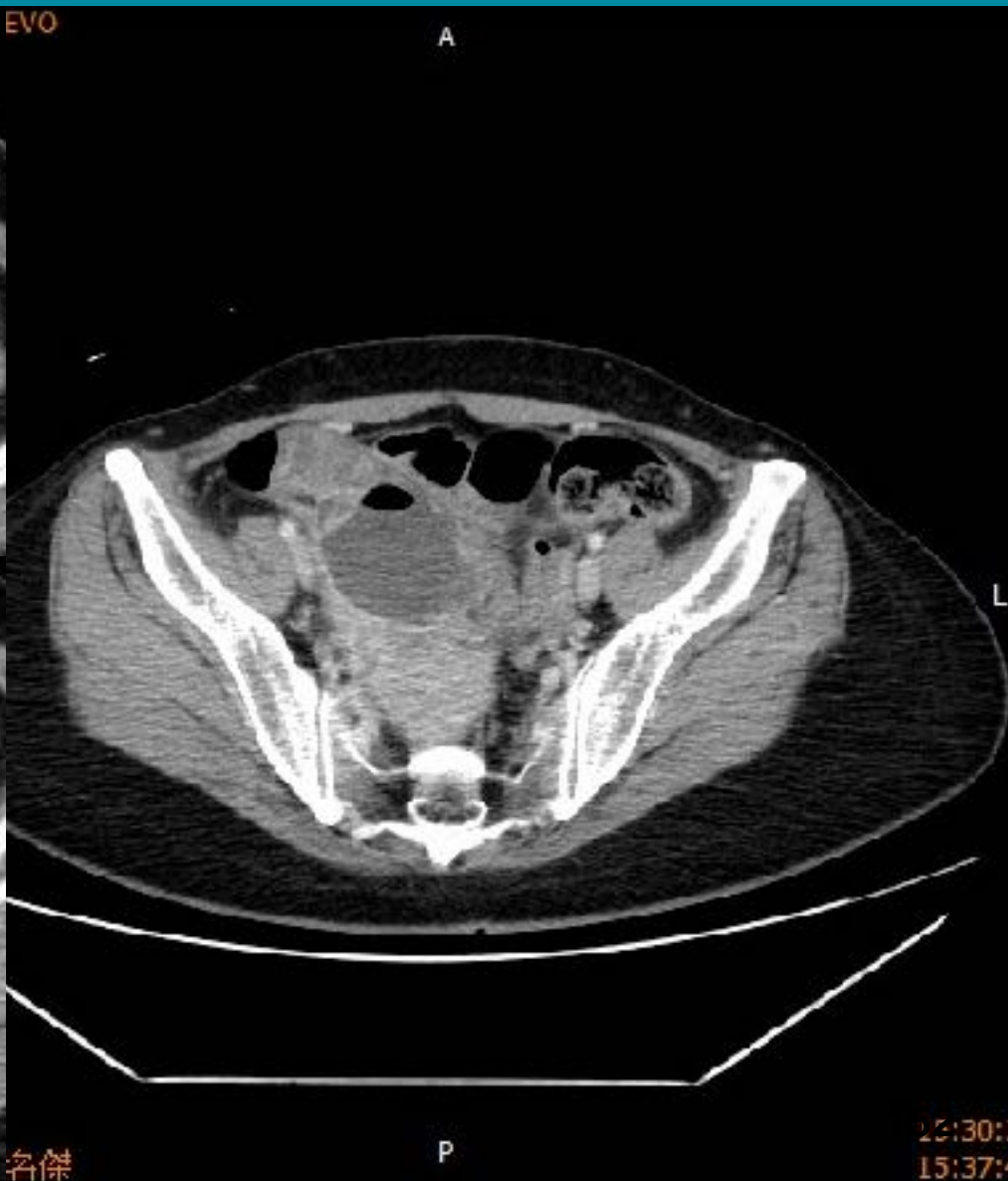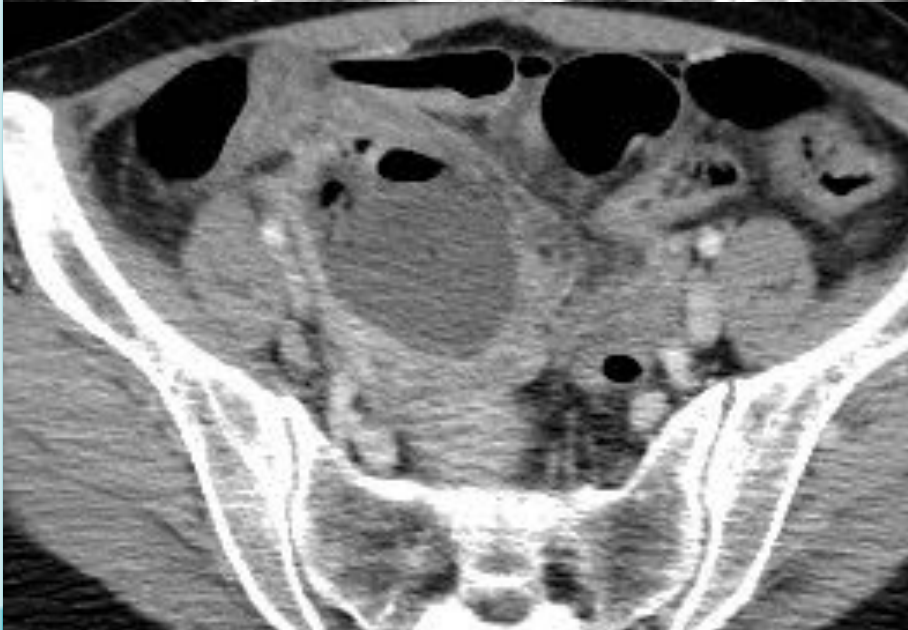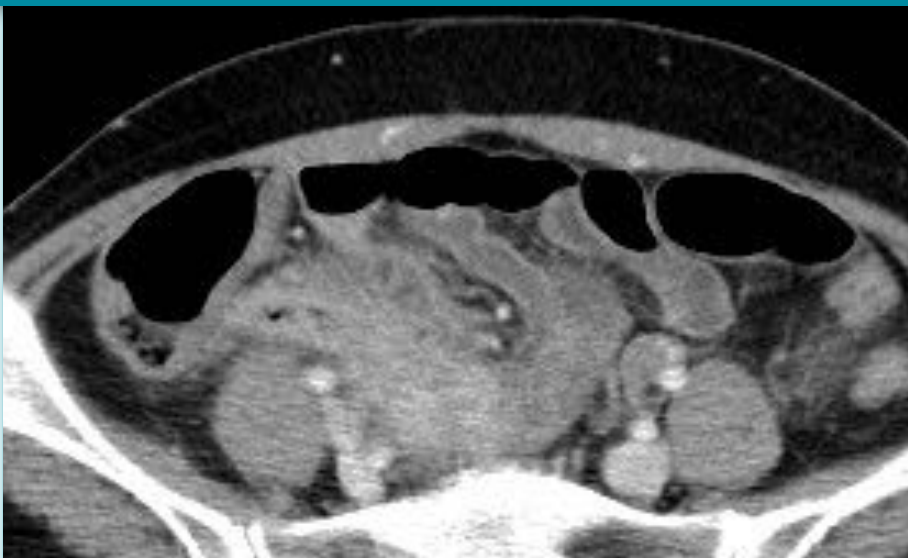KV:
msec

PCPS -bicaval view

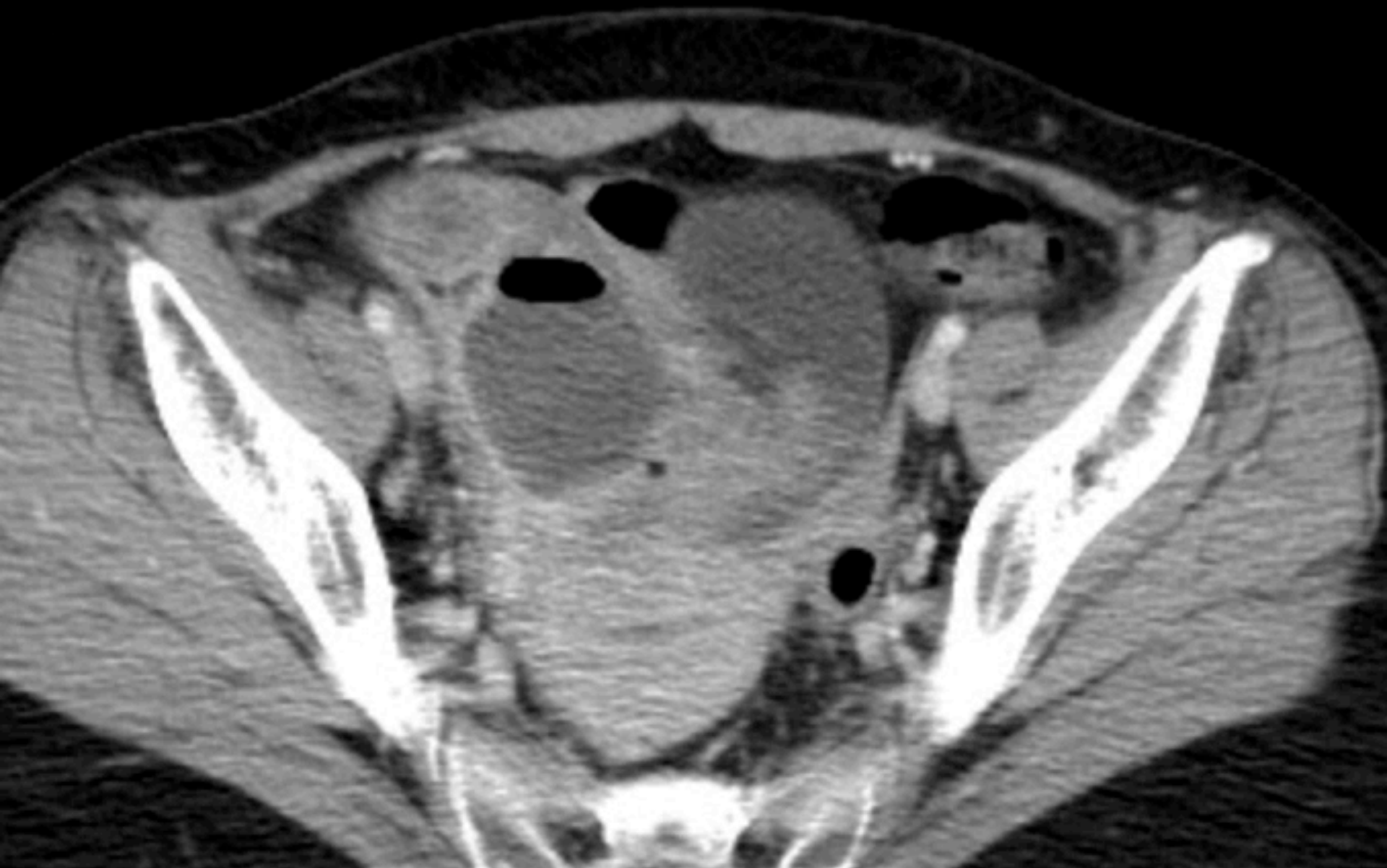
PCI to left main; CPC1 (18 days)



50F, RLQ pain for one week



Radiology refused this drainage



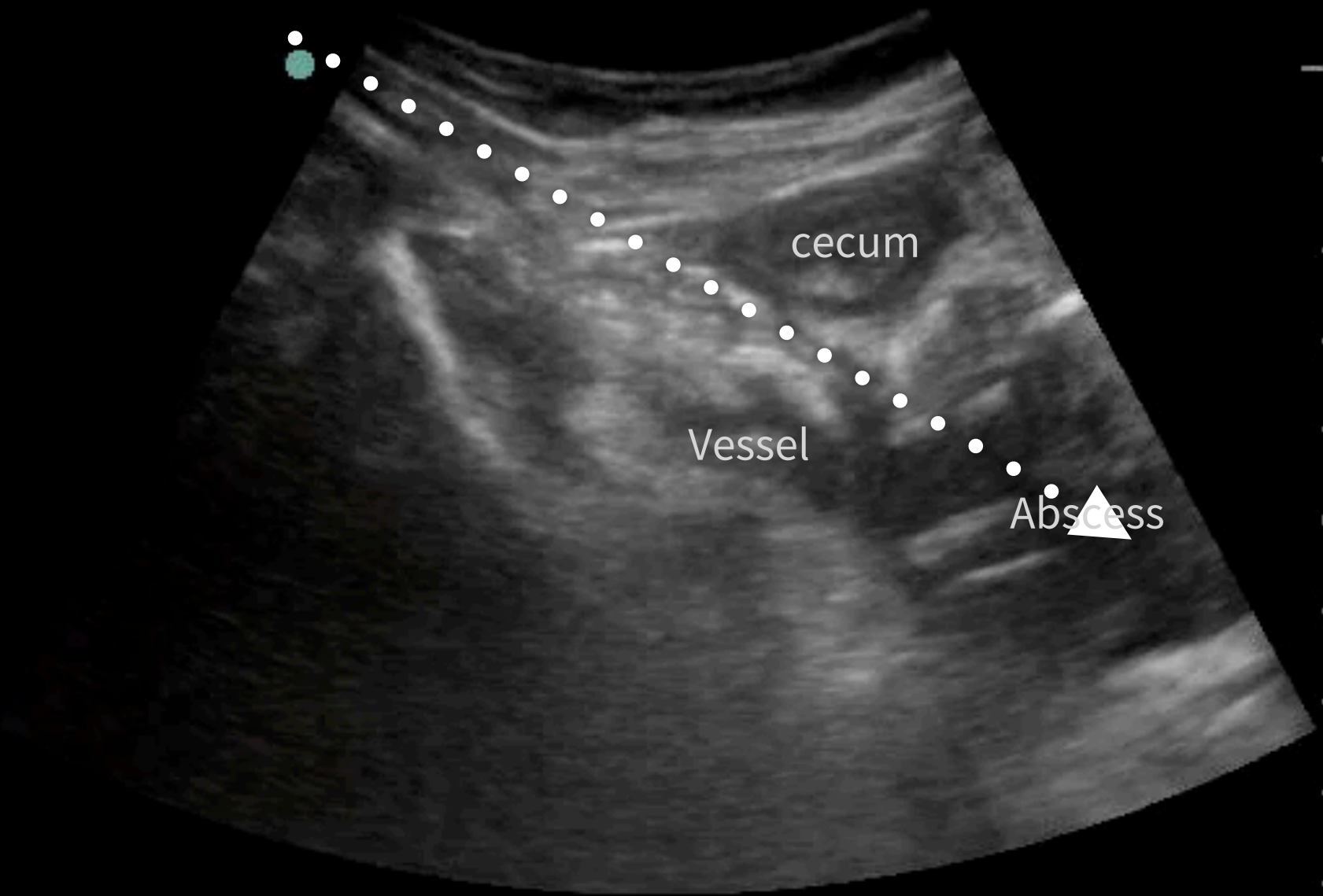
patient

to Gain

Gen

Clip

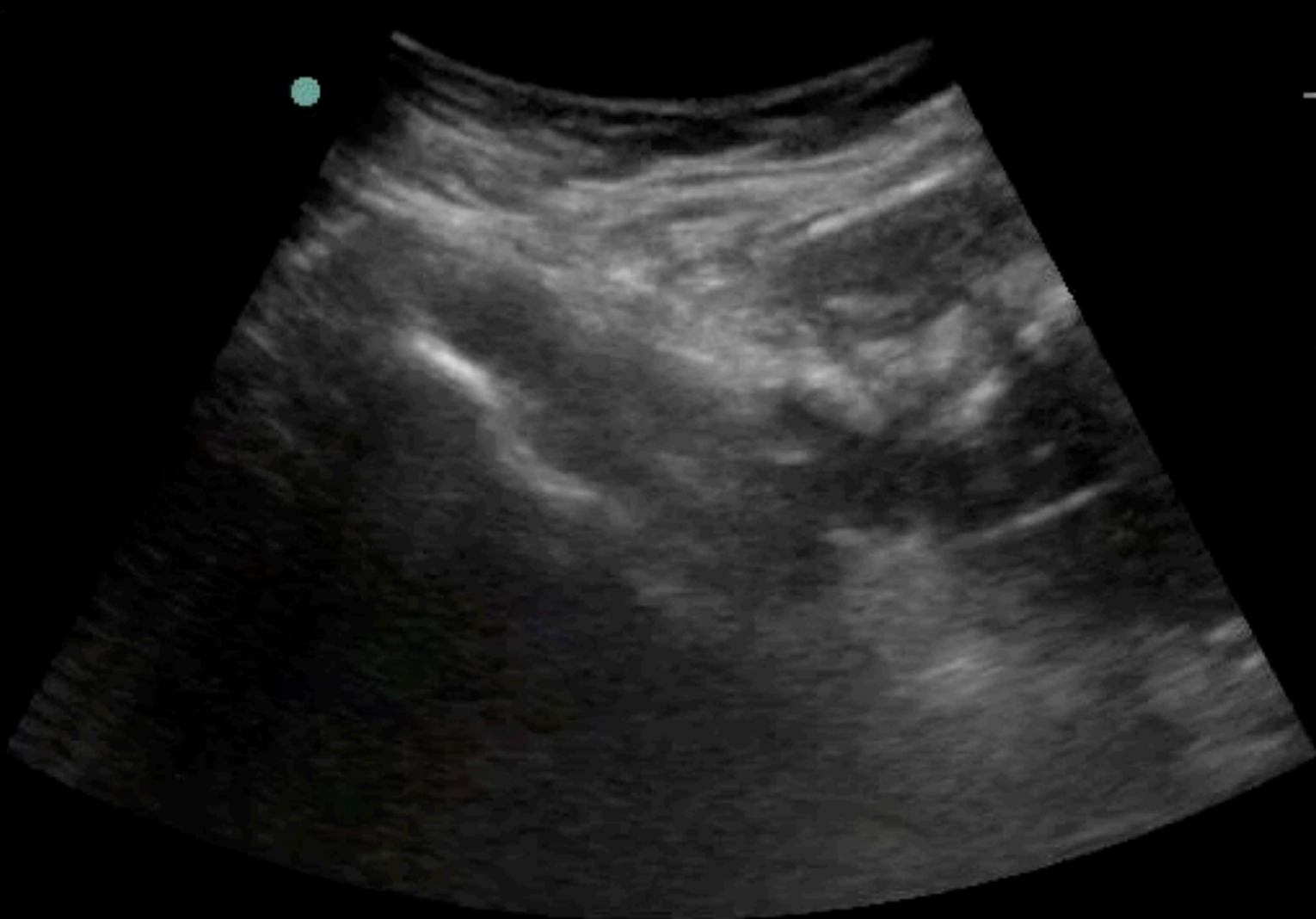
ge 1/3



Pigtail drainage - guiding needle



GenTHI MB



Abd
_ C60
71%
MI
0.8
TIS
0.2

Patient

Auto Gain

Gen

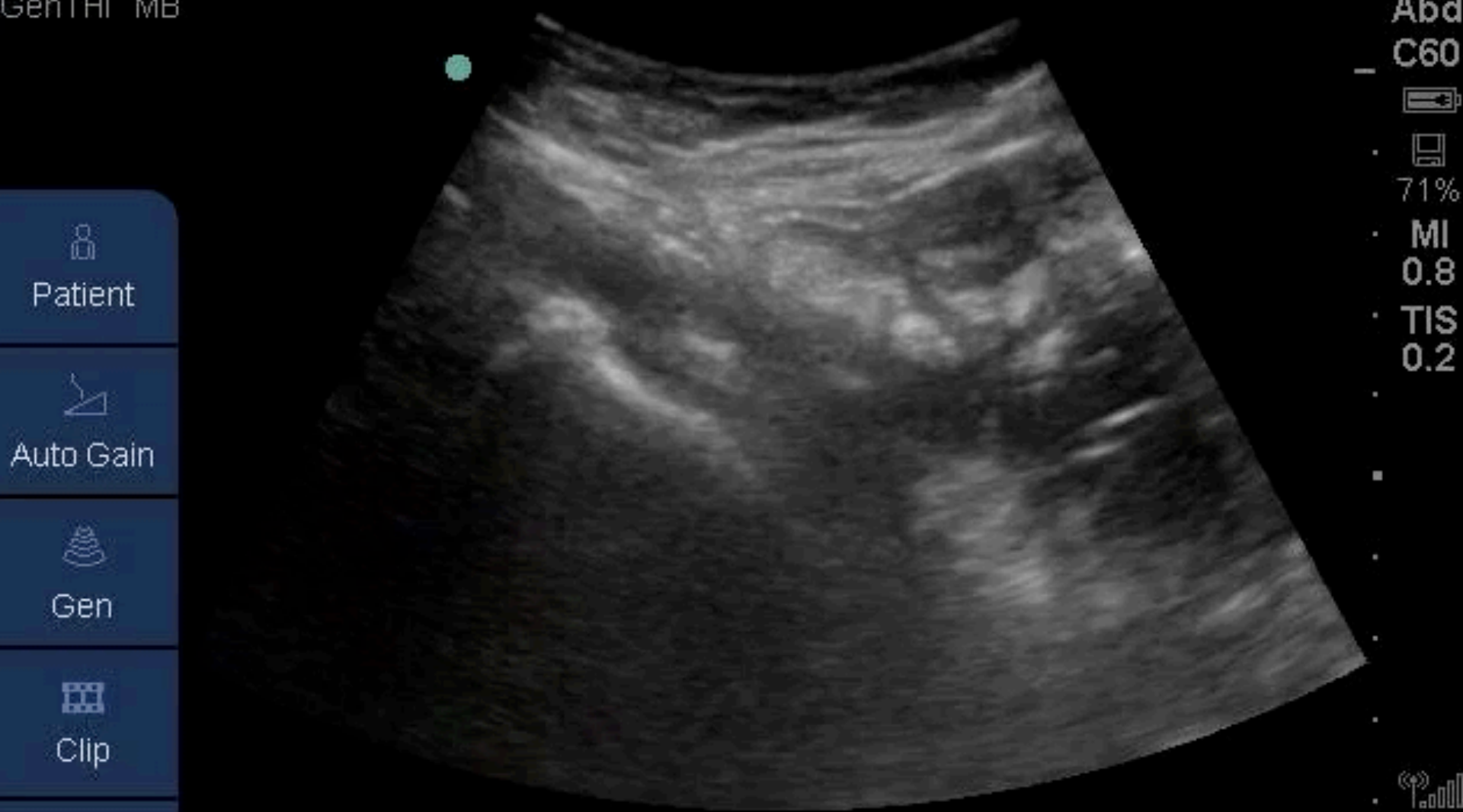
Clip



Pigtail drainage - guiding needle



GenTHI MB




Patient


Auto Gain


Gen


Clip

Abd

C60



71%

MI

0.8

TIS

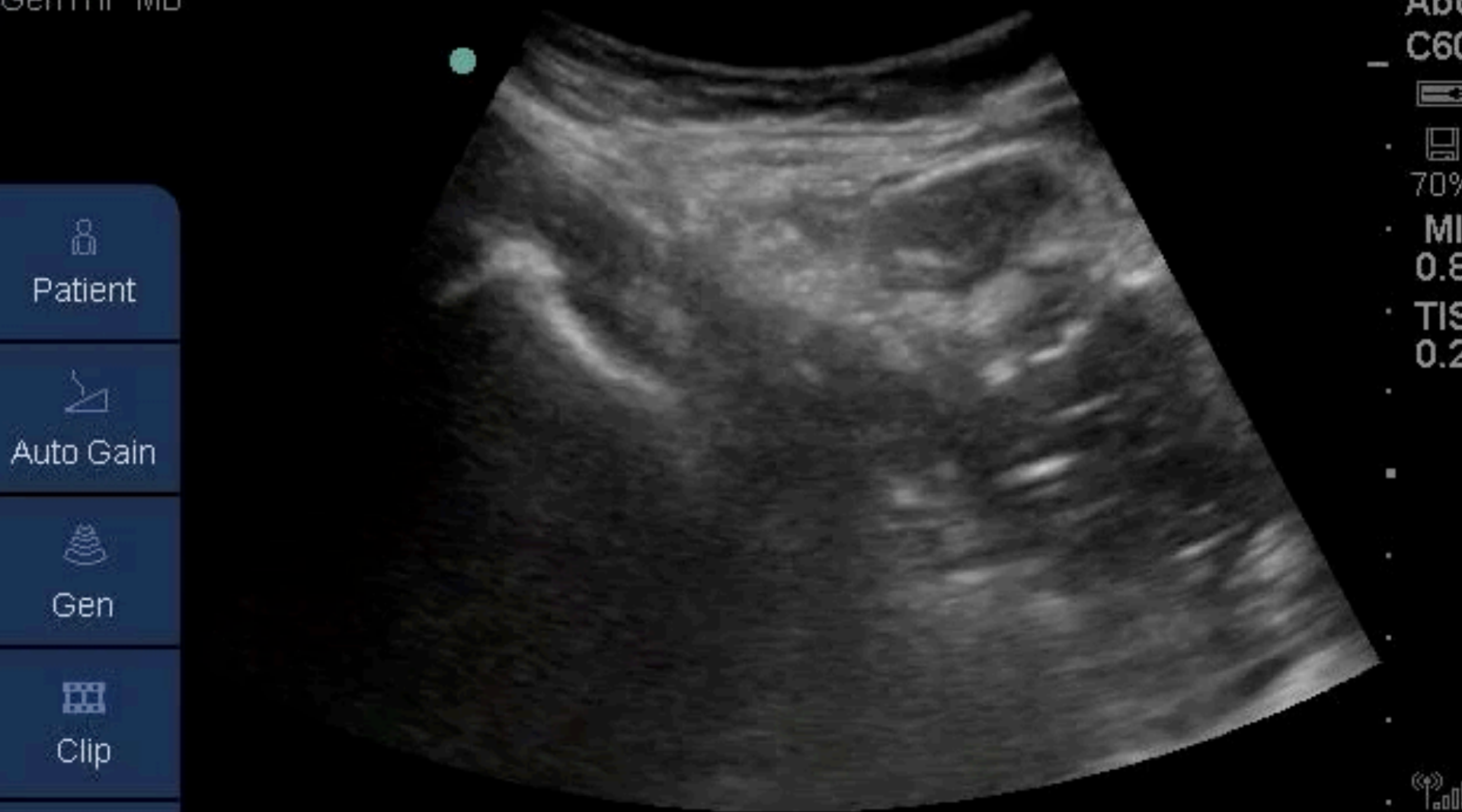
0.2



Pigtail drainage - guidewire



GenTHI MB



Patient



Auto Gain



Gen



Clip

Abd

C60



70%

MI

0.8

TIS

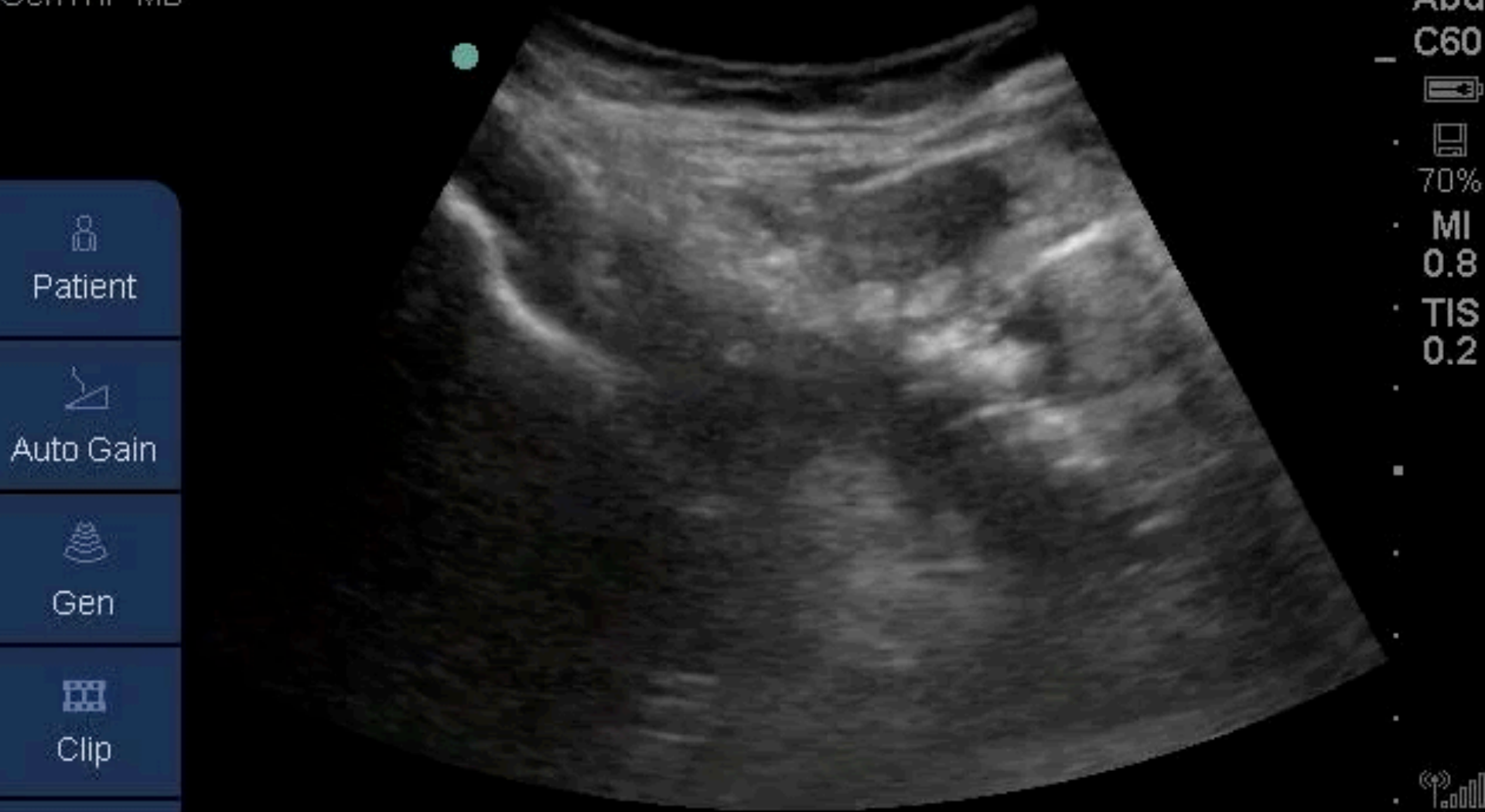
0.2



Pigtail drainage - pigtail through guidewire



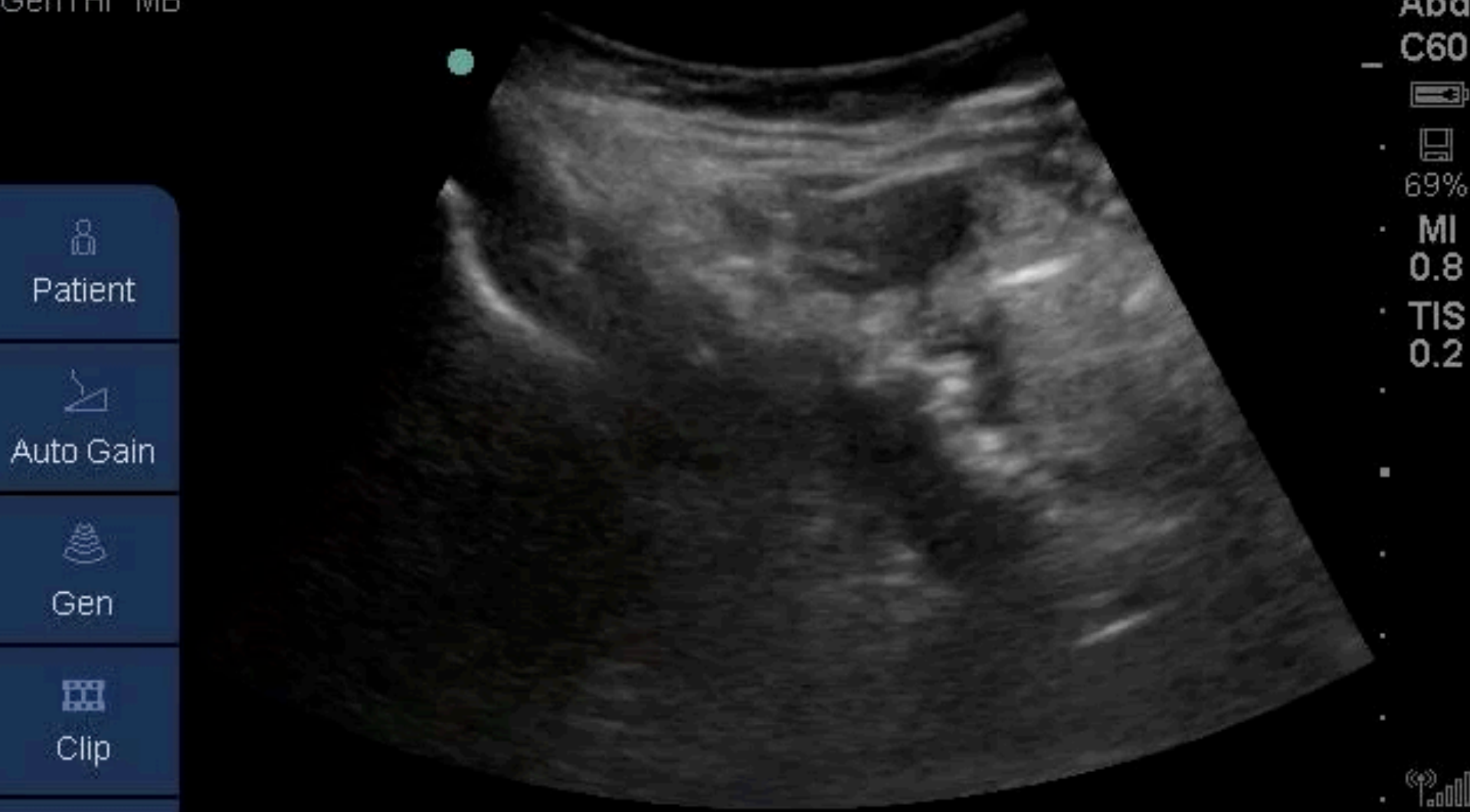
GenTHI MB



Pigtail drainage - pigtail through guidewire



GenTHI MB



Abd
C60
69%
MI
0.8
TIS
0.2

Patient

Auto Gain

Gen

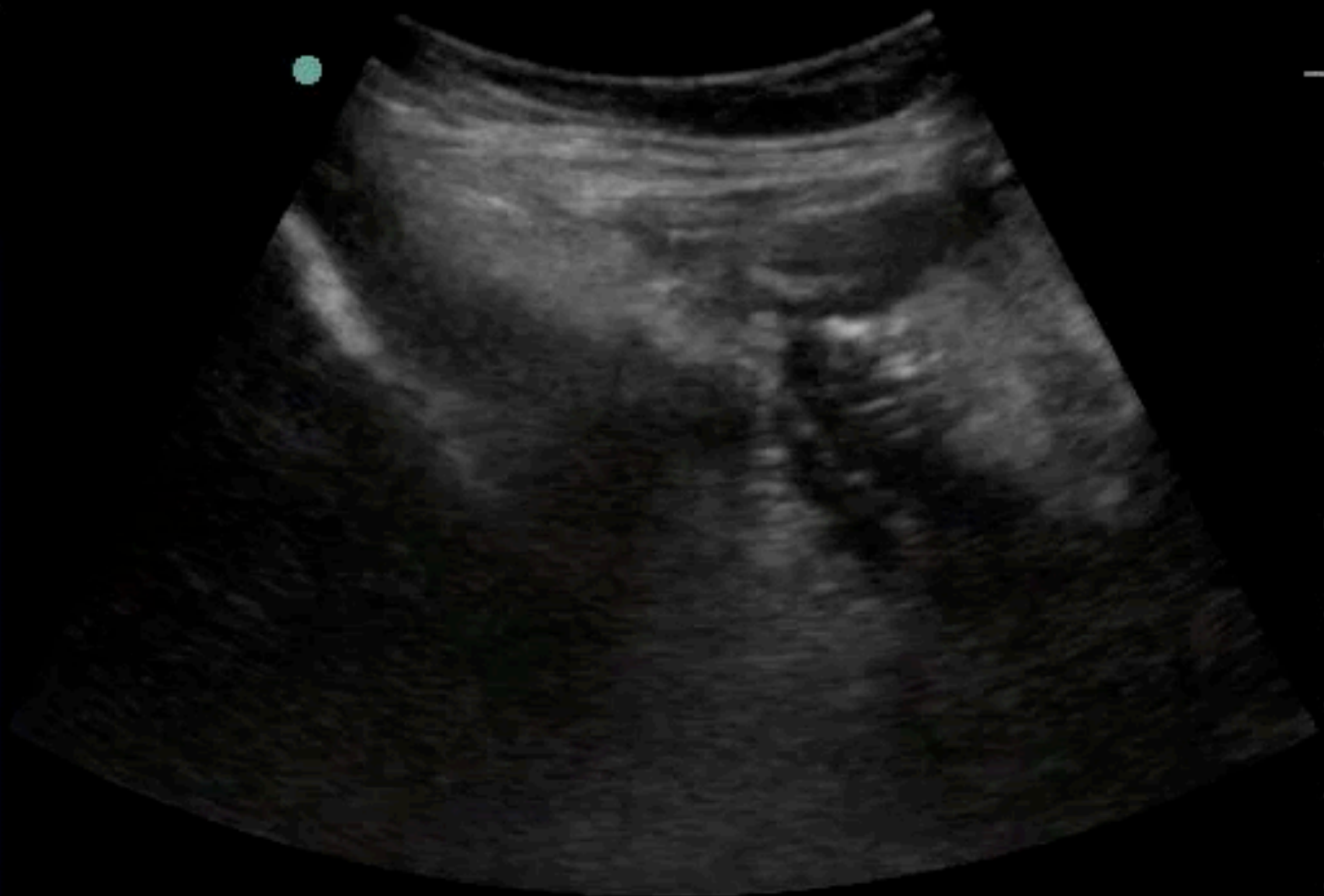
Clip



Pigtail drainage - pigtail



GenTHI MB



Abd

C60



69%

MI

0.8

TIS

0.2



Patient



Auto Gain



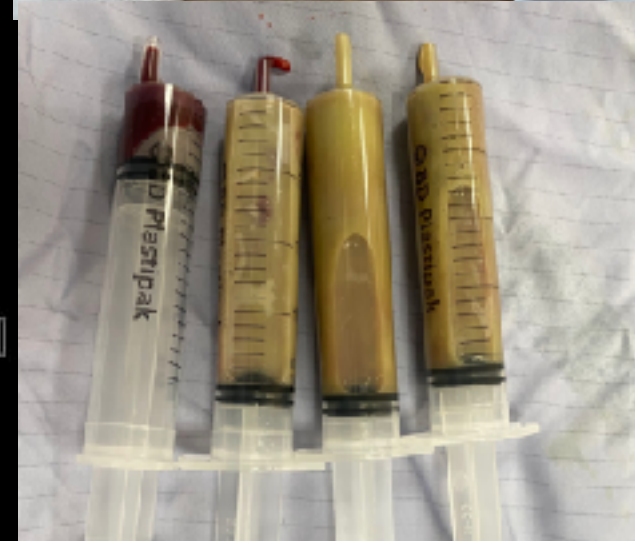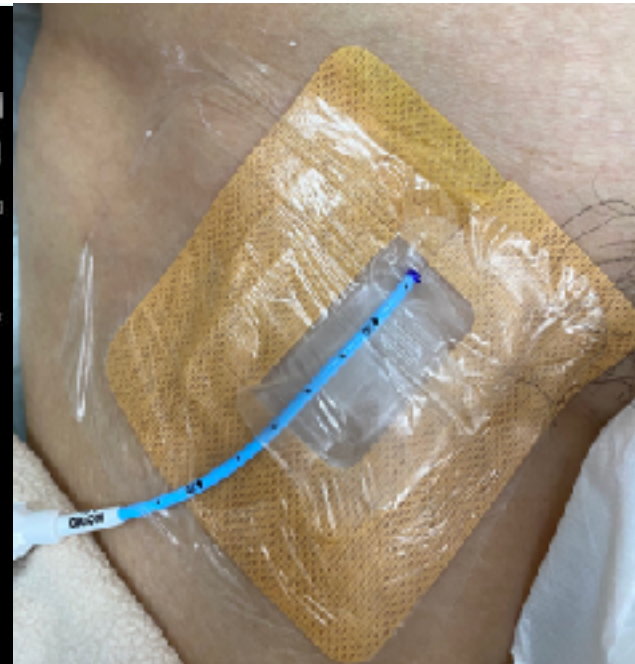
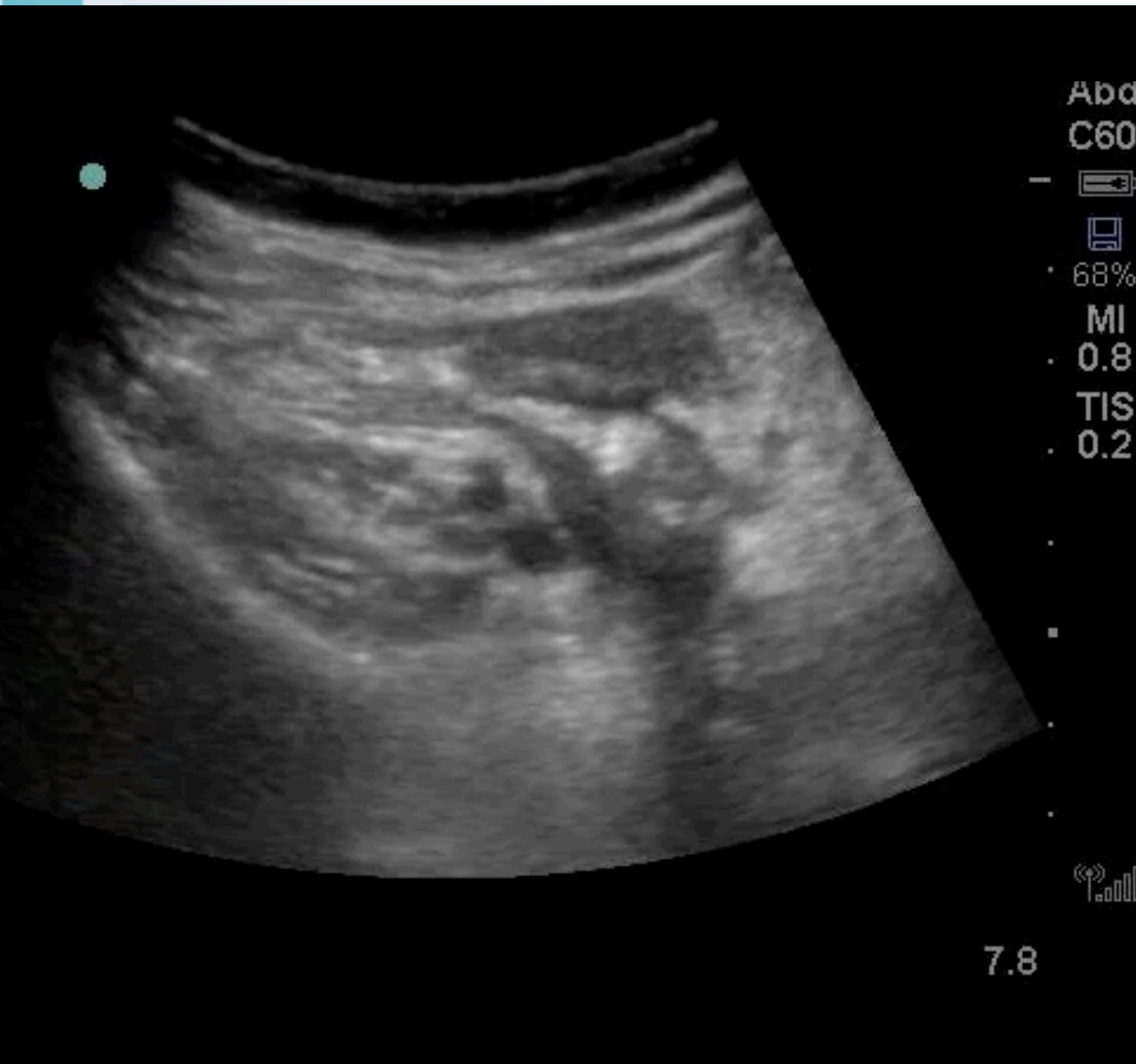
Gen



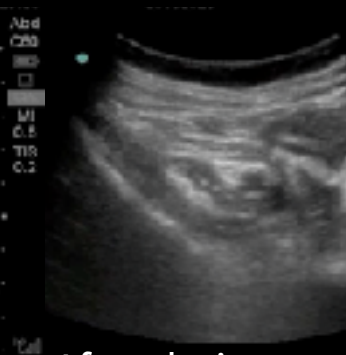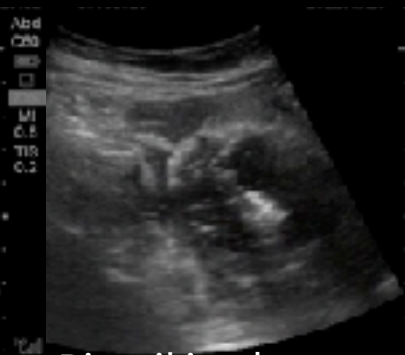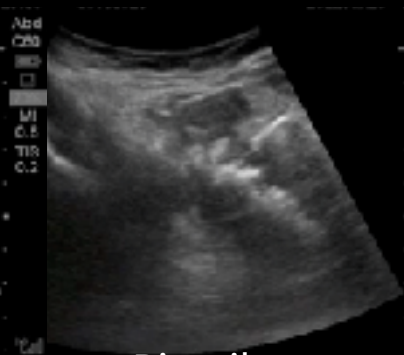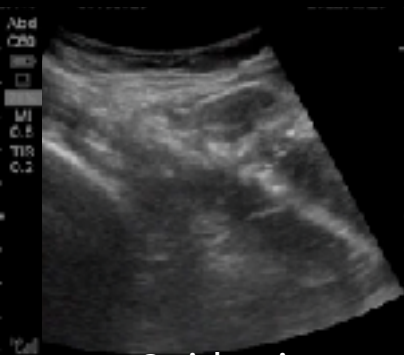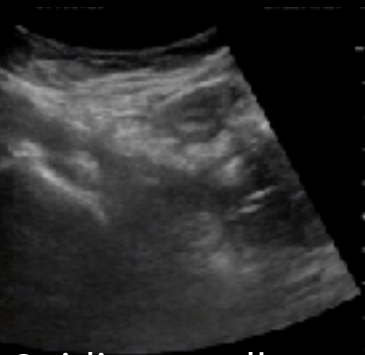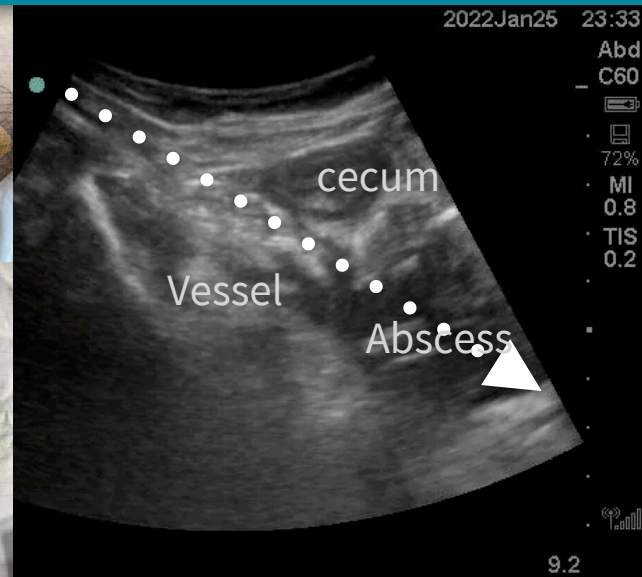
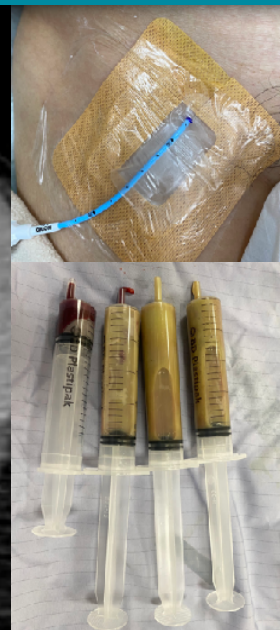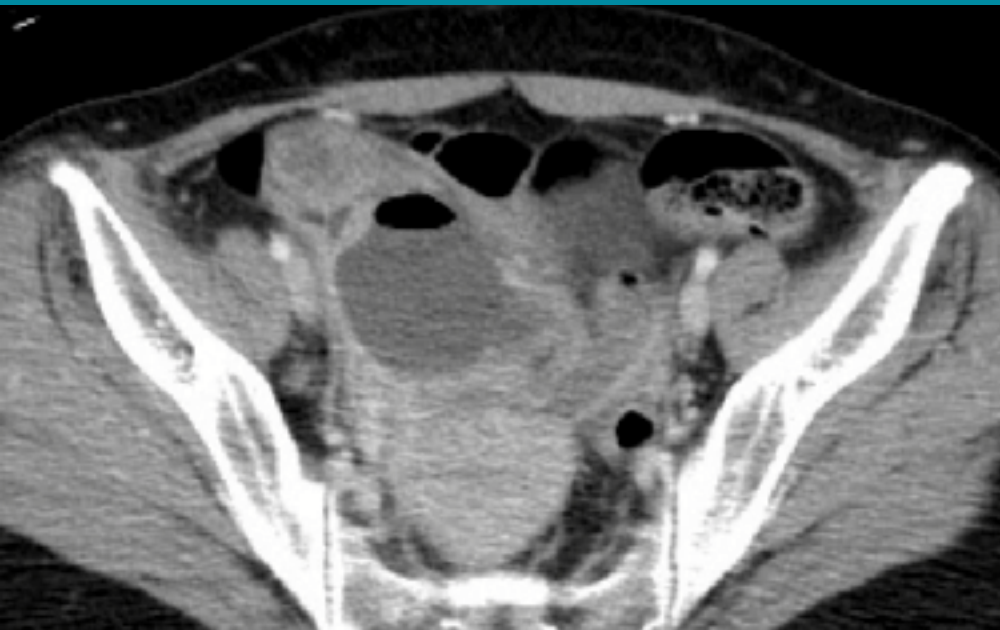Clip



FIRST: master needling



Practice makes perfect needling !!



Guiding needle

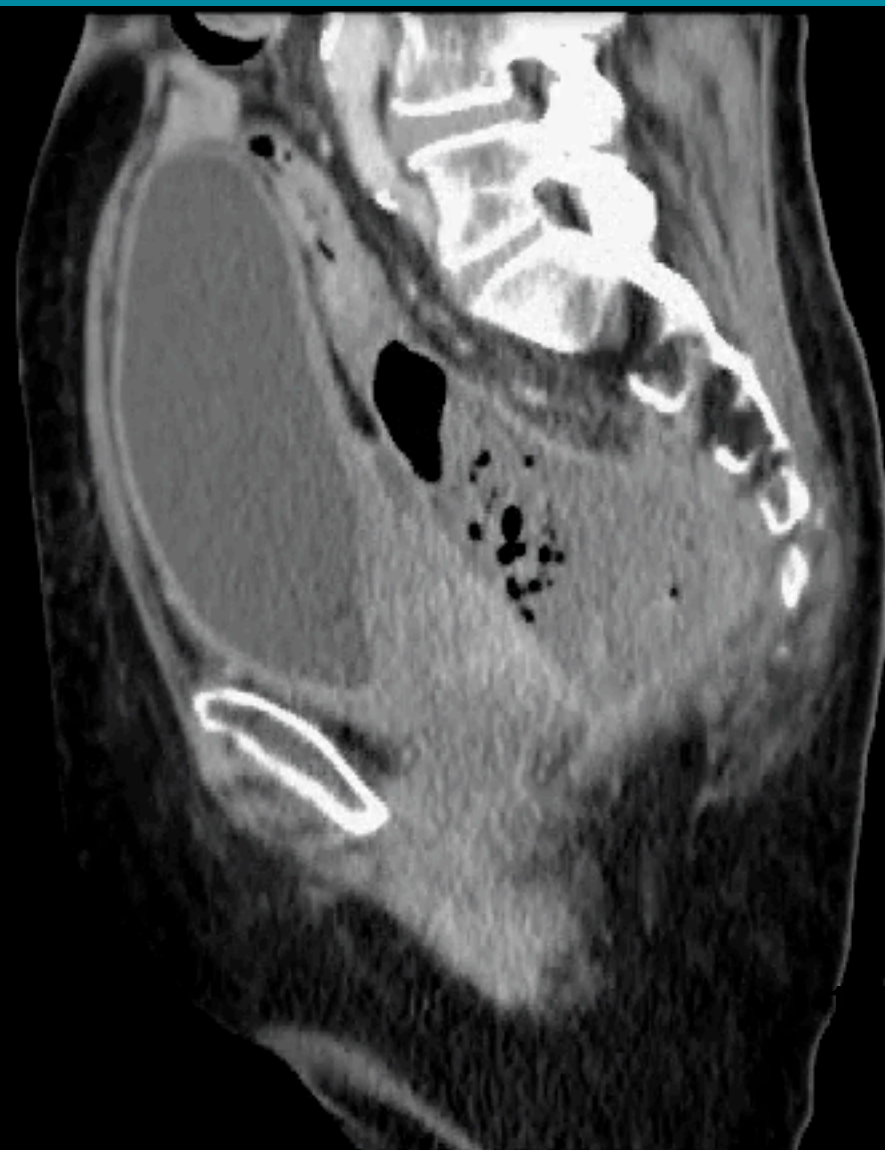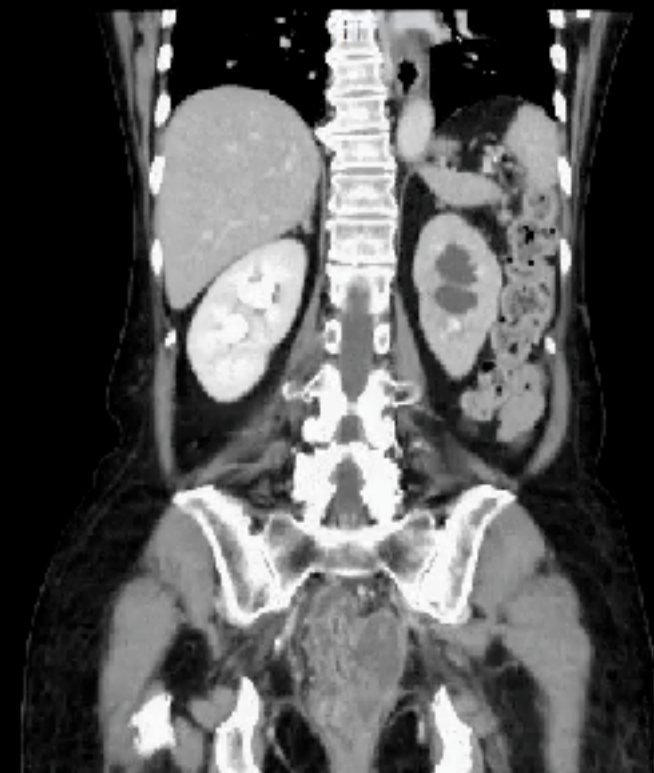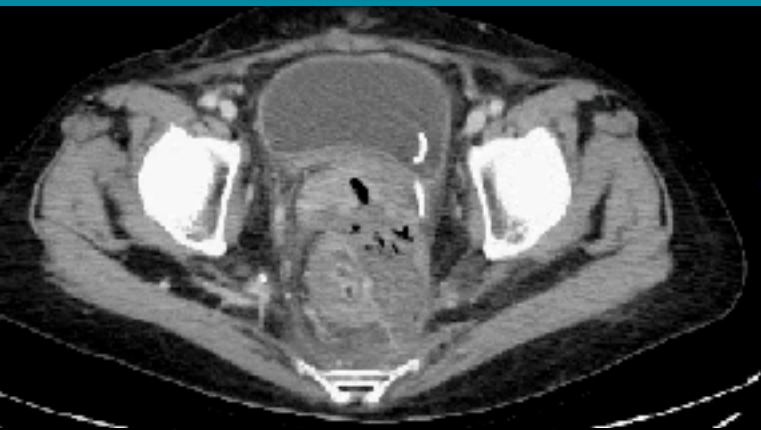Guidewire

Pigtail

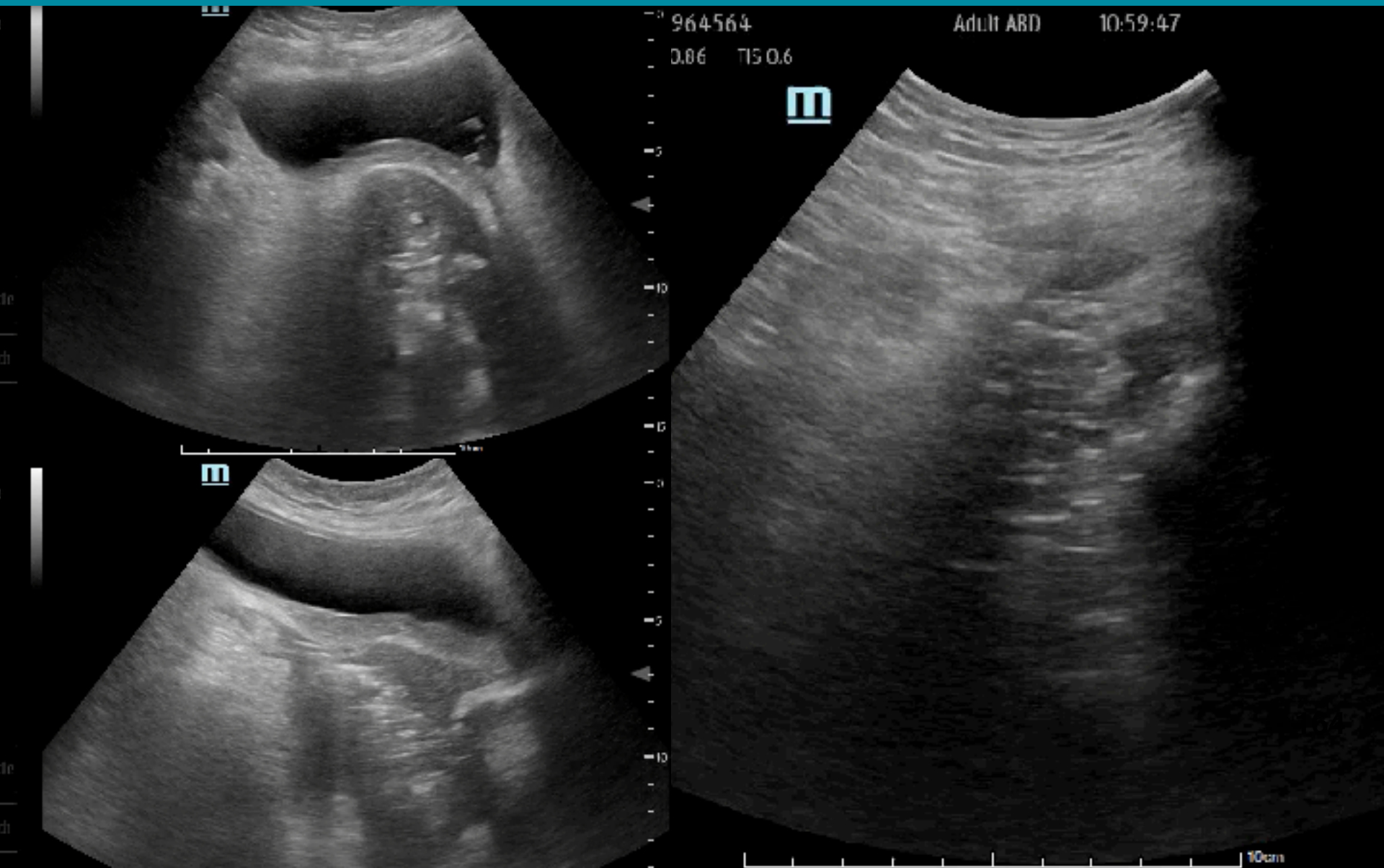
Pigtail in abscess

After drainage

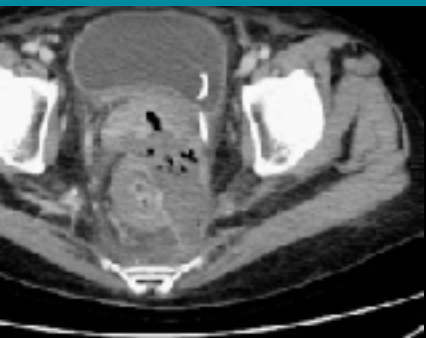72F, Ovarian ca, fever, low abd pain



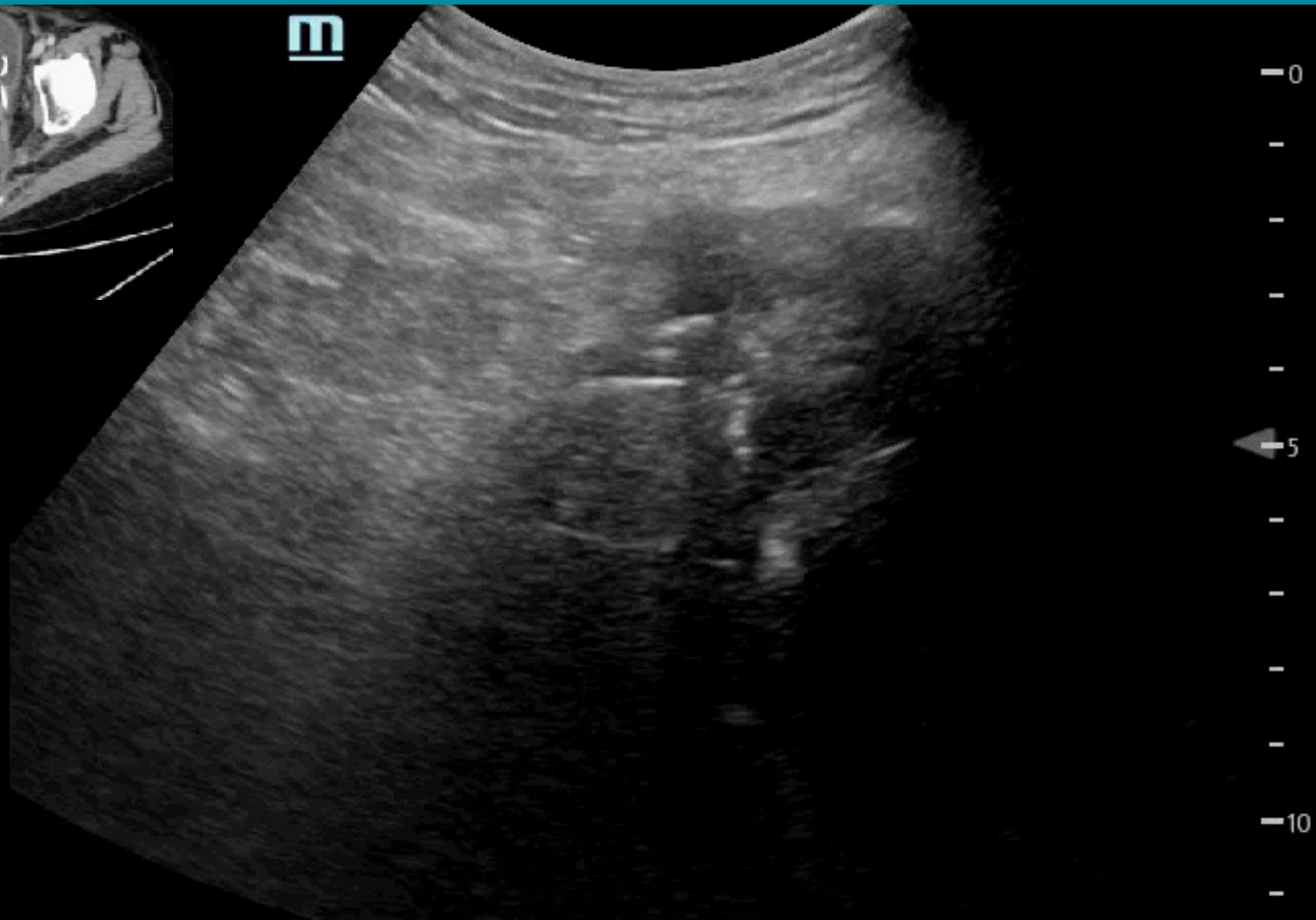
Pelvic abscess



Gluteal pigtail drainage



m



5cm
needle

iTouch

Master Advanced Procedures

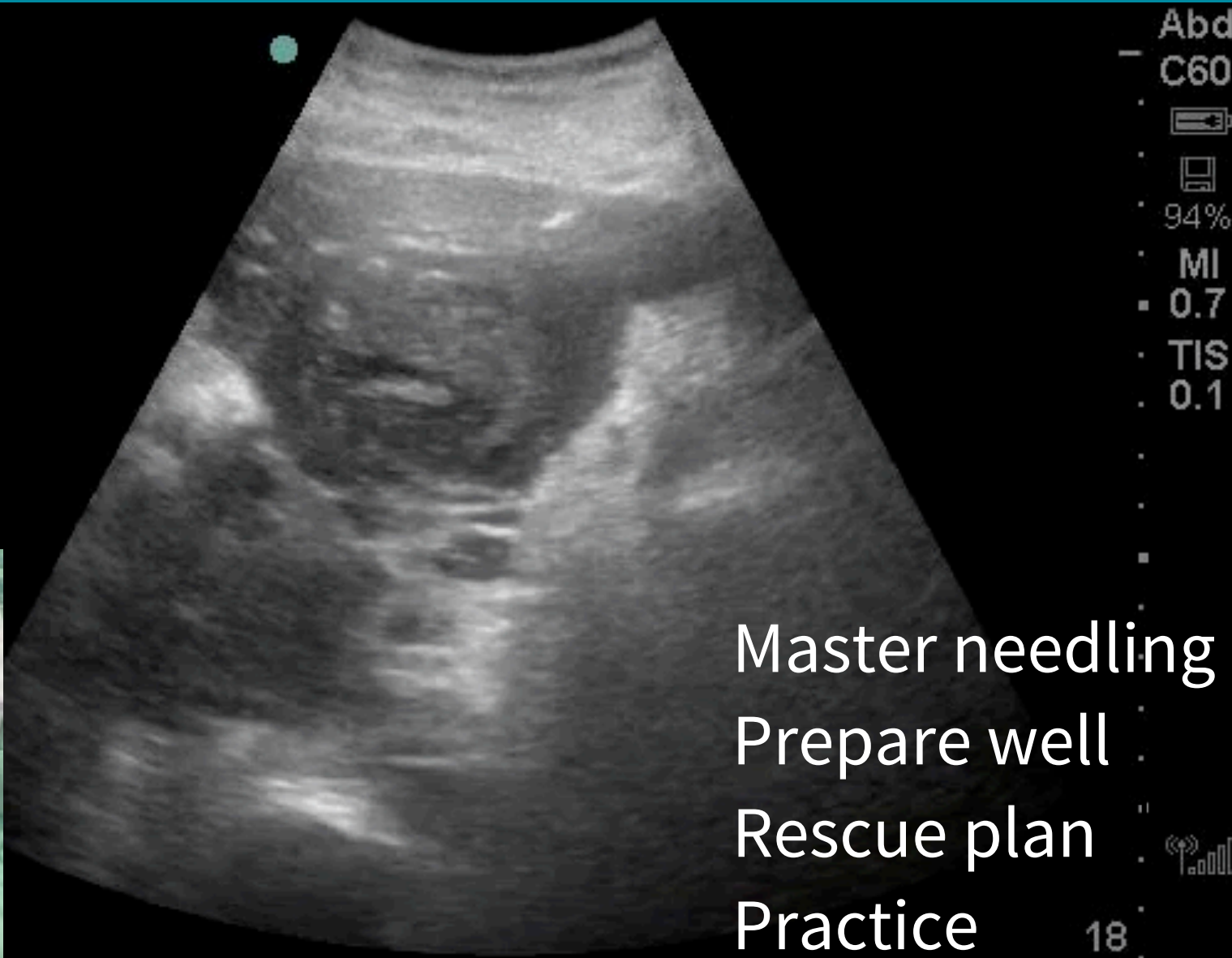
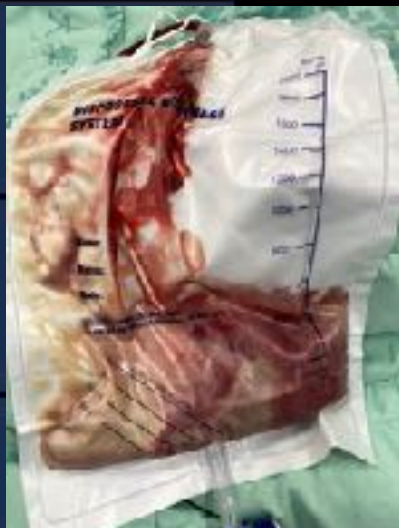GenTHI MB



Patient



Auto Gain



Abd

C60



94%

MI

0.7

TIS

0.1

Master needling
Prepare well
Rescue plan
Practice

超音波看得到的地方，沒有理由到不了！！

