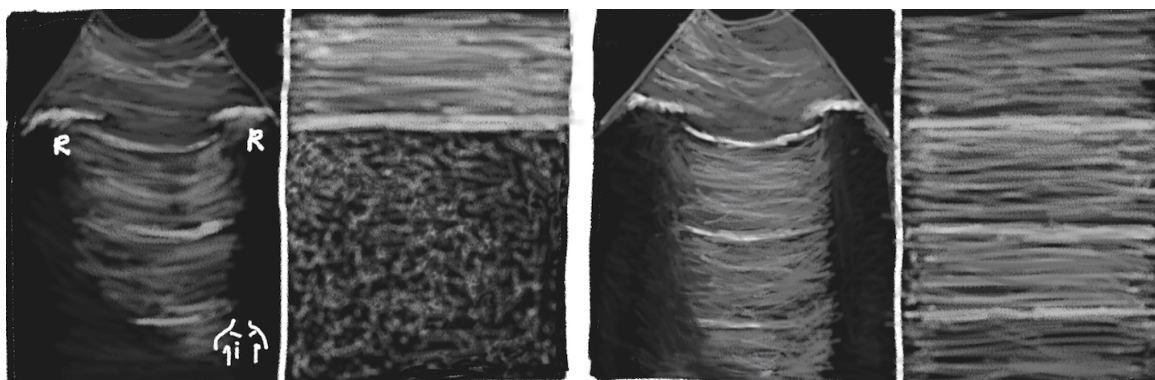




衛生福利部雙和醫院
(委託臺北醫學大學興建經營)
Taipei Medical University - Shuang Ho Hospital,
Ministry of Health and Welfare



POCUS for thoracic cavity



陳國智醫師

雙和醫院 急診醫學科

juice119@gmail.com / POCUSacademy.com

F.O.R.E.S.I.G.H.T. Comprehensive Perioperative Ultrasound Examination

Focused
Peri **O**perative
Risk
Evaluation
Sonography
Involving
Gastro-Abdominal
Hemodynamic, and
Trans-Thoracic Ultrasound

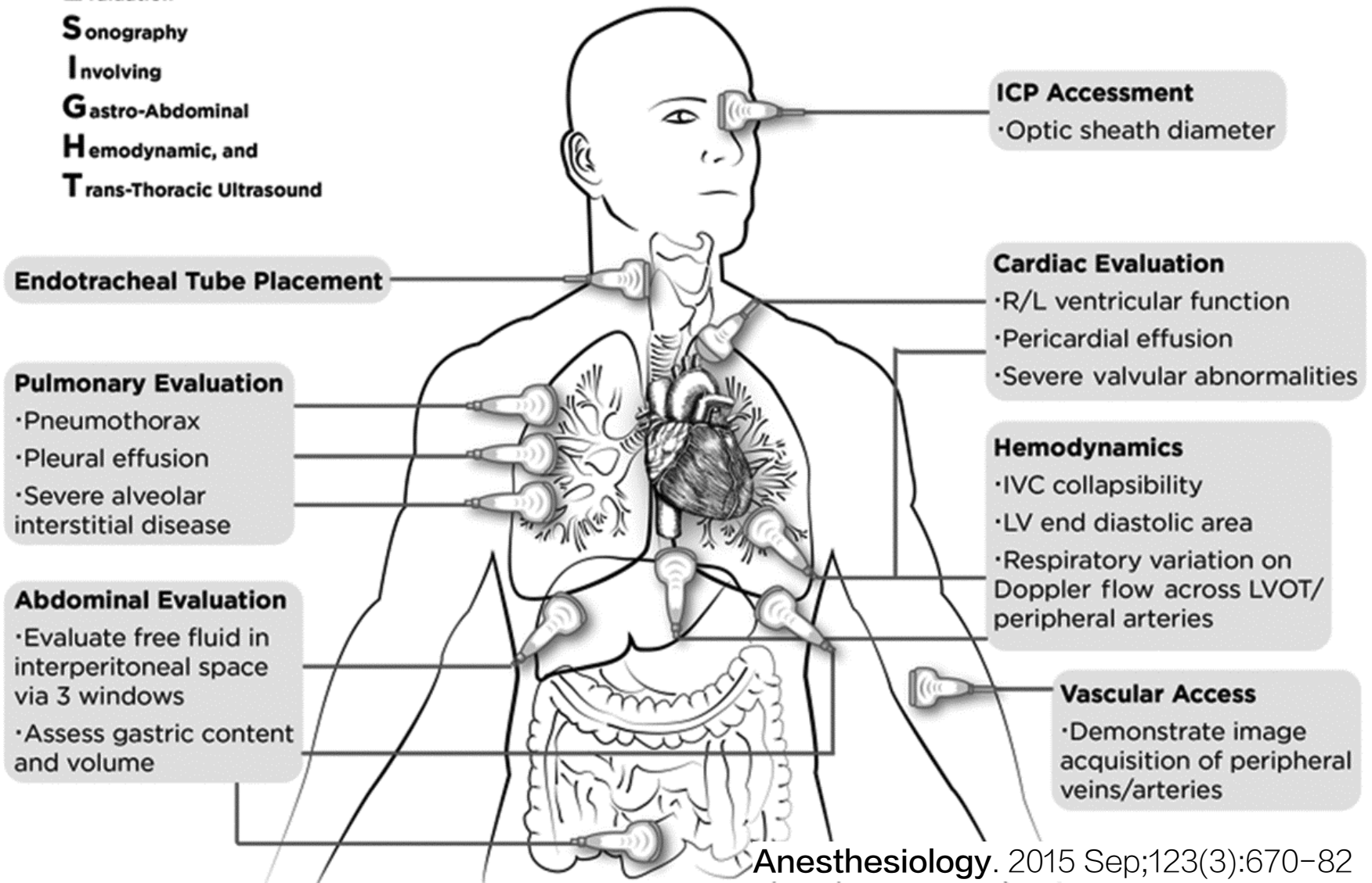
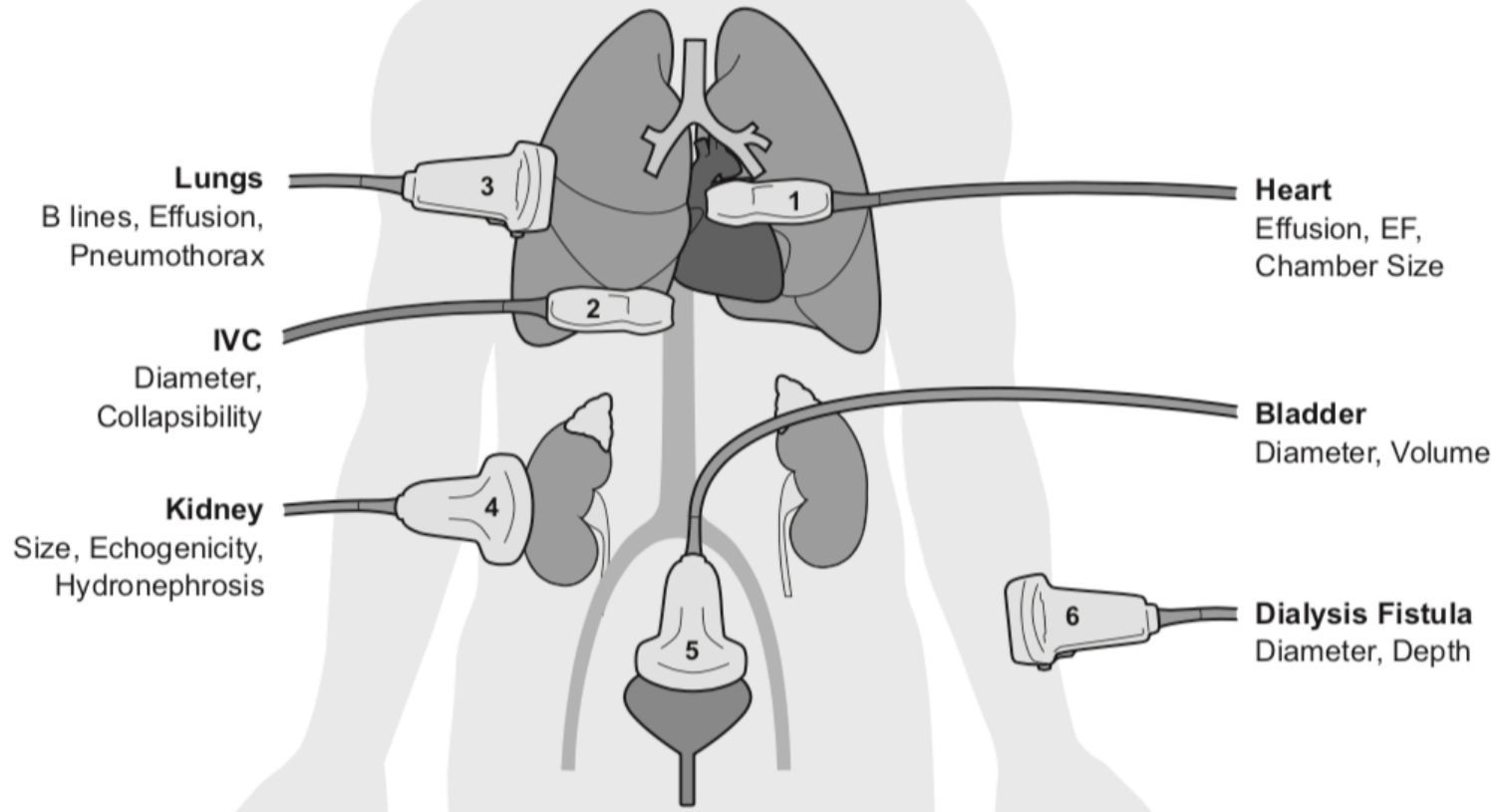


	IMAGE AREA	IMAGE ACQUISITION	PROBE
1	Heart	Parasternal Long Axis (PLAX)	Phased
2	Inferior Vena Cava	Subcostal	Phased
3	Lung	Anterior, Lateral, Posterior	Linear
4	Kidney	Longitudinal, Transverse	Curved
5	Bladder	Suprapubic	Curved
6	Dialysis Fistula	Longitudinal and Transverse	Linear

Johns Hopkins **Nephrology** fellowship

POCUS curriculum



Lung Ultrasound: The Essentials

Thomas J. Marini, MD • Deborah J. Rubens, MD • Yu T. Zhao, BA • Justin Weis, MD • Timothy P. O'Connor, MD • William H. Novak, MD • Katherine A. Kaproth-Joslin, MD, PhD

From the Departments of Imaging Sciences (T.J.M., D.J.R., Y.T.Z., K.A.K.J.), Medicine (J.W., W.H.N.), and Emergency Medicine (T.P.O.), University of Rochester Medical Center, School of Medicine and Dentistry, 601 Elmwood Ave, Box 655, Rochester, NY 14642. Received October 24, 2020; revision requested January 5; revision received January 16; accepted February 5. **Address correspondence to** T.M. (e-mail: *RochesterRadiology2021@gmail.com*).

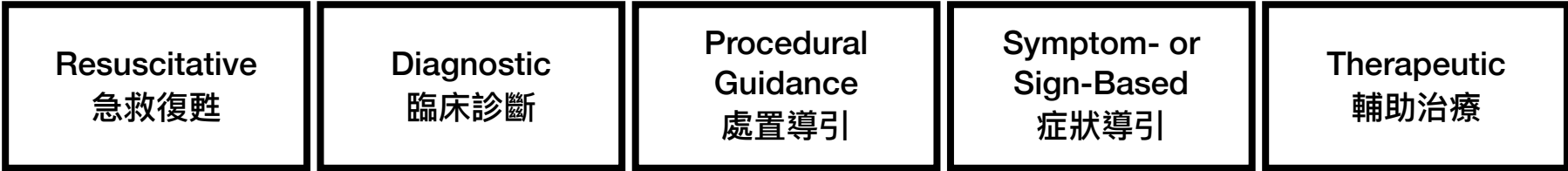Conflicts of interest are listed at the end of this article.

Radiology: Cardiothoracic Imaging 2021; 3(2):e200564 • <https://doi.org/10.1148/ryct.2021200564> • Content codes: **CH US**

Sensitivity and Specificity of Lung US versus Chest Radiography

Indication	Study Type	No. of Patients	Lung US		Chest Radiography	
			Sensitivity (%)	Specificity (%)	Sensitivity (%)	Specificity (%)
Pleural effusion (5)	Prospective	32	92	93	39	85
Pneumonia (7)	Systematic review with meta-analysis	742	95	90	77	91
Pneumothorax (4)	Systematic review with meta-analysis	5314	87	99	46	100
Pulmonary edema (6)	Systematic review with meta-analysis	1827	88	90	73	90

Note.—Sensitivity and specificity values vary slightly from study to study. The pleural effusion statistics are drawn from a sample of critically ill patients.



Core Applications (2023 ACEP Emergency Ultrasound Guidelines)
15項急診超音波核心應用

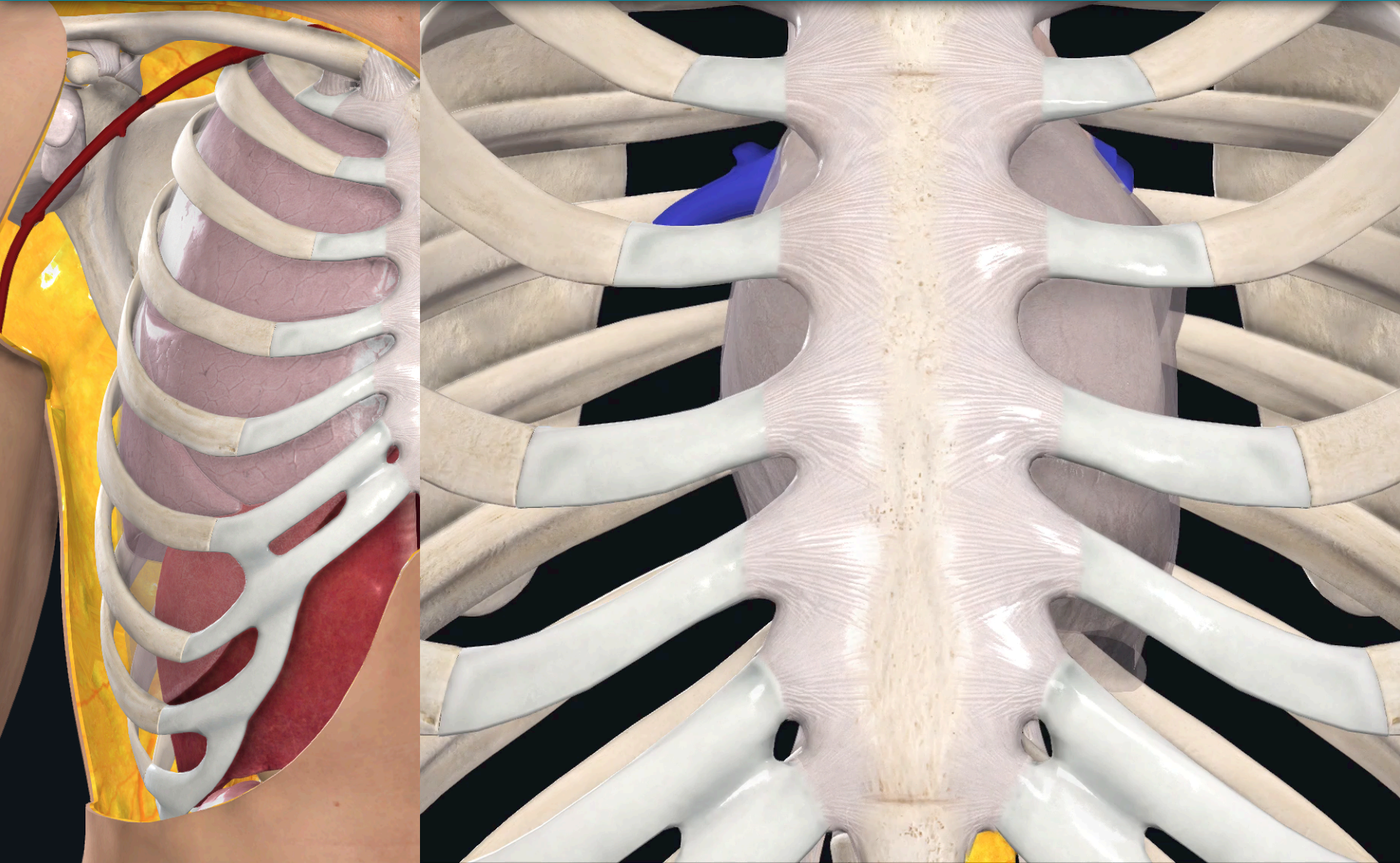
陳國智醫師

Aorta
 DVT
 Trauma
 Thoracic/Airway
 Cardia/HD assessment

Procedural Guidance
 US-guided NB
 Testicular
 Ocular
 Skin & Soft tissue

Hepatobiliary
 Urinary tract
 Pregnancy
 Bowel
 MSK

Thoracic cavity



Normal sternum

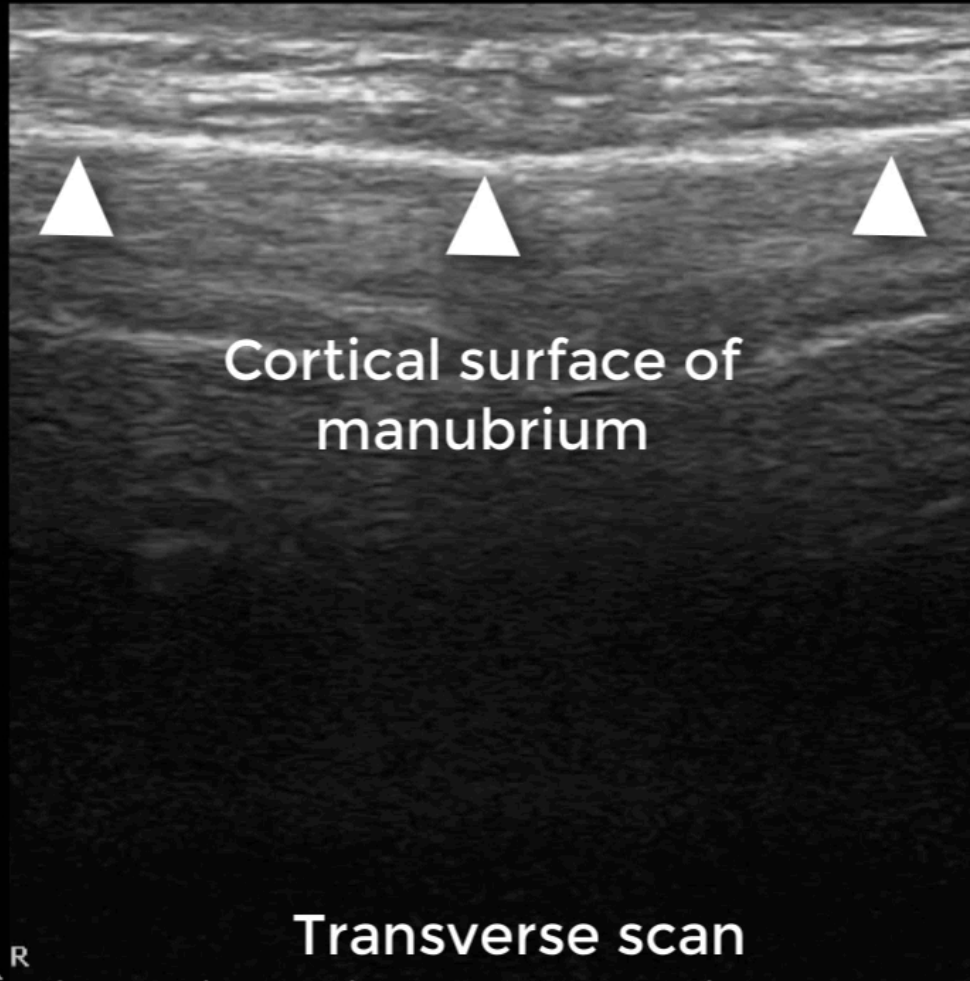
K Gen
2-4
Hz
5cm

es
n 100
3
/3/4

Right



P G R
4.0 12.0



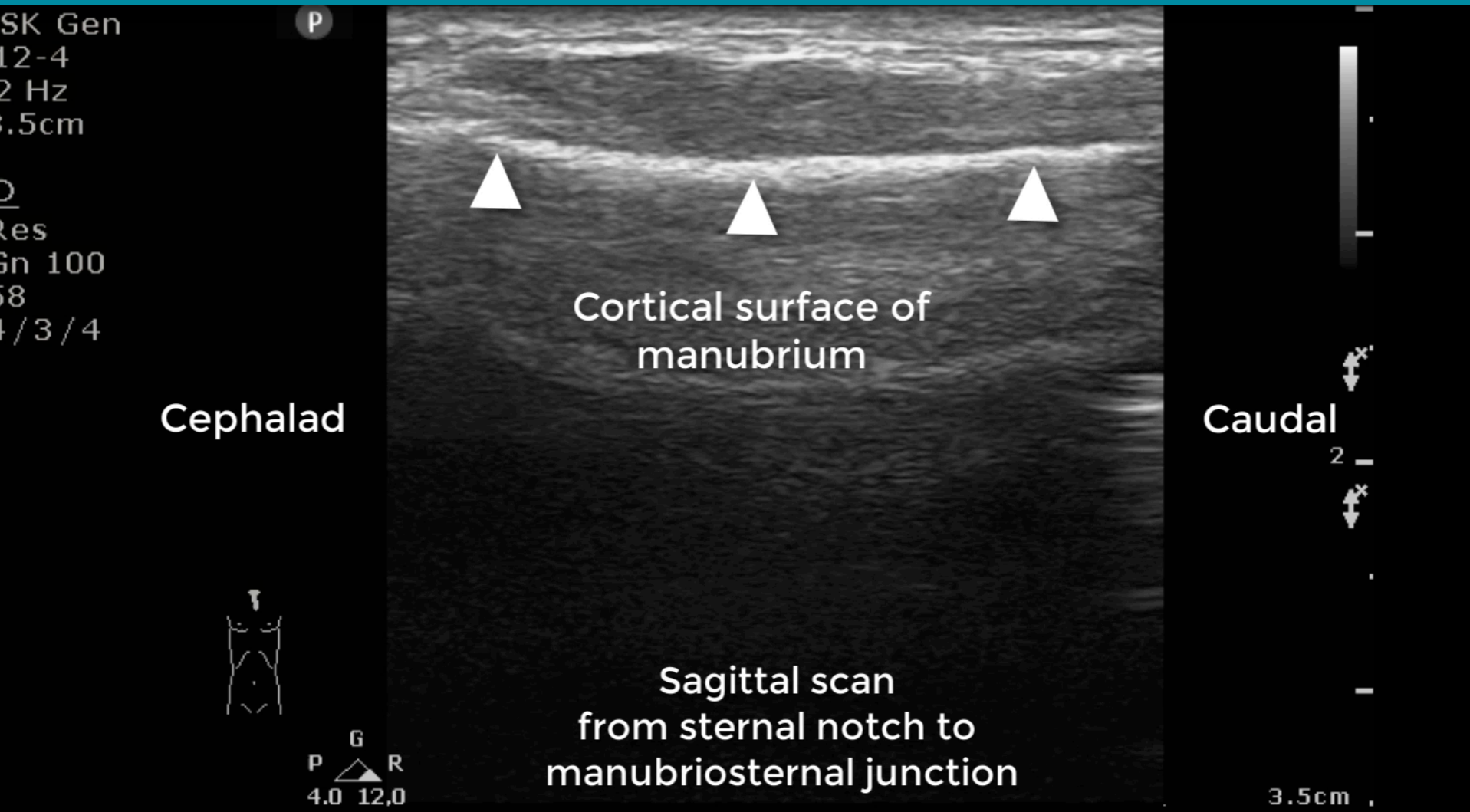
Transverse scan
from junction to xyphoid process



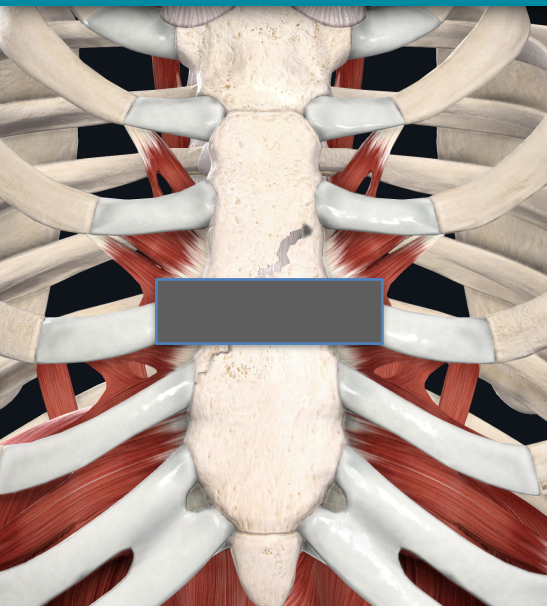
Left

3.5cm

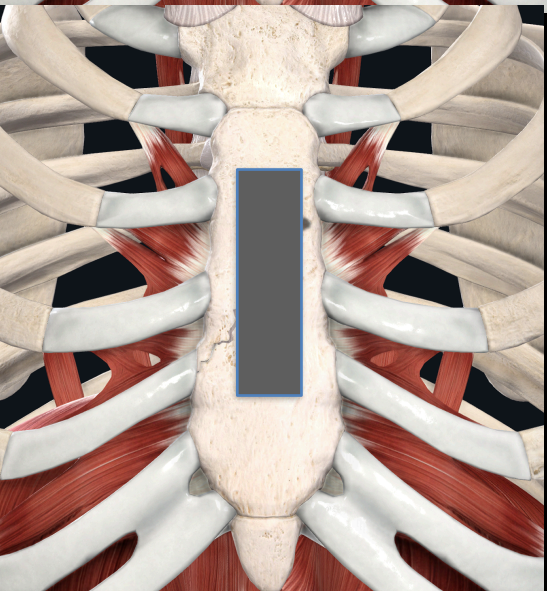
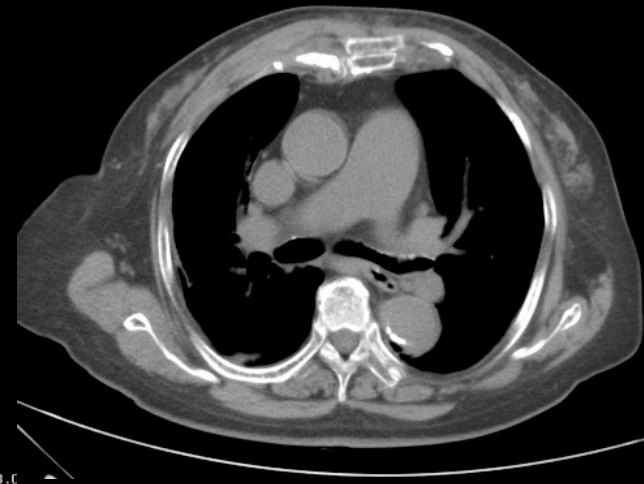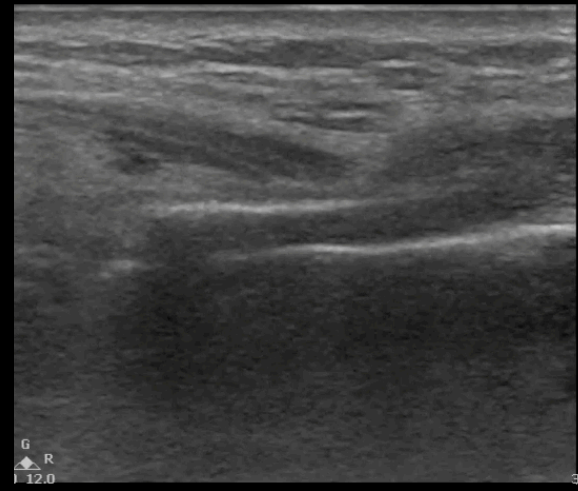
Normal sternum



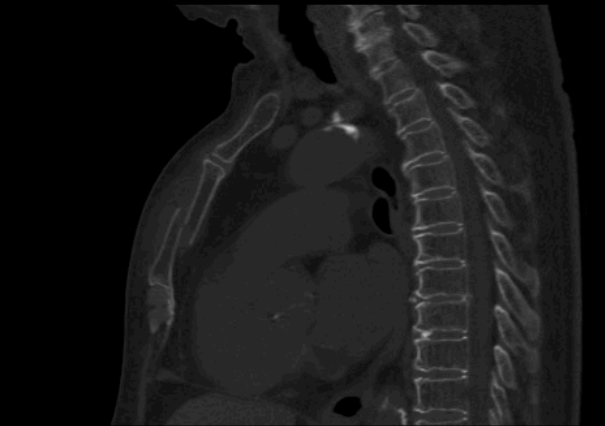
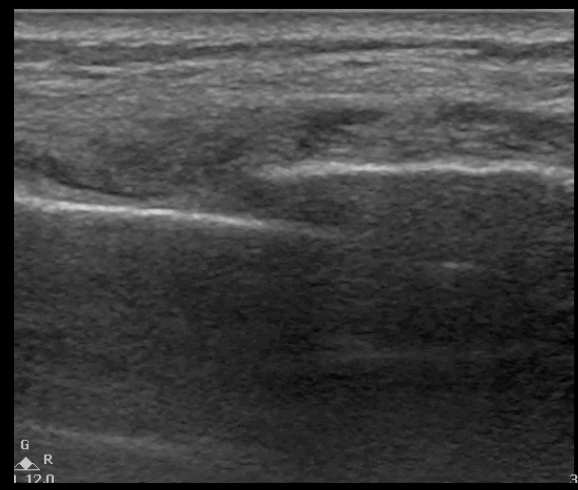
骨折判斷 - 適用長骨 & 平骨



高低落差

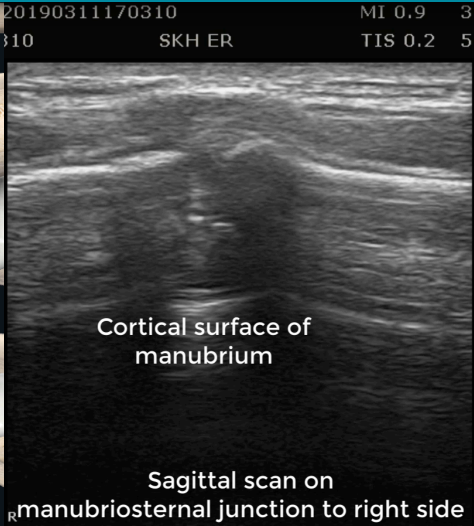
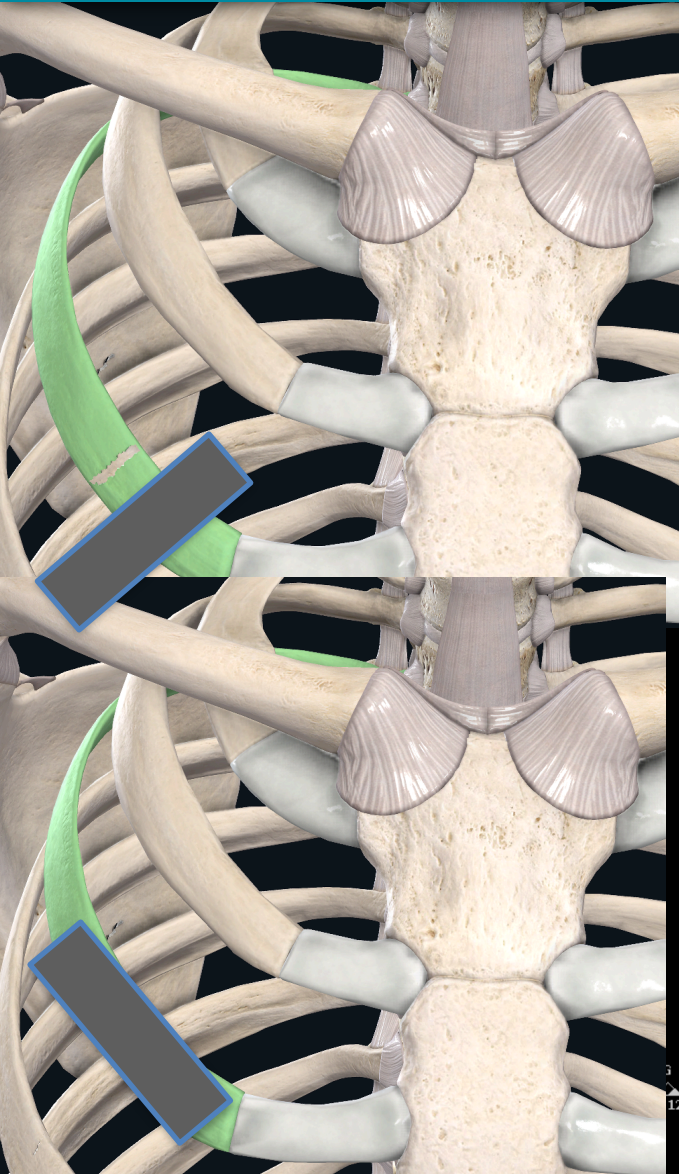


不連續

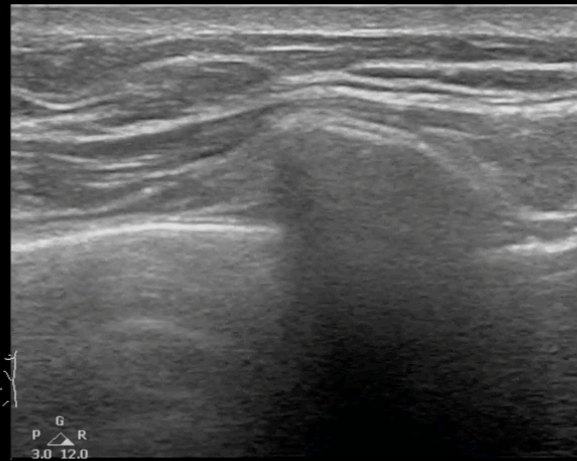


血腫

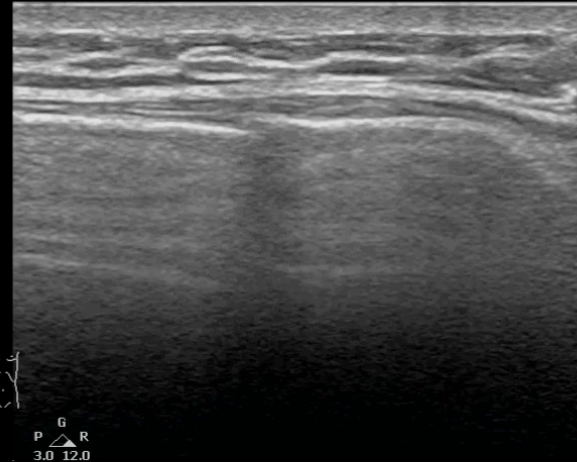
Rib fracture



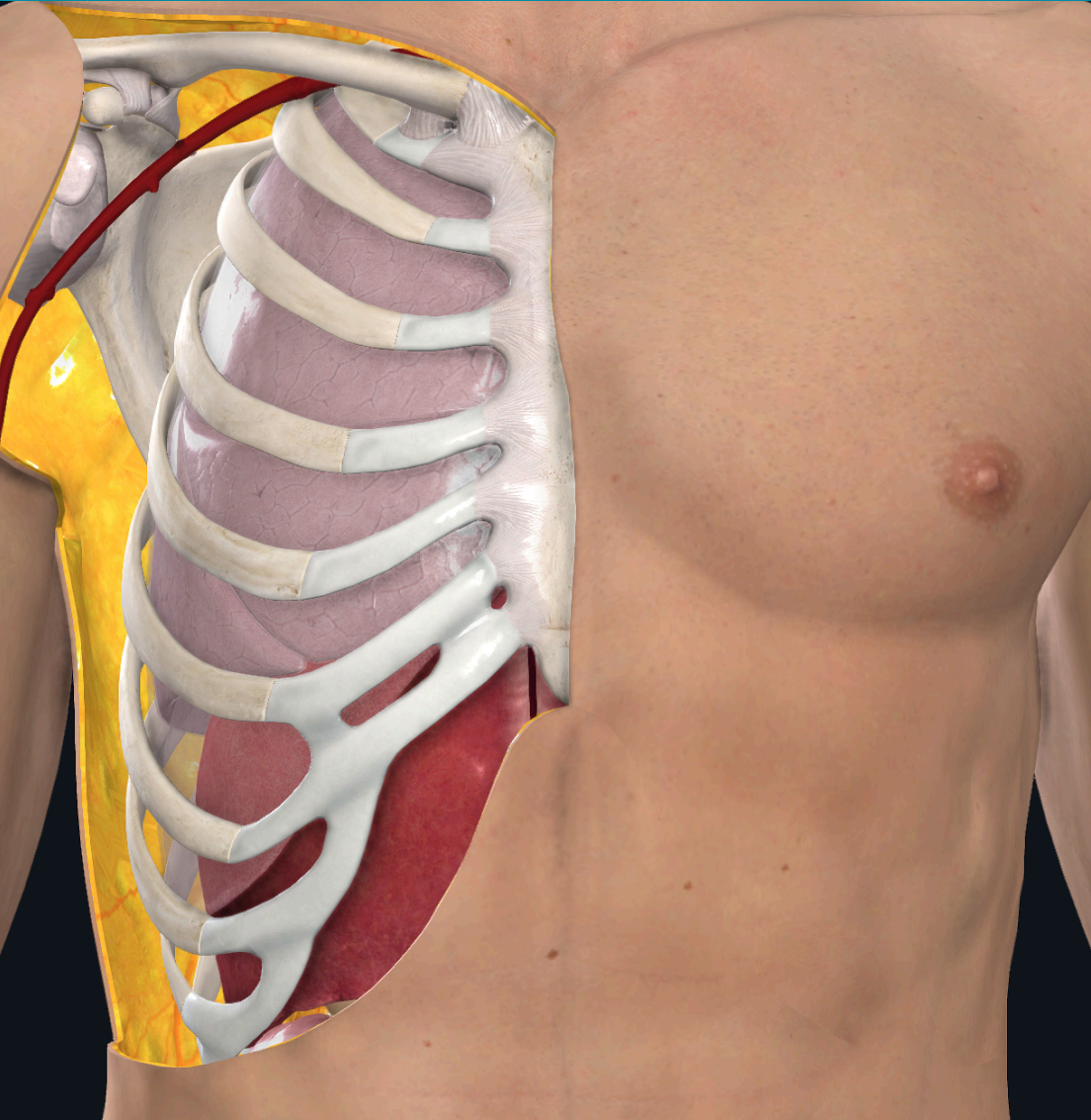
Superficial P
L12-3
46 Hz
3.0cm
2D
Res
Gn 96
C 56
3/2/1



Superficial P
L12-3
46 Hz
3.0cm
2D
Res
Gn 96
C 56
3/2/1

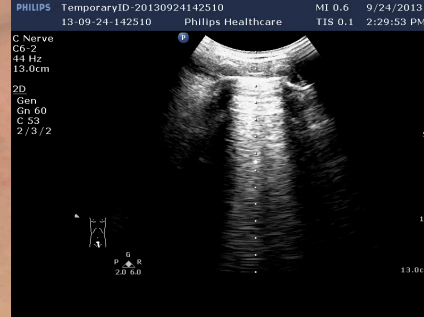
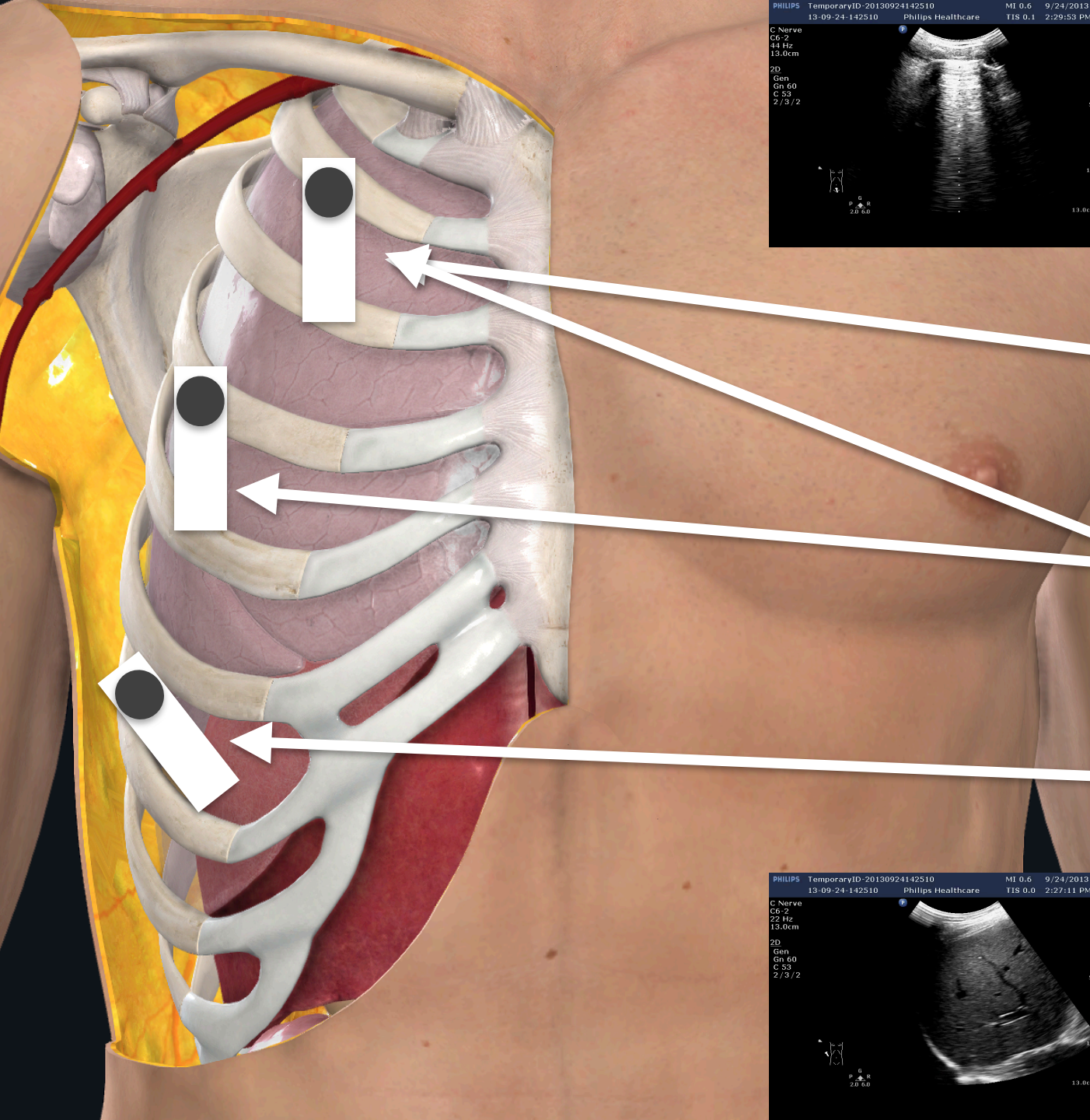


LUNG



Dyspnea
Chest pain

PTX
AIS
PLE

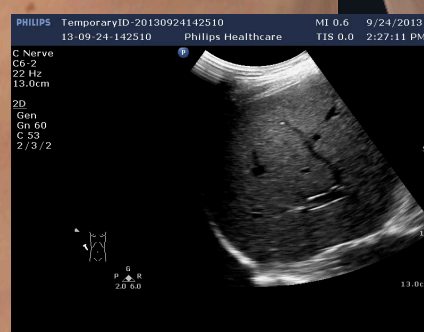


AIR

PTX

AIS

PLE



FLUID

NORMAL LUNG

肋膜/滑動

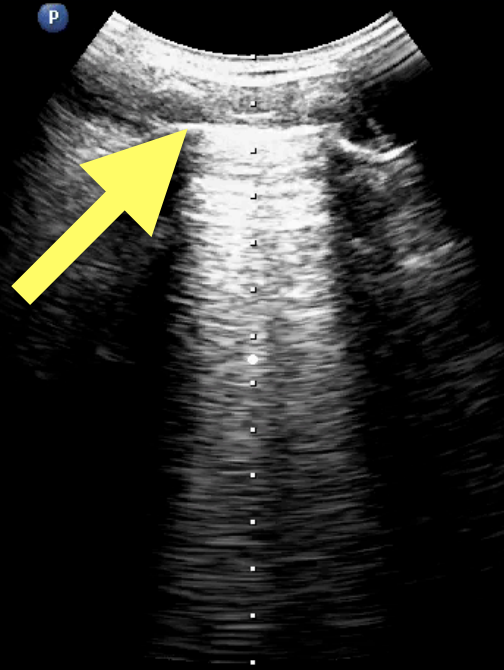
橫膈膜/移動

TemporaryID-20130924142510
13-09-24-142510 Philips Healthcare

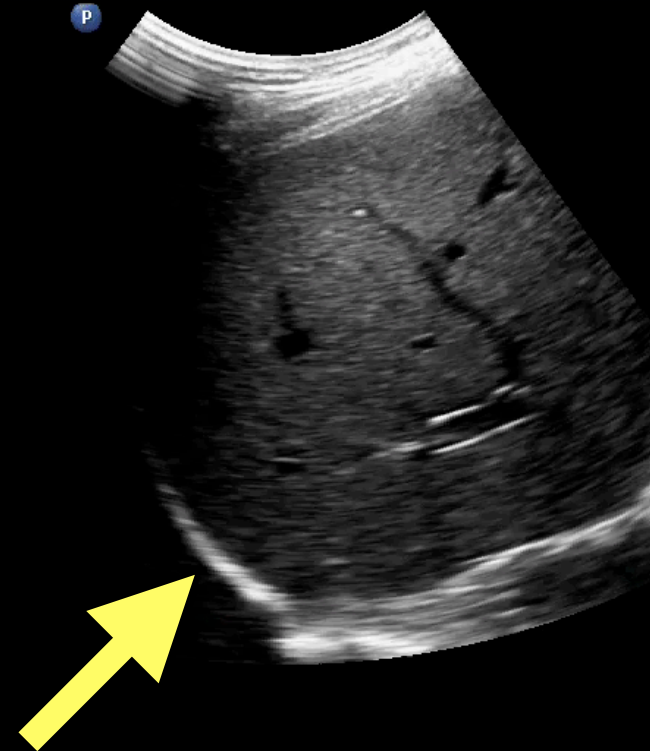
MI 0.6 9/ PHILIPS
TIS 0.1 2::

TemporaryID-20130924142510
13-09-24-142510 Philips Healthcare

MI 0.6 9/24
TIS 0.0 2:27

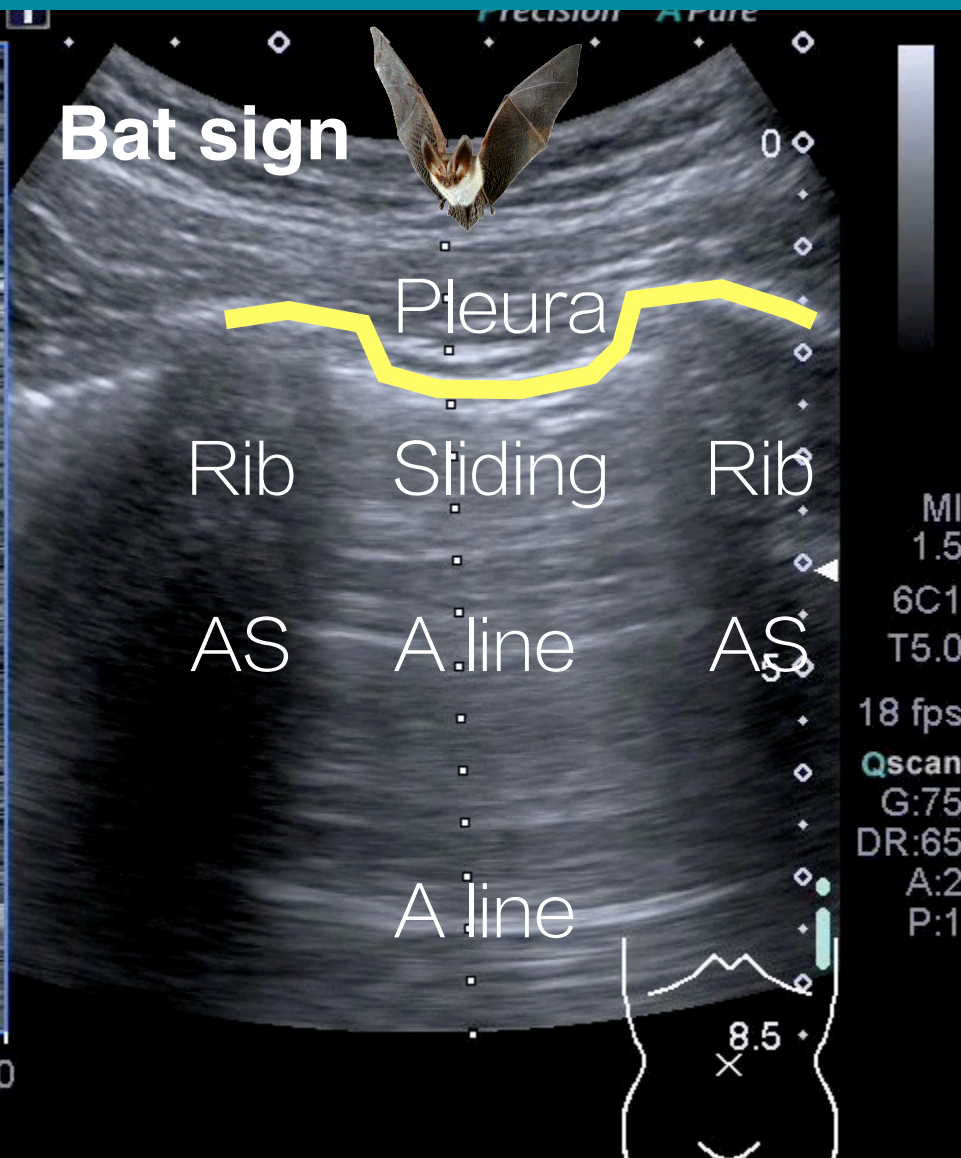
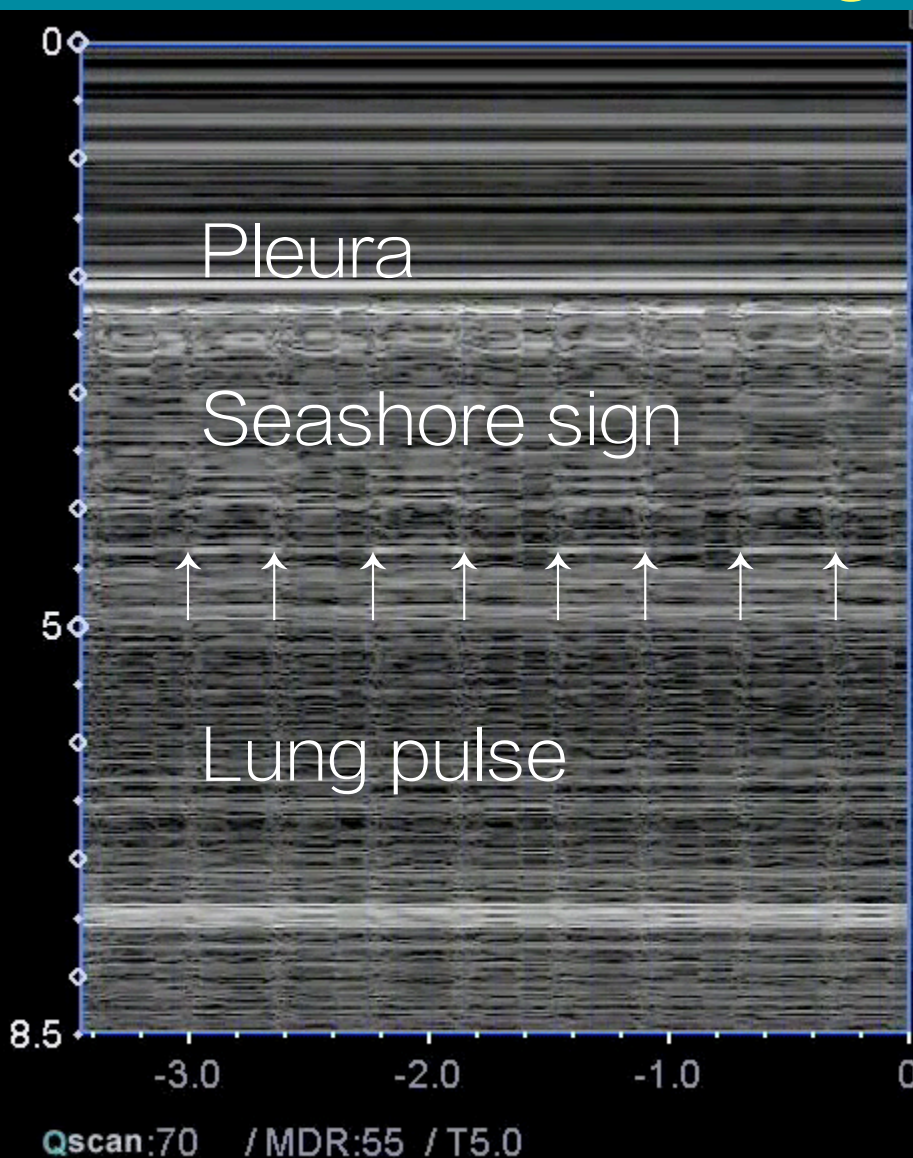


C Nerve
C6-2
22 Hz
13.0cm
2D
Gen
Gn 60
C 53
2/3/2

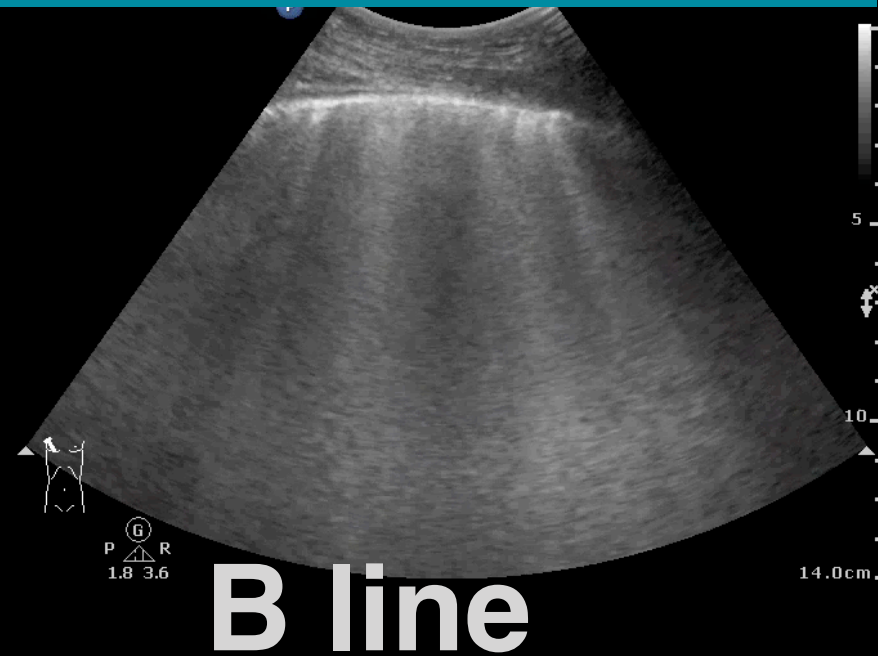
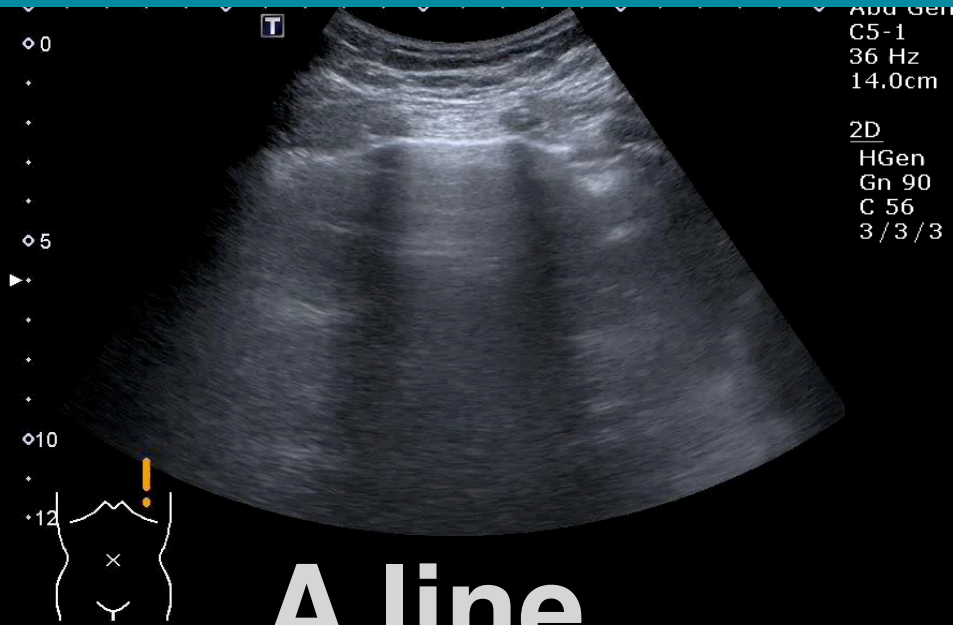


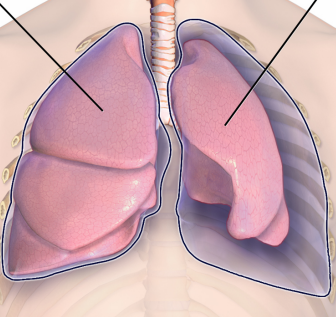
NORMAL LUNG

Sliding + A lines



SLIDING FIRST

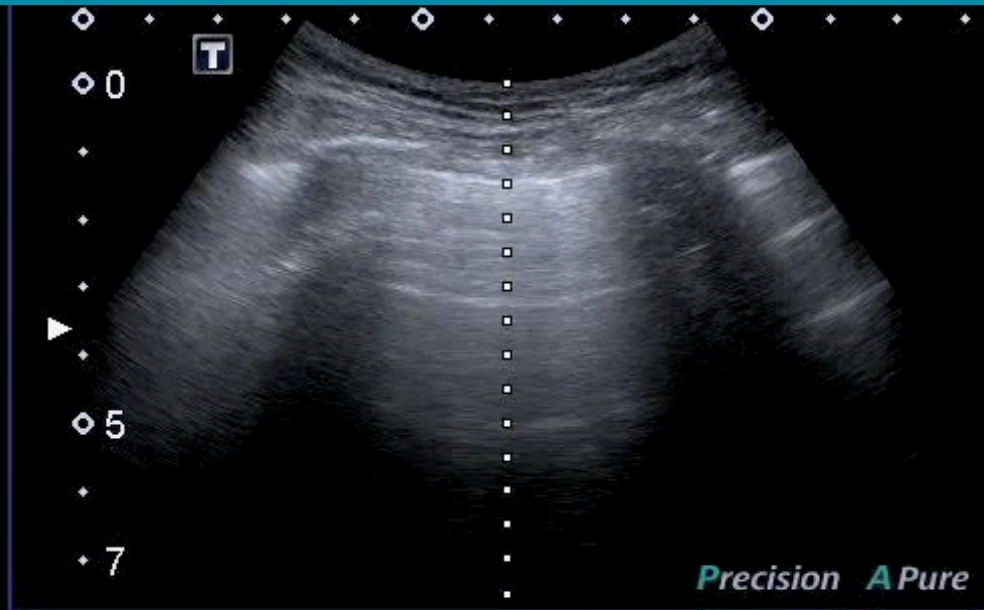
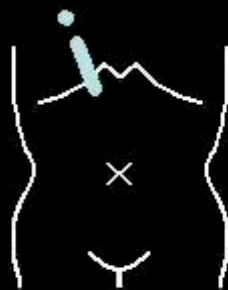




PNEUMOTHORAX ?

Sliding + A lines = Normal pleura

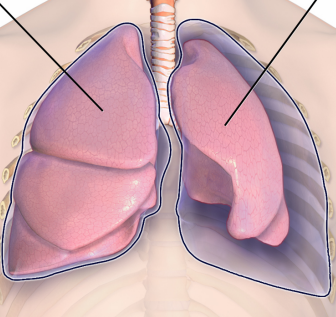
Seashore sign



MI:1.5
6C1
T5.0
18 fps
Qscan
G:71
DR:65
A:2
P:1



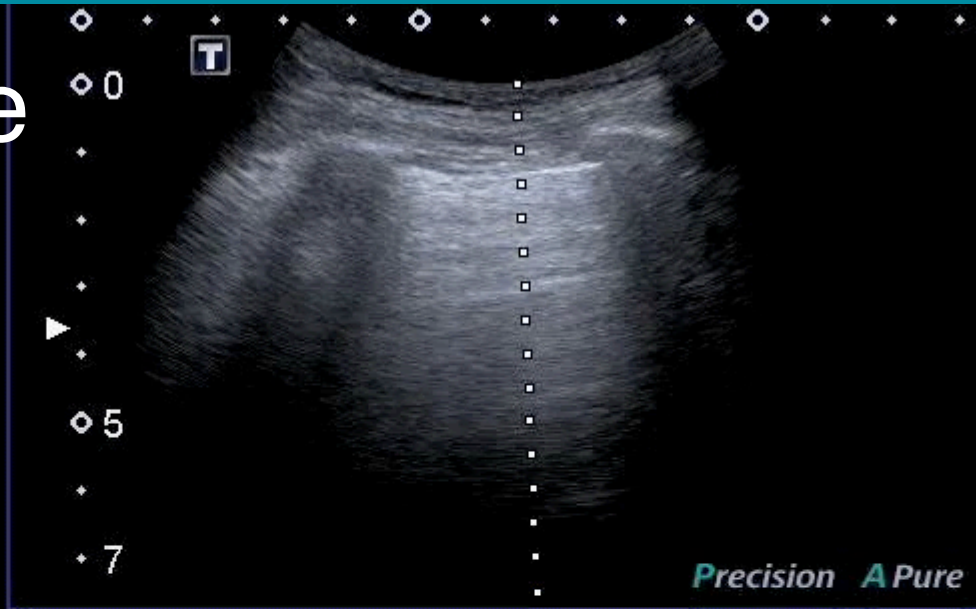
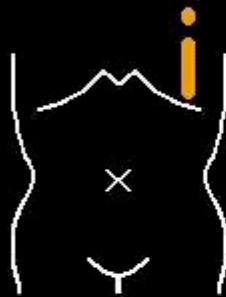0
5
7



PNEUMOTHORAX ?

No Sliding + A lines >> Consider PTX

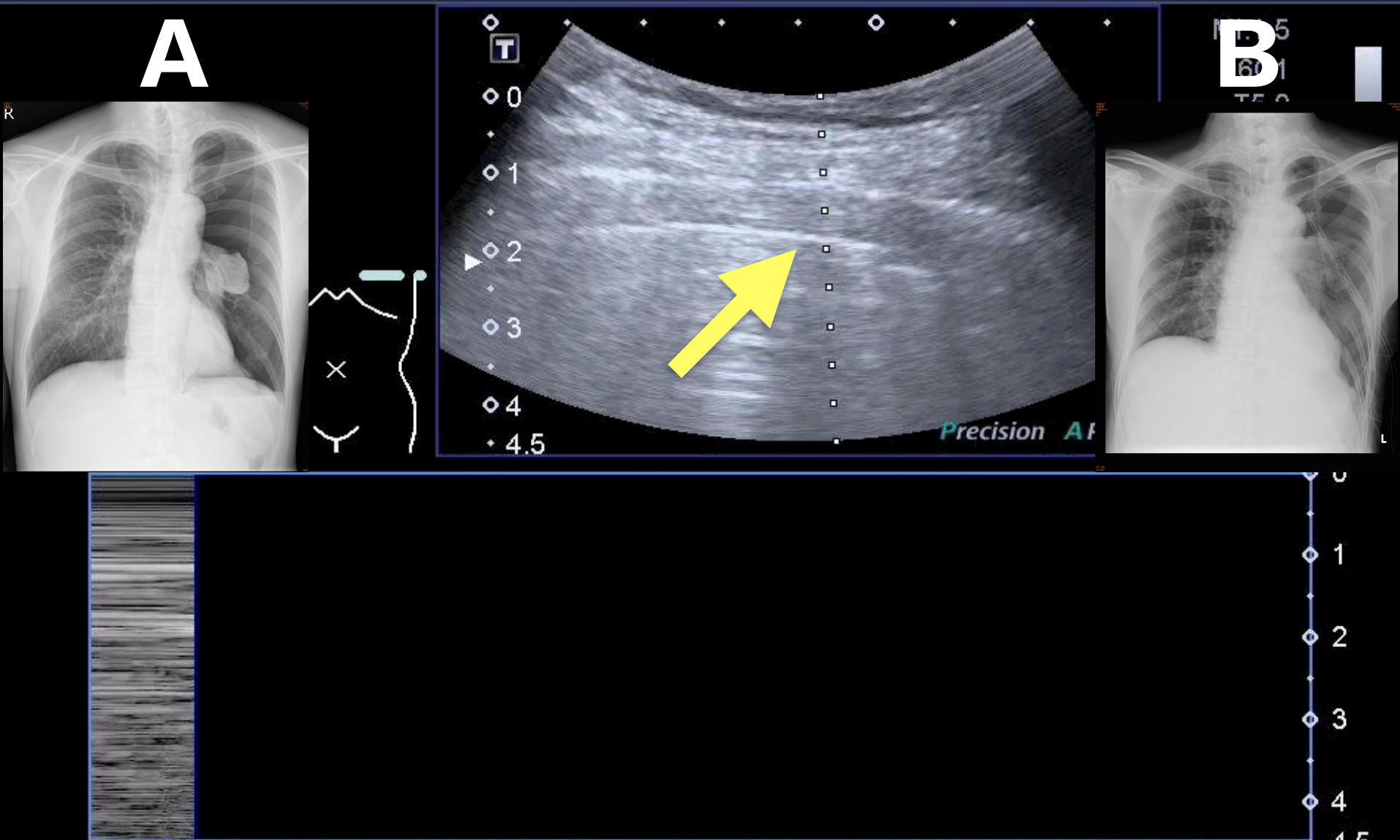
Stratosphere
sign



MI:1.5
6C1
T5.0
18 fps
Qscan
G:71
DR:65
A:2
P:1

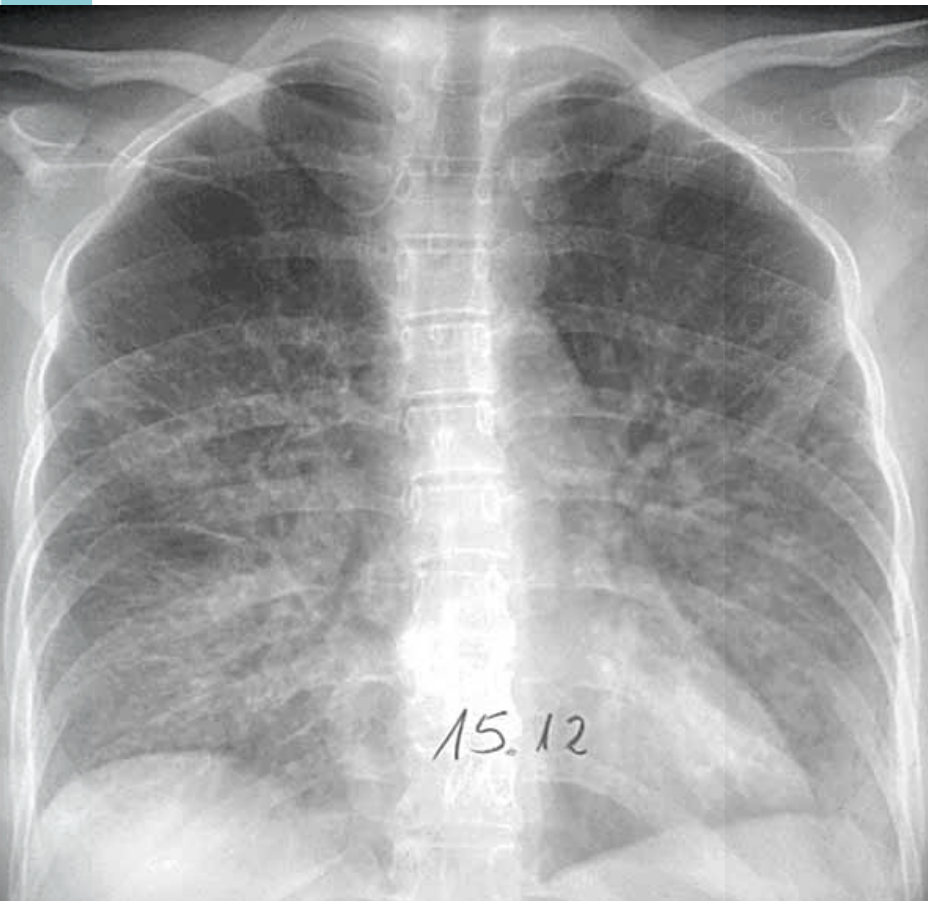


Lung Point



LUNG ROCKETS

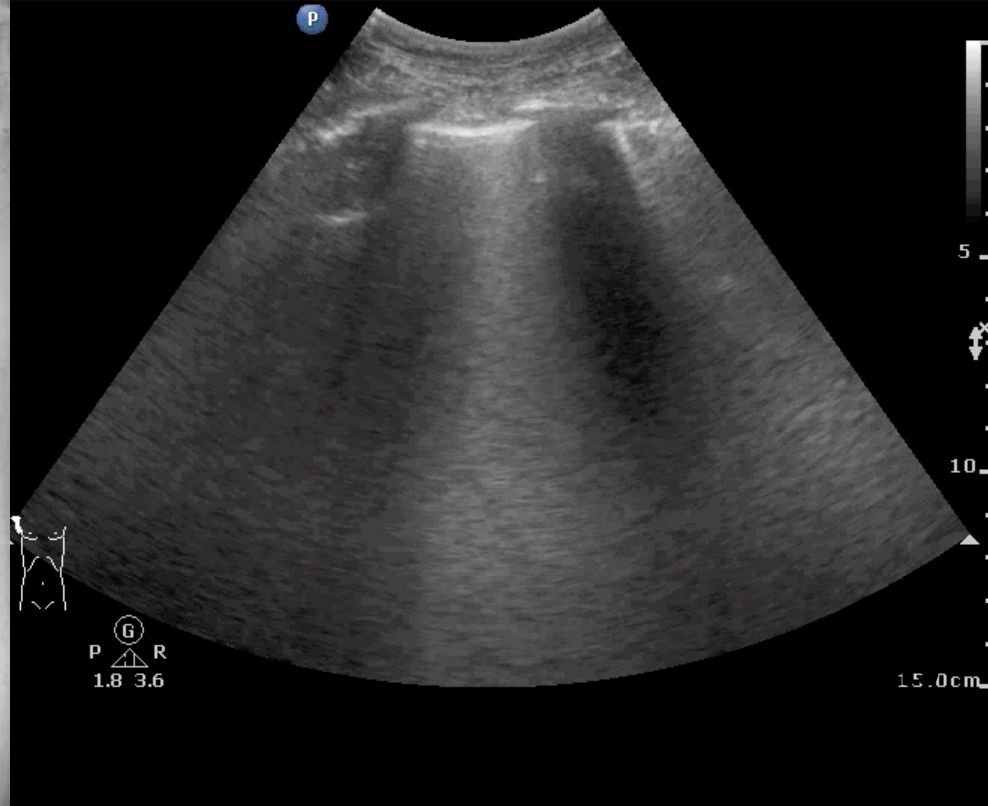
ICS > 3 B lines



8683

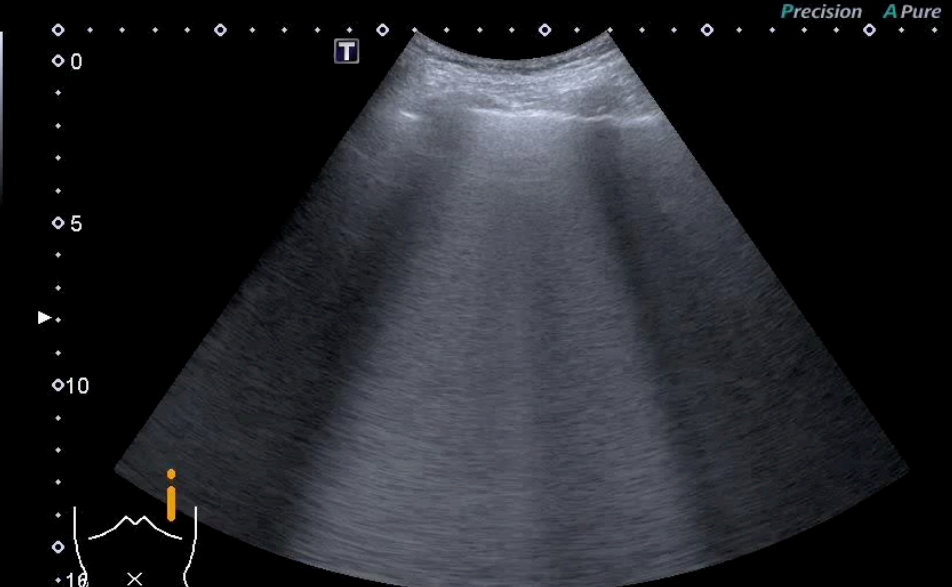
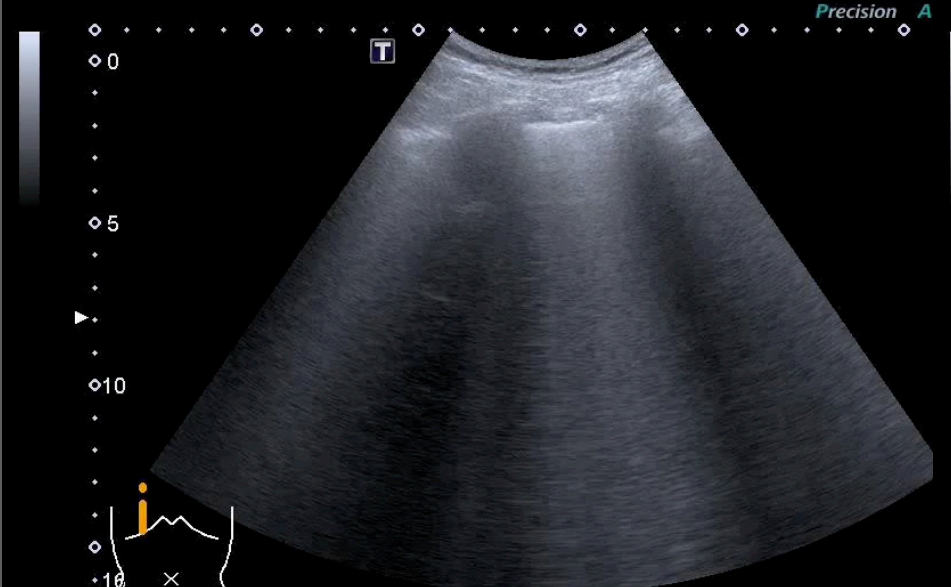
SKH ER

MI 1.1 11/8/2016
TIS 0.1 8:00:36 AM

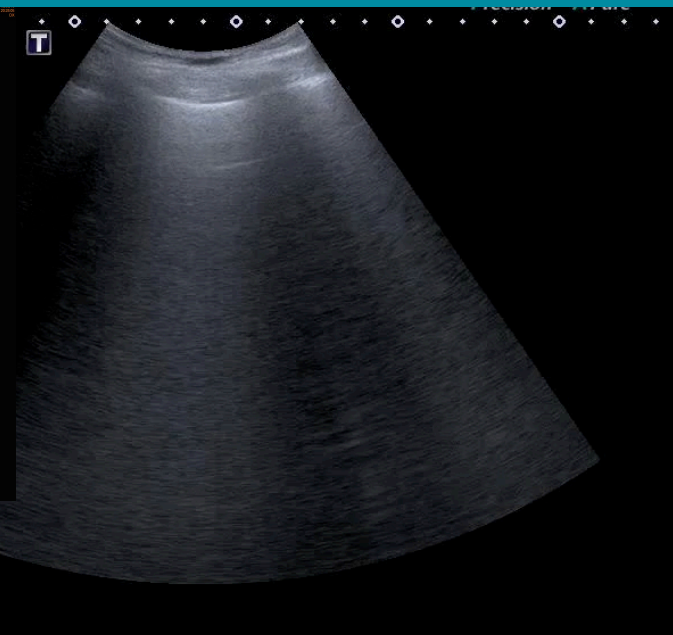
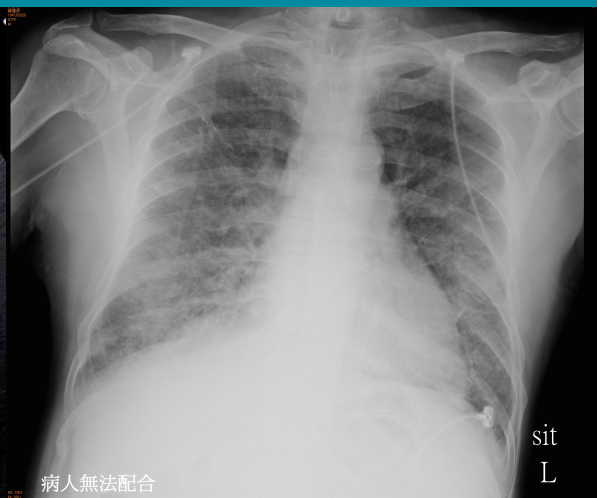
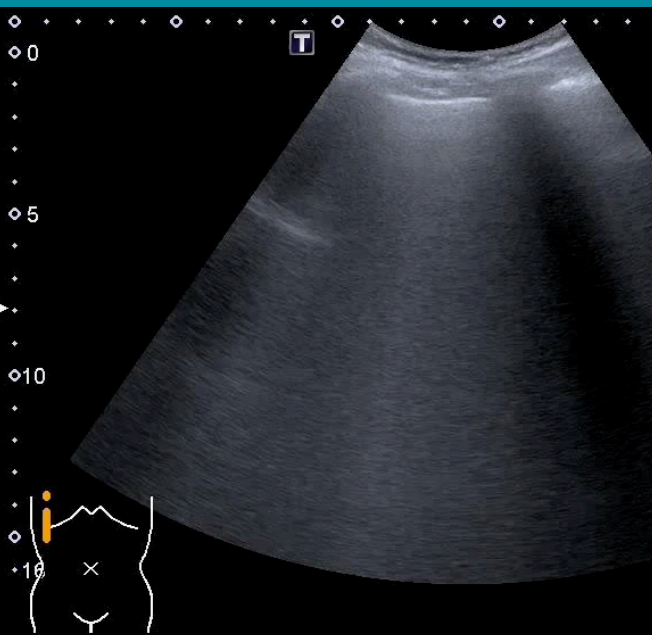


P
G
1.8 3.6

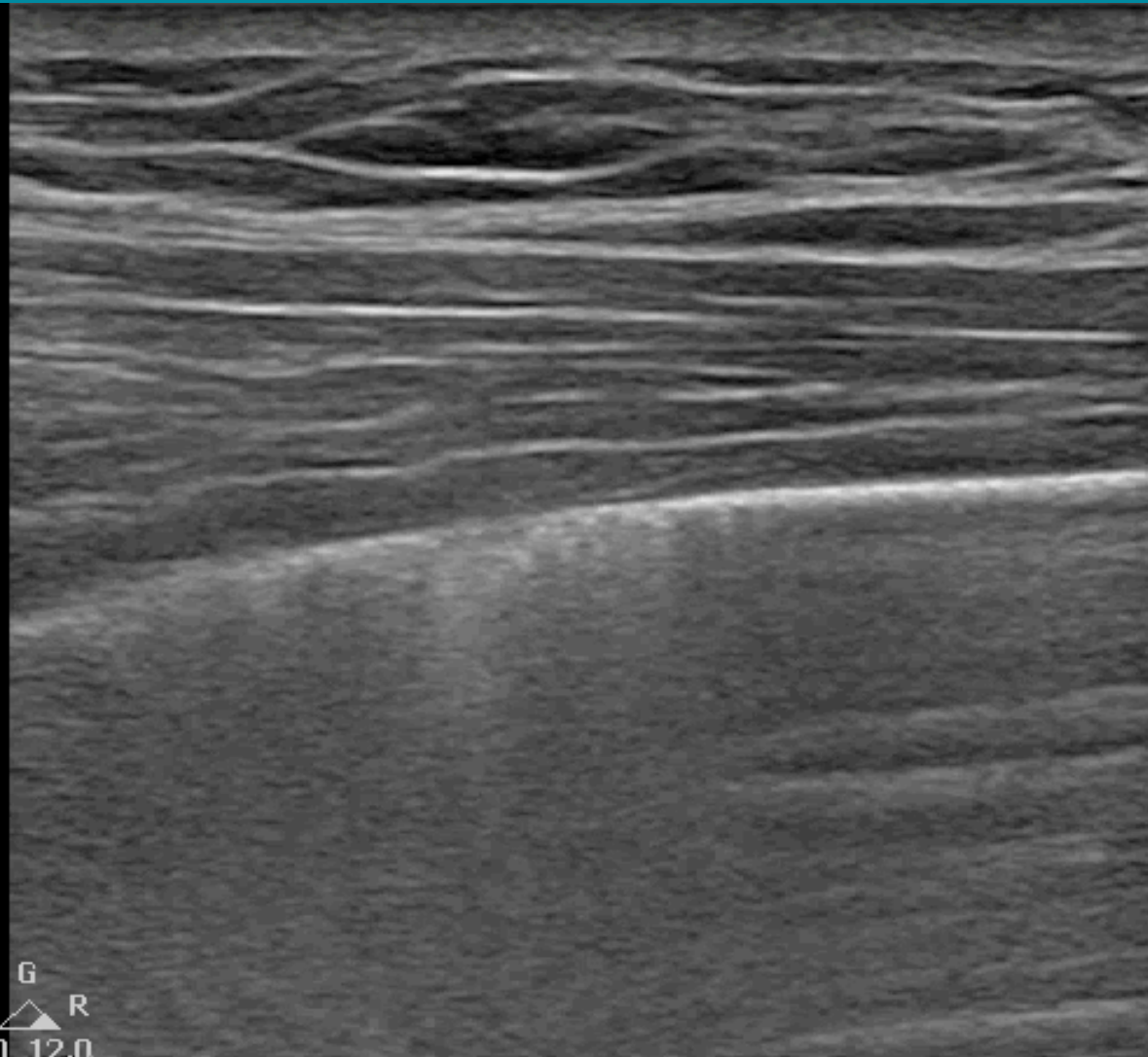
15.0cm



ALEVOLAR INTERSTITIAL SYNDROME



AIS: Localized



Pneumonia

Pneumonitis

Atelectasis

Contusion

Infarction

Pleural disease

Neoplasia

Normal lung

PLEURAL EFFUSION

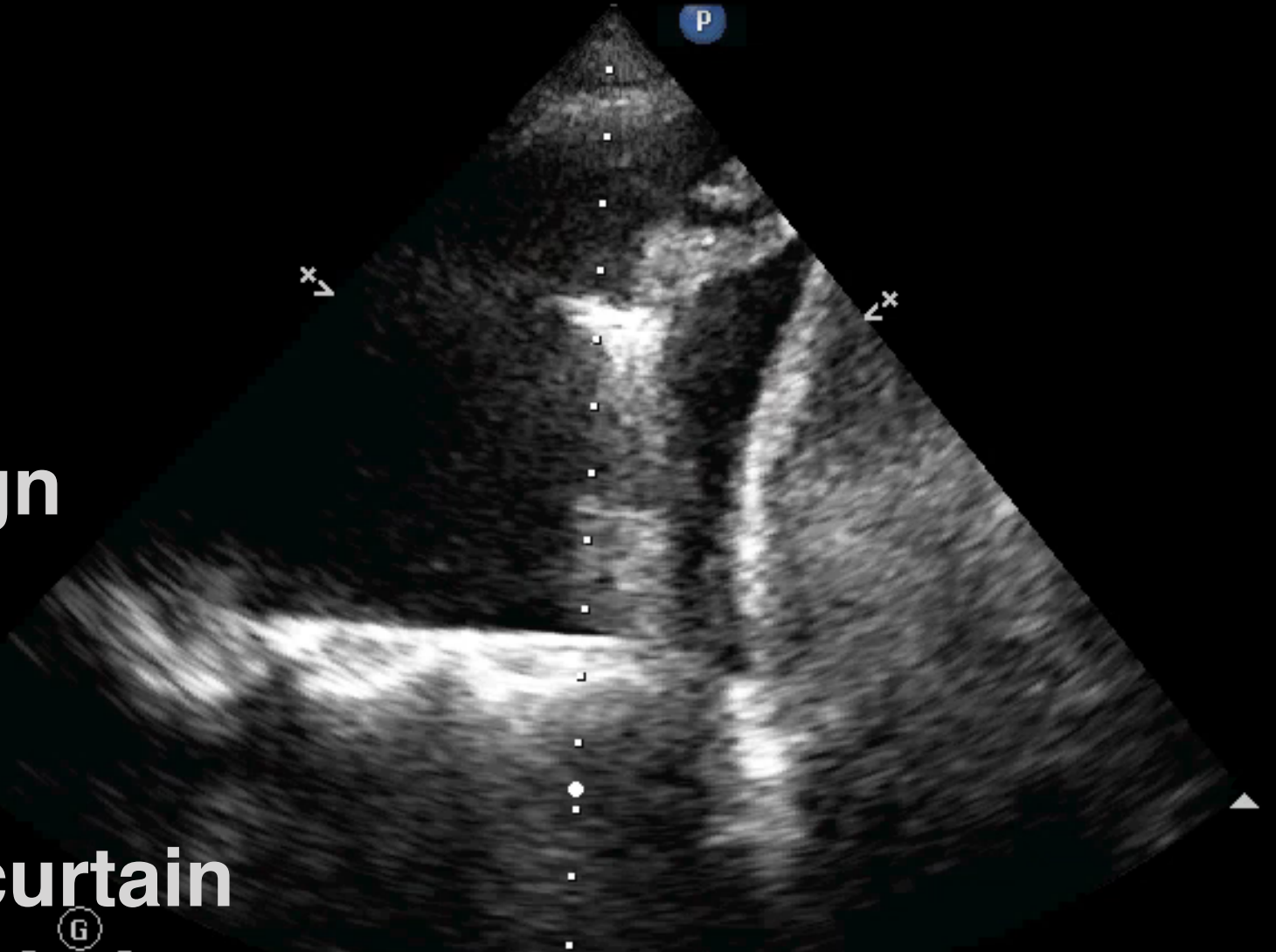
Adult Echo2
S-1
3 Hz
5.0cm

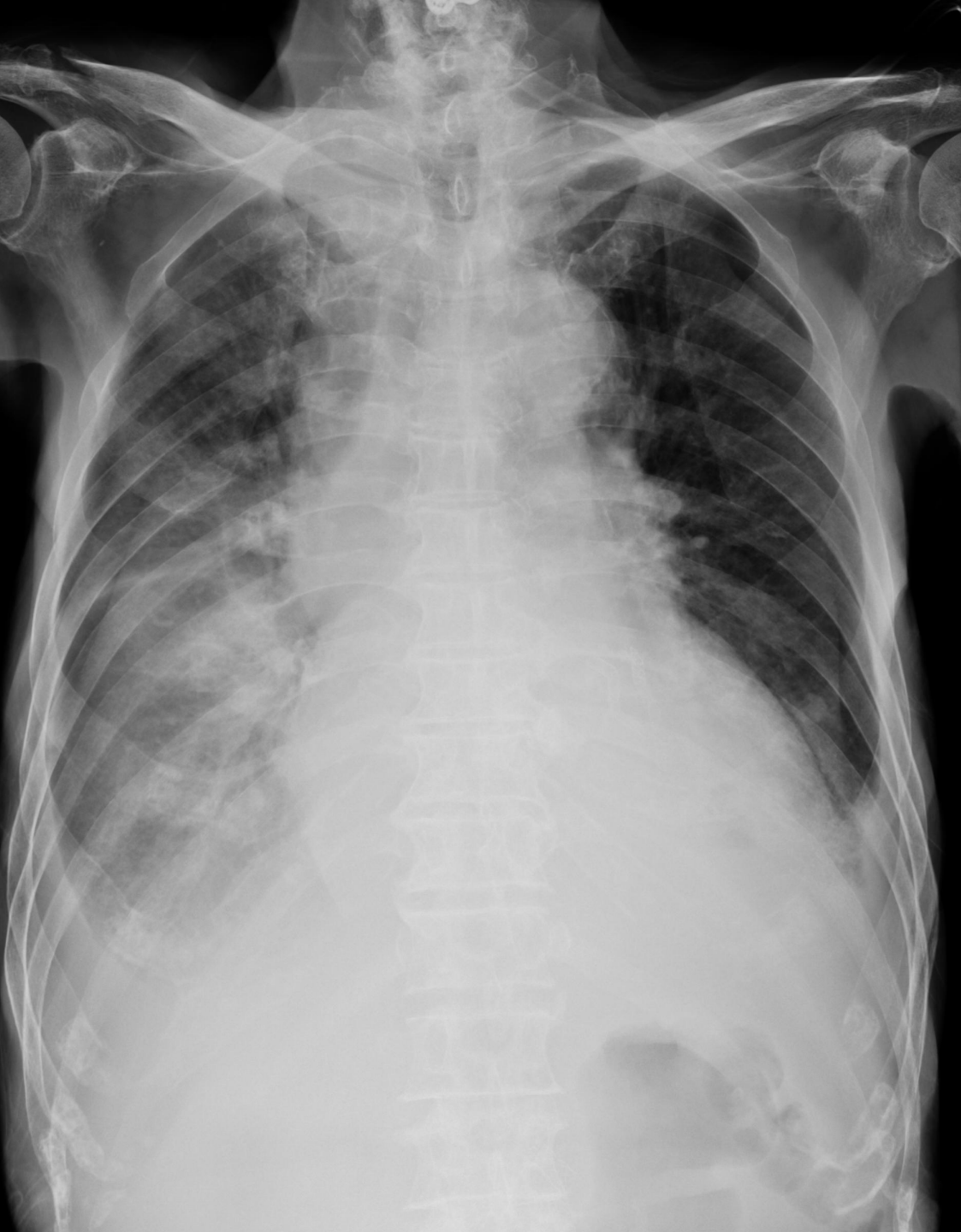Gen
n 30
50
/2/0

Spine sign

Jelly fish

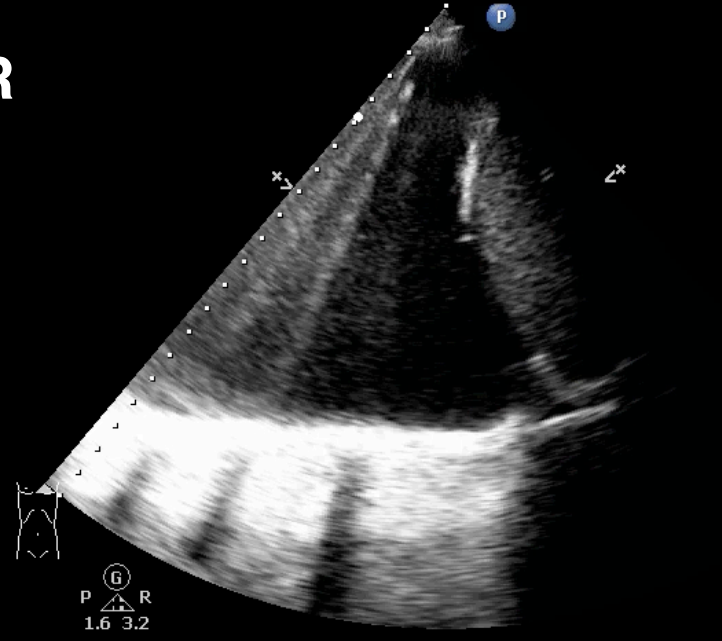
Loss of curtain





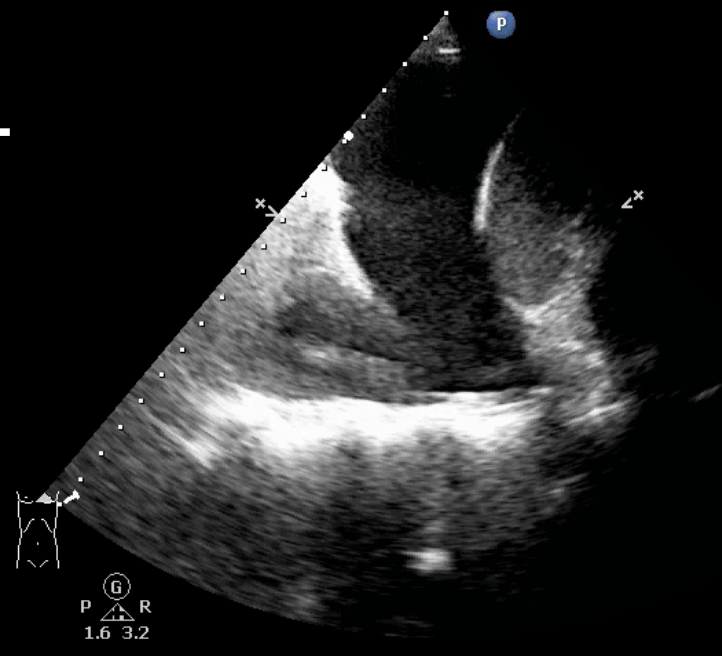
102

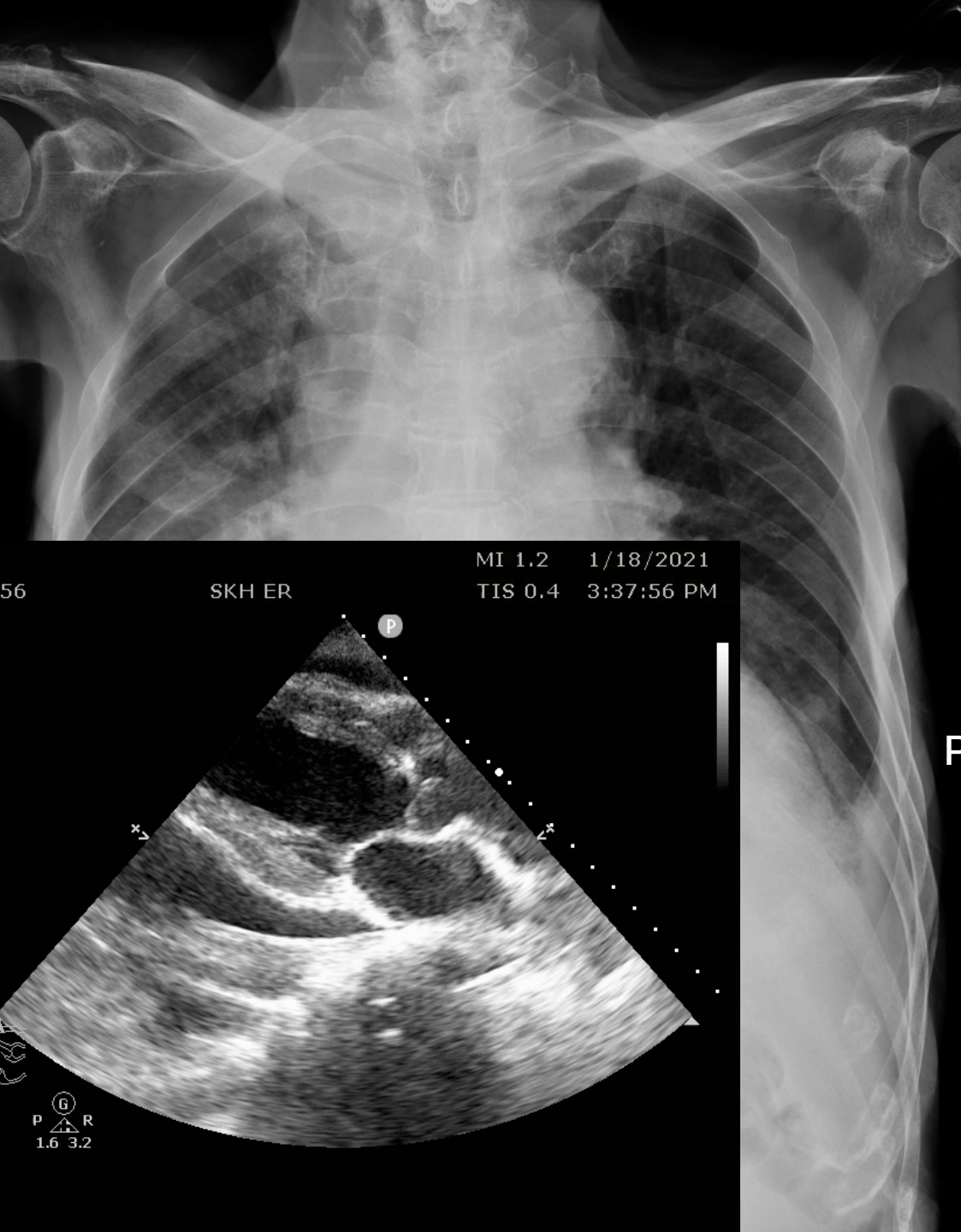
R



102

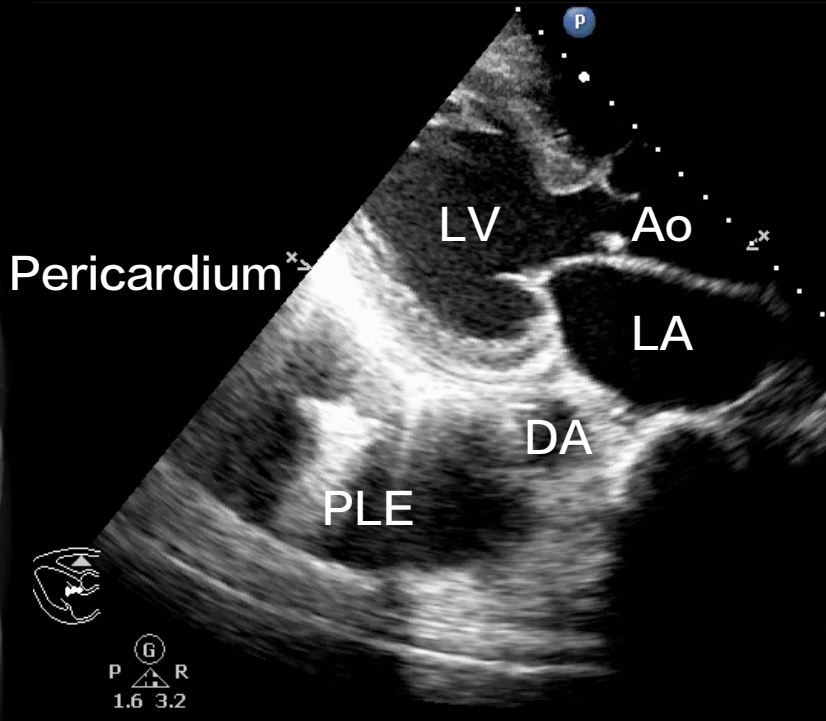
L



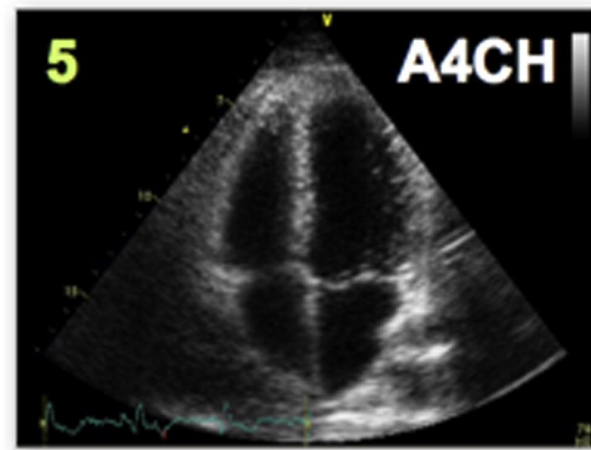
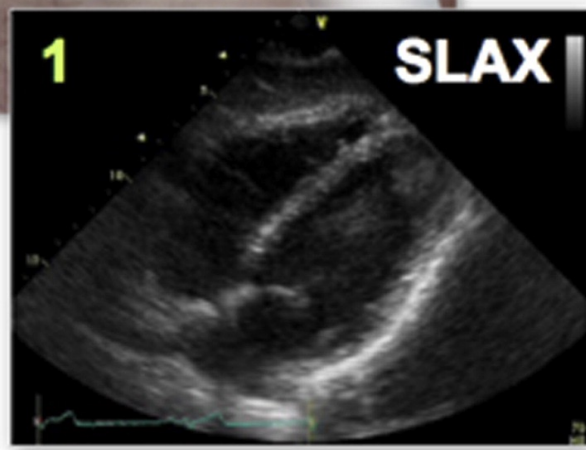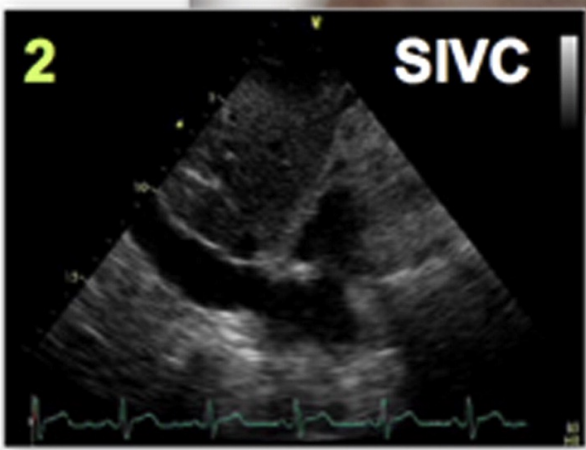
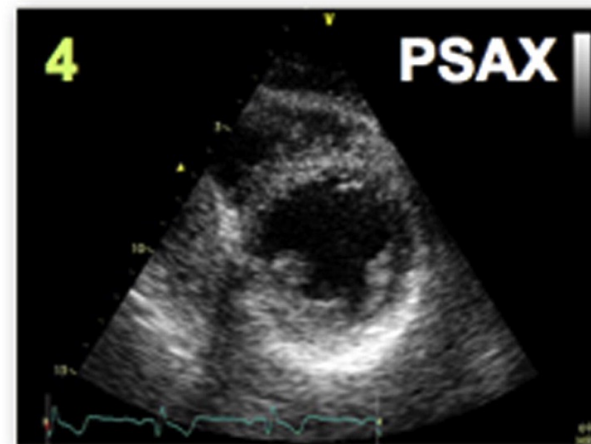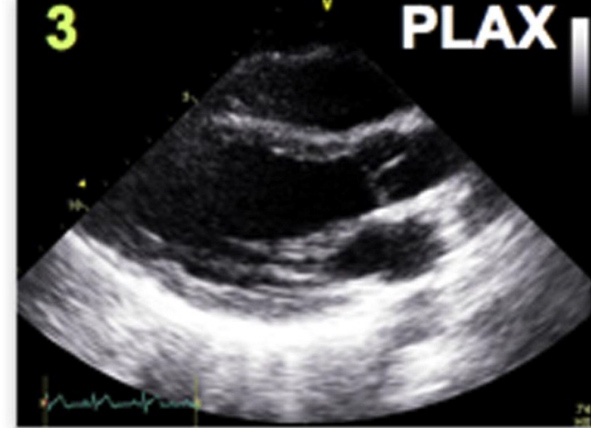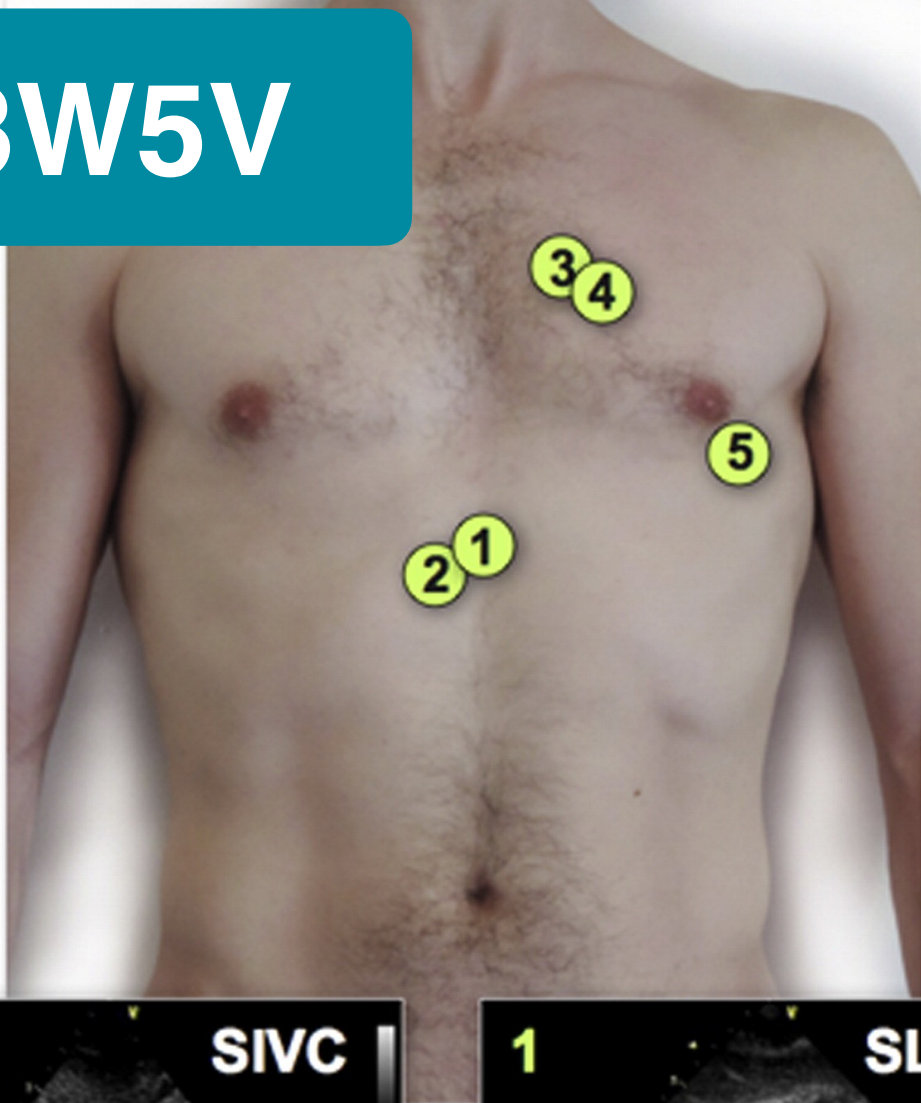


D aorta

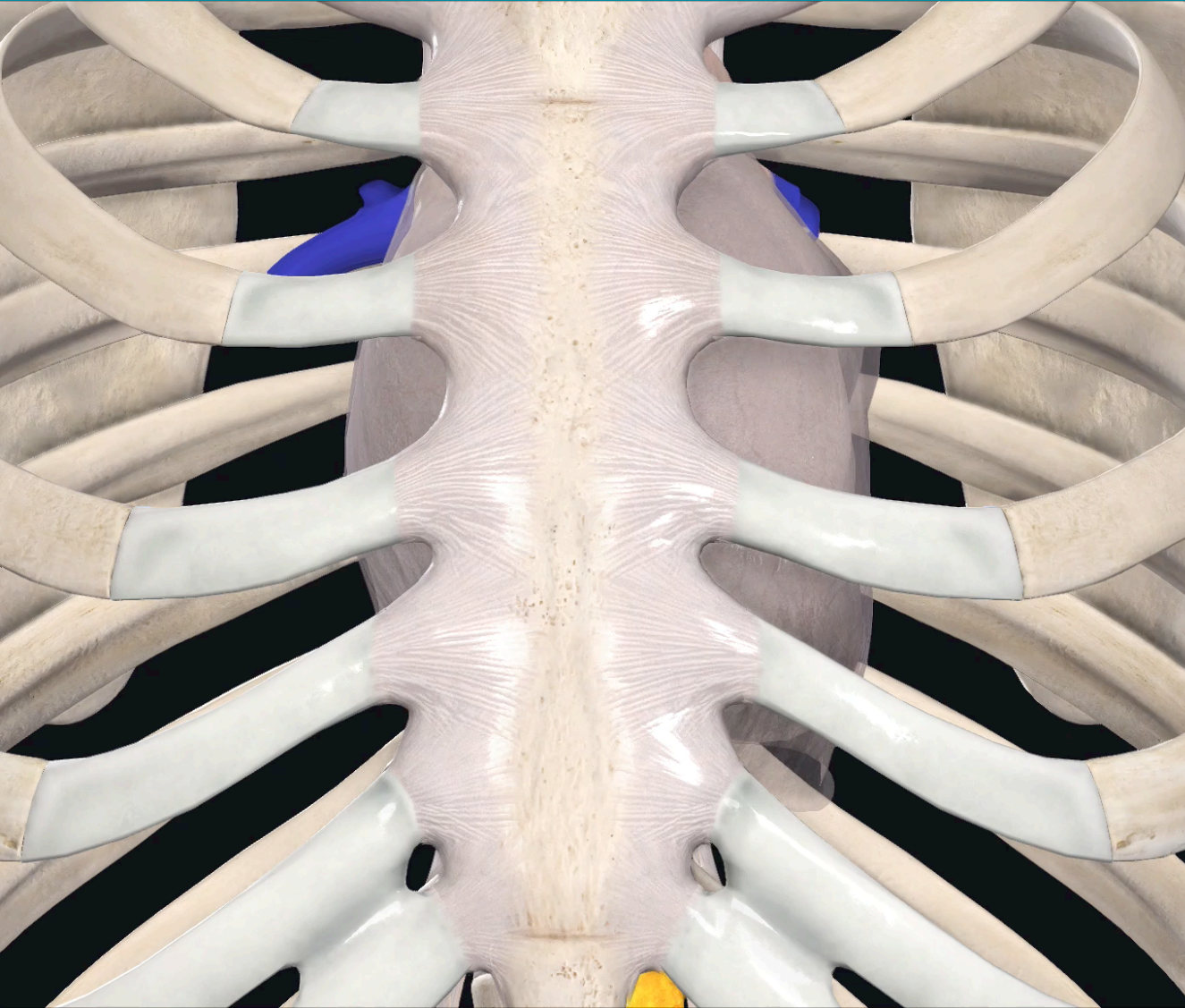
Pericardial vs Pleural



3W5V

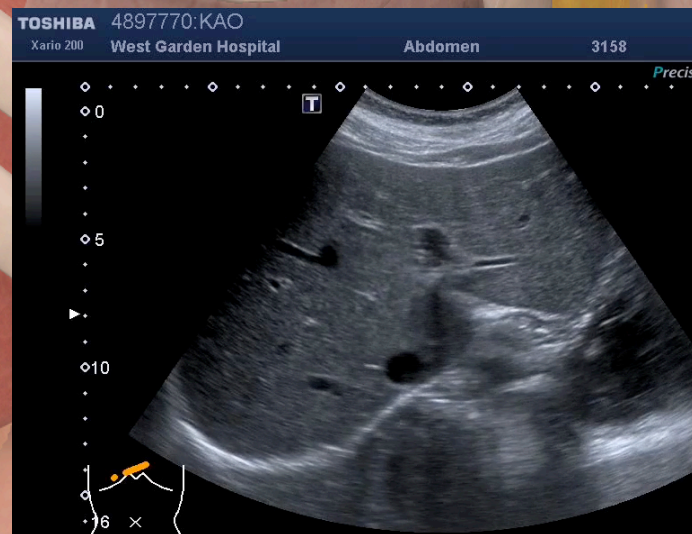
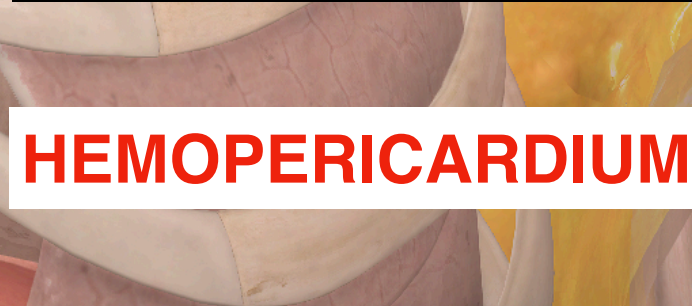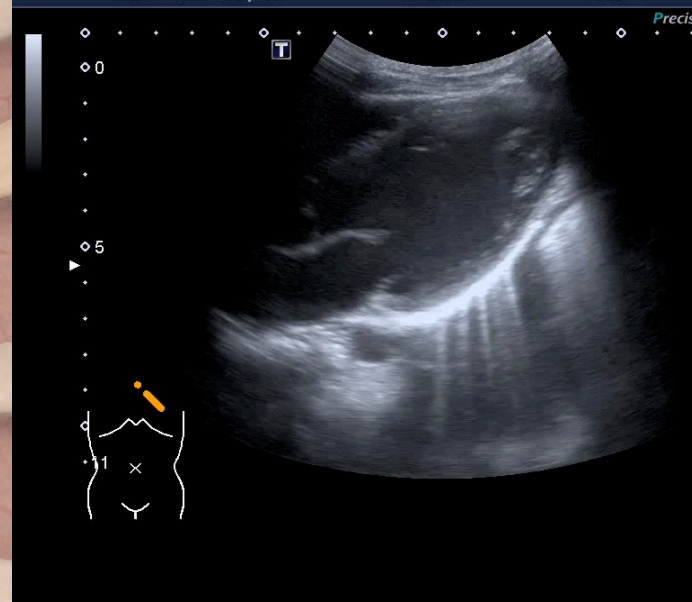
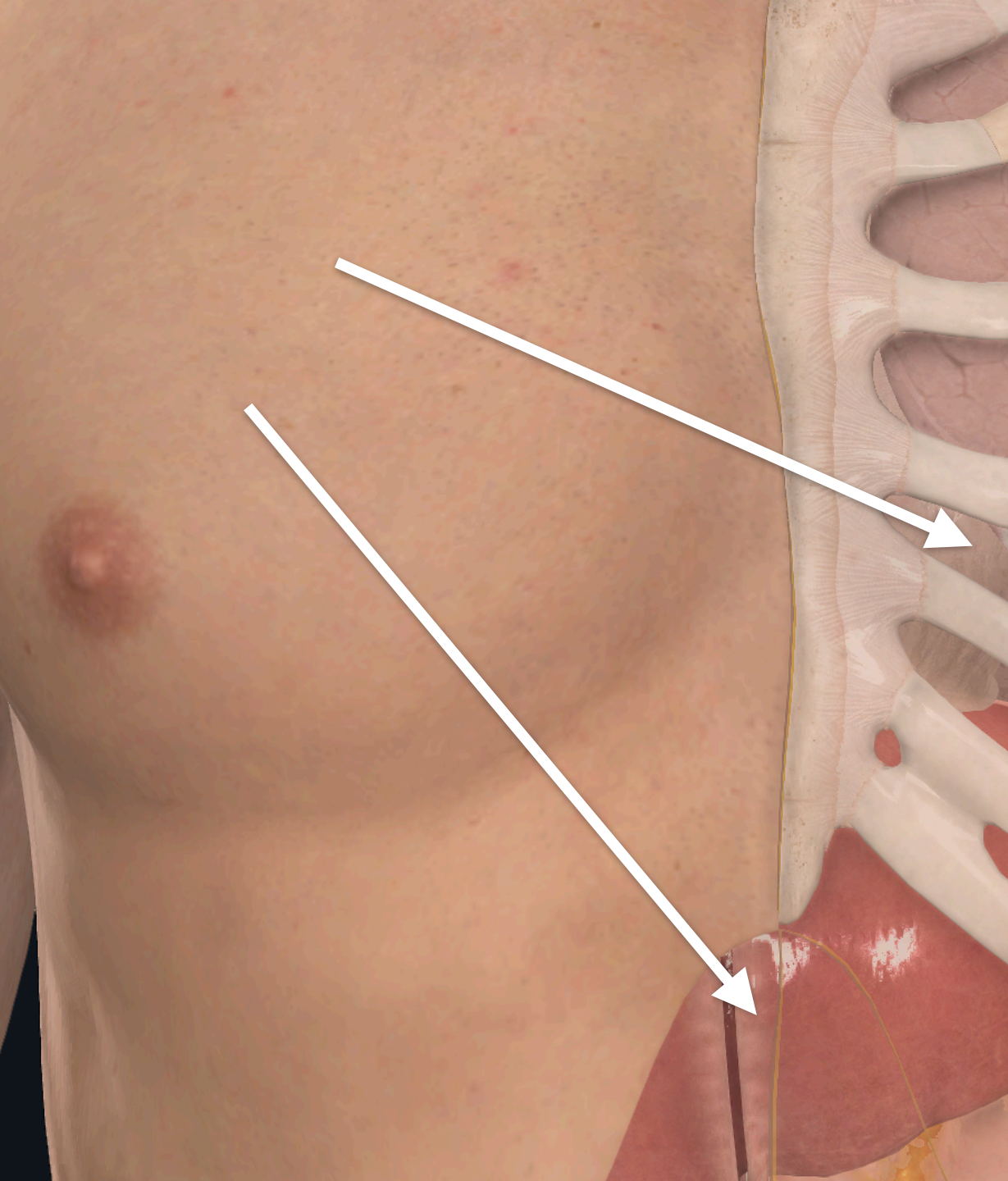


HEART

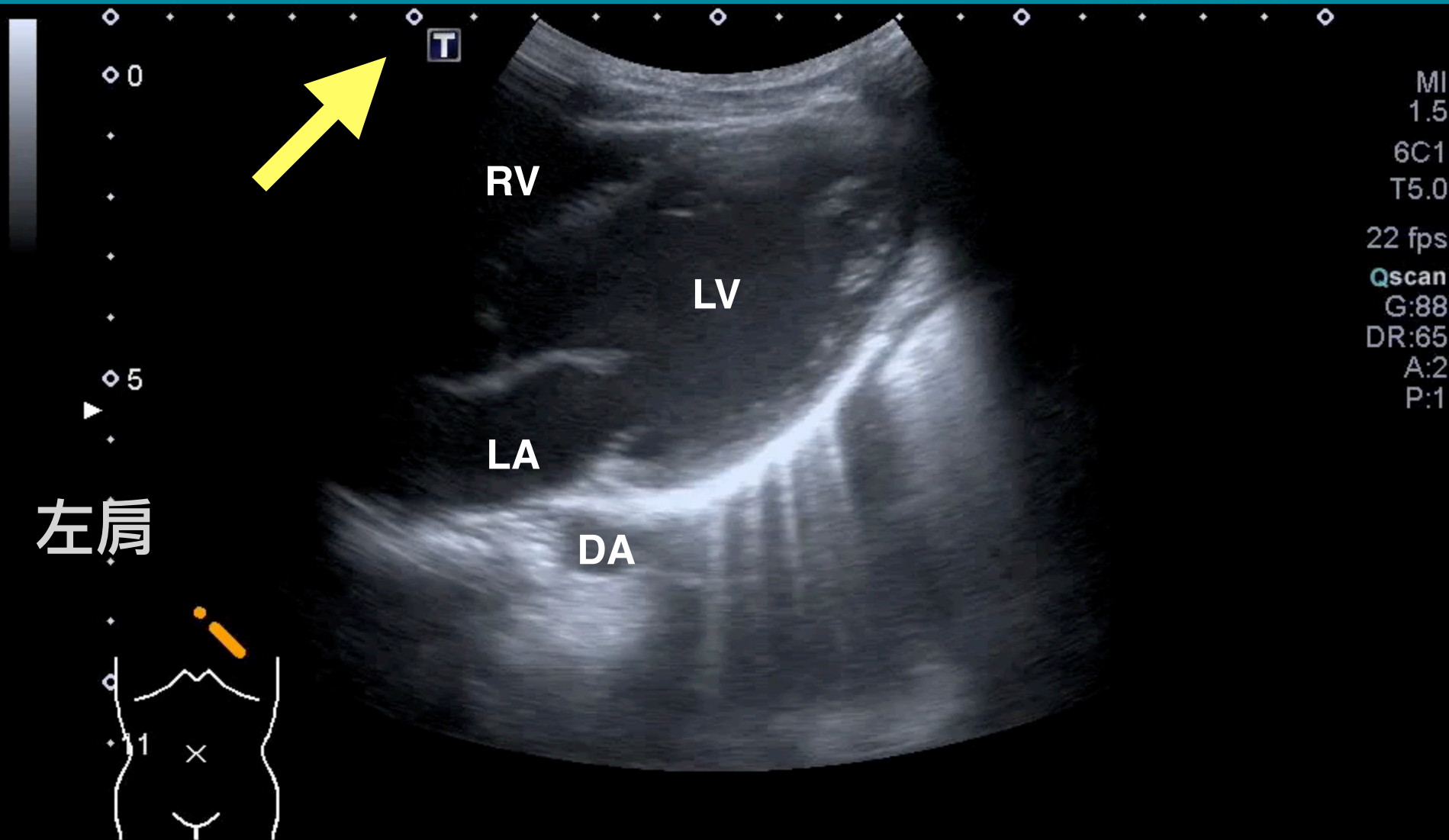


Arrest
Activity

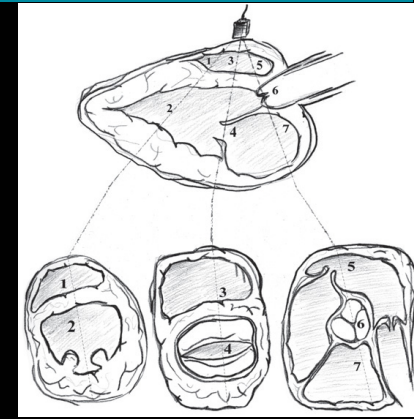
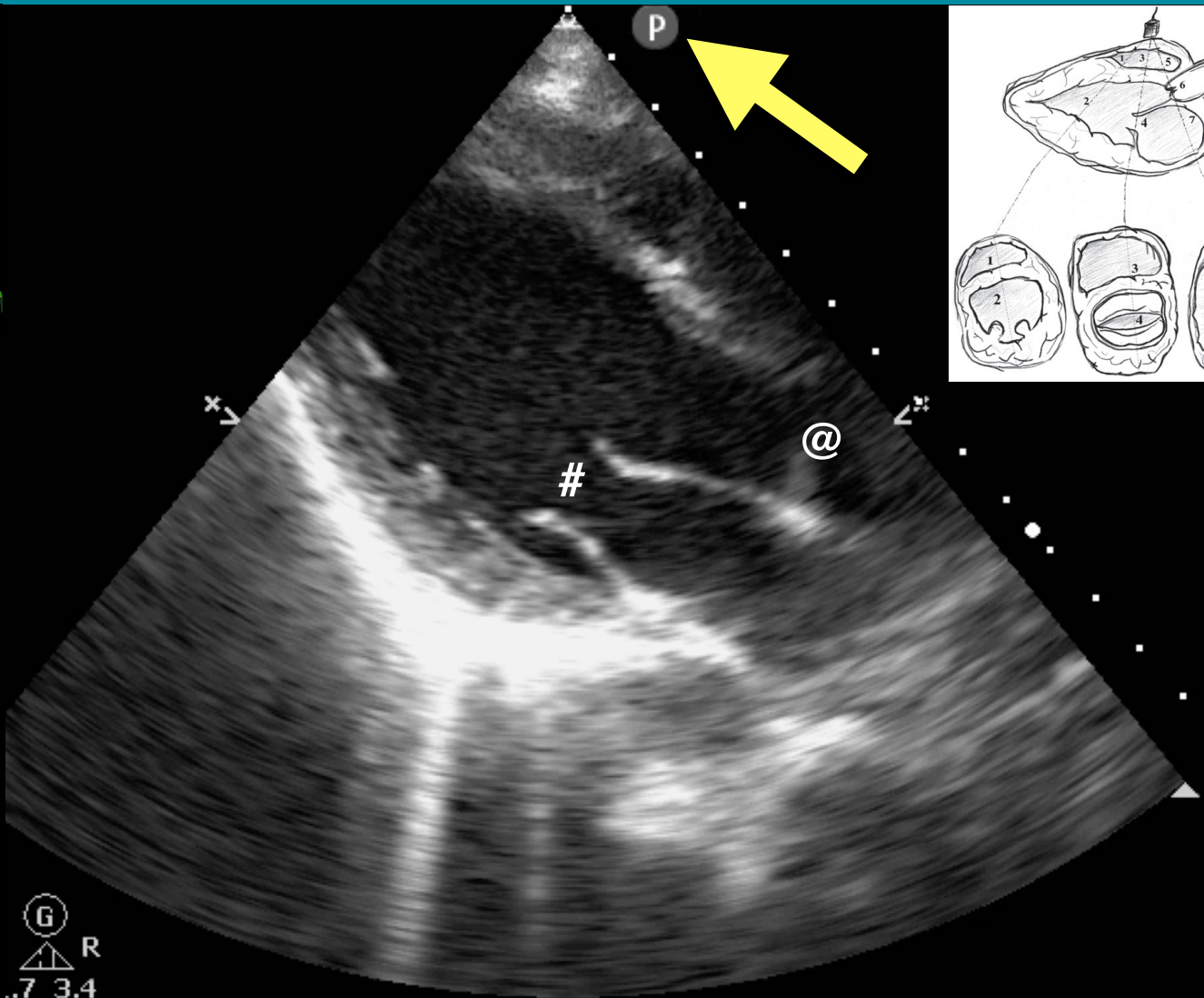
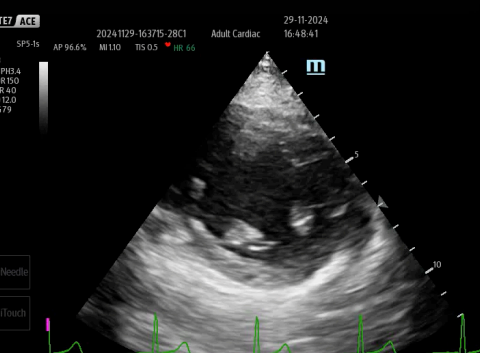
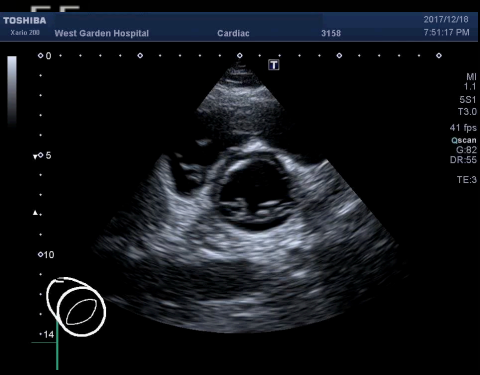
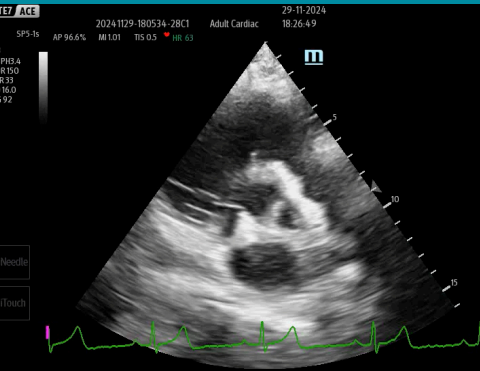
Shock
Effusion



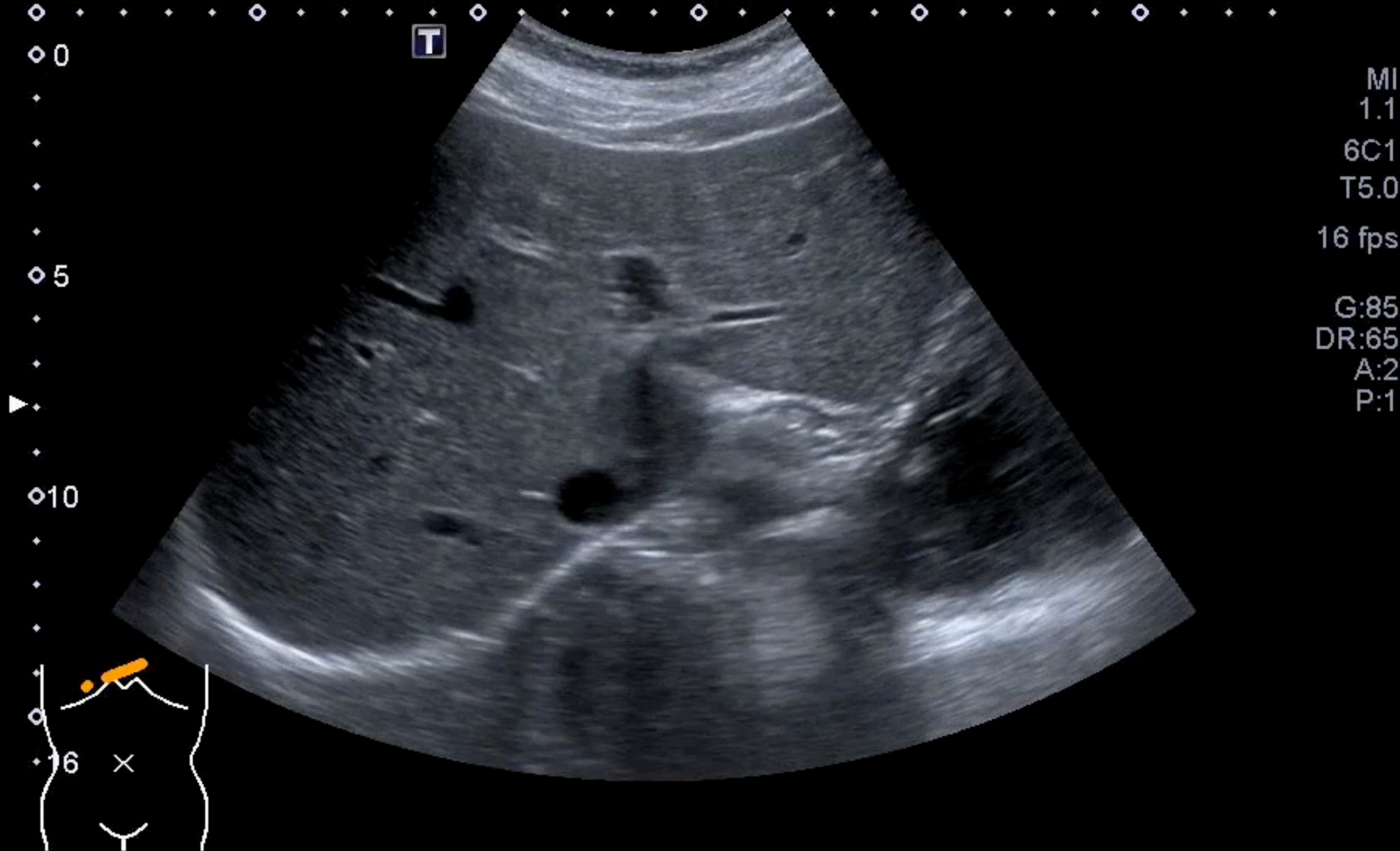
PARASTERNAL LONG AXIS



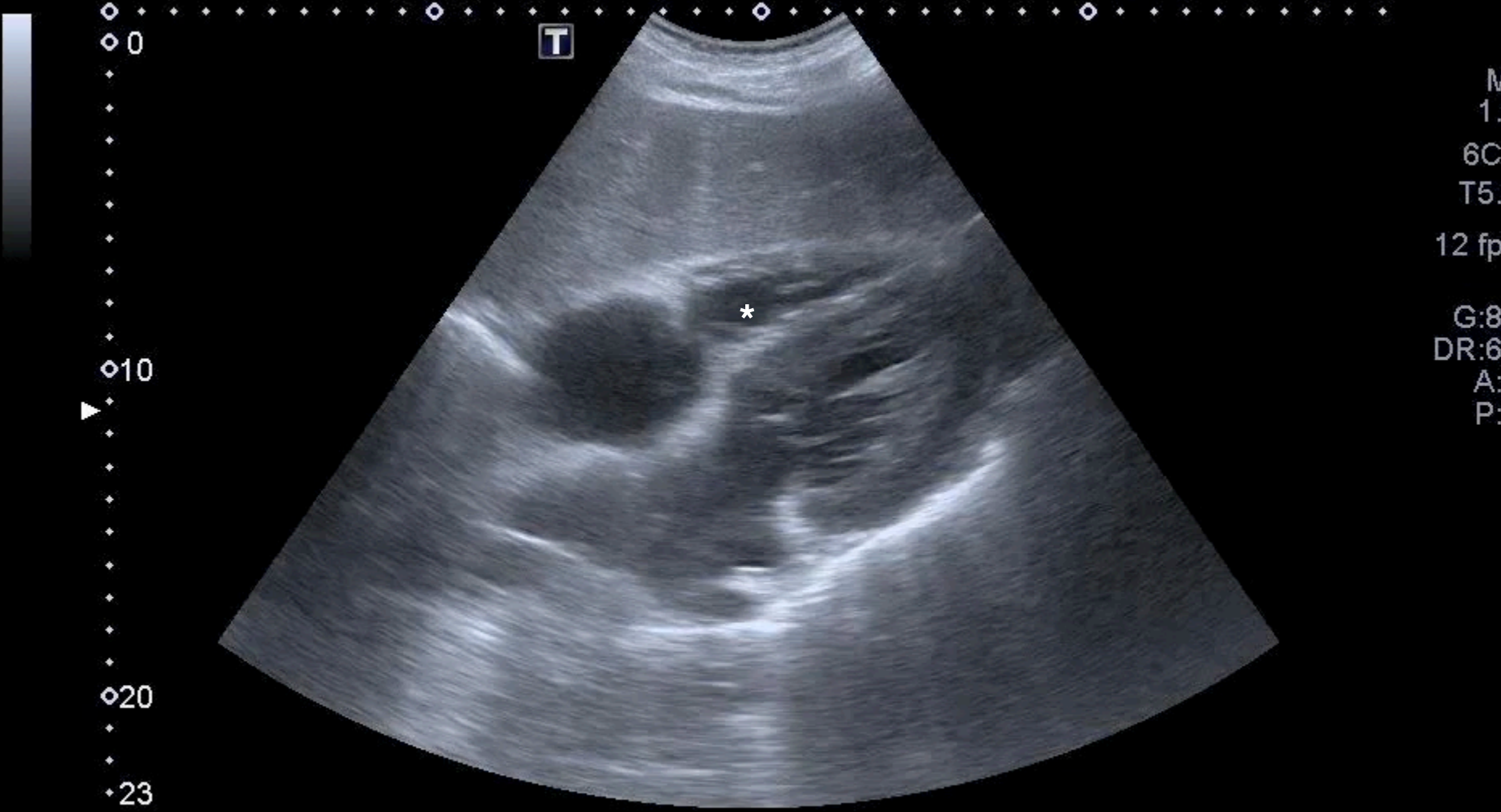PARASTERNAL LONG AXIS



SUBCOSTAL 4 CHAMBER



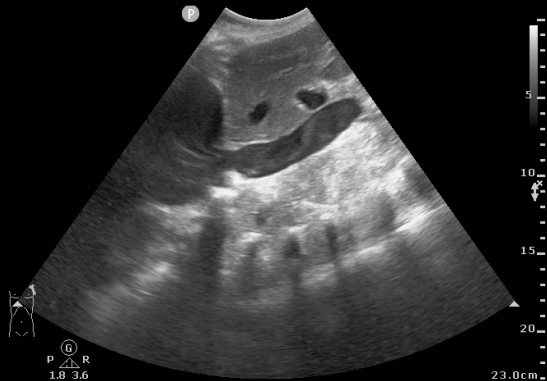CARDIAC ARREST



CARDIAC TAMPONADE

Abd Gen
S5-1
25 Hz
23.0cm

2D
HGen
Gn 100
C 56
3/3/3

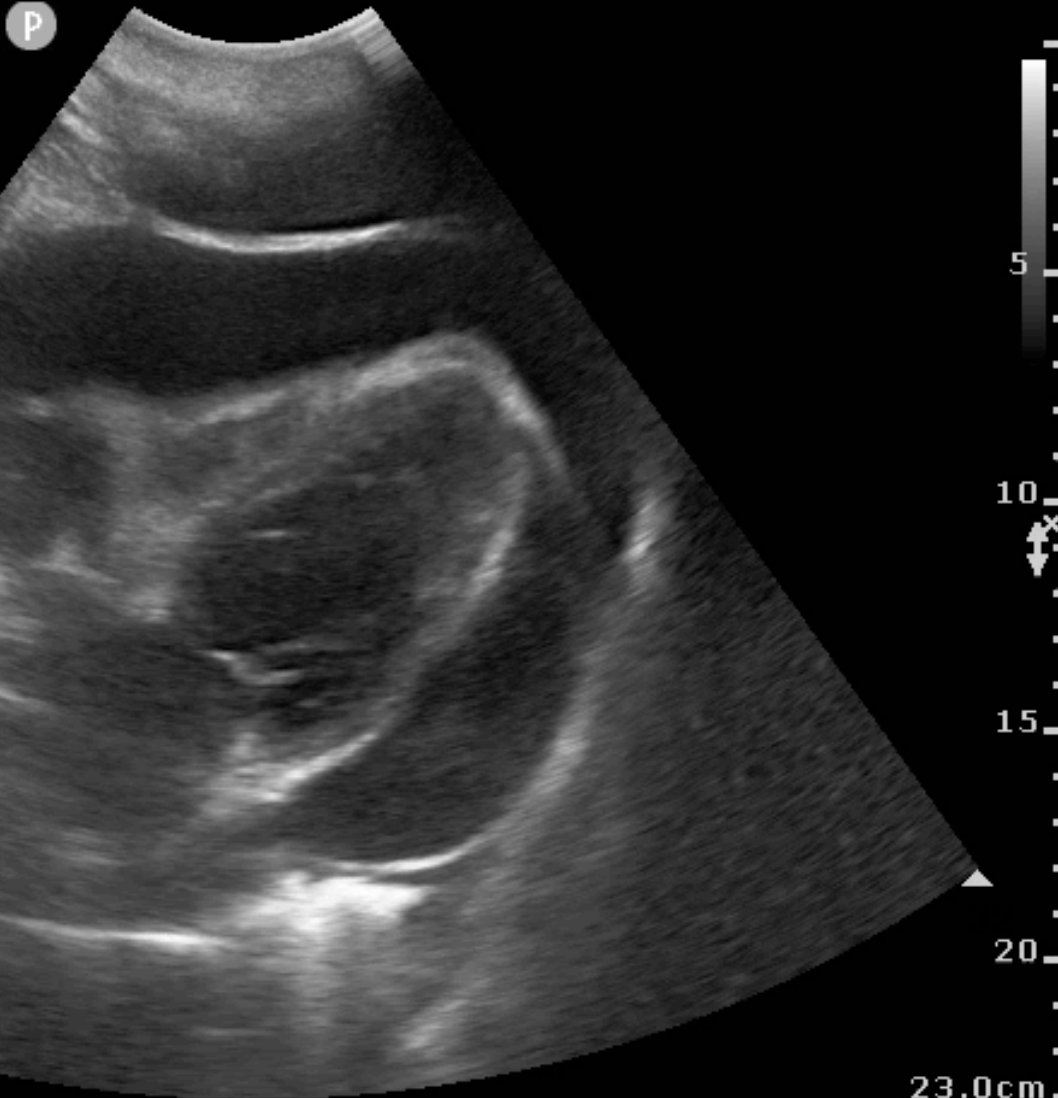


P G R
1.8 3.6

3/3/3



P G R
1.8 3.6



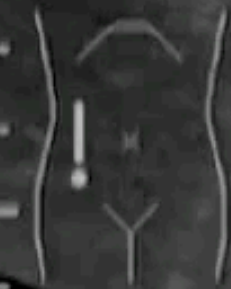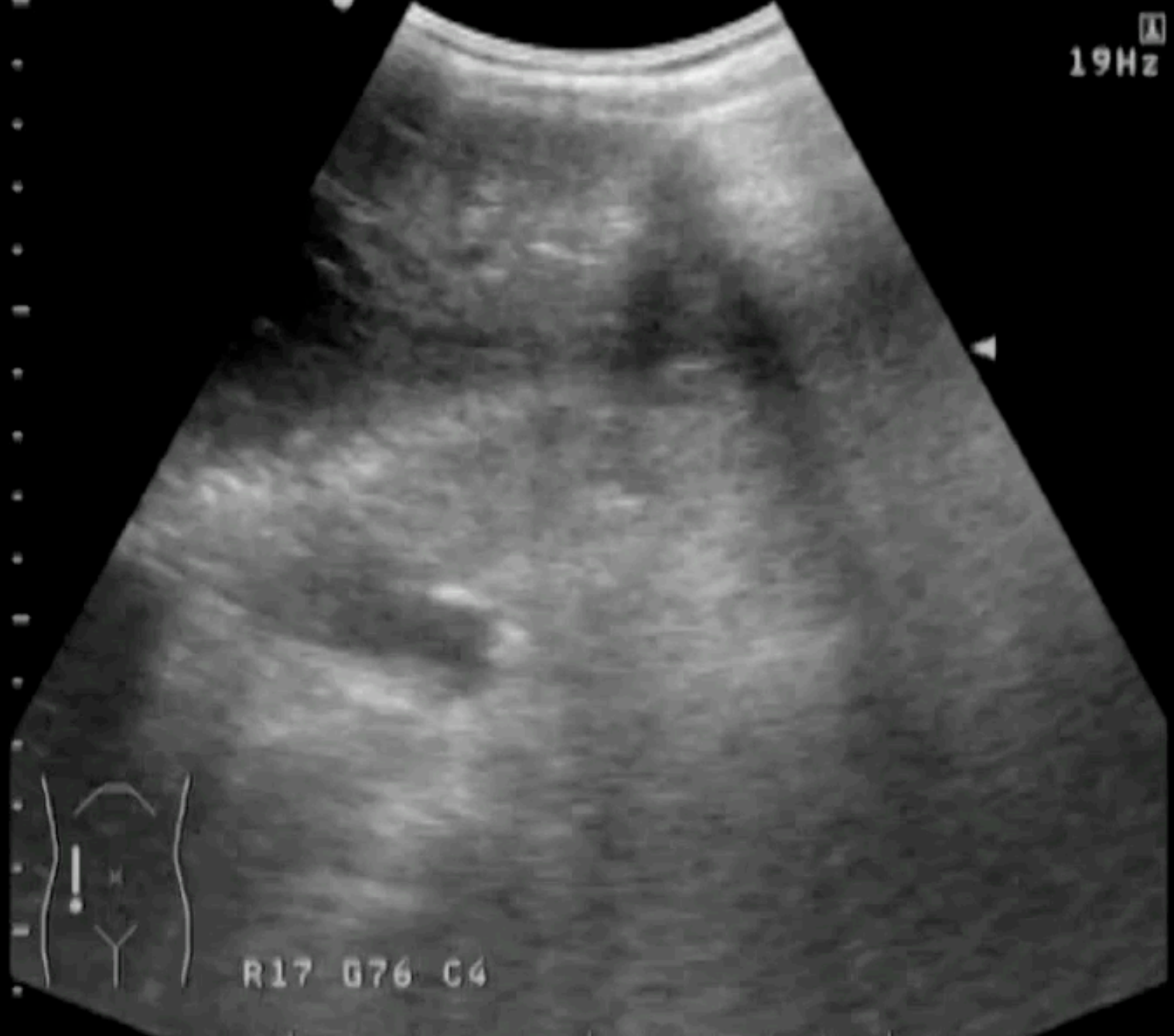
23.0cm

THORACIC CAVITY

Sternum	Pleura	PSLA
Rib	Diaphragm	PSSA
Cartilage	Bat sign	Aortic root
	A line	S4C
	Sliding (B / M)	

19Hz

3.5M S-H
DUA: 100%
MI = 0.6

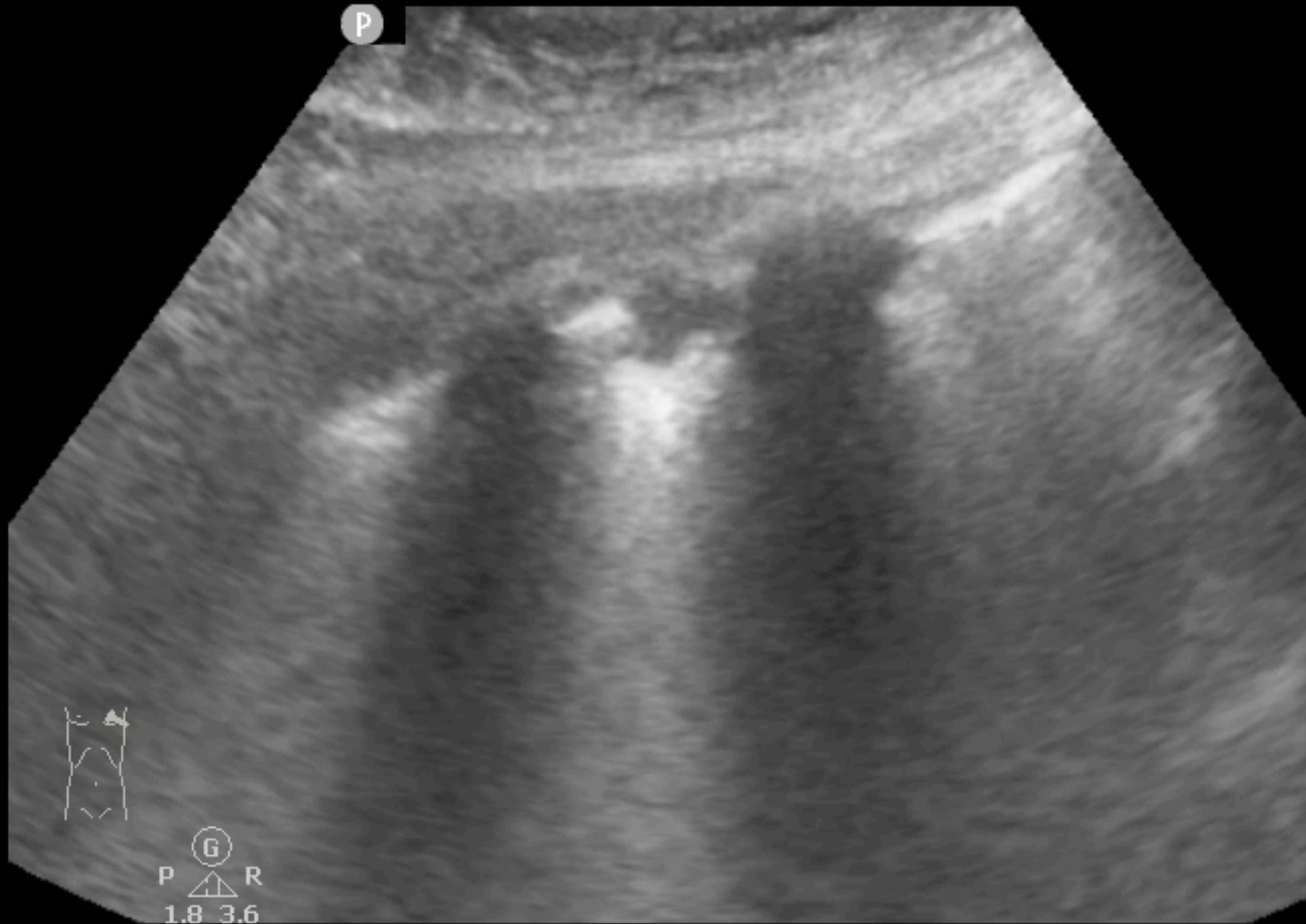


R17 076 C4

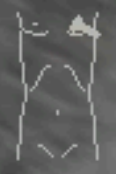1: Abdomen

Gen
1
Hz
0cm

Gen
90
56
3/3



P

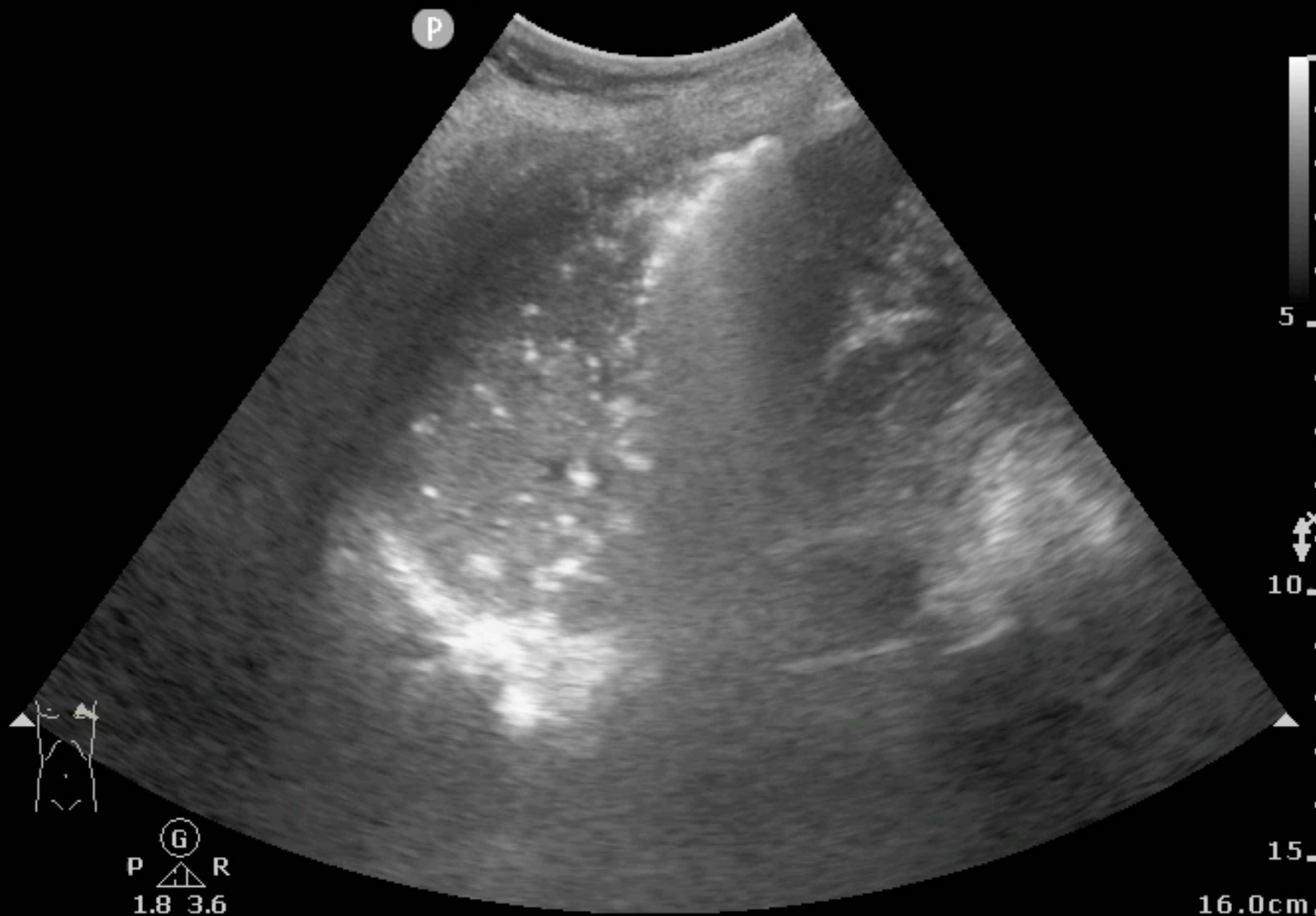


G
P R
1.8 3.6

n

P

3



5

10

15

16.0cm

G
P R
1.8 3.6

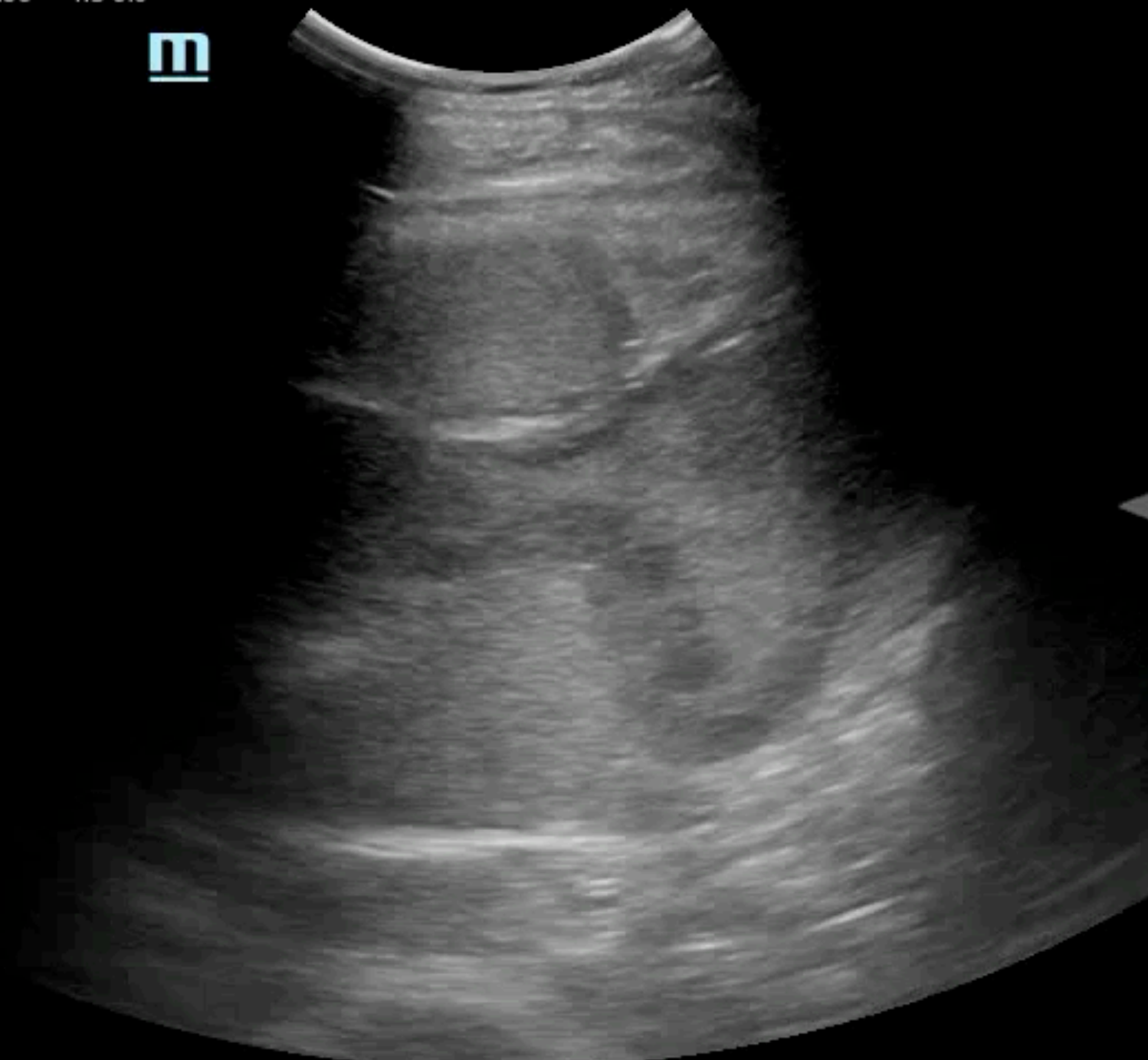


0
0
0



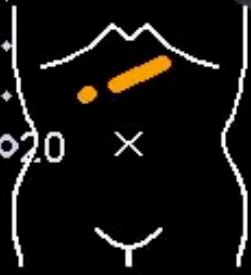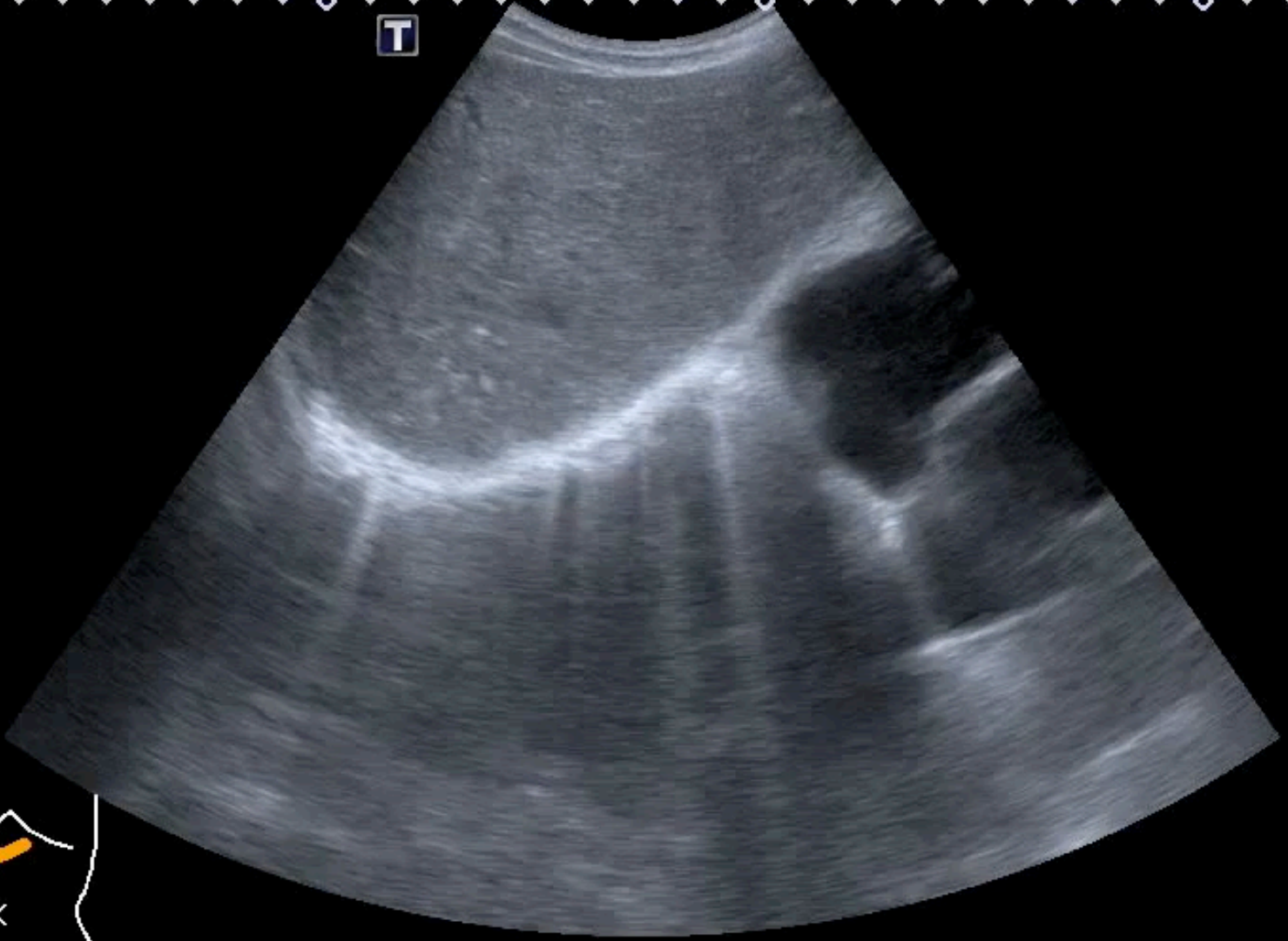
edle

uch



T

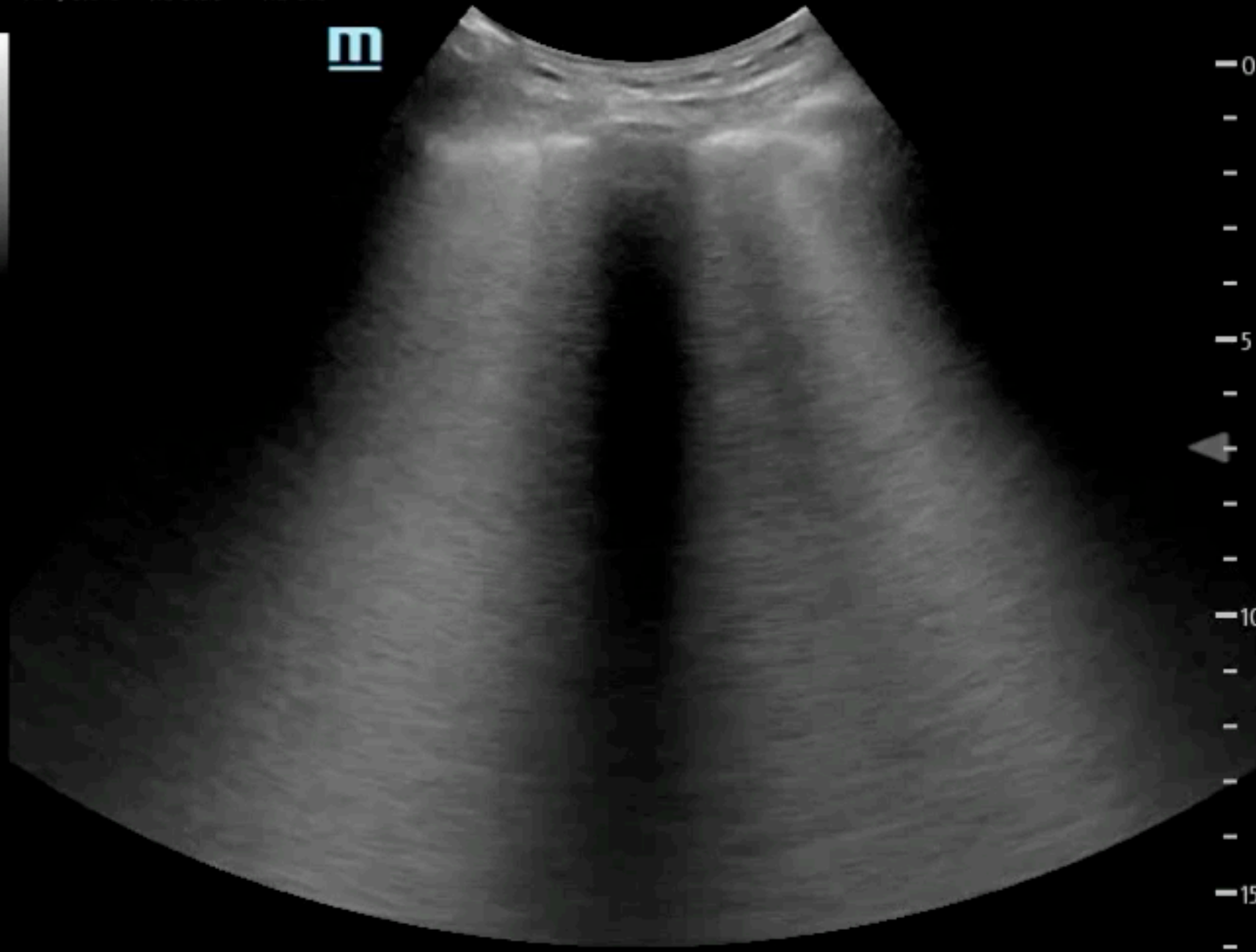
0
10
20



13
C
D

AP 96.6% MI 0.88 TIS 0.6

B
FH5.0
DR 130
FR 18
D 16.0
G 40



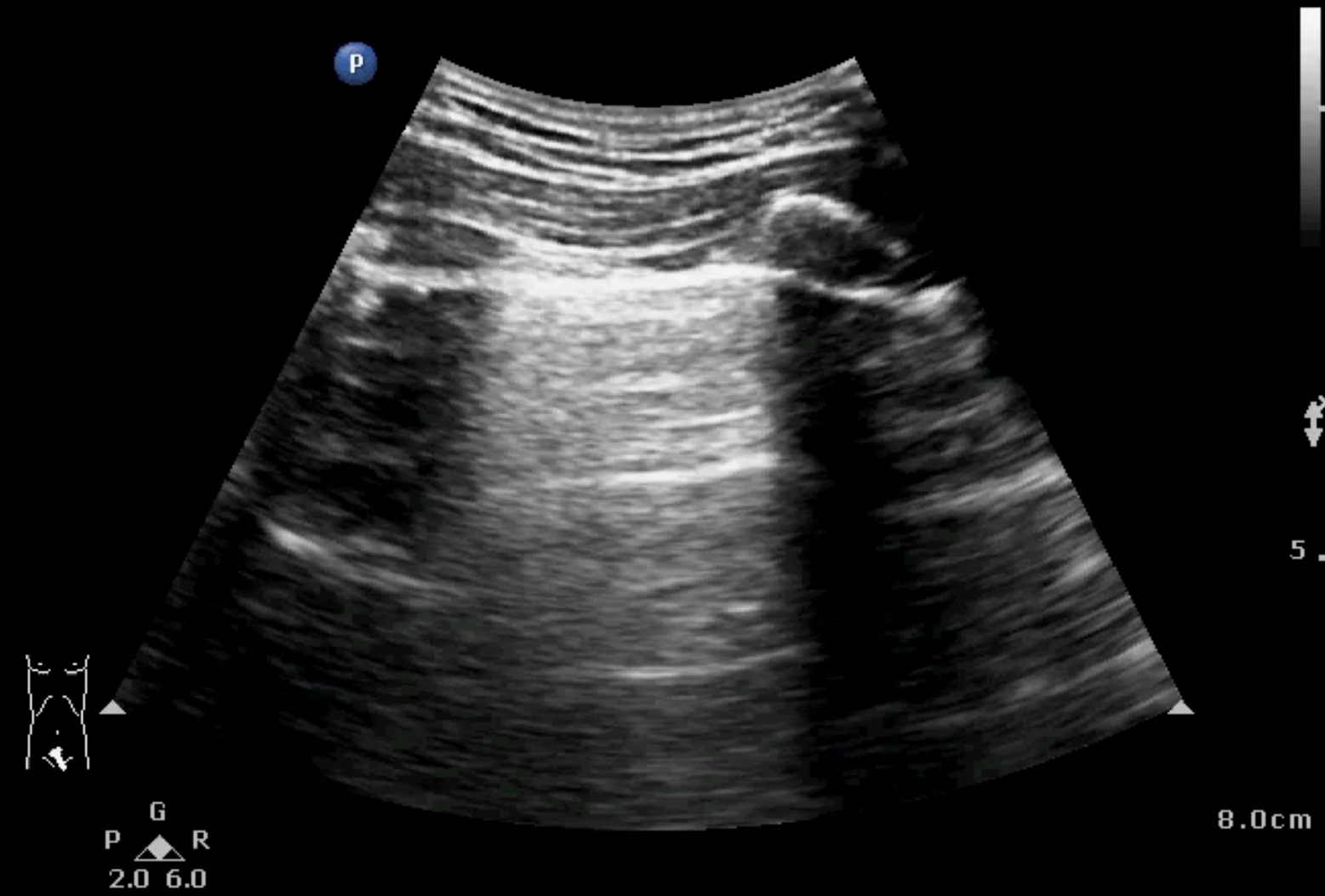
0
-
-
-
-
-5
-
-
-
-10
-
-
-
-
-15
-

iNeedle

iTouch

C Nerve
C6-2
22 Hz
8.0cm

2D
Gen
Gn 68
C 49
2/3/4

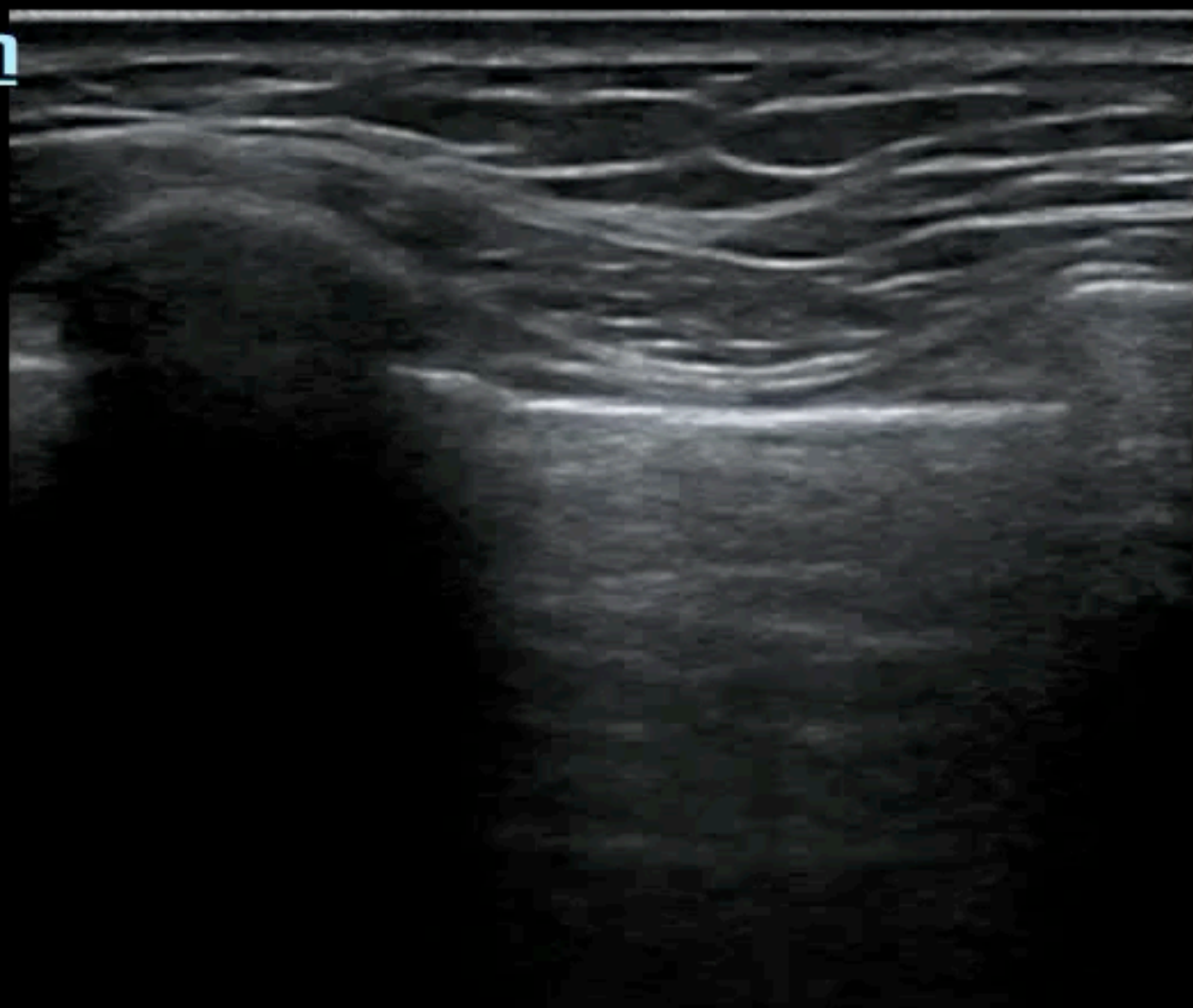


L14-6Ns
MI 0.5
TIS 0.2

AP 96.6%



B
F 7.6~16.2
DR 110
FR 82
D 3.5
G 52



-0

-1

-2

-3

Crd

P21



55%

MI

0.9

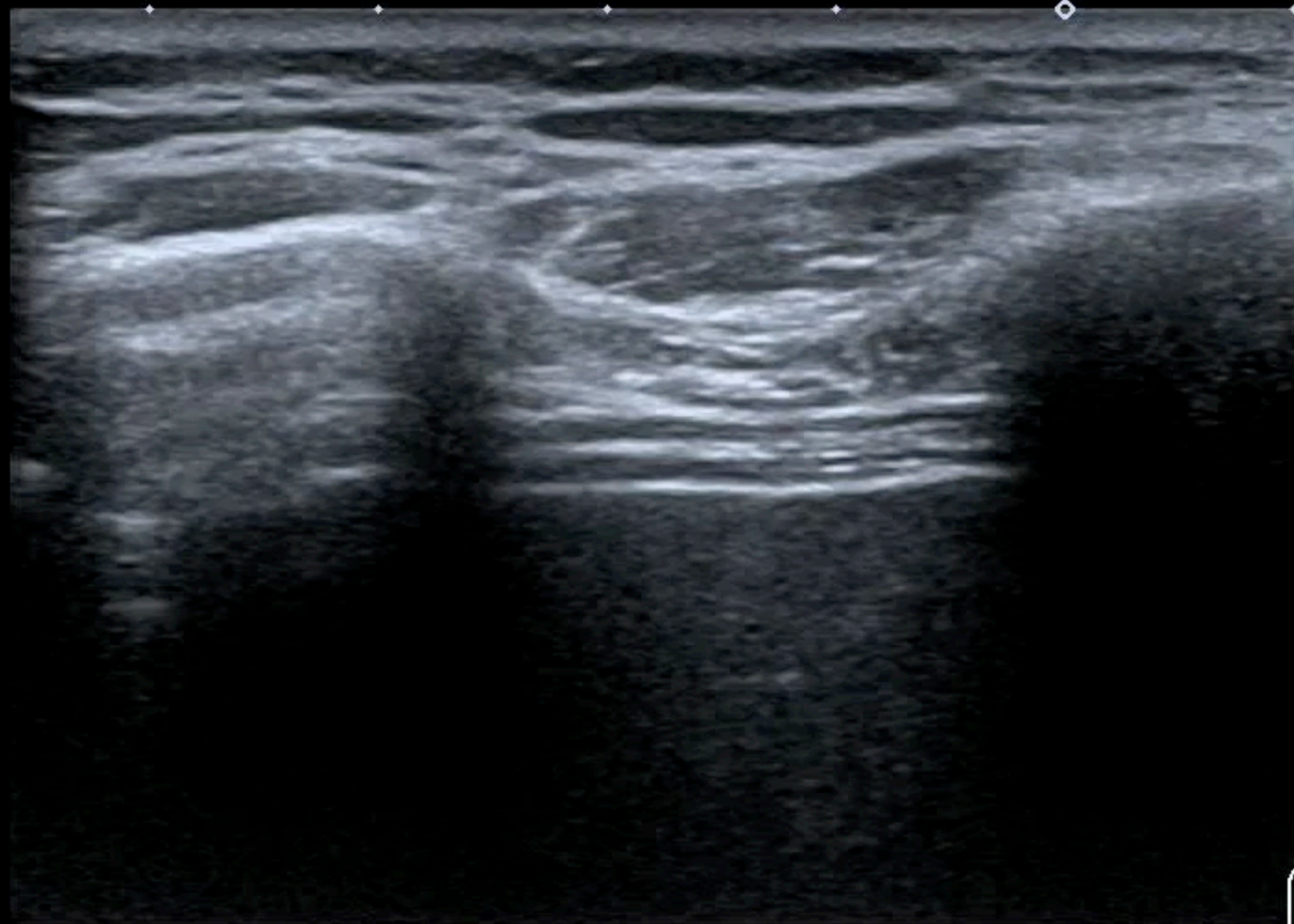
TIS

0.7



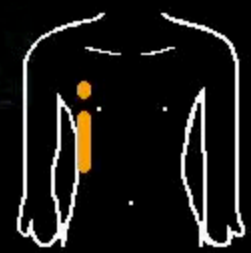19

- T
- 0
- 1
- 2
- 3
- 4



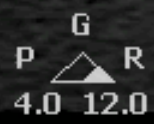
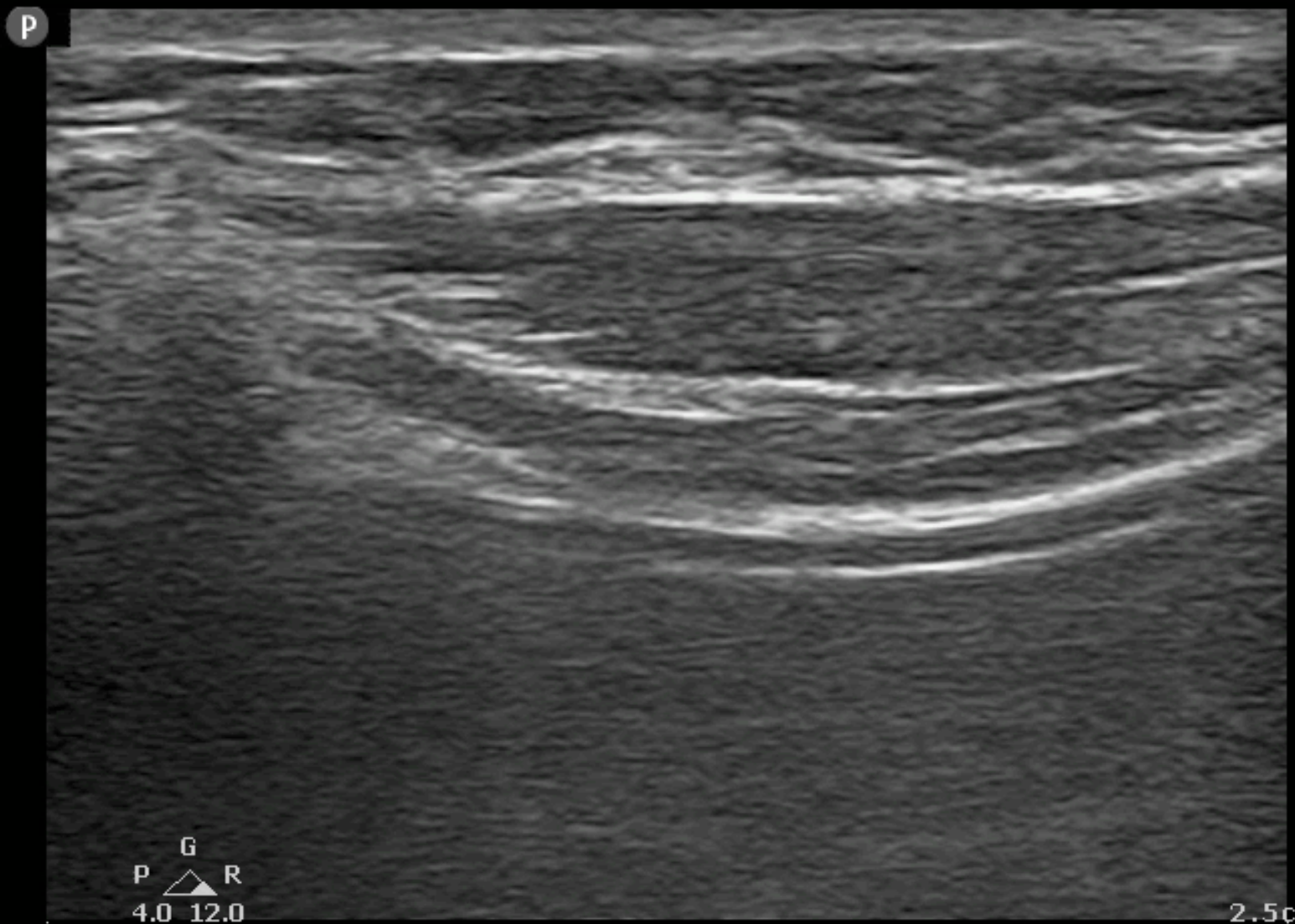
Precision APure+

MI
1.5
14L5
T11
35 fps
Qscan
G:90
DR:60
A:6
P:4



MSK Gen
L12-4
46 Hz
2.5cm

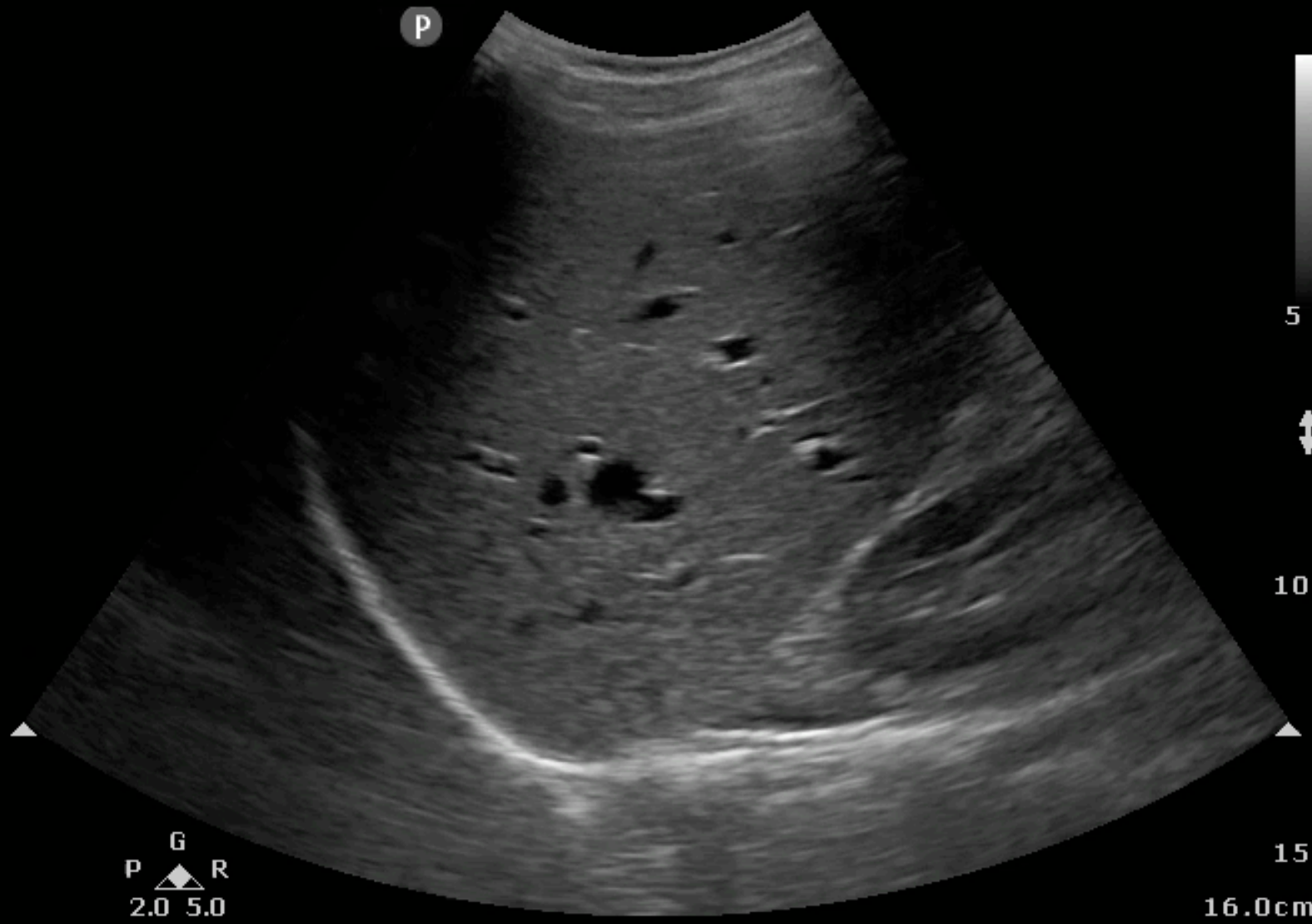2D
Res
Gn 100
58
4/3/4



2.5cm

Abd Gen
C5-2
29 Hz
16.0cm

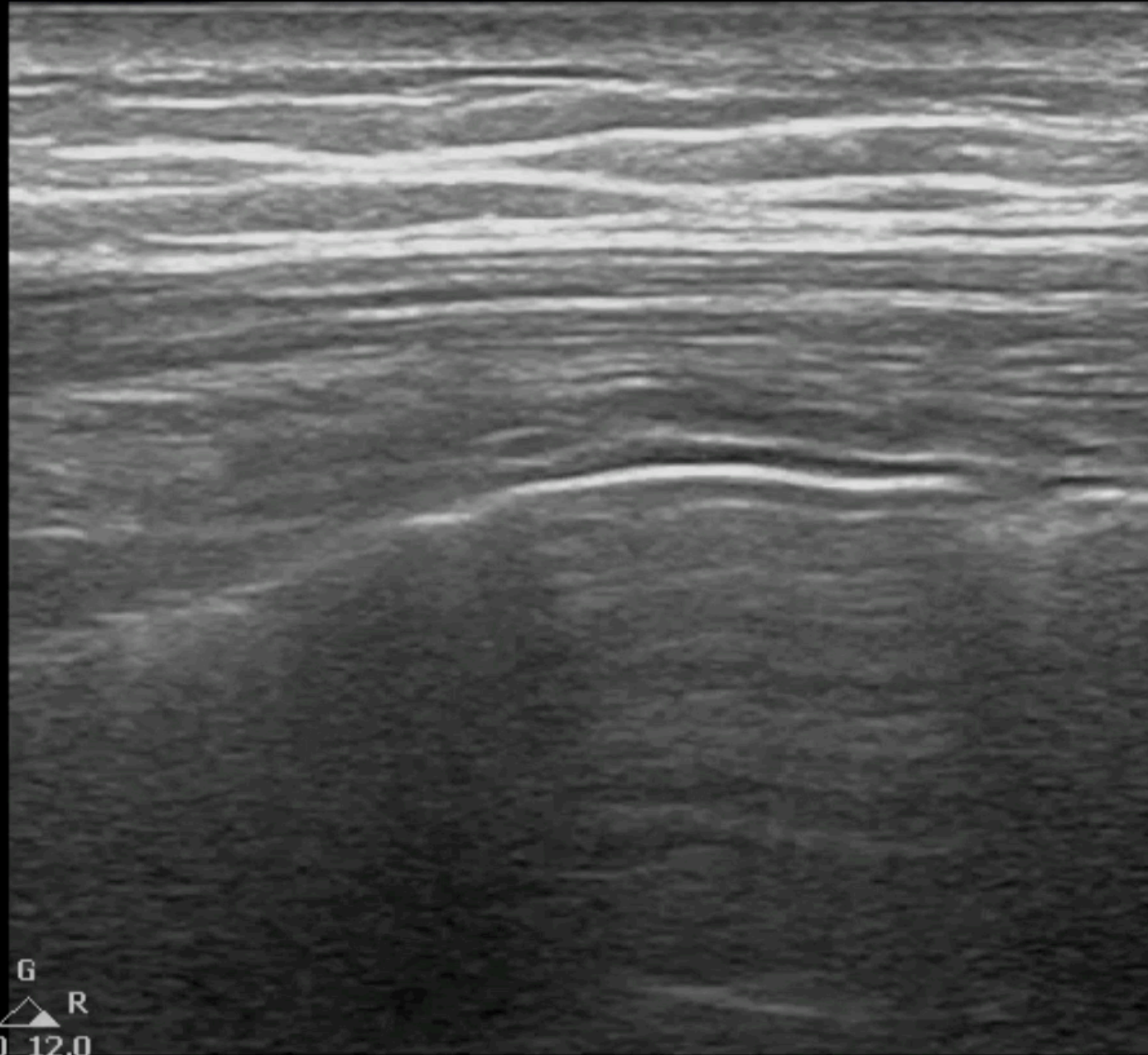
2D
Gen
Gn 64
52
3/3/3



16.0cm

al

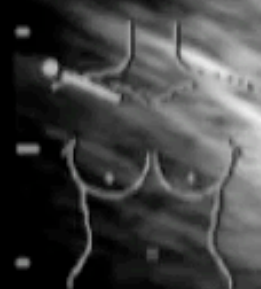
P



P G R
3.0 12.0

3.5c

18Hz 1 3.5M
DUA:
MI =



R12 043 04

1: Abdomen

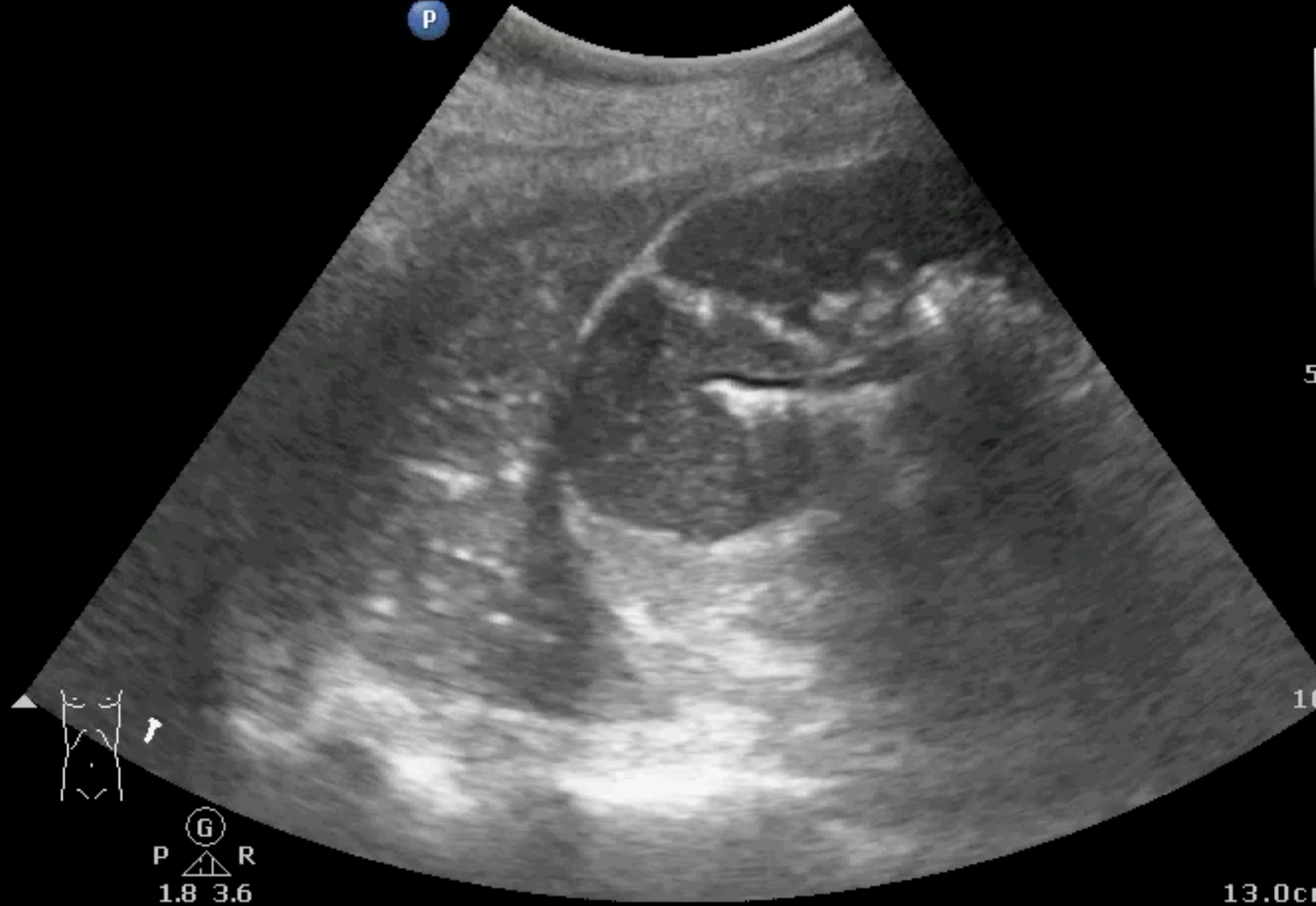
en

m

00

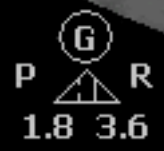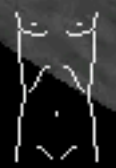3

P



5

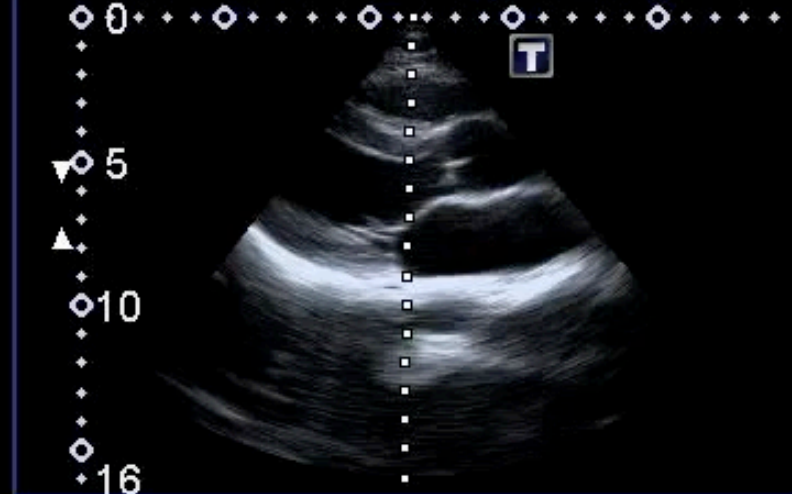
10



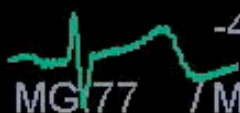13.0cm

G:82
DR:55

TE:3



MI:1.5
5S1
T3.0
32 fps



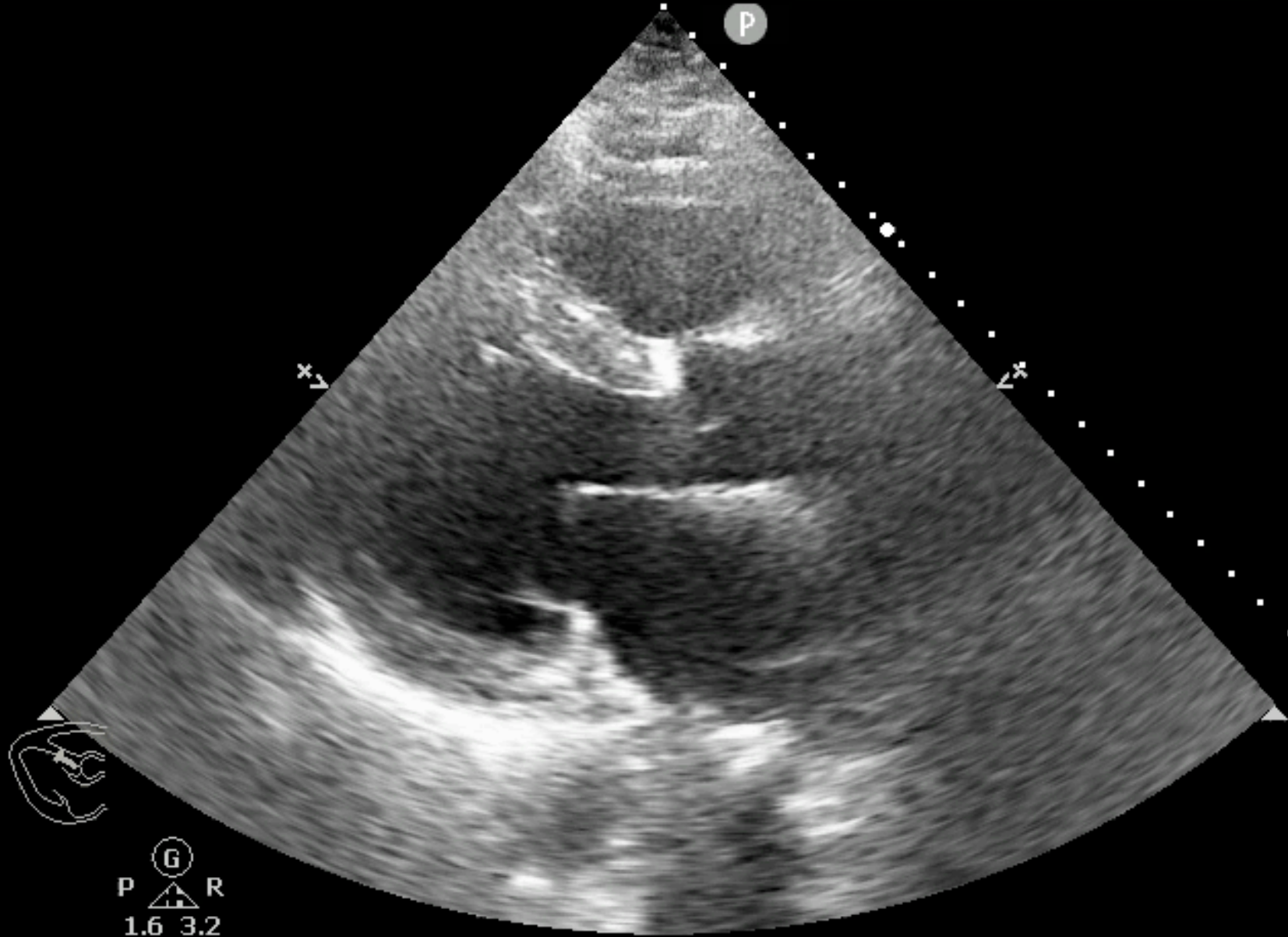
MG:77 / MDR:50 / T3.0



t Echo

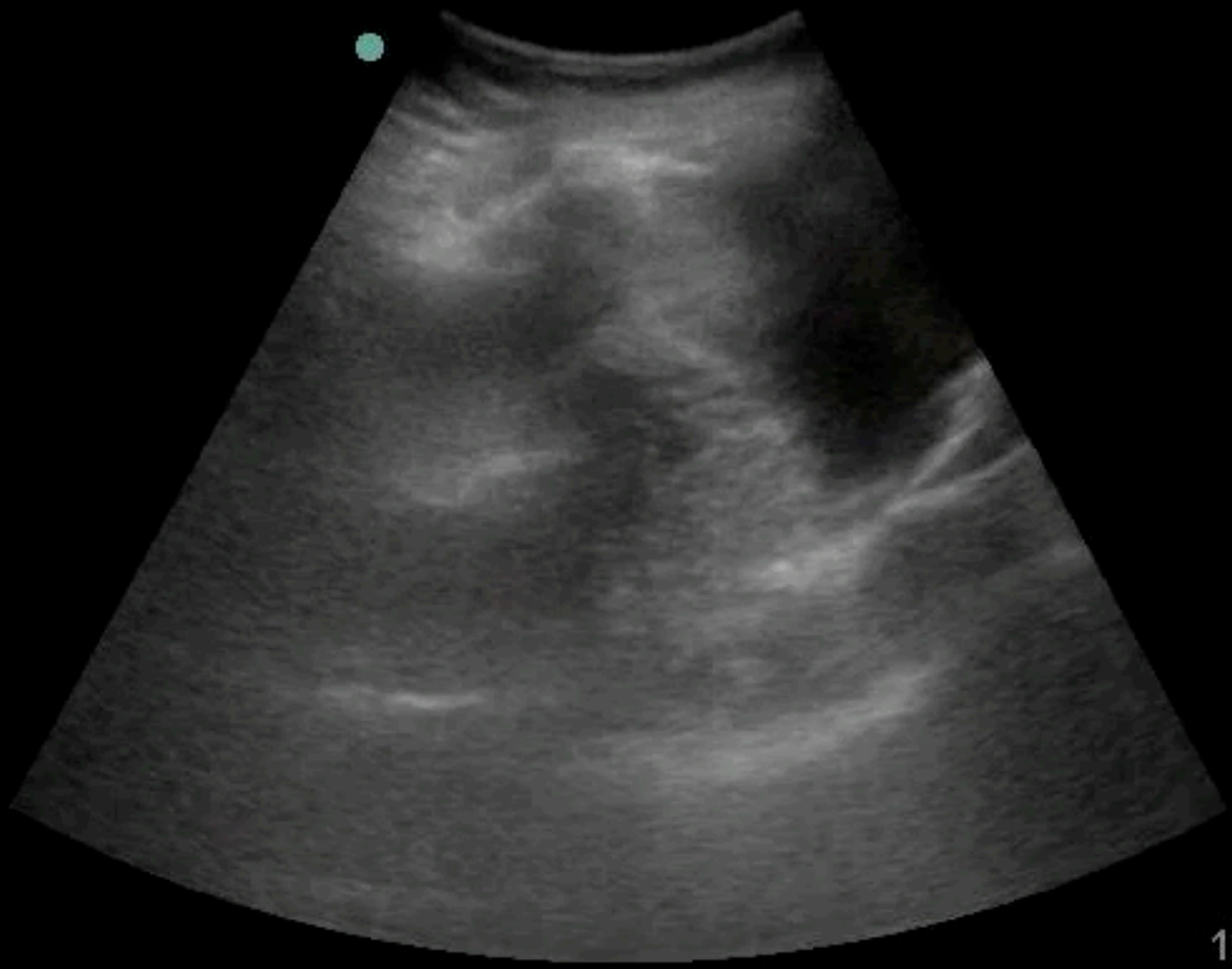
Z
cm

n
52
/0



G
P R
1.6 3.2

-  Patient
-  Auto Gain
-  Gen
-  Clip
-  Page 1/3



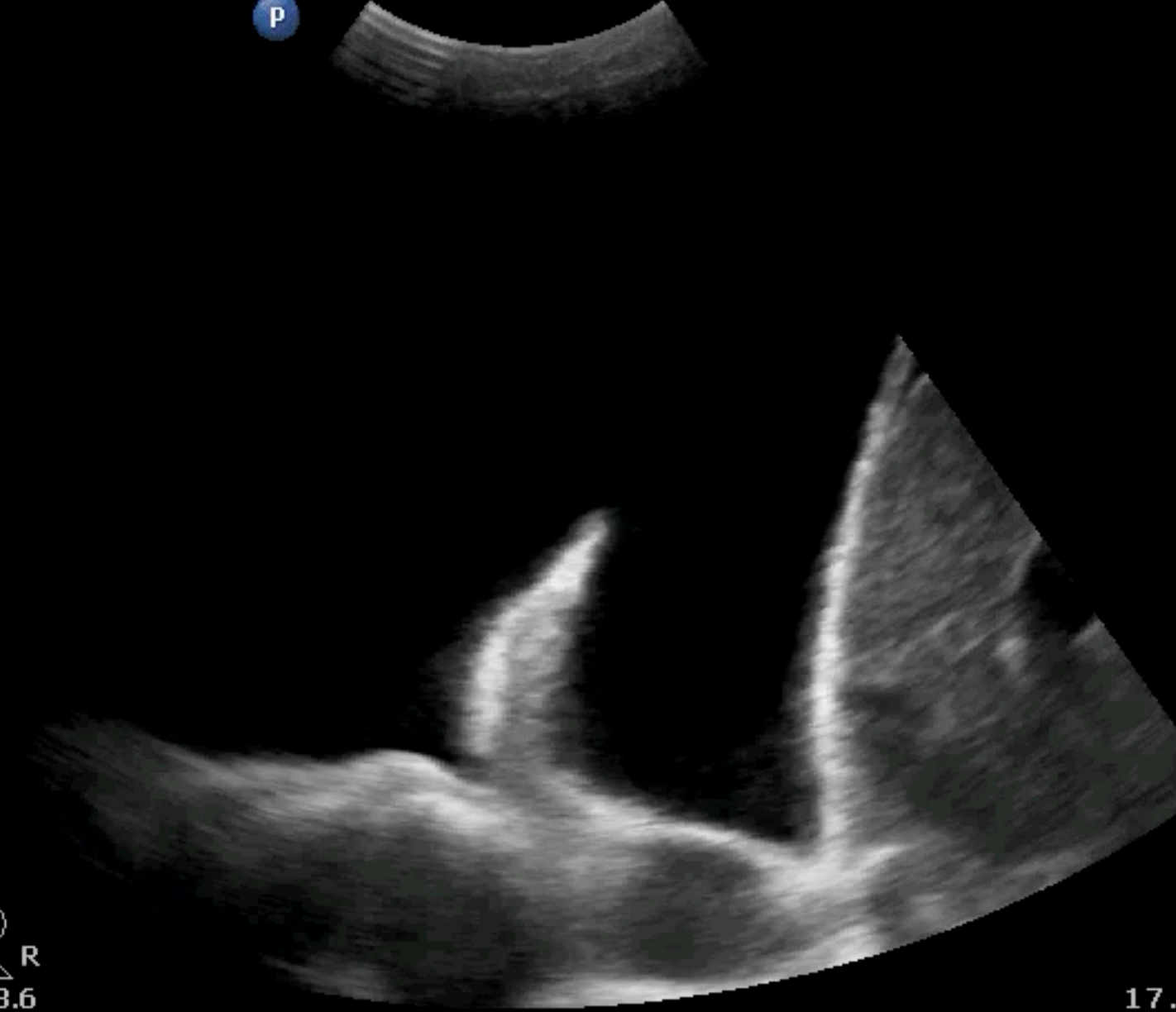Gen
L
Hz
cm

en
60
6
3/3

P



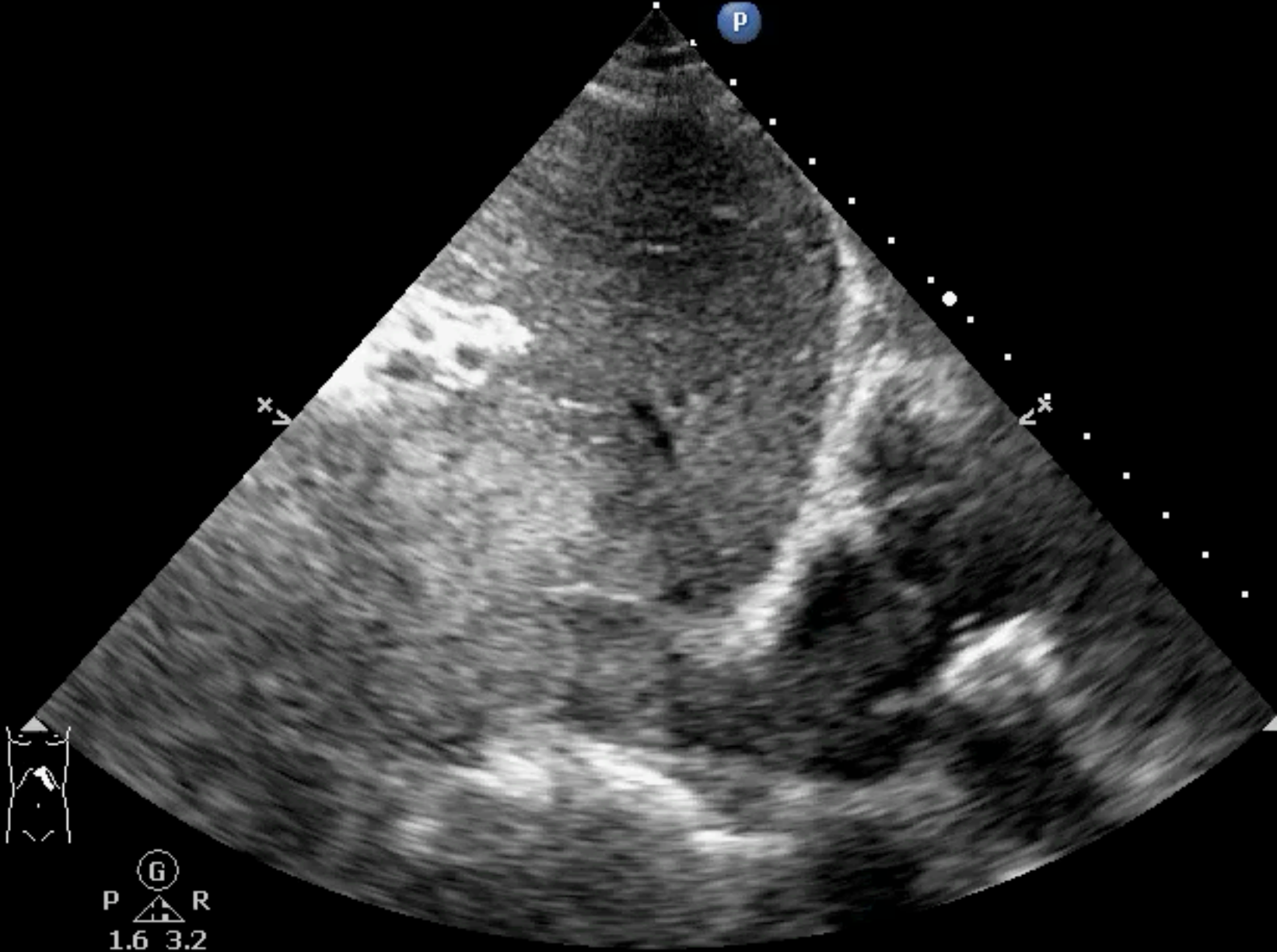
P
G
R
1.8 3.6



17.

lt Echo2
L
Hz
0cm

en
30
0
2/0



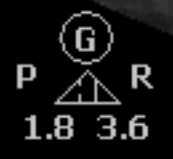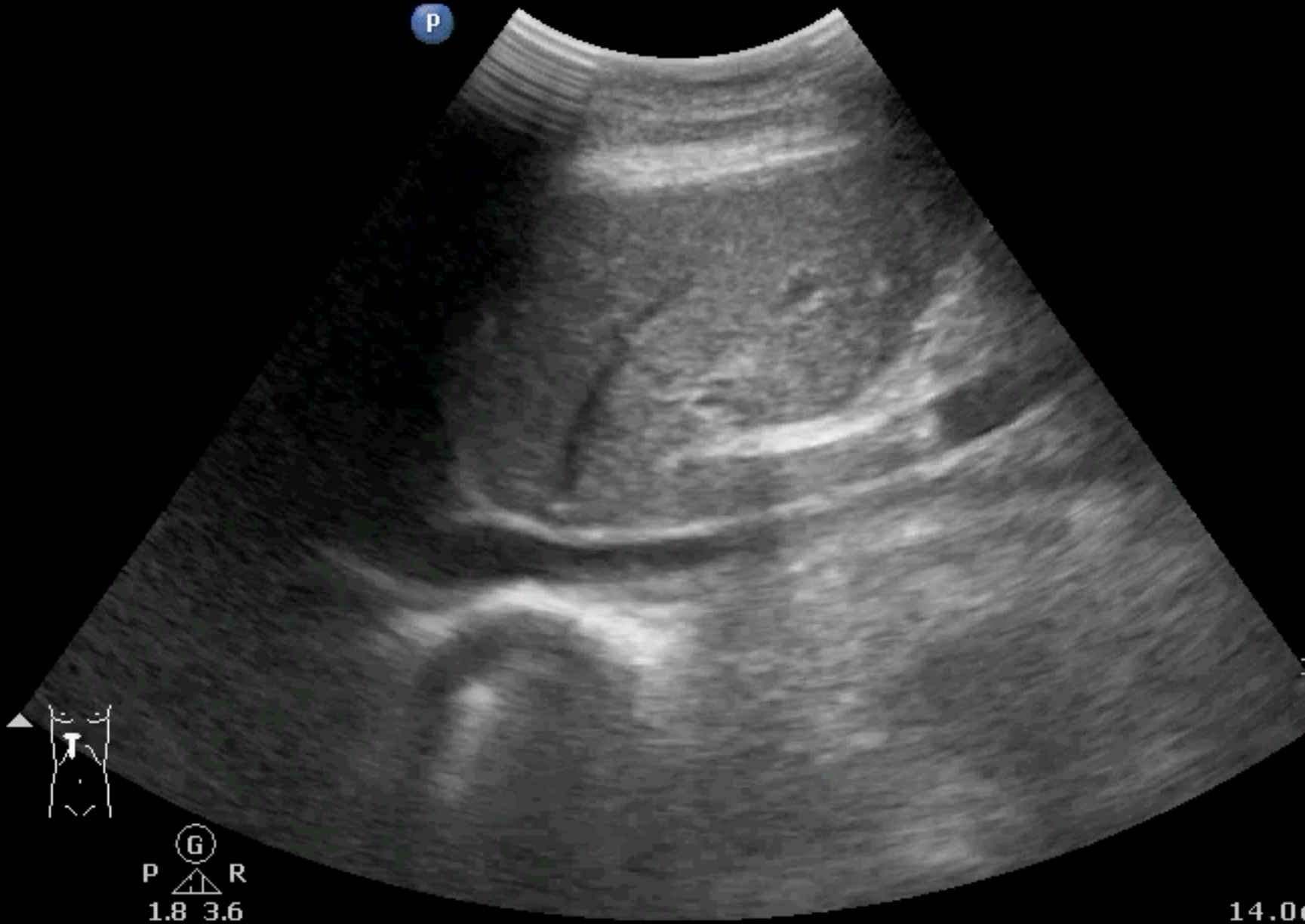
G
P R
1.6 3.2

Gen

z
cm

m
.00
/3

P



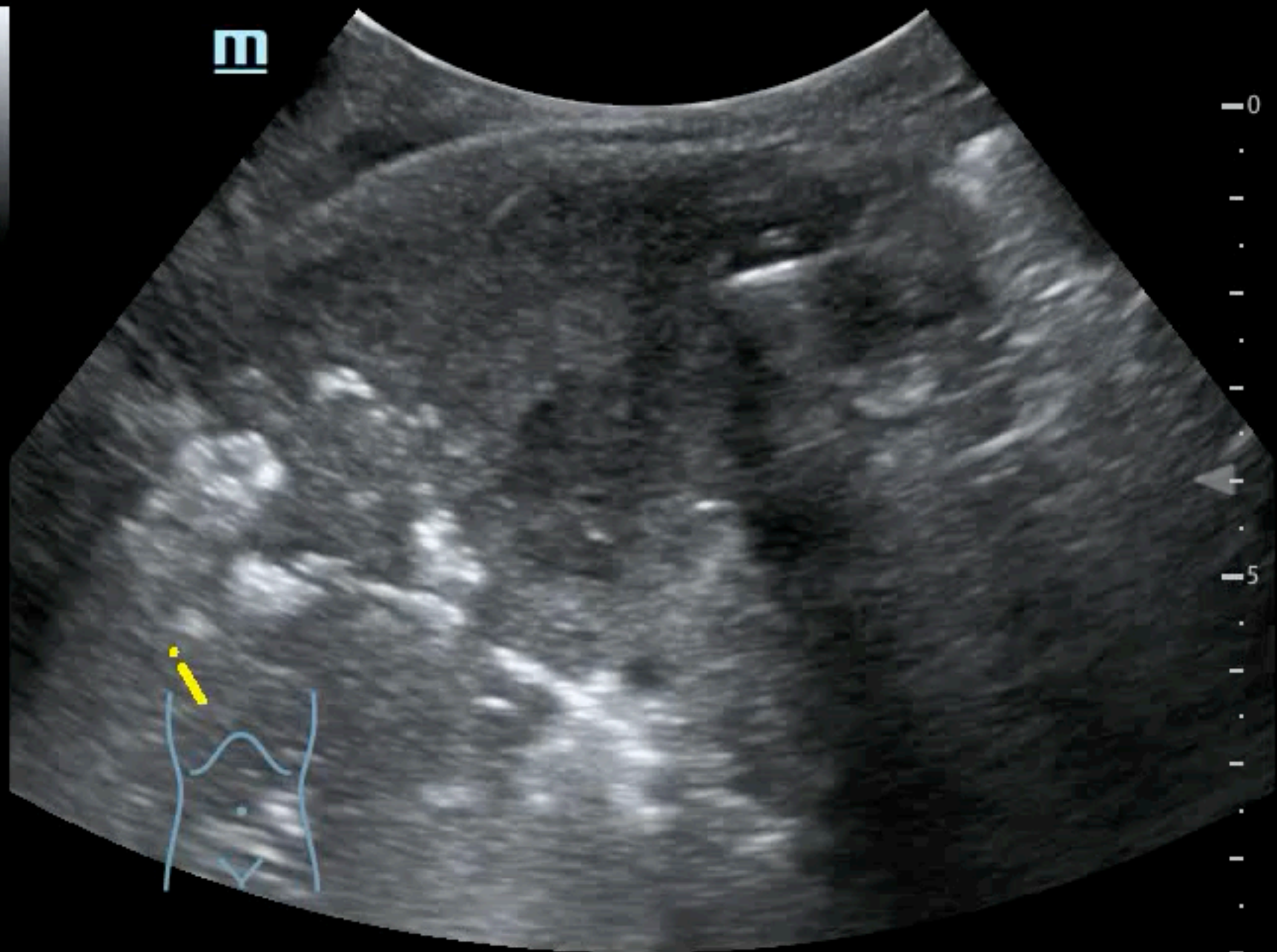
14.00

C5-2s
MI 1.0
TIS 0.6

AP 96.6%



B
FH5.0
DR120
FR32
D9.0
G50

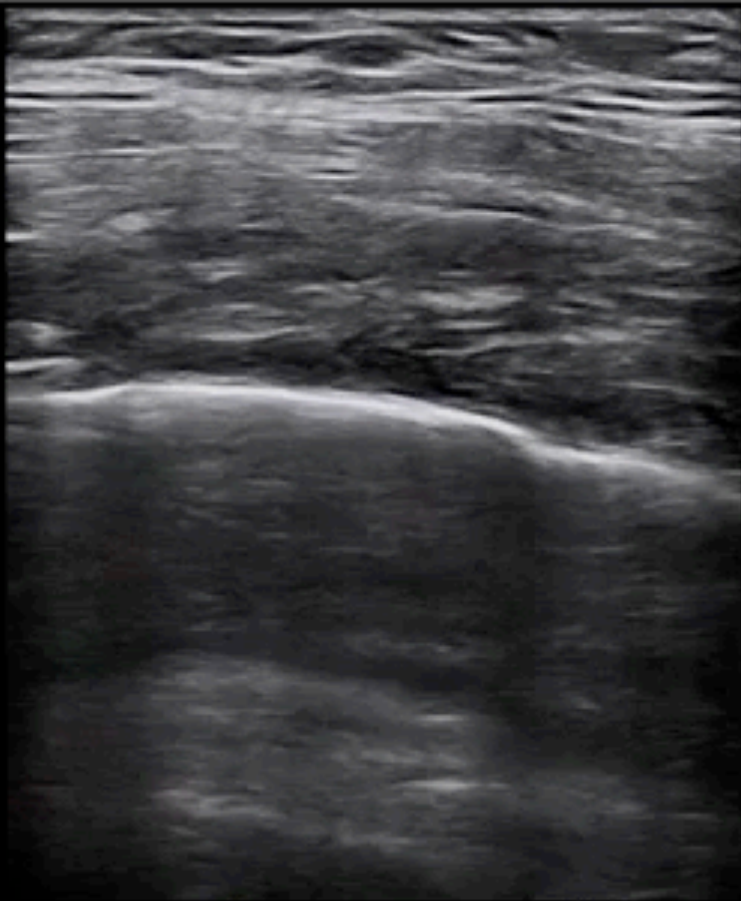



M7
B1
F7.5 / D4.6
G52 / FR43
IP5 / DR95



M



—
—
—
—
-2
—
—
-4
—

1/213



Precision A Pure

Prec

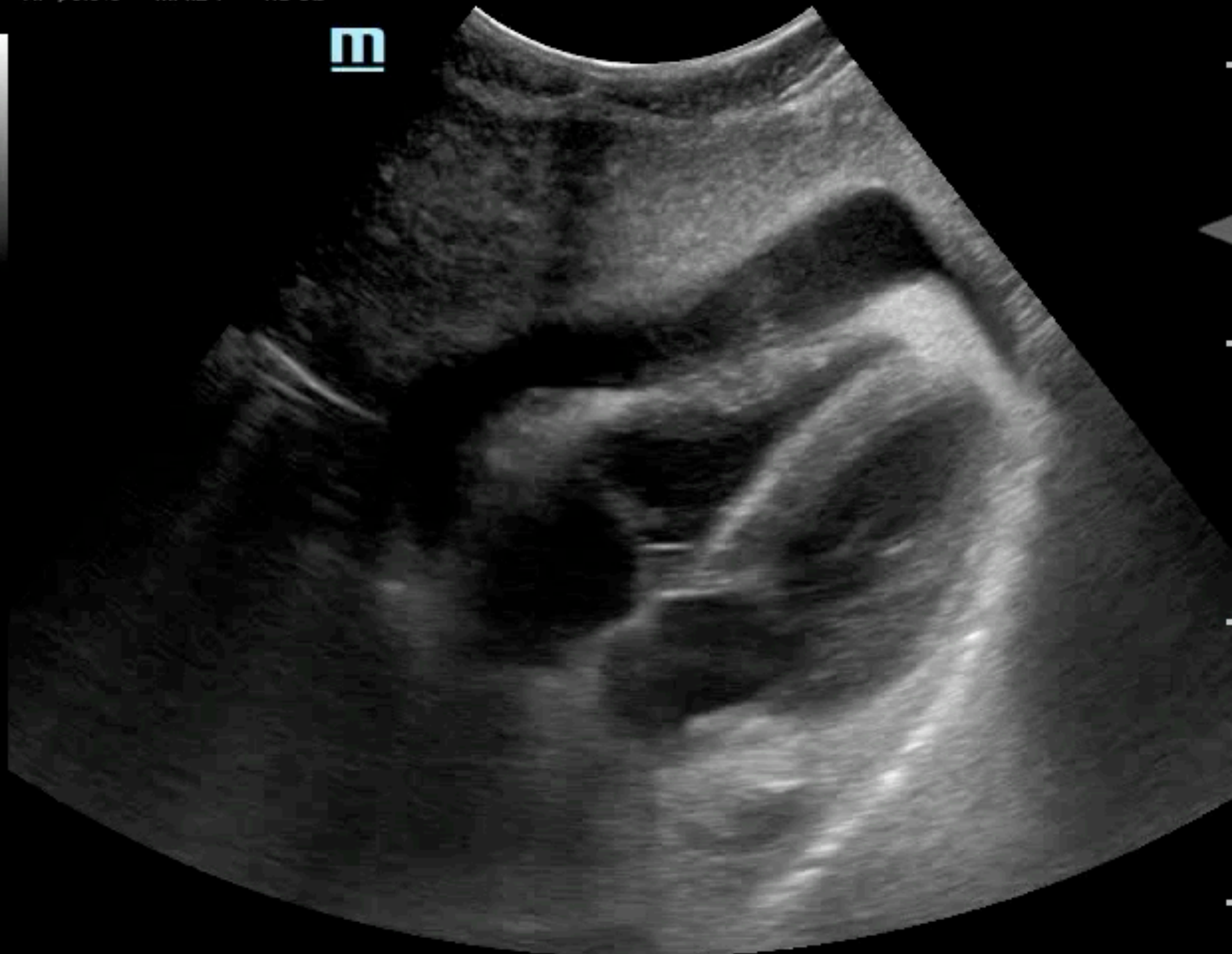
T

T

MI
1.1
6C1
T5.0
16 fps
Qscan
G:89
DR:65
A:2
P:1

m

0
15
3
0
0



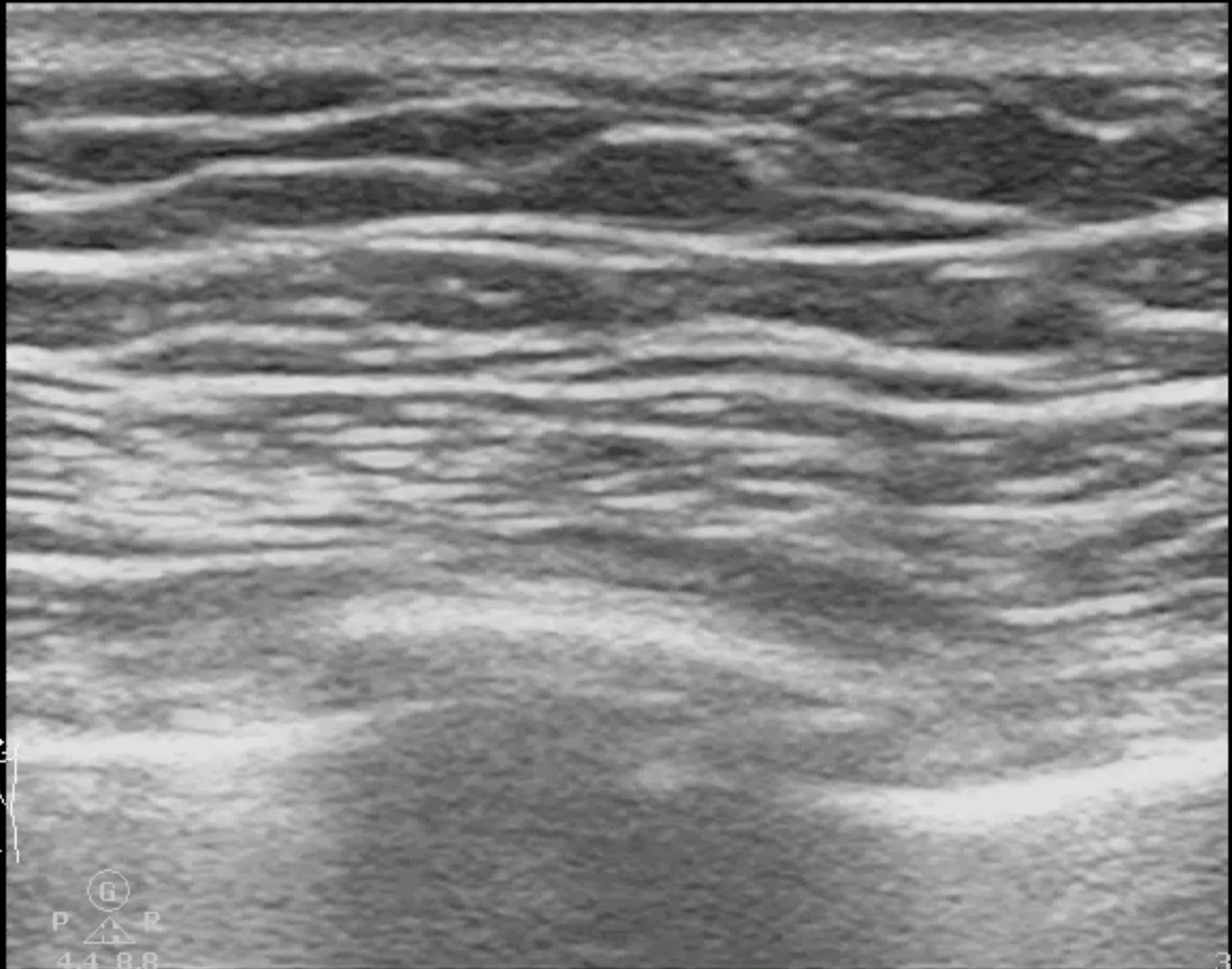
edle

uch

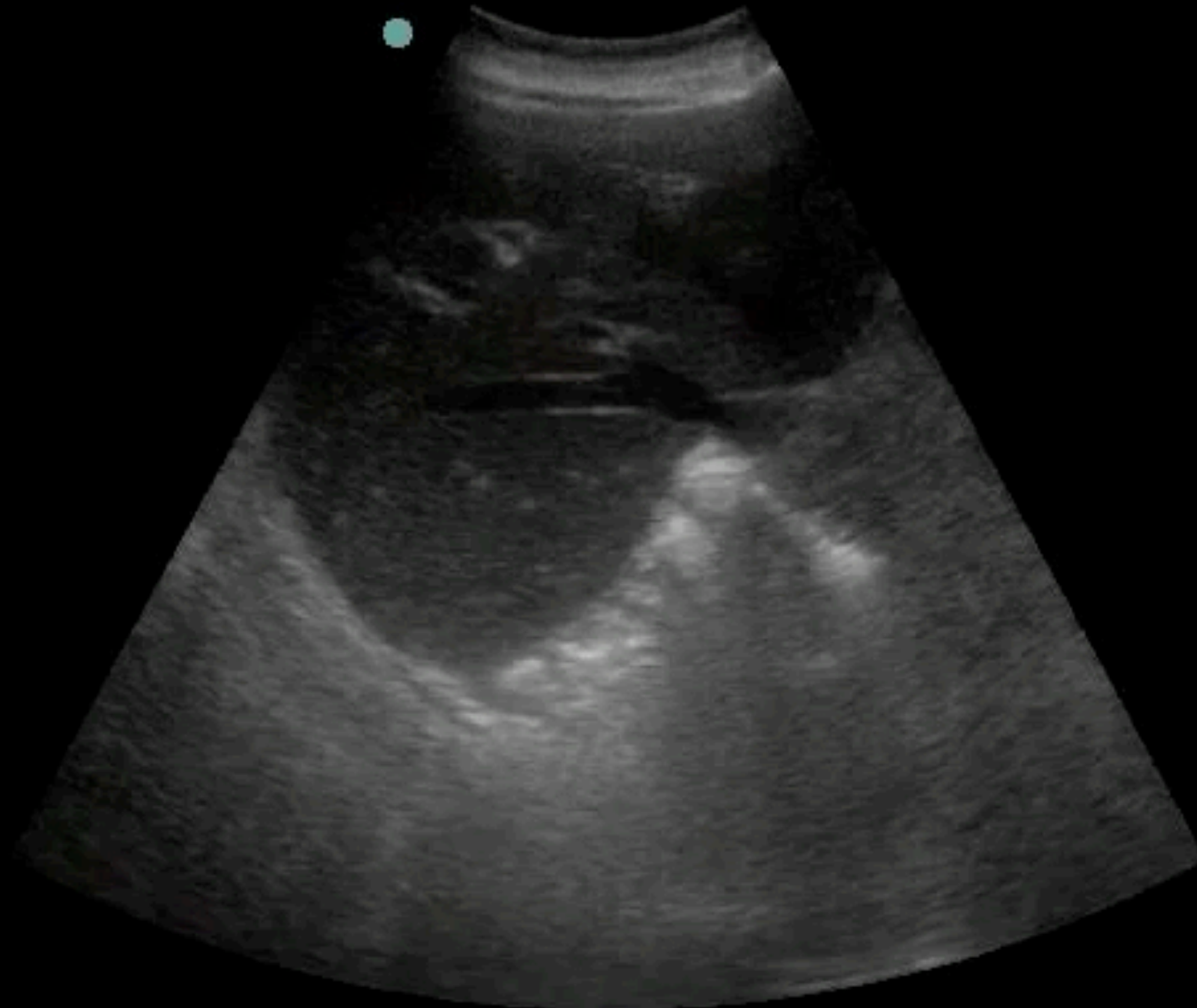
ous
-3
Hz
cm

P

en
78
1
3/2



3.0

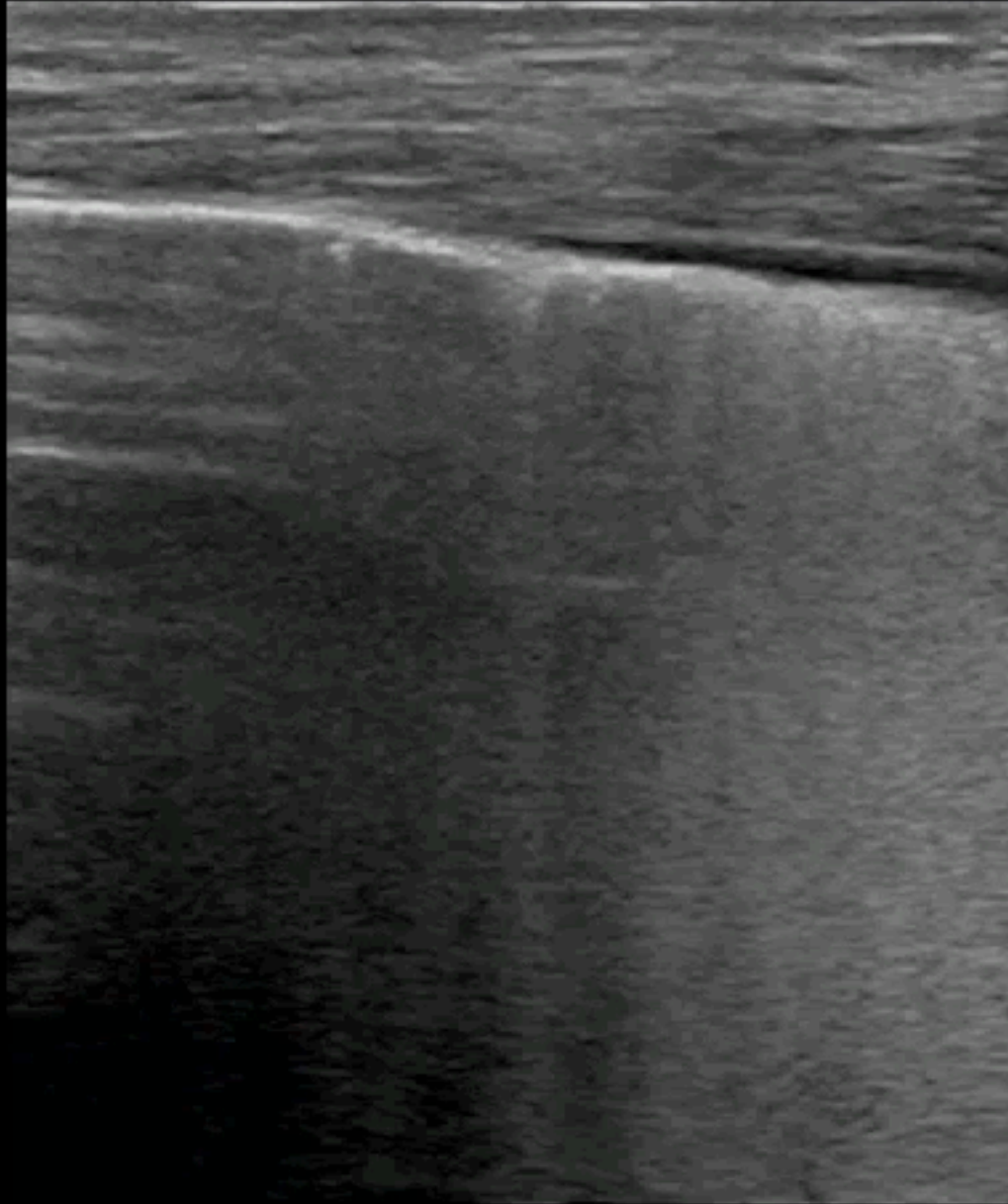

Abc
C60
74%
MI
0.6
TIS
0.1



cial

P

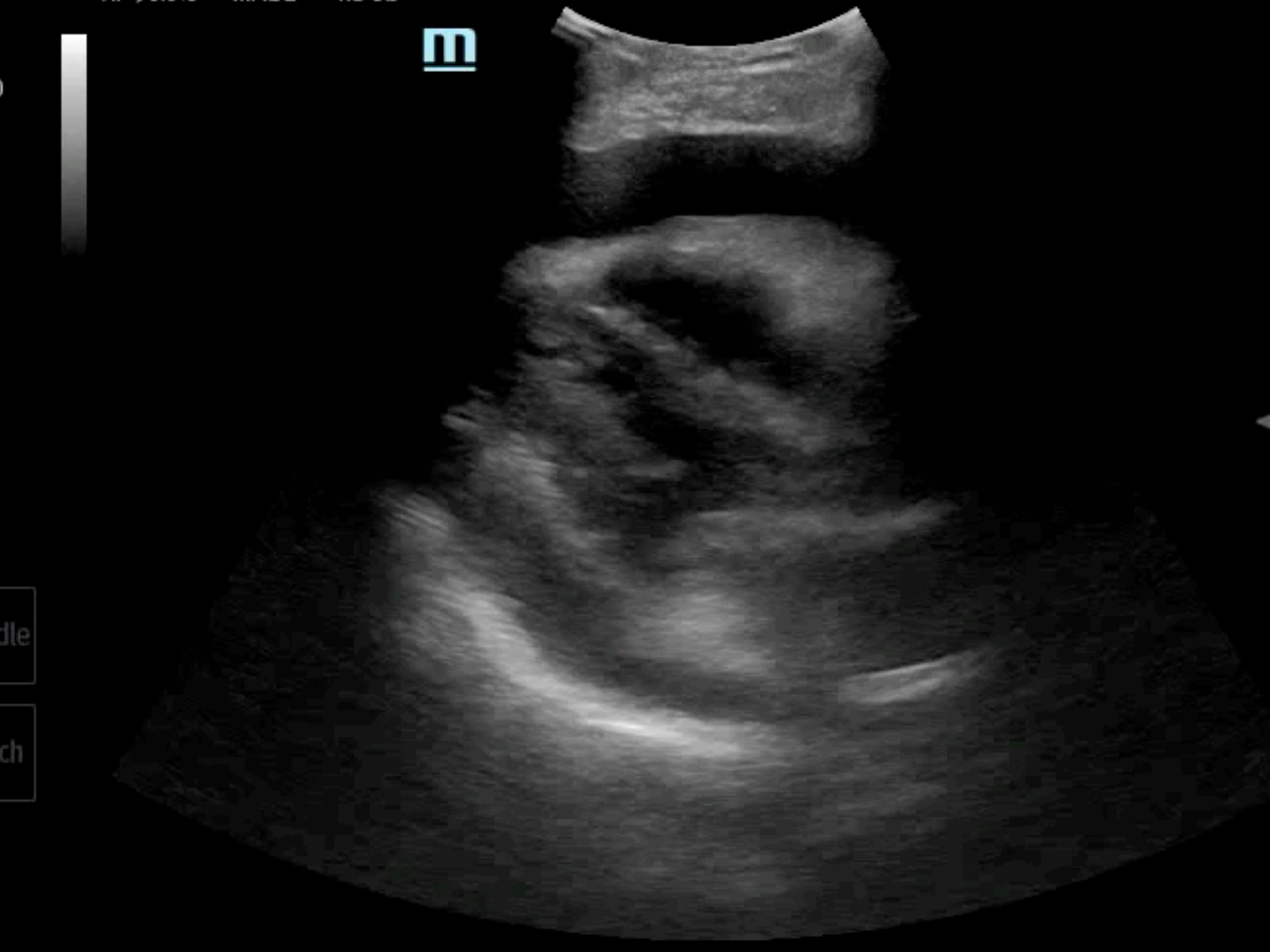


2

4

4.5cm





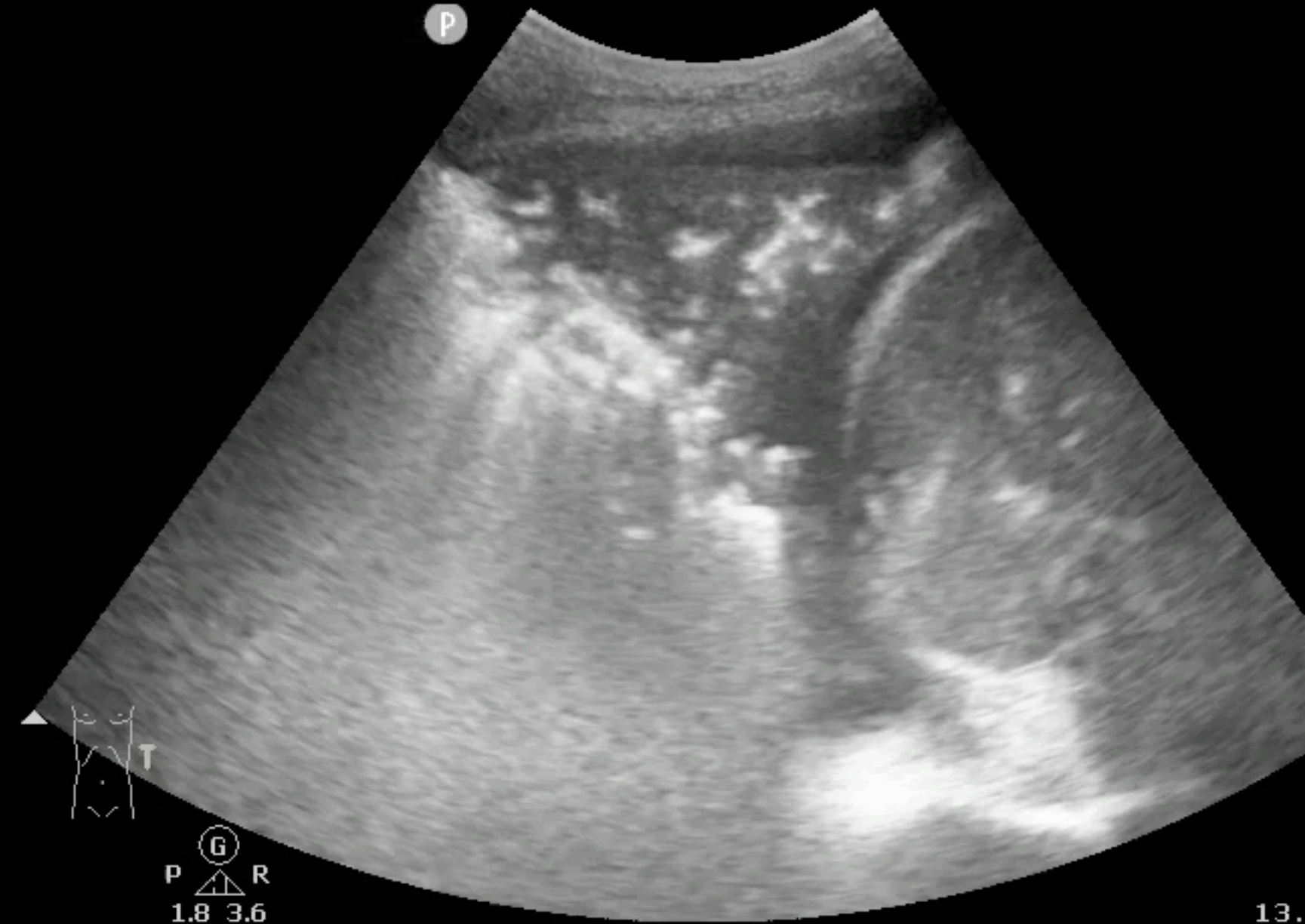
M

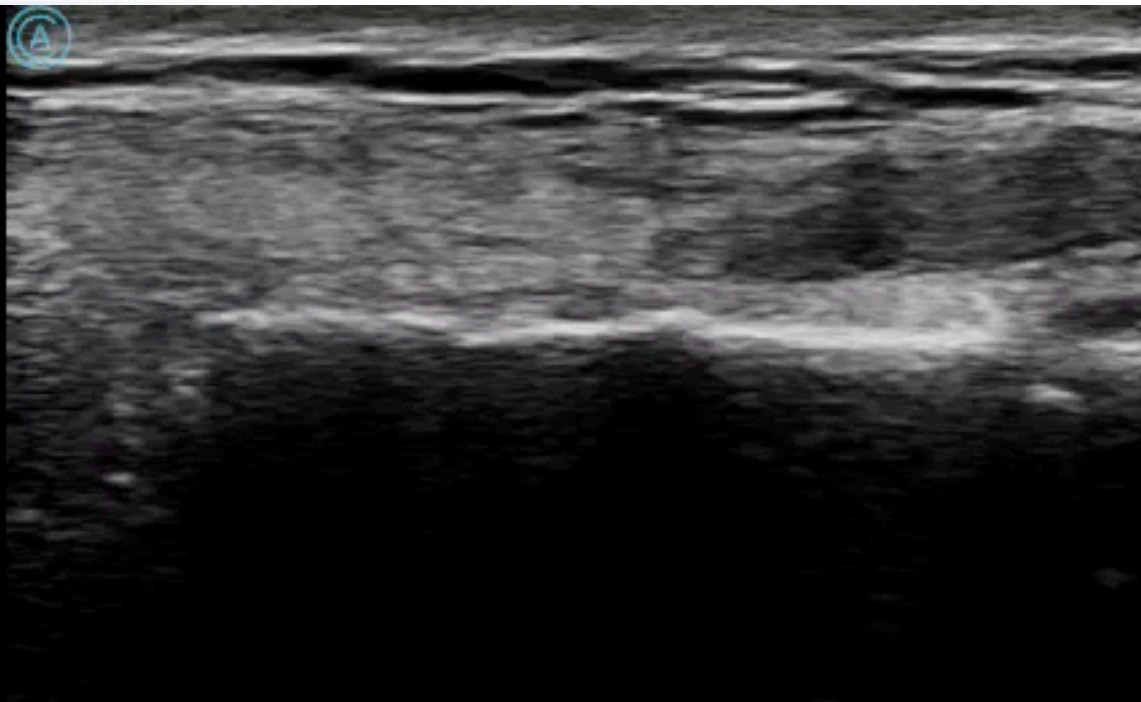
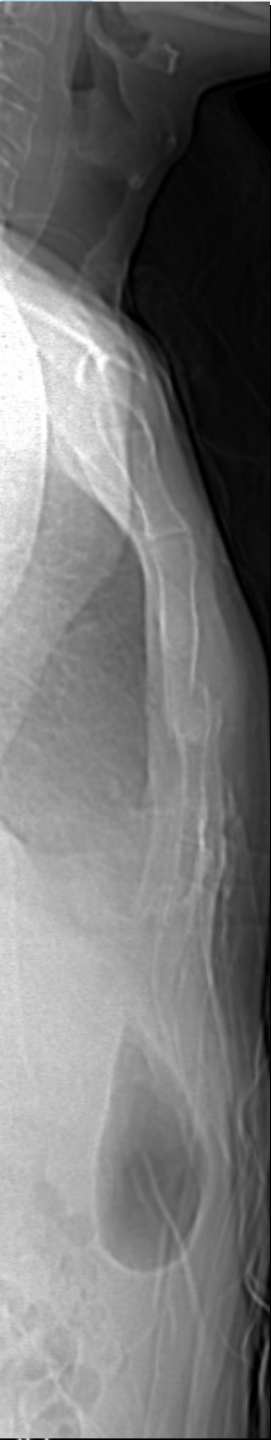
dle

ch

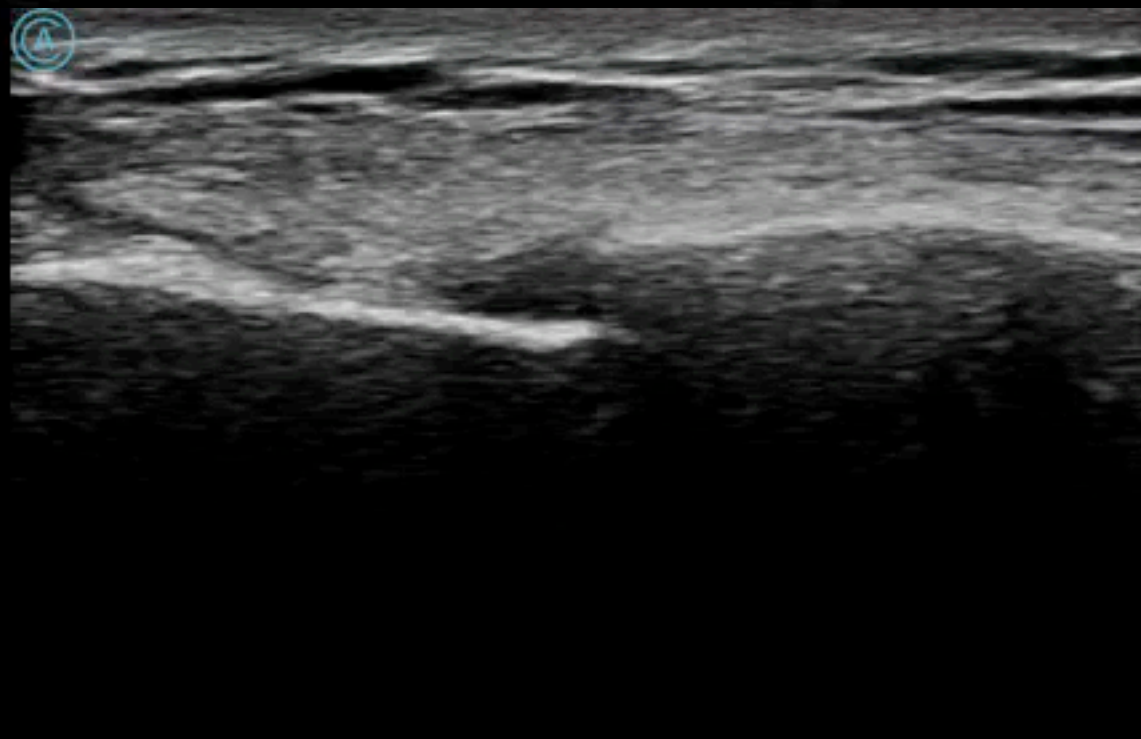
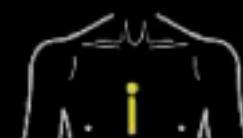
Gen
1
Hz
0cm

en
100
6
3/3

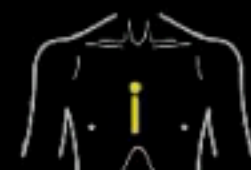



SE: 0
IM: 2



SE: 0
IM: 1



C5-2s

AP 96.6%

MI 0.78

TIS 0.5

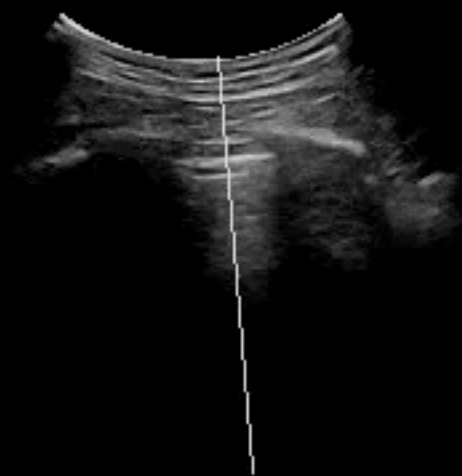B

FH5.0
DR 130
FR 18
D 9.0
G 40


M

FH5.0
DR 95
D 9.0
G 50
V 75

m



0
5



0
5

iNeedle

iTouch



0 5 10 15 20 25 30 35 40 45 50 55 60 65 70 75 80 85 90 95 100

C5-2s

AP 96.6%

MI 0.78



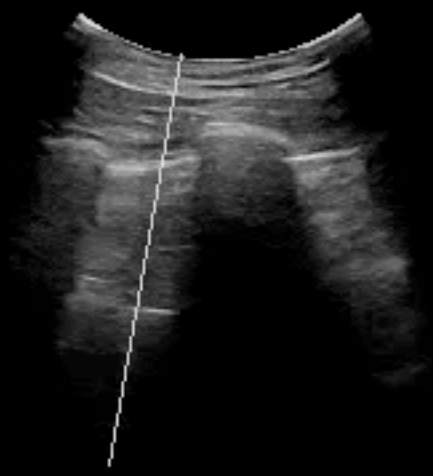
TIS 0.5

B

FH5.0
DR 130
FR 18
D 9.0
G 40

M

FH5.0
DR 95
D 9.0
G 50
V 75



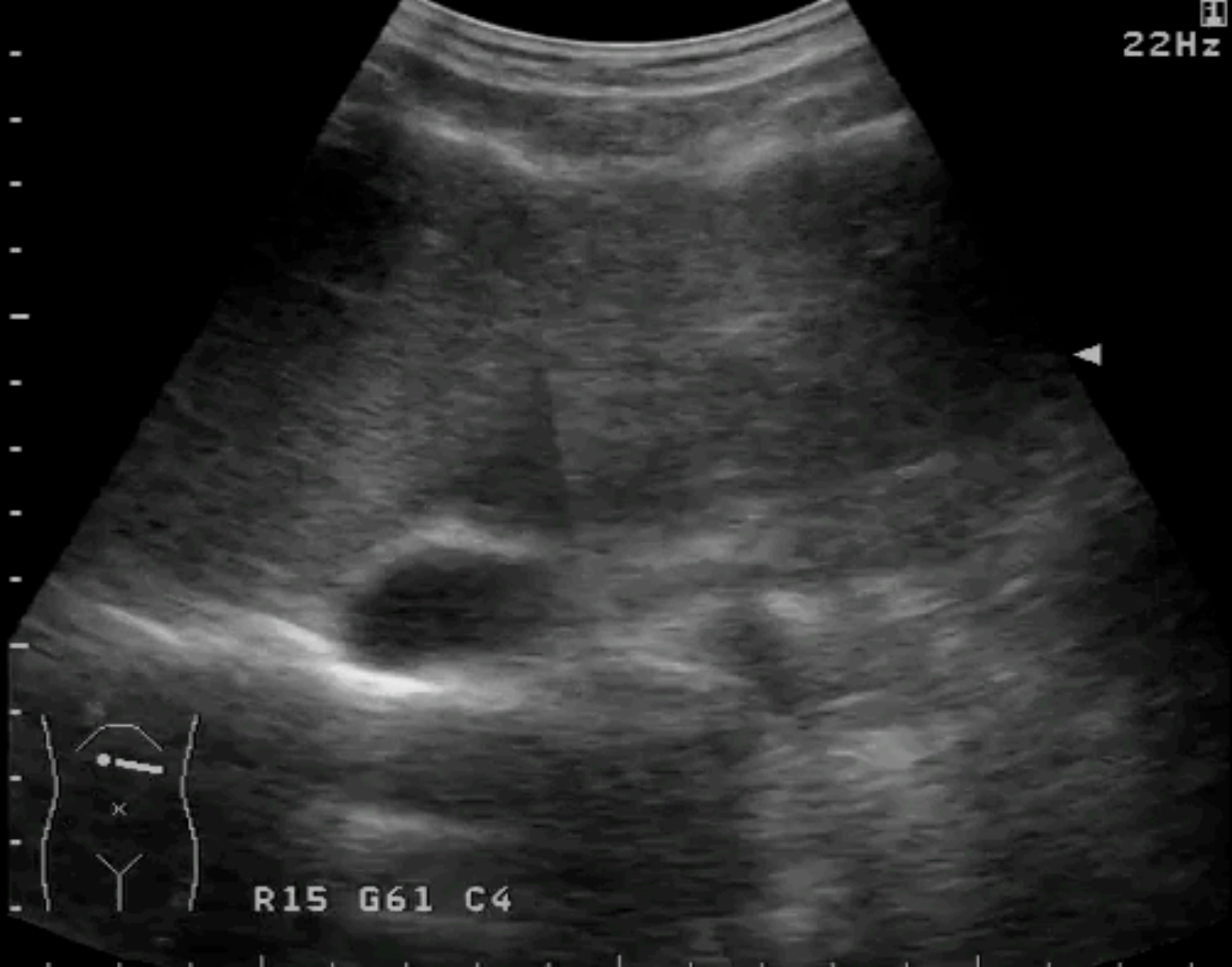
iNeedle

iTouch



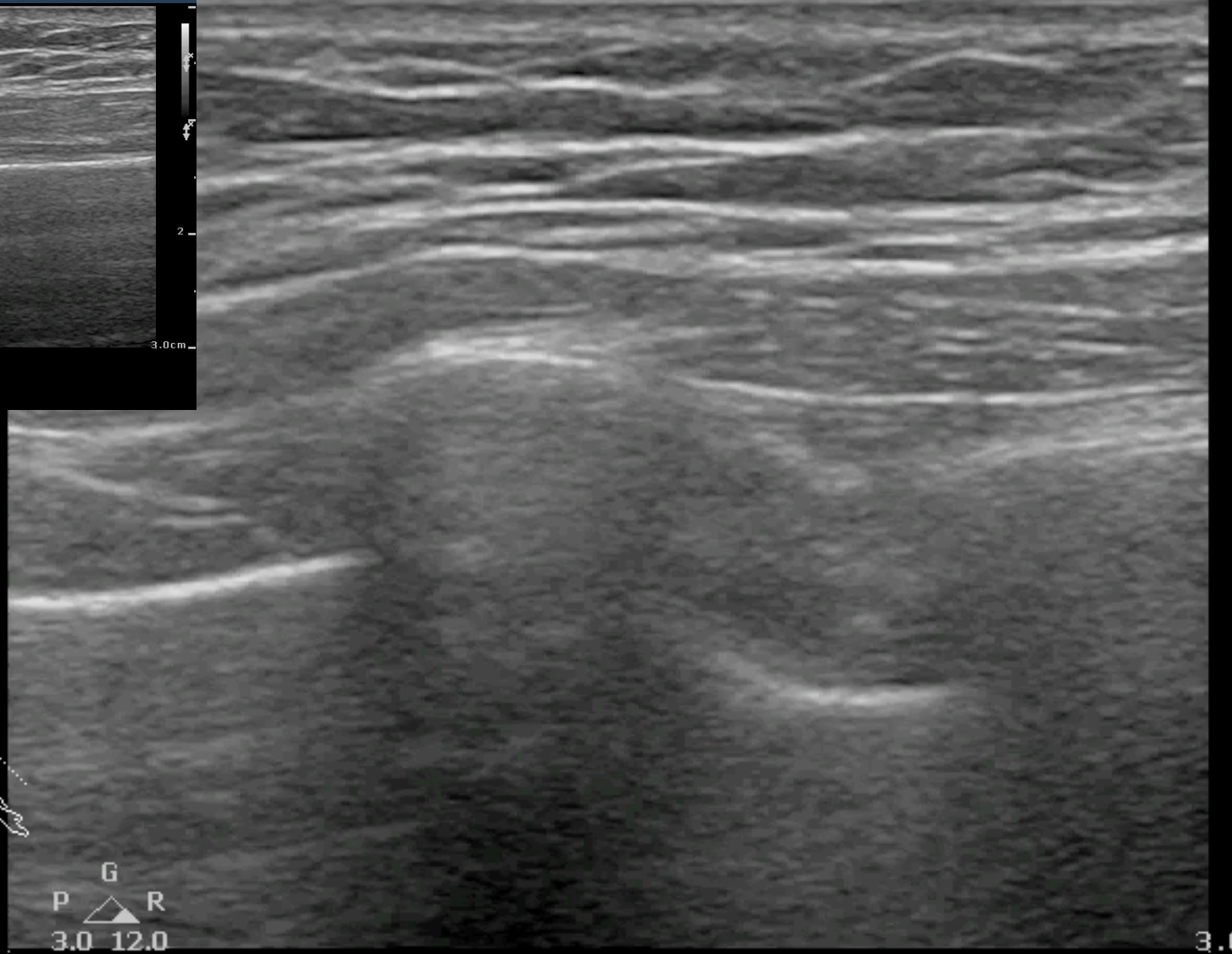
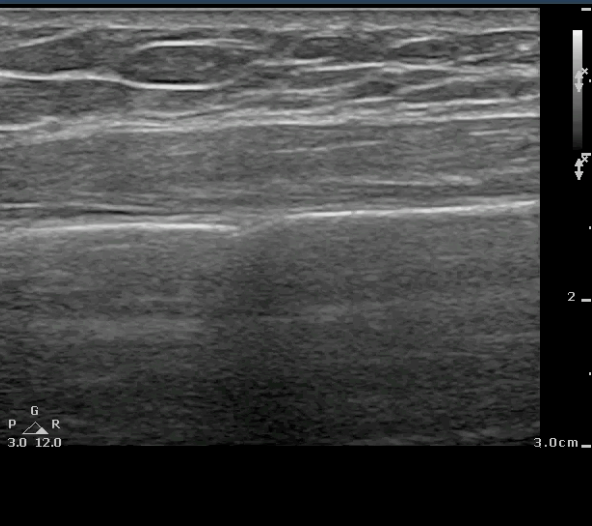
22Hz

3.5M S
DUA: 10
MI = 0



R15 G61 C4

: Abdomen



3.0

Precision A Pure+

0

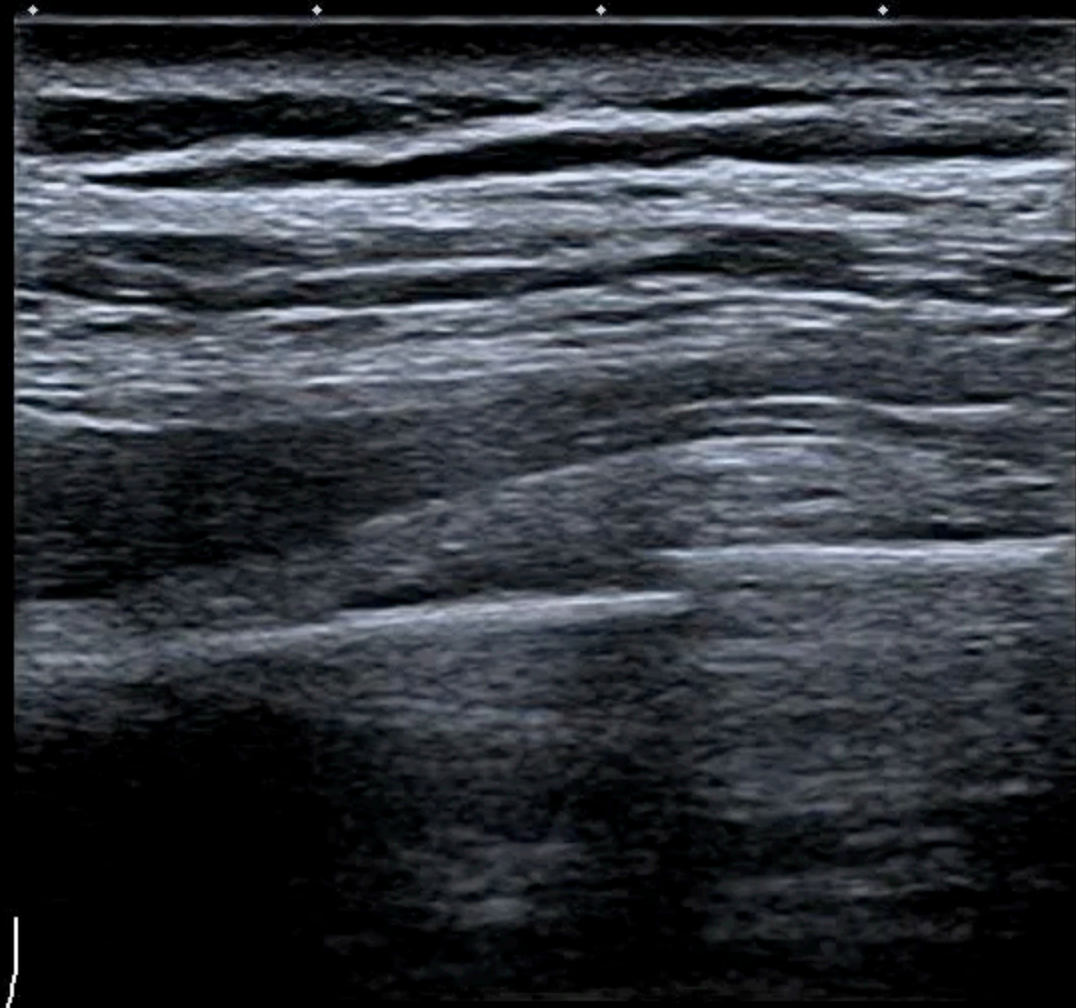
T

1

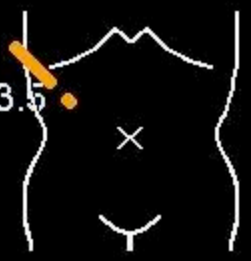2

3

3.5



MI
1.5
11L4
diffT9.0
30 fps
G:83
DR:55
A:6
P:3



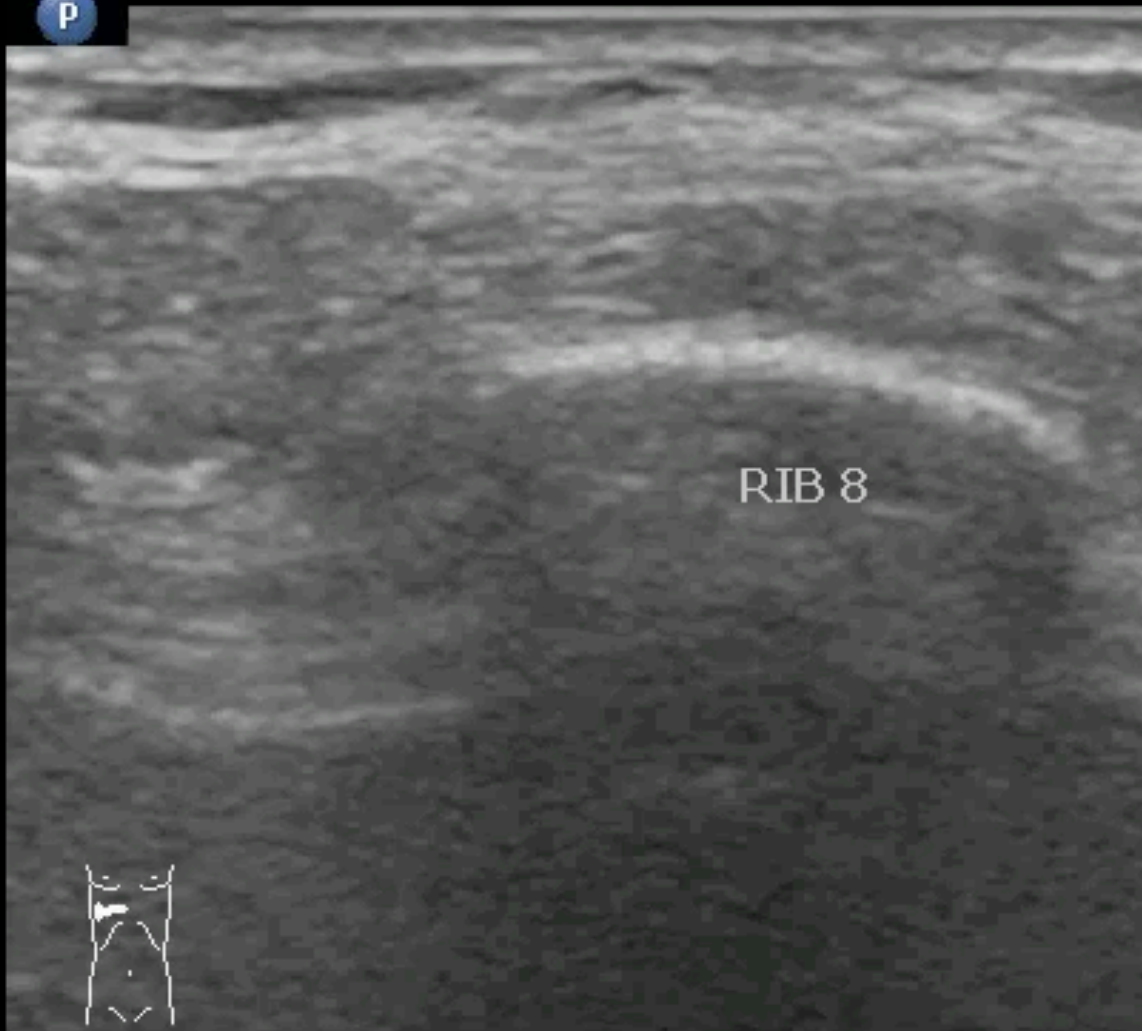100%

SKIN ER

34 Hz
2.0cm

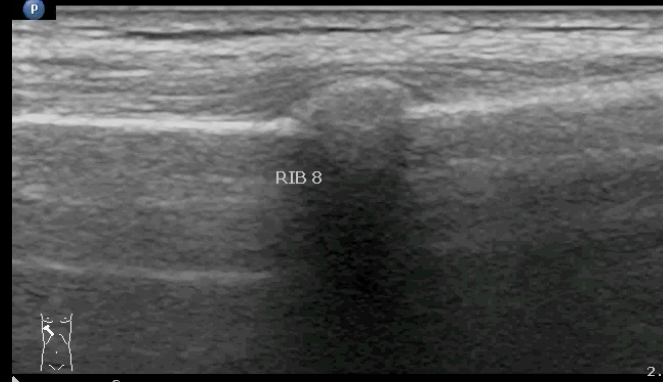2D
Gen
Gn 86
C 53
4/3/2

P



RIB 8

G
P R
3.0 12.0



RIB 8

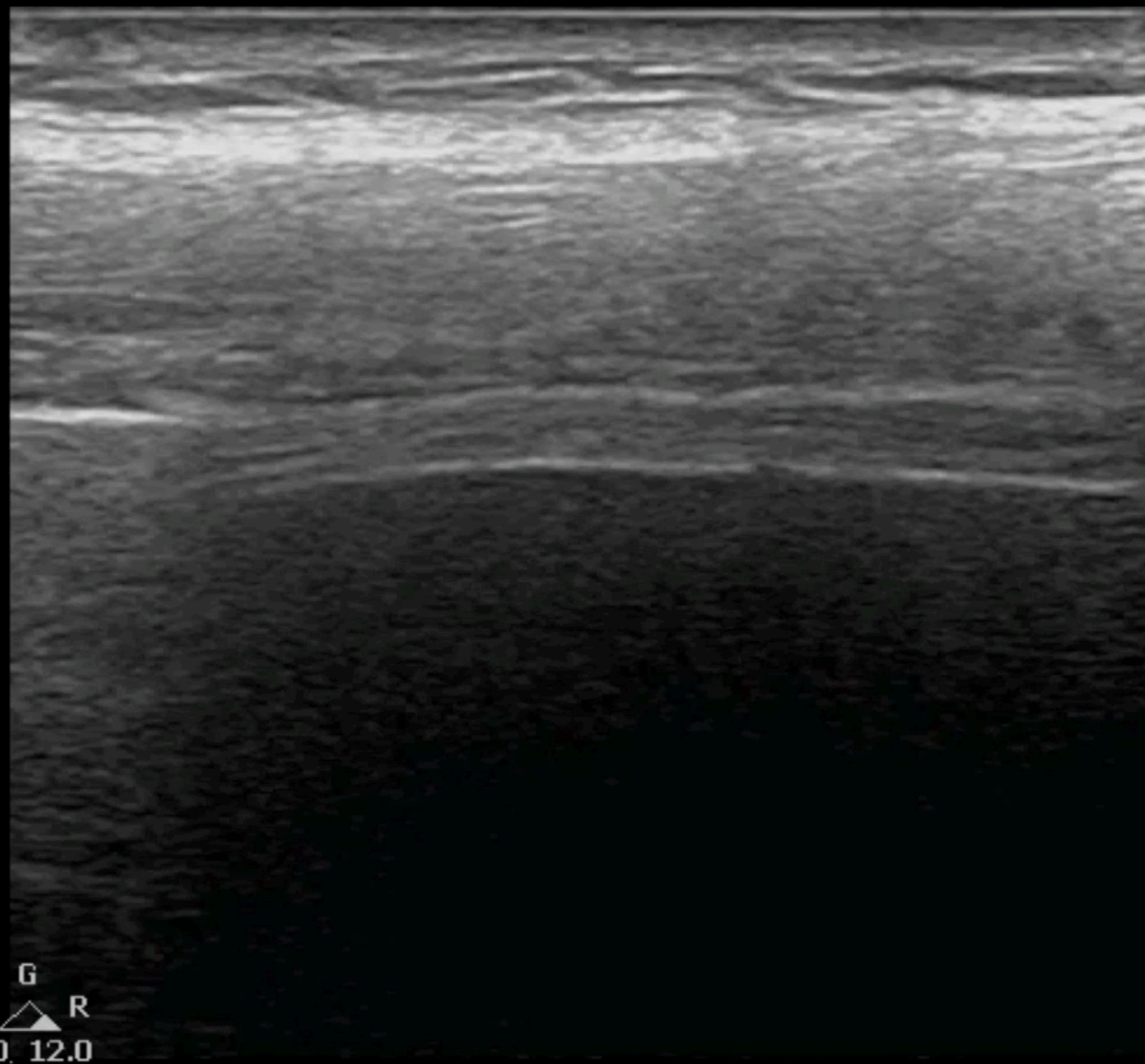
G
P R
3.0 12.0

1
↑
↓

2.0cm

icial

P



1

2



G
P R
3.0 12.0

3.5cm

CES: 5.25 AP 96.6% MI 0.92 TIS 0.6

25/01/18

0
30
0
0



SE
IM

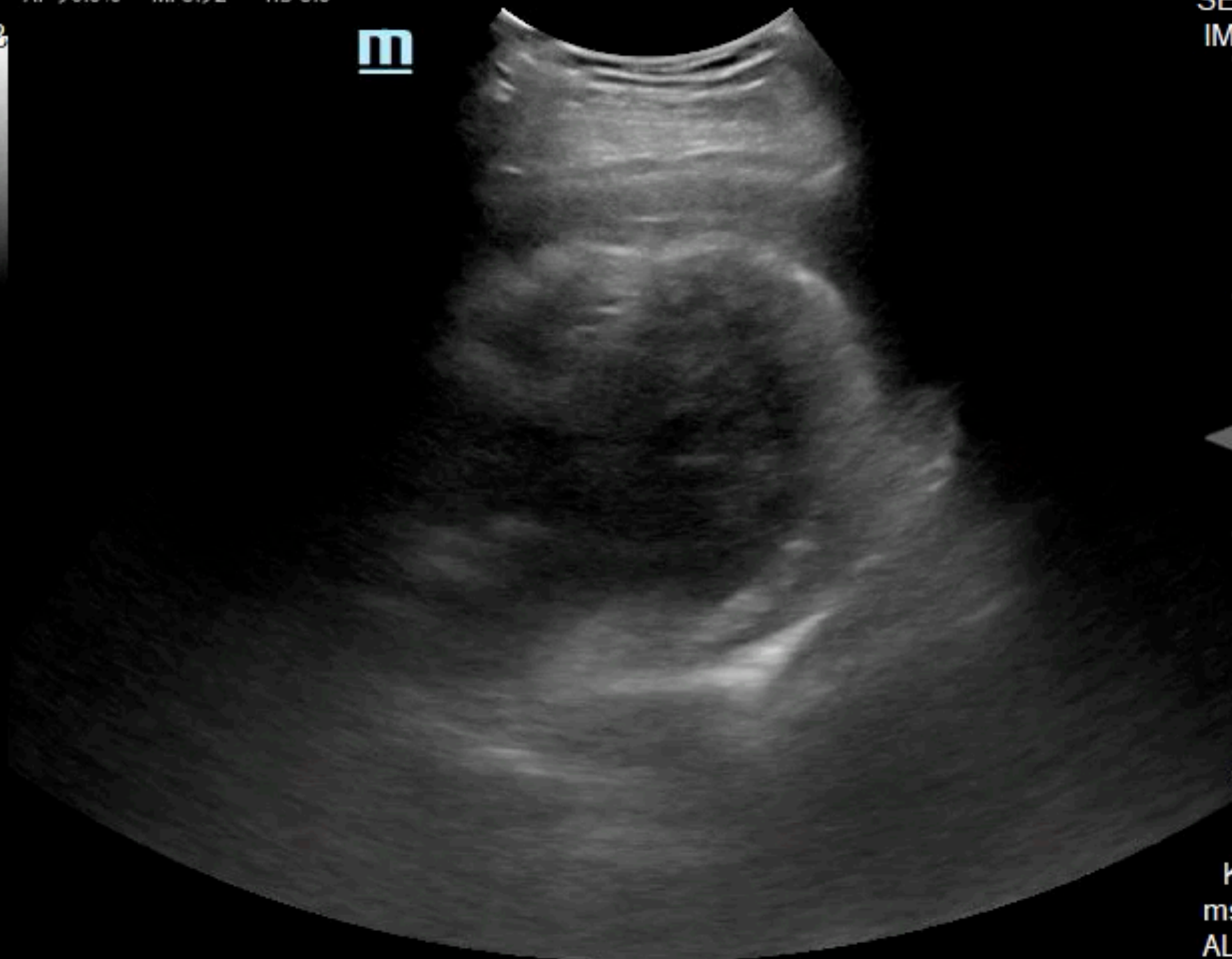
edle

uch

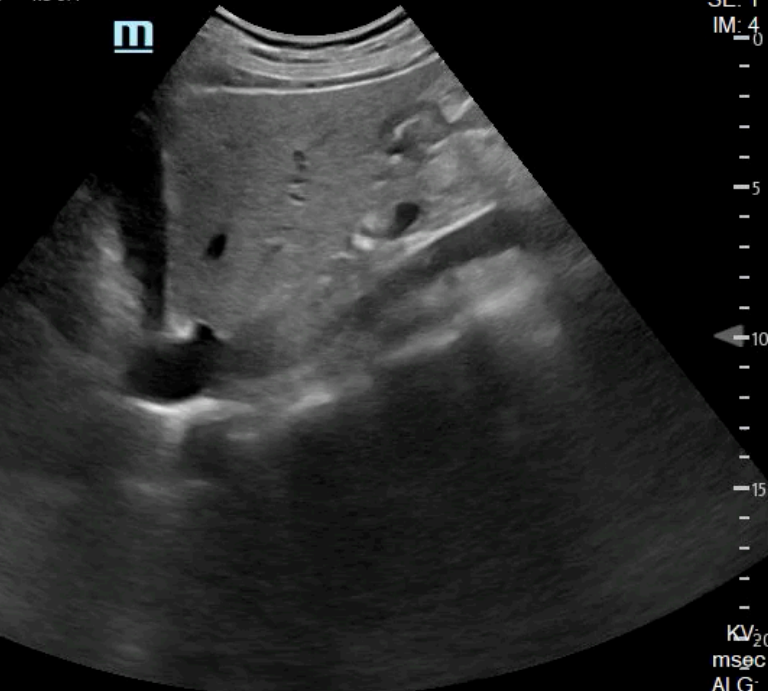
: mm

OV:

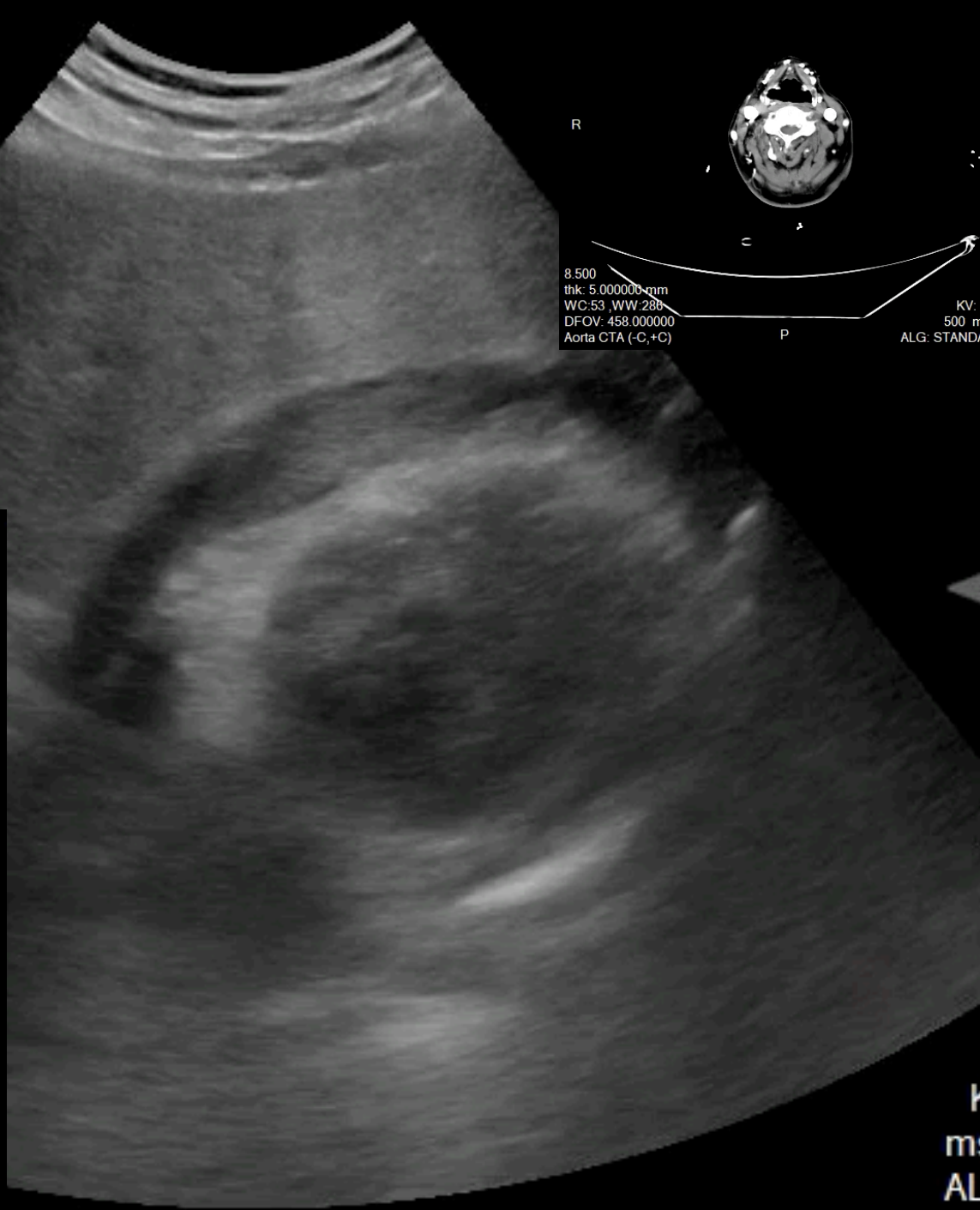
K
ms
AL



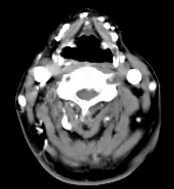
m



SE: 1
IM: 4
0
-5
-10
-15
-20
KV: 20
msec
ALG:



R



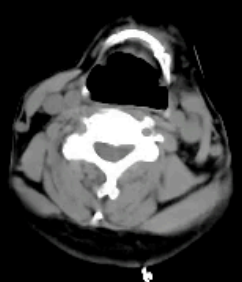
8.500
thk: 5.000000 mm
WC:53 ,WW:286
DFOV: 458.000000
Aorta CTA (-C,+C)

P

KV: 500 m
ALG: STAND

02/07/10
4:50:15

R



L

500
thk: 5.000000 mm
WC:53 ,WW:286
DFOV: 458.000000
Aorta CTA (-C,+C)

P

KV: 120
500 msec
ALG: STANDARD

K
m
AL