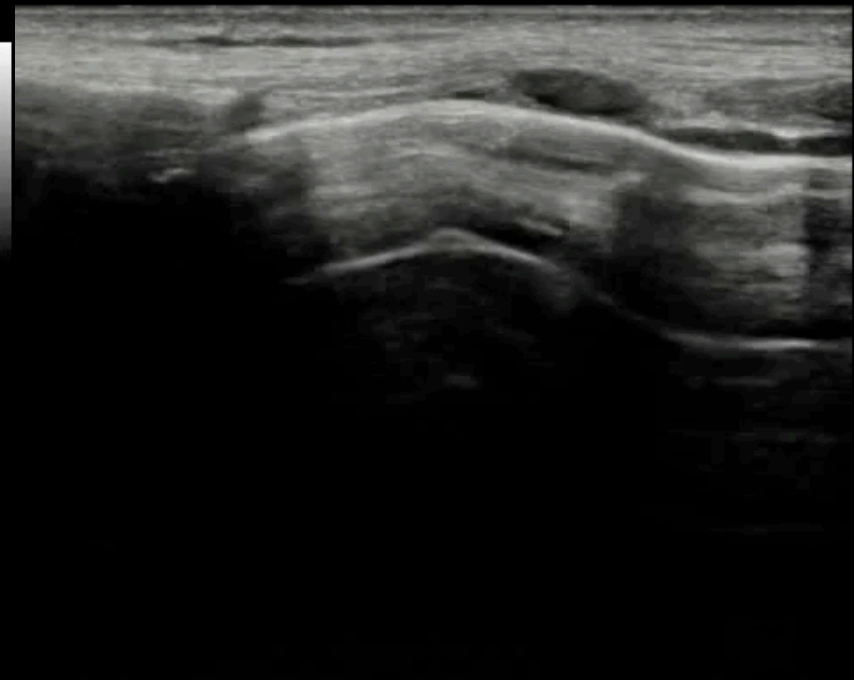
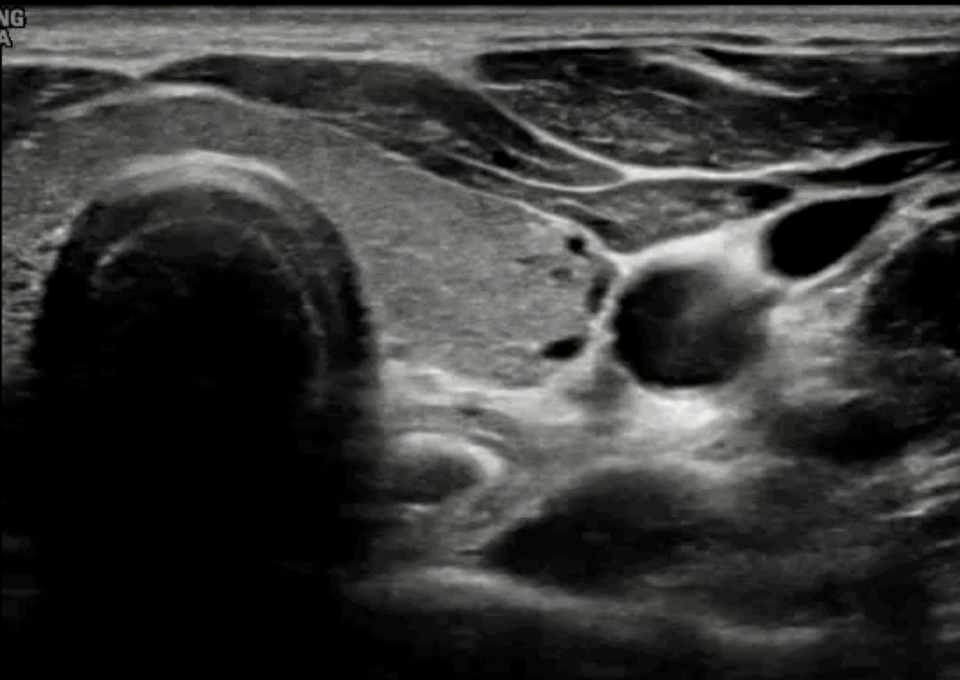
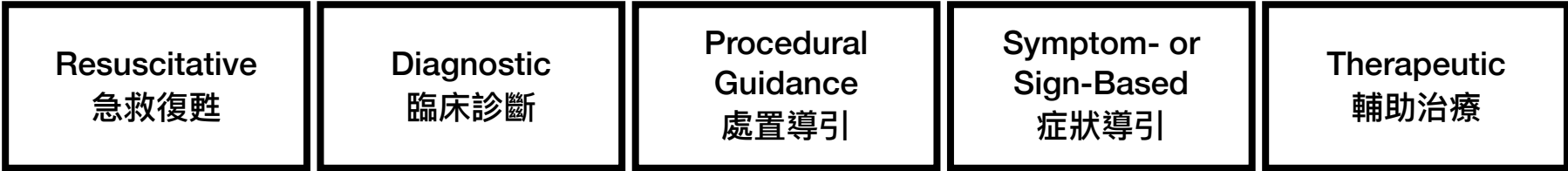POCUS for Airway & Neck

陳國智醫師 雙和醫院急診醫學科

juice119@gmail.com

POCUSacademy.com



Core Applications (2023 ACEP Emergency Ultrasound Guidelines)
15項急診超音波核心應用

陳國智醫師

Aorta

DVT

Trauma

Thoracic/Airway

Cardia/HD assessment

Procedural Guidance

US-guided NB

Testicular

Ocular

Skin & Soft tissue

Hepatobiliary

Urinary tract

Pregnancy

Bowel

MSK

SONOANATOMY CHECK LIST

Airway	Neck
Hyoid bone	Parotid gland
Epiglottis	Submandibular gland
Thyroid cartilage	Thyroid gland
Cricothyroid membrane	Tongue & Tonsil
Cricoid cartilage	CCA / IJV / VA
Tracheal cartilage	SCM / ASM / MSM
Cervical esophagus	Mandible / Mastoid / Vertebral body & TP

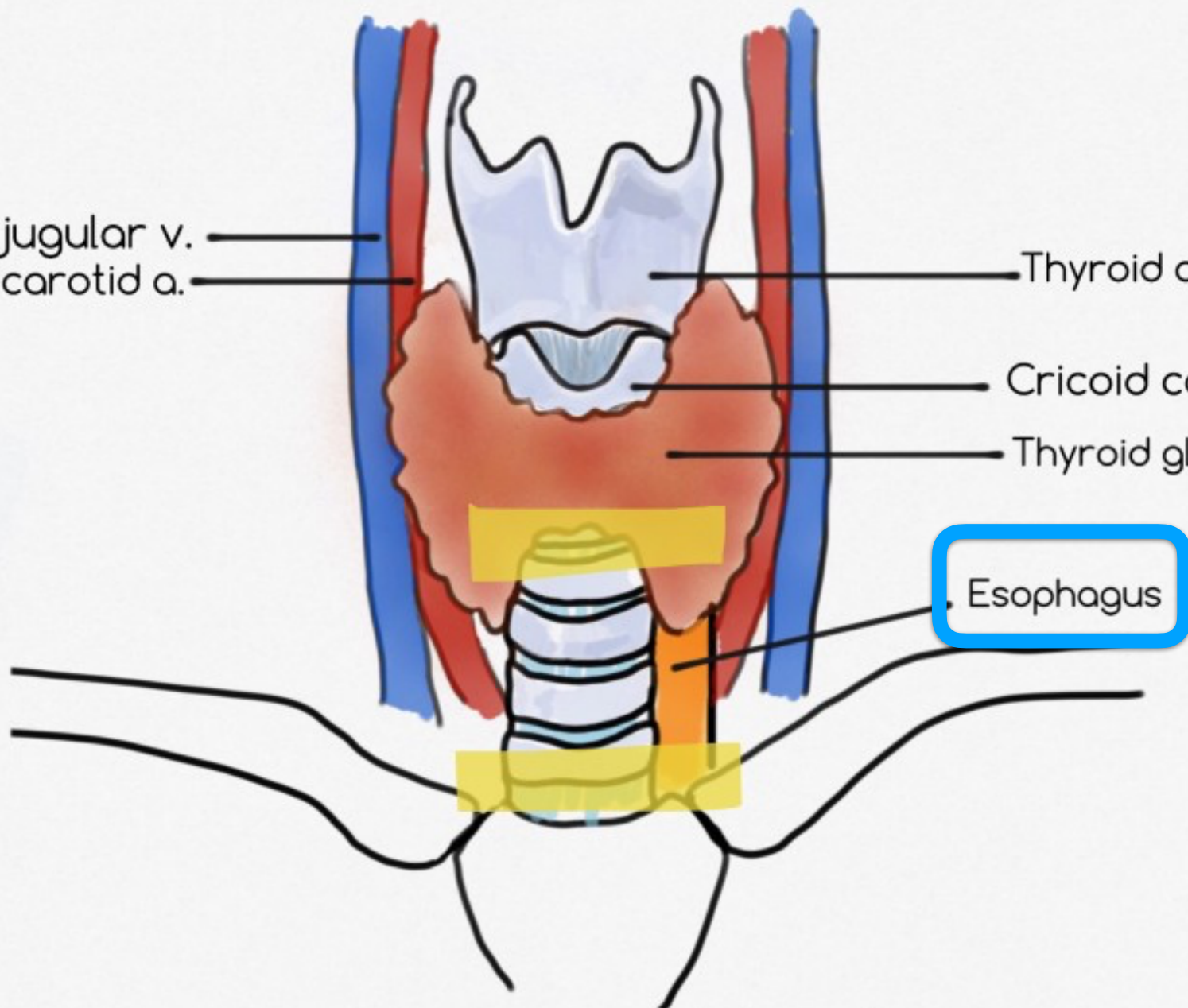
Internal jugular v.
Common carotid a.

Thyroid cartilage

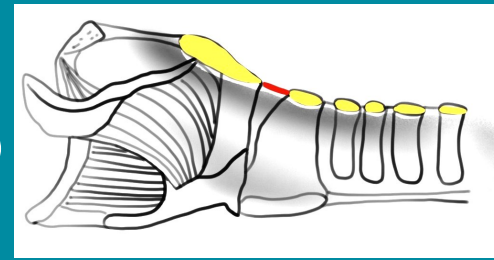
Cricoid cartilage

Thyroid gland

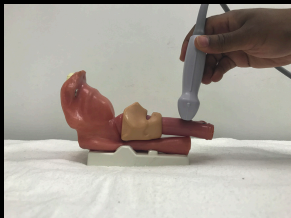
Esophagus



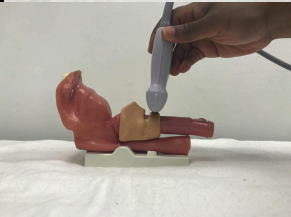
AIRWAY POCUS



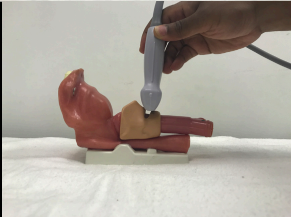
1



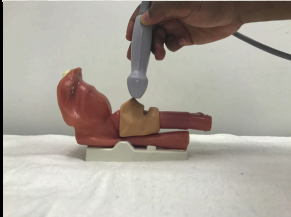
2



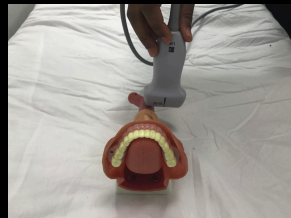
3




4



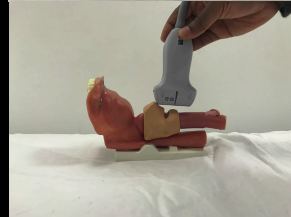
5



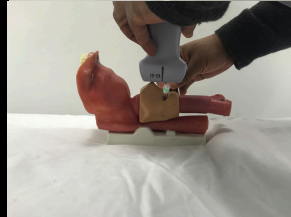
6



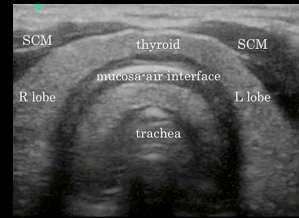
7



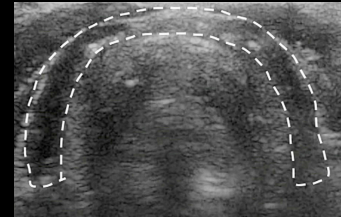
8



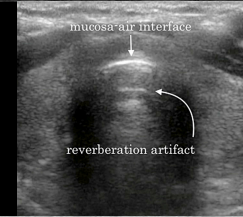
B



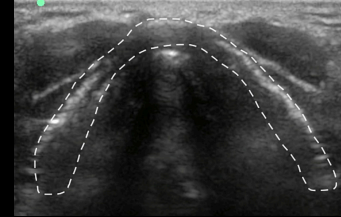
G



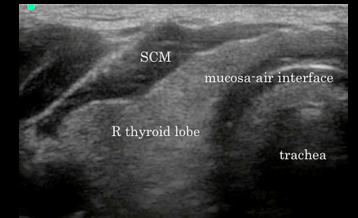
D



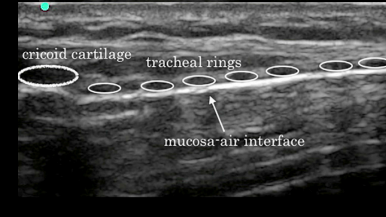
E



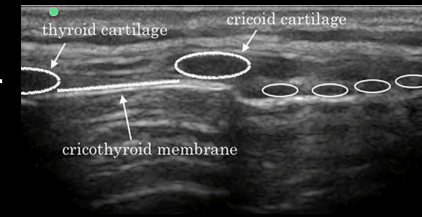
H



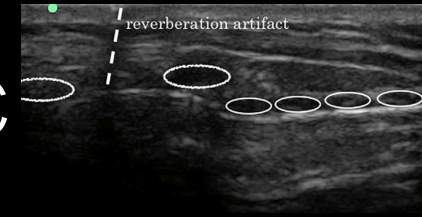
A

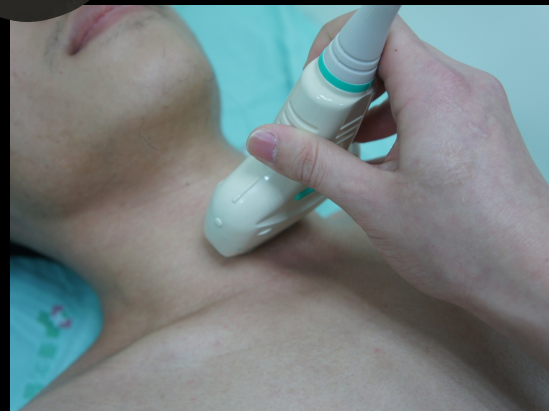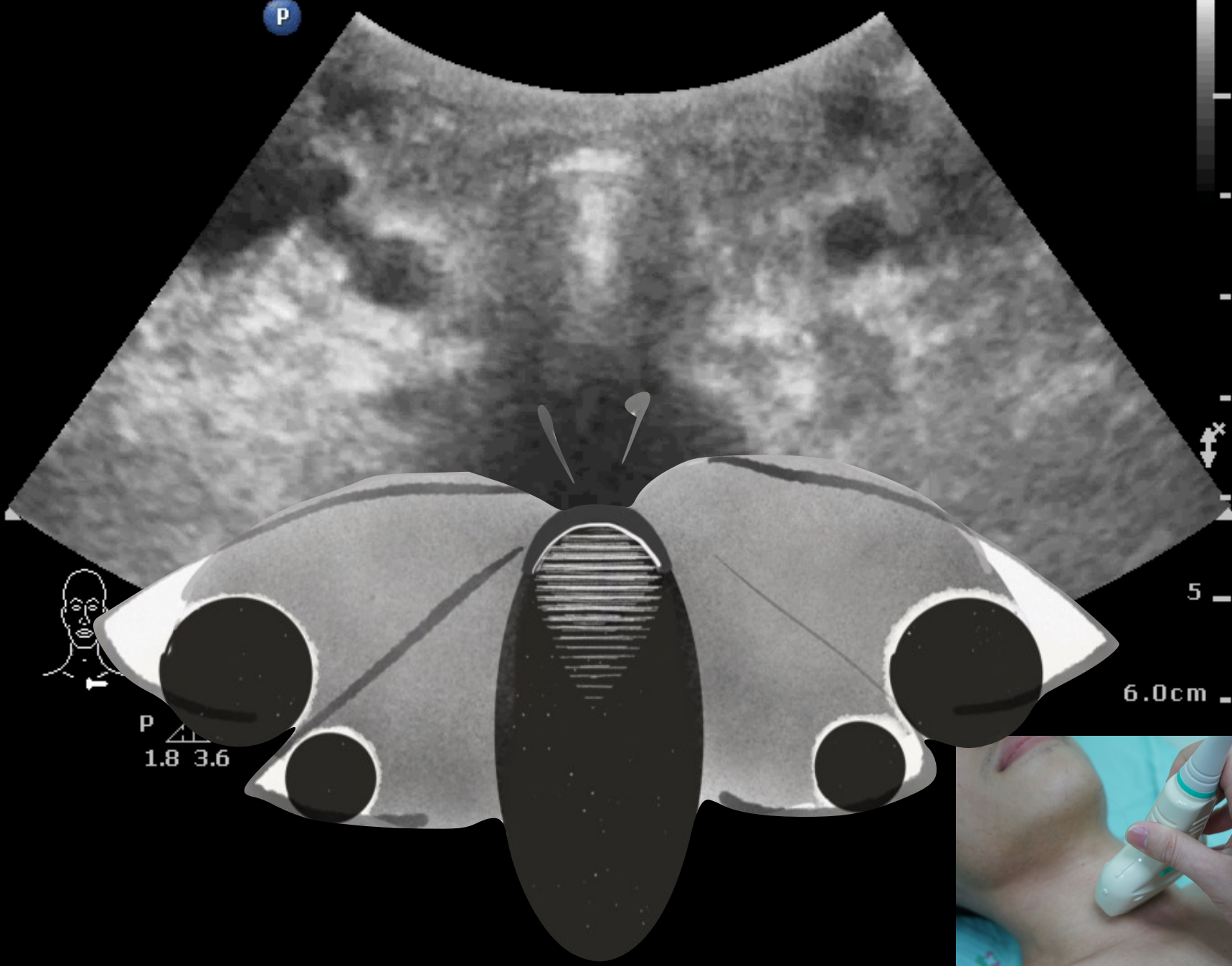


F

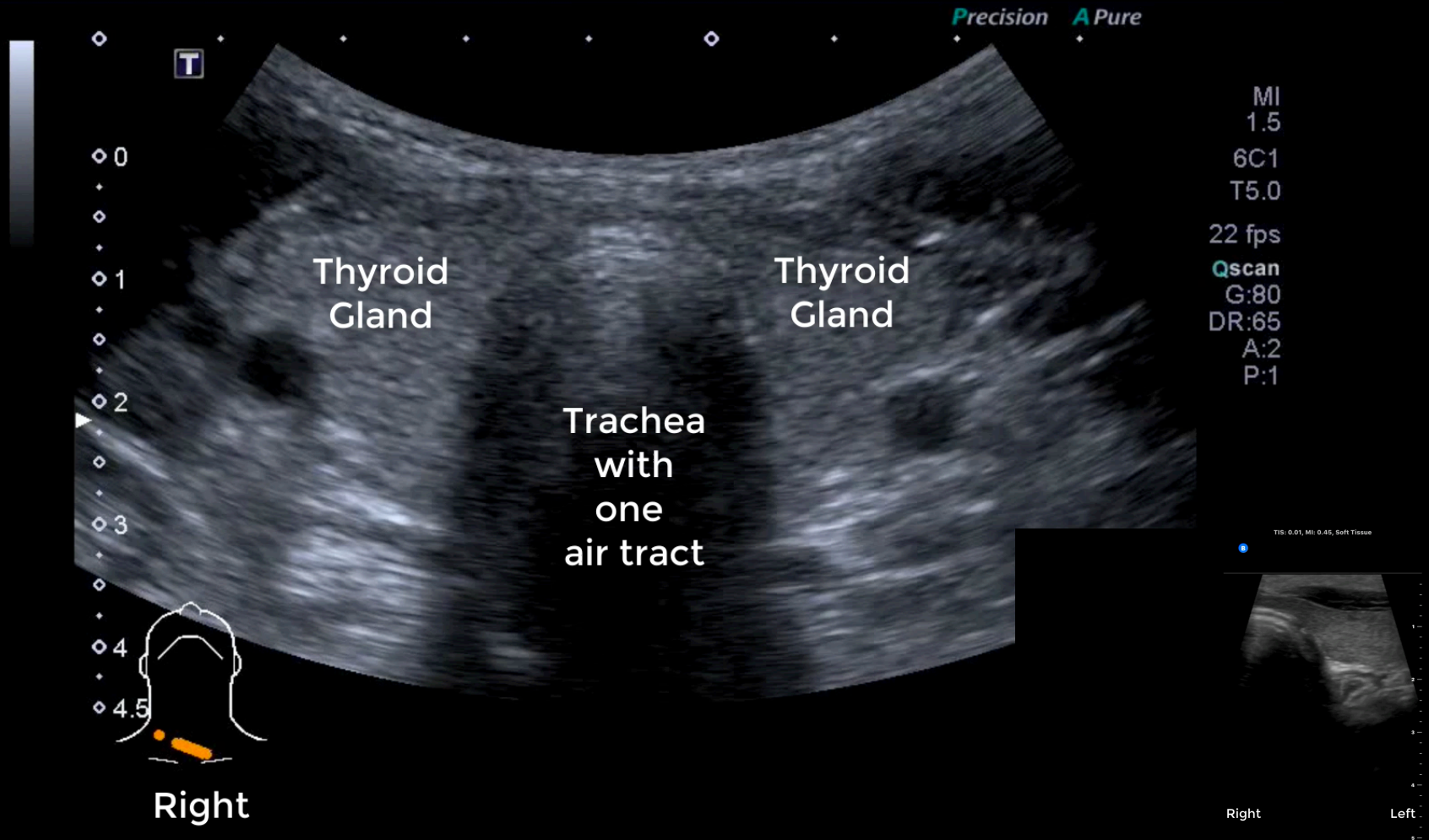


C

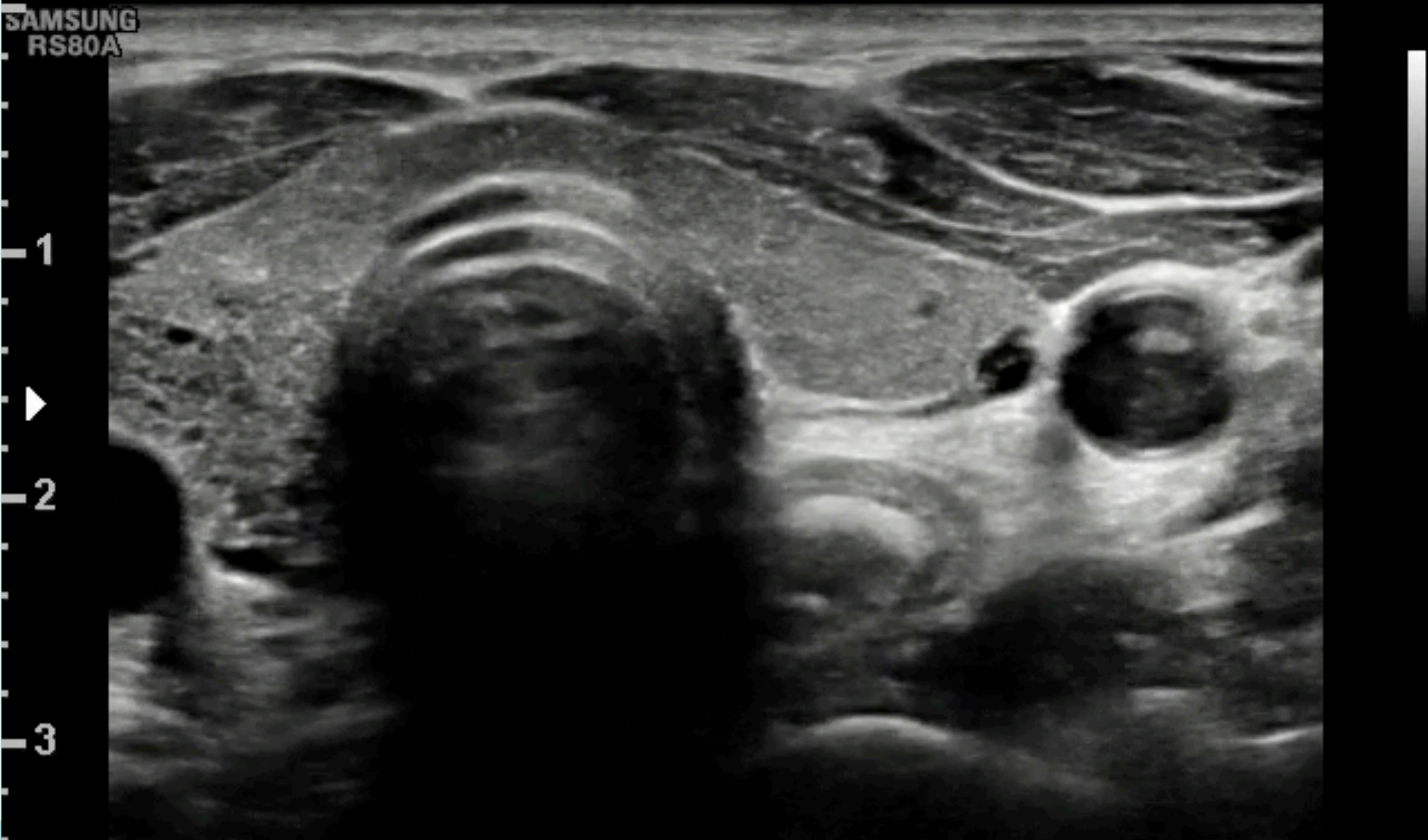




AIRWAY (ONE TRACT)



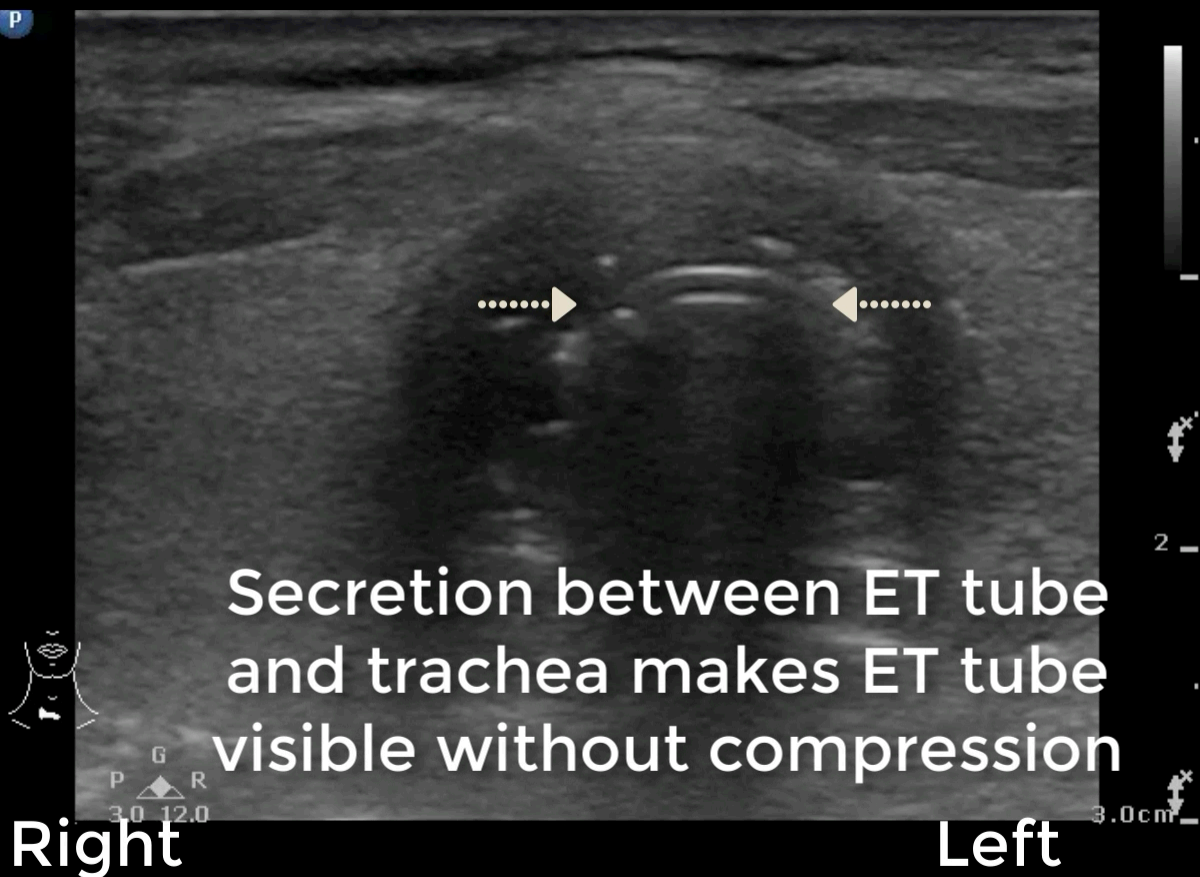
AIRWAY & ESOPHAGUS



AIRWAY (ONE TRACT)

Superficial P
L12-3
31 Hz
3.0cm

2D
Gen
Gn 100
C 52
4/3/2



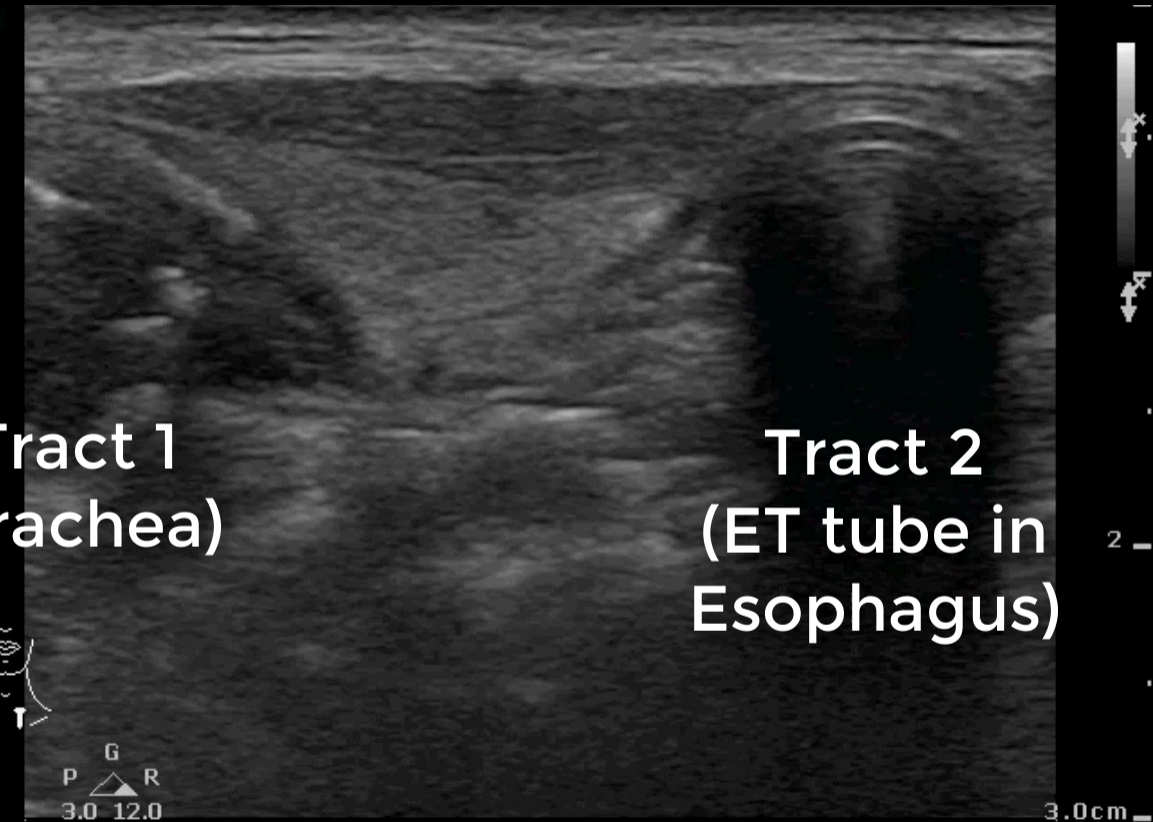
ESO INTUBATION (2 TRACTS)

Superficial P
L12-3
46 Hz
3.0cm

2D
Res
Gn 60
C 56
3/2/1

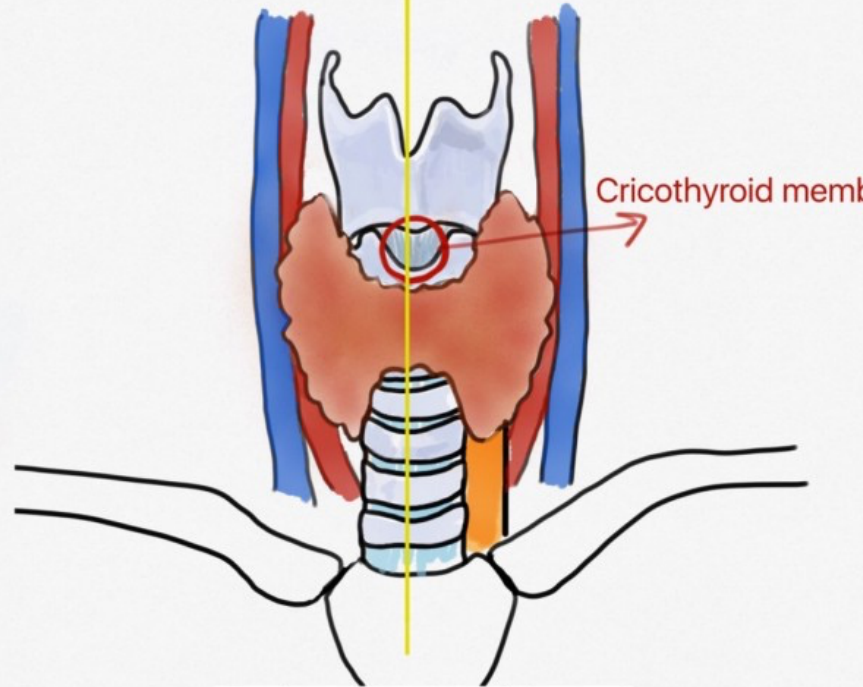
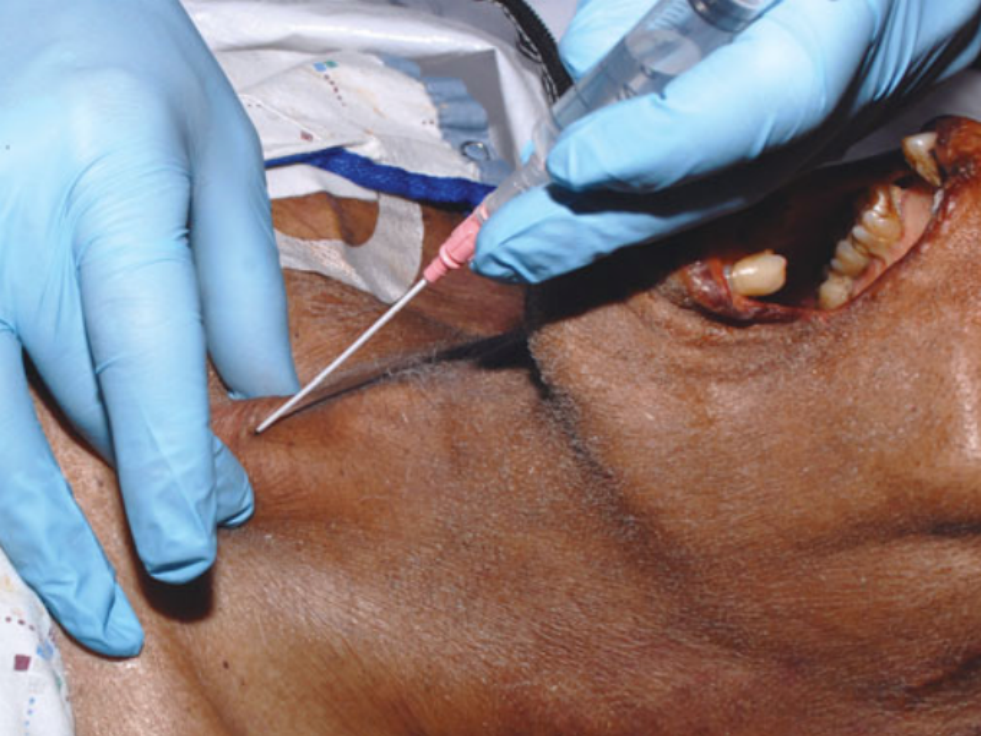Tract 1
(Trachea)

Tract 2
(ET tube in
Esophagus)

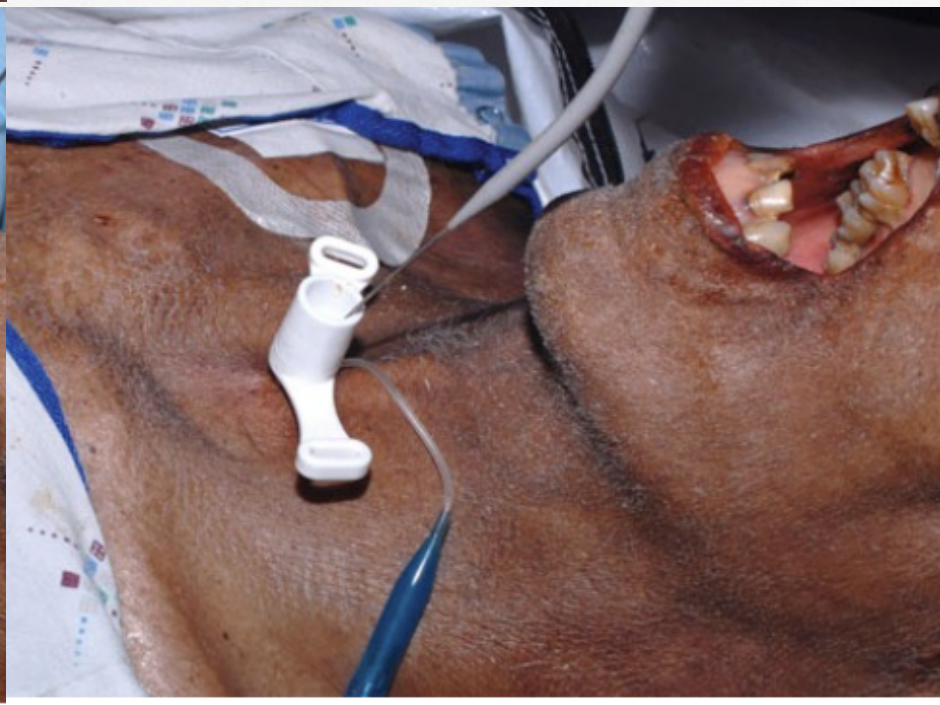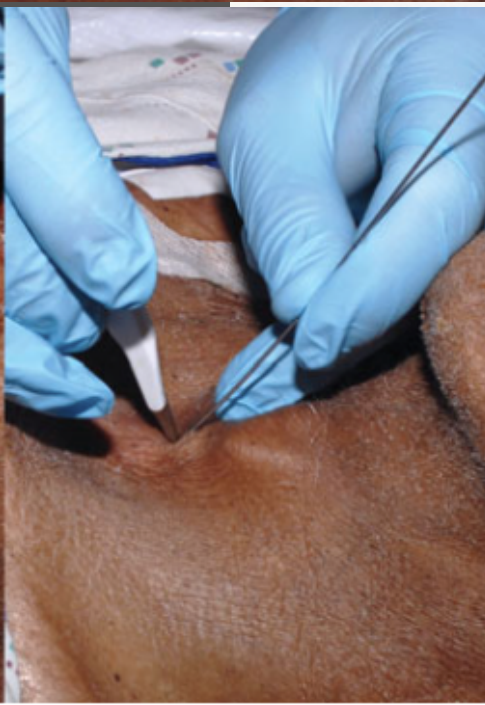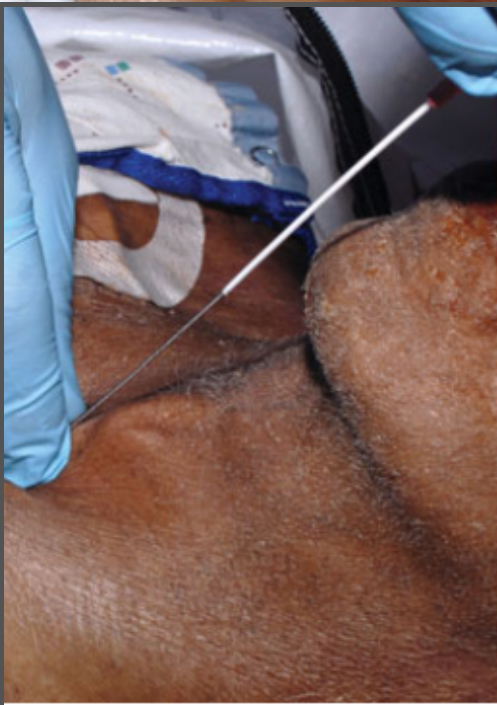


Right

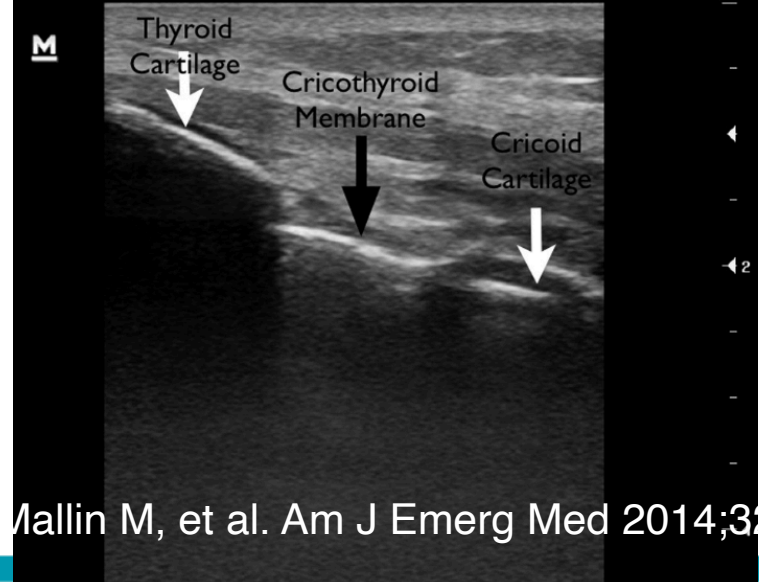
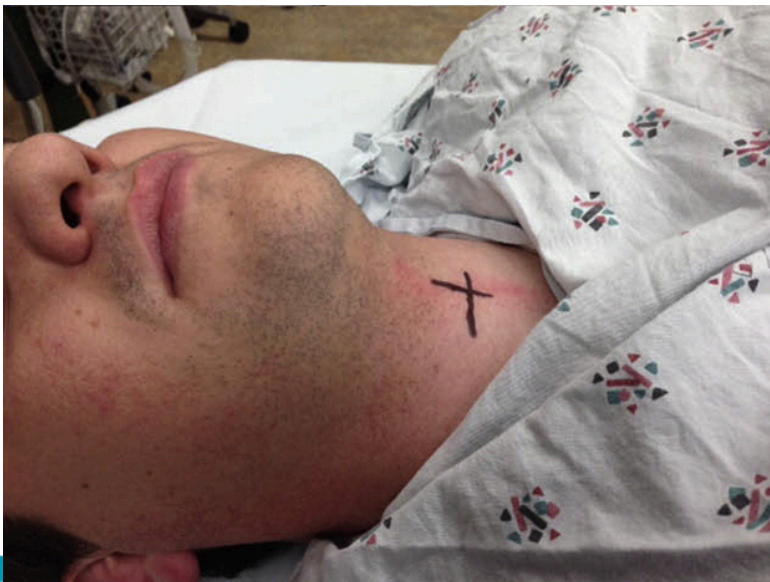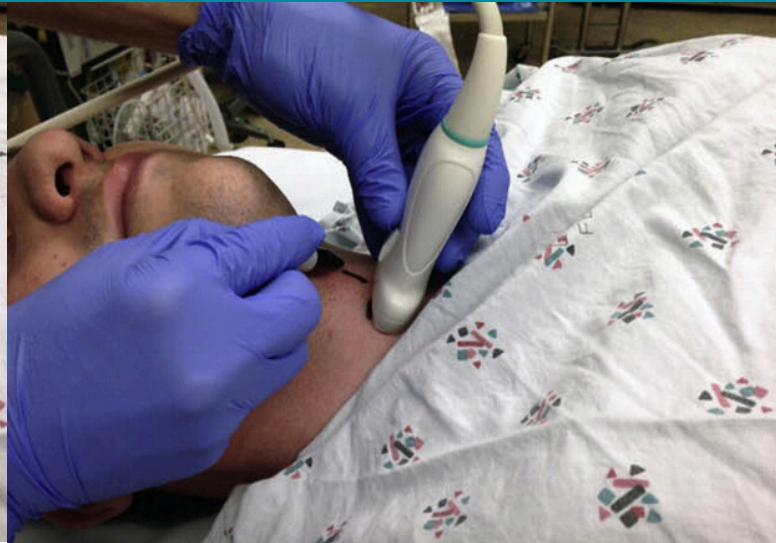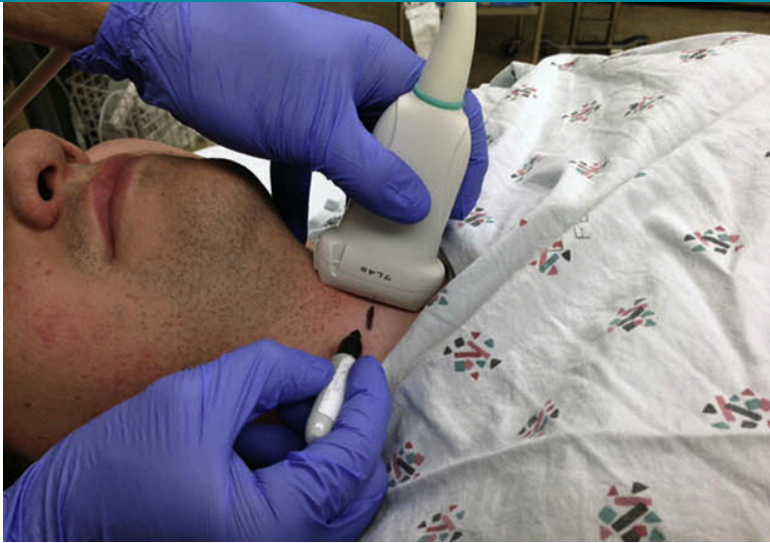Left



Copyright © 2016 HSU CHE CHANG. All rights reserved

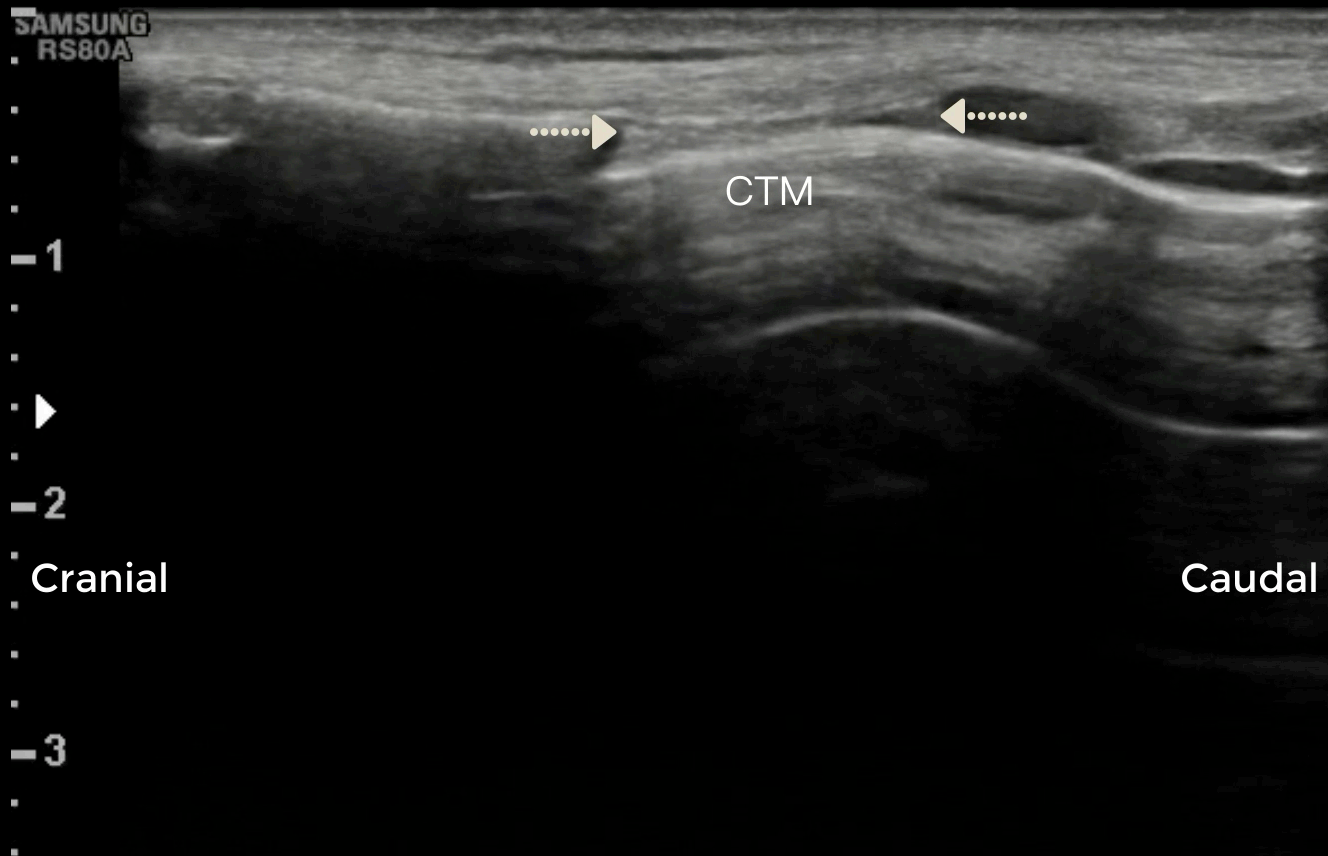


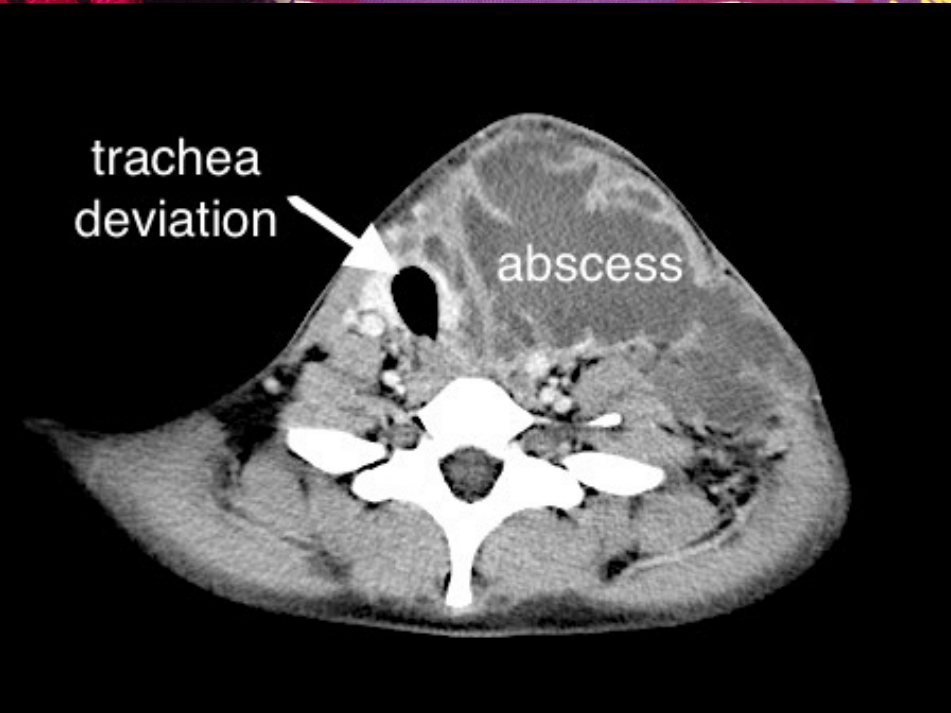
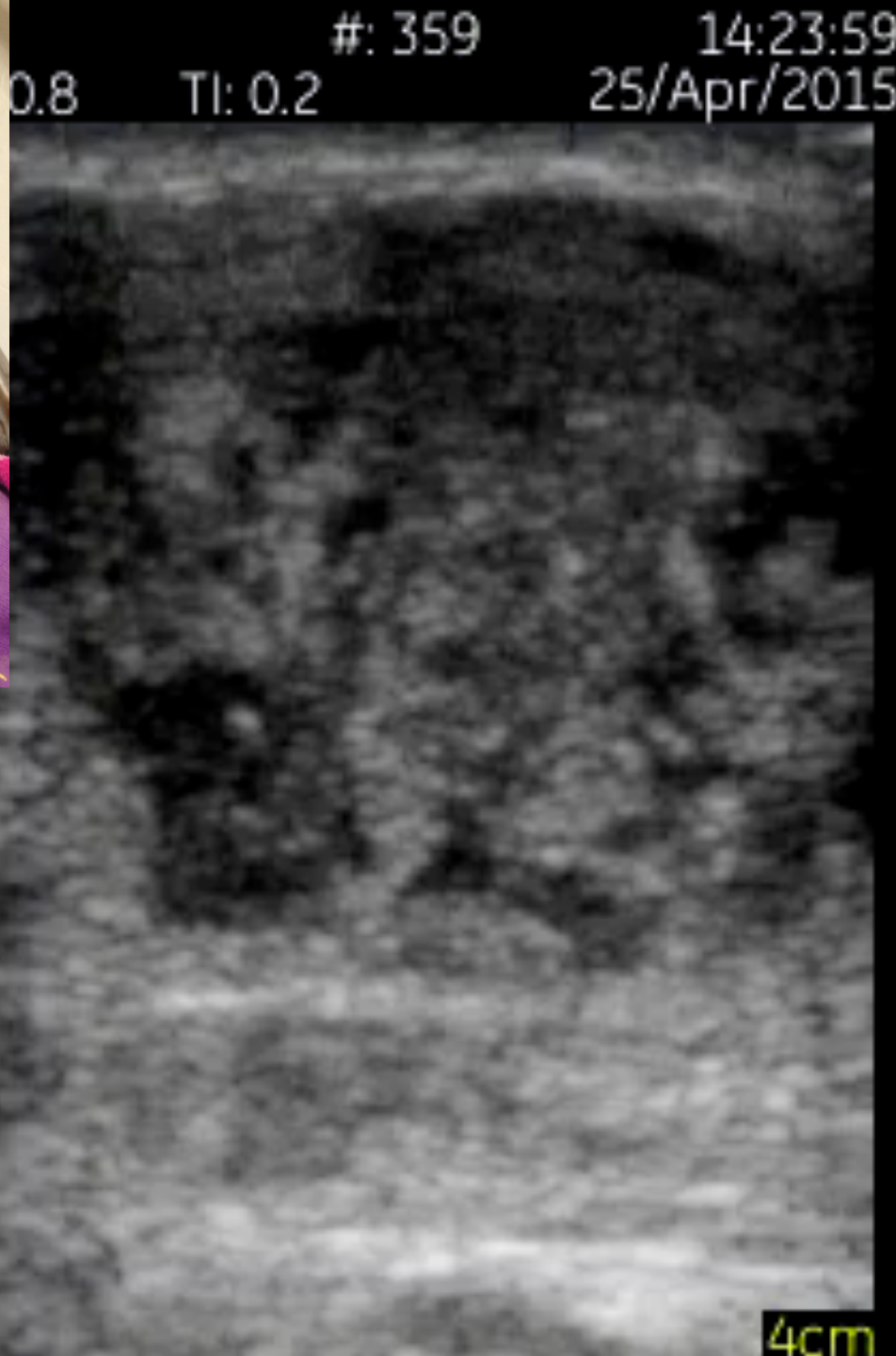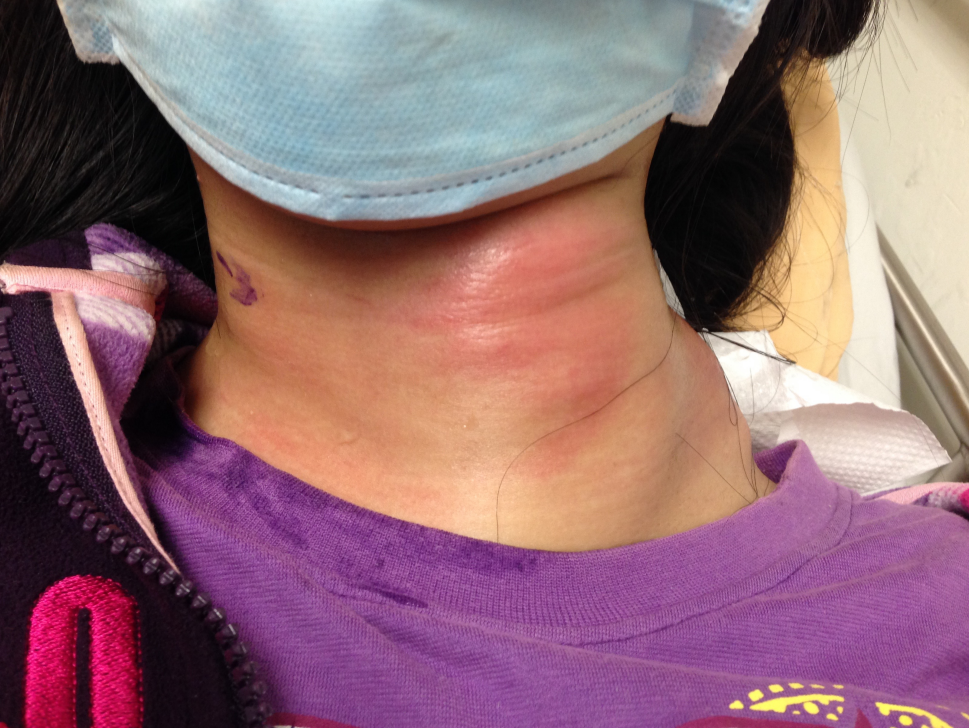CTM LOCALIZATION PRIOR TO INTUBATION



AIRWAY & CTM

L3-12A / SmallParts / FPS40 / MI0.96 / TI0.1 / 01-09-2016 10:32:09 AM
2D G53/DR58/FA4/P90/2.7/Frq Pen./3.5cm

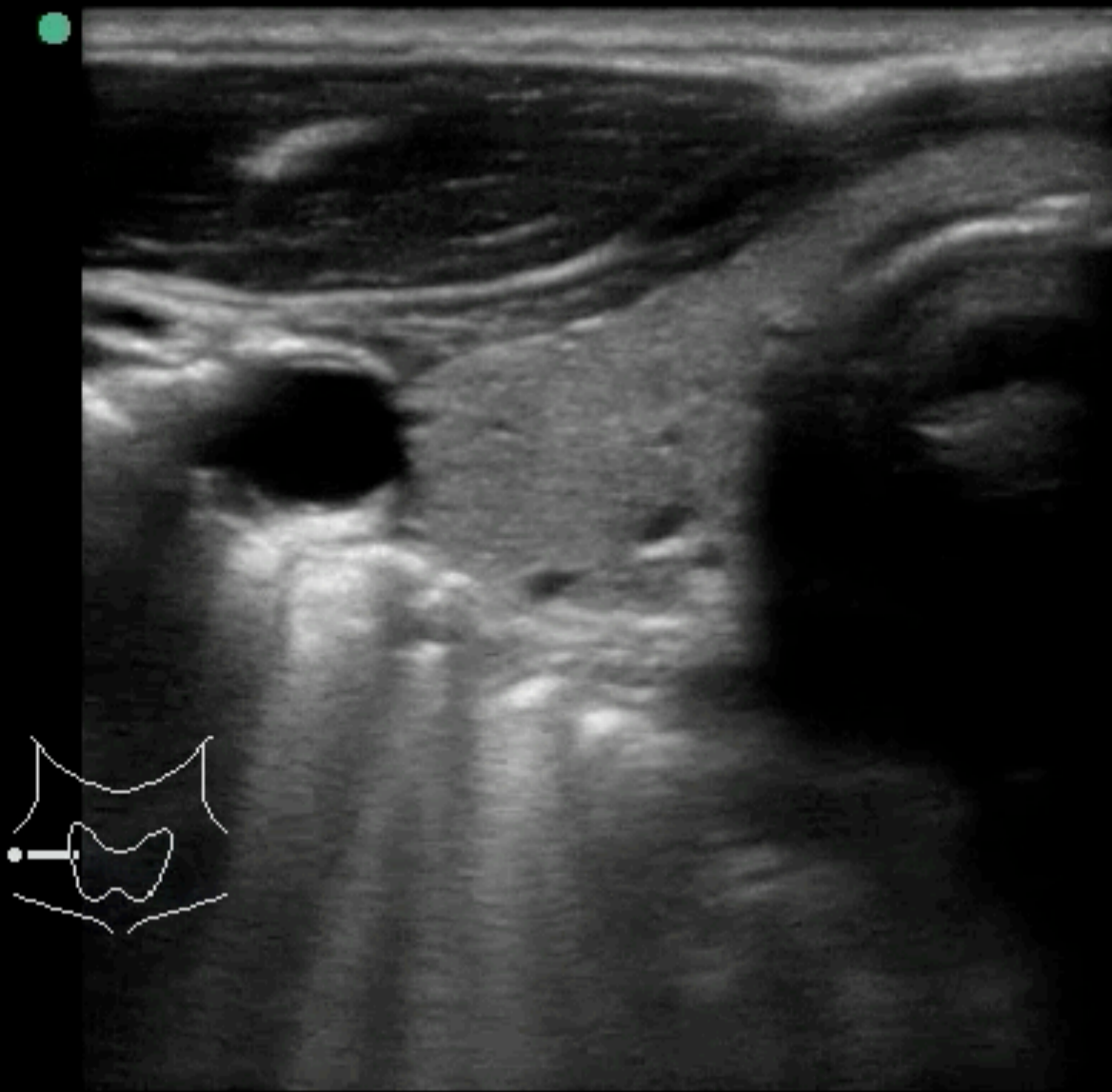




4cm

Subcutaneous emphysema

Gen
S MB



SmP
HFL



40%

MI

0.7

TIS

0.1

A

B

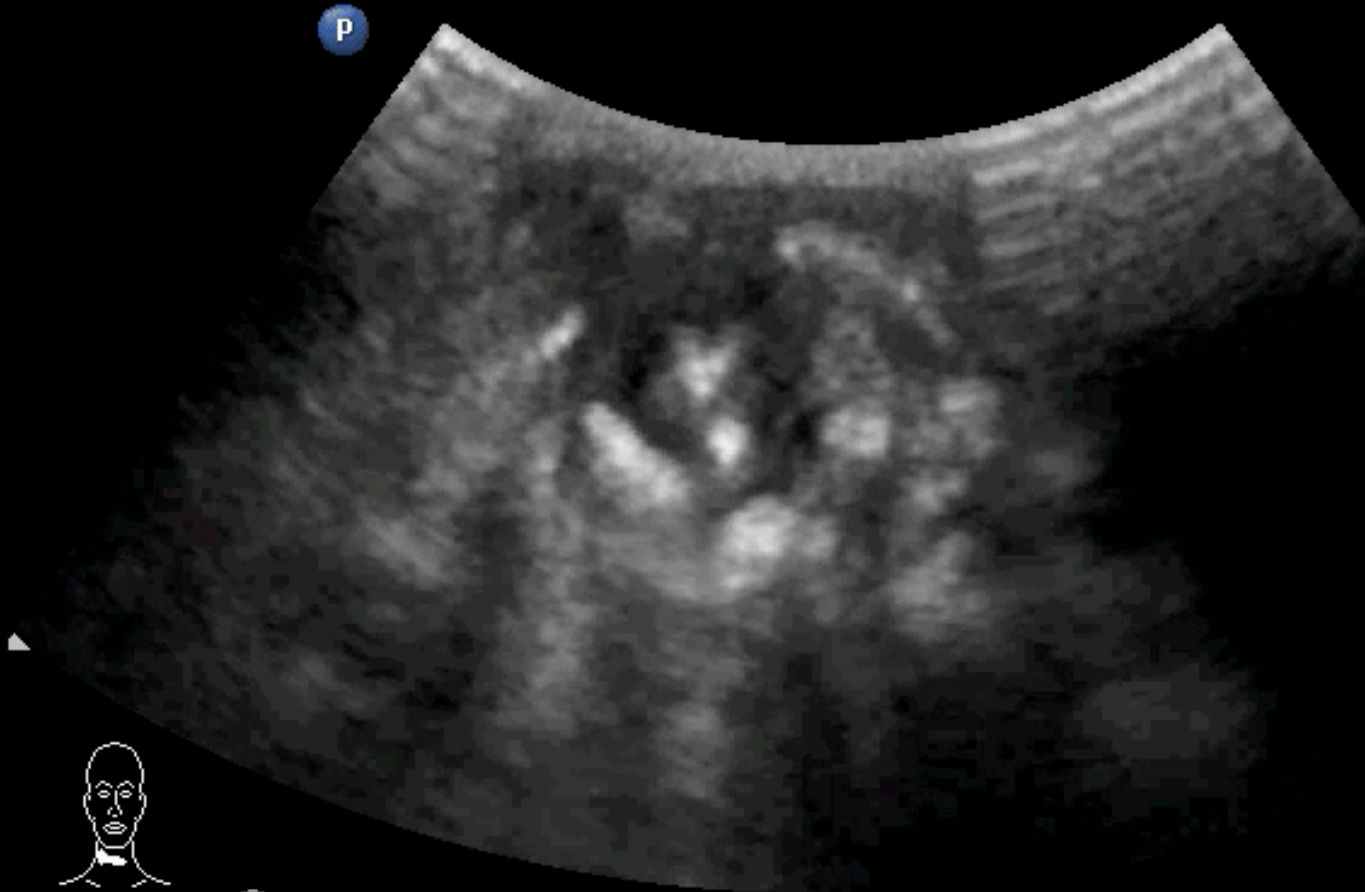

4.0

Stridor & dyspnea

Abd Gen
C5-1
64 Hz
5.0cm

2D
HGen
Gn 90
C 56
3/3/3



G
P R
1.8 3.6

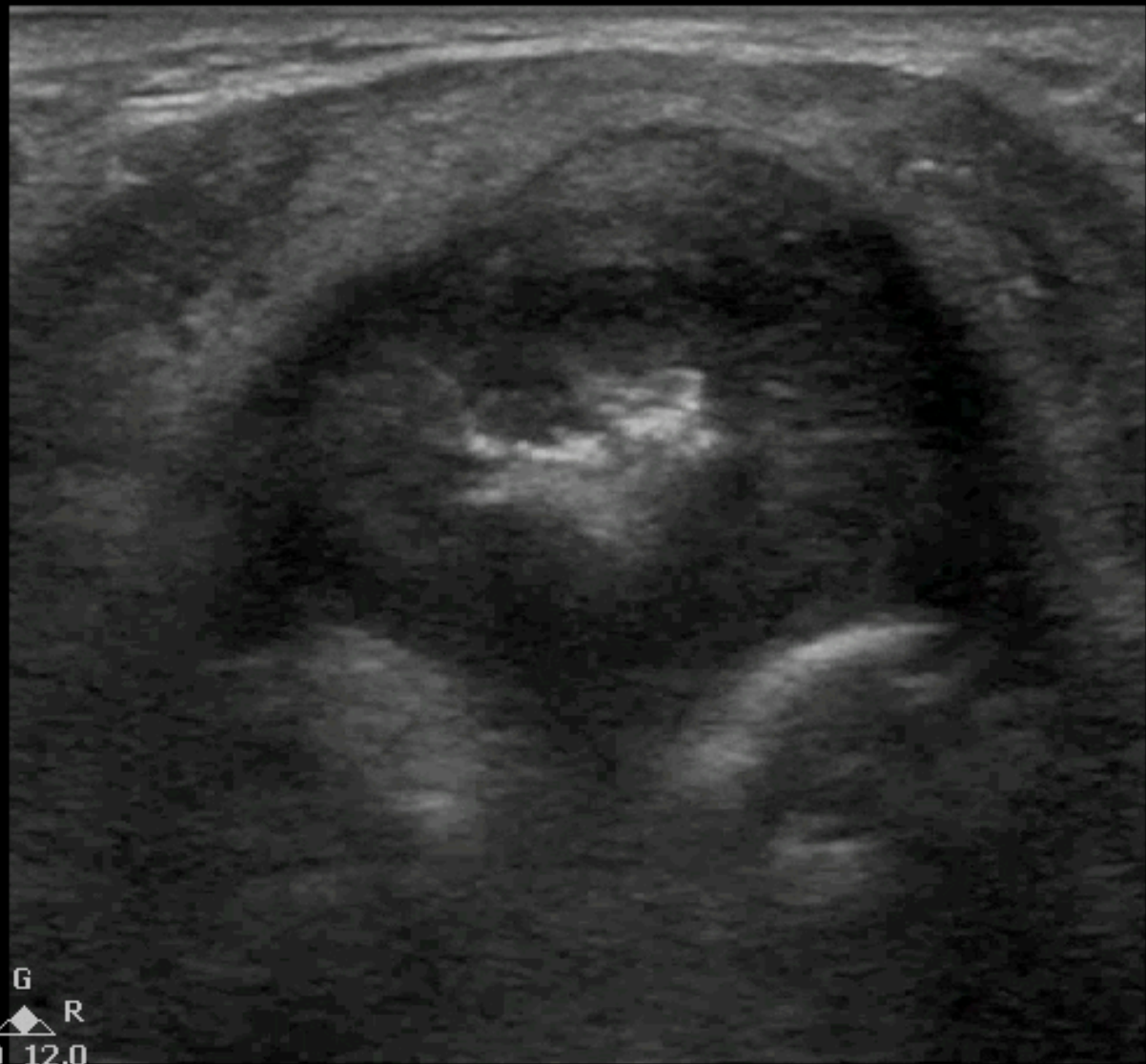
5.0cm

Laryngeal tumor

Superficial
L12-3
31 Hz
3.5cm

P

2D
Gen
Gn 93
C 52
4/3/2



G
P R
3.0 12.0

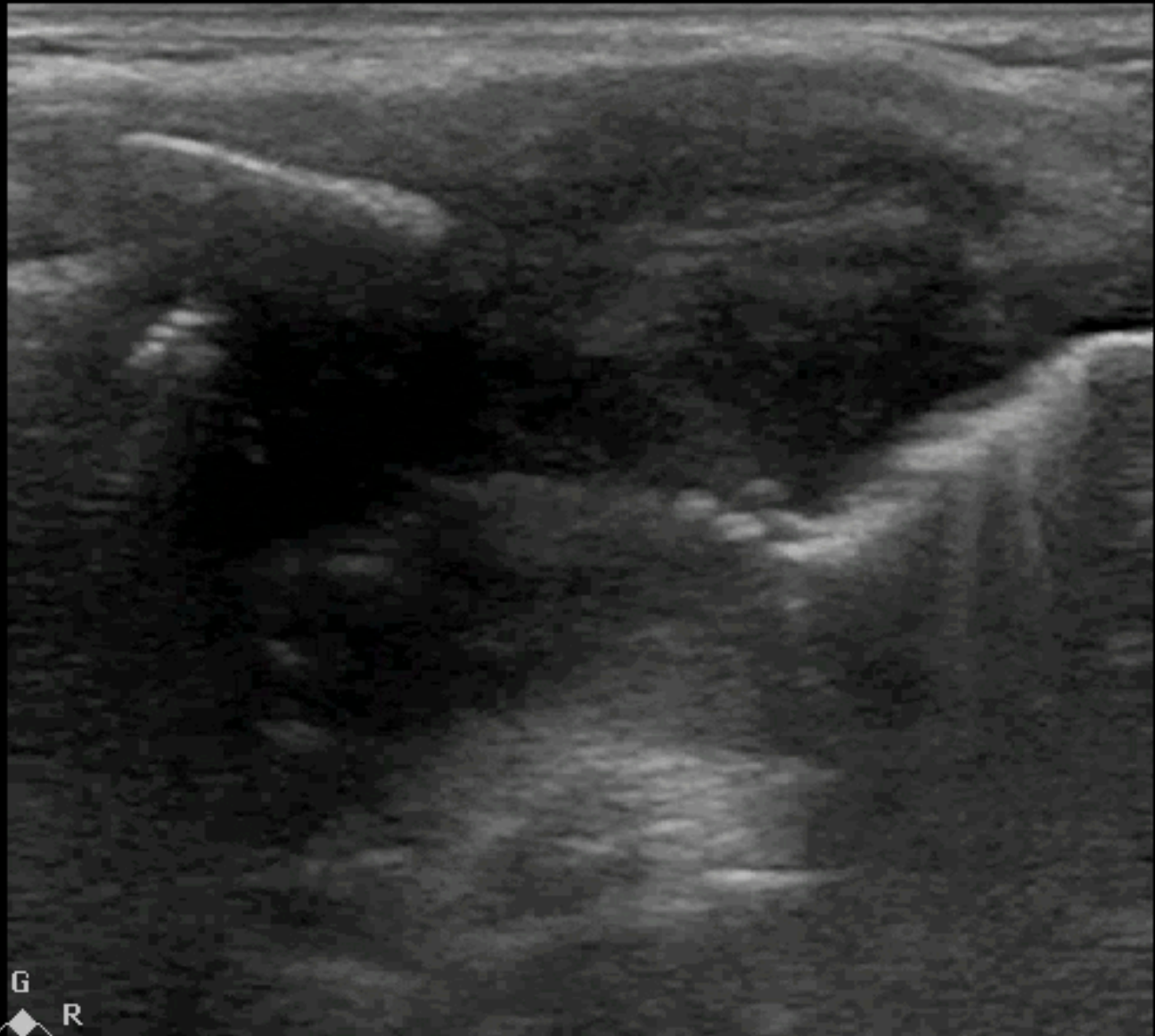
3.5cm

Cricothyroidotomy ?

Superficial
-3
Hz
5cm

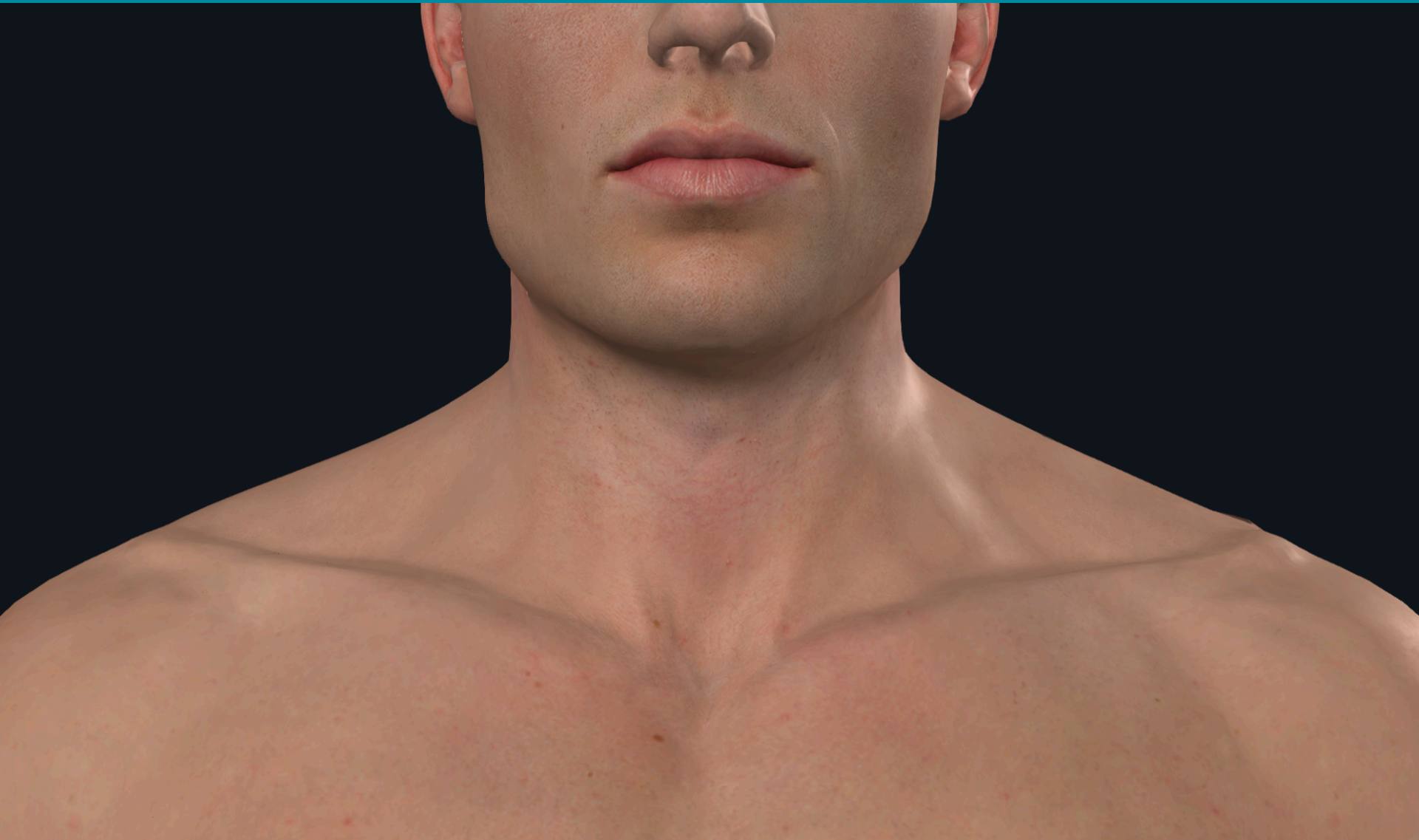P

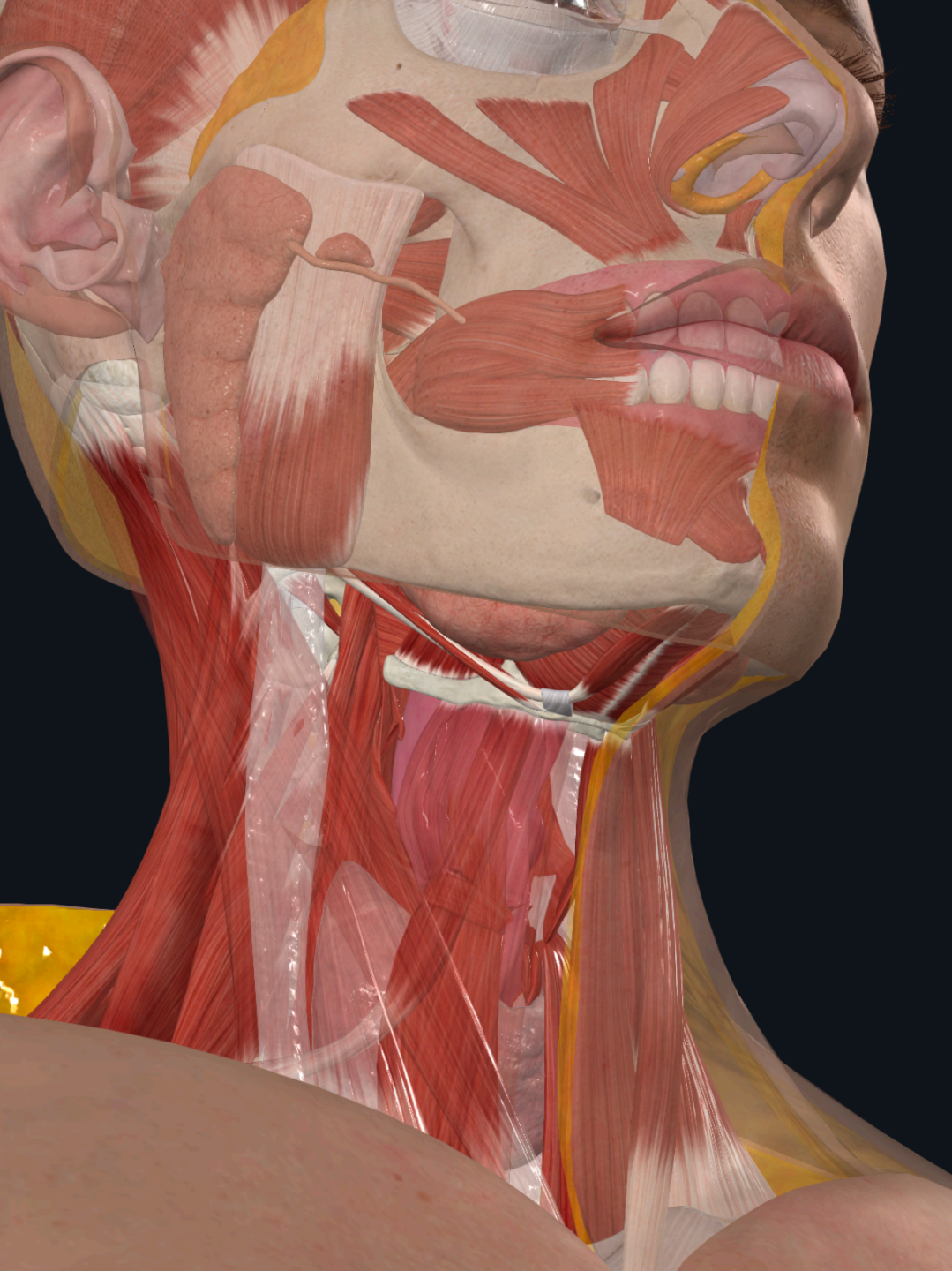n
93
52
3/2



P G R

AIRWAY & NECK POCUS IN ER



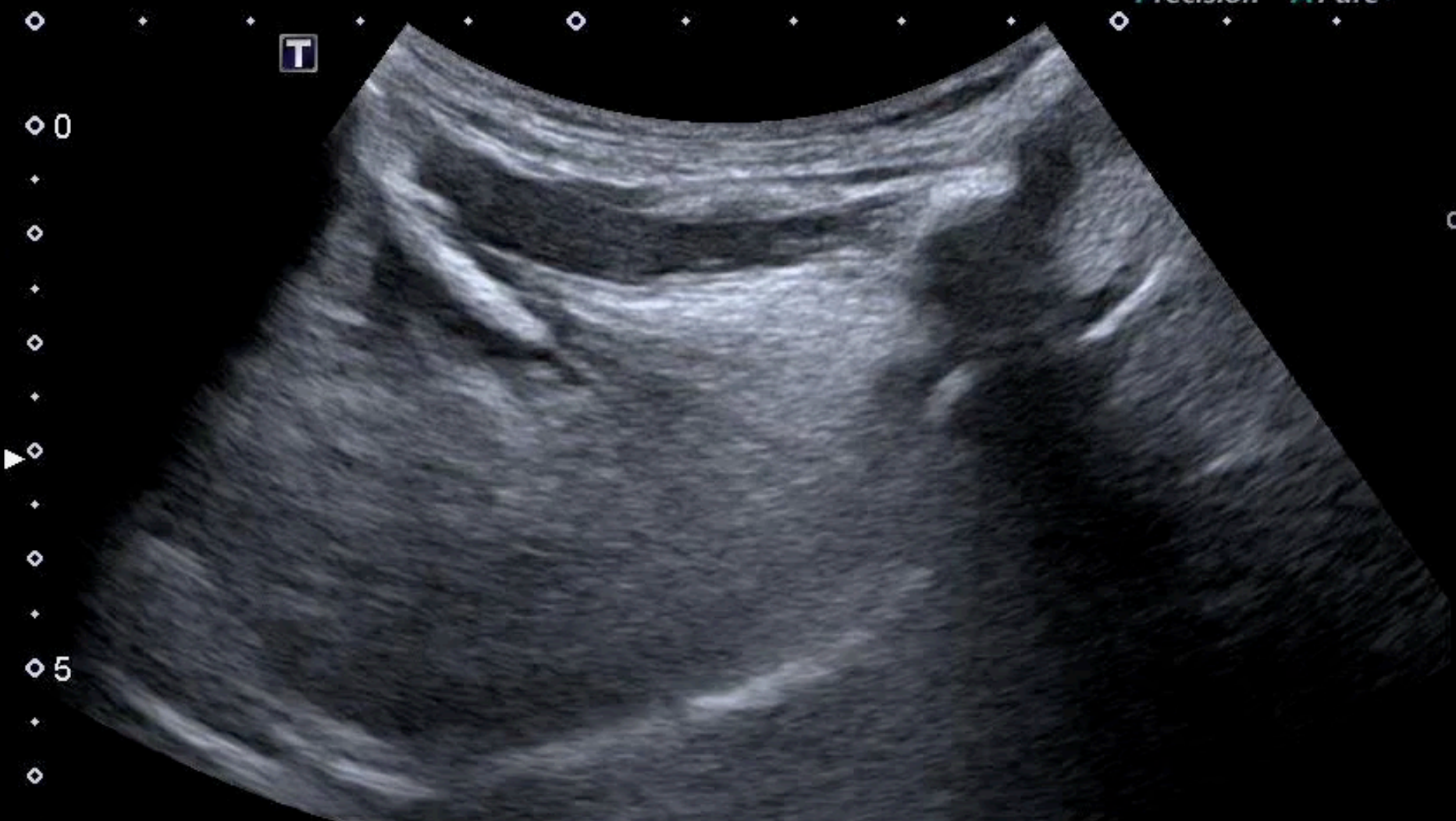


1 Epiglottis

2 Tonsils

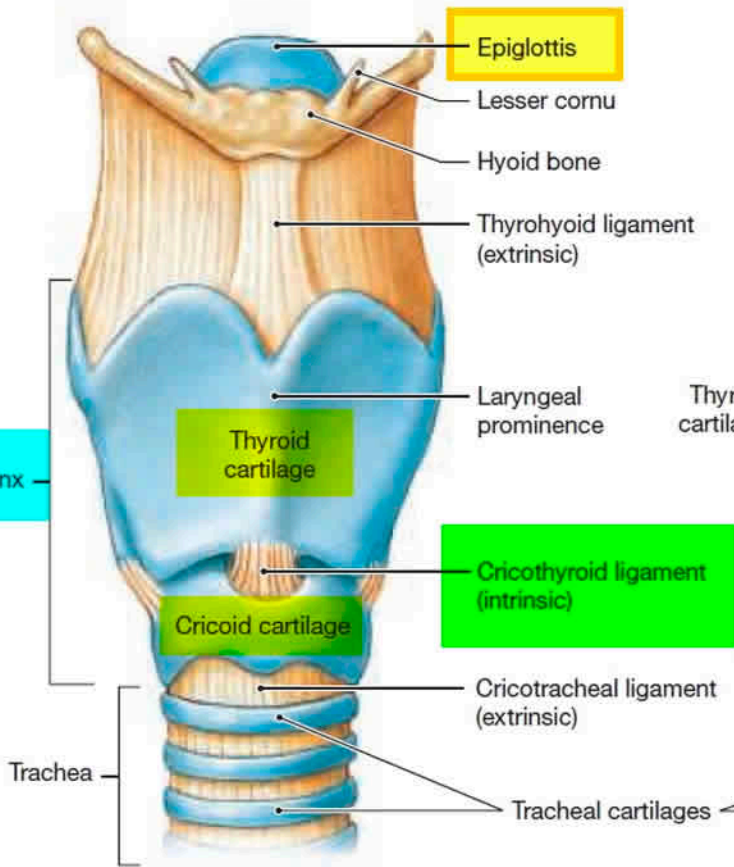
3 Glands

T

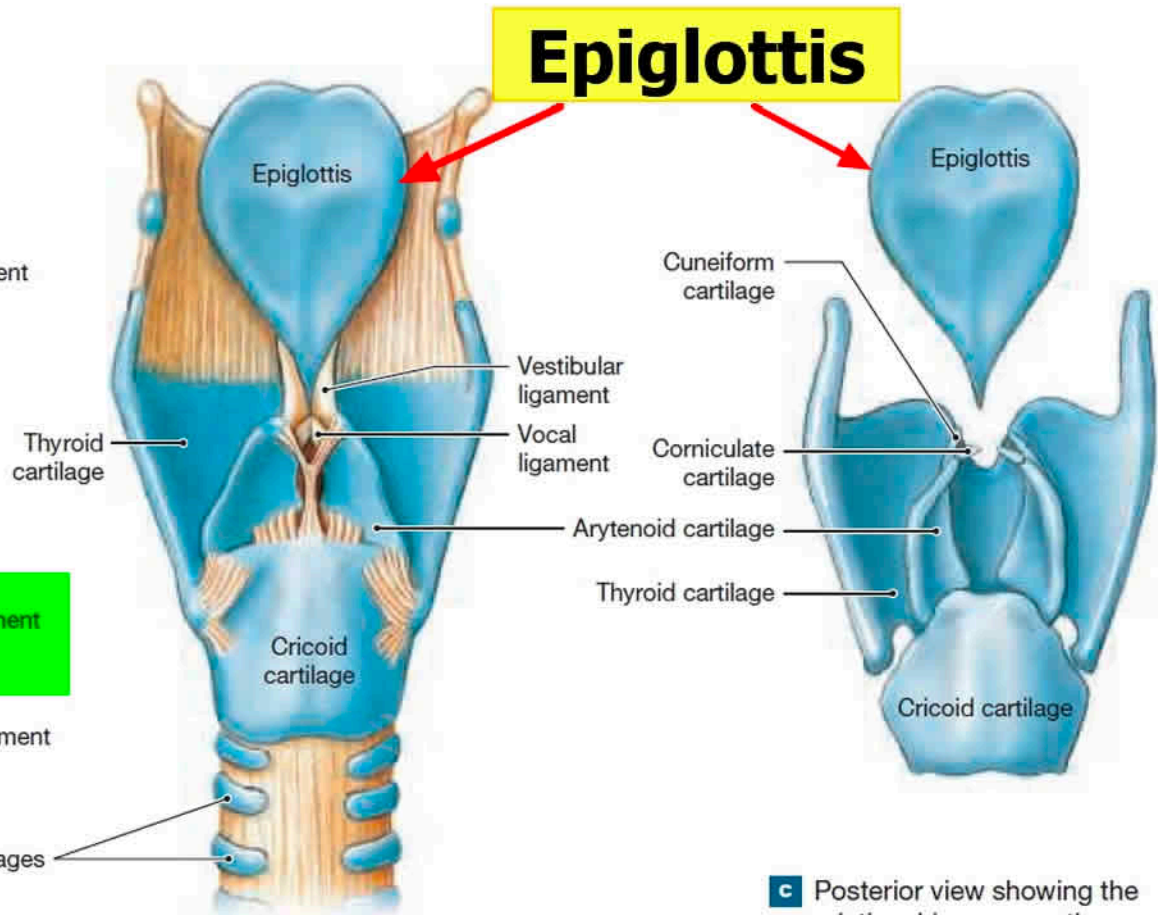


SONOANATOMY

Anatomy of the Larynx

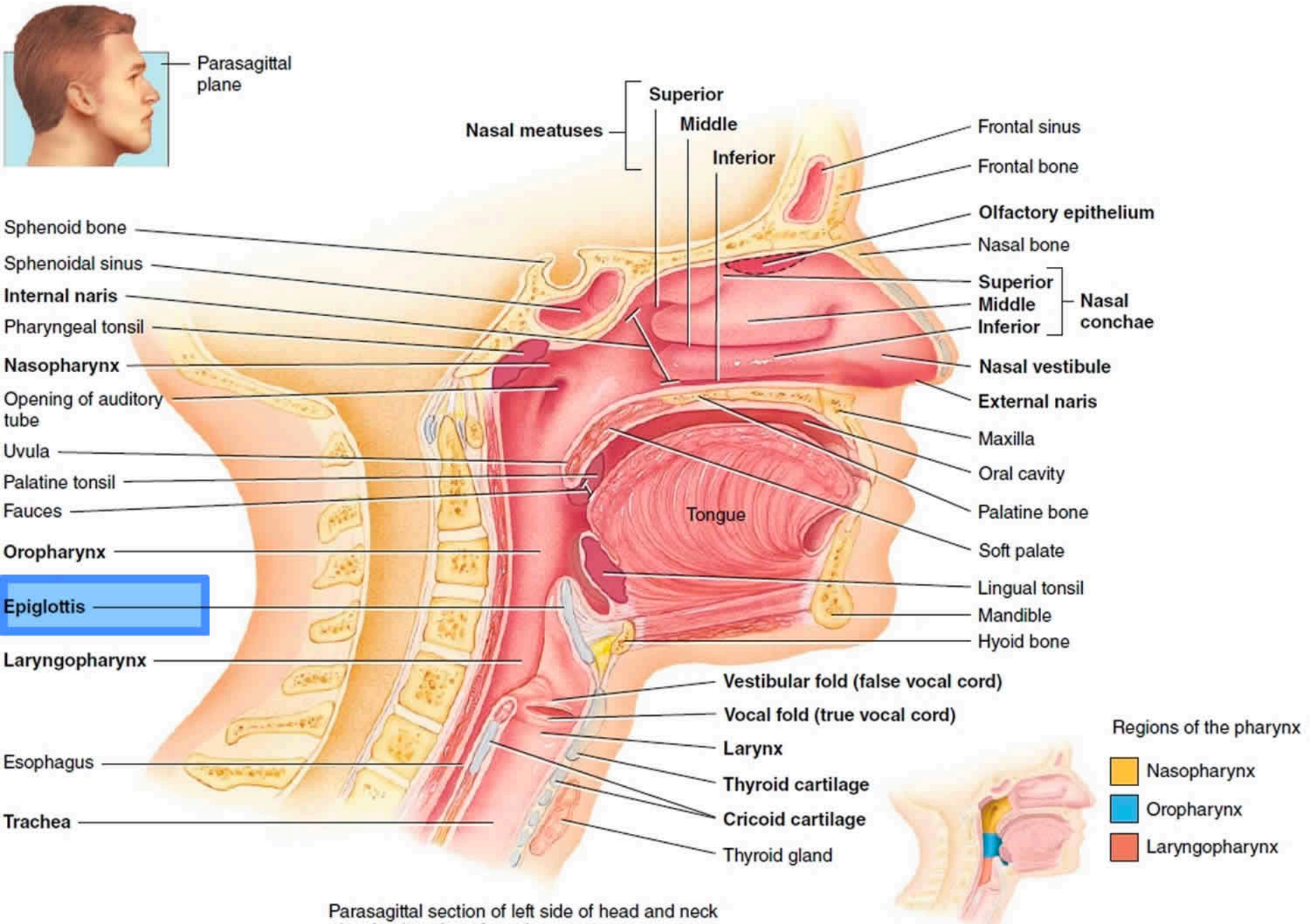


a Anterior view of the intact larynx



b Posterior view of the intact larynx

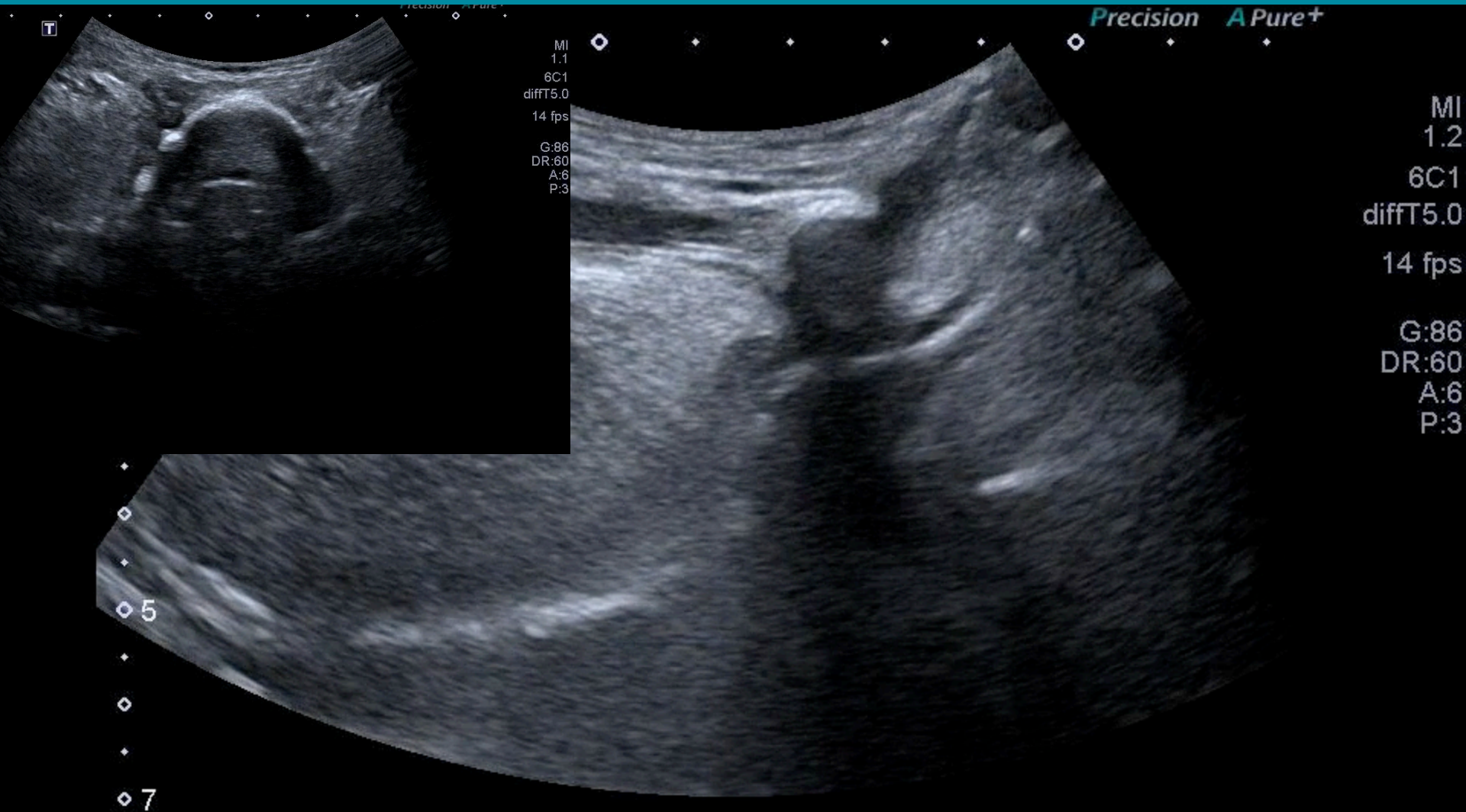
c Posterior view showing the relationships among the individual laryngeal cartilages



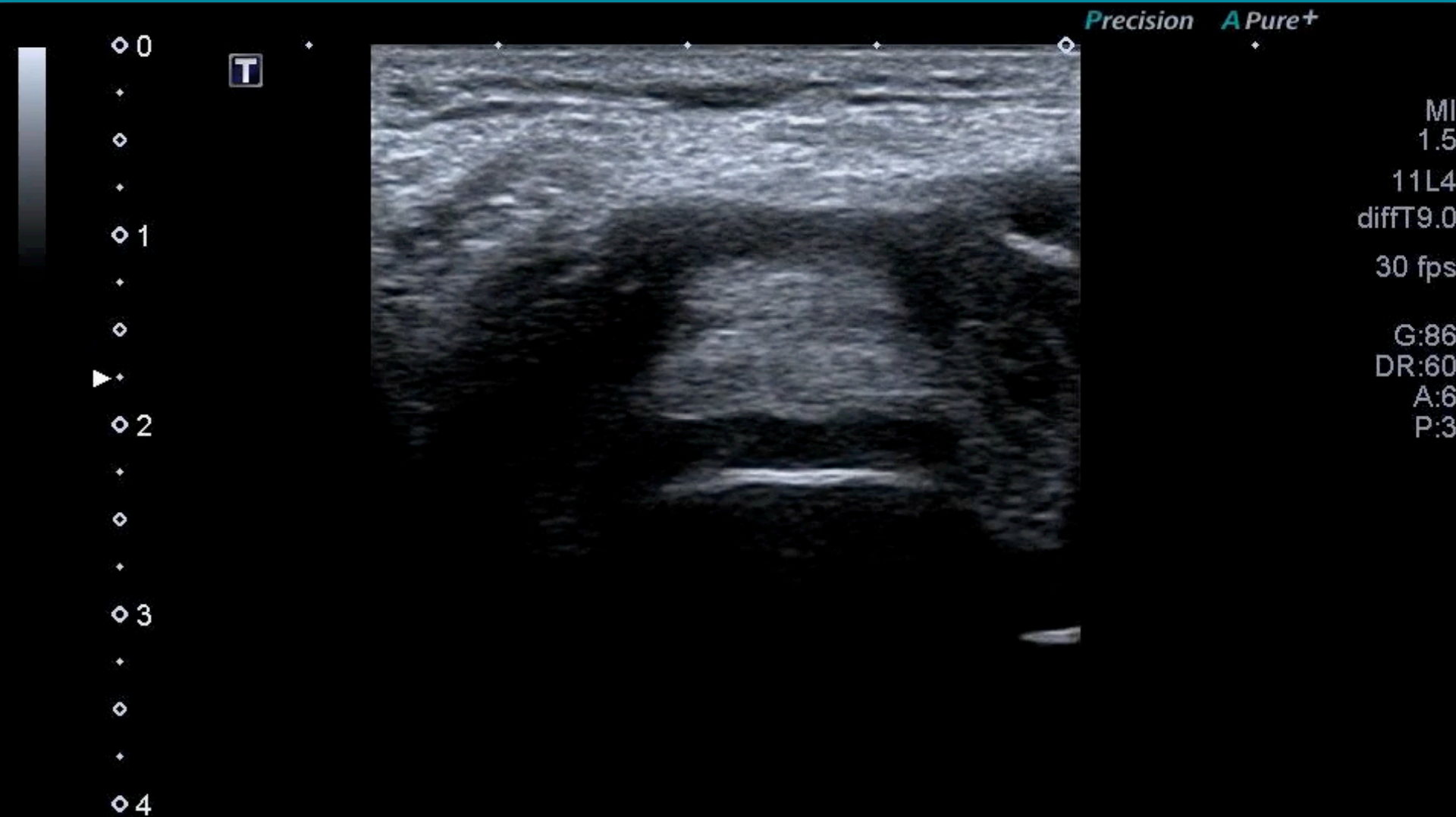
Parasagittal section of left side of head and neck showing location of respiratory structures

- Regions of the pharynx
- Nasopharynx
 - Oropharynx
 - Laryngopharynx

Hyoid bone: landmark for epiglottitis



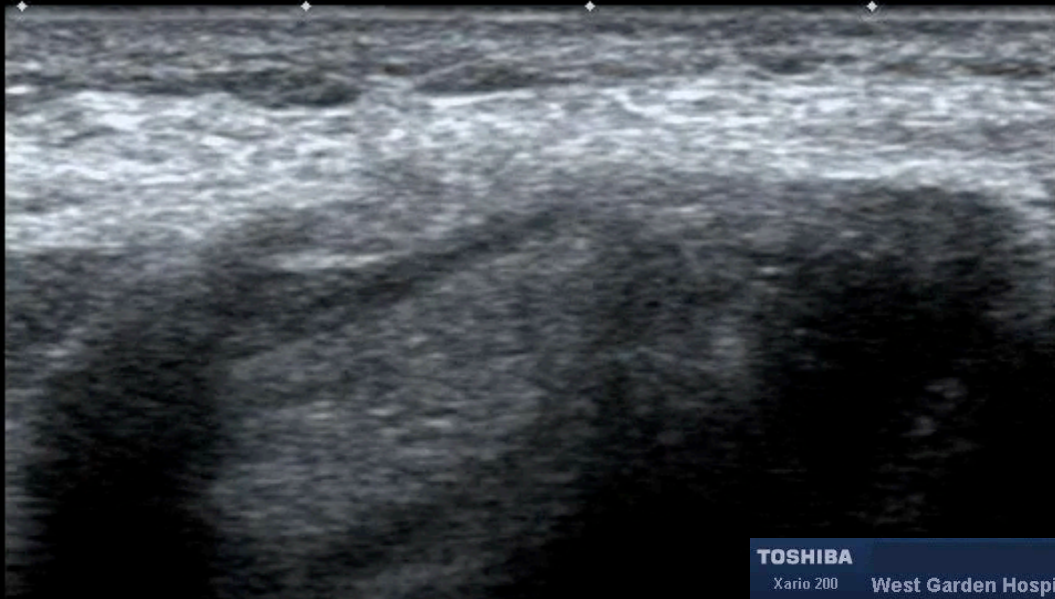
Epiglottitis



Landmark: hyoid bone

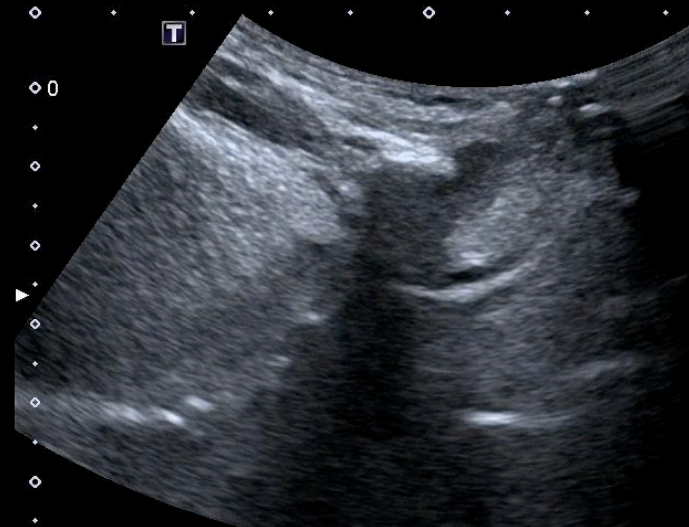
Epiglottitis

0
T
1
2
3
3.5



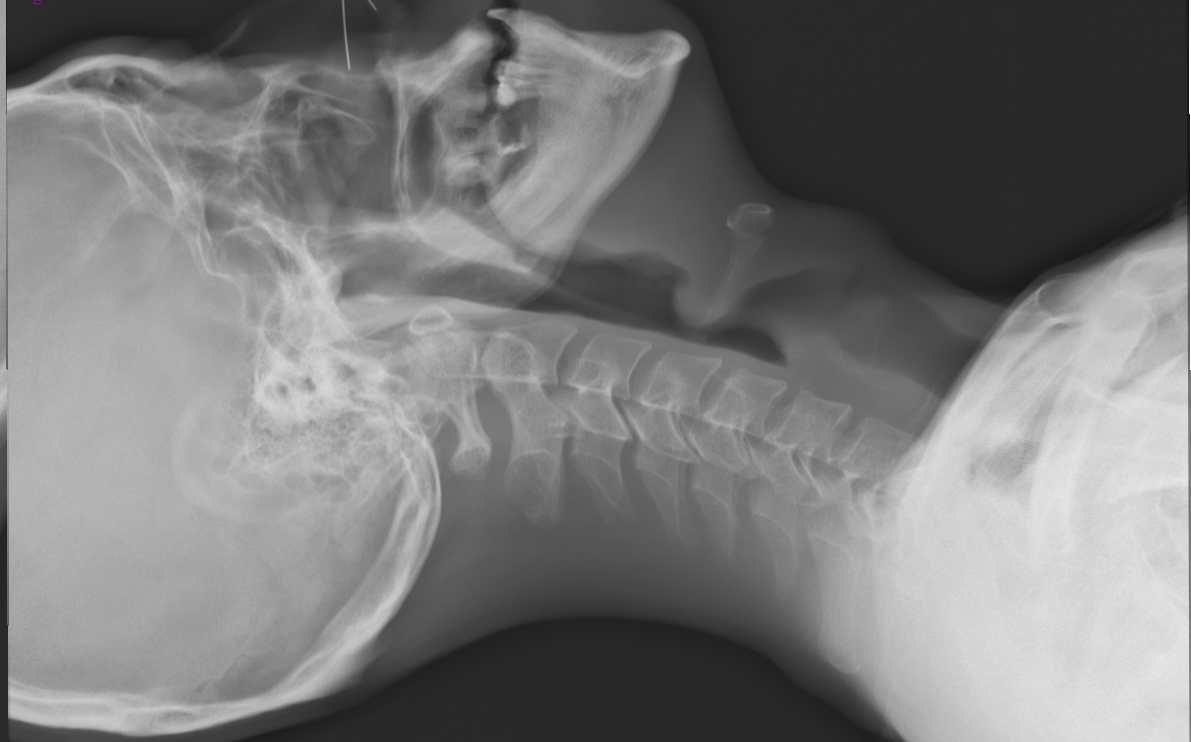
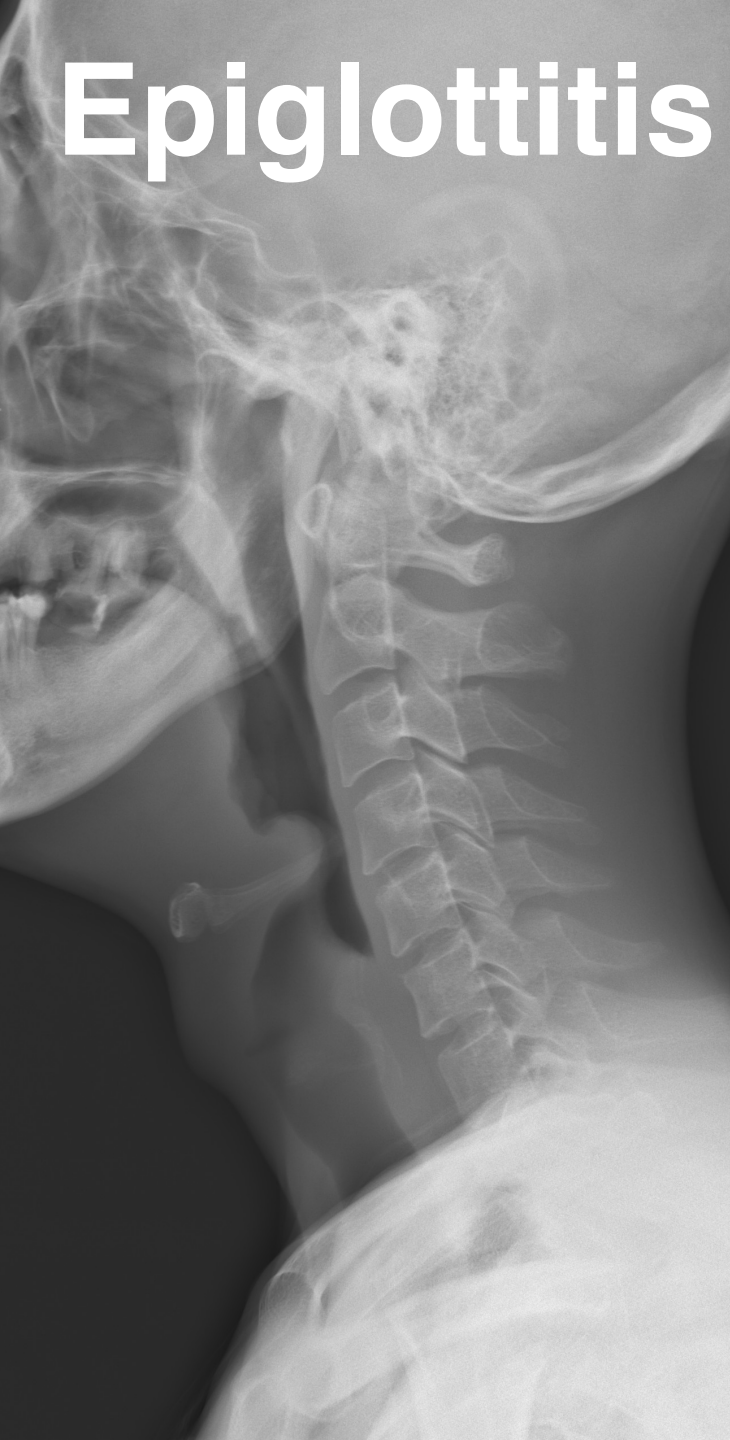MI
1.5
11L4
diffT9.0
30 fps
G:92
DR:60
A:5
P:1

TOSHIBA
Xario 200 West Garden Hospital MSK 3 313

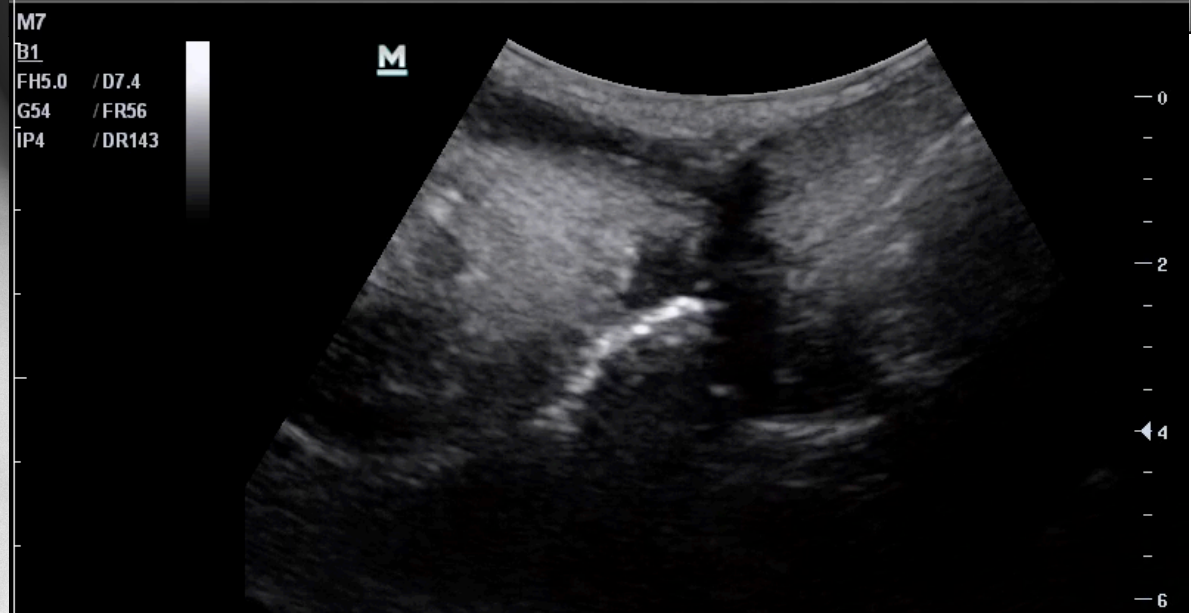


Landmark: hyoid bone

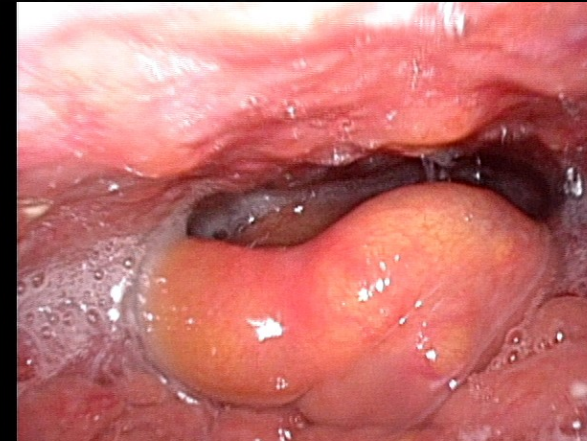
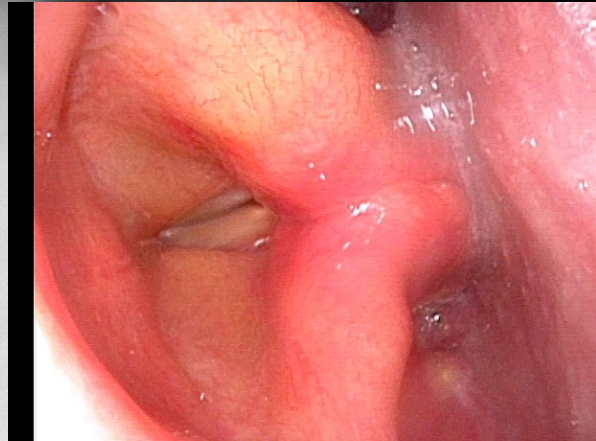
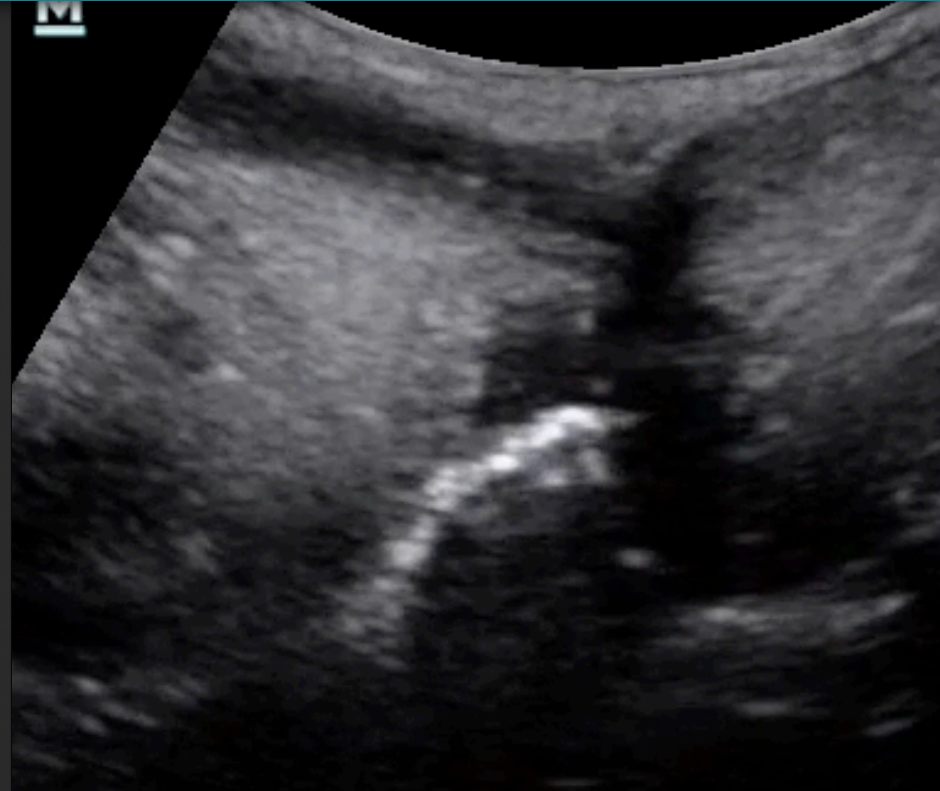
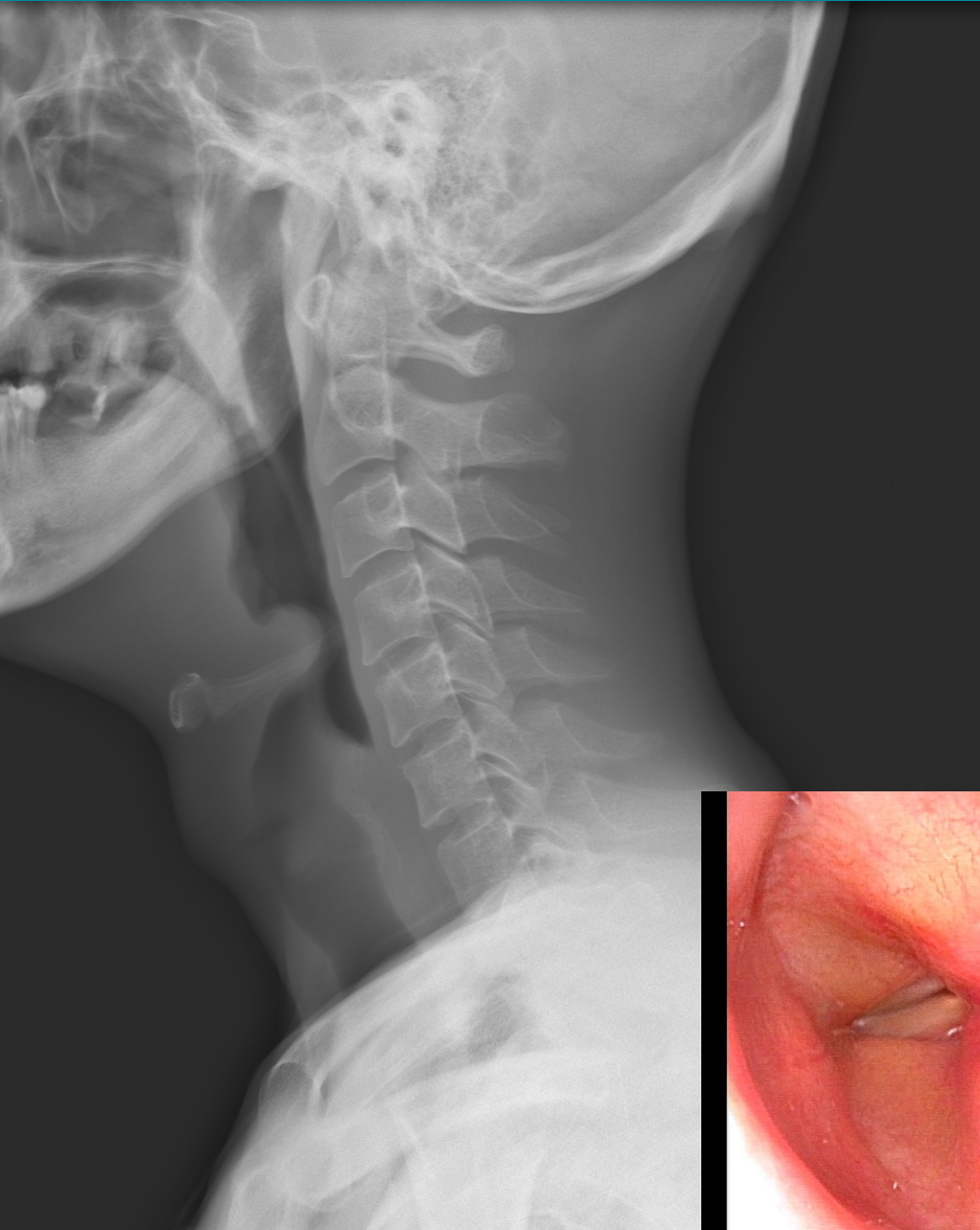Epiglottitis



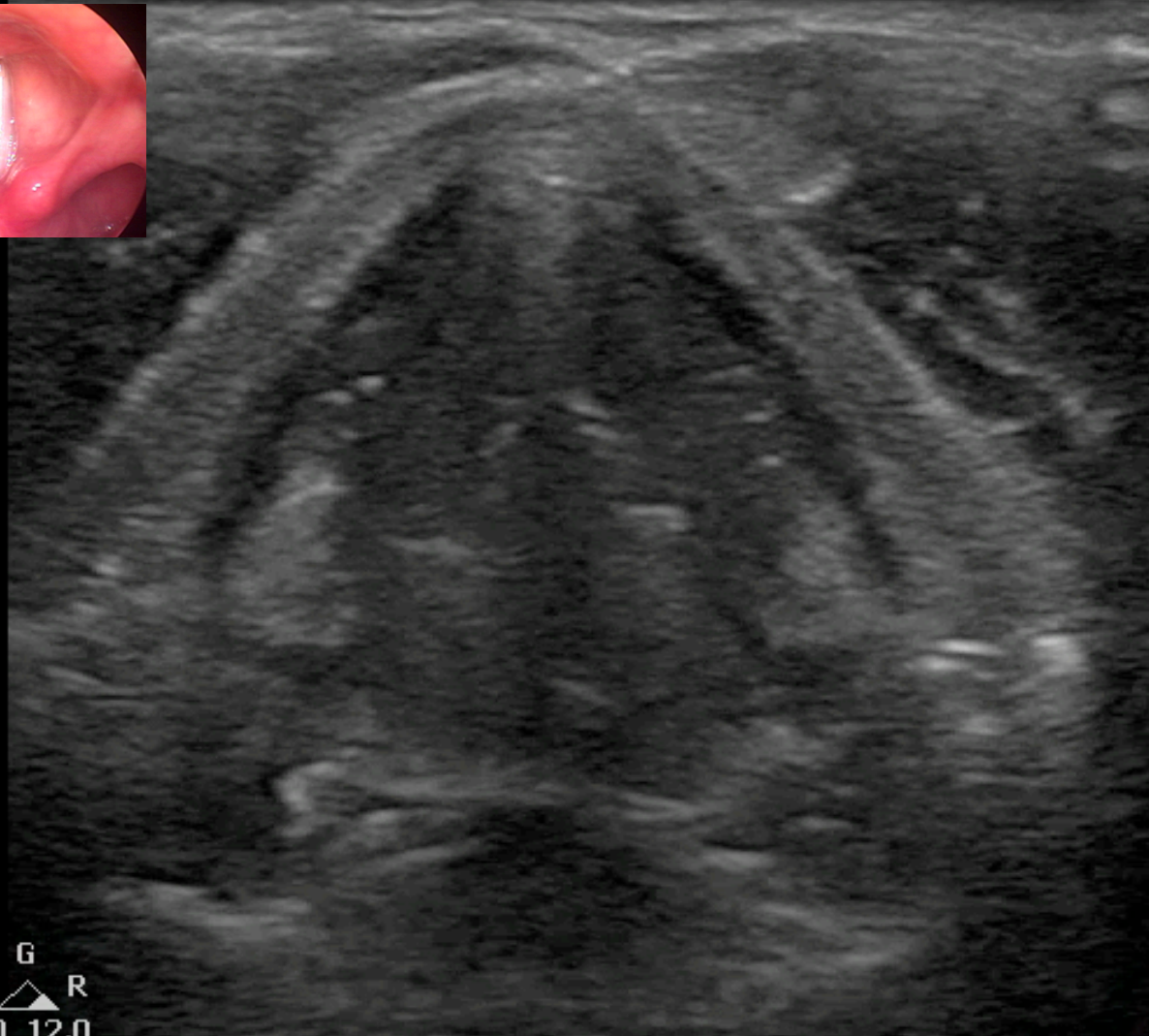
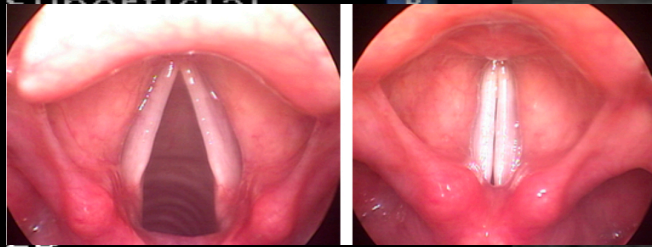
mindray liu 01577831 14/10/2022 11:10:51 AP 92.8% MI 0.6 TIS 0.3
C5-2s Adult ABD



Acute epiglottitis



Vocal cords



Res
Gn 100
C 56
3 / 2 / 1

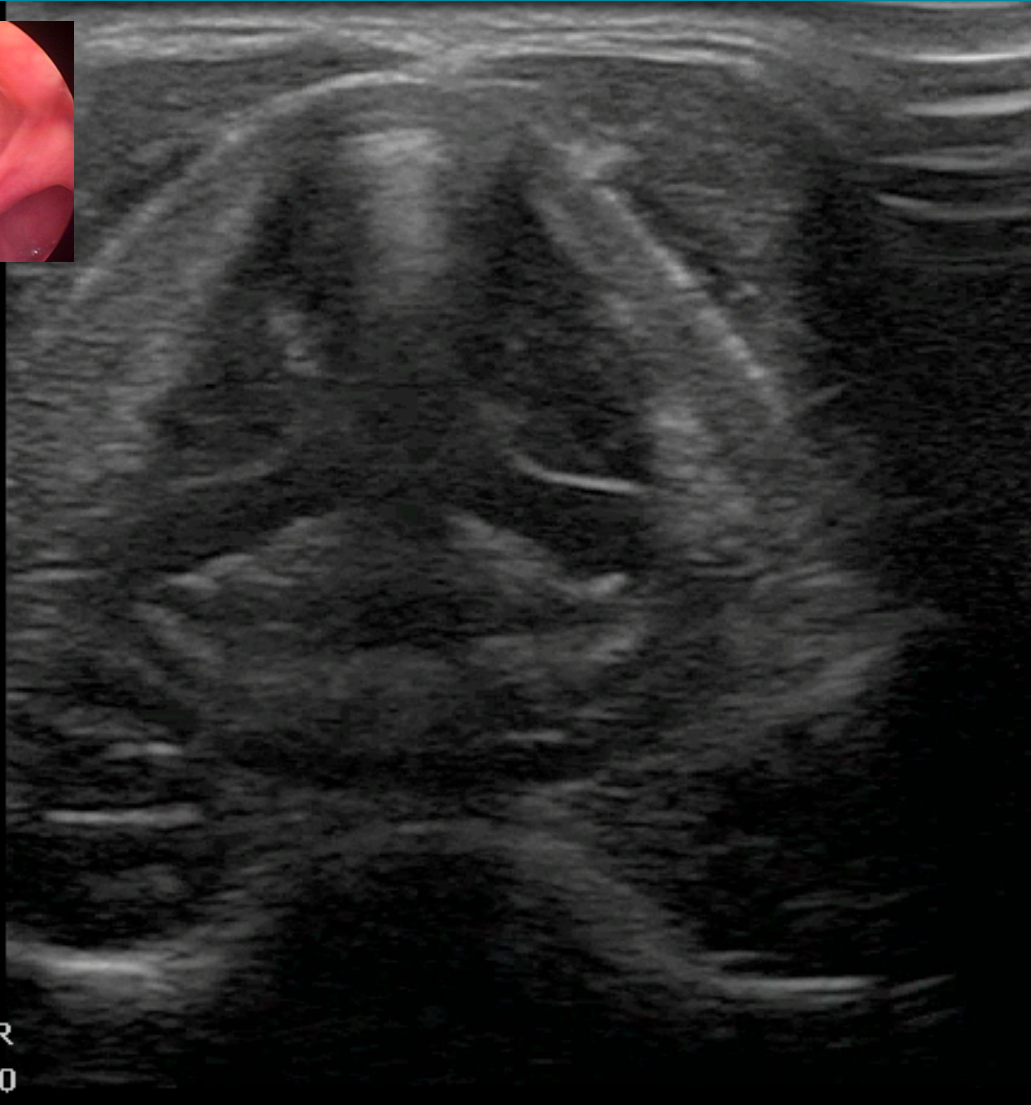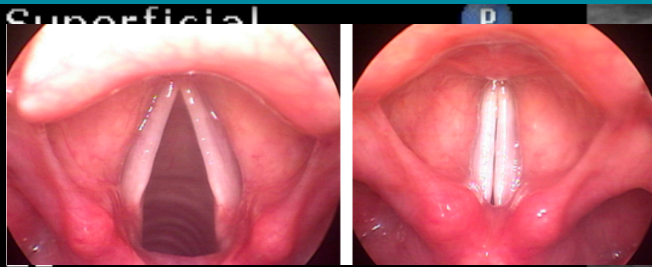


G
P R
3.0 12.0

3.5cm

Landmark: thyroid cartilage

Phonation



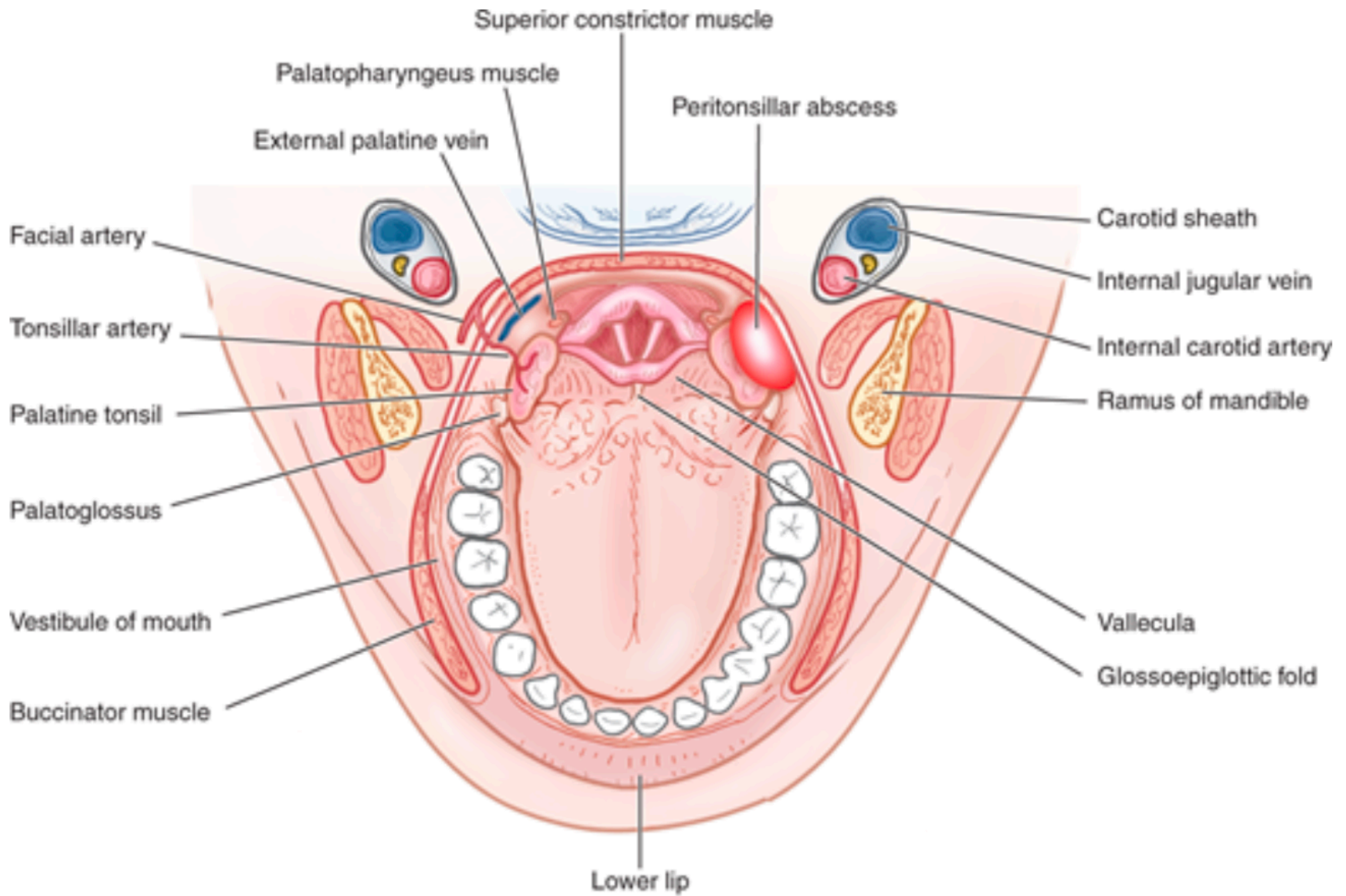
Res
Gn 100
C 56
3 / 2 / 1



G
P R
3.0 12.0

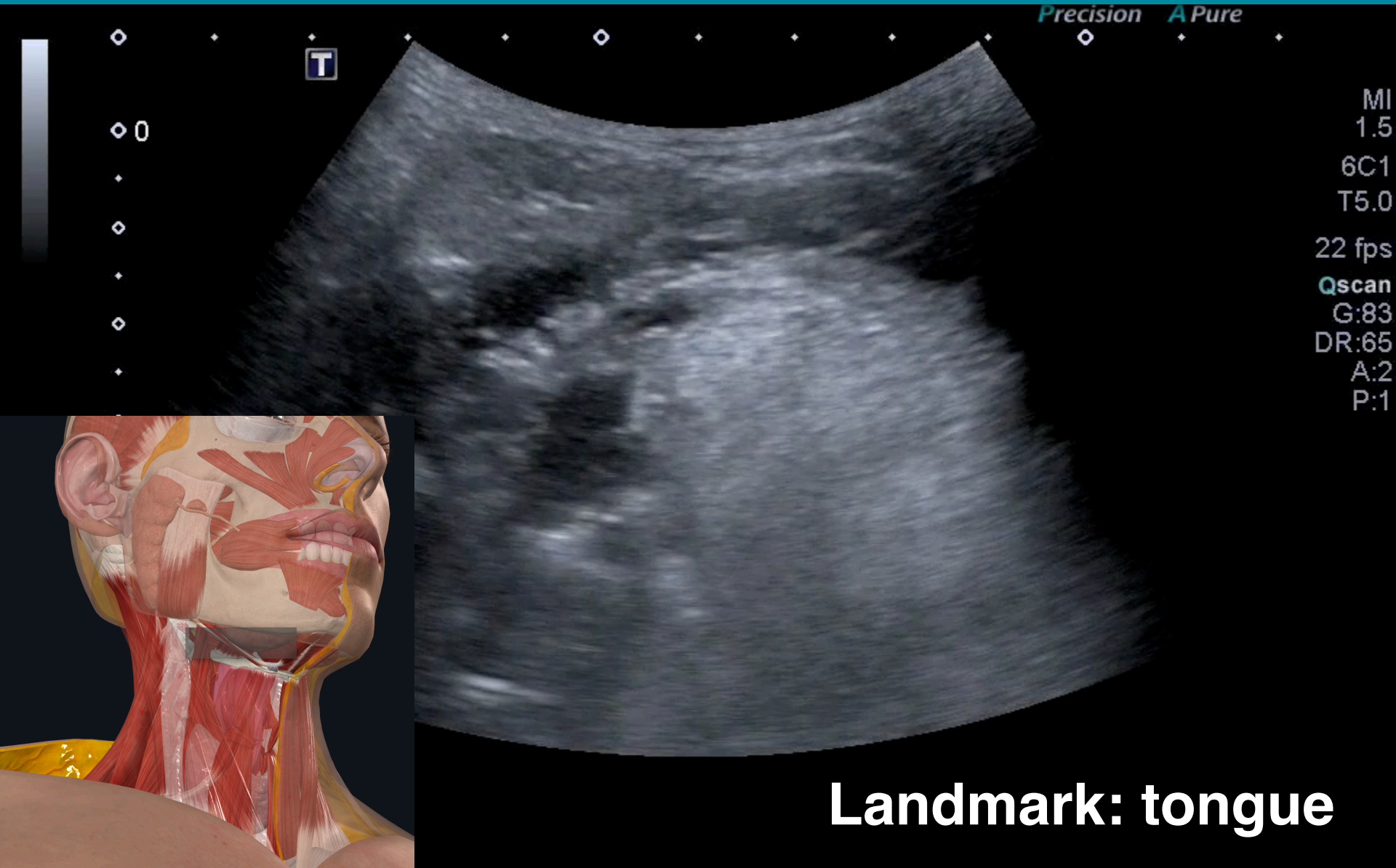
Landmark: thyroid cartilage

4.0cm



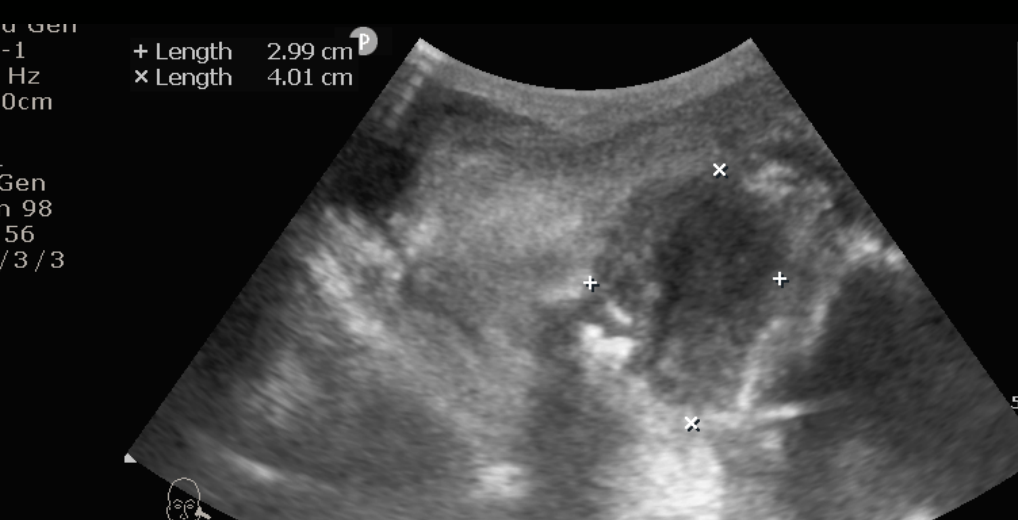
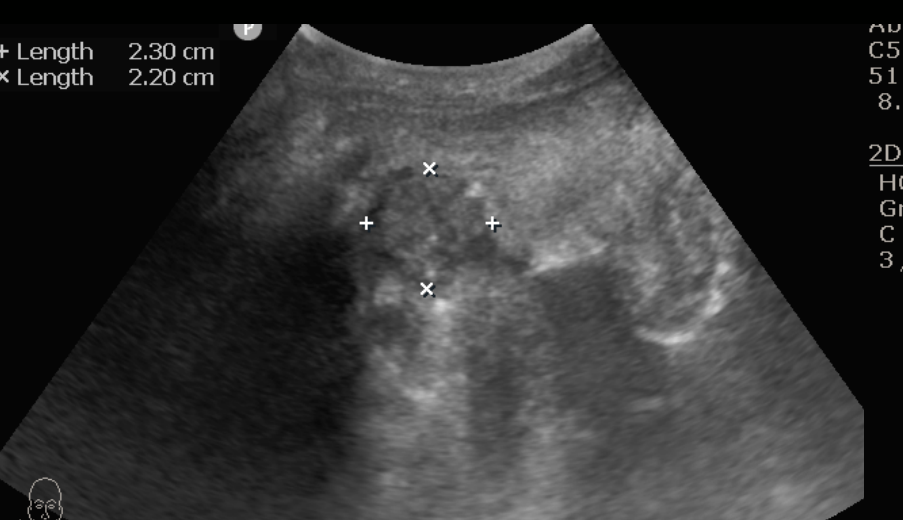
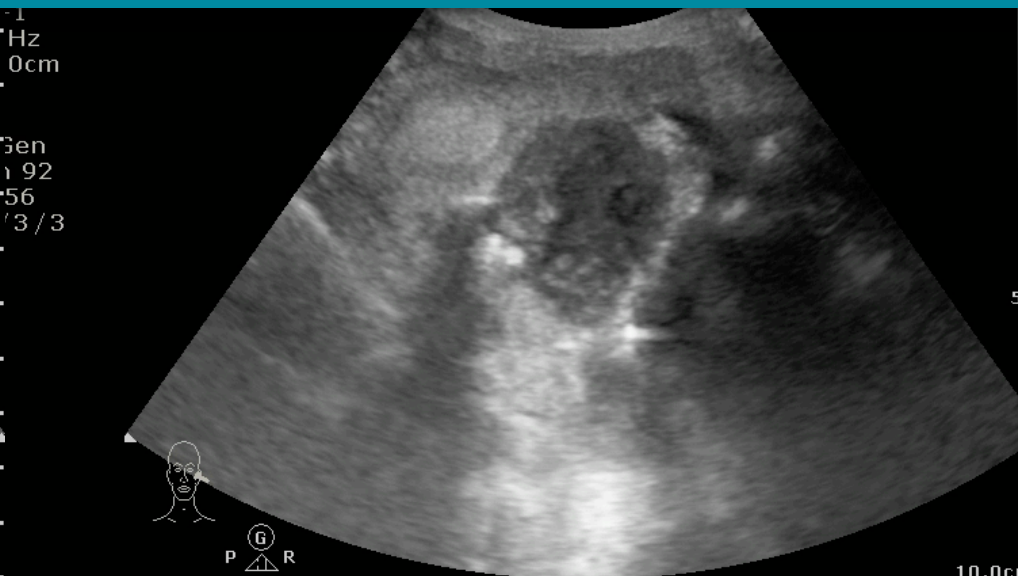
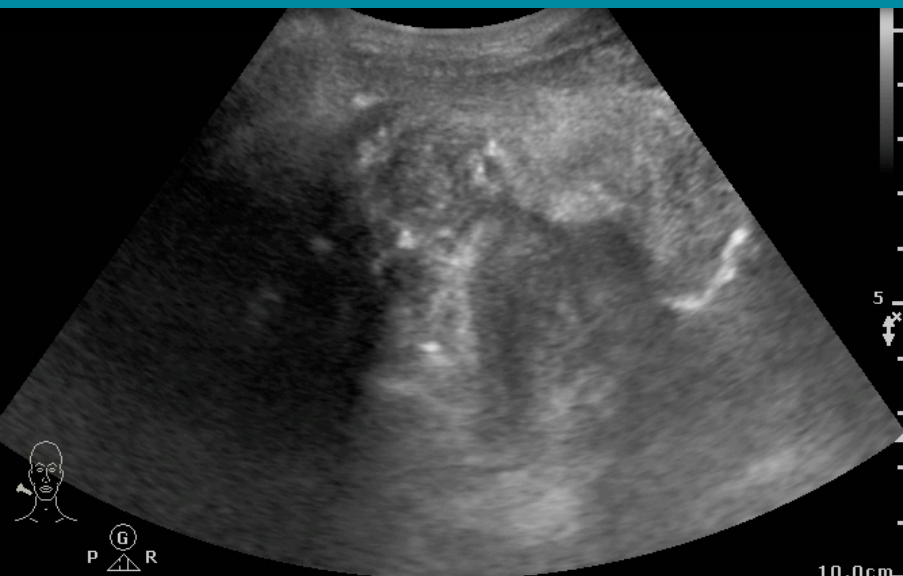
Source: Reichman EF: Emergency Medicine Procedures, Second Edition: www.accesssurgery.com
 Copyright © The McGraw-Hill Companies, Inc. All rights reserved.

Tonsil



Landmark: tongue

26M, severe left throat pain

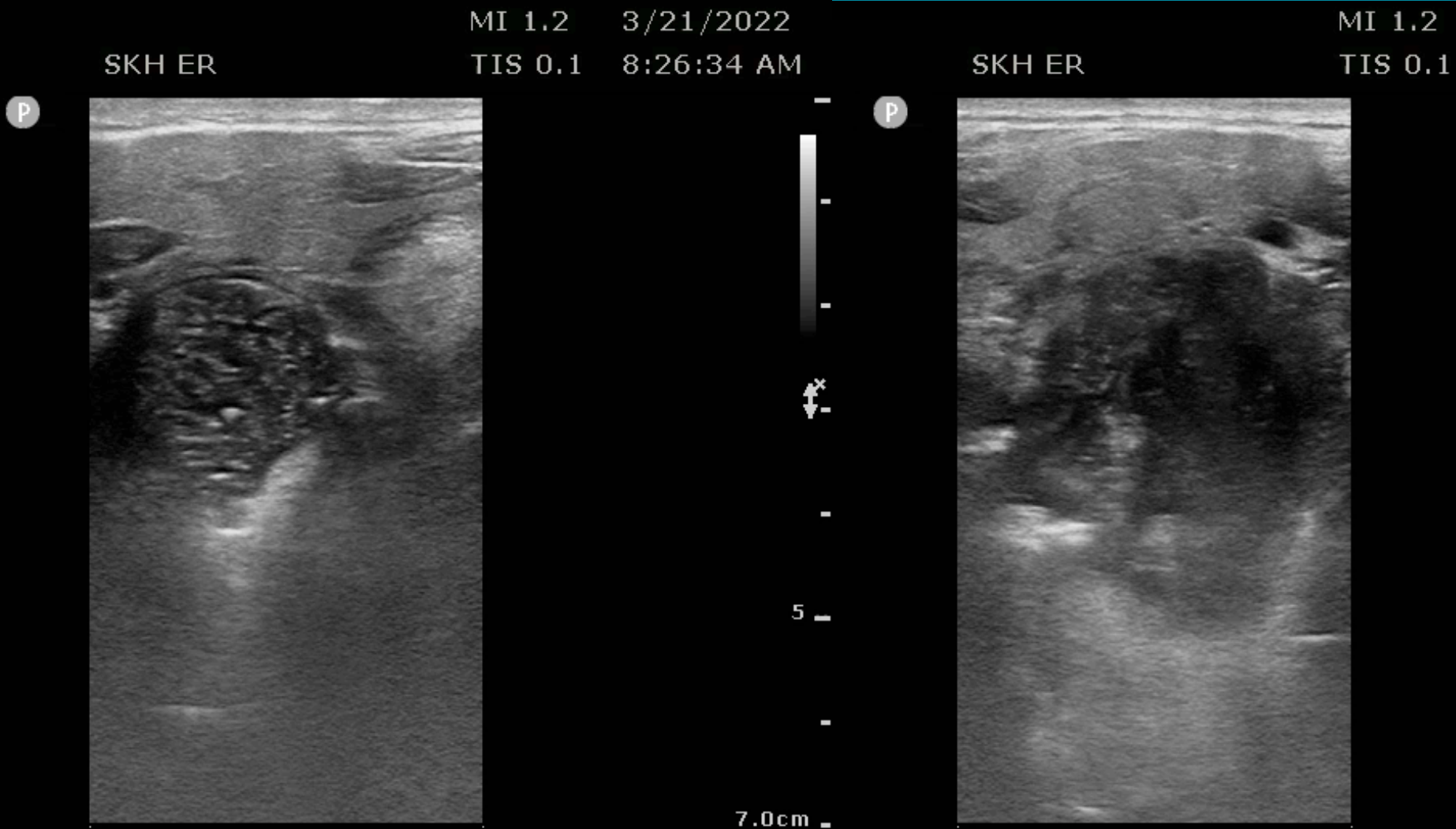


51 Hz
8.0 cm
5
10.0cm

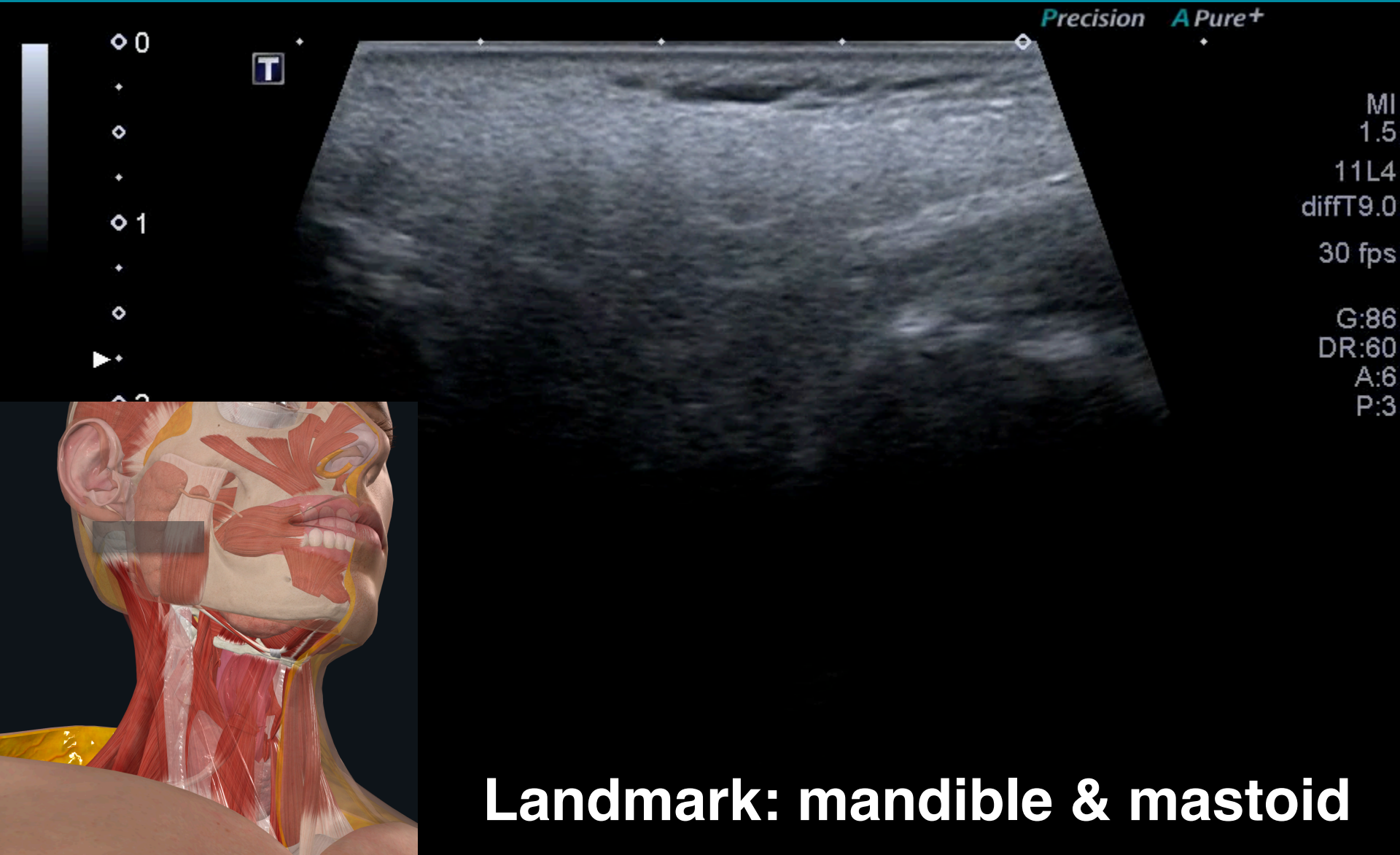
51 Hz
8.0 cm
2D
HGen
Gn 98
C 56
3/3/3

+ Length 2.99 cm
x Length 4.01 cm

Peritonsillar abscess

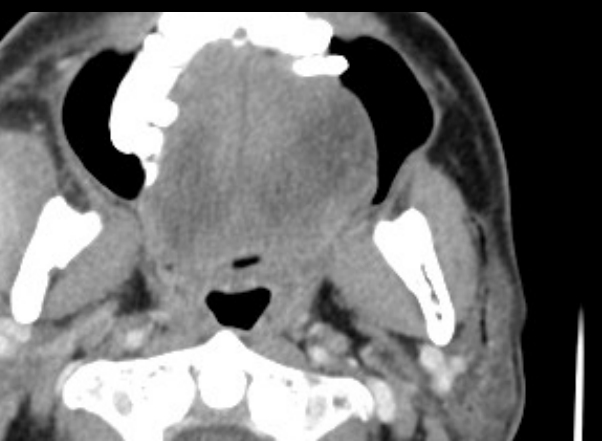
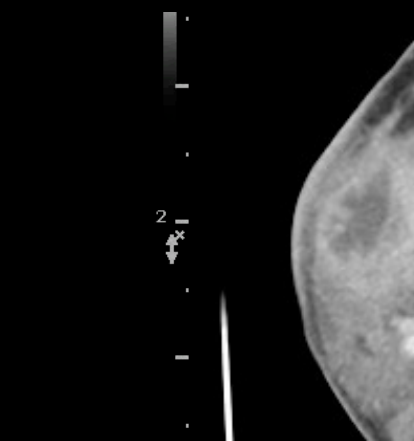
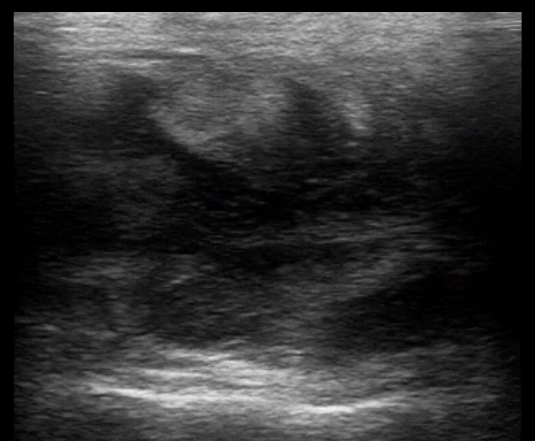
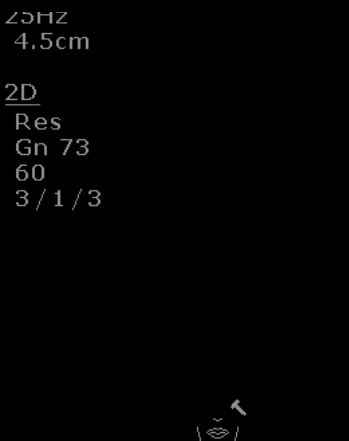
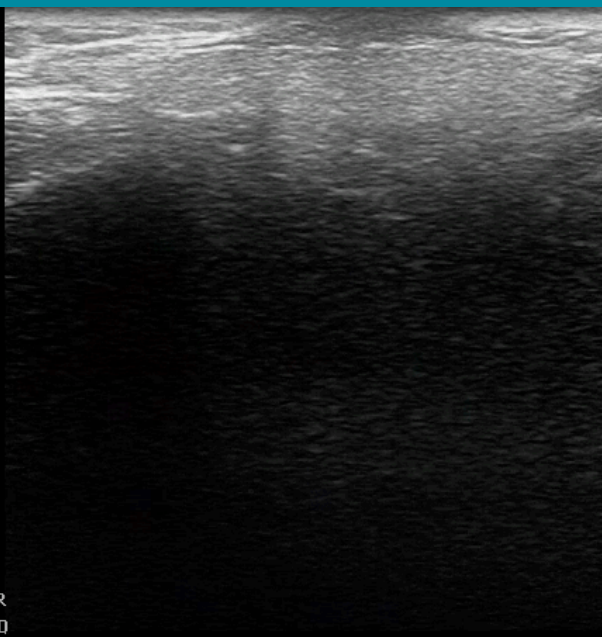

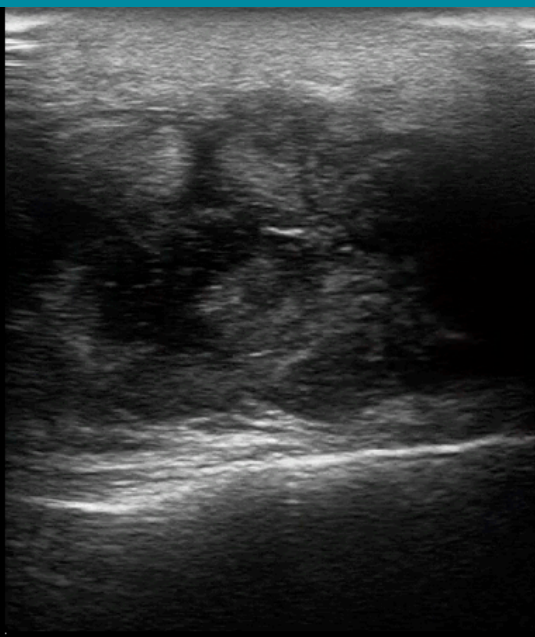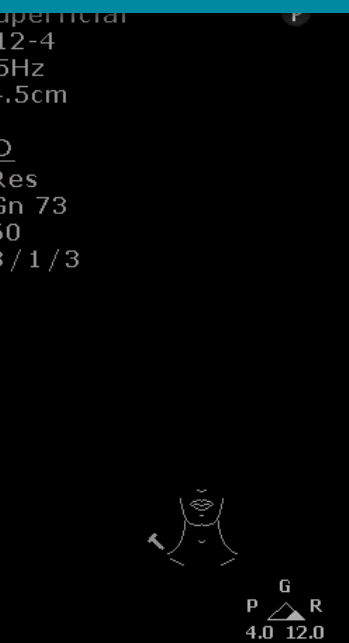


Parotid gland

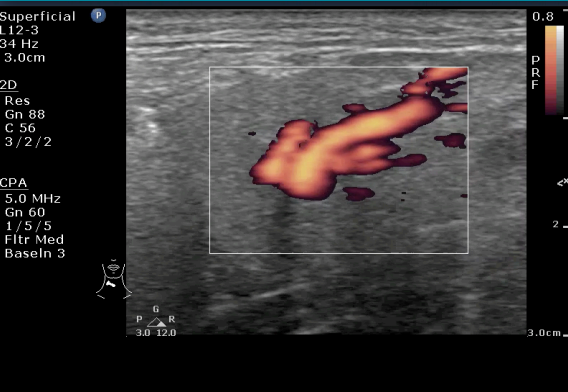


Landmark: mandible & mastoid

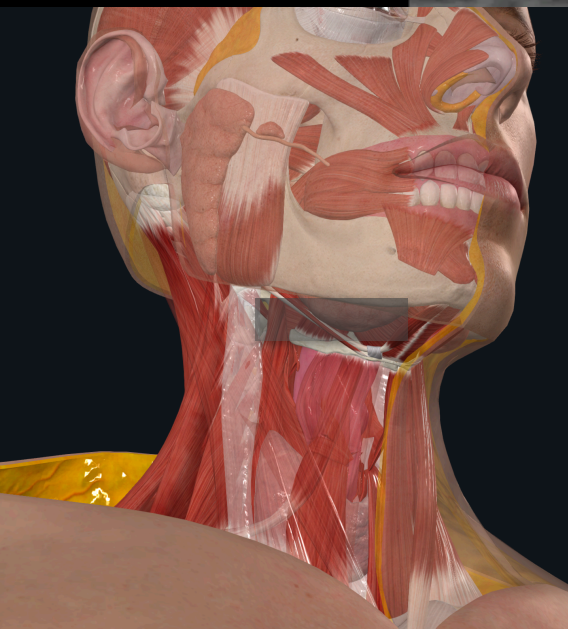69M, 右臉腫，門診轉入腮腺炎



Submandibular gland



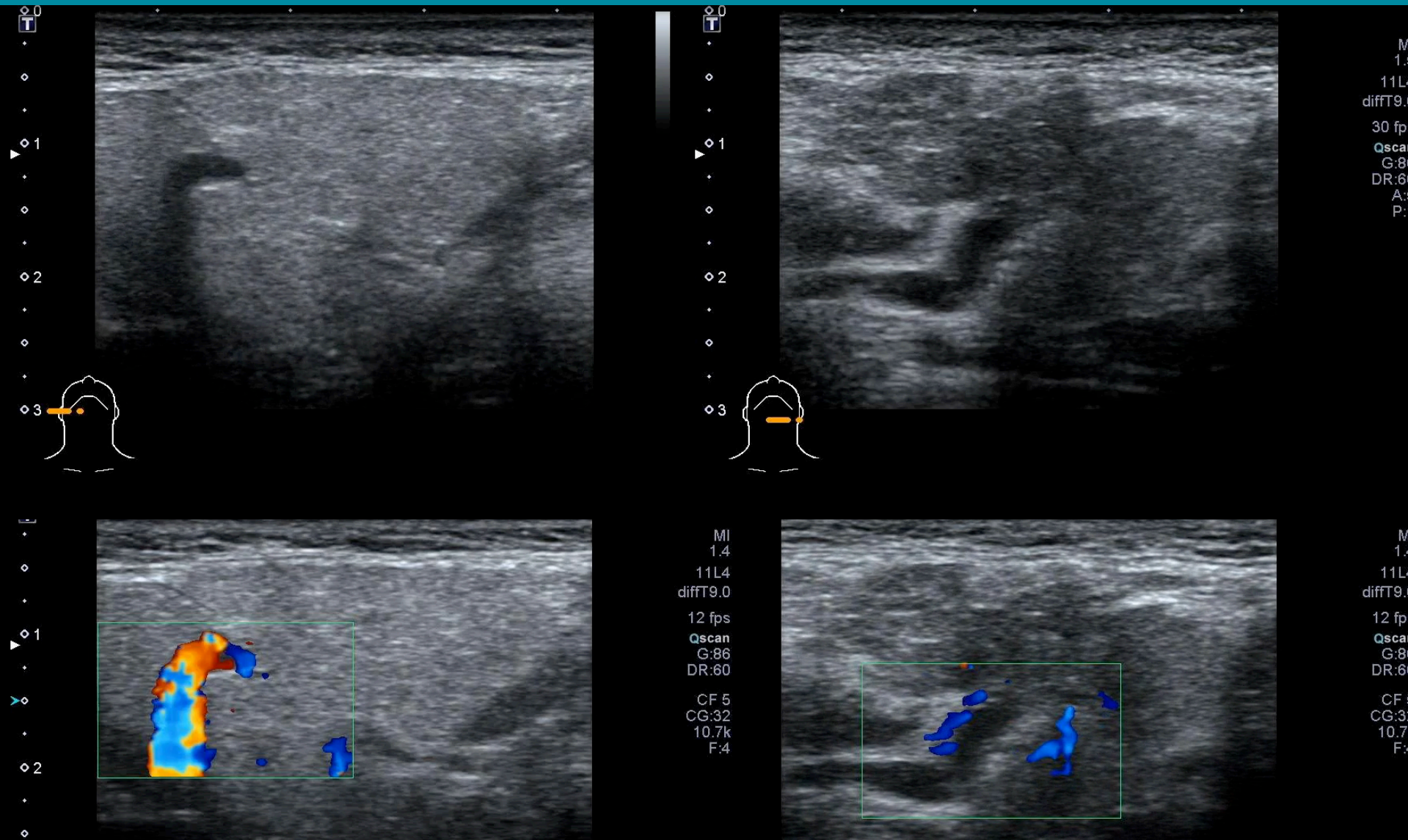
C 56
3/2/1



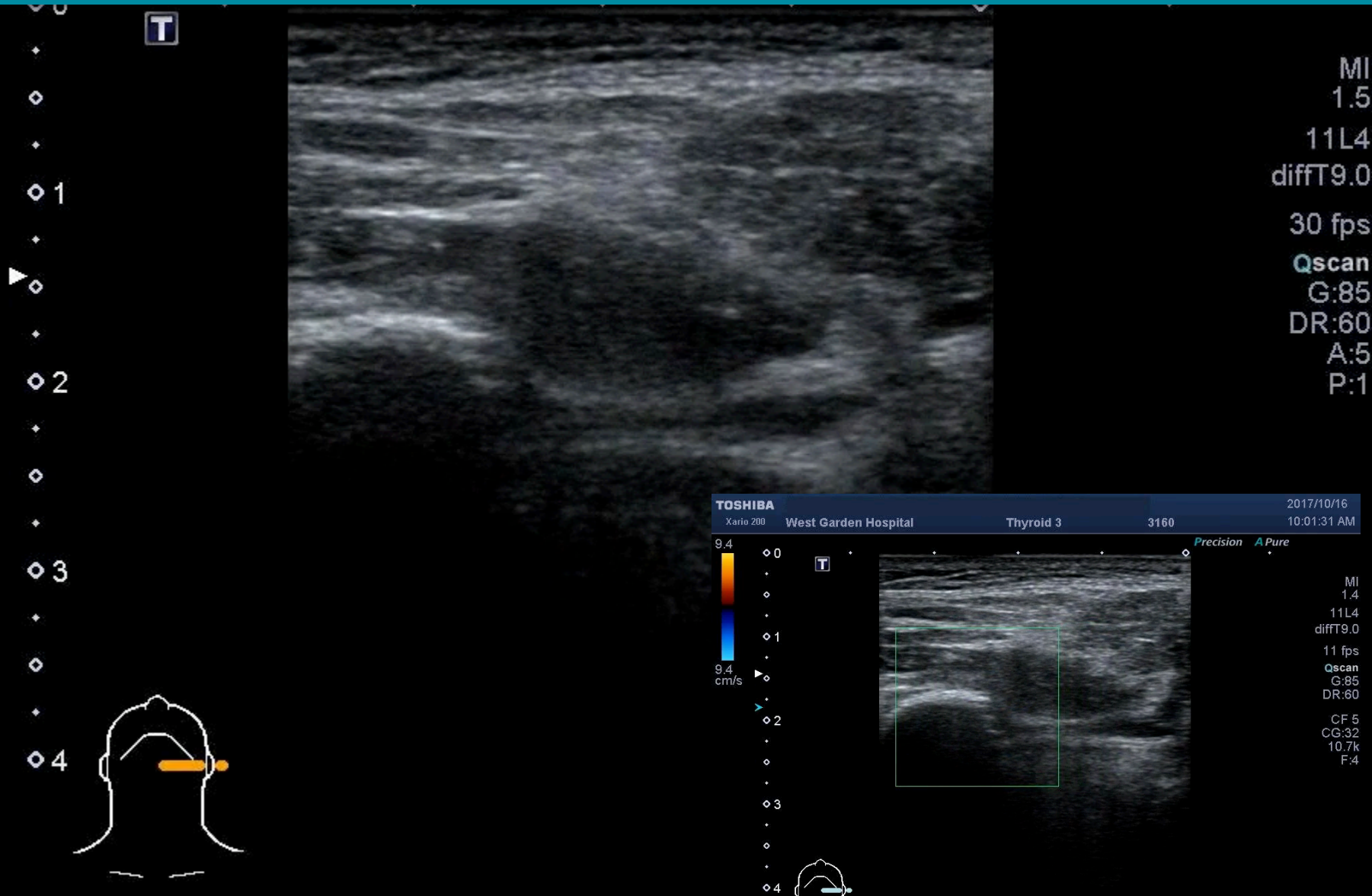
Landmark: mandible or CCA

2
3.0cm

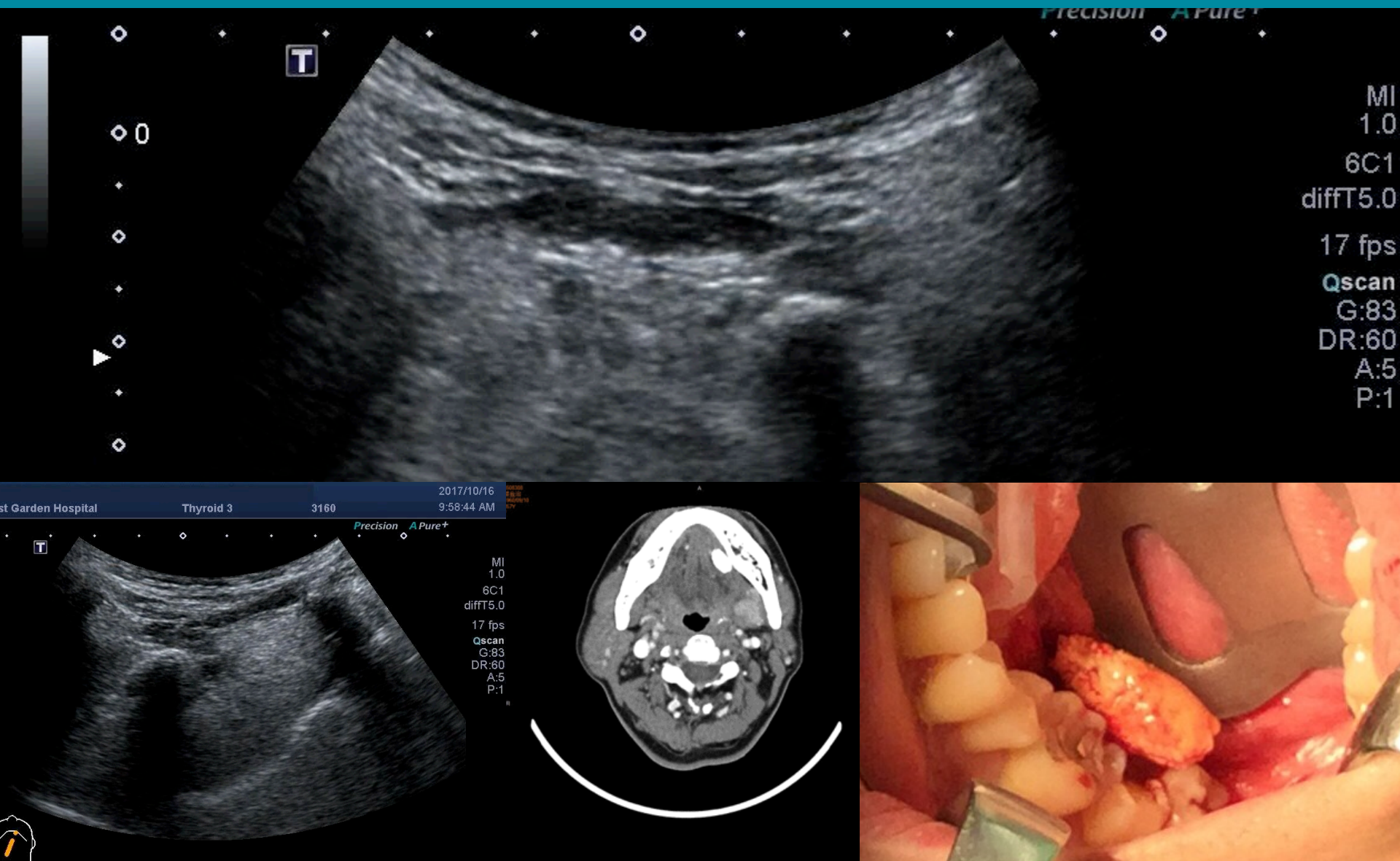
57F, 左下巴痛好幾週



57F, 左下巴痛好幾週



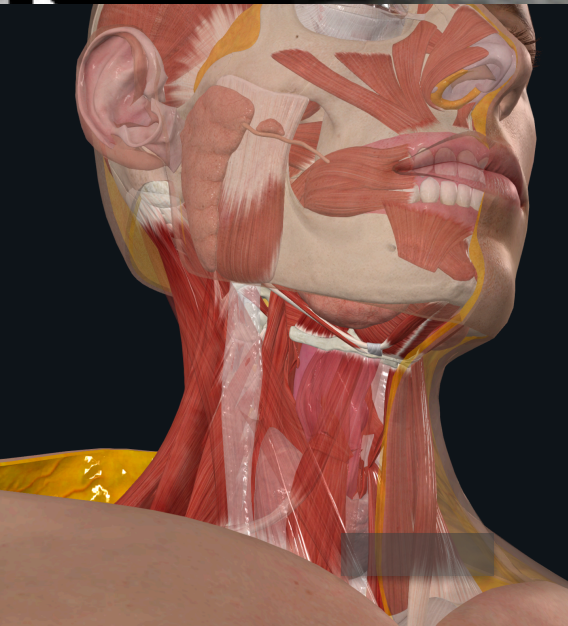Sialolithiasis



Thyroid gland

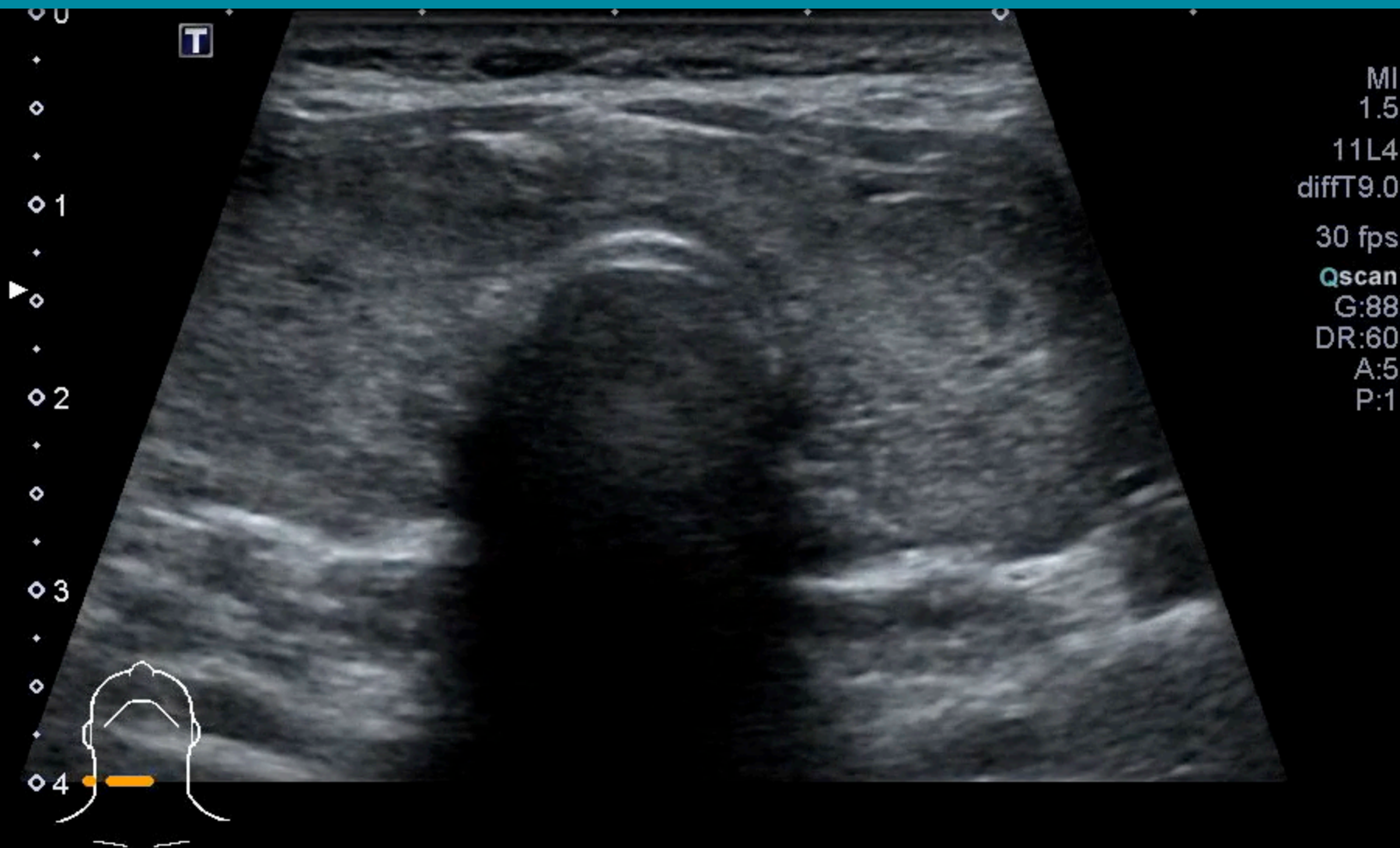
SAMSUNG
RS80A

1

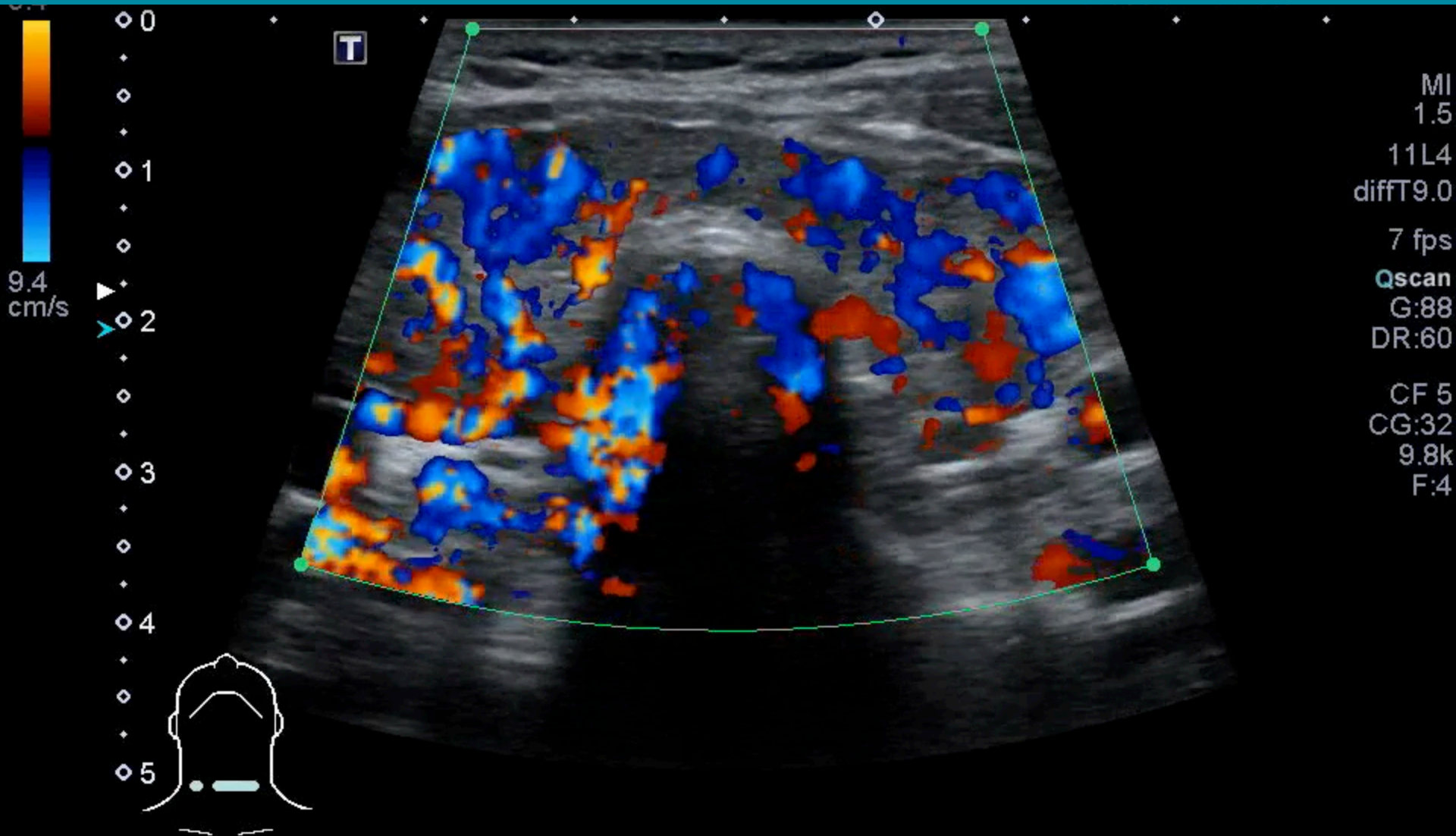


Landmark: suprasternal notch & trachea

36F, 雙腳無力低血鉀



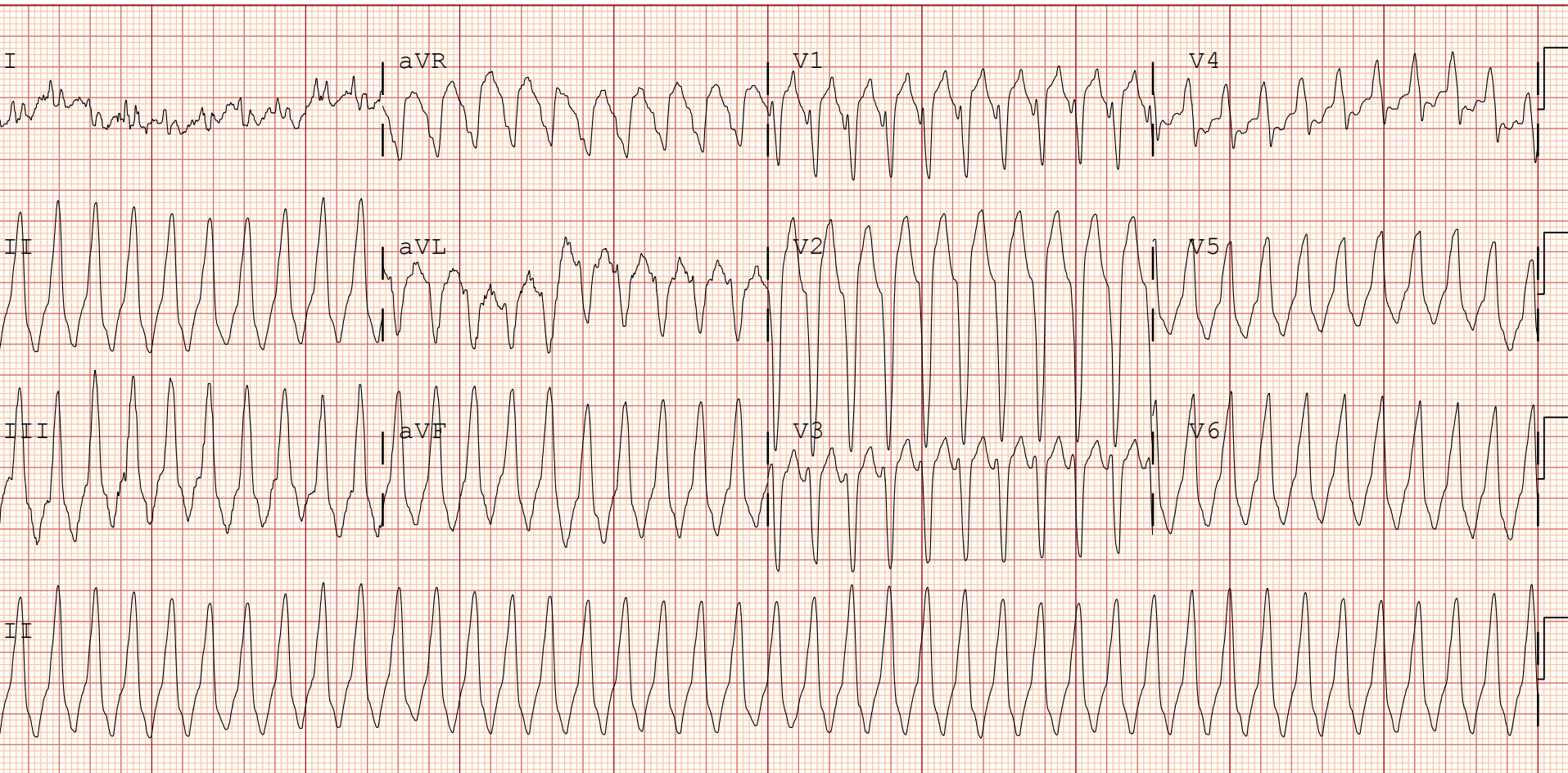
Hyperthyroidism



43F, palpitation & cold sweating

12 Lead; Standard Placement

Not confirmed



Device:

Speed: 25 mm/sec

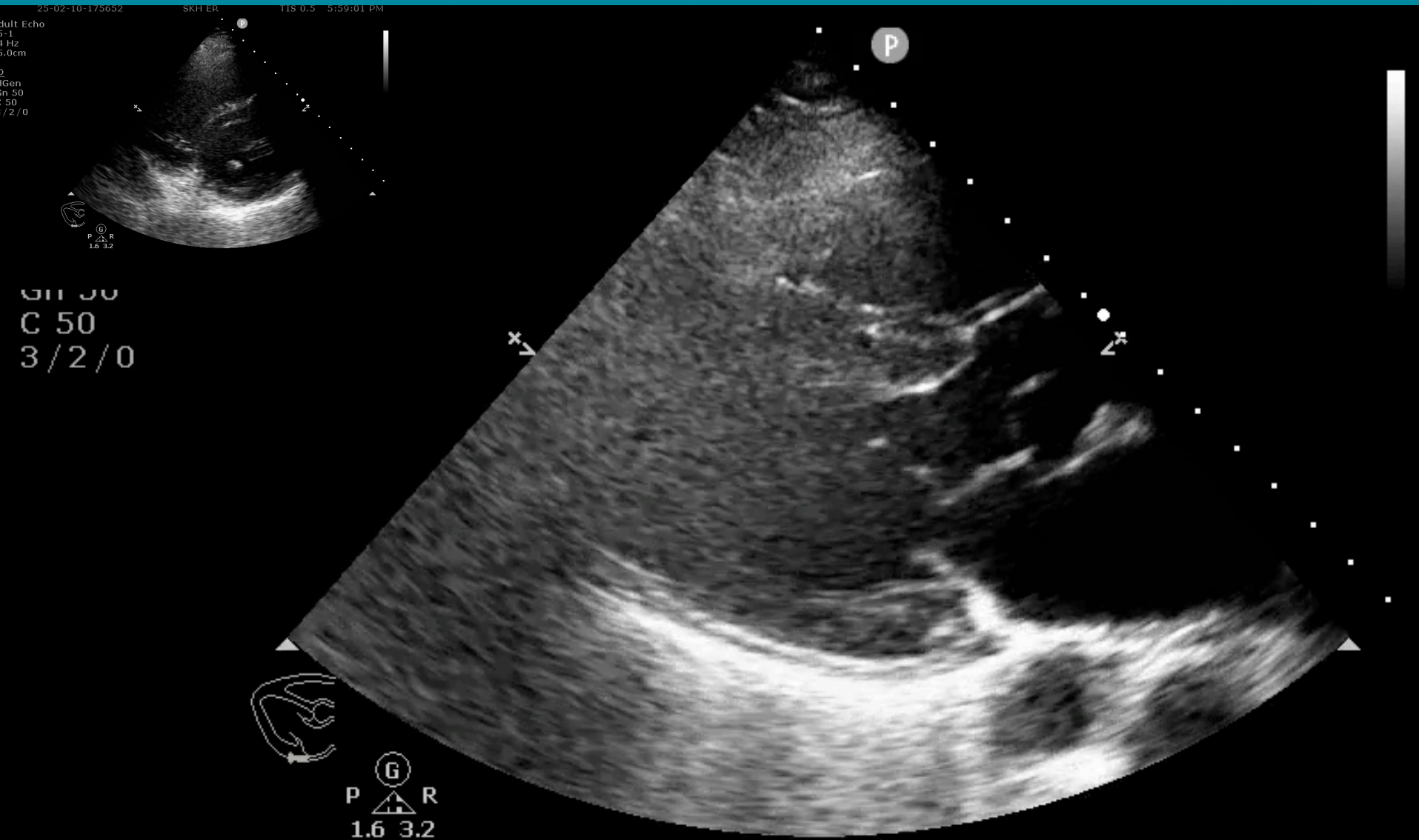
Limb: 10 mm/mV

Chest: 10 mm/mV

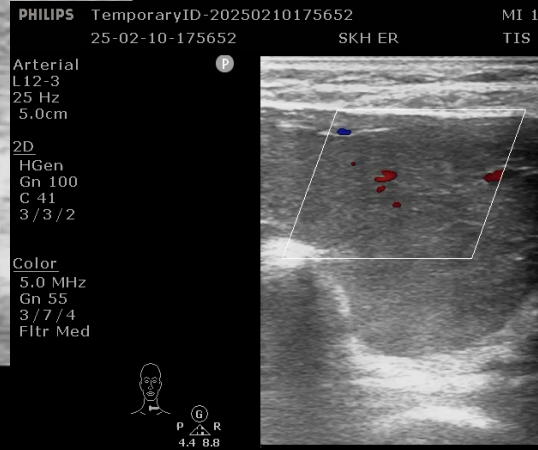
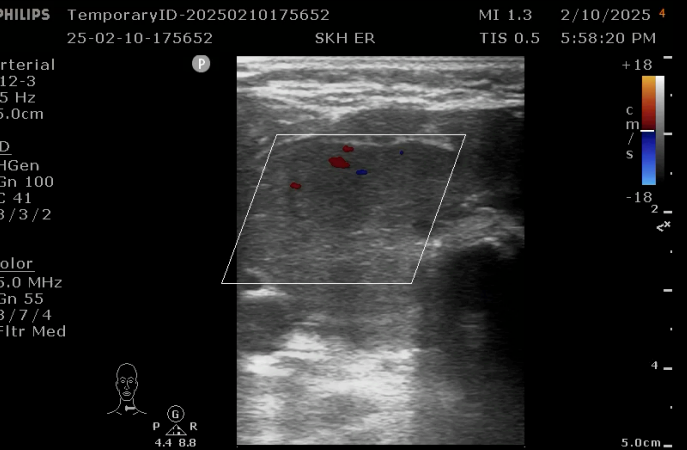

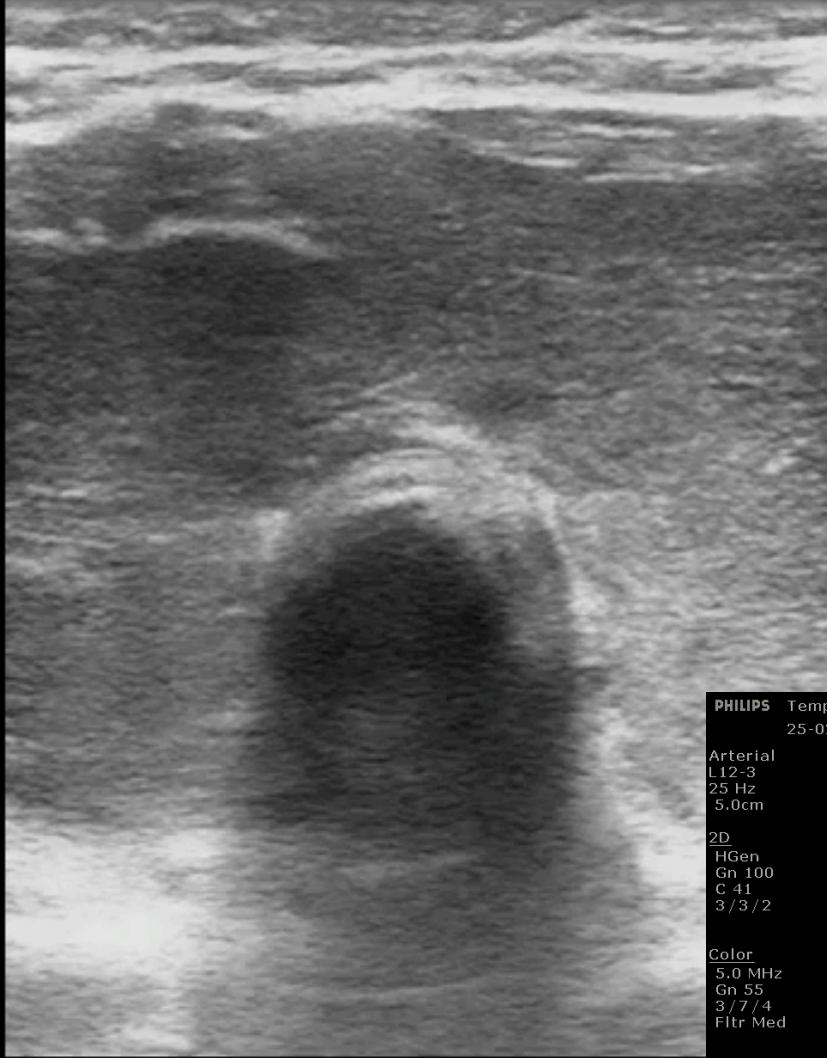
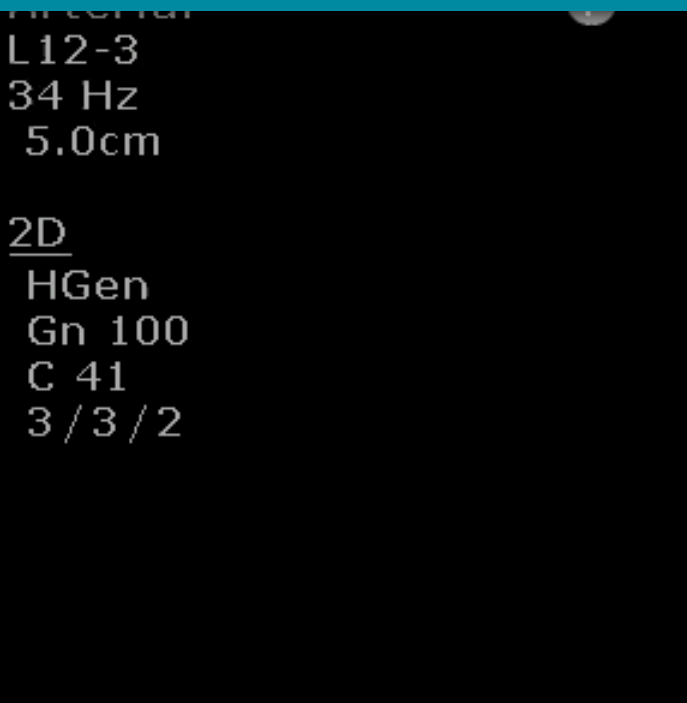
F 60~ 0.5-40 Hz W

PH100B CL P?

43F, palpitation & cold sweating



43F, palpitation & cold sweating

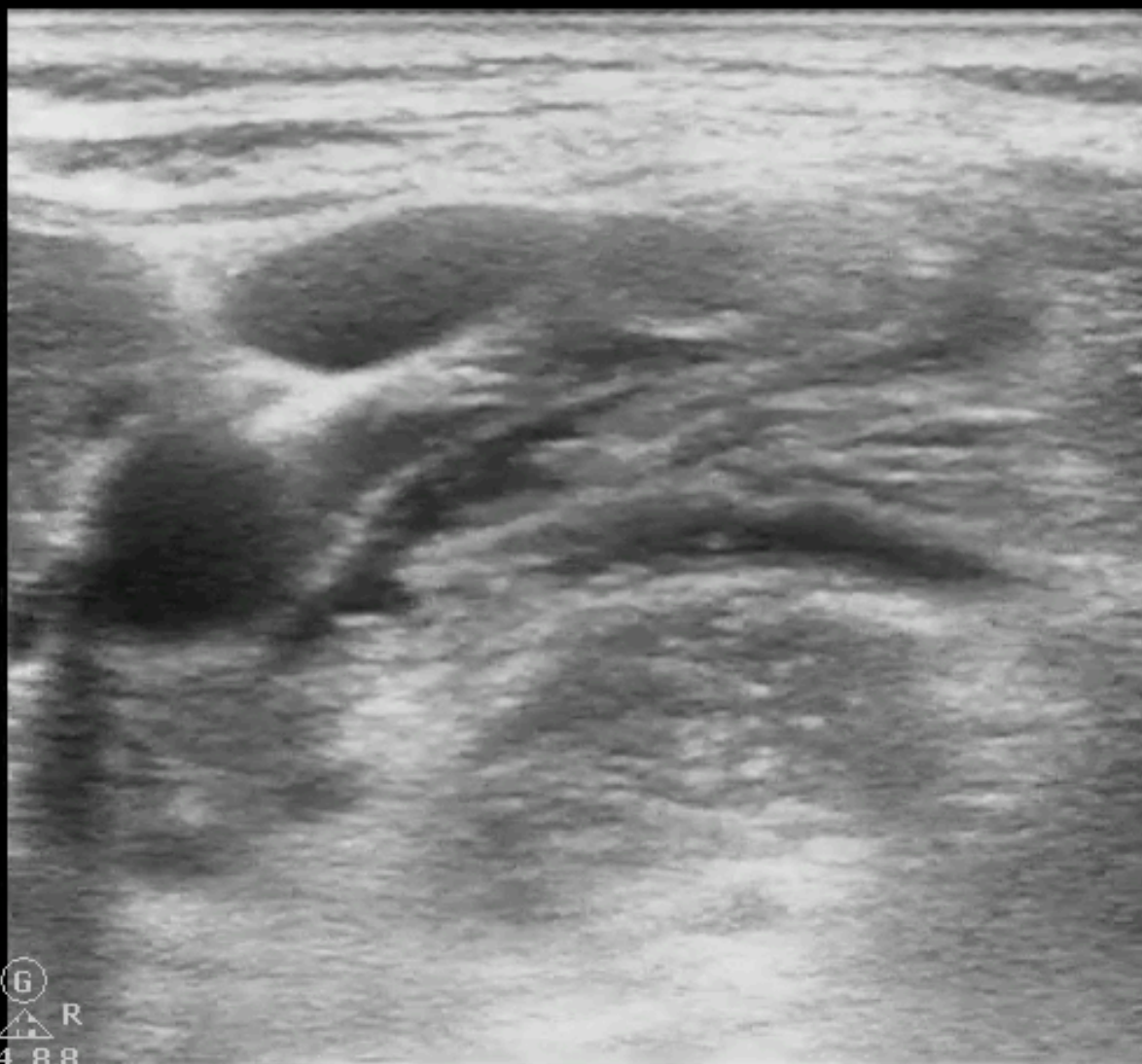


SGB

Arterial
L12-3
42 Hz
3.5cm

2D
HGen
Gn 98
C 41
3 / 3 / 2

P

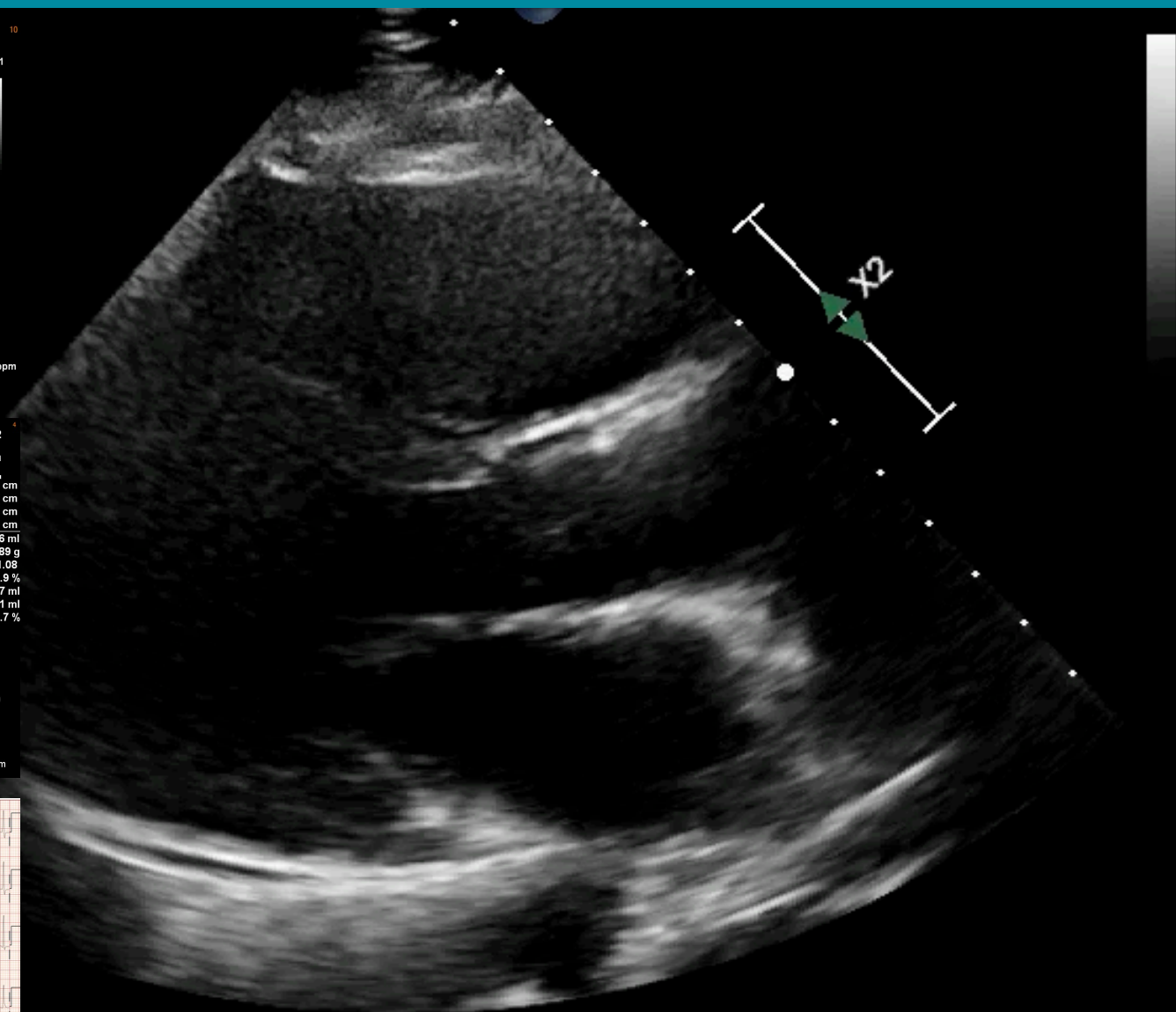
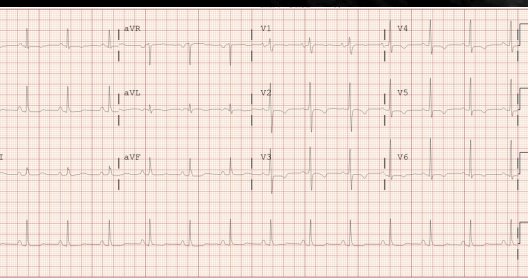
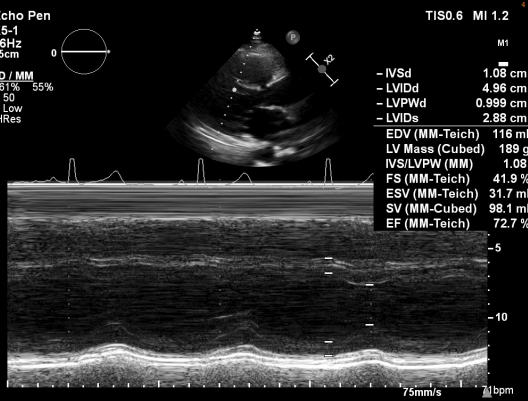
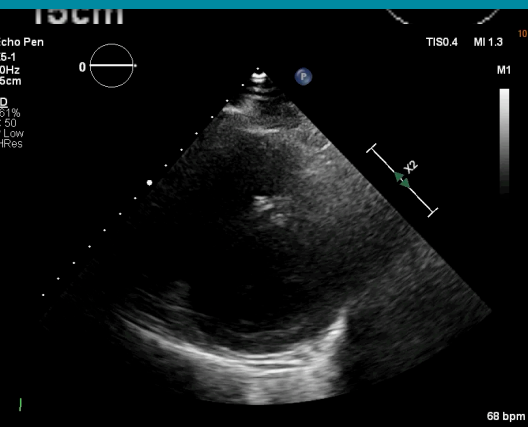


G
P R
4.4 8.8

2

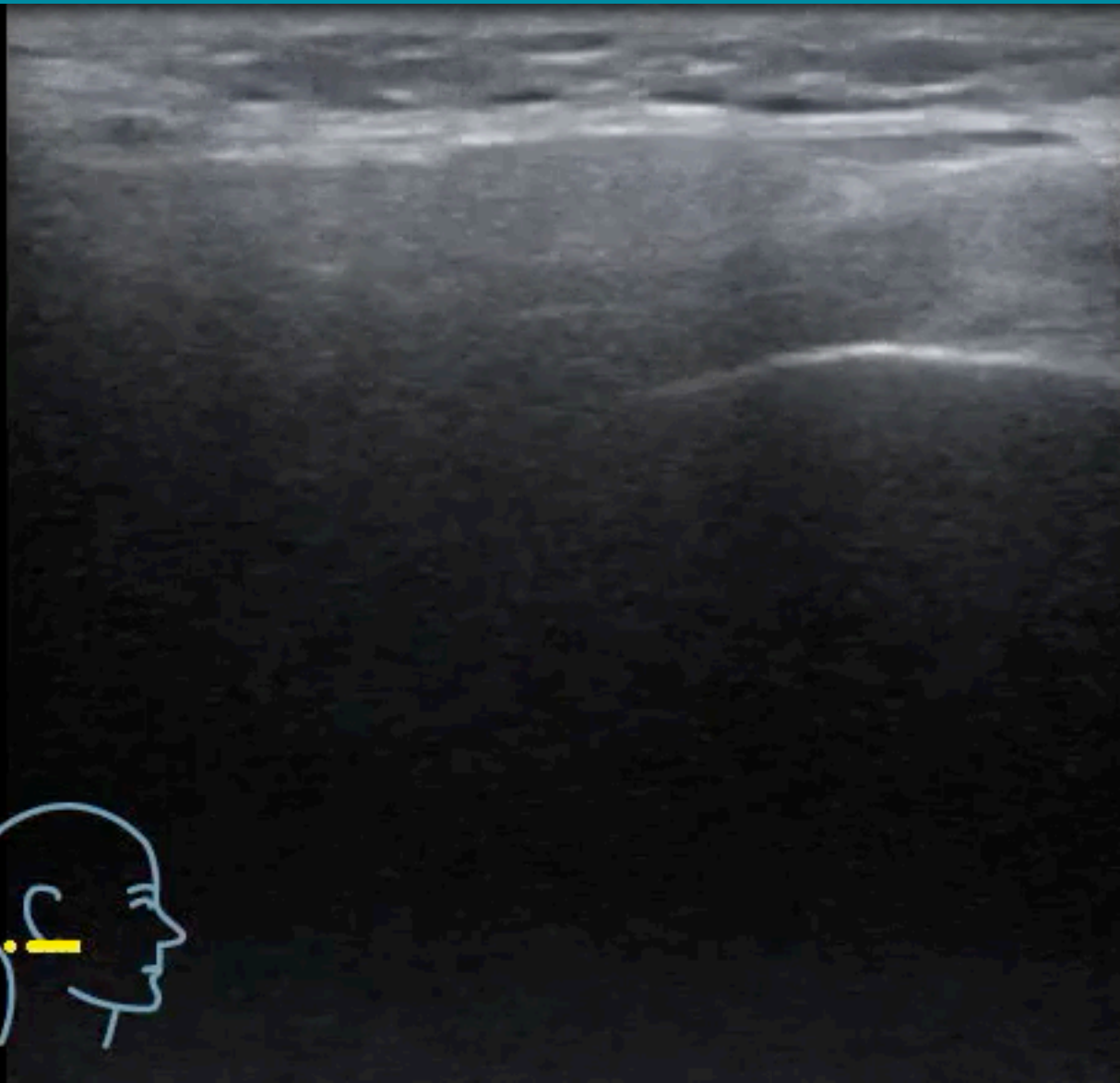
3.5cm

43F, palpitation & cold sweating



50M, 右下巴腫快一週，這三天更腫

2025/02/09
FH9.0
DB 105
PF19005CER
PR 51
D 4.0
G 59



IM: 0

-1

-2

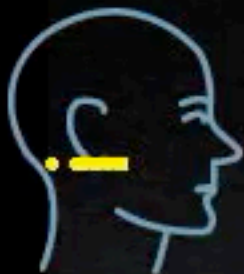-3

KV:

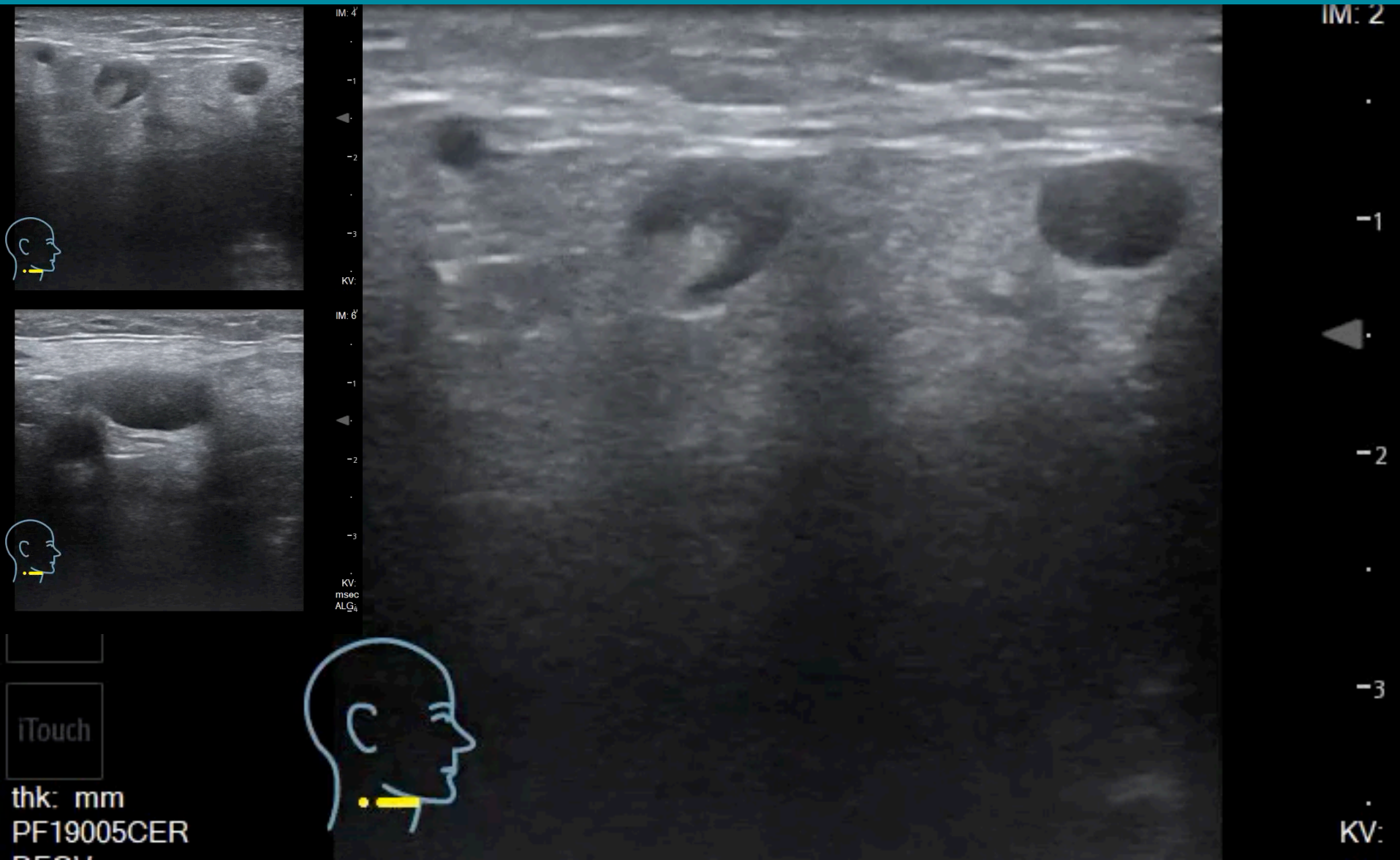
iNeedle

iTouch

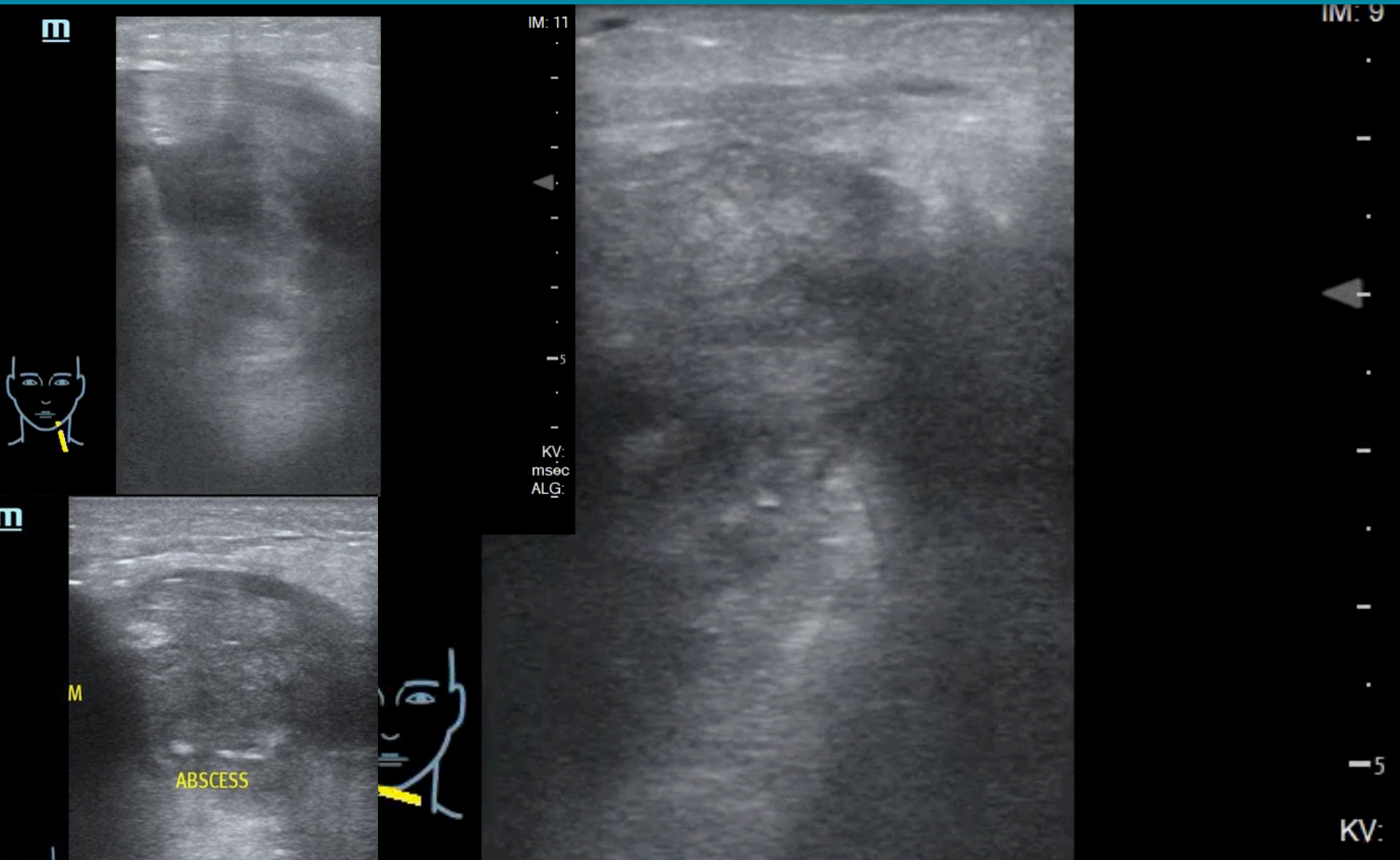
thk: mm
PF19005CER
REFM



50M, 右下巴腫快一週，這三天更腫



50M, 右下巴腫快一週，這三天更腫



SONOANATOMY CHECK LIST

Airway	Neck
Hyoid bone	Parotid gland
Epiglottis	Submandibular gland
Thyroid cartilage	Thyroid gland
Cricothyroid membrane	Tongue & Tonsil
Cricoid cartilage	CCA / IJV / VA
Tracheal cartilage	SCM / ASM / MSM
Cervical esophagus	Mandible / Mastoid / Vertebral body & TP