RESUSCITATIVE TEE

Resuscitative TEE Project

https://www.resuscitativetee.com/

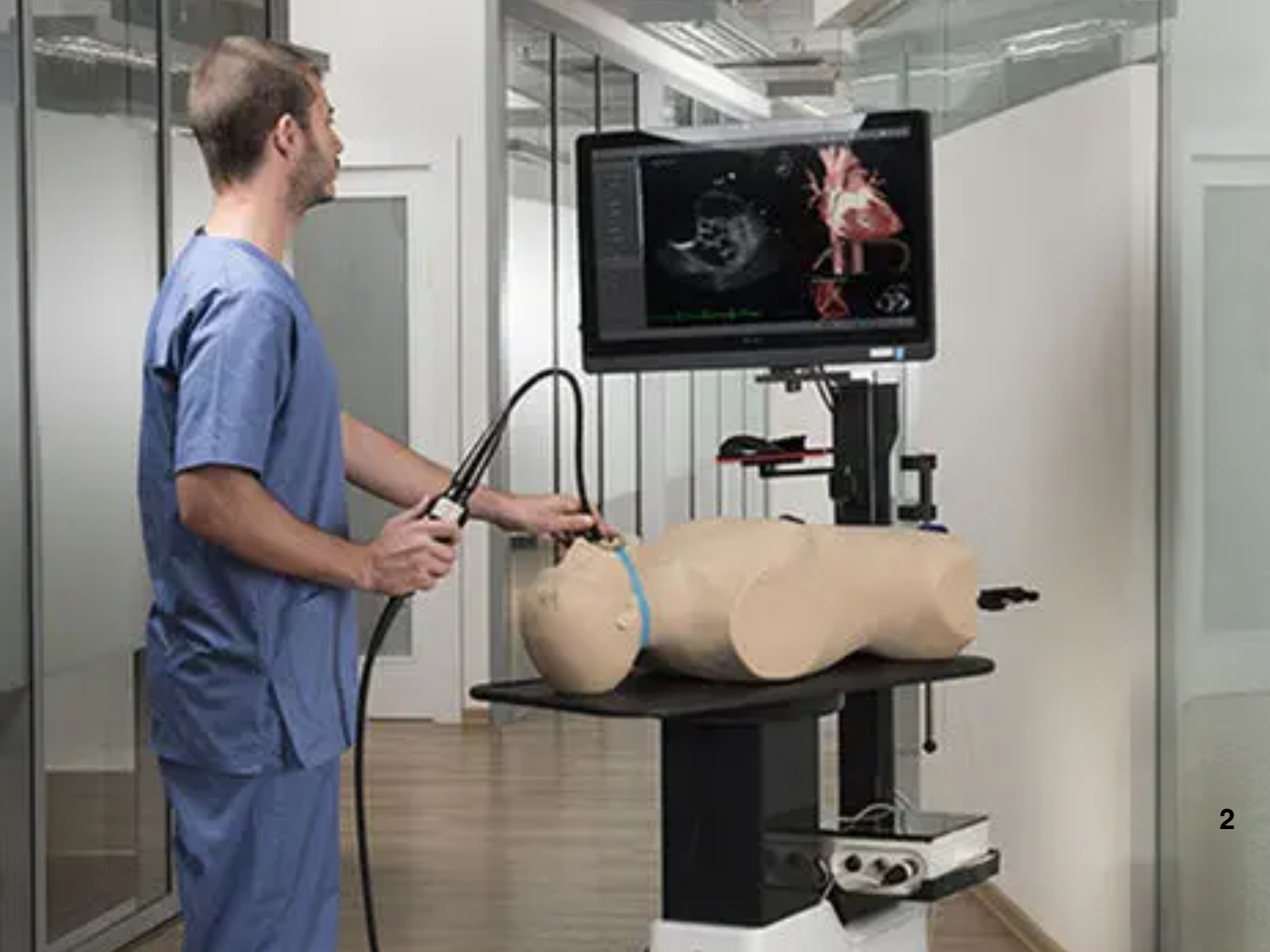

WHY TEE IN ER ?

Resuscitative TEE Project

https://www.resuscitativetee.com/

American College of Emergency Physicians®

ADVANCING EMERGENCY CARE

POLICY STATEMENT

Approved April 2017

Guidelines for the Use of Transesophageal Echocardiography (TEE) in the ED for Cardiac Arrest

Table 2 – Advantages and disadvantages of using TOE in place of TTE during cardiac arrest.

Advantages	Disadvantages
Higher image quality	More invasive
Excellent sonic windows, not limited by patient factors	Risk of injury
Continuous imaging, ability to optimise chest compressions in real time	Decreased availability in emergency setting
Decreased interruptions to chest compressions	Requires additional ultrasound training
Ability to obtain higher number of views and therefore greater anatomic scope	

中斷 壓胸 骨頭 肺臟 血管

American College of Emergency Physicians®

ADVANCING EMERGENCY CARE

POLICY STATEMENT

Guidelines for the Use of Transesophageal Echocardiography (TEE) in the ED for Cardiac Arrest

對象: 急救 / 插管患者

禁忌: 食道、氣管、頸部損傷

American College of Emergency Physicians®

ADVANCING EMERGENCY CARE

POLICY STATEMENT

Approved June 2023

Use of Transesophageal Echocardiography (TEE) in the ED for Shock, Cardiac Arrest, and Procedural Guidance

需具備資格

初學者: 25例 /TTE經驗: 10例

RESUSCITATION 203 (2024) 110372

Available online at ScienceDirect

Resuscitation

journal homepage: www.elsevier.com/locate/resuscitation

Review

Transoesophageal echocardiography in cardiac arrest: From the emergency department to the intensive care unit

Thomas Edmiston[a], *Fabio Sangalli*[b], *Hatem Soliman-Aboumarie*[c], *Pietro Bertini*[d], *Hannah Conway*[e], *Antonio Rubino*[f,*]

	Comprehensive TOE	Focused TOE (fTOE)	Resuscitative TOE (rTOE)
Level of competence	Comprehensive	Focused	Focused
Number of views	20–28 views	8 views	3 + 2 views
Scanning modalities	Advances Doppler modalities and 3D/4D	2D and colour Doppler to confirm significant valve disease	2D only to rule in/out possible causes for CA and guide resuscitation
Scope of exam	Broad curriculum	Critical haemodynamic instability	Cardiac arrest, peri-arrest conditions and major trauma
Setting	Echolab, interventional cardiology, cardiac ORs and ICU	Acute care setting and non-cardiac ORs	Acute care setting, emergency department, out-of-hospital

Review

Transoesophageal echocardiography in cardiac arrest: From the emergency department to the intensive care unit

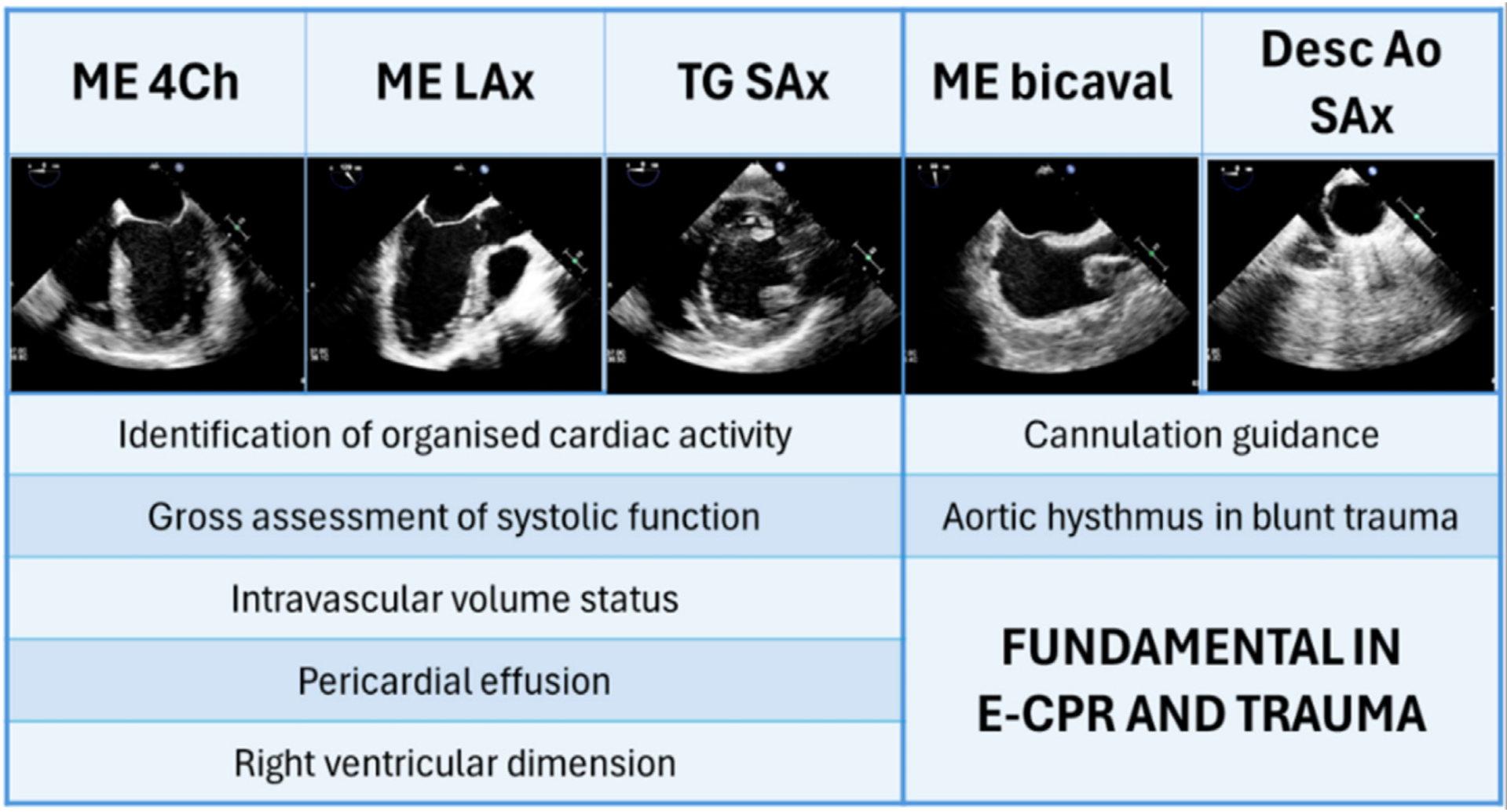

Fig. 1 – TOE Scanning protocol in cardiac arrest.

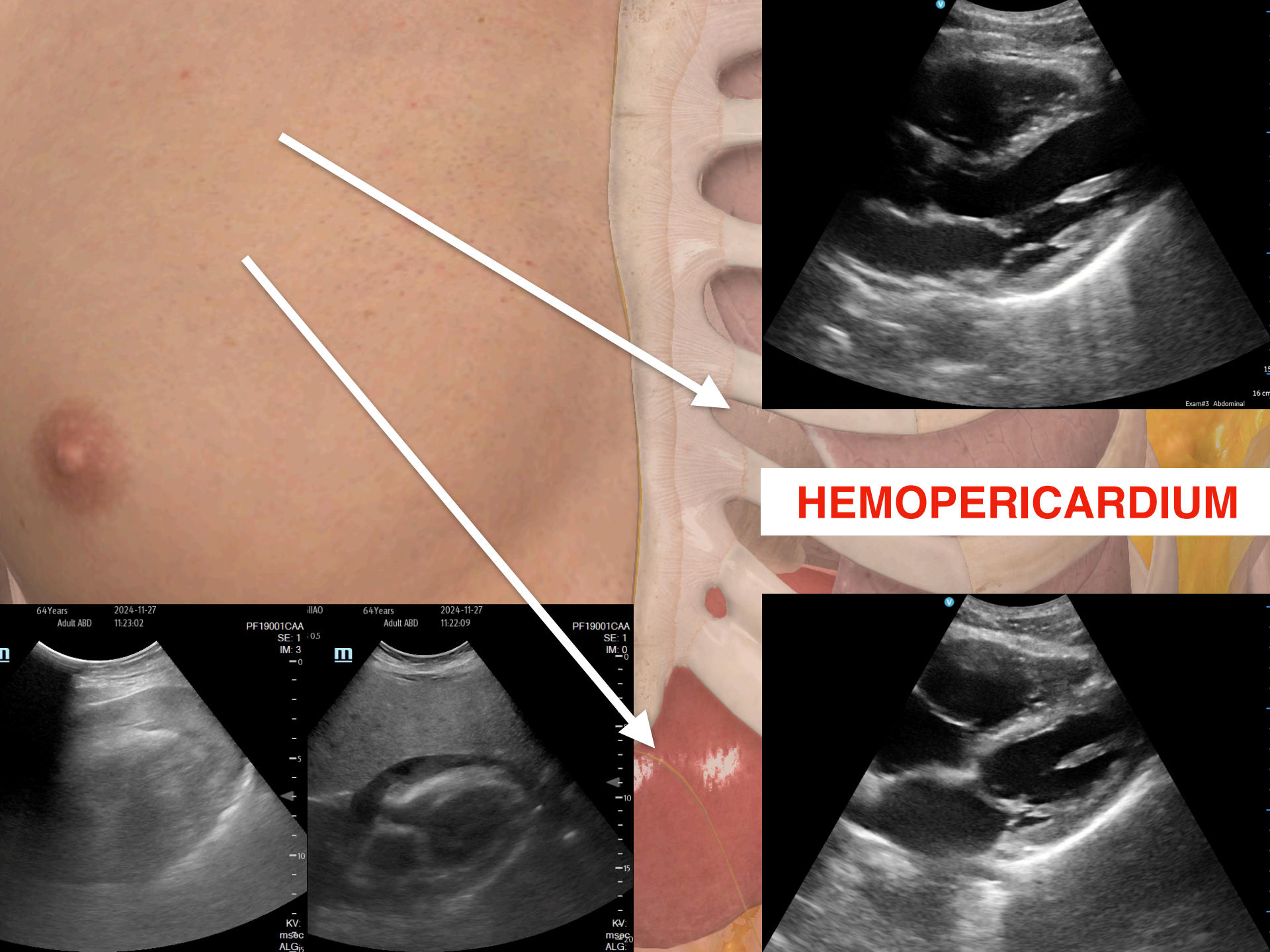
HEMOPERICARDIUM
64Years
Adult ABD
2024-11-27
11:23:02
PF19001CAA
SE: 1
IM: 3
64Years
Adult ABD
2024-11-27
11:22:09
PF19001CAA
SE: 1
IM: 0
Exam#3 Abdominal

3W5V

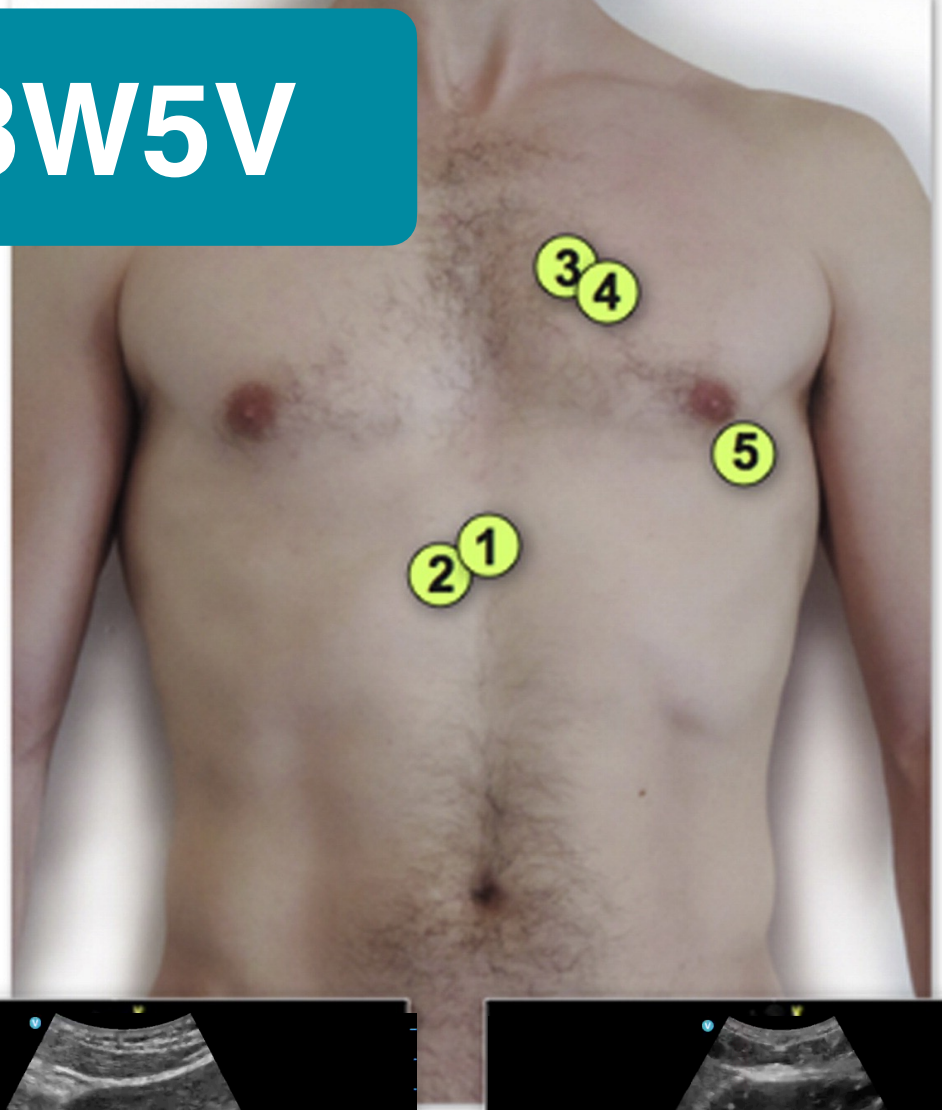
3
4
5
2
1

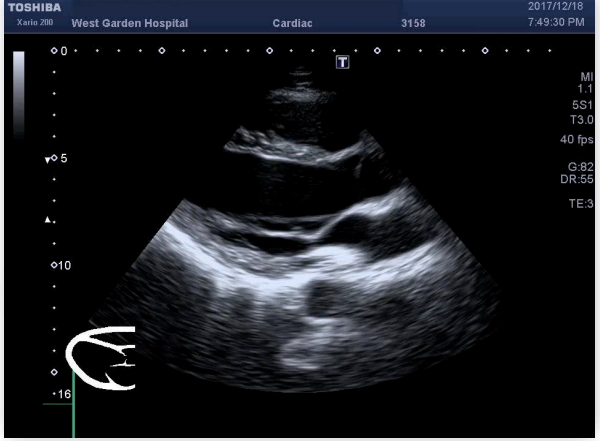
TOSHIBA
Xario 200
West Garden Hospital
Cardiac
3158
2017/12/18
7:49:30 PM
MI
1.1
5S1
T3.0
40 fps
G:82
DR:55
TE:3

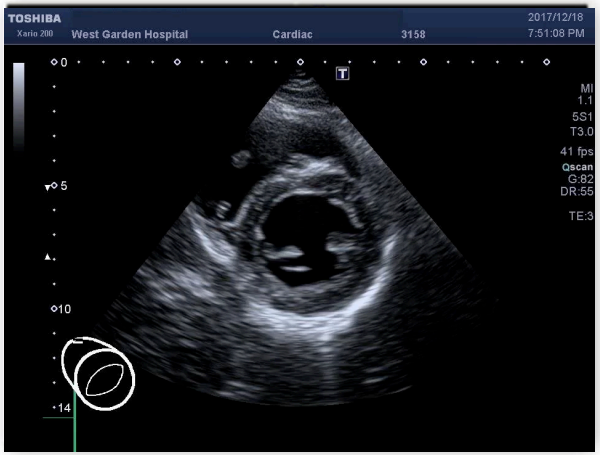
TOSHIBA
Xario 200
West Garden Hospital
Cardiac
3158
2017/12/18
7:51:08 PM
MI
1.1
5S1
T3.0
41 fps
Qscan
G:82
DR:55
TE:3

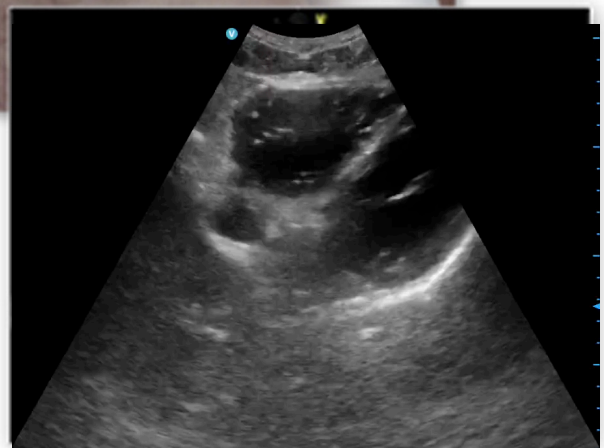

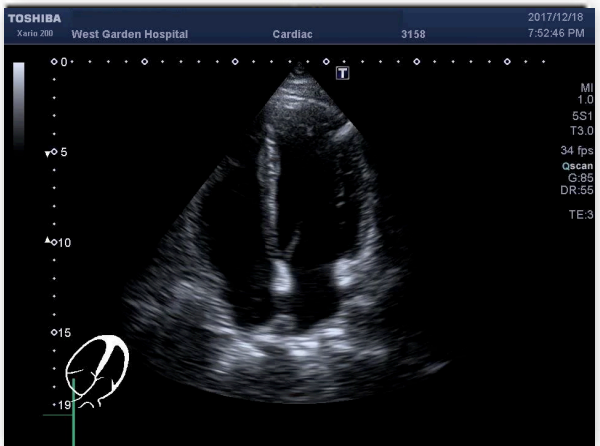
TOSHIBA
Xario 200
West Garden Hospital
Cardiac
3158
2017/12/18
7:52:46 PM
MI
1.0
5S1
T3.0
34 fps
Qscan
G:85
DR:55
TE:3


991
992


991

TEE 清消作業教學

TransEsophageal Echocardiography

TransEsophageal Echocardiography

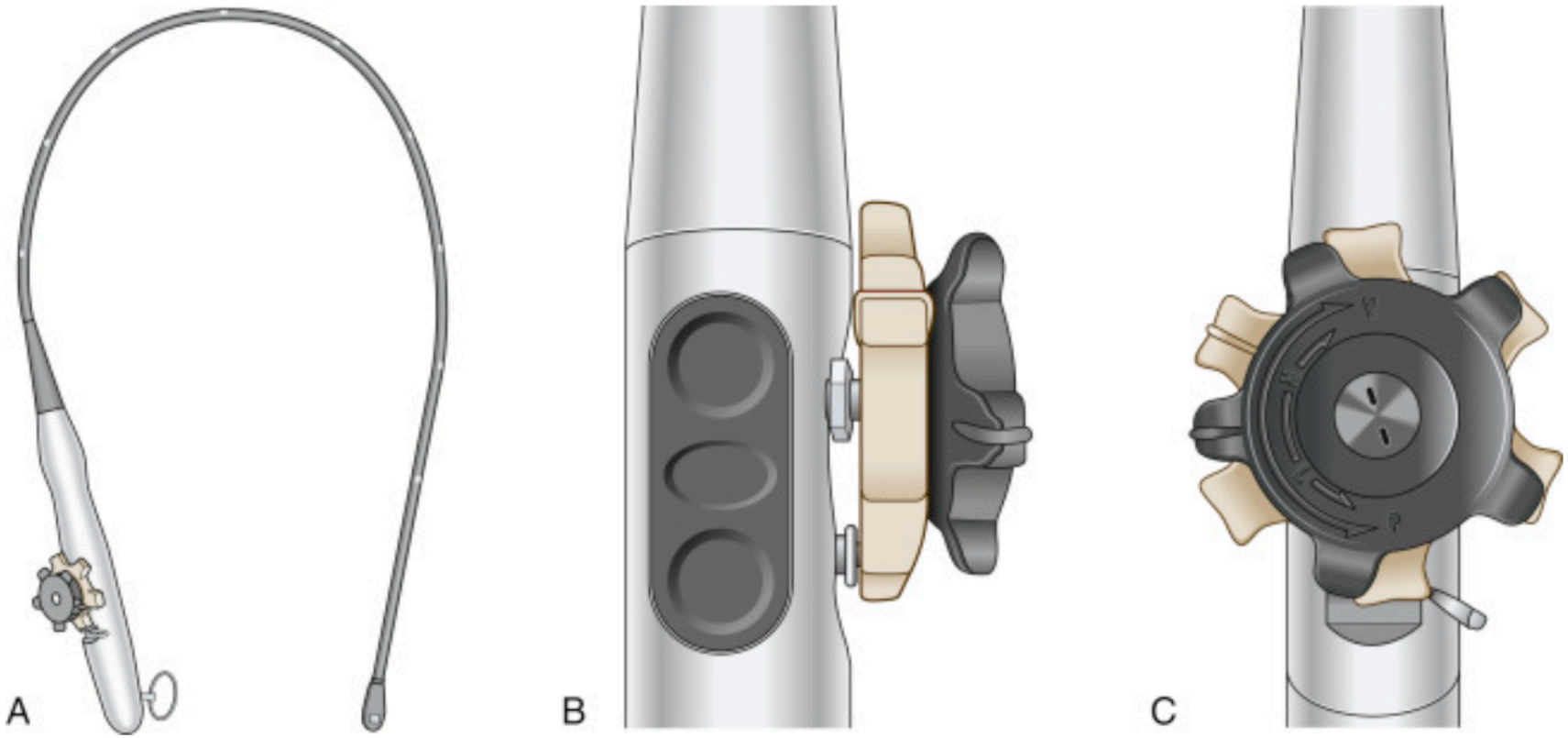

1主線: 前進後退加順逆轉動

2轉輪: 控制前後左右彎曲

2按鈕: 調節晶體角度 (0~180)

~ Radiology Key

How to perform TEE ?

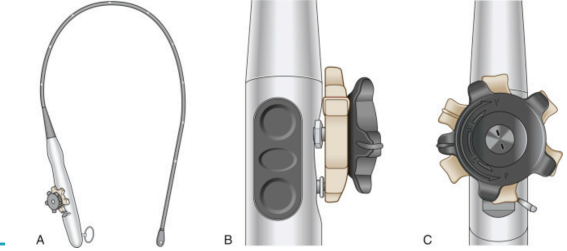

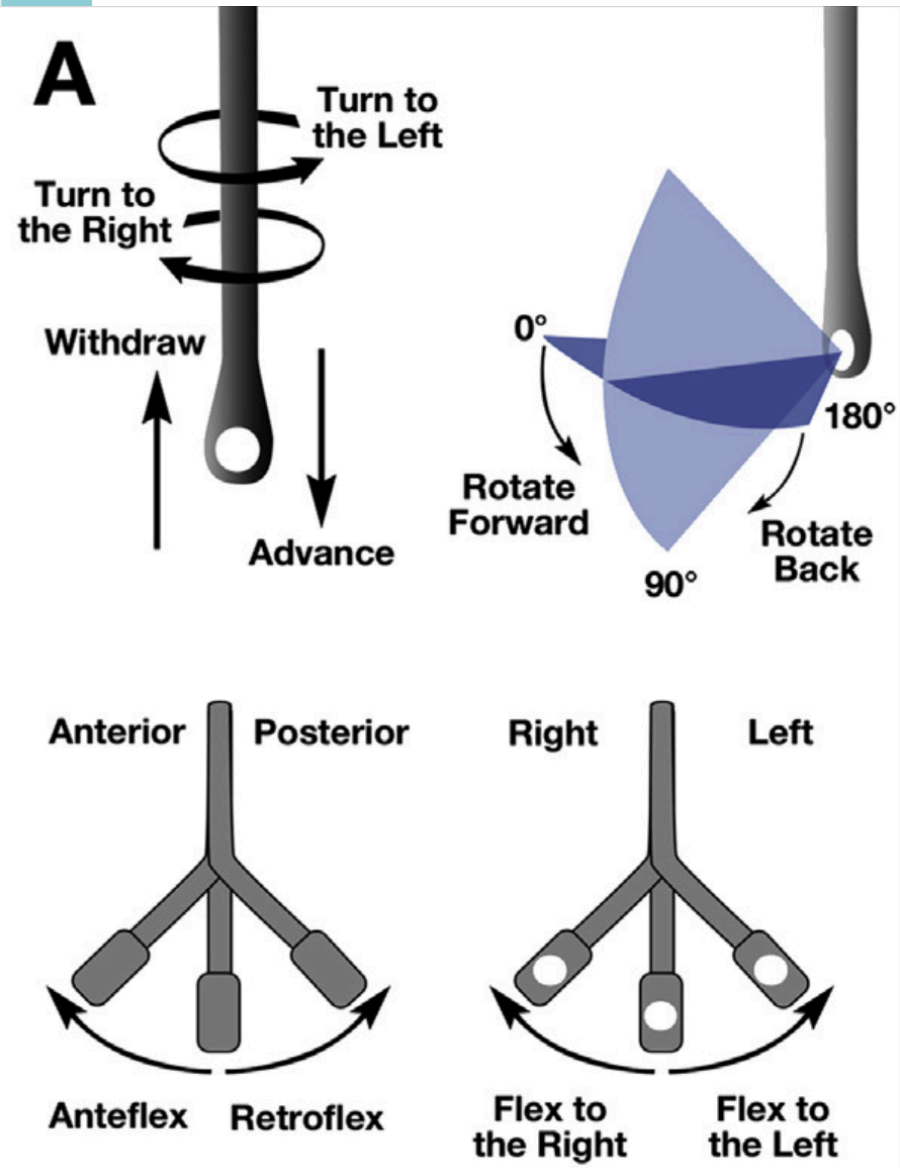

進和退

順逆轉

面朝前 晶體旋

前後彎

左右彎

ASE TEE guidelines 2019

How to perform TEE ?

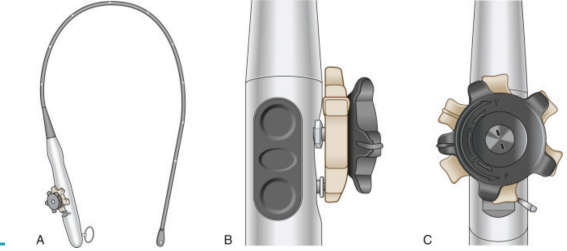

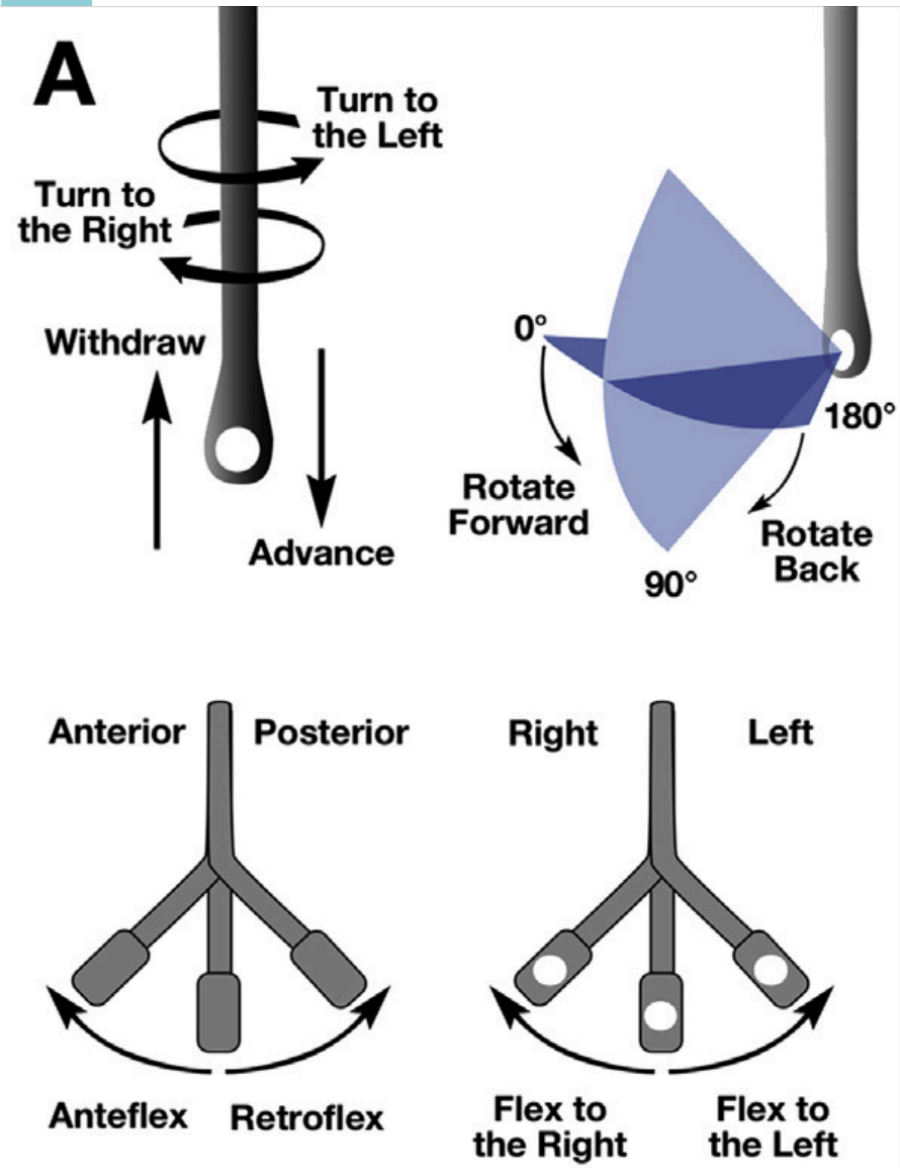

主幹線順時鐘: 看腔靜脈

大轉輪順時鐘: 向前彎曲

小轉輪順時鐘: 向右彎曲

ASE TEE guidelines 2019

How deep should we go ?

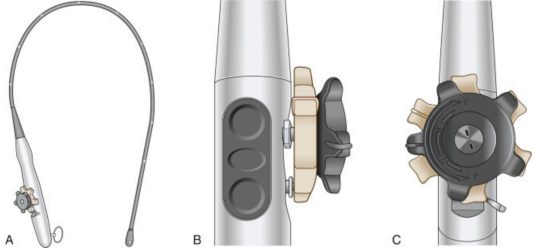

4

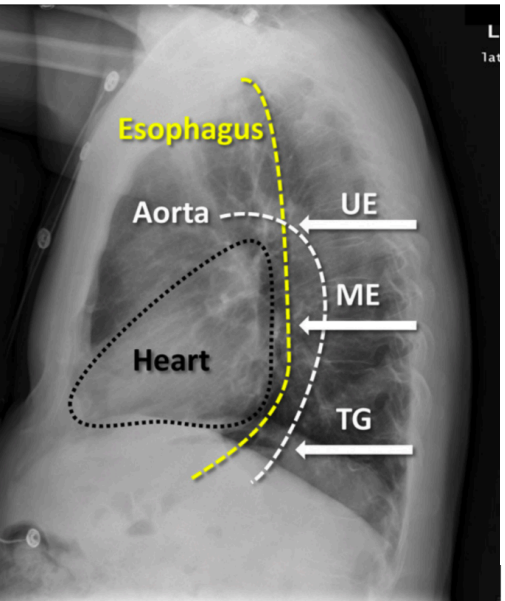

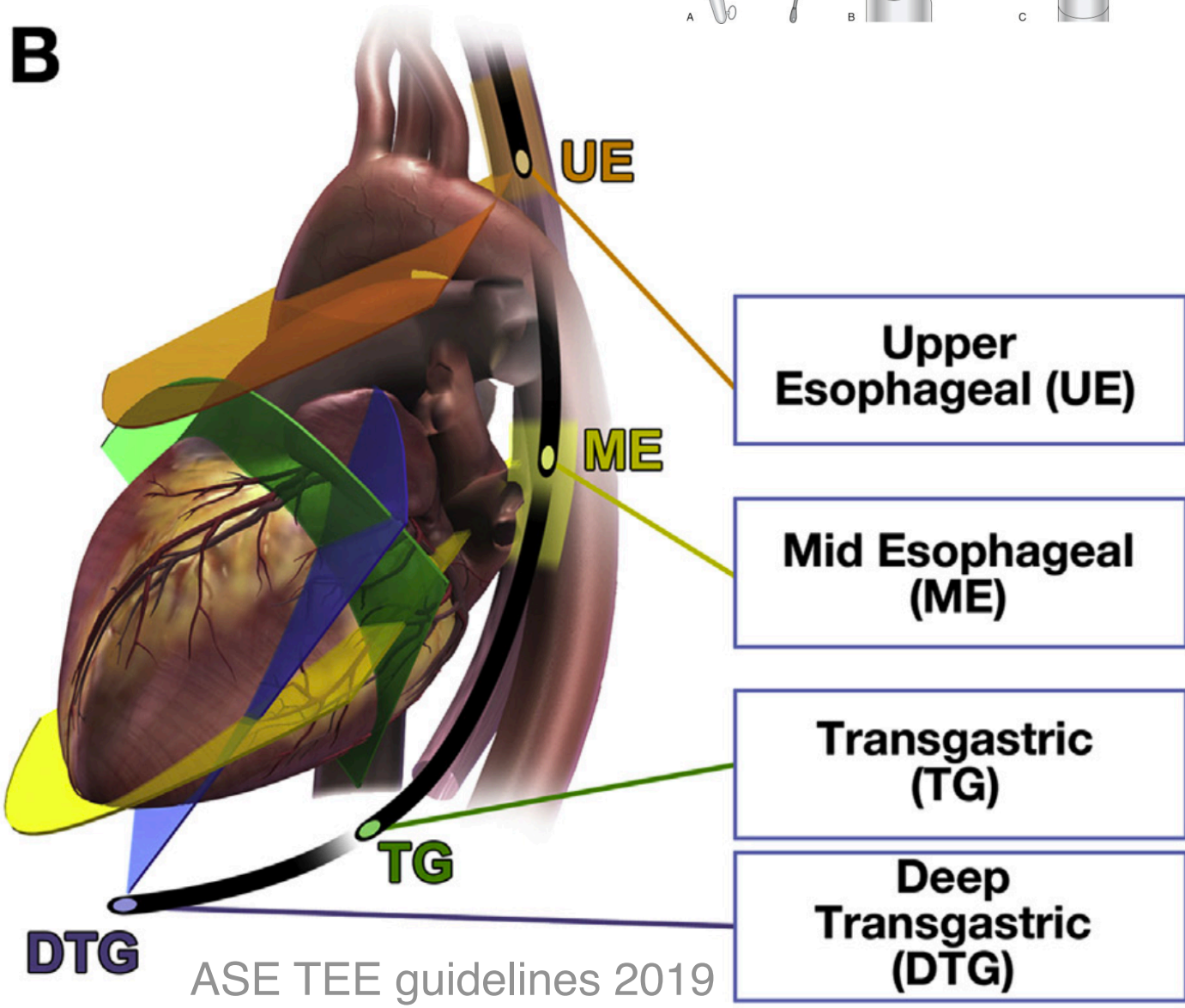

ASE TEE guidelines 2019

TEE Basic Views at different levels

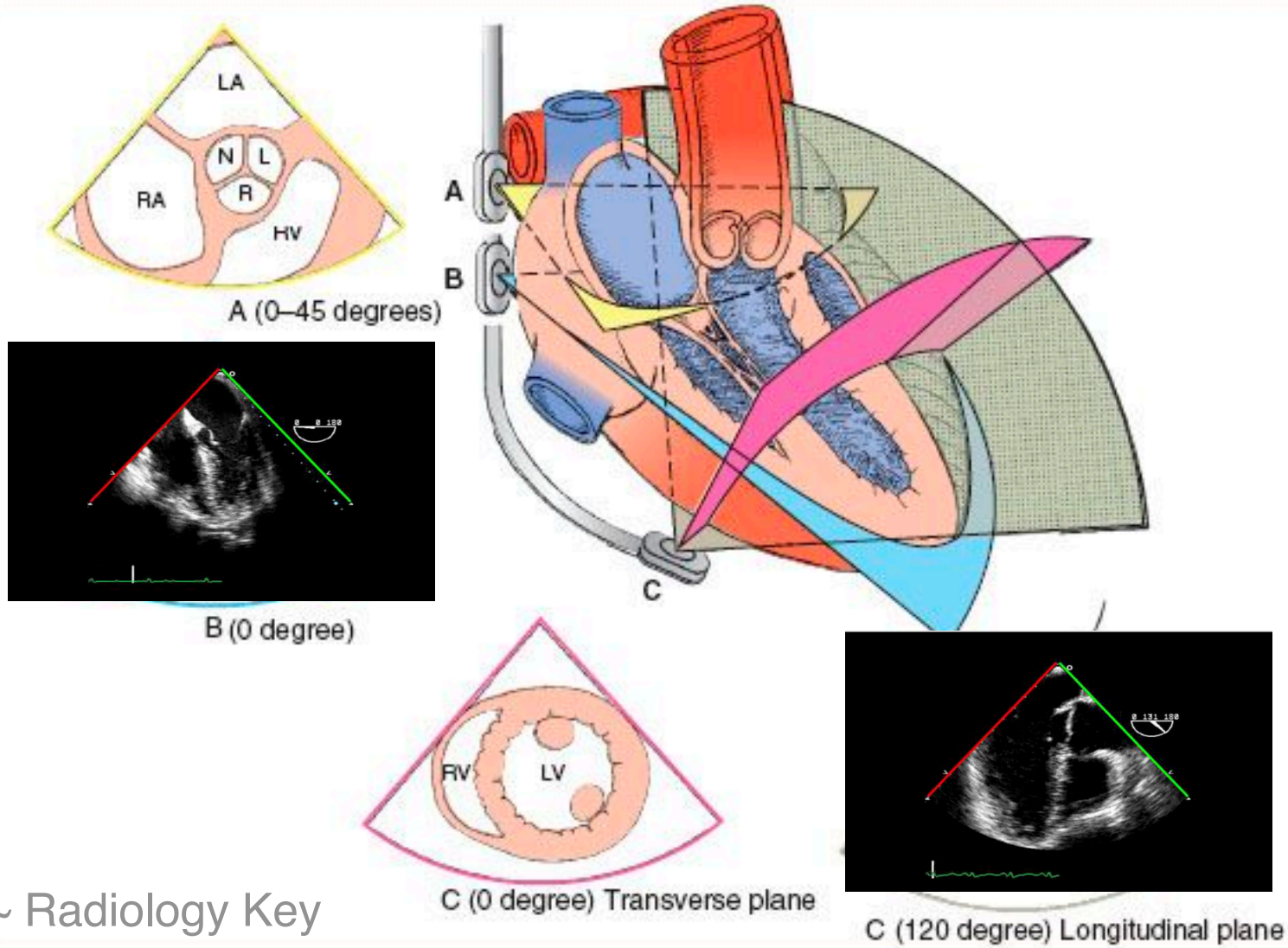

~ Radiology Key

How to define degree ?

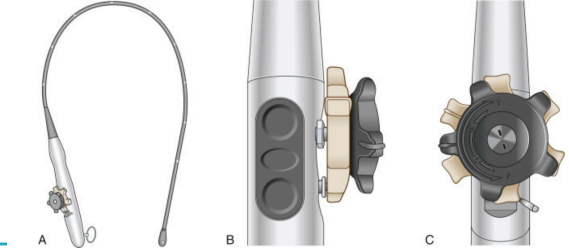

0° **90°** **180°**

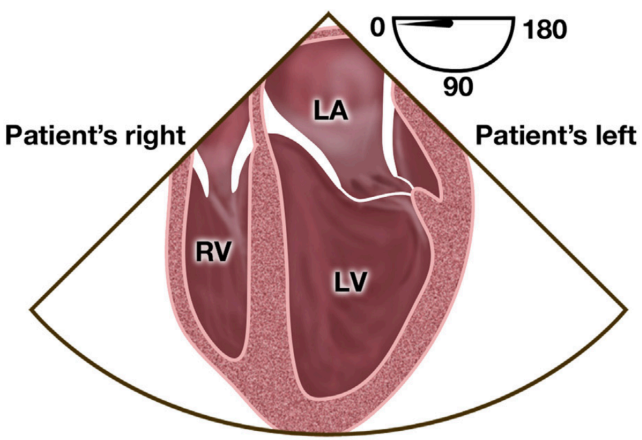

A. Multiplane angle 0

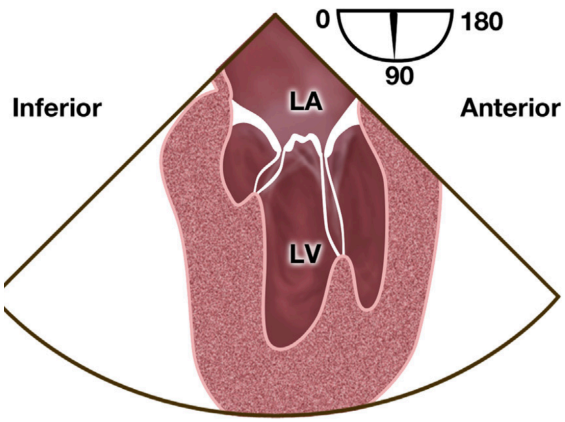

B. Multiplane angle 90

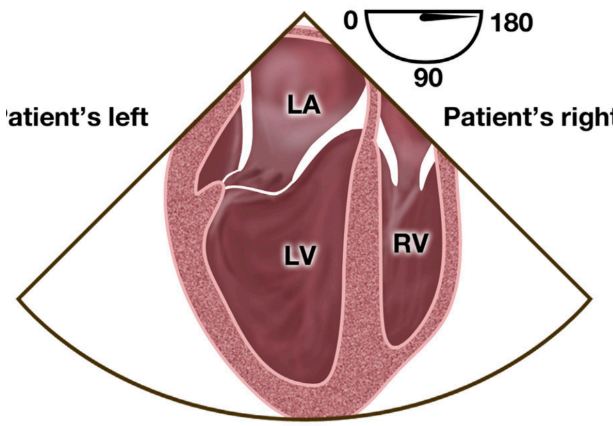

C. Multiplane angle 180

最接近TEE的腔室為 LA

ASE TEE guidelines 2019

確認0°和90°的定位

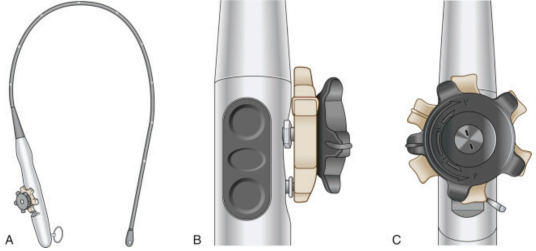

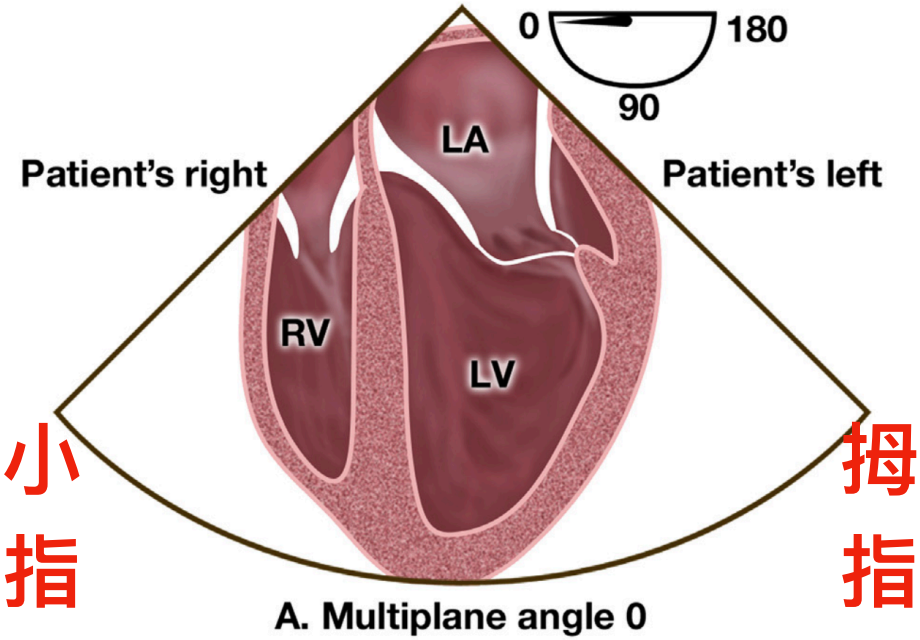

A. Multiplane angle 0

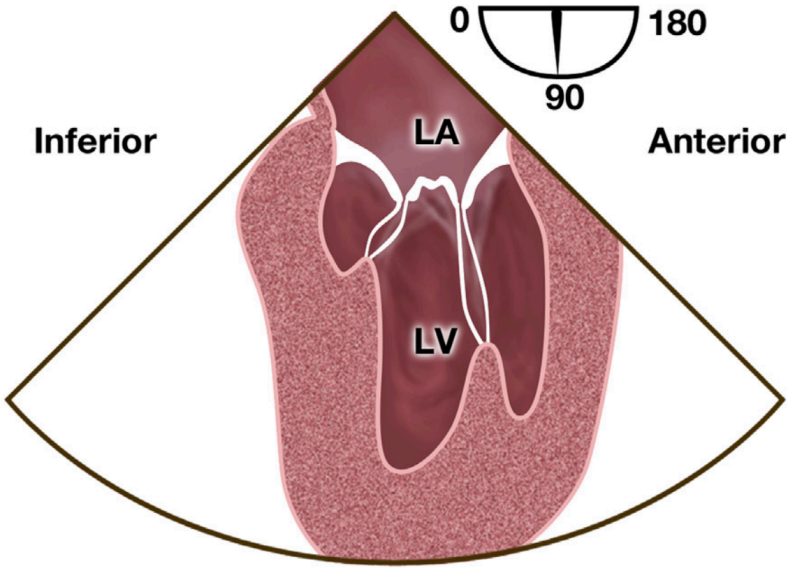

B. Multiplane angle 90

A

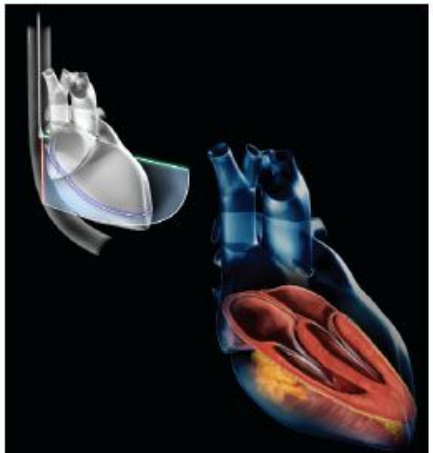

B

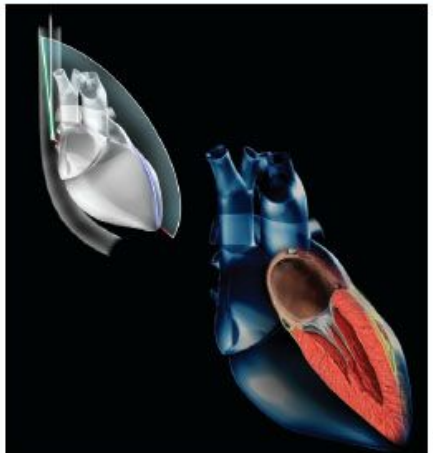

B

TEE: ME-4C (0°)

ME 4-Ch

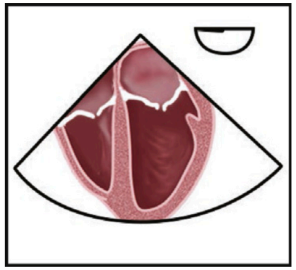

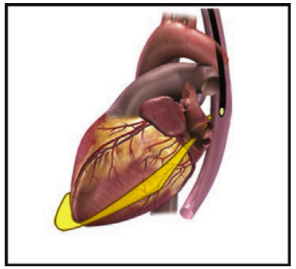

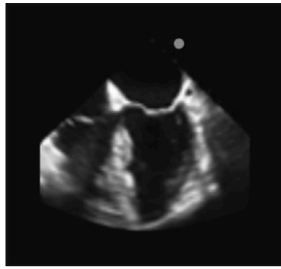

TTE: A4C

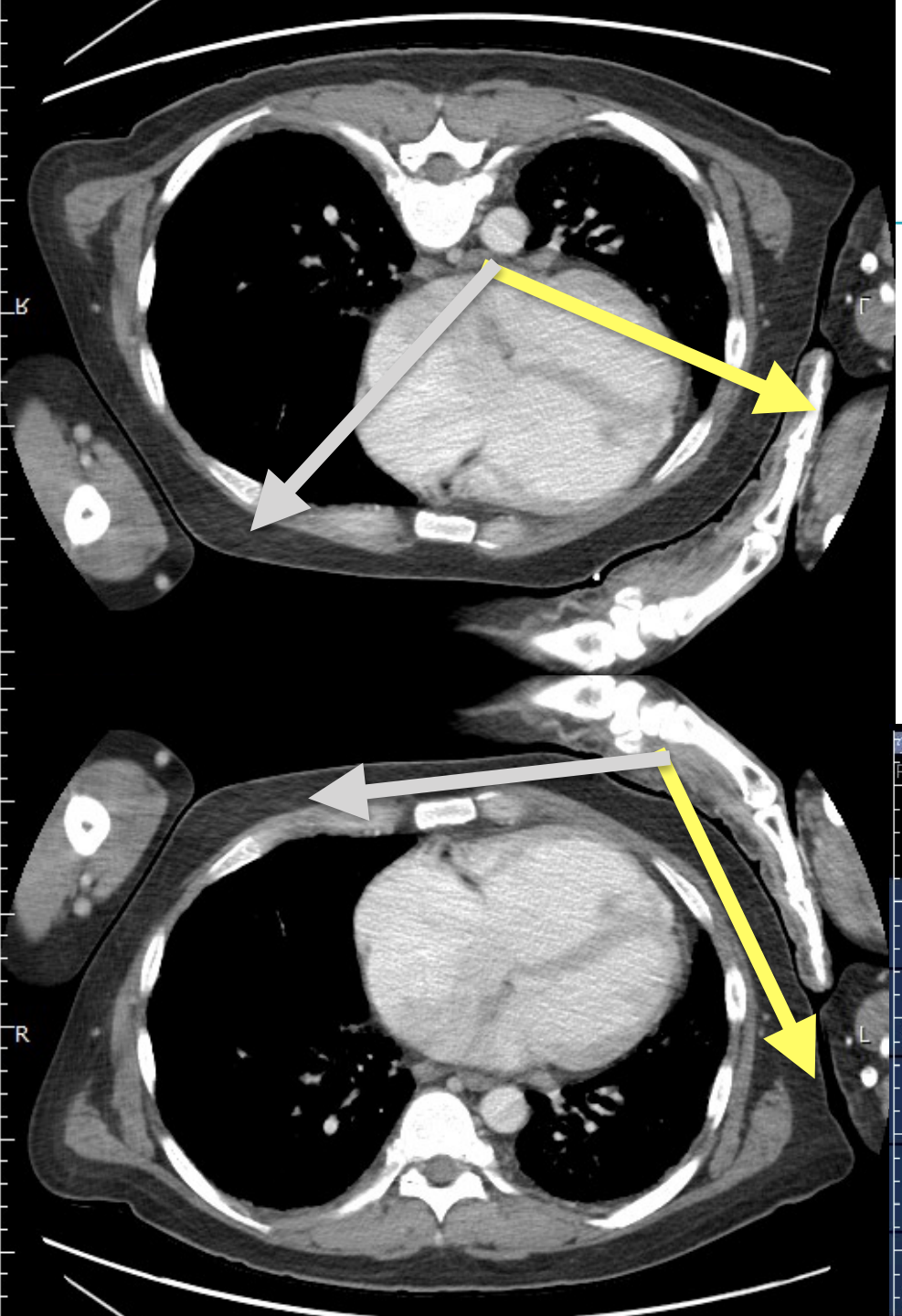

完整TEE 28 Views

ASE TEE guidelines 2019

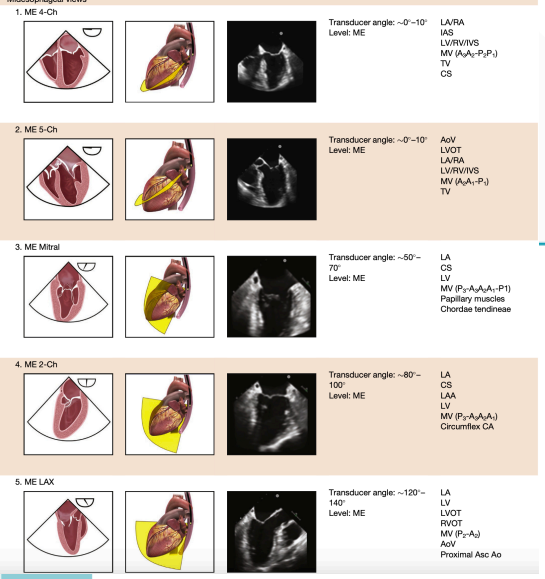

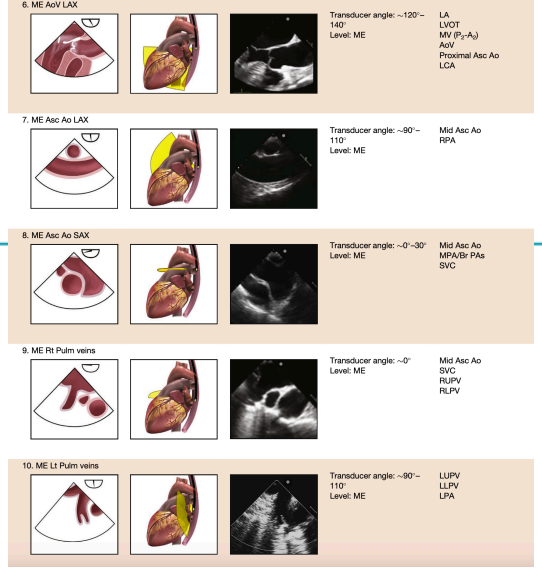

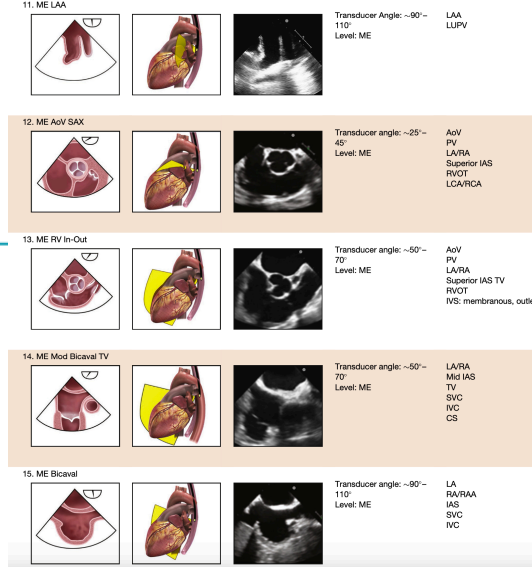

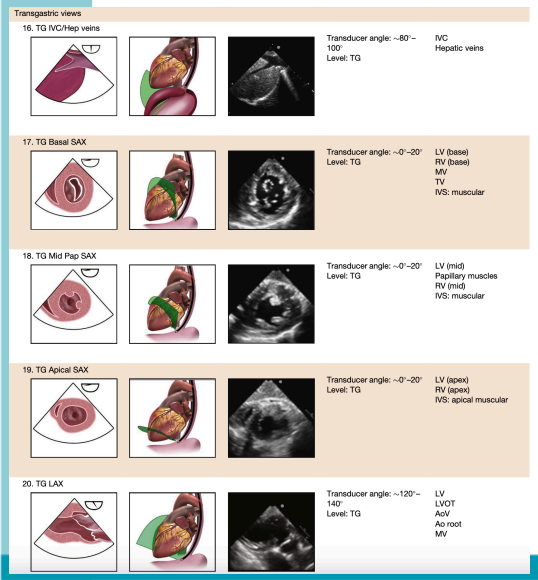

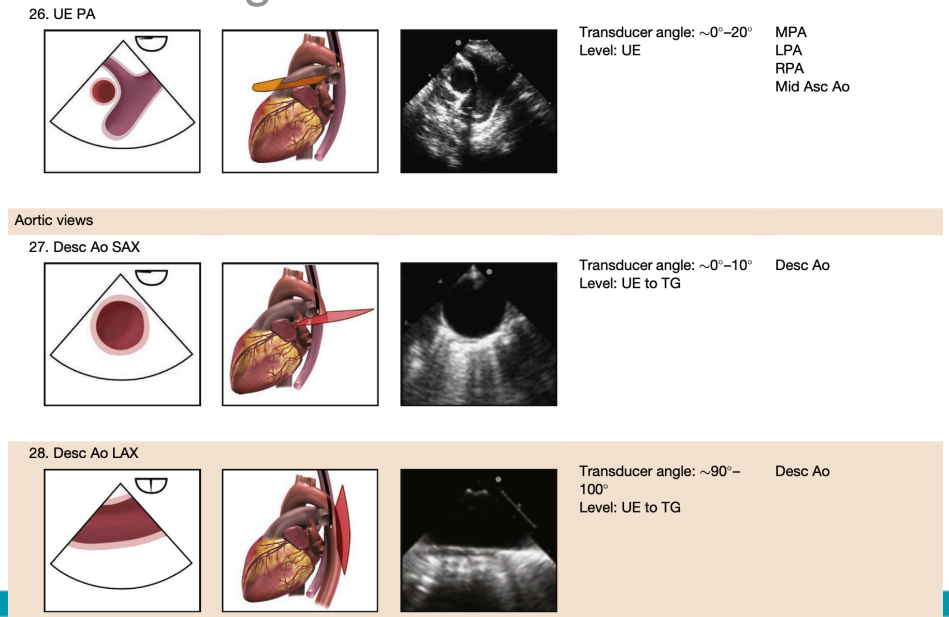

Obtaining the 20 Standard Transesophageal Echocardiography Views

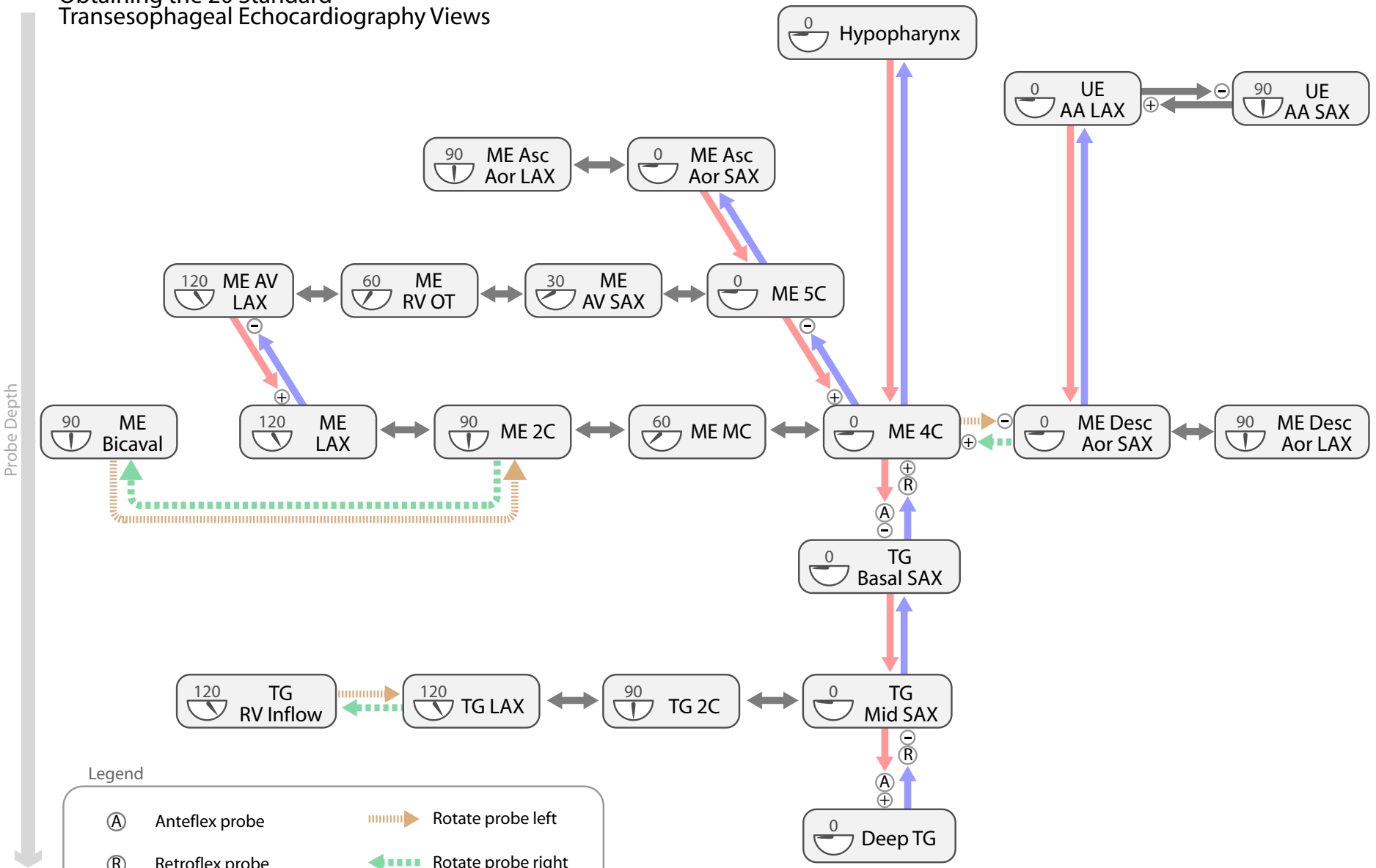

Legend

- Anteflex probe
- Retroflex probe
- Decrease omniplane depth (display depth)
- Increase omniplane depth (display depth)
- Change omniplane angle
- Rotate probe left
- Rotate probe right
- Increase probe depth
- Decrease probe depth
- Omniplane angle

2C - Two Chamber
4C - Four Chamber
5C - Five Chamber
AA - Aortic Arch
AV - Aortic Valve

Asc Aor - Ascending Aortic
Desc Aor - Descending Aortic
OT - Outflow Tract (Inflow-Outflow)
LAX - Long Axis
MC - Mitral Commissural

ME - Mid Esophageal
RV - Right Ventricle
SAX - Short Axis
TG - Transgastric
UE - Upper Esophageal

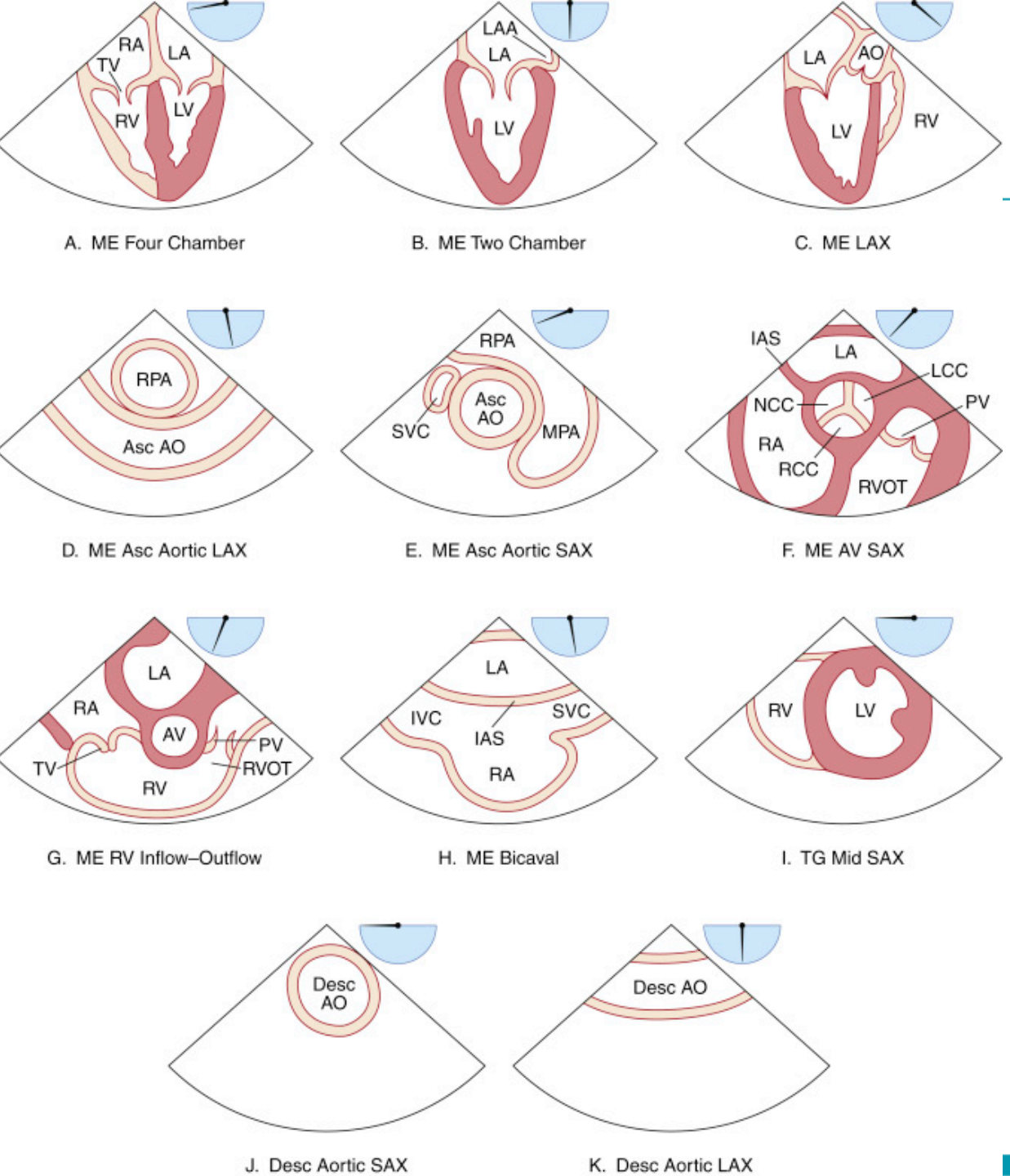

ASE/SCA 11 Basic Peri-OP Views

~ Radiology Key

RESUSCITATIVE TEE VIEW GUIDE

ME 4C

RA, LA, RV, LV
MV, TV, pericardium

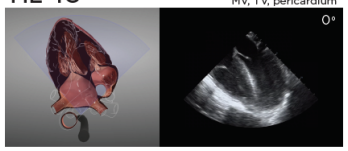

- Pathology pericardium
- RWMA
- LV/RV size & function
- Valvular pathology

TG SAX PAP

LV, RV

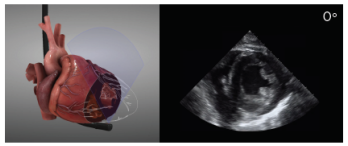

- LV function
- RWMA
- Pathology pericardium

ME 2C

LA, LV, MV, LAA

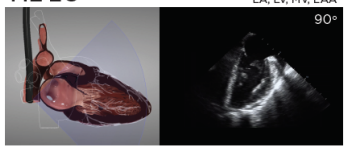

- Pathology LV
- LV apex
- Pathology MV
- Thrombus LAA

ME Asc Ao SAX

Right PA, Main PA

- Asc Aorta
- Pathology of PA
- Pulmonary embolism

ME RV I-O

LA, RA, TV, RVOT

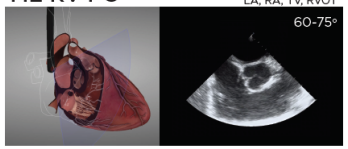

- Pathology RVOT
- Doppler TV

ME DTA LAX

DTA

- Flow reversal (AI)
- IABP
- Impella
- VA ECMO

ME LAX

LV, LA, MV, AV

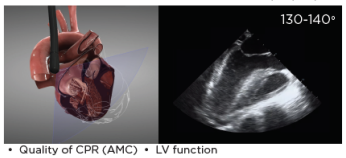

- Quality of CPR (AMC)
- LV function
- Pathology MV
- Pathology AV

ME Bicaval

IVC, RA, SVC

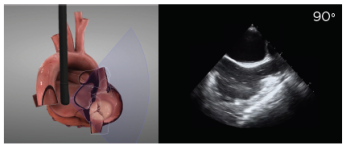

- Procedure guidance
- Venous guidewire
- ECMO
- Volume responsiveness

ME AV SAX

Cusps of AV, LA, RA, Pulmonic valve

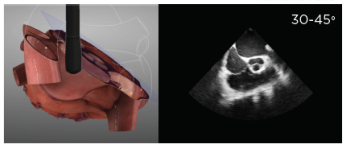

- Aortic stenosis
- ASD
- Pathology RVOT
- RCA and LMCA

ME Asc Ao LAX

Right PA Asc. Aorta

- Pulmonary embolism
- Pathology PA
- Outflow cannula
- LVAD

ME DTA SAX

DTA

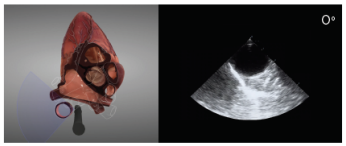

- IABP
- Impella
- VA ECMO

Deep TG SC

LV, RV, AV, MV, LVOT

- Doppler (VTI) LVOT

THE RESUSCITATIVE TEE WORKSHOP

www.resuscitativetee.com

INTELLIGENT ULTRASOUND

TEE-GUIDED CARDIAC ARREST RESUSCITATION

@Pandrus @FTeranMD

NON-SHOCKABLE RHYTHM
1. Epinephrine
2. Perform Cardiac Arrest Ultrasound

SHOCKABLE RHYTHM
1. Defibrillate / Cardiovert
2. Continue ACLS

TEE — CPR IN PROGRESS - PRIMARY SURVEY

- TEE Mid-Esophageal 4c / Trans-Gastric Short Axis → **Pericardial Effusion / Tamponade** → Pericardiocentesis
- TEE Mid-Esophageal Long Axis → **Inadequate LV compression / Obstruction LVOT** → Reposition AMC

TEE — RHYTHM CHECK 1

- TEE Mid-Esophageal 4c → **Ventricular Fibrillation** → Defibrillate
- TEE Mid-Esophageal 4c → **Pseudo-PEA** → Hs and Ts / Consider treating as profound shock

US — CPR IN PROGRESS - SECONDARY SURVEY

- ABDOMINAL FREE FLUID → **Free Fluid in Chest or Abdomen** → Consider surgical etiology
- AORTA → **AAA > 4 cm** → Consider ruptured AAA
- FEMORAL VEINS → **DVT** → Consider thrombolysis for PE

US TEE — RHYTHM CHECK 2

- PLEURA → **Pneumothorax** → Thoracostomy
- Mid-Esophageal 4c → **ROSC** → Post Cardiac Arrest Care
- Mid-Esophageal 4c → **Cardiac Standstill & $EtCO_2$ <20 mmHg after 20 minutes** → Terminate Resuscitation

TEE — ADDITIONAL VIEW

- Mid-Esophageal Bicaval → Procedural Guidance

TEE: Transesophageal Echocardiography

AMC: Area of Maximal Compression

US: Transthoracic / Transabdominal Ultrasound (i.e. Phased Array Probe)

RESUSCITATIVE TEE VIEW GUIDE

ME 4C

RA, LA, RV, LV
MV, TV, pericardium

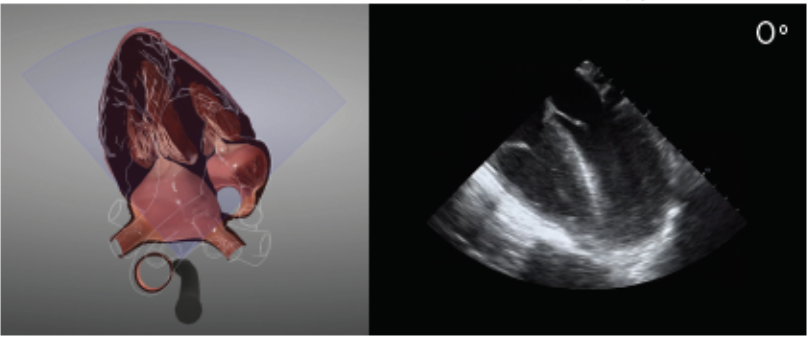

- Pathology pericardium
- RWMA
- LV/RV size & function
- Valvular pathology

ME LAX

LV, LA, MV, AV

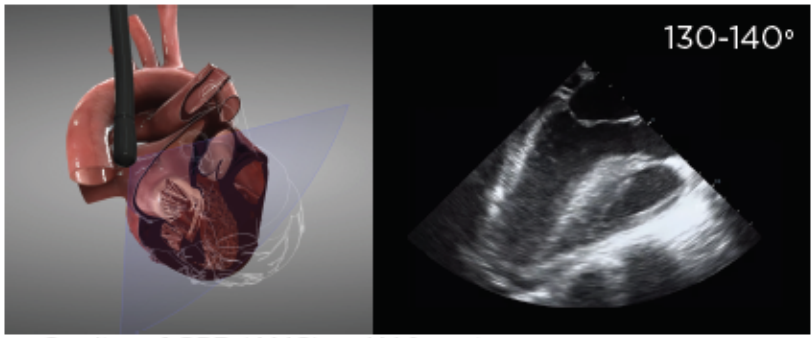

- Quality of CPR (AMC)
- LV function
- Pathology MV
- Pathology AV

TG SAX PAP

LV, RV

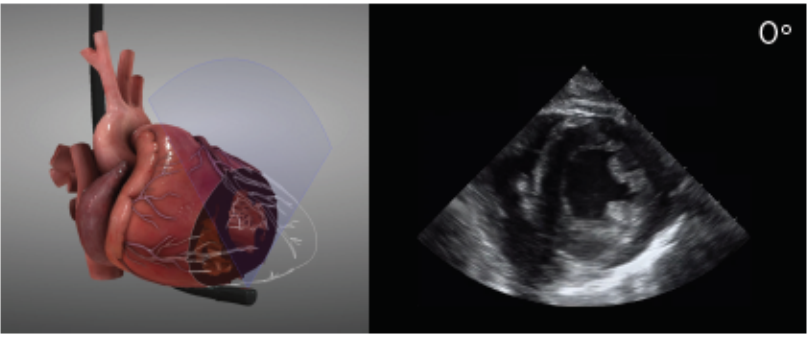

- LV function
- RWMA
- Pathology pericardium

ME Bicaval

IVC, RA, SVC

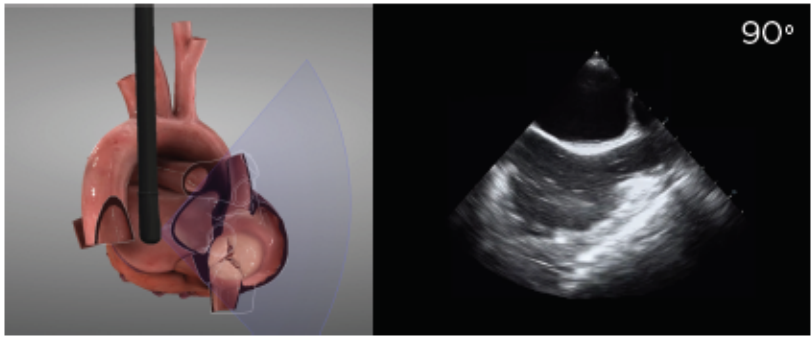

- Procedure guidance
- Venous guidewire
- ECMO
- Volume responsiveness

DOI: 10.1002/emp2.12758

JACEP OPEN
JOURNAL OF THE AMERICAN COLLEGE OF EMERGENCY PHYSICIANS OPEN
A GLOBAL JOURNAL OF EMERGENCY MEDICINE
Open Access
WILEY

CONCEPTS

Imaging

Transesophageal echocardiography in the emergency department: A comprehensive guide for acquisition, implementation, and quality assurance

Duncan McGuire DO[1] | Steven Johnson DO[1] | Nicholas Mielke BS[2] | Amit Bahl MD[1]

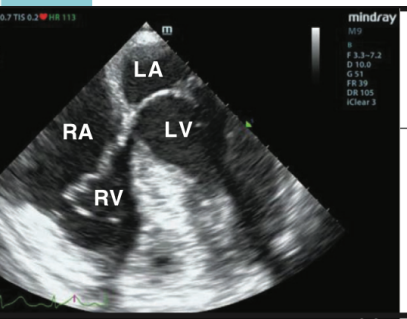

Midesophageal 4 chamber (ME 4C)

1. Insert 30-35 cm from incisors
2. Keep omniplane angle at 0°

Visualization:

- Gross left ventricular (LV) function
- LV:RV size
- Pericardial effusion
- Valvular pathology
- Regional wall motion abnormalities

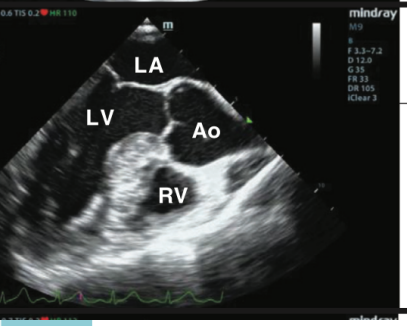

Midesophageal long axis (ME LAX)

1. Rotate omniplane 130-140°

Visualization:

- LV connecting to the LV outflow tract and the aortic valve
- Assess quality of compressions in cardiac arrest
- Pathology of mitral and aortic valve

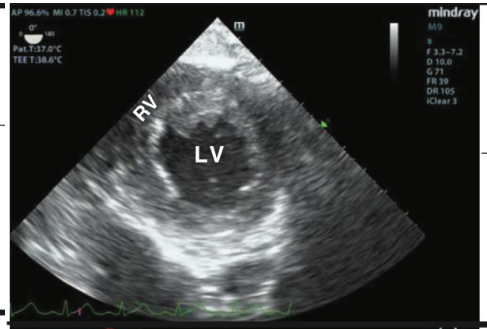

Transgastric short axis (TG SAX)

1. Adjust omniplane back to 0°
2. Advance the probe to a depth of 40-45cm while applying gentle anteflexion

Visualization:

- Gross LV:RV ratio
- Interventricular septal bowing
- Regional LV wall motion abnormalities
- Pericardial effusion

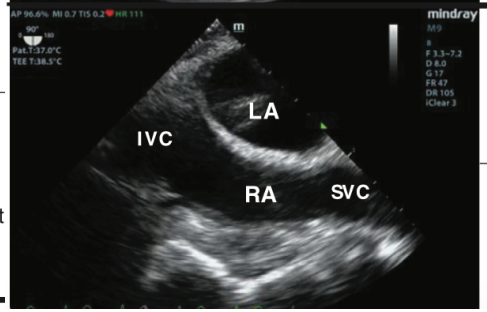

Midesophageal bicaval (ME Bicaval)

1. Withdraw probe to depth of 30-35cm (yielding ME 4C view)
2. Rotate omniplane 90°

Visualization:

- ECMO cannulation
- Guidewire or transvenous pacemaker insertion

ME 4C view (0°) (定位點)

ME LAX view (120°) (CPR 品質)

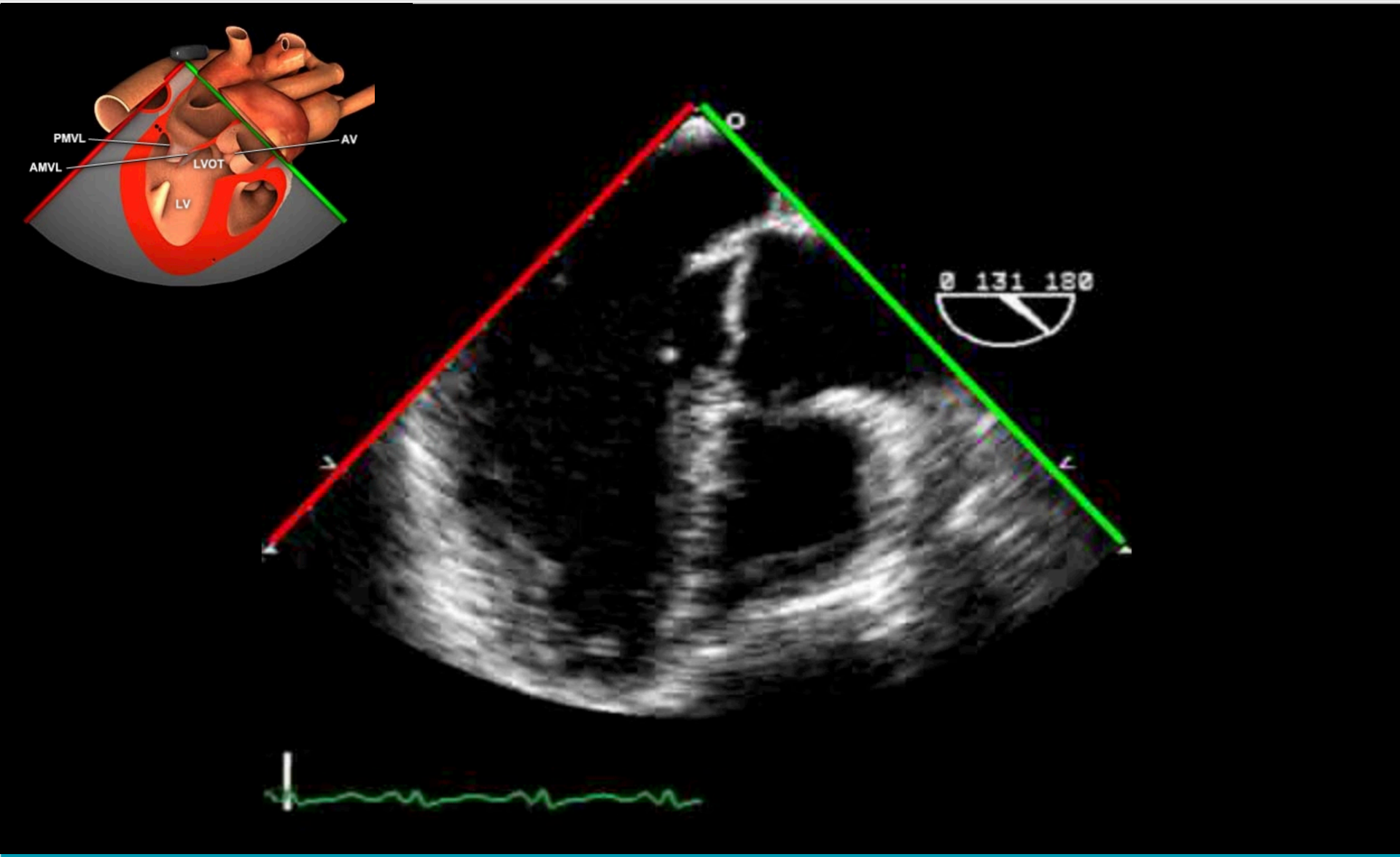

ME Bicaval view (90°)(管路/容積)

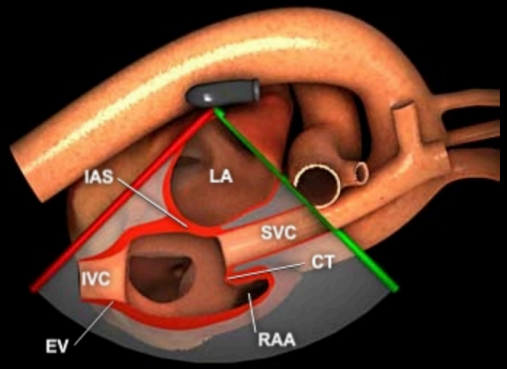

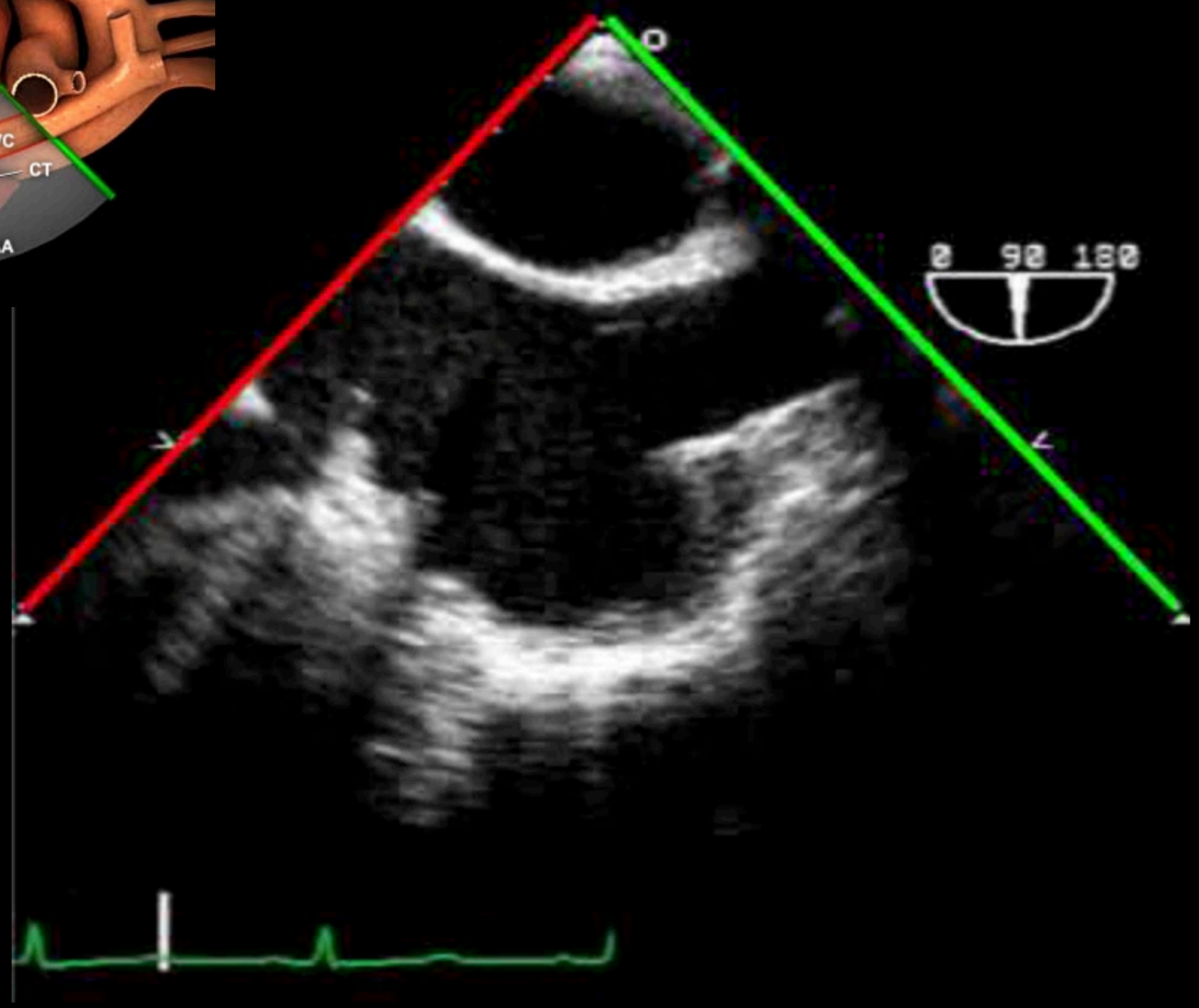

ME Descending aorta SAX view (逆轉向身後)

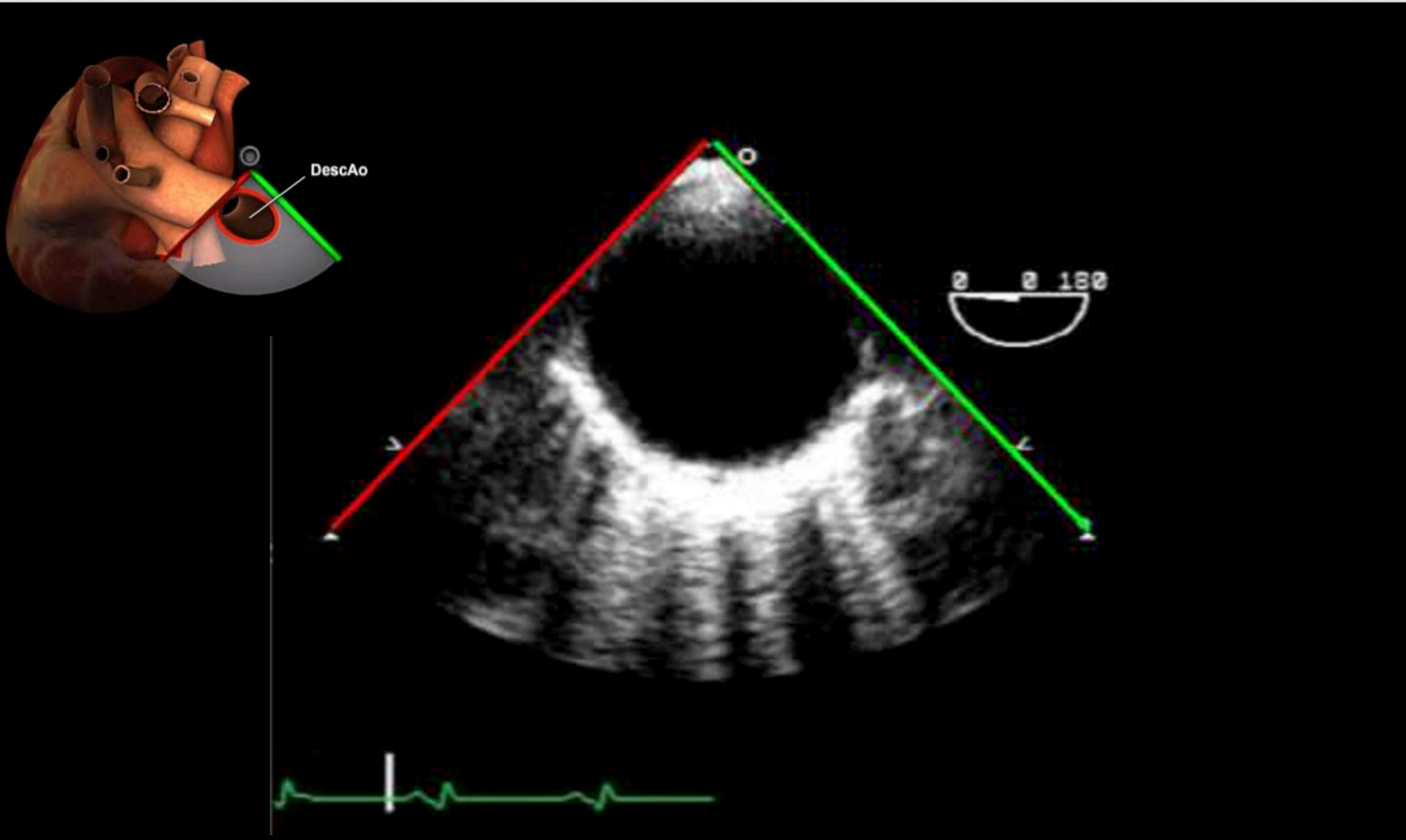

ME Descending aorta LAX view(逆轉向身後)

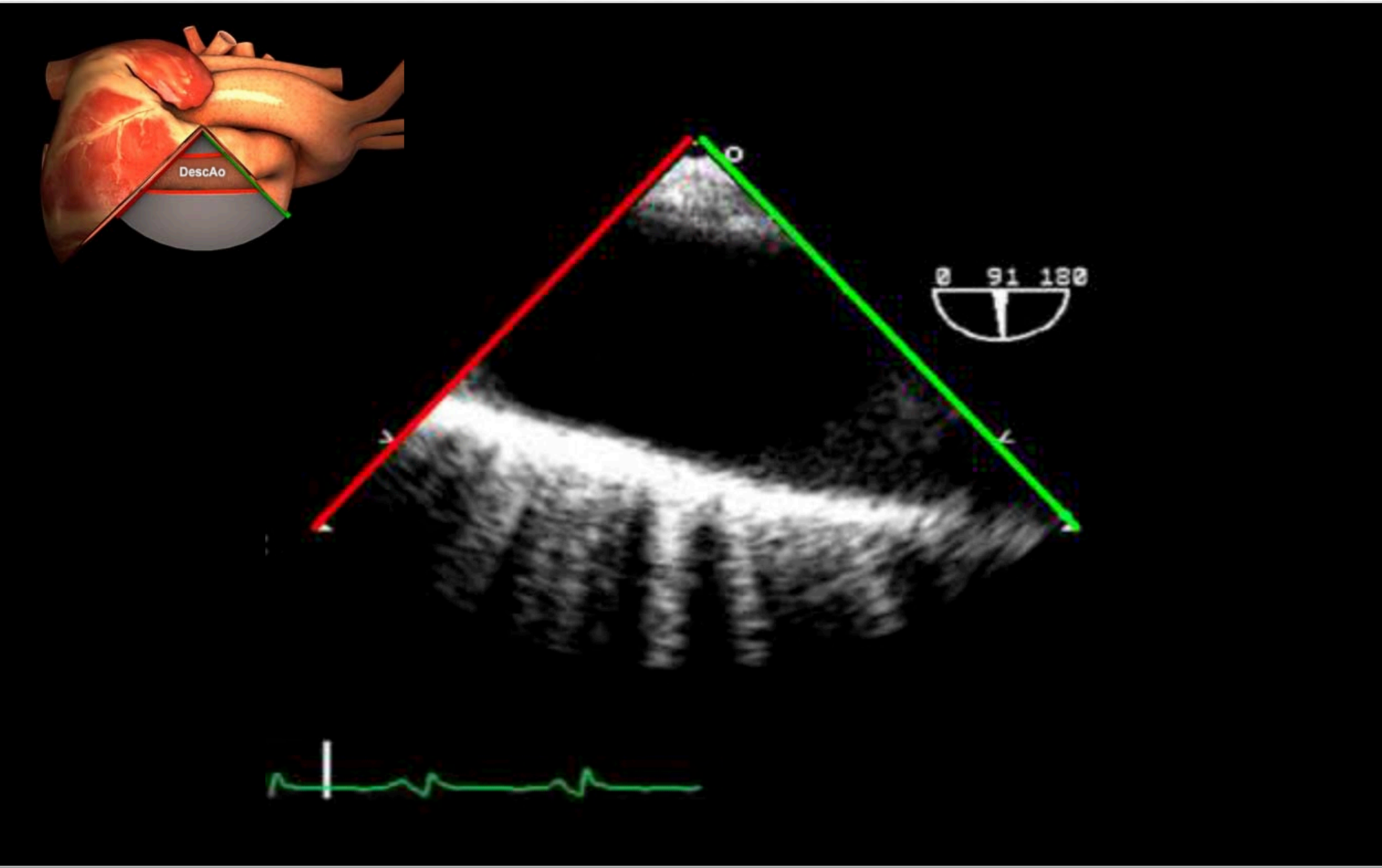

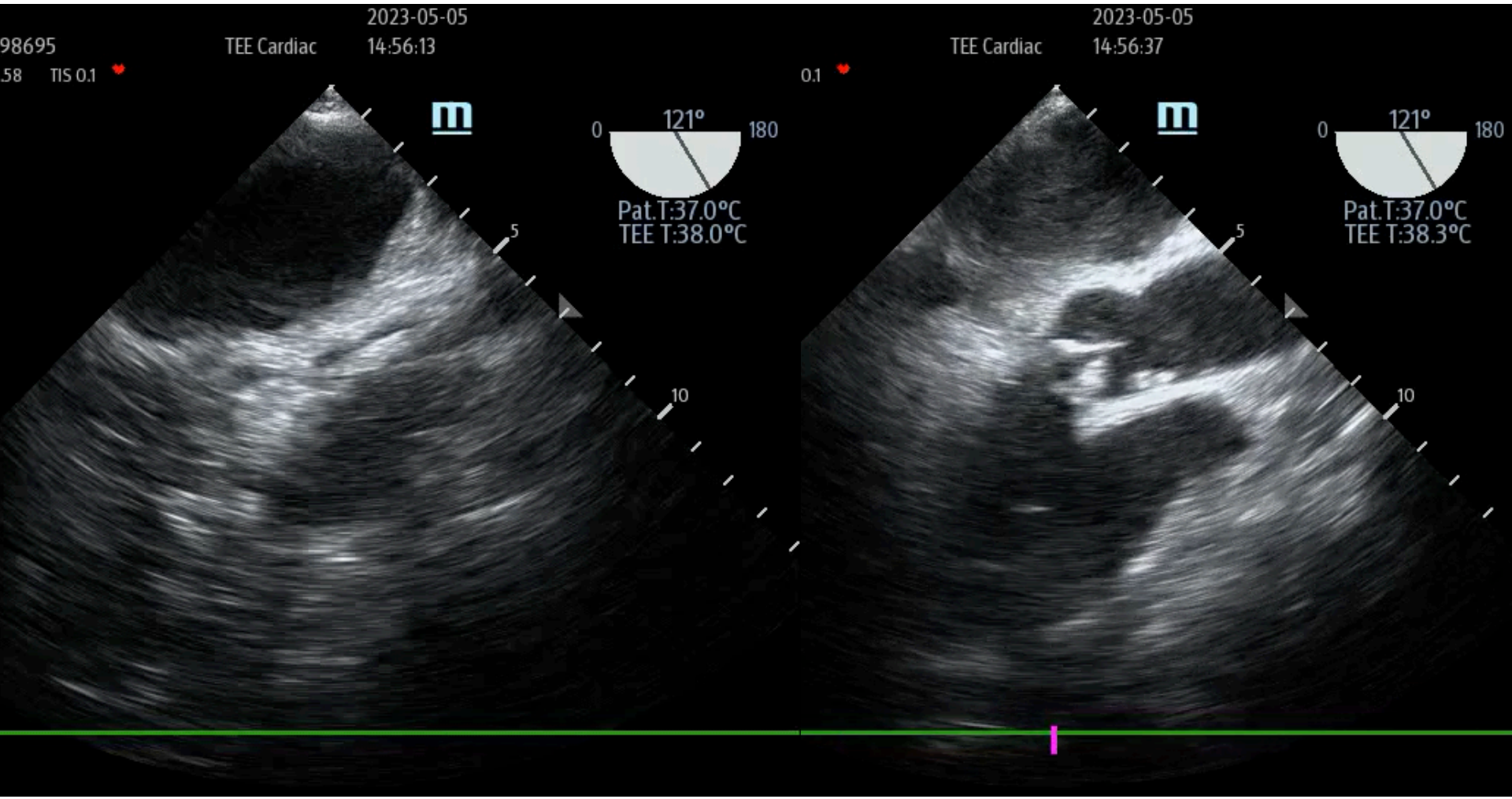

TEE GUIDED COMPRESSION

Teran, F. et al. JACC. 2020


The physician was adjusting the chest compression
point based on the real-time images of TEE

Diagnostic Role/Procedural Guidance

- Identification of potentially treatable pathologies (i.e., cardiac tamponade)
- Intra- or peri-arrest procedural guidance (i.e., ECMO)

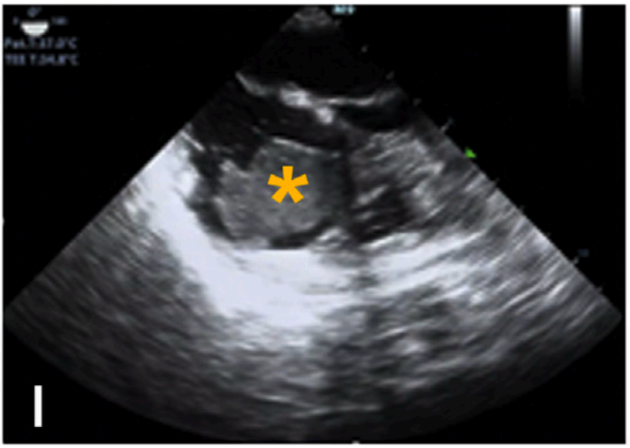

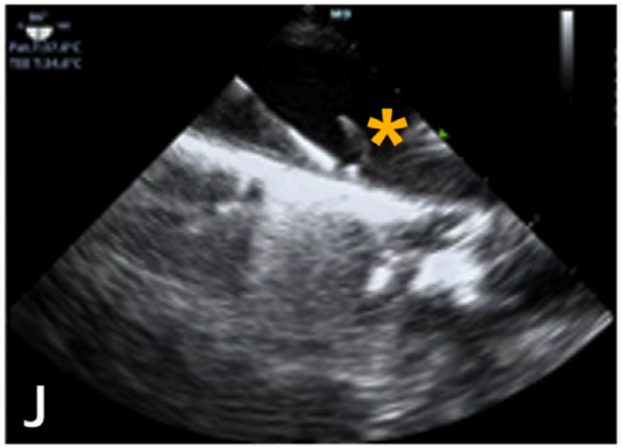

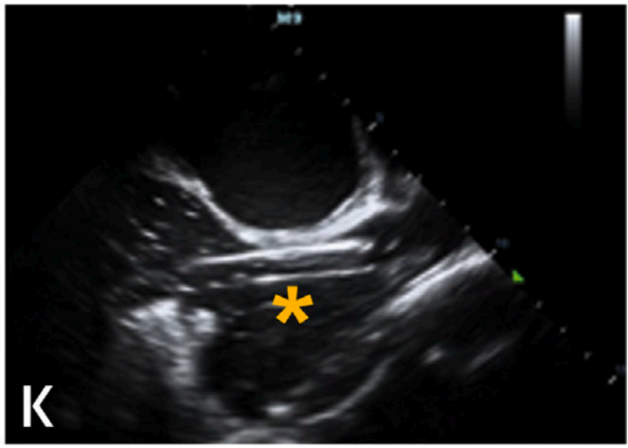

Prognostic Role

- Characterization of myocardial activity (i.e., cardiac standstill, organized vs. disorganized contractions)
- Continuous imaging of cardiac function

Teran, F. et al. JACC. 2020

TEE - BICAVAL VIEW

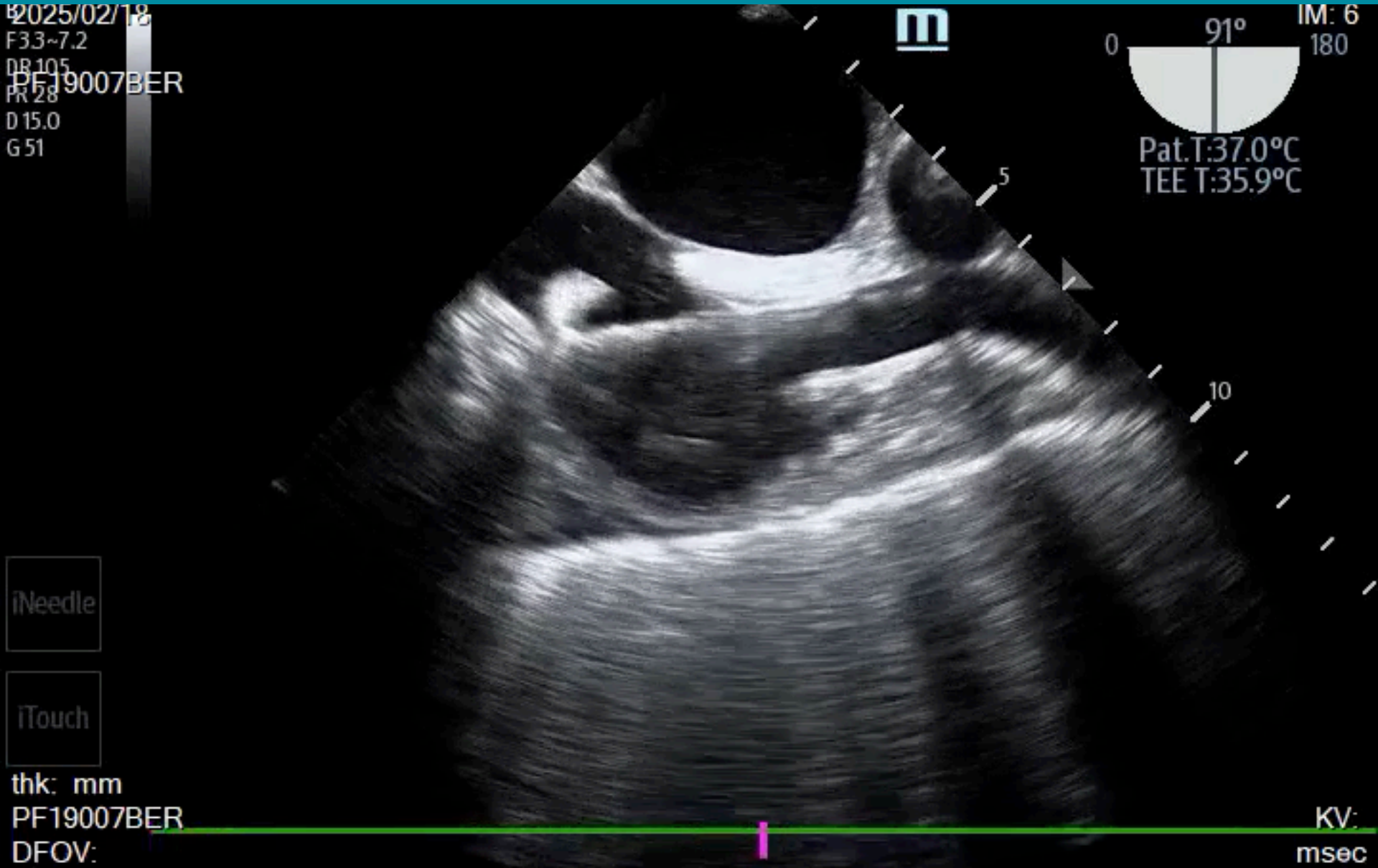

TE7 ACE

2023-05-05

TEE Cardiac 15:03:13

P7-3Ts AP 96.6% MI 0.58 TIS 0.1

B
F 3.3~7.2
DR 105
FR 28
D 15.0
G 75

0° 0 180

Pat.T:37.0°C
TEE T:38.5°C

5

TE7 ACE

2023-05-05

TEE Cardiac 15:02:31

P7-3Ts AP 96.6% MI 0.58 TIS 0.1

B
F 3.3~7.2
DR 105
FR 28
D 15.0
G 75

100° 0 180

Pat.T:37.0°C
TEE T:38.6°C

5

10

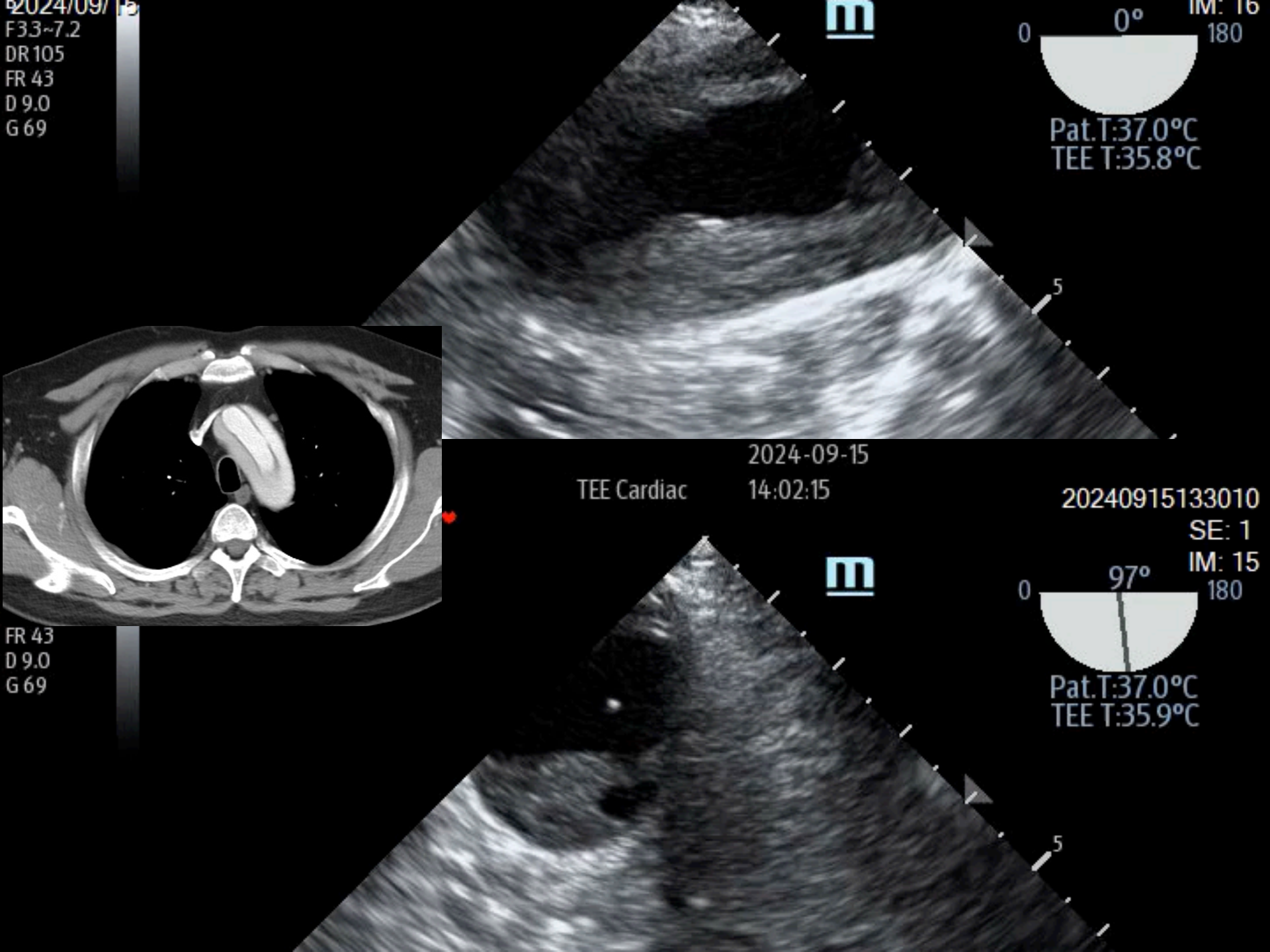
2024/09/15
F3.3~7.2
DR 105
FR 43
D 9.0
G 69
0°
0
180
IM: 16
Pat.T:37.0°C
TEE T:35.8°C
5
2024-09-15
TEE Cardiac
14:02:15
202409151330 10
SE: 1
IM: 15
97°
0
180
FR 43
D 9.0
G 69
Pat.T:37.0°C
TEE T:35.9°C
5

TG Mid SAX view (0°) (大輪順轉前彎向心)

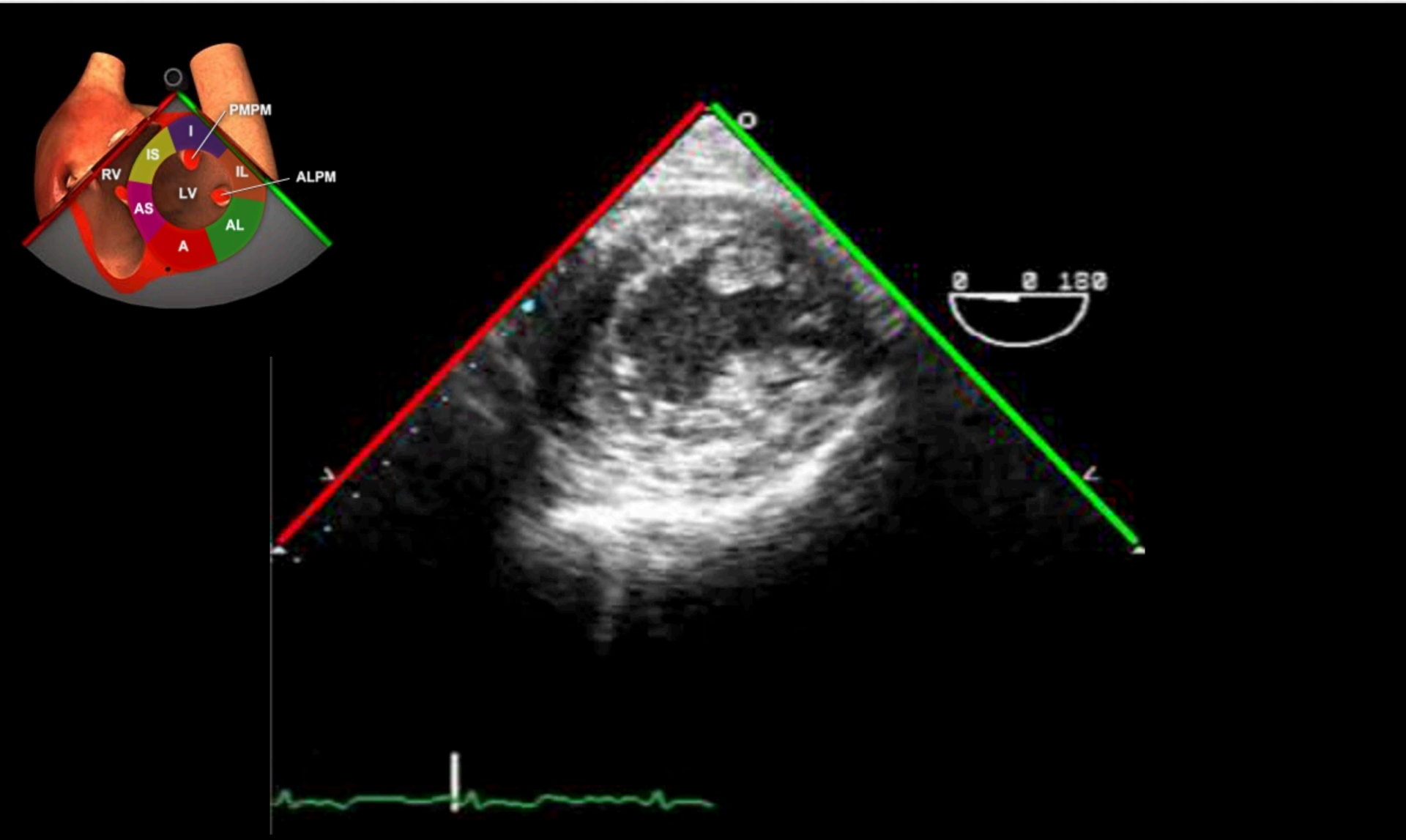

TG LAX view (CPR 品質另一選擇)

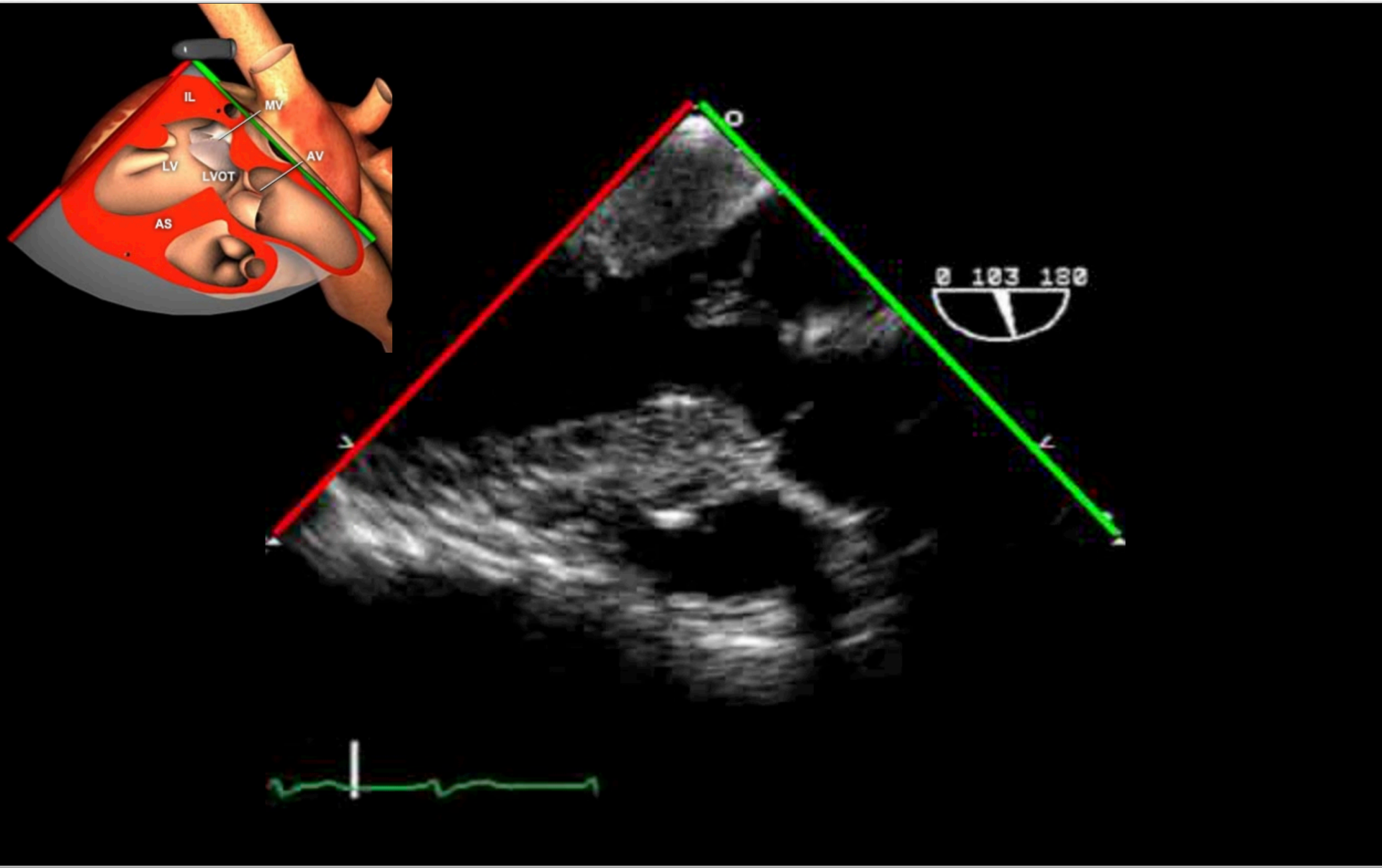

ME Ascending aorta SAX view

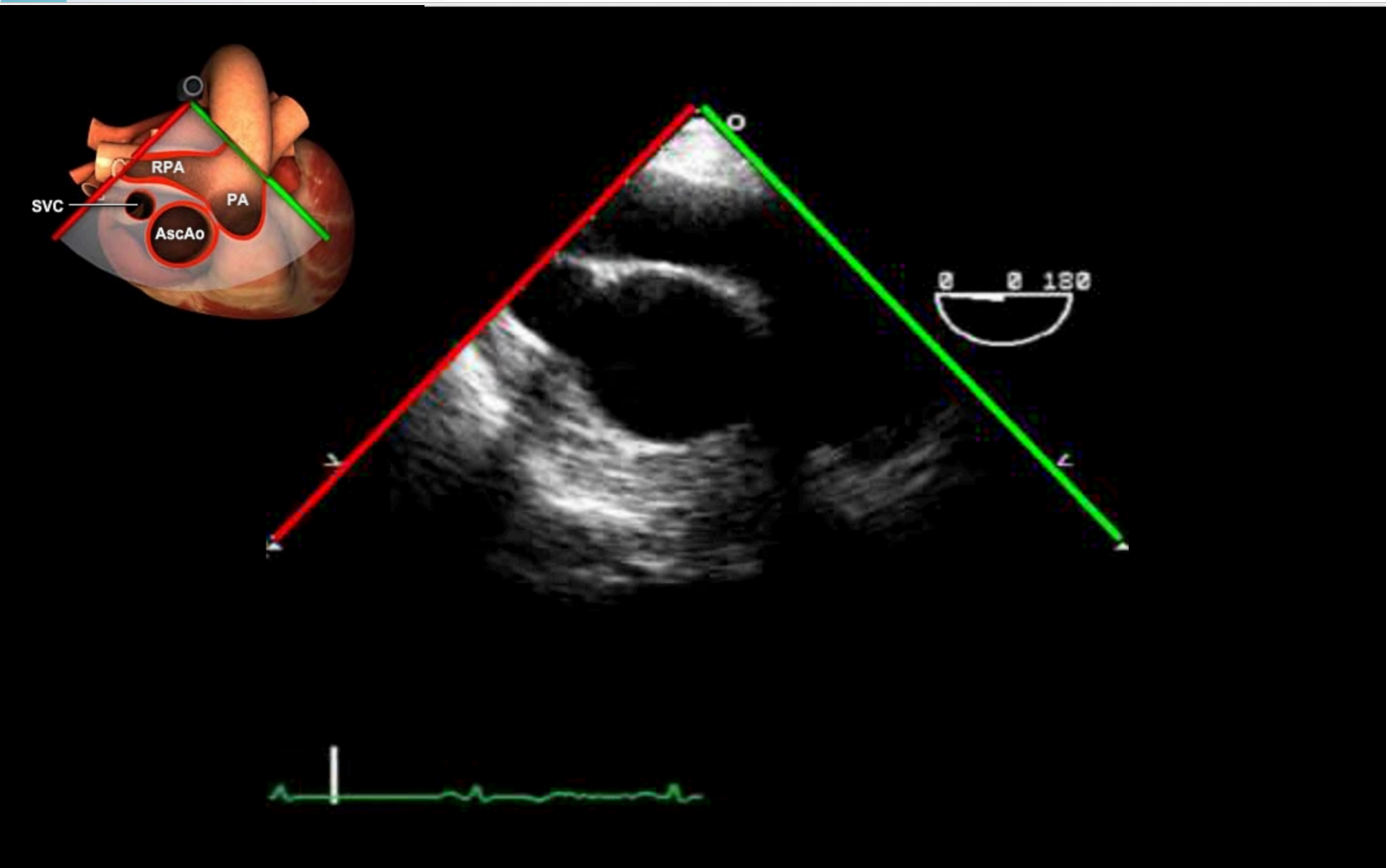

ME Ascending aorta LAX view

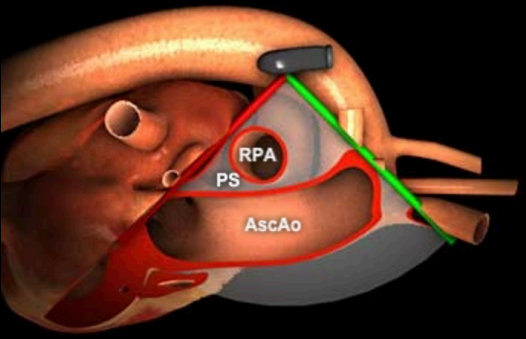

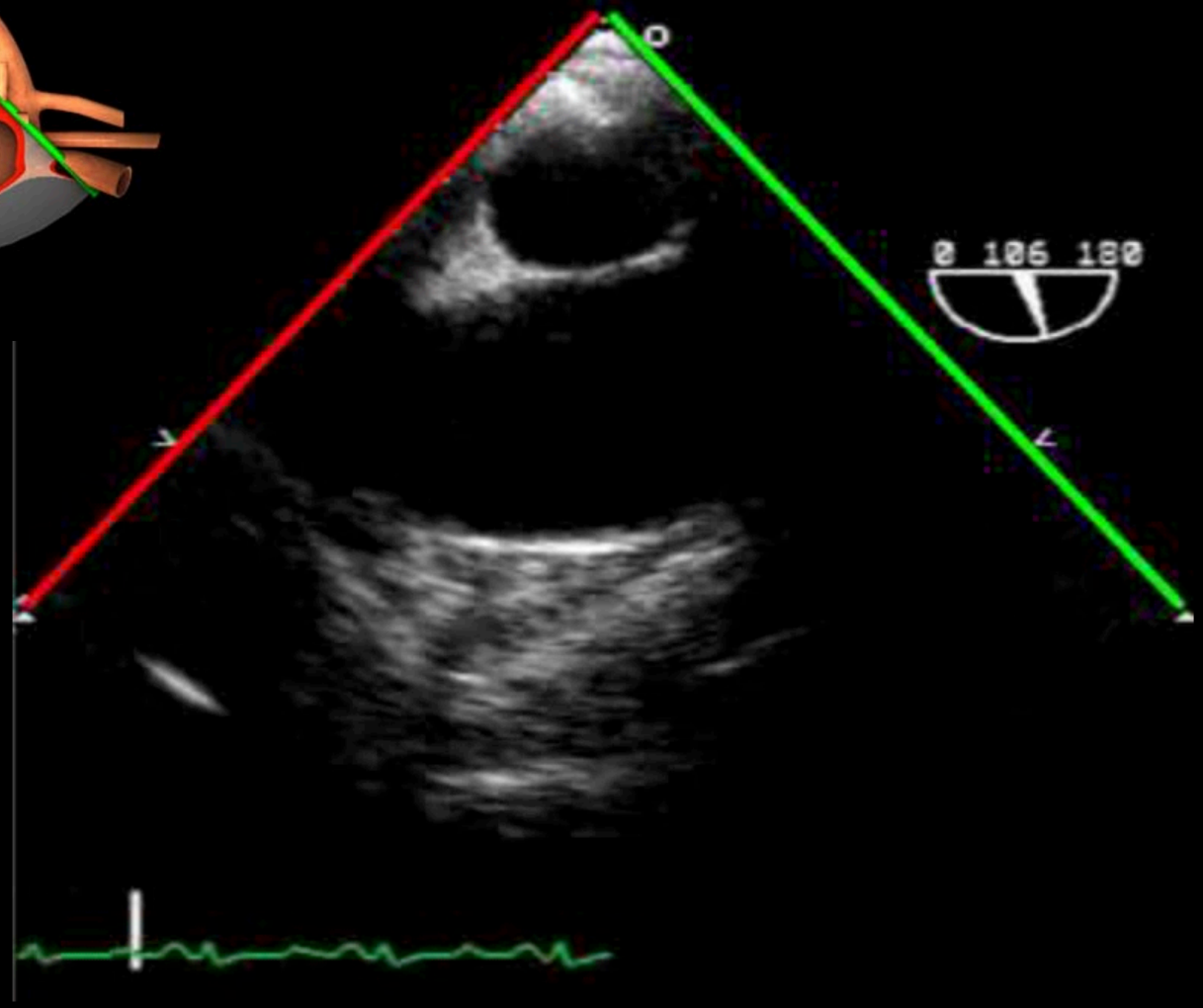

UE Aortic arch LAX view

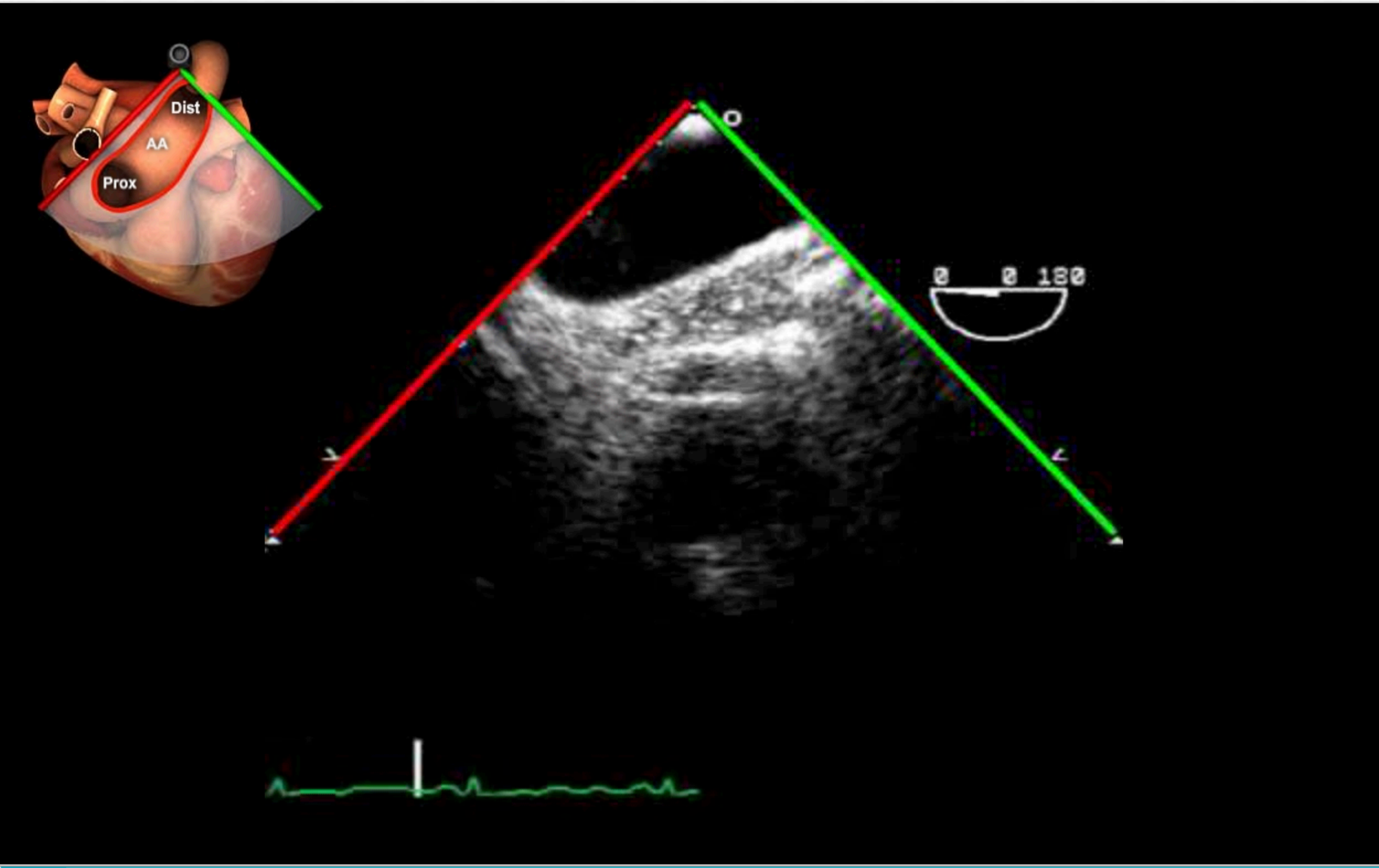

UE Aortic arch SAX view

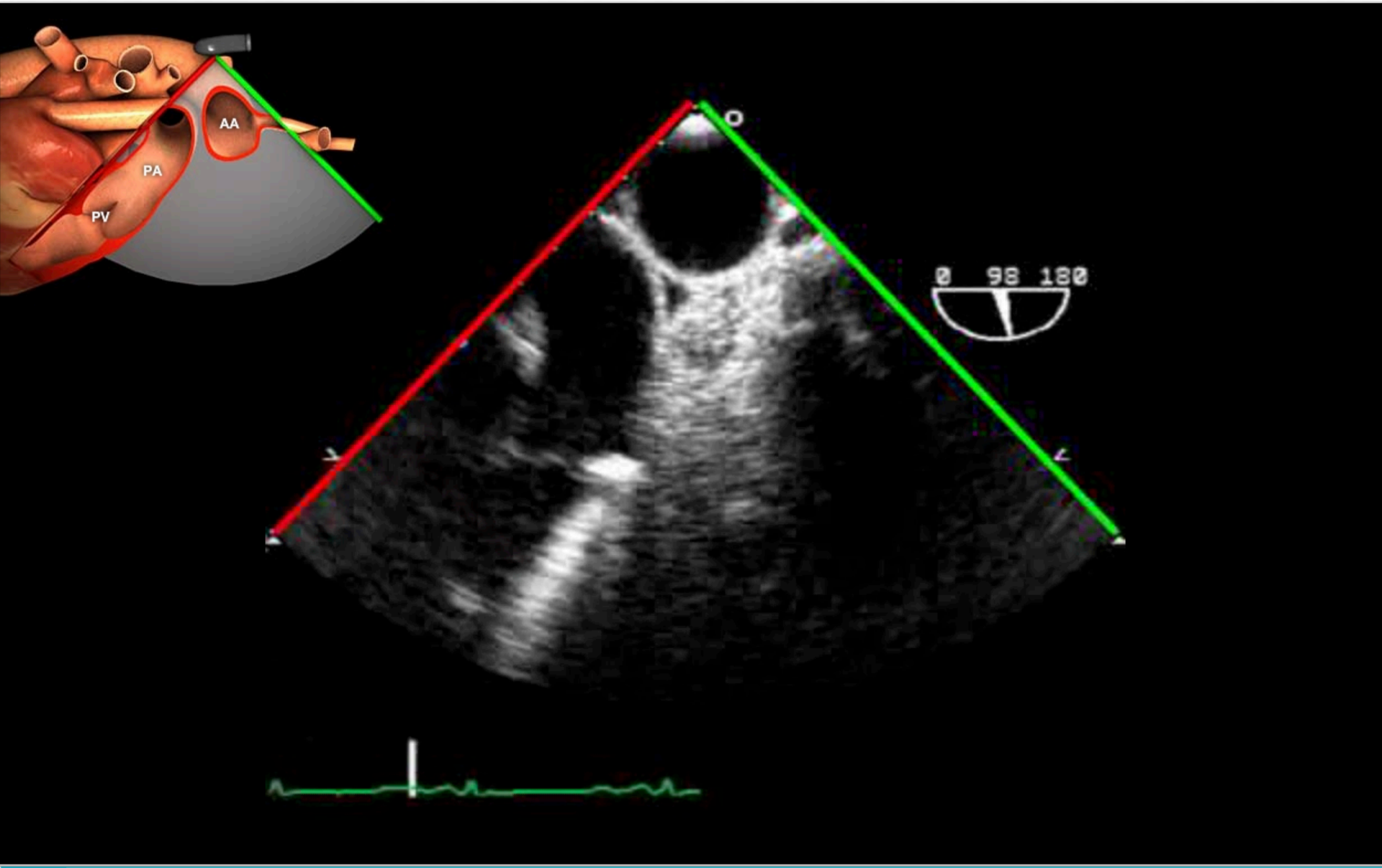

FIGURE 2 **Incorporation of Focused TEE During Cardiac Arrest Resuscitation Care**

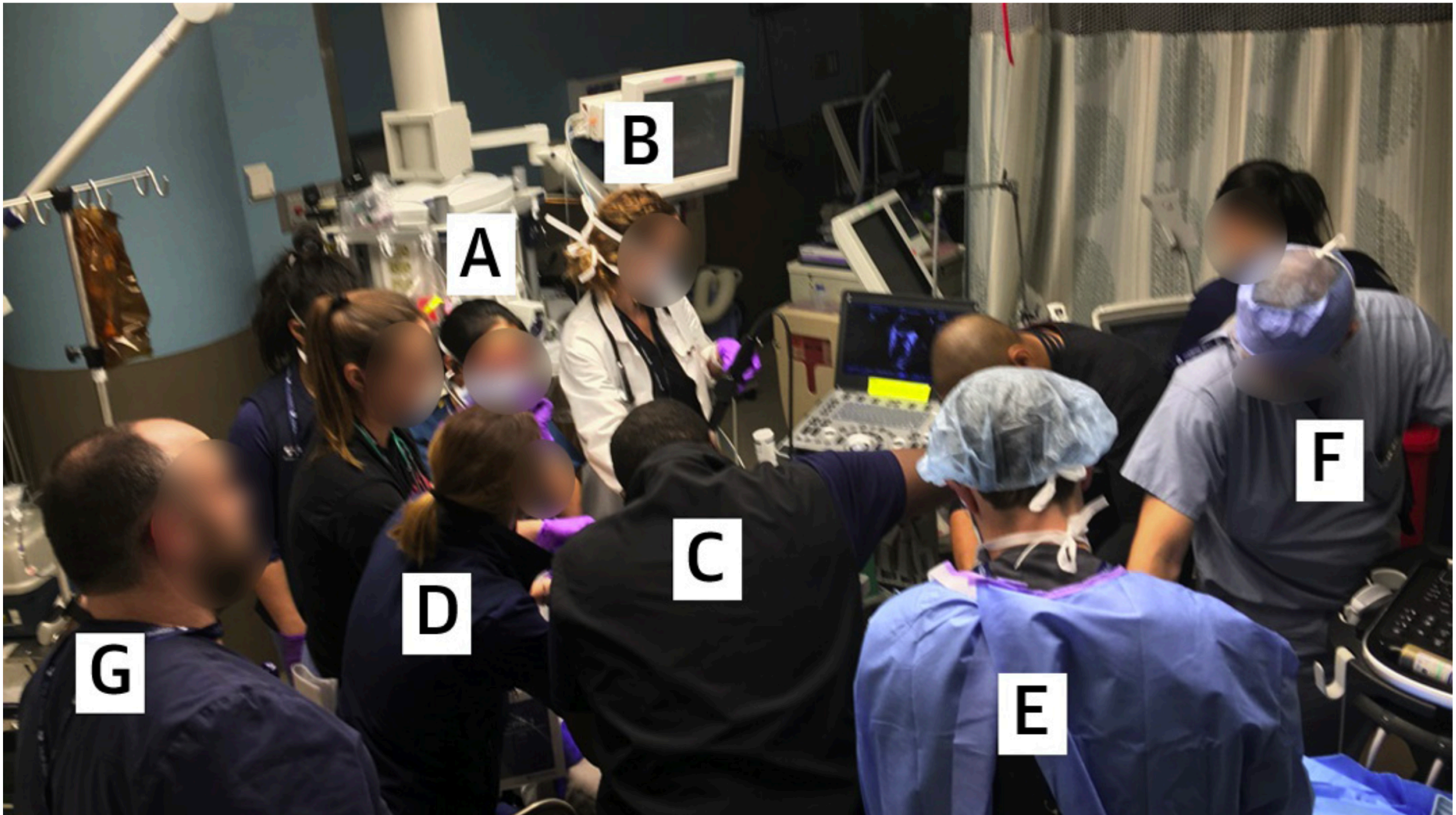

Core Ultrasound in REsuscitation (CURE): A novel protocol for ultrasound-assistant life support via application of both transesophageal and transthoracic ultrasound

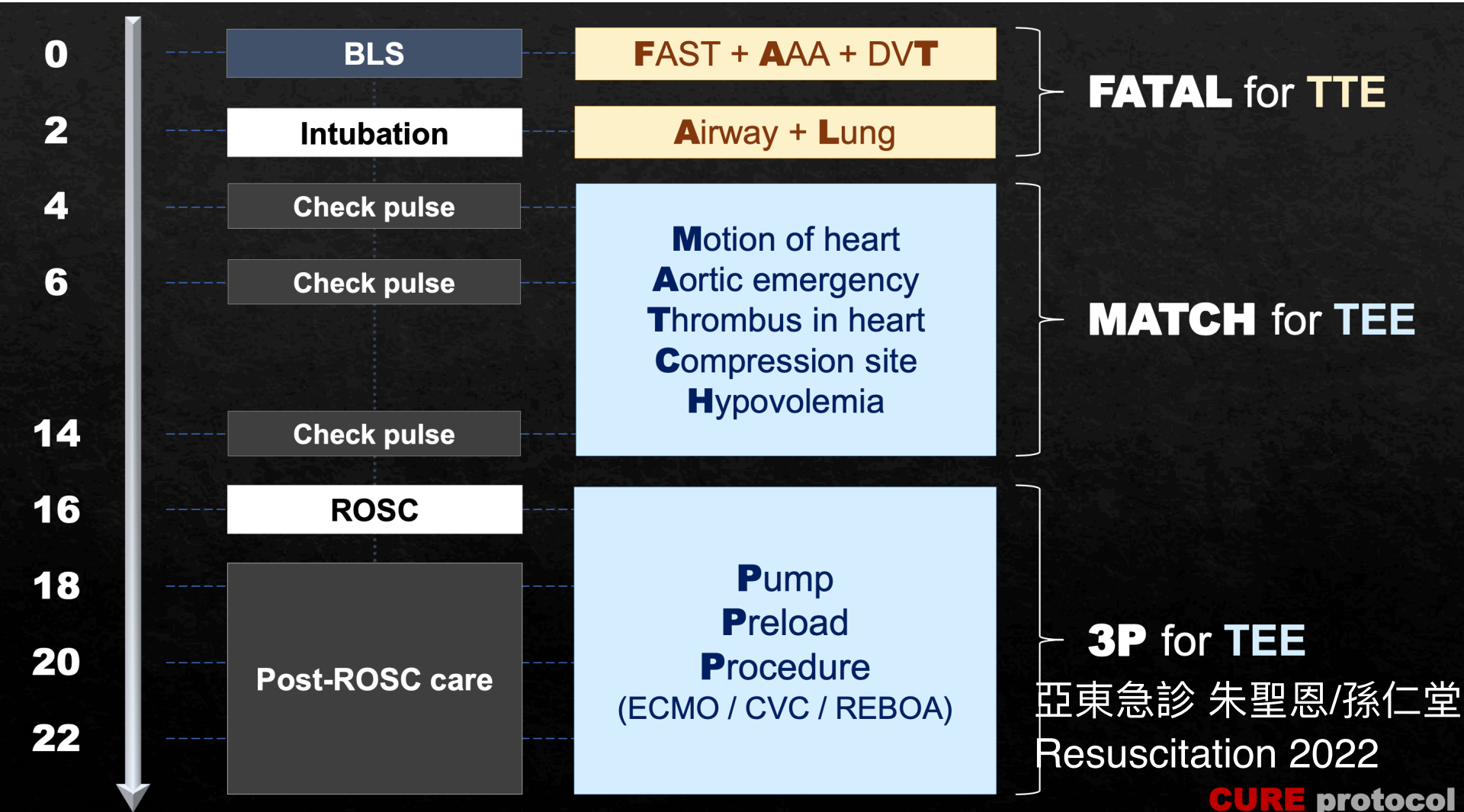

Core Ultrasound in REsuscitation (CURE): A novel protocol for ultrasound-assistant life support via application of both transesophageal and transthoracic ultrasound

亞東急診 朱聖恩/孫仁堂 Resuscitation 2022

Core Ultrasound in REsuscitation (CURE): A novel protocol for ultrasound-assistant life support via application of both transesophageal and transthoracic ultrasound

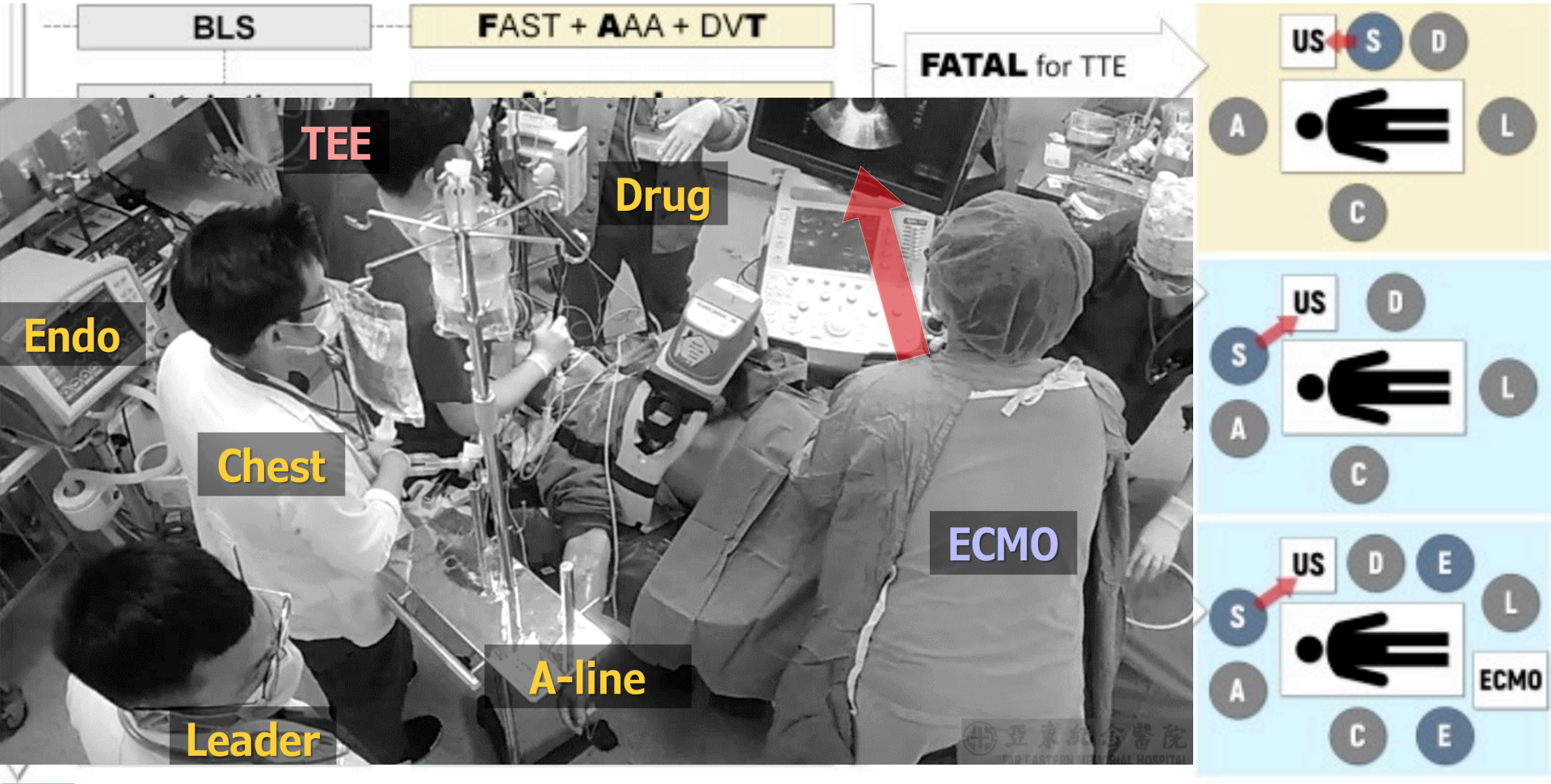

亞東急診 朱聖恩/孫仁堂 Resuscitation 2022

Core Ultrasound in REsuscitation (CURE): A novel protocol for ultrasound-assistant life support via application of both transesophageal and transthoracic ultrasound

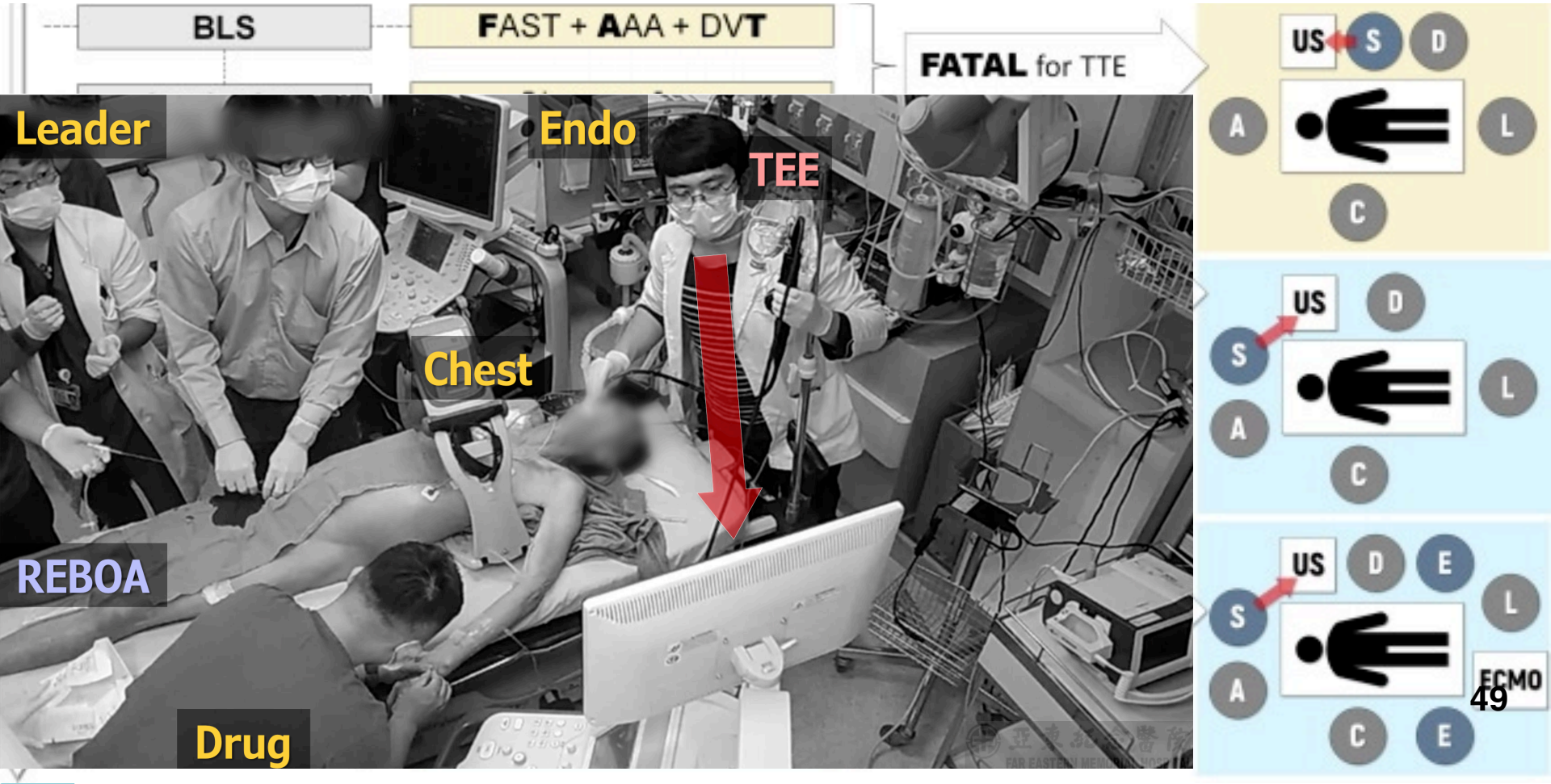

亞東急診 朱聖恩/孫仁堂 Resuscitation 2022

FATAL for TTE

(Curved probe)

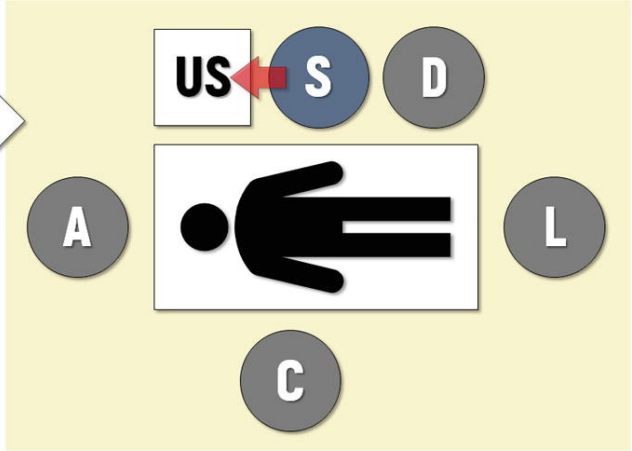

US location

MATCH for TEE

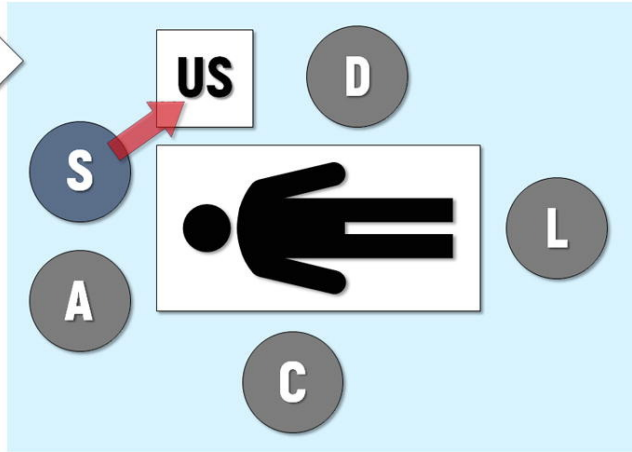

mCASA

A line

3P for TEE

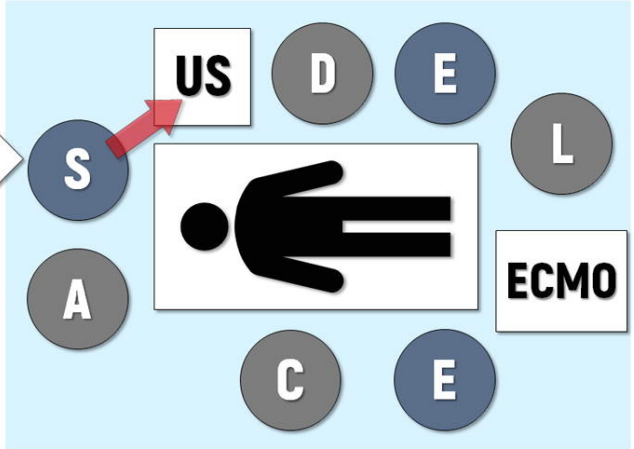

TEE

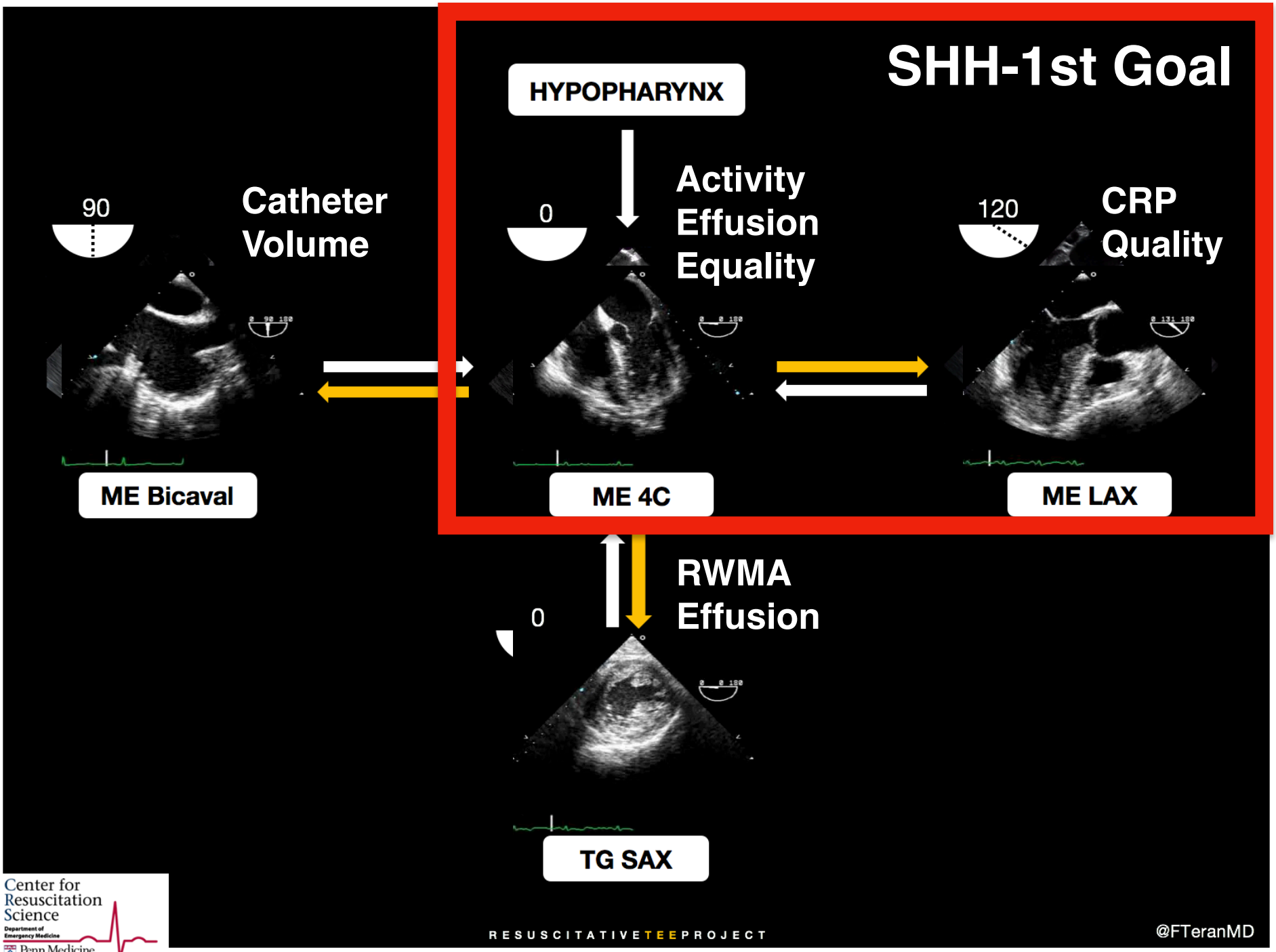
SHH-1st Goal
HYPOPHARYNX
Activity
Effusion
Equality
90
Catheter
Volume
0
120
CRP
Quality
ME Bicaval
ME 4C
ME LAX
RWMA
Effusion
0
TG SAX
Center for
Resuscitation
Science
Department of
Emergency Medicine
Penn Medicine
RESUSCITATIVE TEE PROJECT
@FTeranMD

67M, collapsed in the park

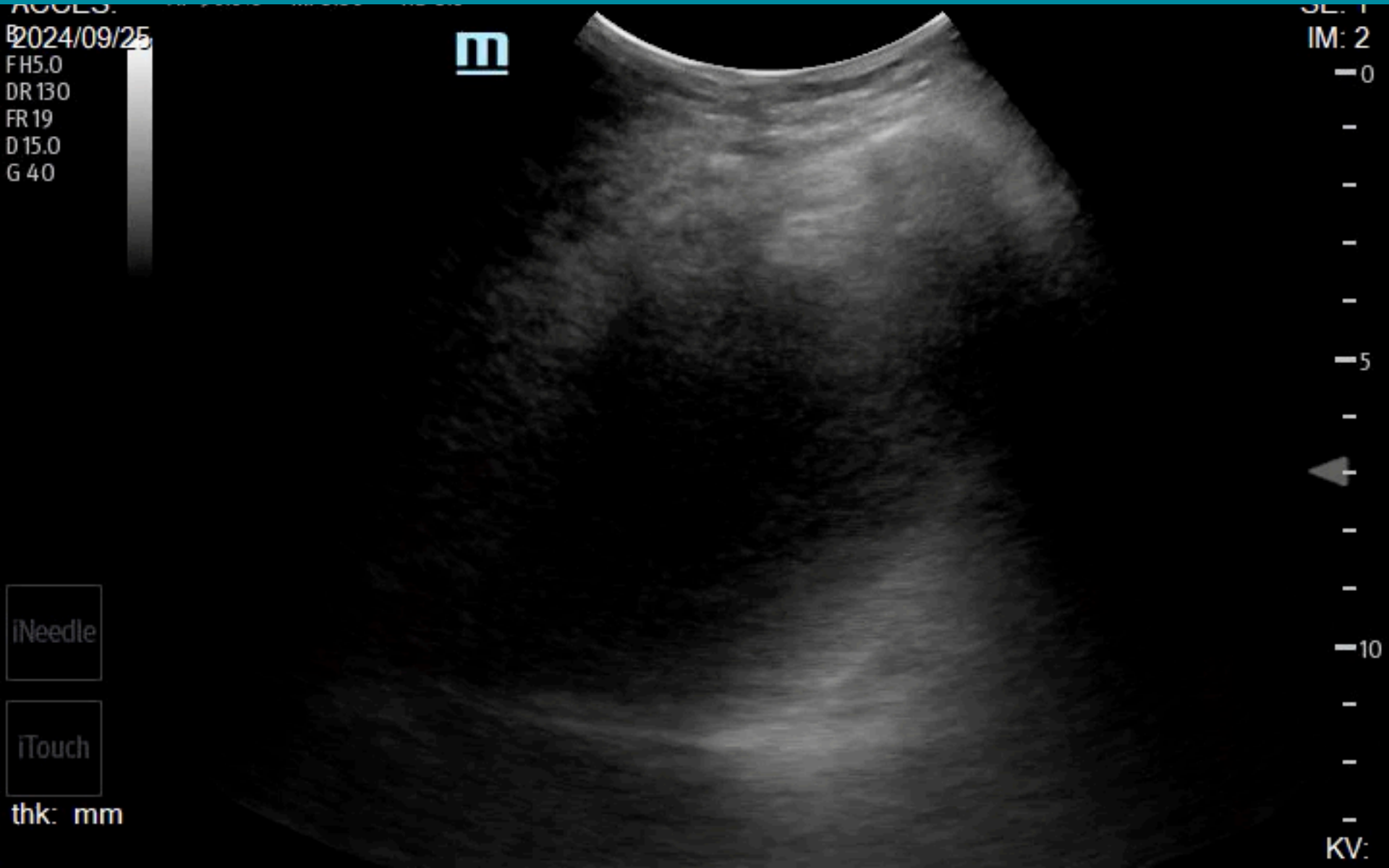

Resuscitative TEE

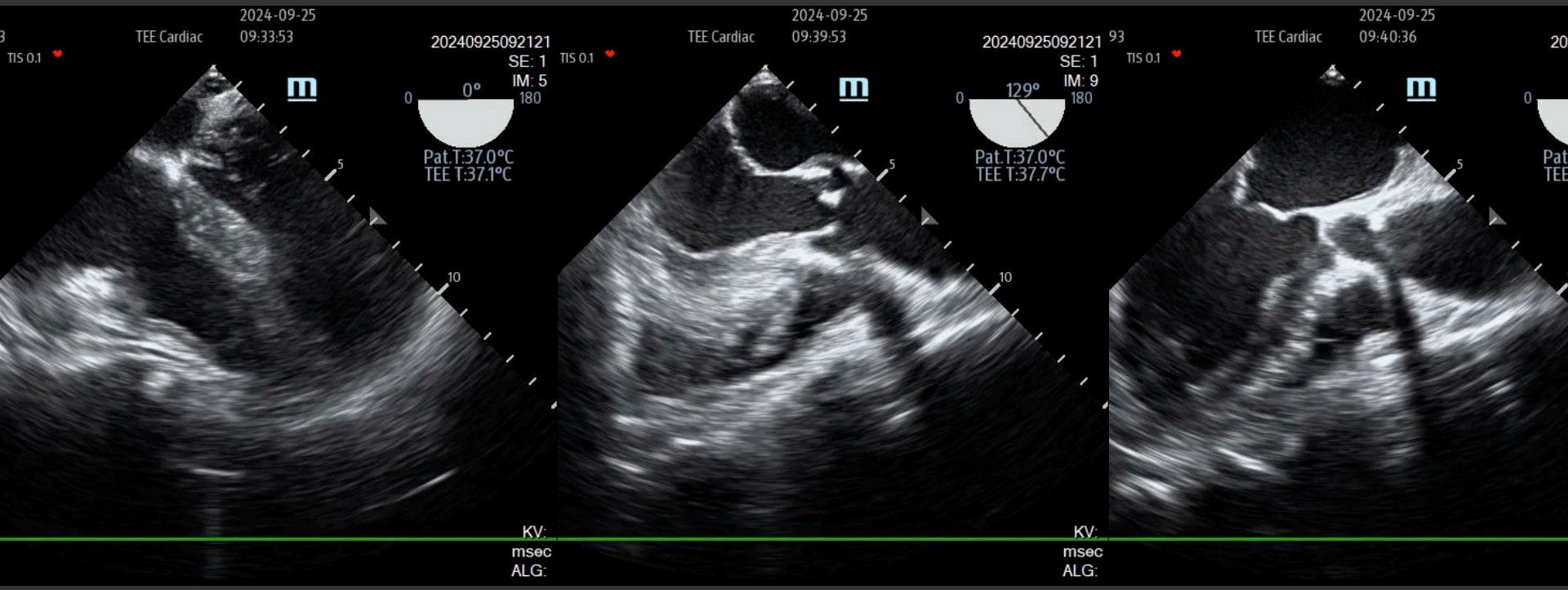

VF & DC shock

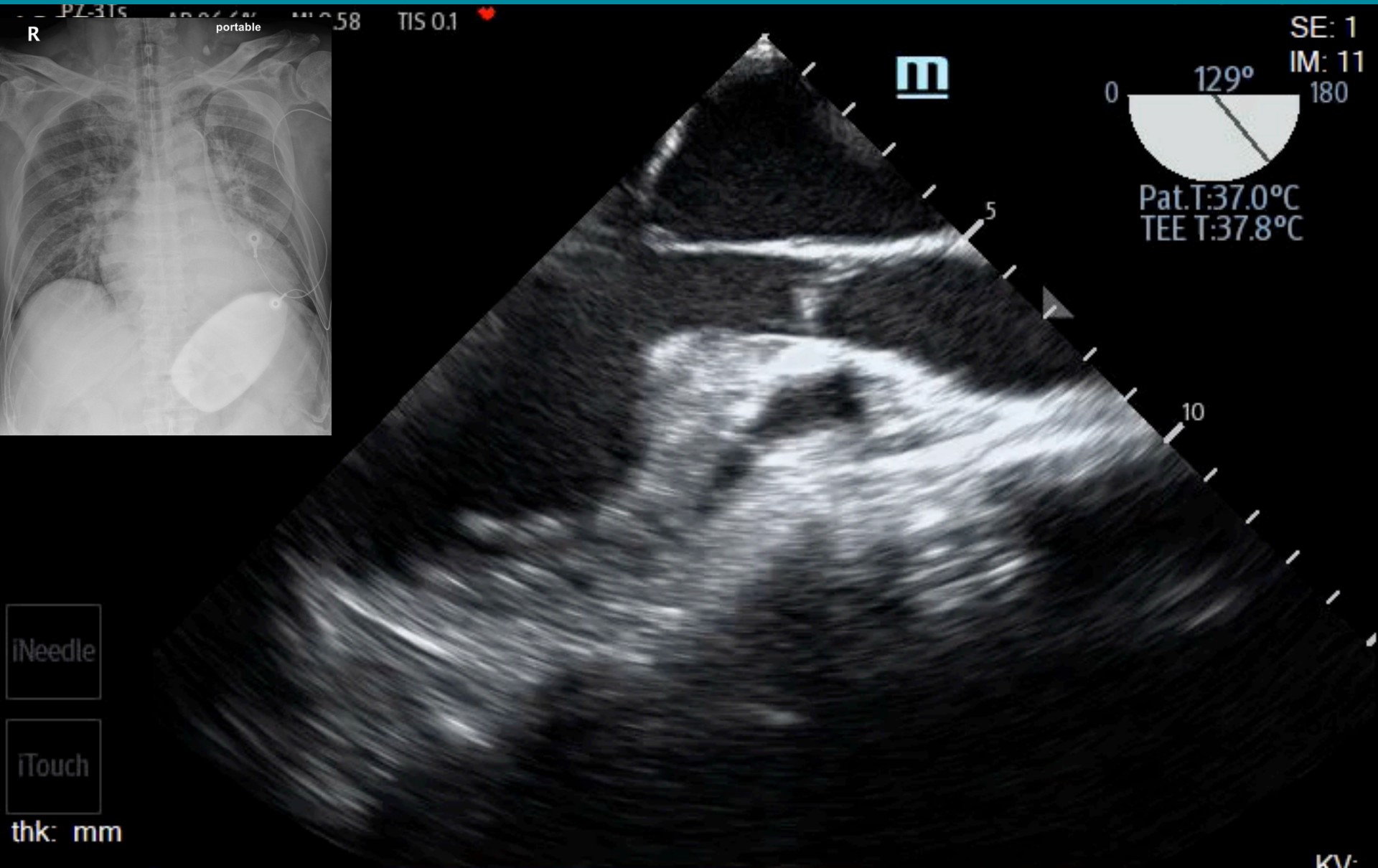
R
portable
TIS 0.1
SE: 1
IM: 11
0
129°
180
Pat.T:37.0°C
TEE T:37.8°C
5
10
iNeedle
iTouch
thk: mm

SGB for refractory VF

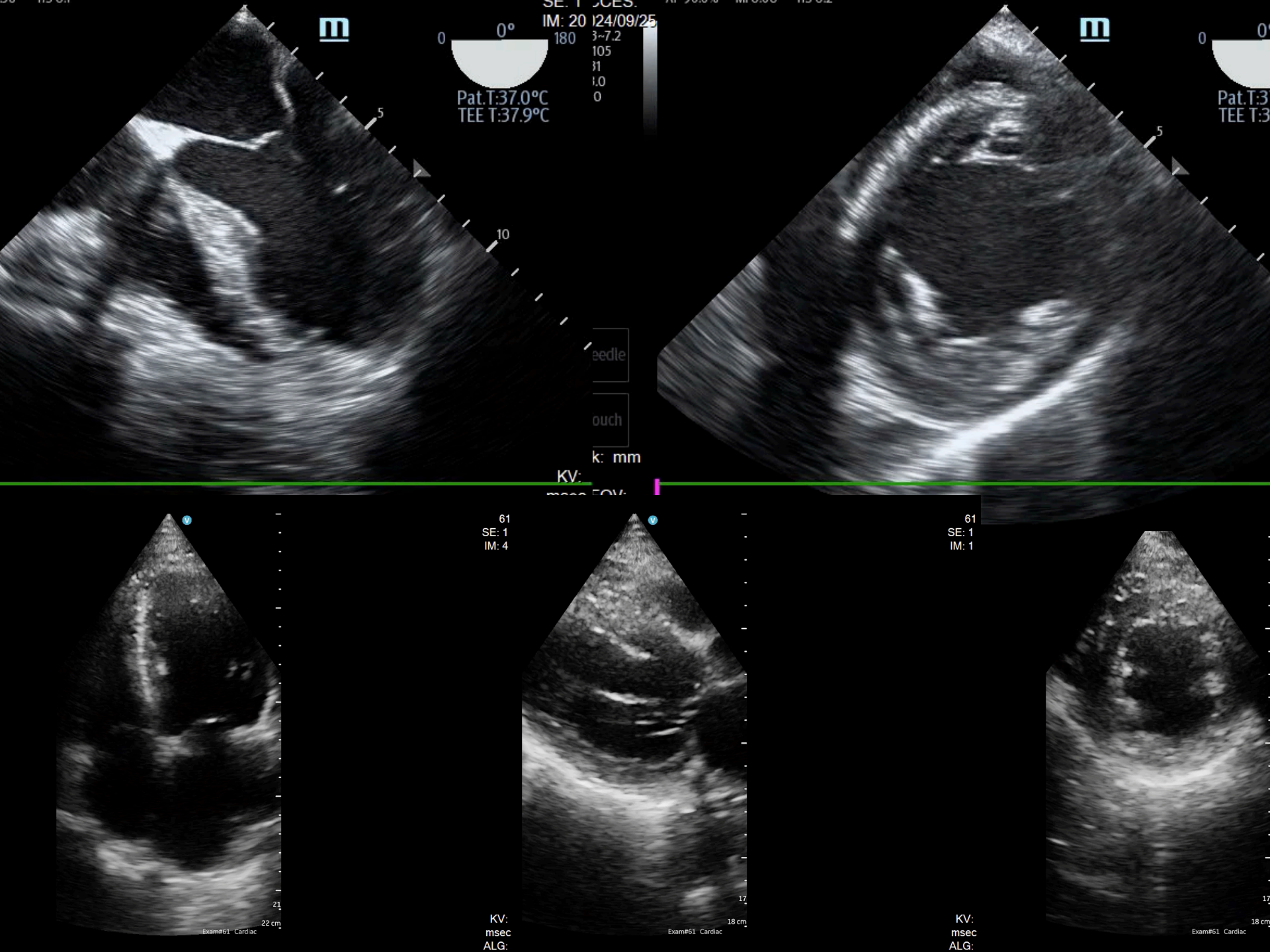
IM: 20
24/09/25
0°
180
Pat.T:37.0°C
TEE T:37.9°C
KV:
61
SE: 1
IM: 4
22 cm
Exam#61 Cardiac
18 cm
61
SE: 1
IM: 1

73M, Shock >> Arrest

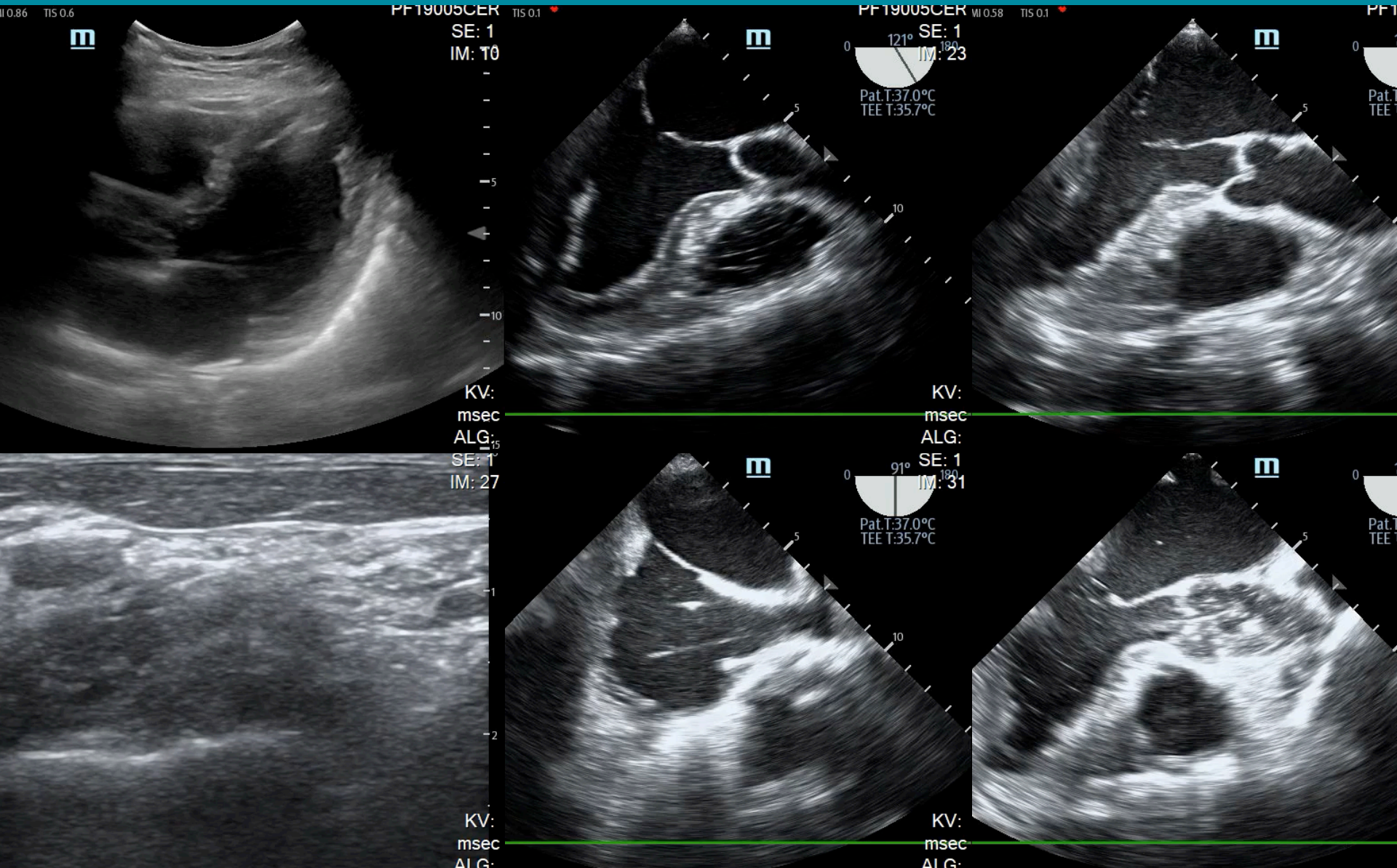

RESUSCITATIVE TEE PROJECT

HOME ABOUT RESOURCES
BLOG RESUSTEE COLLABORATIVE

THE RESUSCITATIVE TEE WORKSHOP
THE LEARNING LAB

SEARCH

TEE RESOURCES

Virtual Transesophageal Echocardiography
Toronto General Hospital Department of Anesthesia
Perioperative Interactive Education

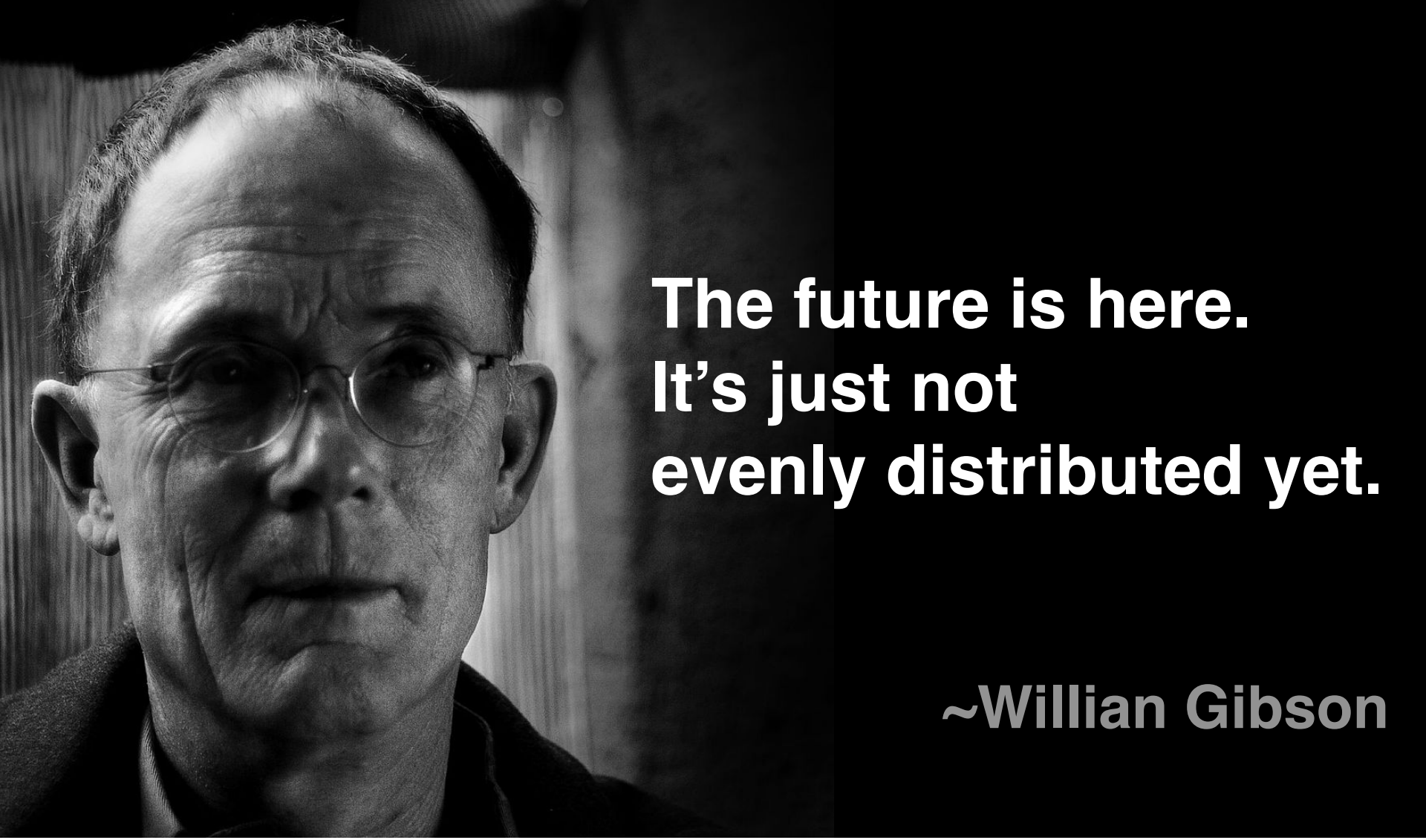

How to Perform Resuscitative Transesophageal Echocardiography in the Emergency Department

By Michael O'Neil, MD; Arun Nagdev, MD; and Felipe Teran, MD | on July 21, 2020 | 0 Comment

Review

Transoesophageal echocardiography in cardiac arrest: From the emergency department to the intensive care unit

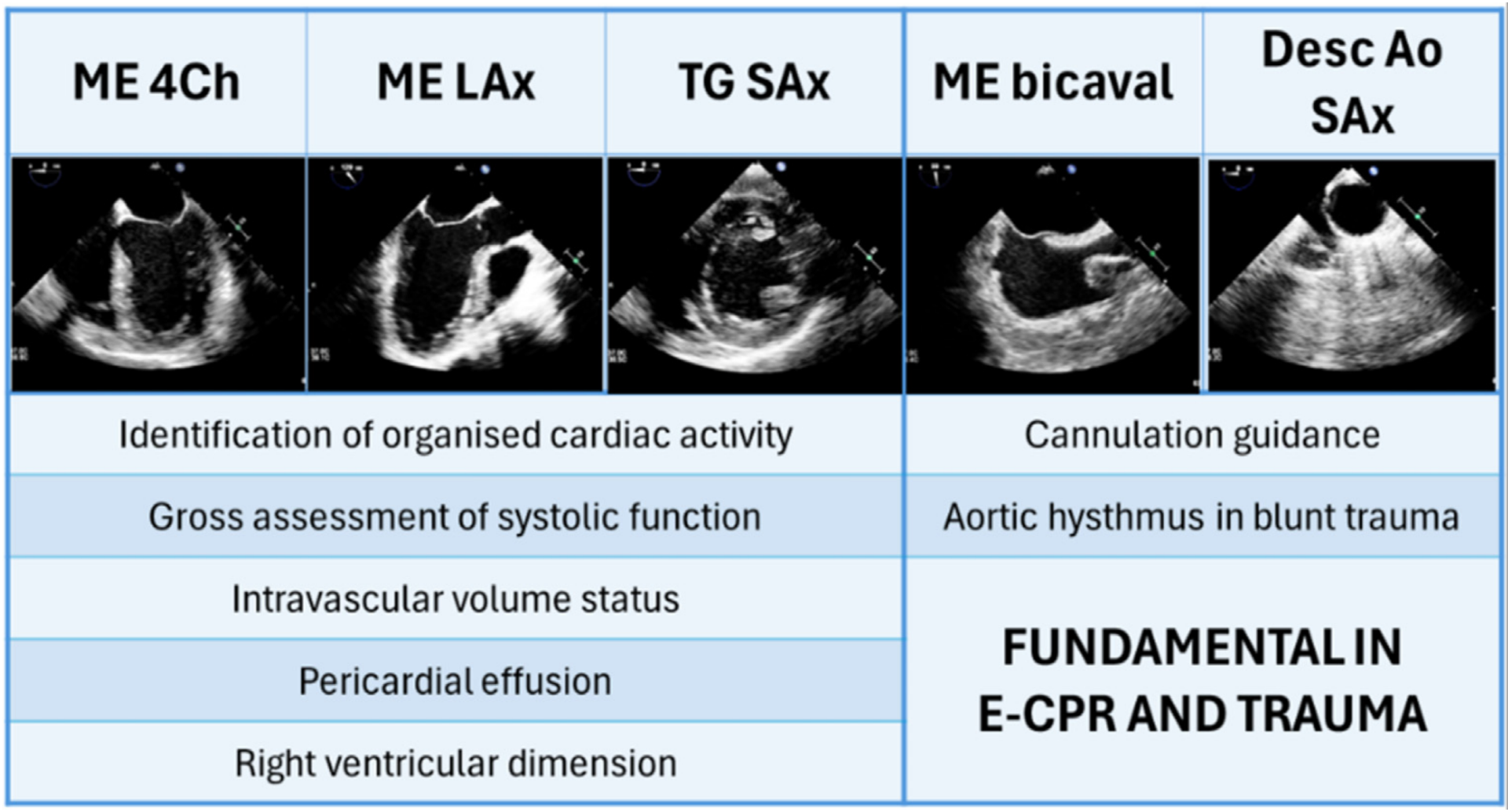

RESUSCITATIVE TEE

TTE	TEE
PSLA	ME 4C
PSSA	ME LAX
S4C	TG SAX
IVC	ME Bicaval
A4C	Descending Aorta SAX