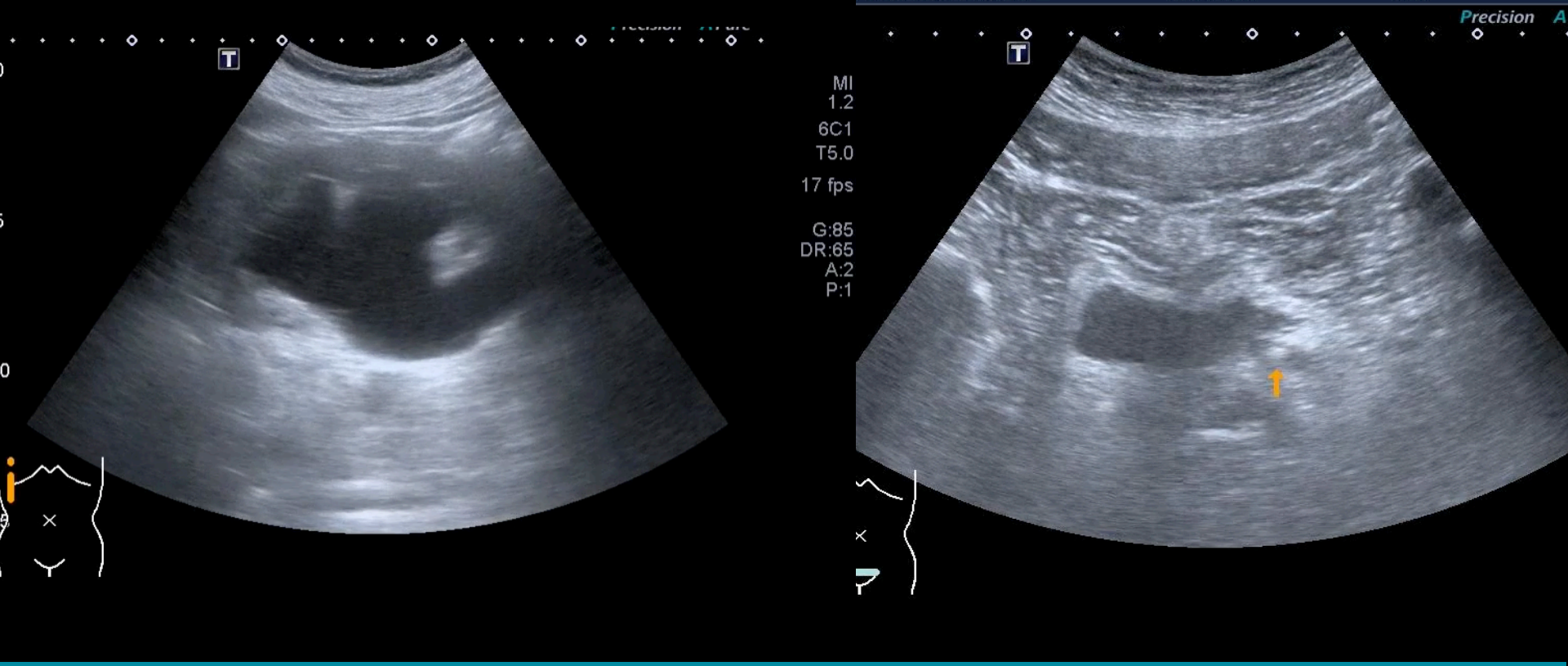

Kidney / Ureter / Bladder

陳國智醫師 雙和醫院急診醫學科

juice119@gmail.com

POCUSacademy.com

Resuscitative 急救復甦	Diagnostic 臨床診斷	Procedural Guidance 處置導引	Symptom- or Sign-Based 症狀導引	Therapeutic 輔助治療

Core Applications (2023 ACEP Emergency Ultrasound Guidelines)
15項急診超音波核心應用

陳國智醫師

Aorta	Procedural Guidance	Hepatobiliary
DVT	US-guided NB	Urinary tract
Trauma	Testicular	Pregnancy
Thoracic/Airway	Ocular	Bowel
Cardia/HD assessment	Skin & Soft tissue	MSK

共通語言: 3D立體介面

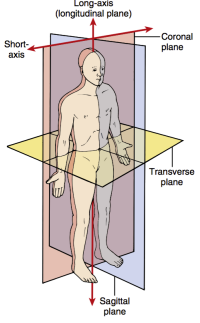

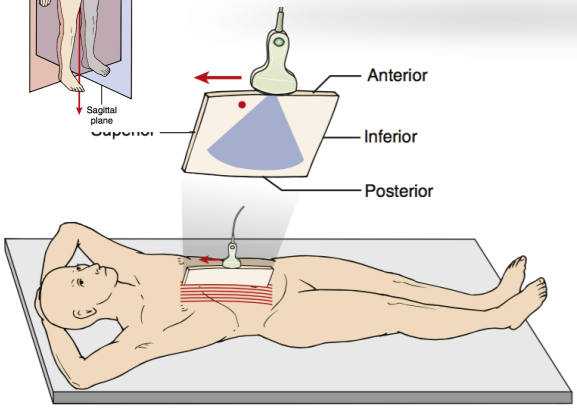

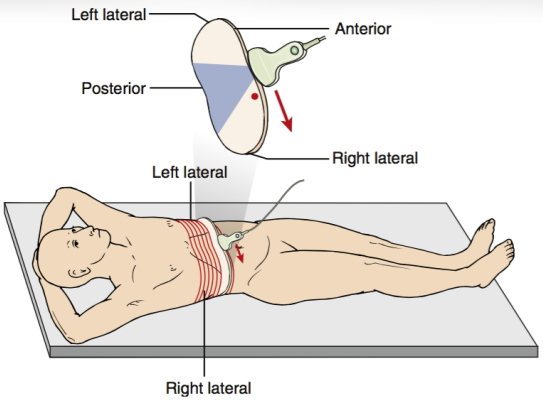

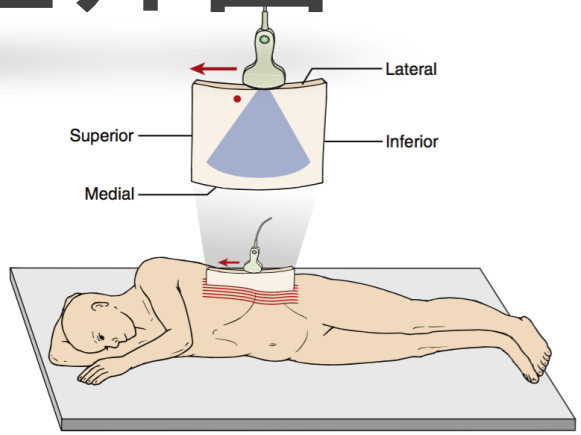

Sagittal 縱

Transverse 橫

Coronal 側

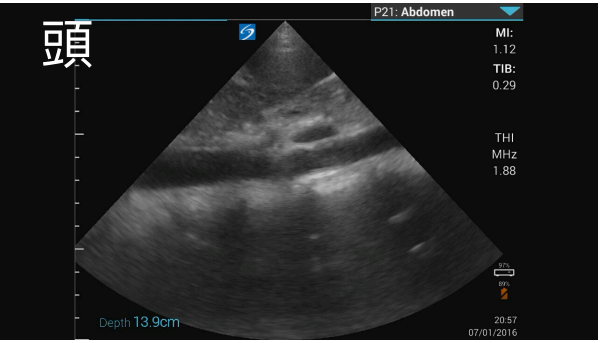

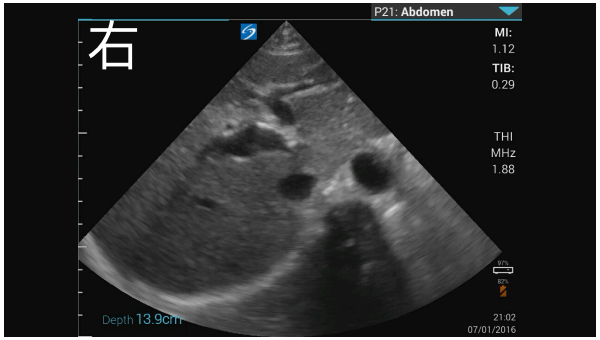

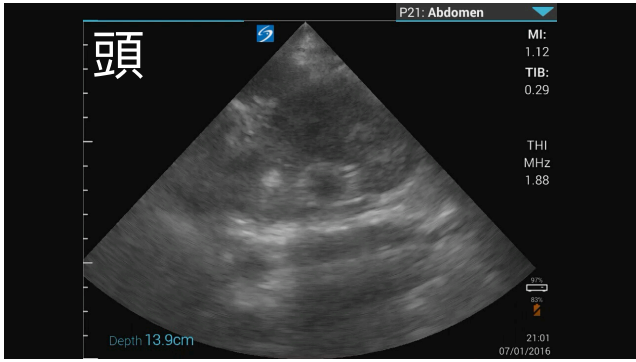

掃描前用手指碰觸探頭表面確認方向

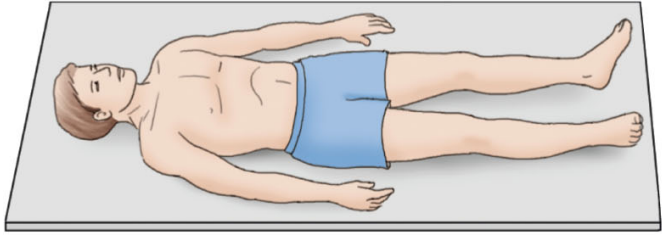

Supine

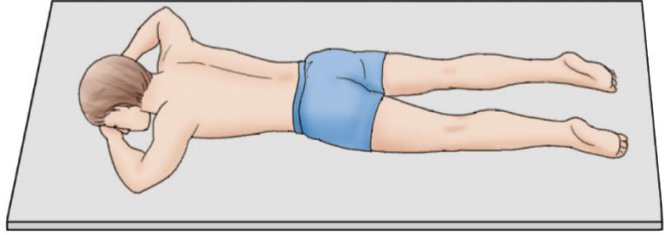

Prone

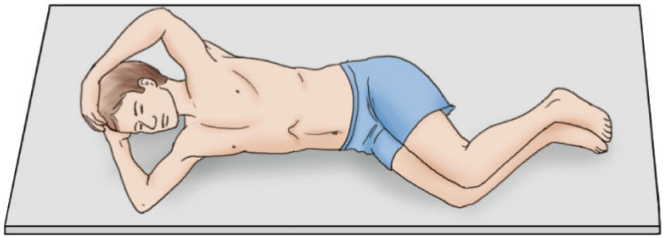

Right lateral decubitus

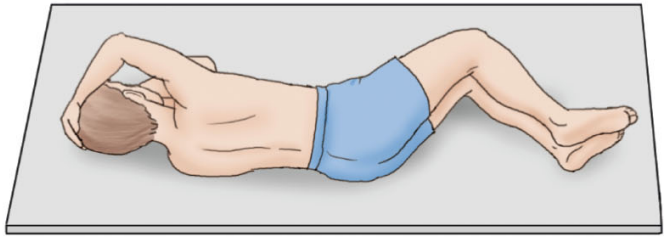

Left lateral decubitus

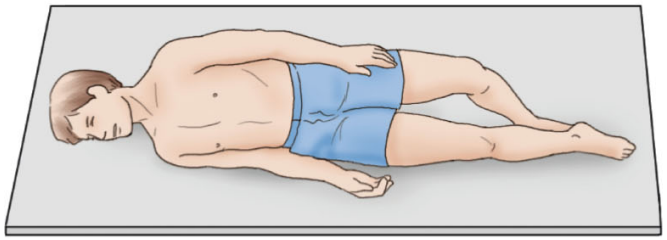

Right posterior oblique

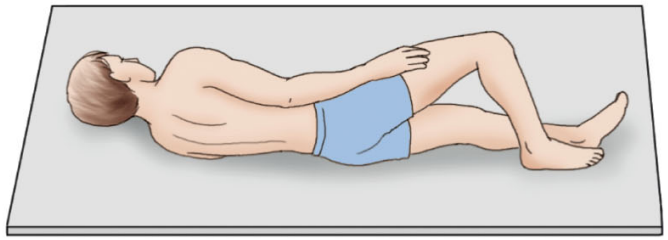

Left posterior oblique

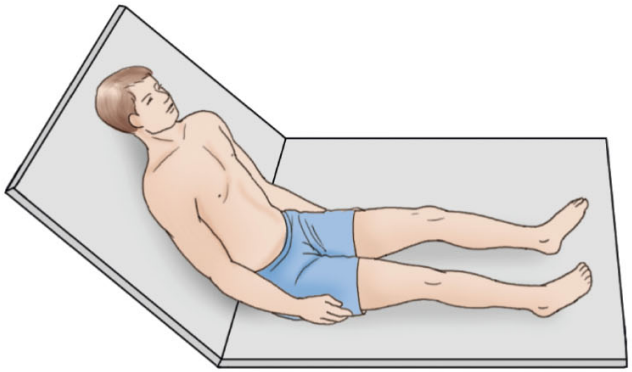

Sitting semi-erect

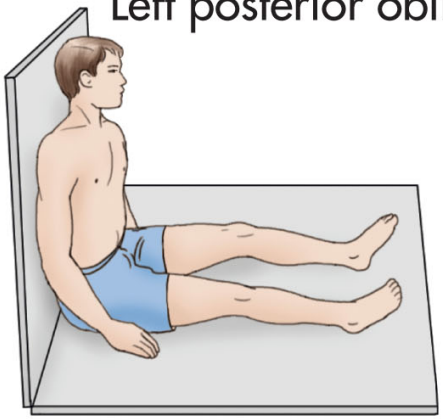

Sitting erect

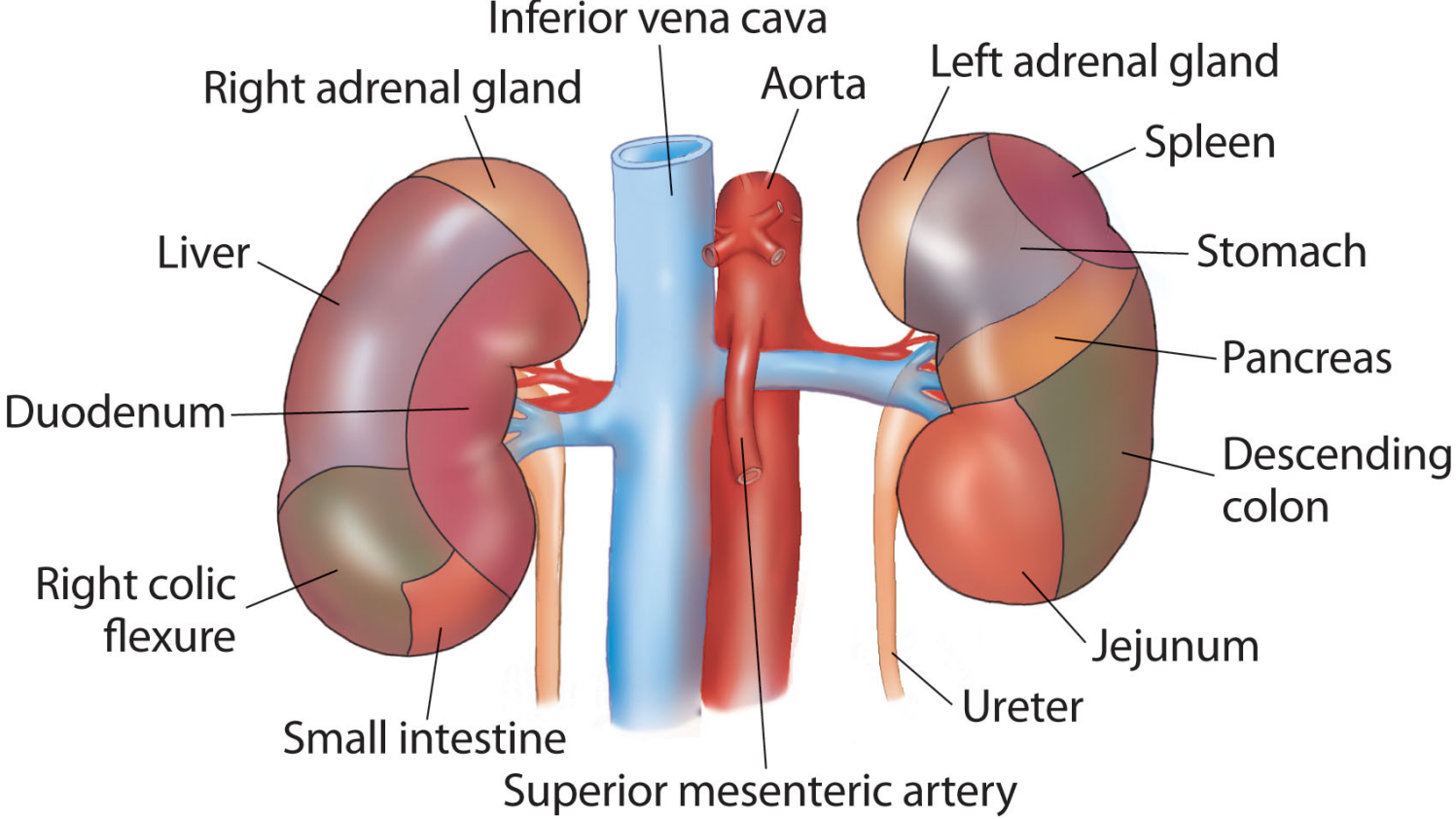
Inferior vena cava
Right adrenal gland
Aorta
Left adrenal gland
Spleen
Liver
Stomach
Pancreas
Duodenum
Descending colon
Right colic flexure
Jejunum
Ureter
Small intestine
Superior mesenteric artery

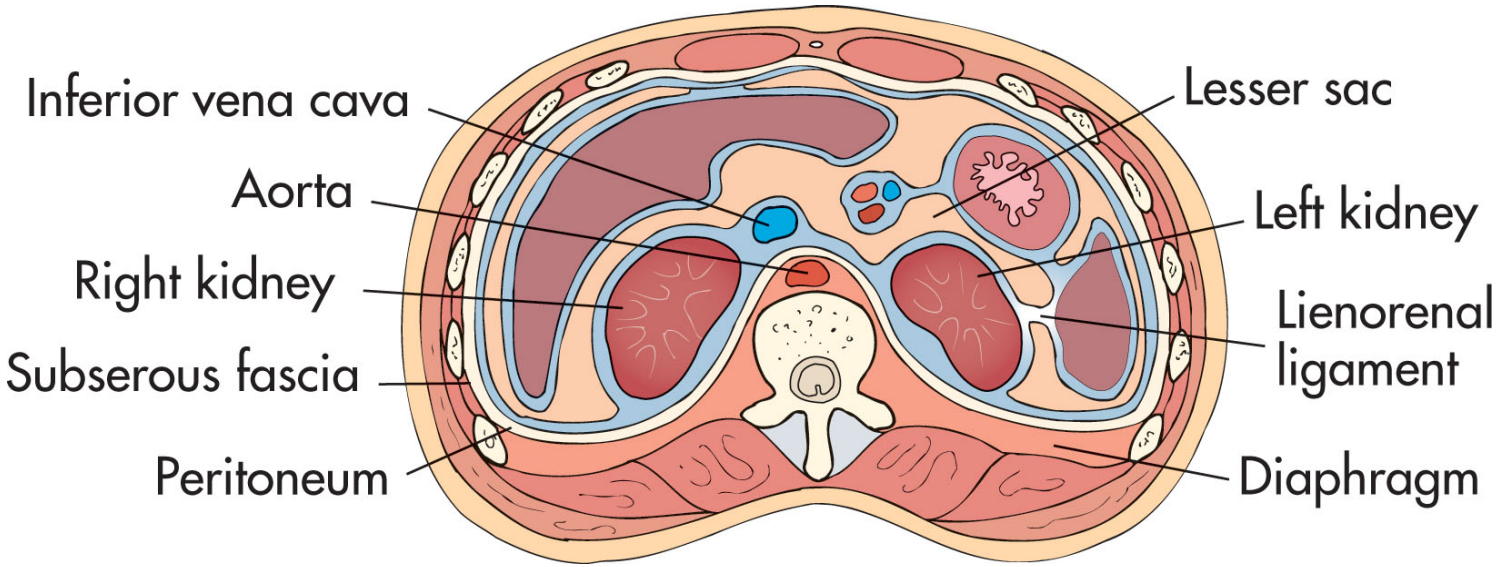
Inferior vena cava
Lesser sac
Aorta
Left kidney
Right kidney
Lienorenal ligament
Subserous fascia
Peritoneum
Diaphragm

PLOS ONE

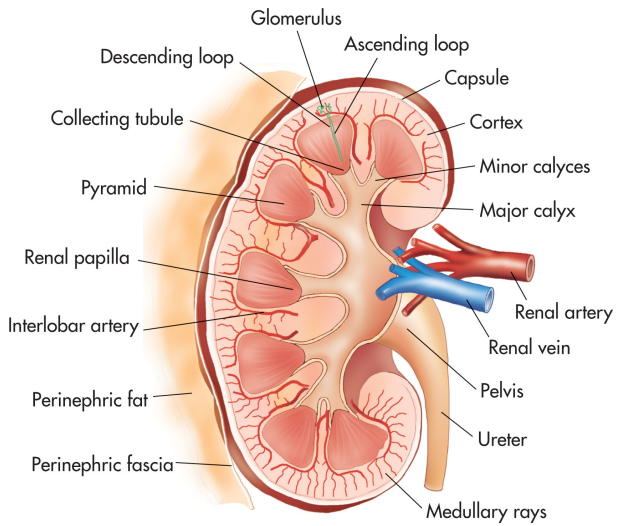

RKL 10.62±0.69cm
LKL 10.76±0.70cm
RKW 4.78±0.75cm
LKW 5.10±0.64cm

OPEN ACCESS

Citation: Su H-A, Hsieh H-Y, Lee C-T, Liao S-C, Chu C-H, Wu C-H (2019) Reference ranges for ultrasonographic renal dimensions as functions of age and body indices: A retrospective observational study in Taiwan. PLoS ONE 14(11): e0224785. https://doi.org/10.1371/journal.pone.0224785

Editor: Giuseppe Remuzzi, Istituto Di Ricerche Farmacologiche Mario Negri, ITALY

Received: November 30, 2018

Accepted: October 22, 2019

Published: November 7, 2019

RESEARCH ARTICLE

Reference ranges for ultrasonographic renal dimensions as functions of age and body indices: A retrospective observational study in Taiwan

Hsuan-An Su[1], Han-Ying Hsieh[2], Chien-Te Lee[3], Shang-Chih Liao[3], Chi-Hsiang Chu[4], Chien-Hsing Wu[3]*

1 Department of Medical Education, Kaohsiung Chang Gung Memorial Hospital, Kaohsiung, Taiwan, **2** Department of Pediatrics, Tung's MetroHarbor Hospital, Taichung, Taiwan, **3** Division of Nephrology, Department of Internal Medicine, Kaohsiung Chang Gung Memorial Hospital, Kaohsiung, Taiwan, **4** Clinical Trial Center, Kaohsiung Chang Gung Memorial Hospital, Kaohsiung, Taiwan

* chienhsingwu@gmail.com

Abstract

An ethnicity-based reference range for normal renal size is fundamental for ultrasonographic assessment. Herein, we aimed to establish a Chinese renal reference by a large sample size, as well as to elucidate the relationship of renal dimension to age and body indices, with the aid of a comprehensive literature review. Records of 3707 healthy cases were obtained from health evaluation centers of Kaohsiung and Linkuo Chang Gung Memorial Hospitals. As a result, the mean right renal length was 10.62±0.69 cm, left renal length 10.76±0.70 cm, right renal width 4.78±0.75 cm, and left renal width 5.10±0.64 cm. Renal size was well-correlated curvilinearly to age, while linearly to body height, body weight, and body mass index. Renal size increases and then decreases with aging, and significant variations of renal size exist among different ethnicities. Our work provides a reliable reference range for renal size in the Chinese population, and valid relationships between renal dimensions and other parameters.

RESEARCH ARTICLE

Reference ranges for ultrasonographic renal dimensions as functions of age and body indices: A retrospective observational study in Taiwan

Hsuan-An Su[1], Han-Ying Hsieh
Chien-Hsing Wu[3]*

1 Department of Medical Education, K
2 Department of Pediatrics, Tung's M
Department of Internal Medicine, Kao

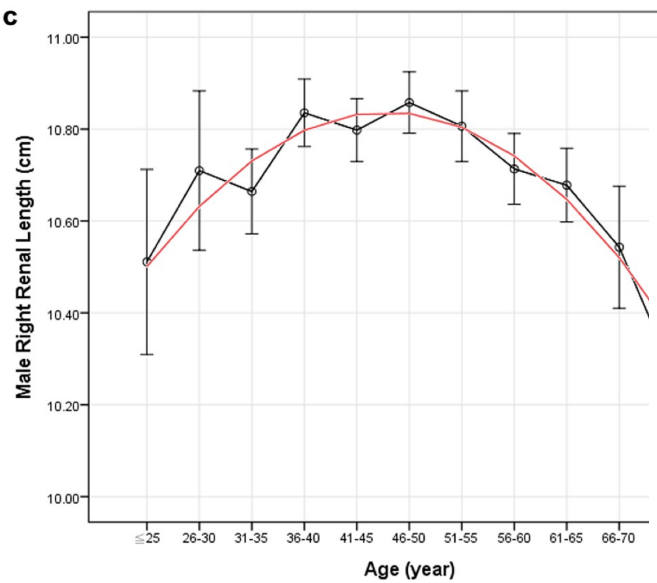

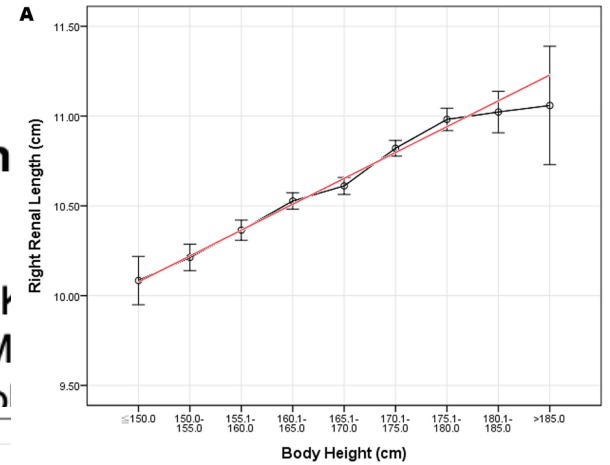

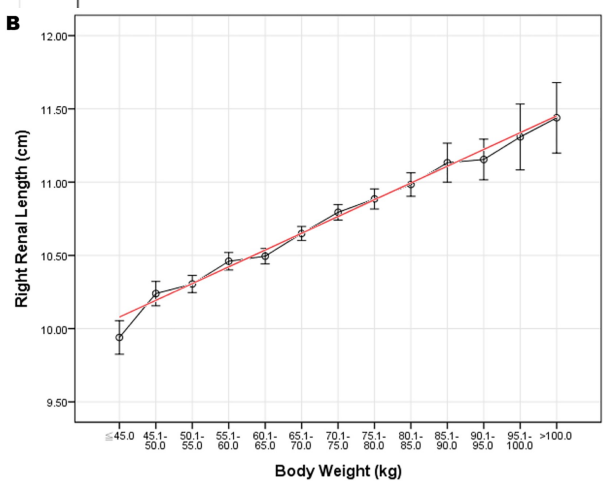

Liao[3], Chi-Hsiang Chu[4],

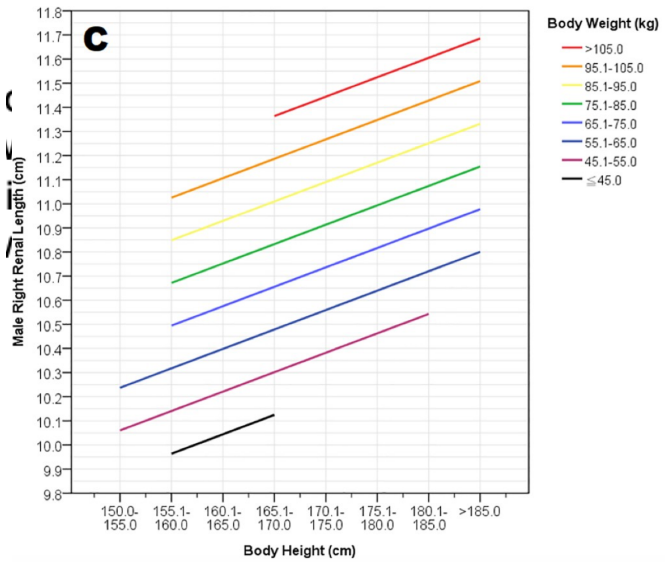

damental for ultrasono-
renal reference by a large
nension to age and body indi-

Kidney

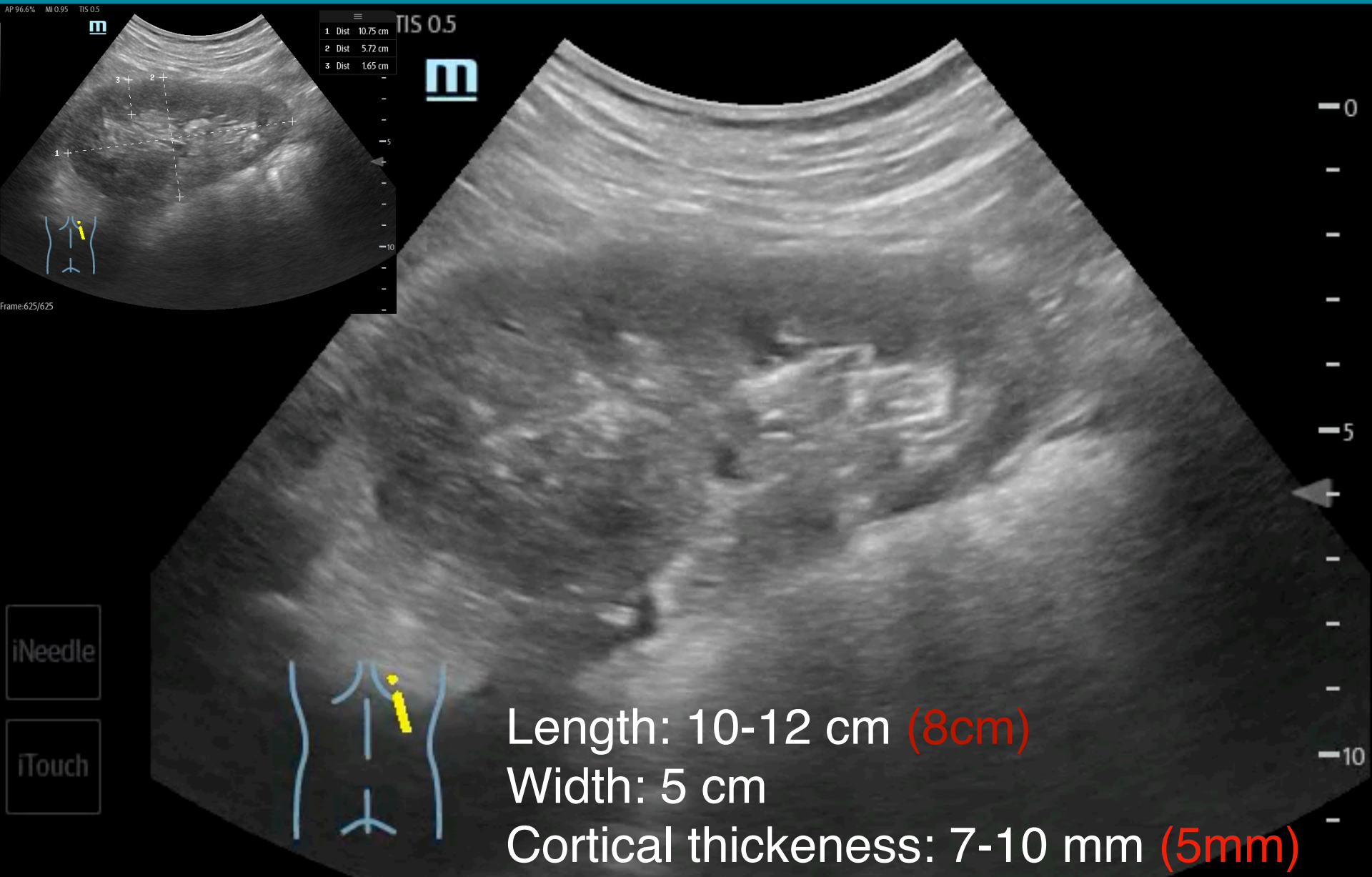
AP 96.6% MI 0.95 TIS 0.5
1 Dist 10.75 cm
2 Dist 5.72 cm
3 Dist 1.65 cm
Frame:625/625
TIS 0.5
iNeedle
iTouch
Length: 10-12 cm (8cm)
Width: 5 cm
Cortical thickness: 7-10 mm (5mm)

Kidney

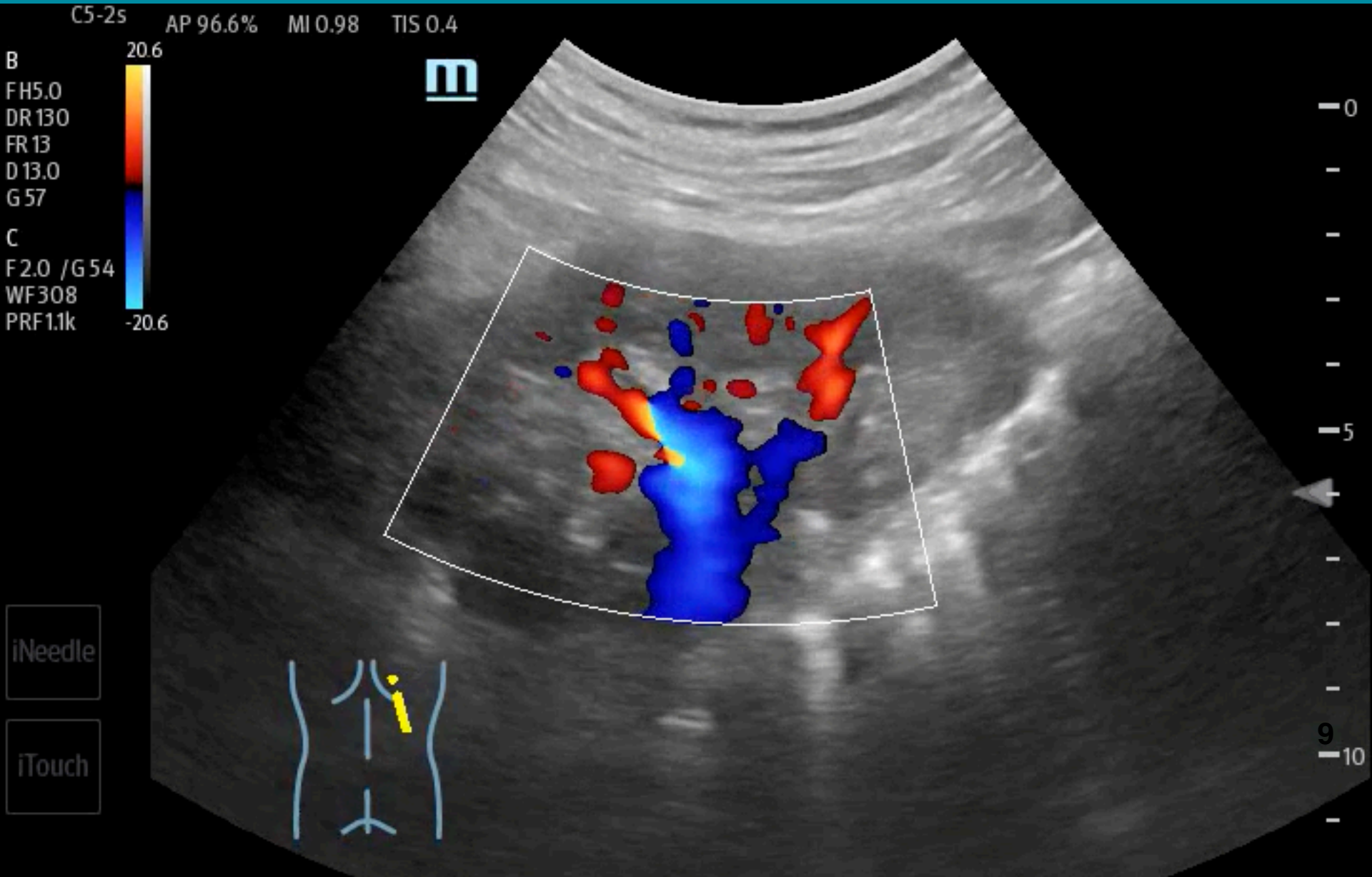
C5-2s
AP 96.6%
MI 0.98
TIS 0.4
B
FH5.0
DR 130
FR 13
D 13.0
G 57
C
F 2.0 /G 54
WF 308
PRF 1.1k
20.6
-20.6
iNeedle
iTouch
0
5
9
10

Kidney

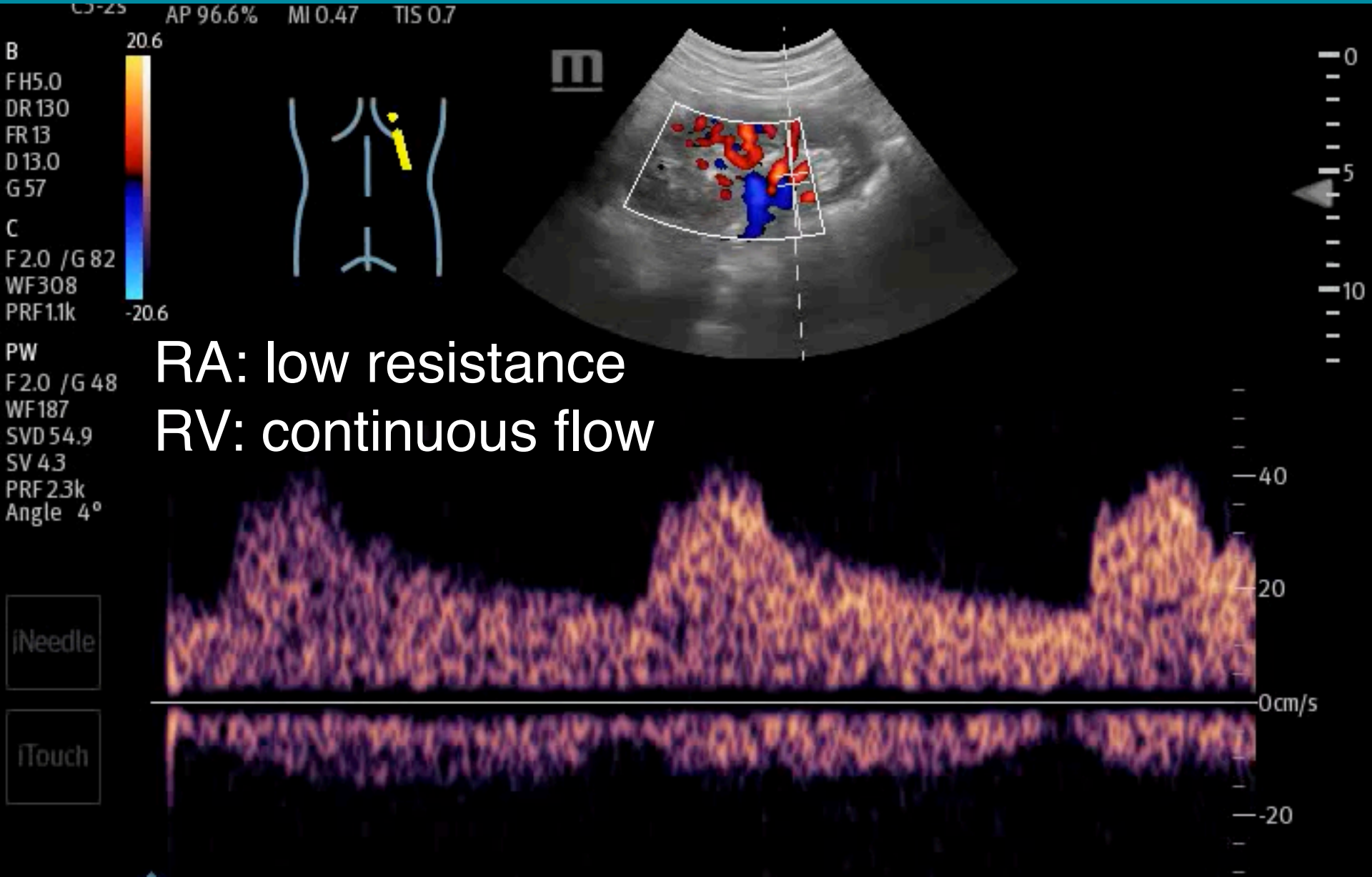

RA: low resistance
RV: continuous flow

Echogenecity

Pancreas > Spleen >Liver > Renal cortex

Echogenecity: Iso-hypo-hyper

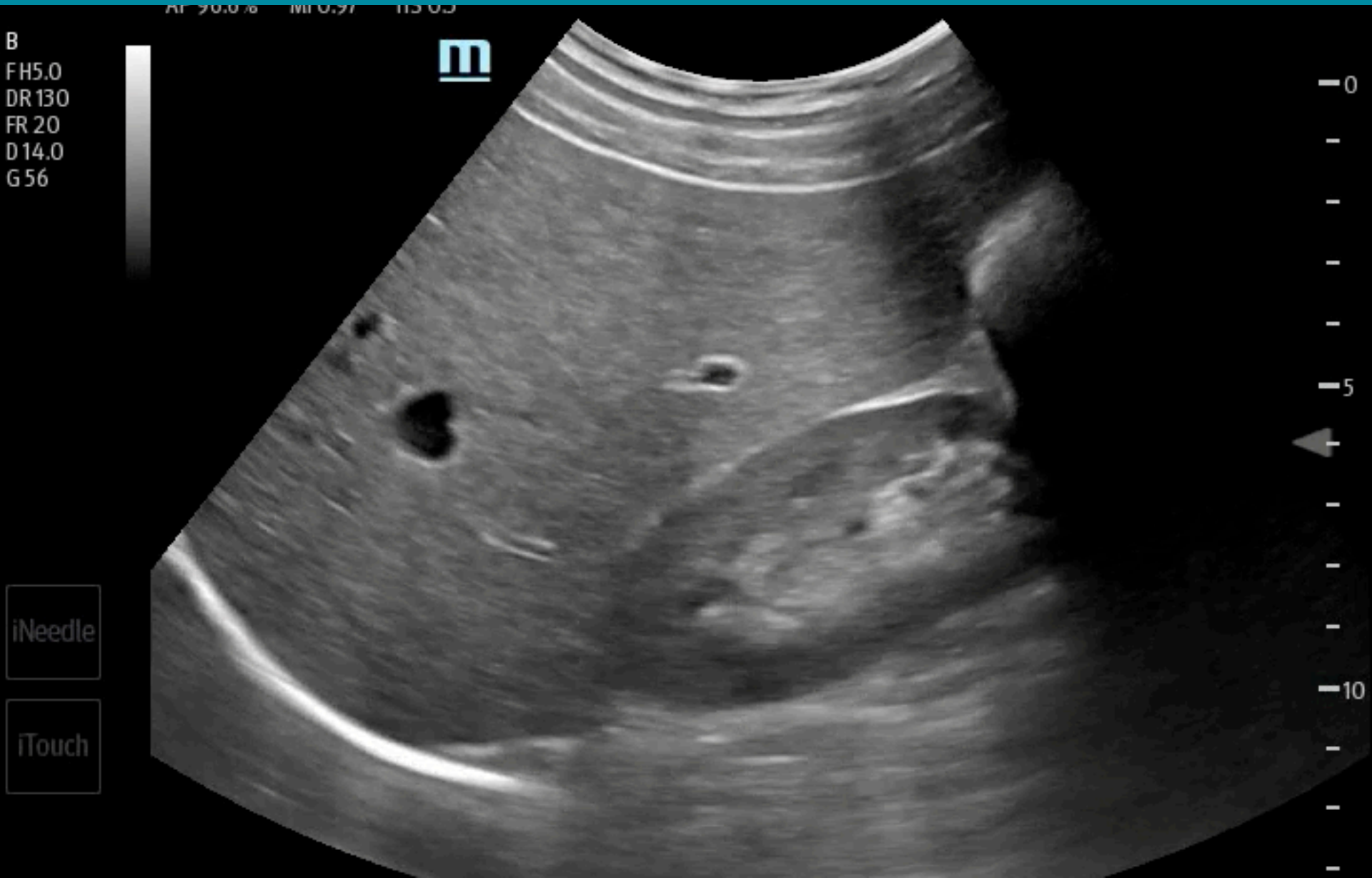


劍突---腋前線
肋間擺位微調

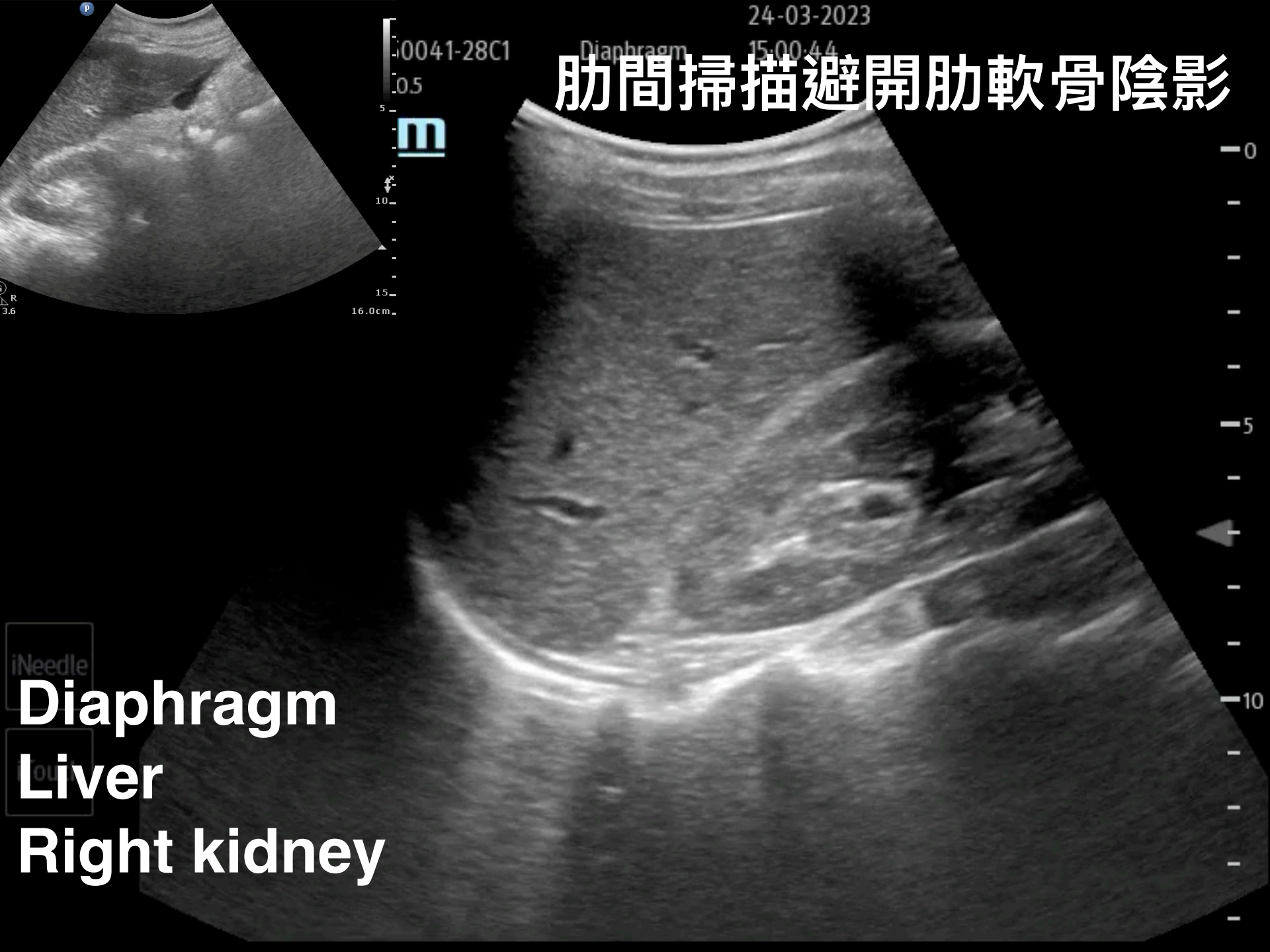
肋間掃描避開肋軟骨陰影
24-03-2023
Diaphragm
15:00:44
0041-28C1
0.5
16.0cm
iNeedle
Diaphragm
Liver
Right kidney

Intussusception

小孩優先找右上腹

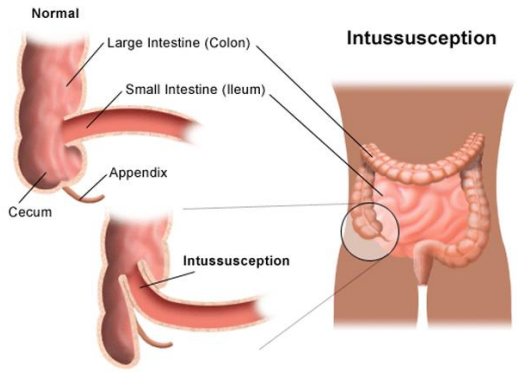

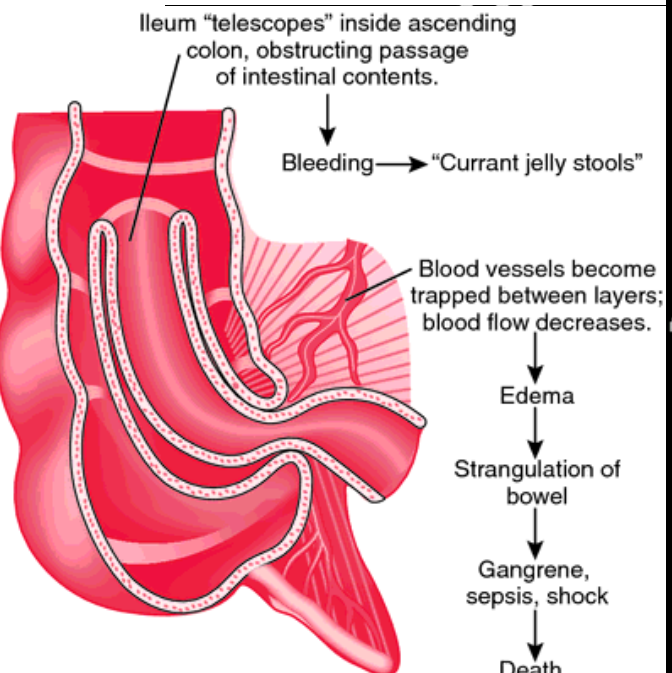

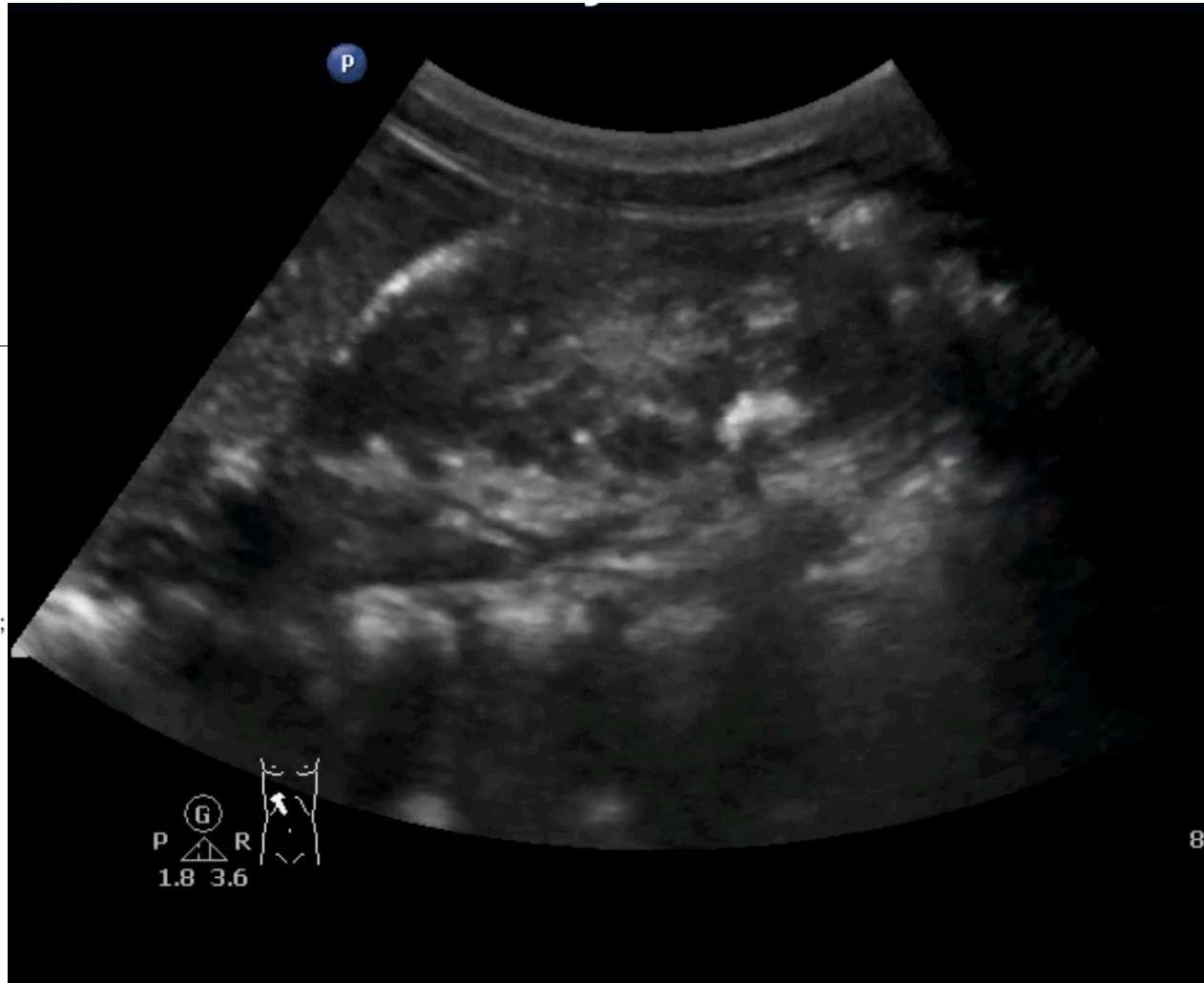

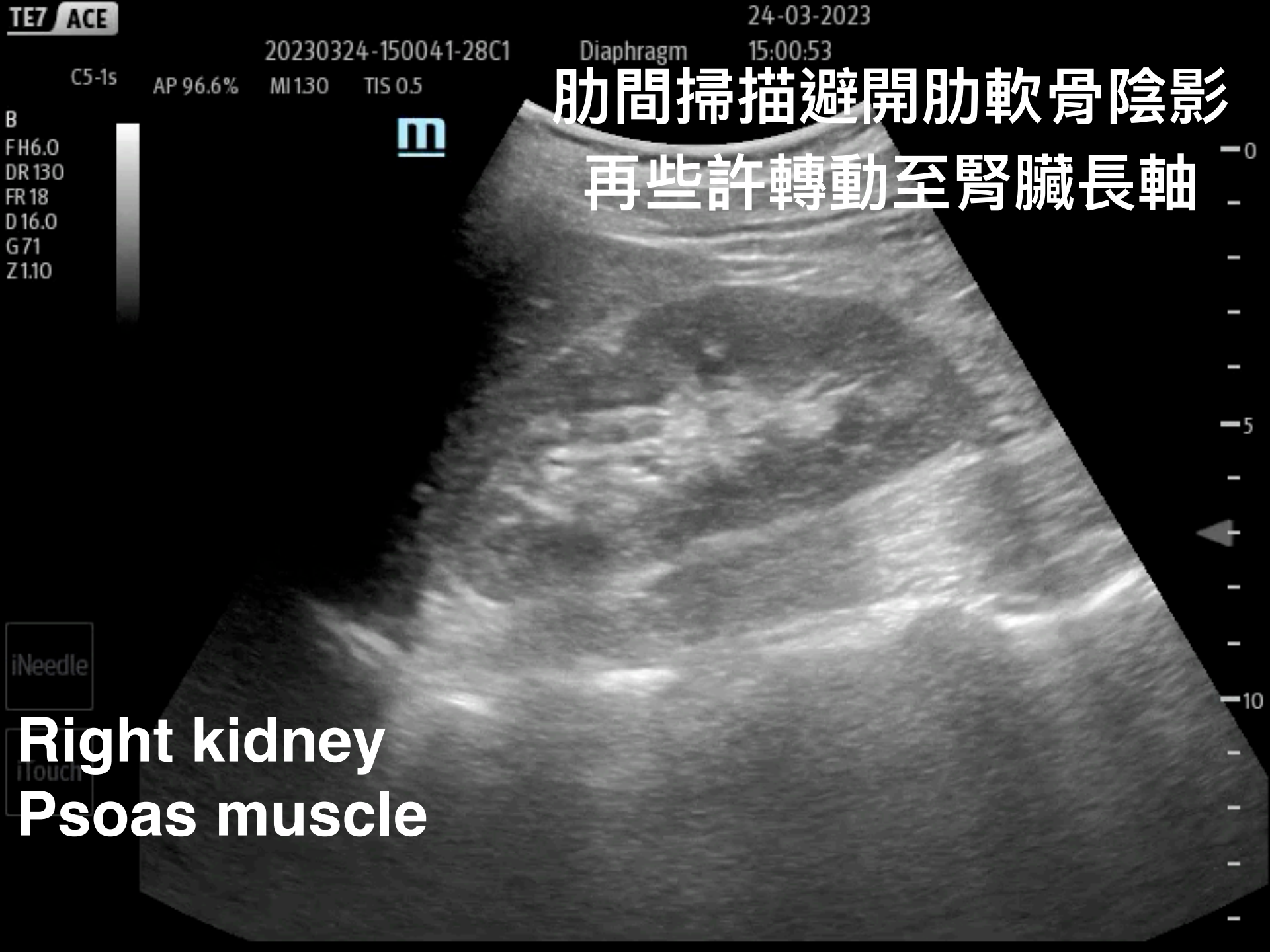
TE7 ACE
24-03-2023
20230324-150041-28C1
Diaphragm
15:00:53
C5-1s
AP 96.6%
MI 1.30
TIS 0.5
B
F H6.0
DR 130
FR 18
D 16.0
G 71
Z 1.10
肋間掃描避開肋軟骨陰影
再些許轉動至腎臟長軸
iNeedle
iTouch
Right kidney
Psoas muscle

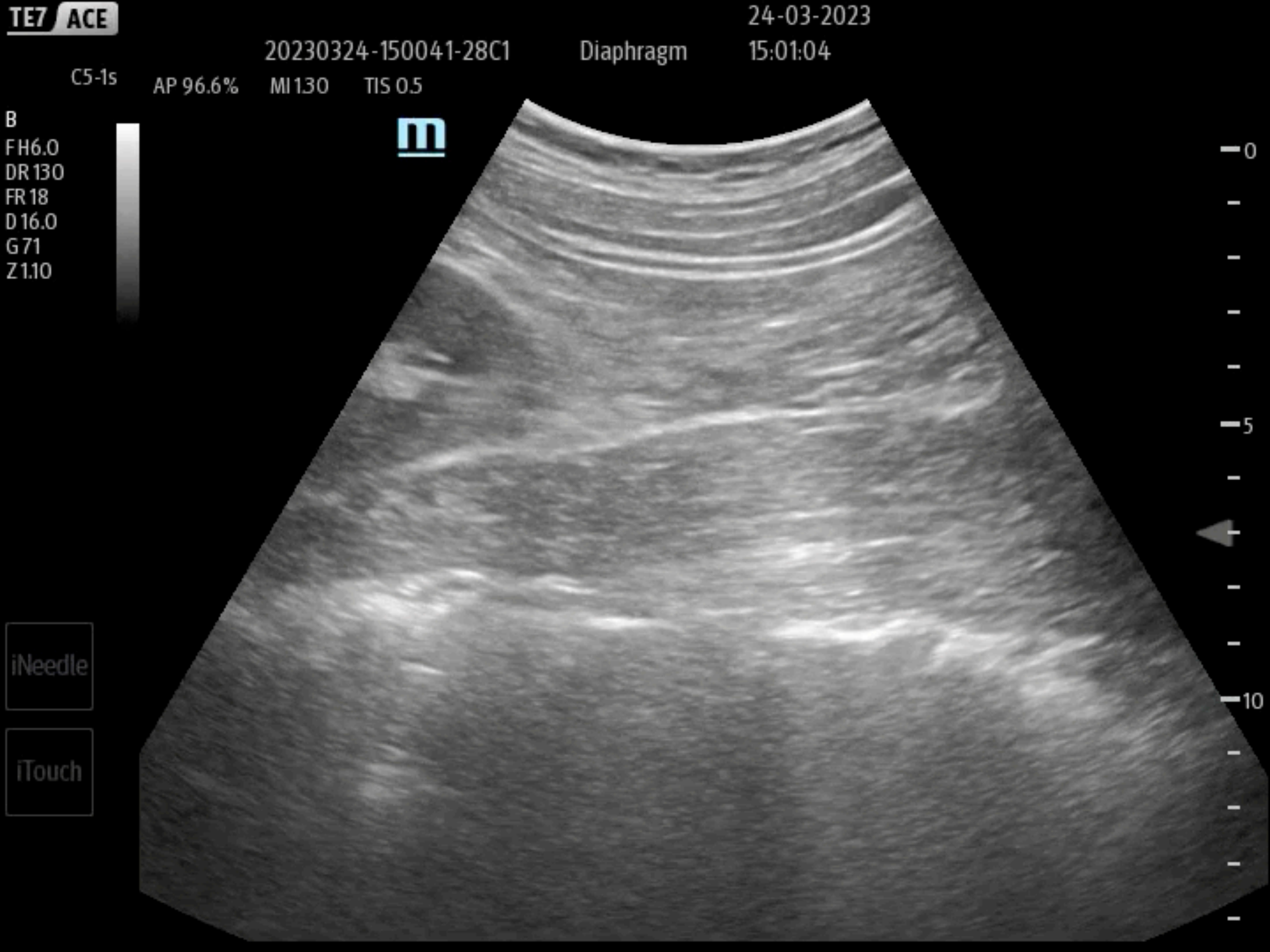
TE7 ACE
24-03-2023
20230324-150041-28C1
Diaphragm
15:01:04
C5-1s
AP 96.6%
MI 1.30
TIS 0.5
B
F H6.0
DR 130
FR 18
D 16.0
G 71
Z 1.10
iNeedle
iTouch
0
5
10

Renal artery: side of aorta

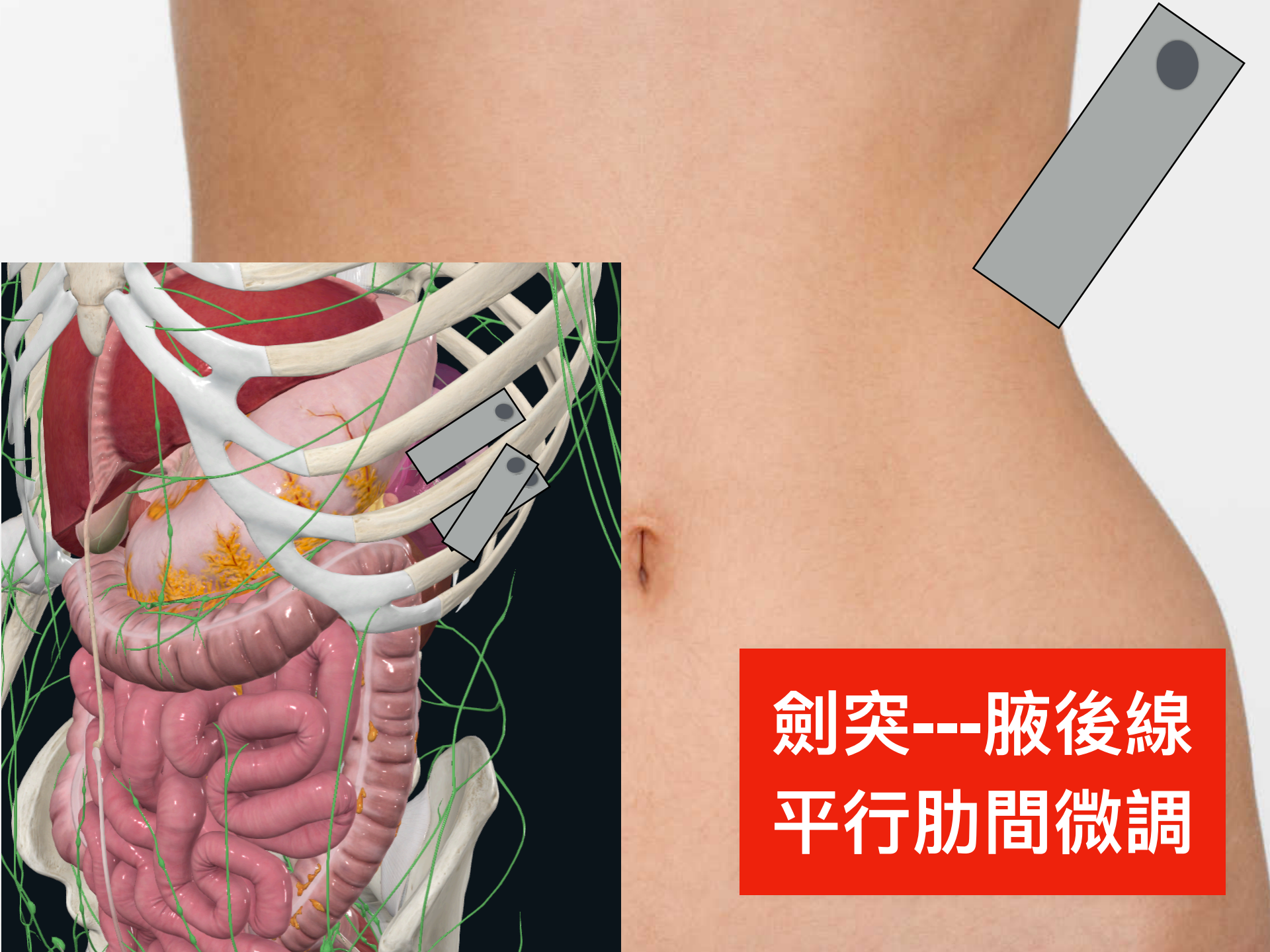
劍突---腋後線
平行肋間微調

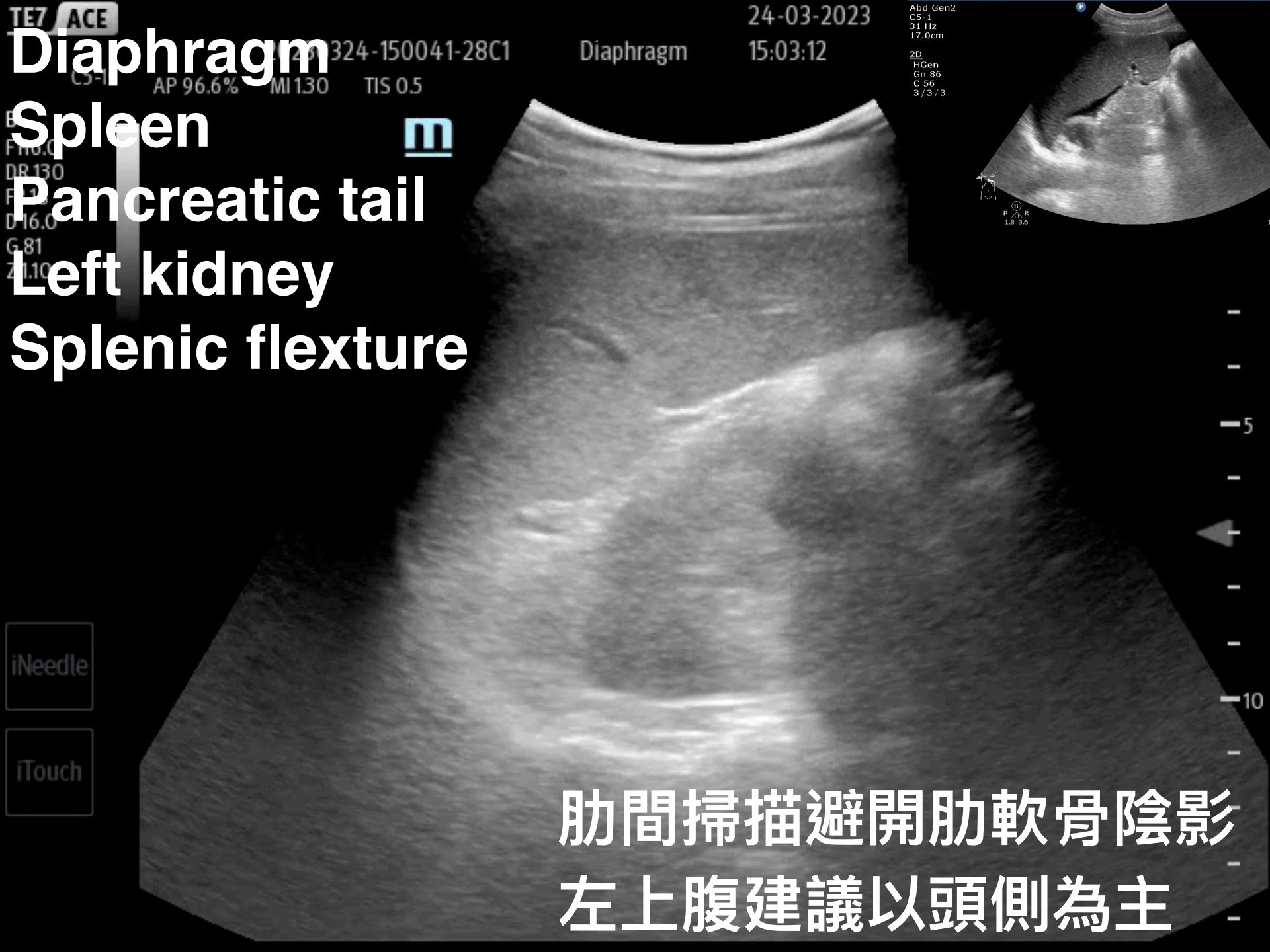
TE7 ACE
24-03-2023
15:03:12
Diaphragm
AP 96.6%
MI 1.30
TIS 0.5
Abd Gen2
C5-1
31 Hz
17.0cm
2D
HGen
Gn 86
C 56
3/3/3
iNeedle
iTouch
Diaphragm
Spleen
Pancreatic tail
Left kidney
Splenic flexture
肋間掃描避開肋軟骨陰影
左上腹建議以頭側為主

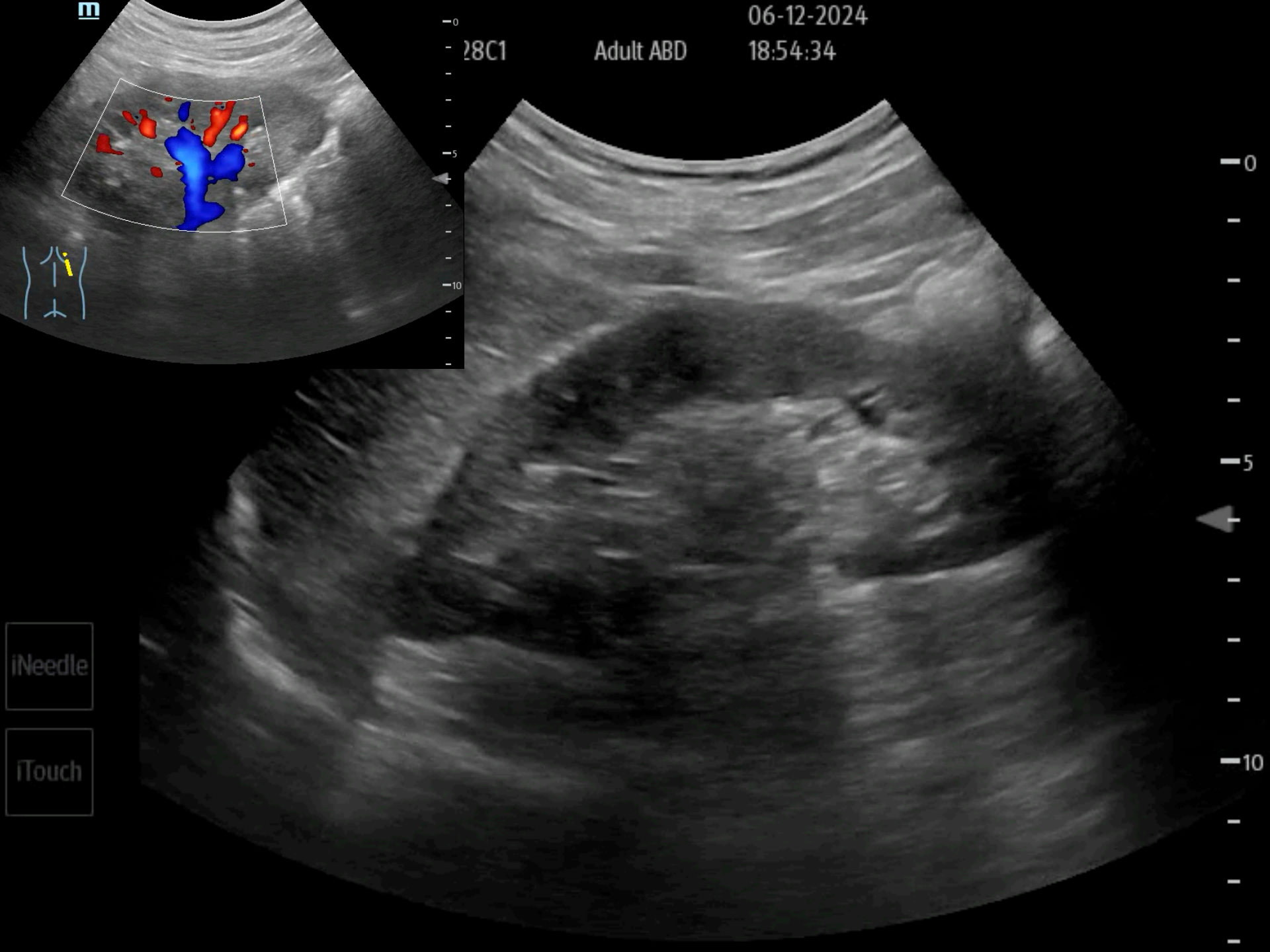
06-12-2024
28C1
Adult ABD
18:54:34
iNeedle
iTouch

恥骨聯合上
先縱-後橫

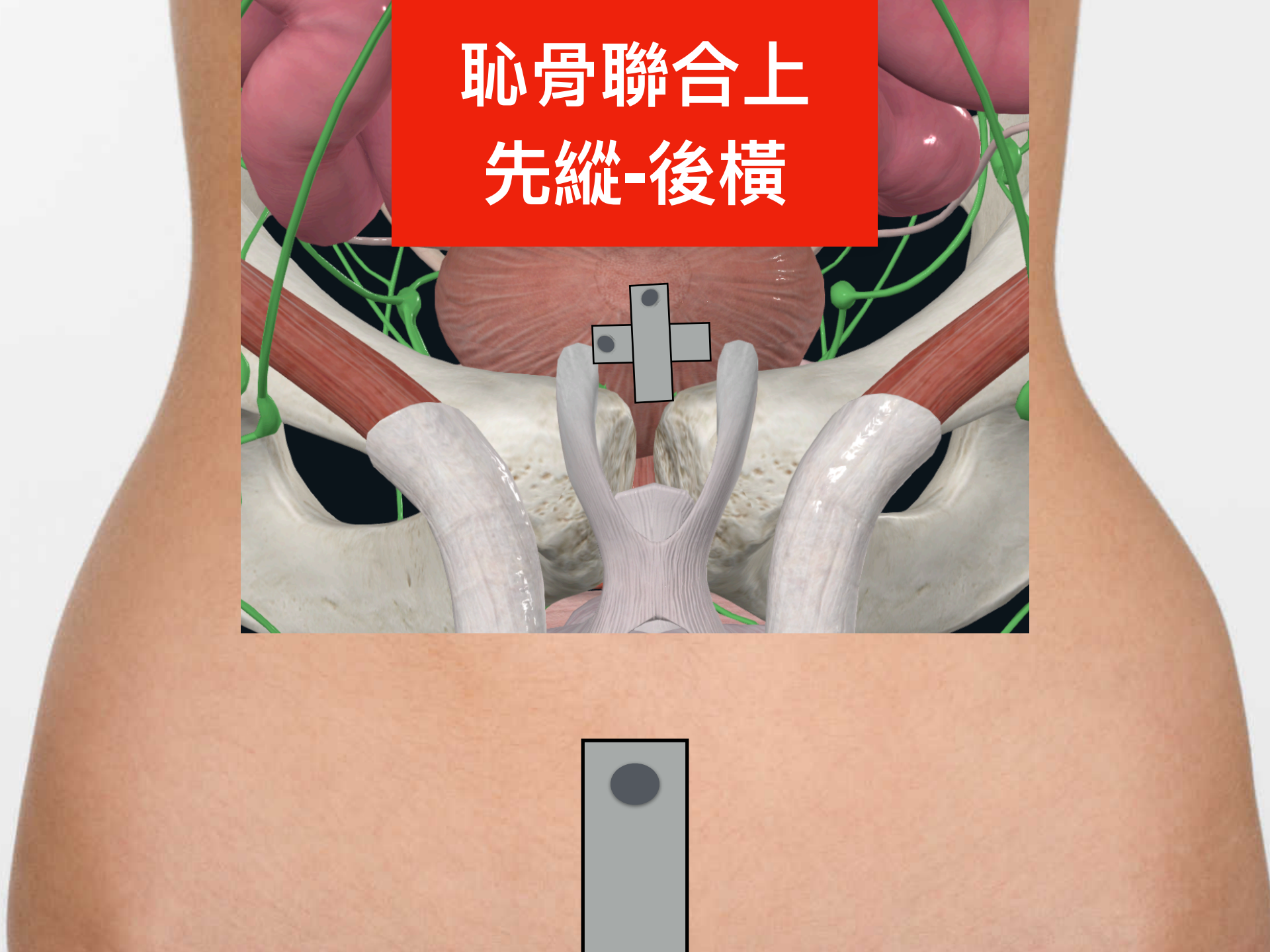

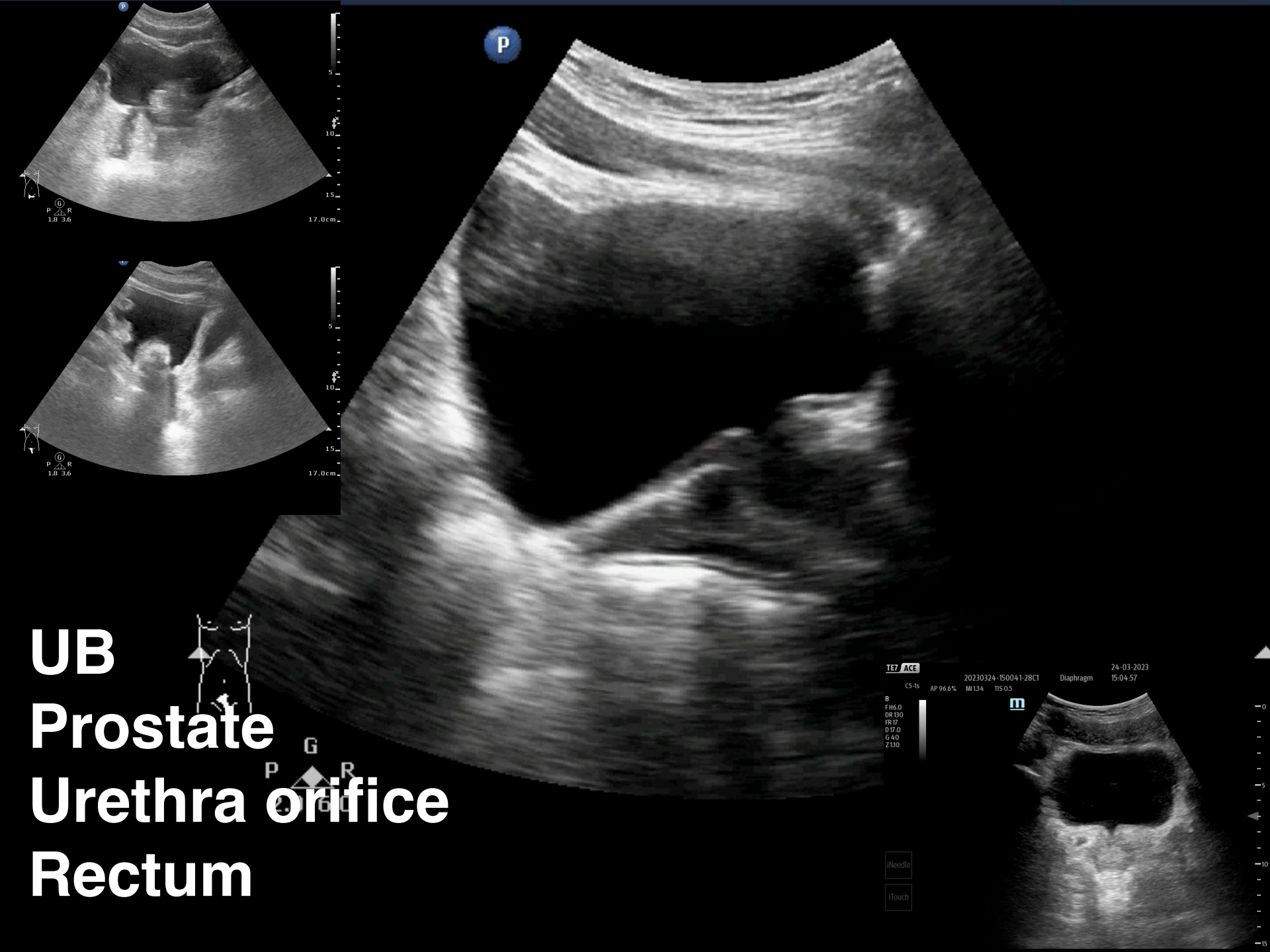

UB
Prostate
Urethra orifice
Rectum

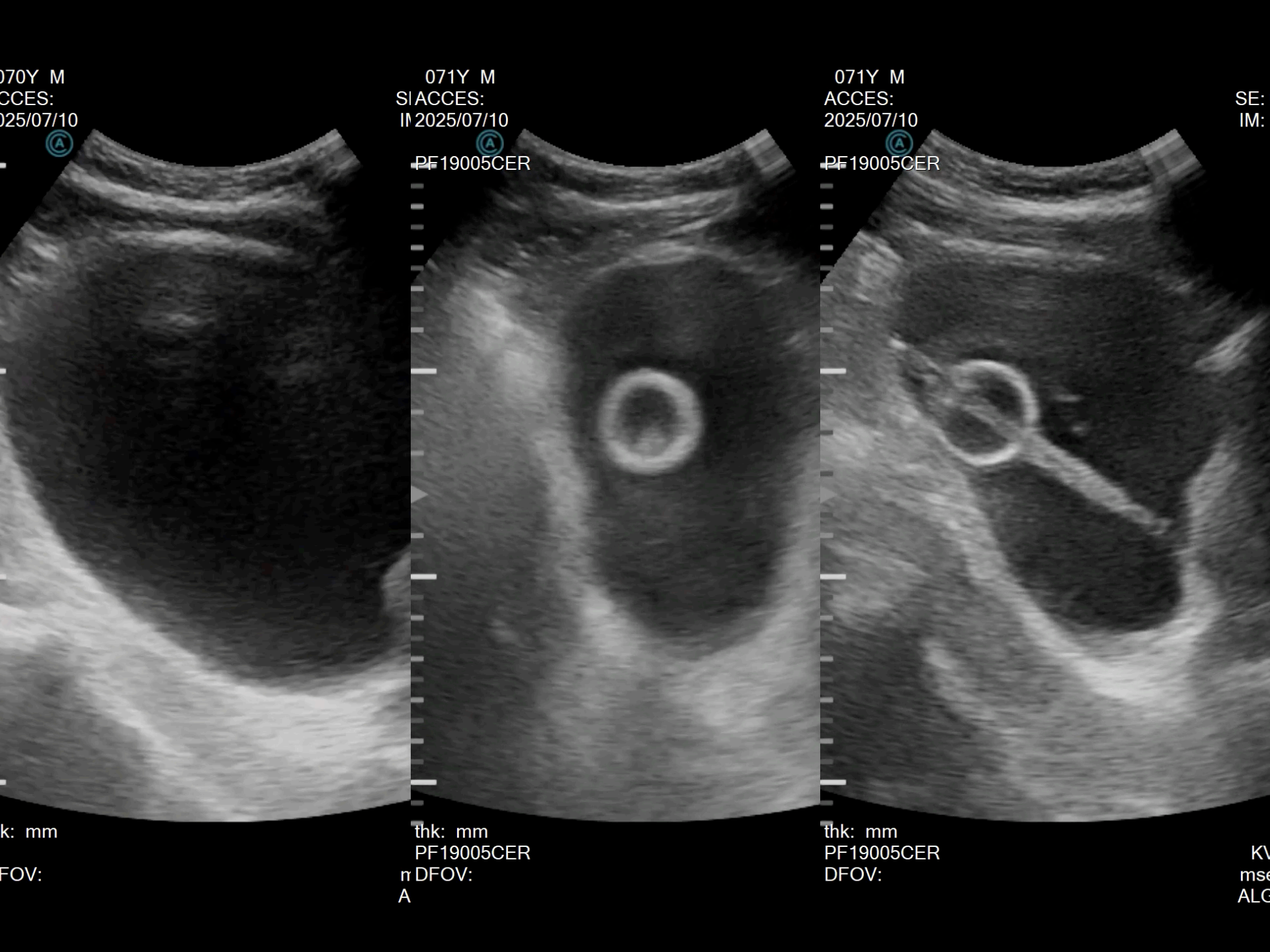
070Y M
CCES:
025/07/10
k: mm
FOV:
071Y M
SI ACCES:
IN 2025/07/10
PF19005CER
thk: mm
PF19005CER
n DFOV:
A
071Y M
ACCES:
2025/07/10
PF19005CER
thk: mm
PF19005CER
DFOV:
SE:
IM:
KV
mse
ALG

Renal colic的D/D永遠要有AAA

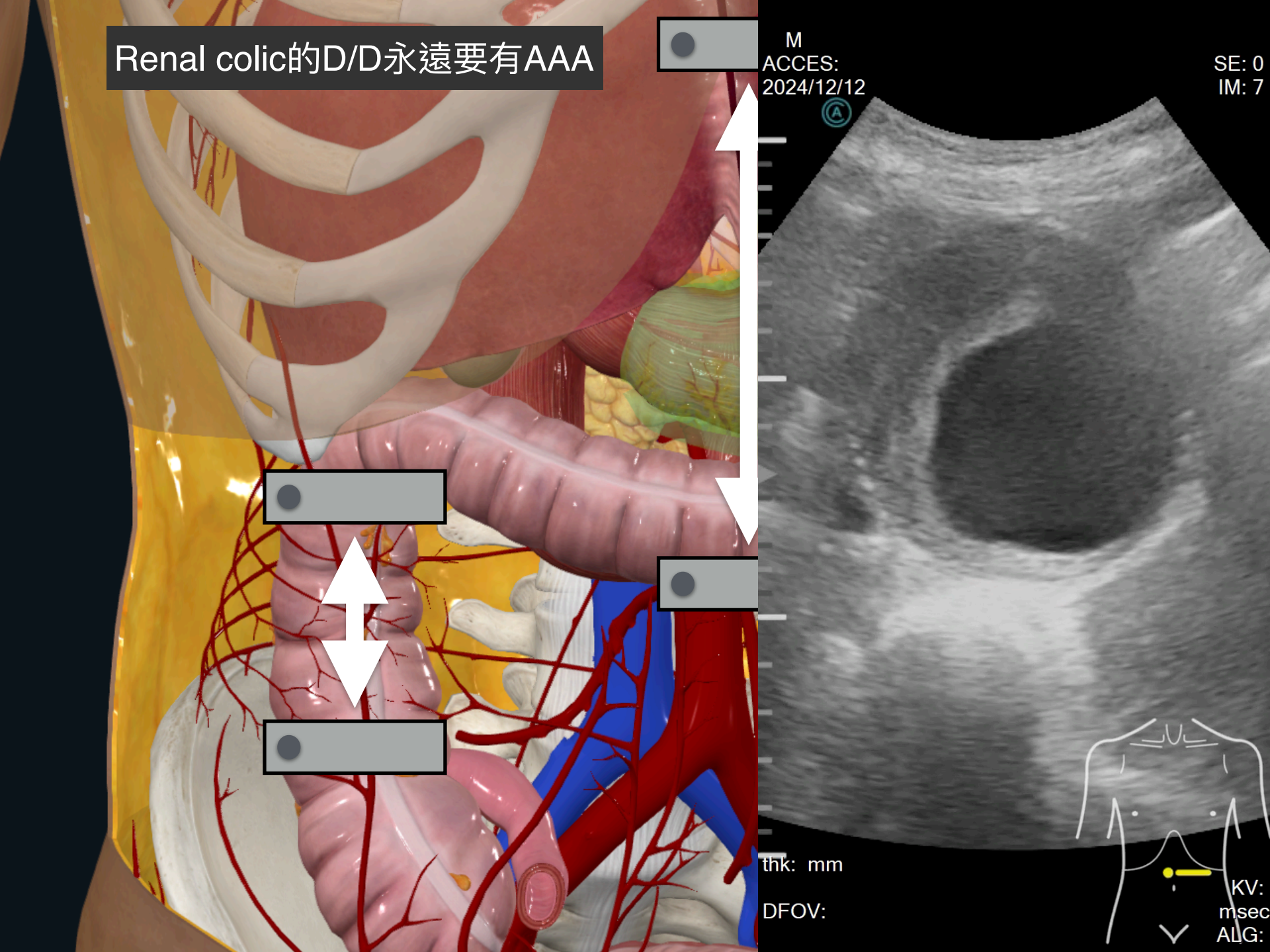

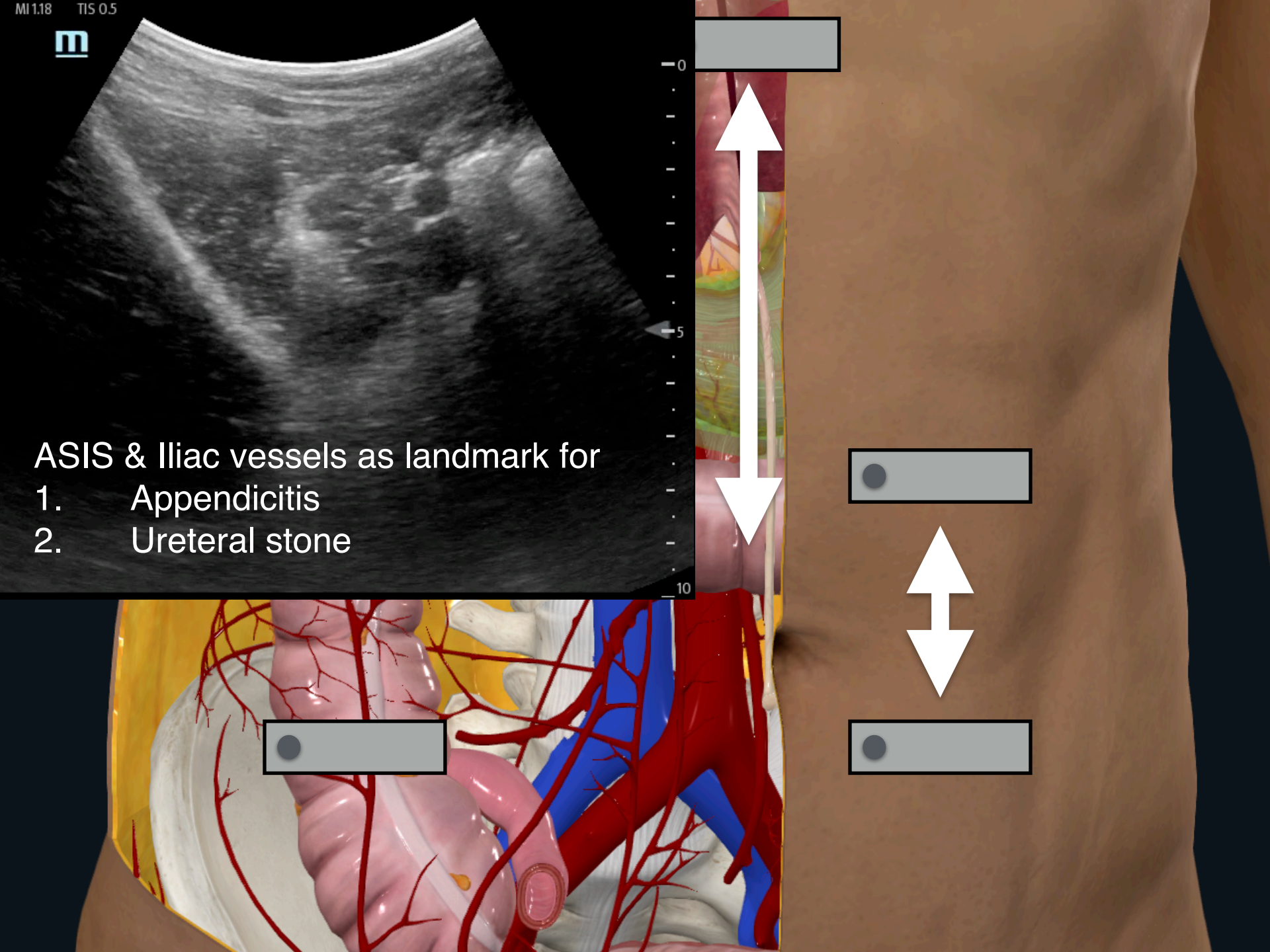
MI 1.18
TIS 0.5
0
5
10
ASIS & Iliac vessels as landmark for
1. Appendicitis
2. Ureteral stone

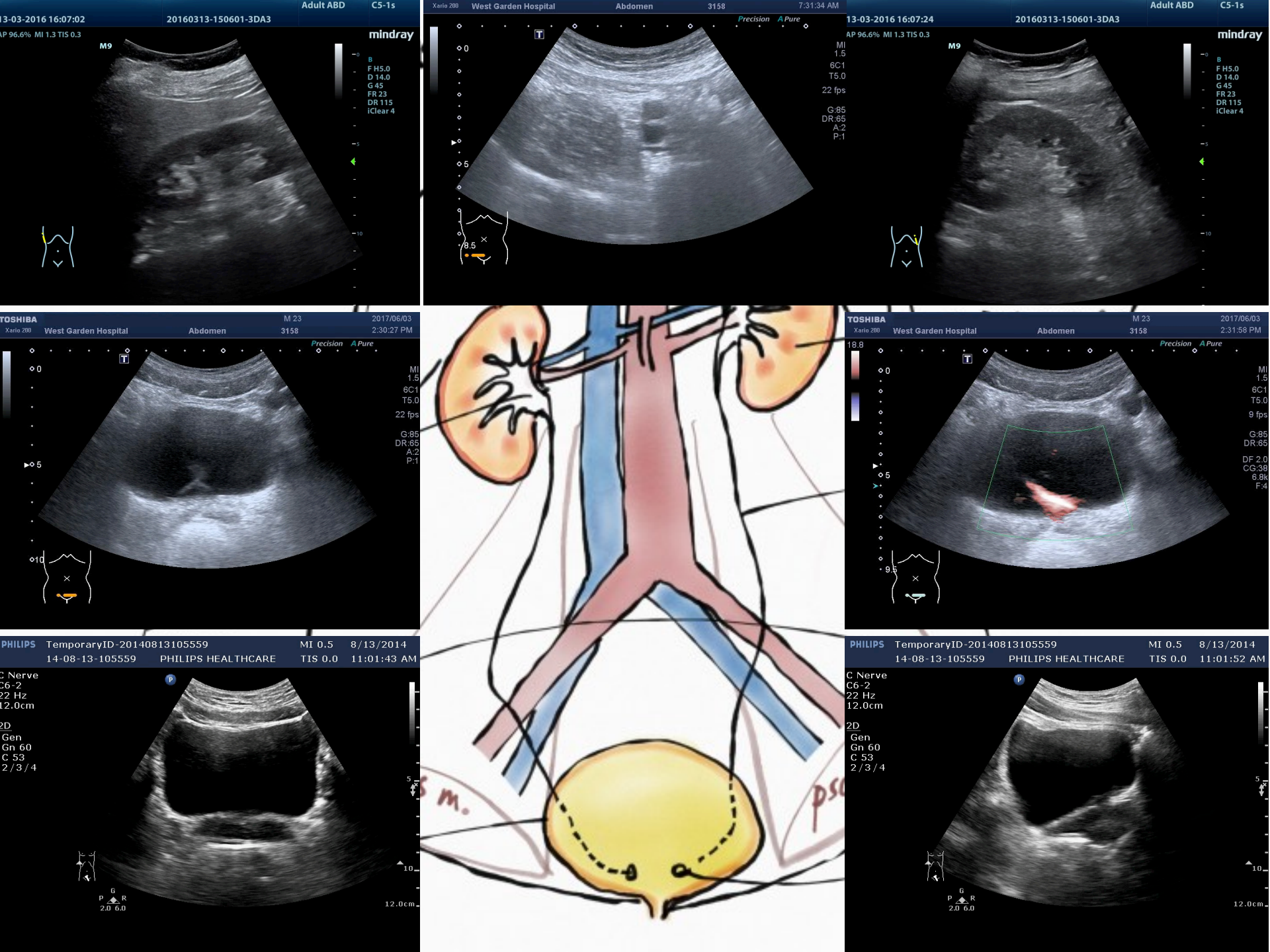
13-03-2016 16:07:02
20160313-150601-3DA3
Adult ABD
C5-1s
mindray
M9
Xario 200
West Garden Hospital
Abdomen
3158
7:31:34 AM
Precision
A Pure
13-03-2016 16:07:24
TOSHIBA
M 23
2017/06/03
2:30:27 PM
2:31:58 PM
PHILIPS
TemporaryID-20140813105559
14-08-13-105559
PHILIPS HEALTHCARE
MI 0.5
TIS 0.0
8/13/2014
11:01:43 AM
11:01:52 AM
C Nerve
C6-2
22 Hz
12.0cm
2D
Gen
Gn 60
C 53
2/3/4

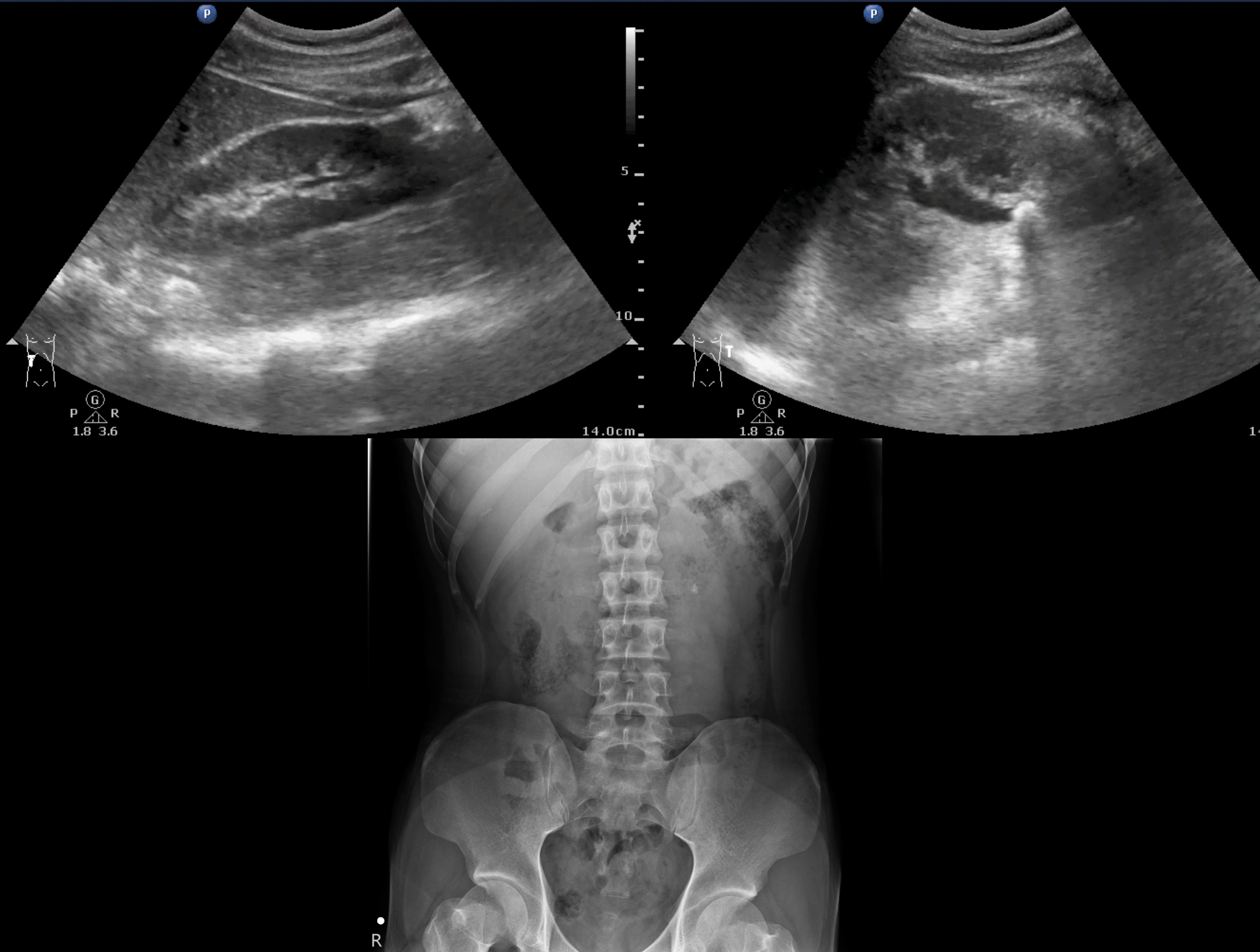
P
5
10
14.0cm
P R
1.8 3.6
P
P R
1.8 3.6
R

Coronal view for hydronephrosis

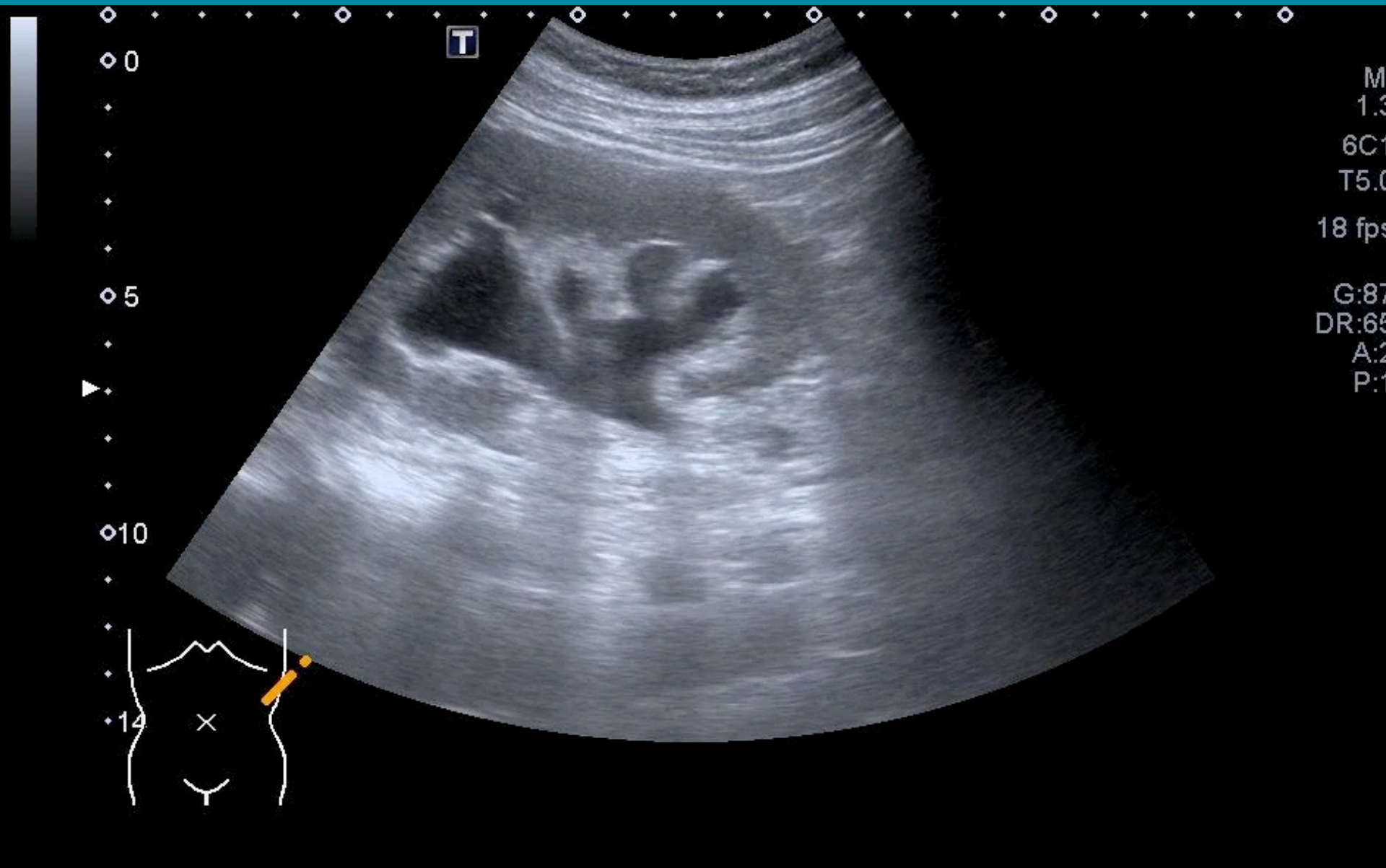

Transverse (medial to colon)

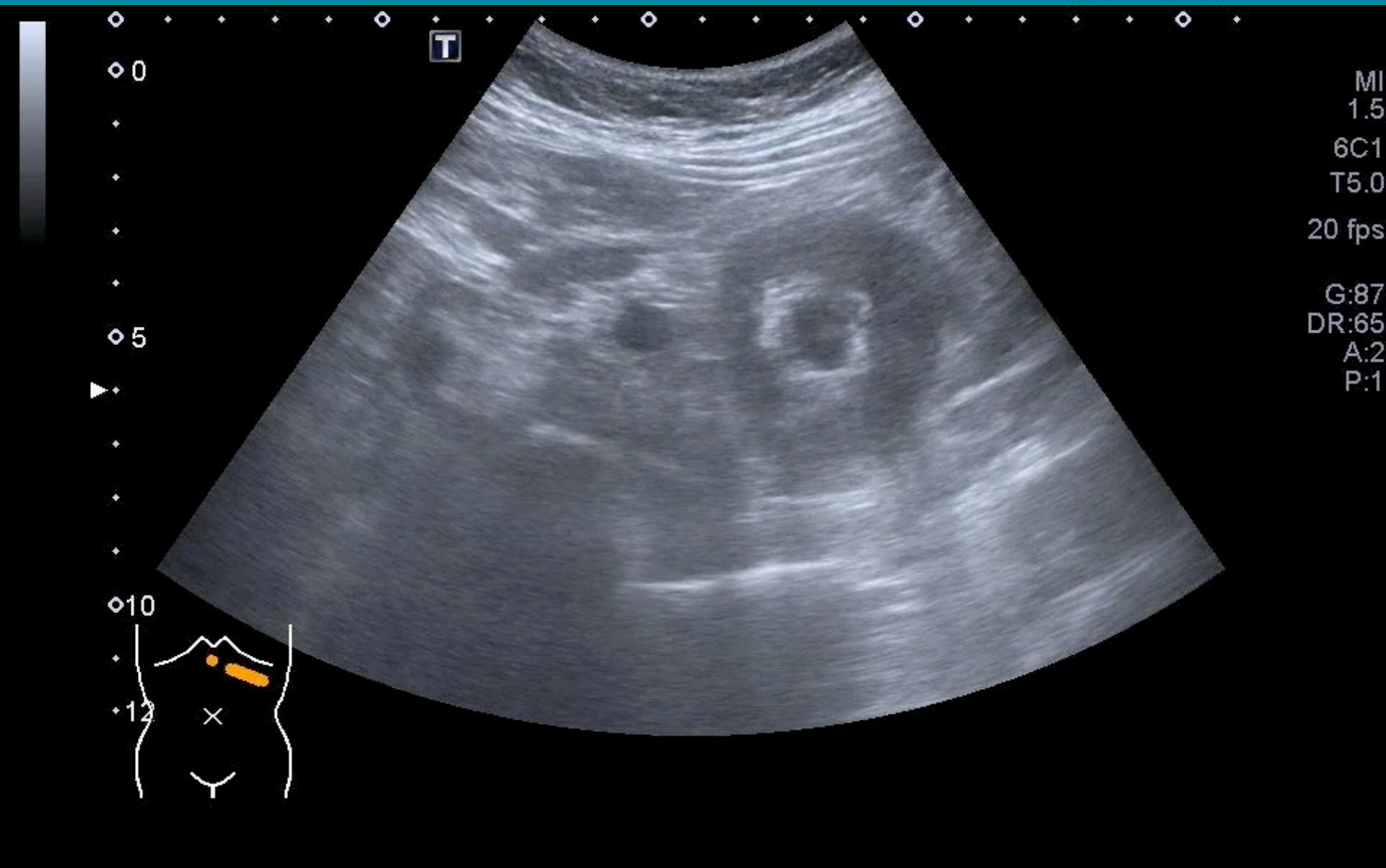

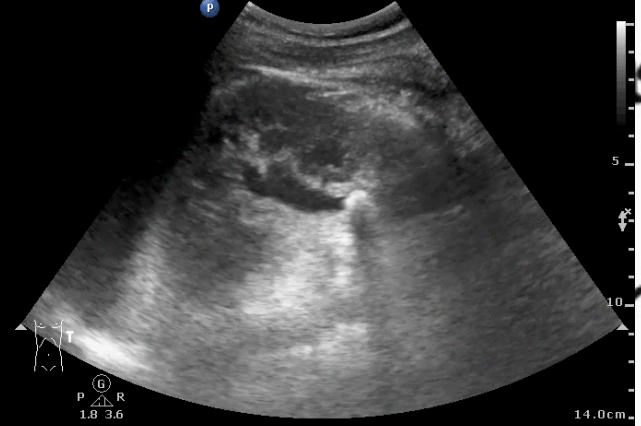

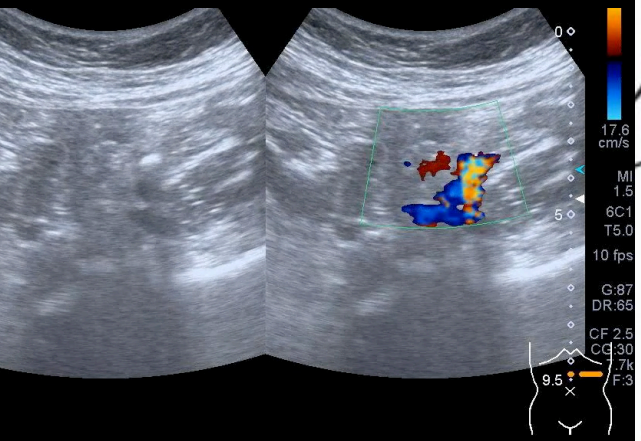

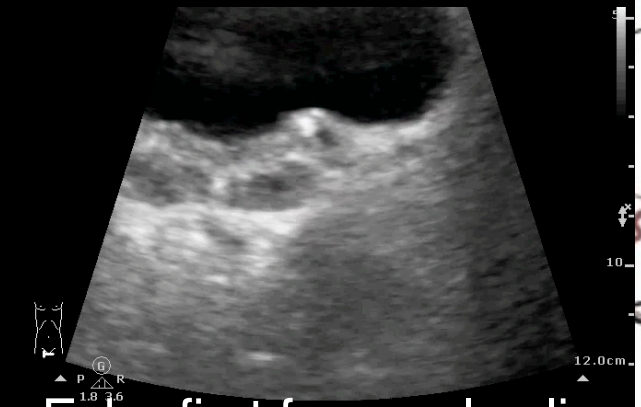

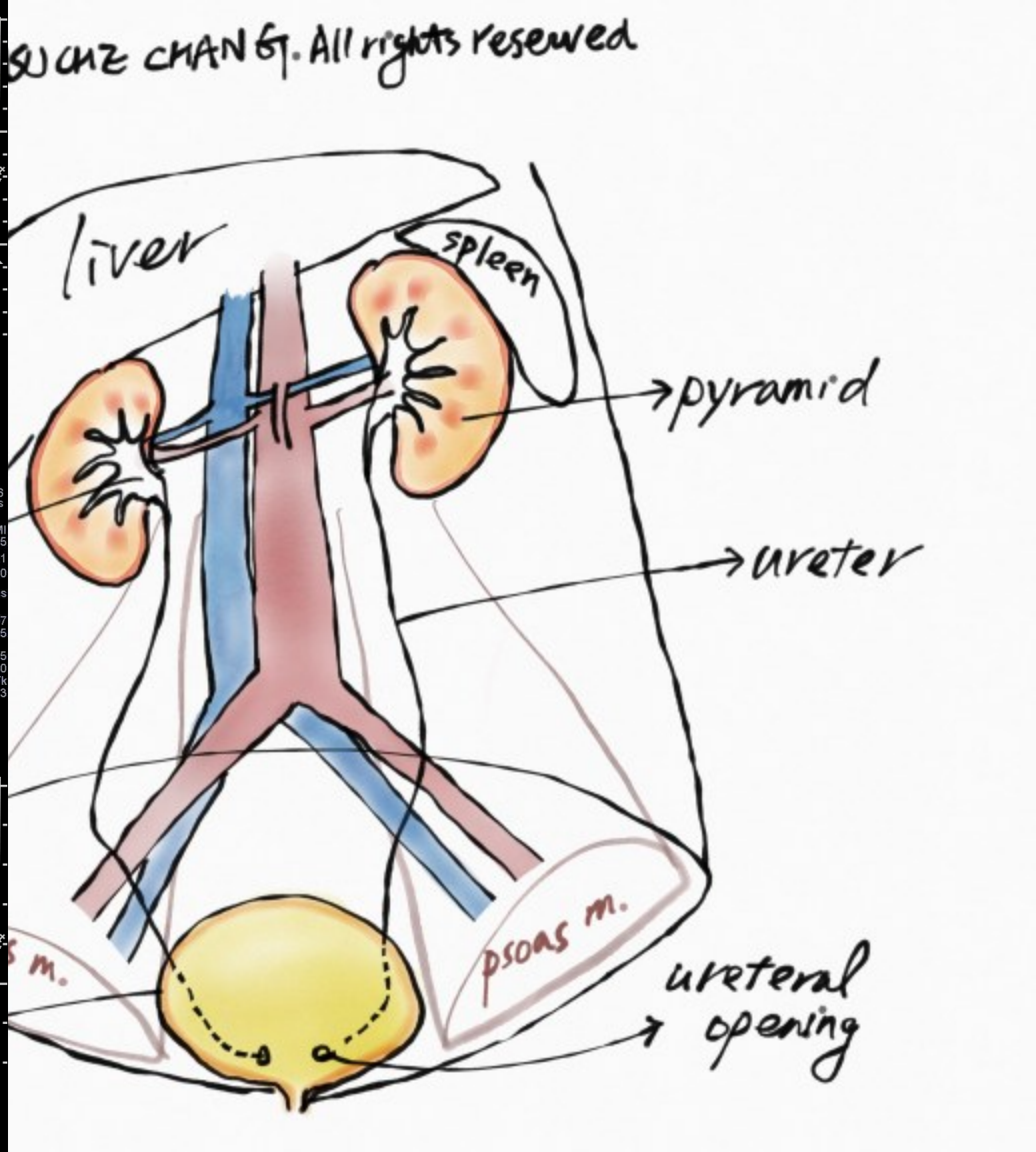

Echo first for renal colic

Throw the SAFER Lasso!

Size

Air

Fluid

Echo-genicity

Regional lesion

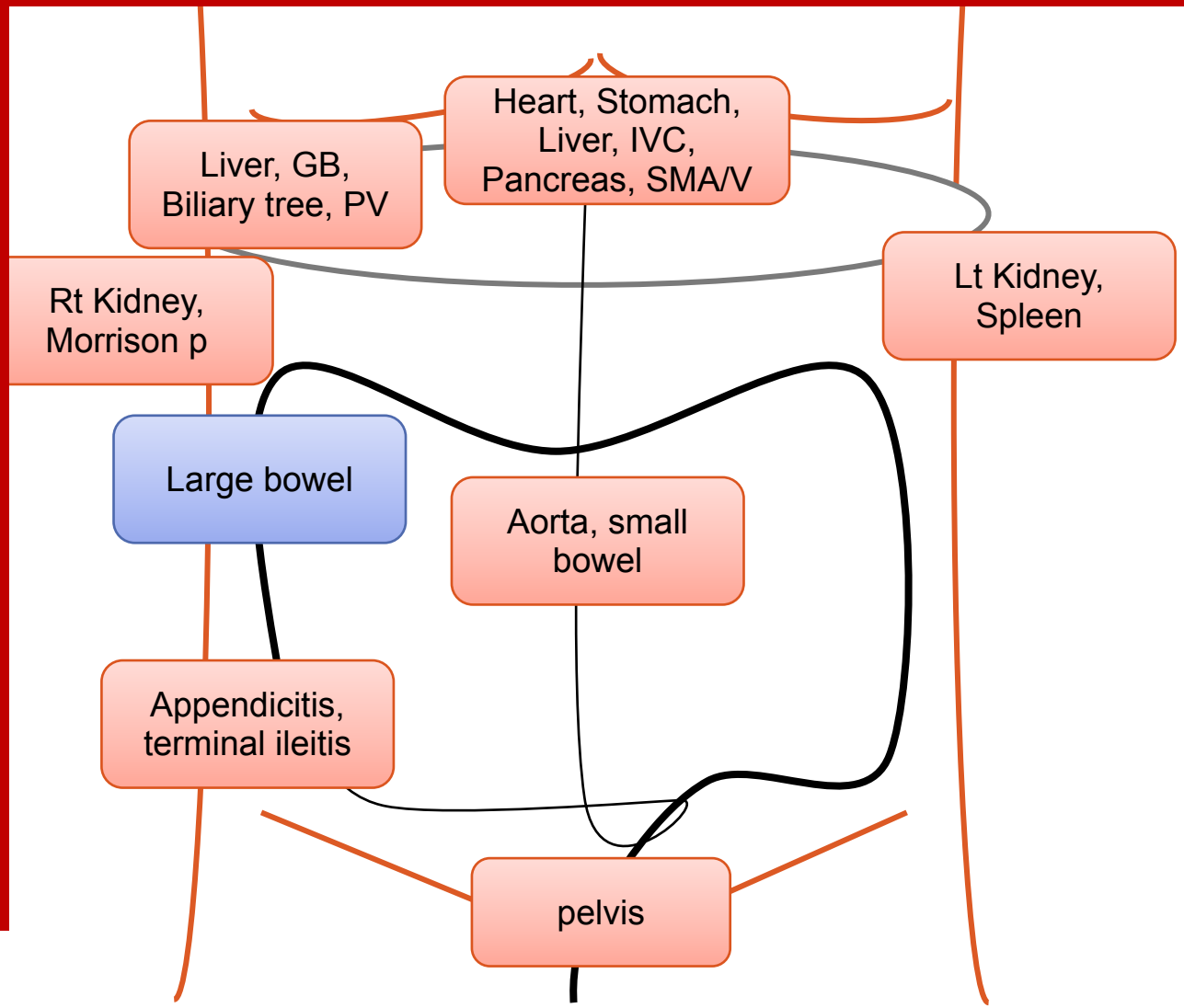

Focused Assessment

Size	Normal / Abnormal
Air (free / trapped)	Y / N
Fluid (free / trapped)	Y / N
Echogenicity	Homo / Hetero
Regional lesion	Y / N

Focused Assessment

Size	
Air (free / trapped)	Within / Surrounding
Fluid (free / trapped)	Within / Surrounding
Echogenicity	
Regional lesion	Stones . Mass . Shape

Size - enlargement

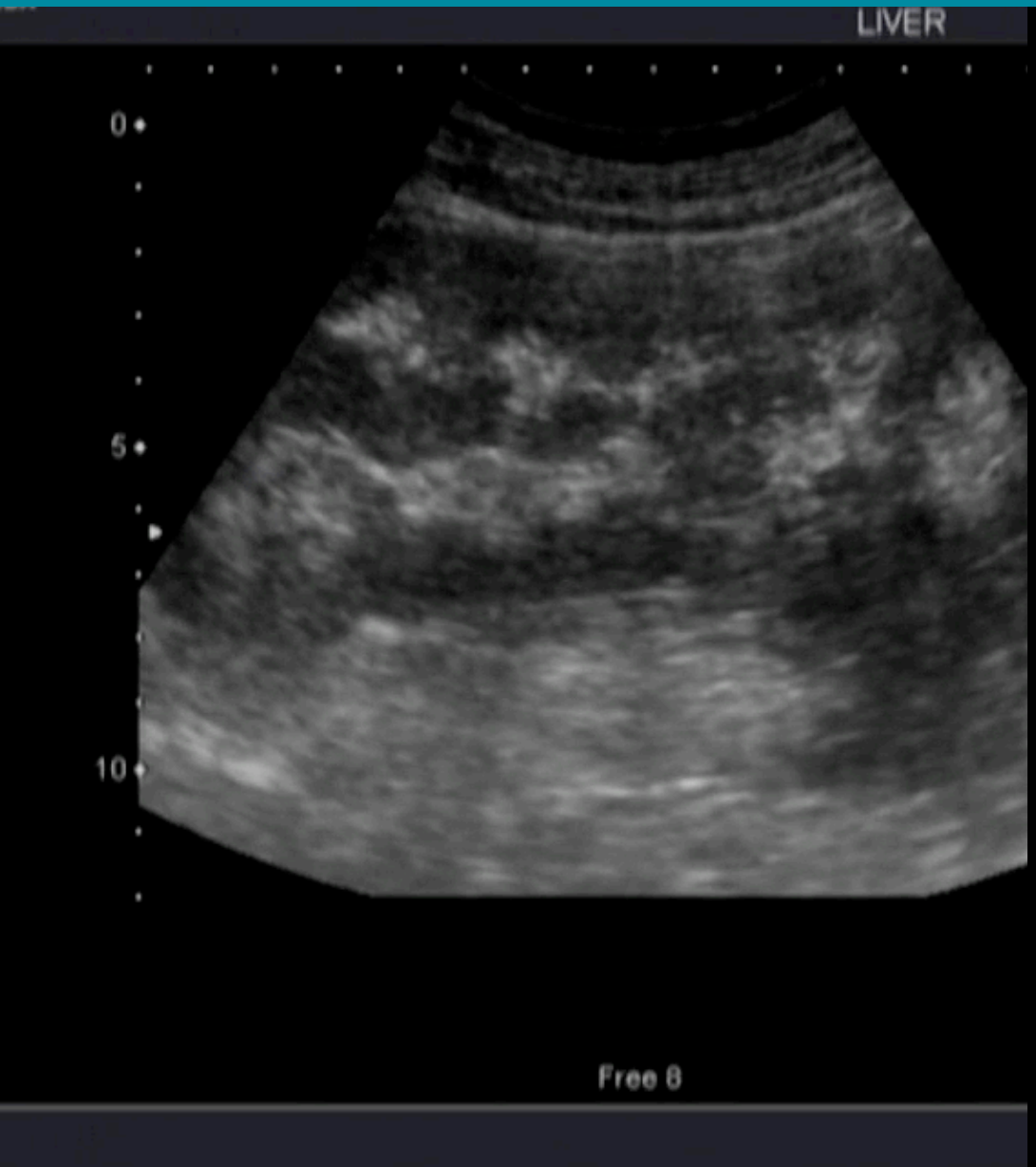

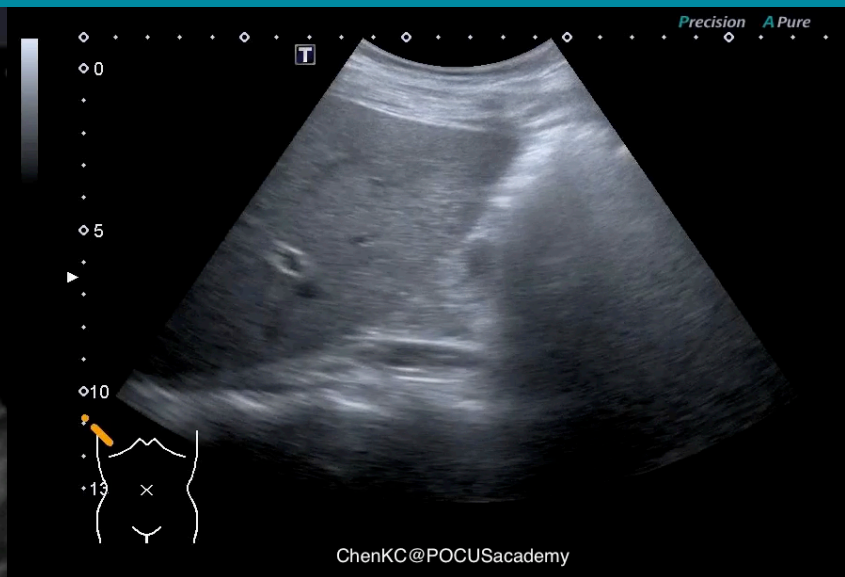

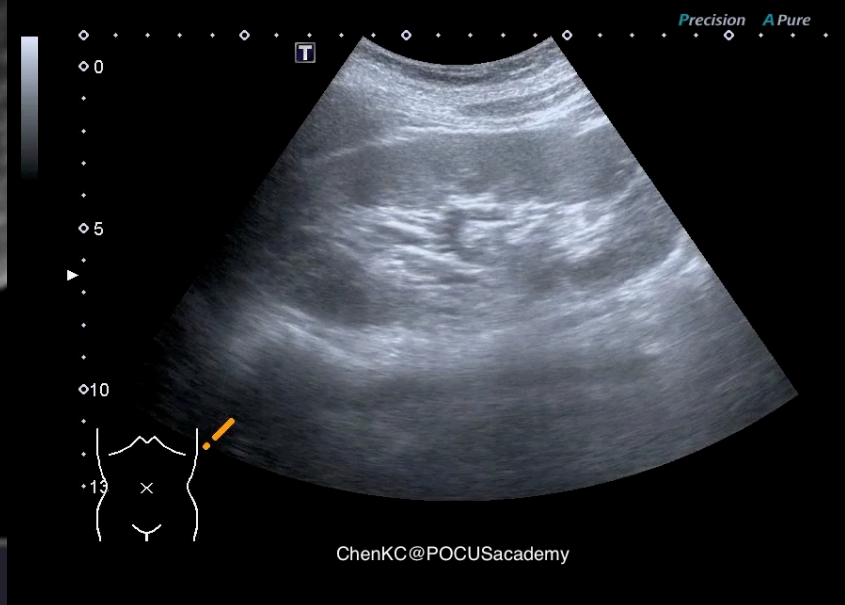

Size - enlargement

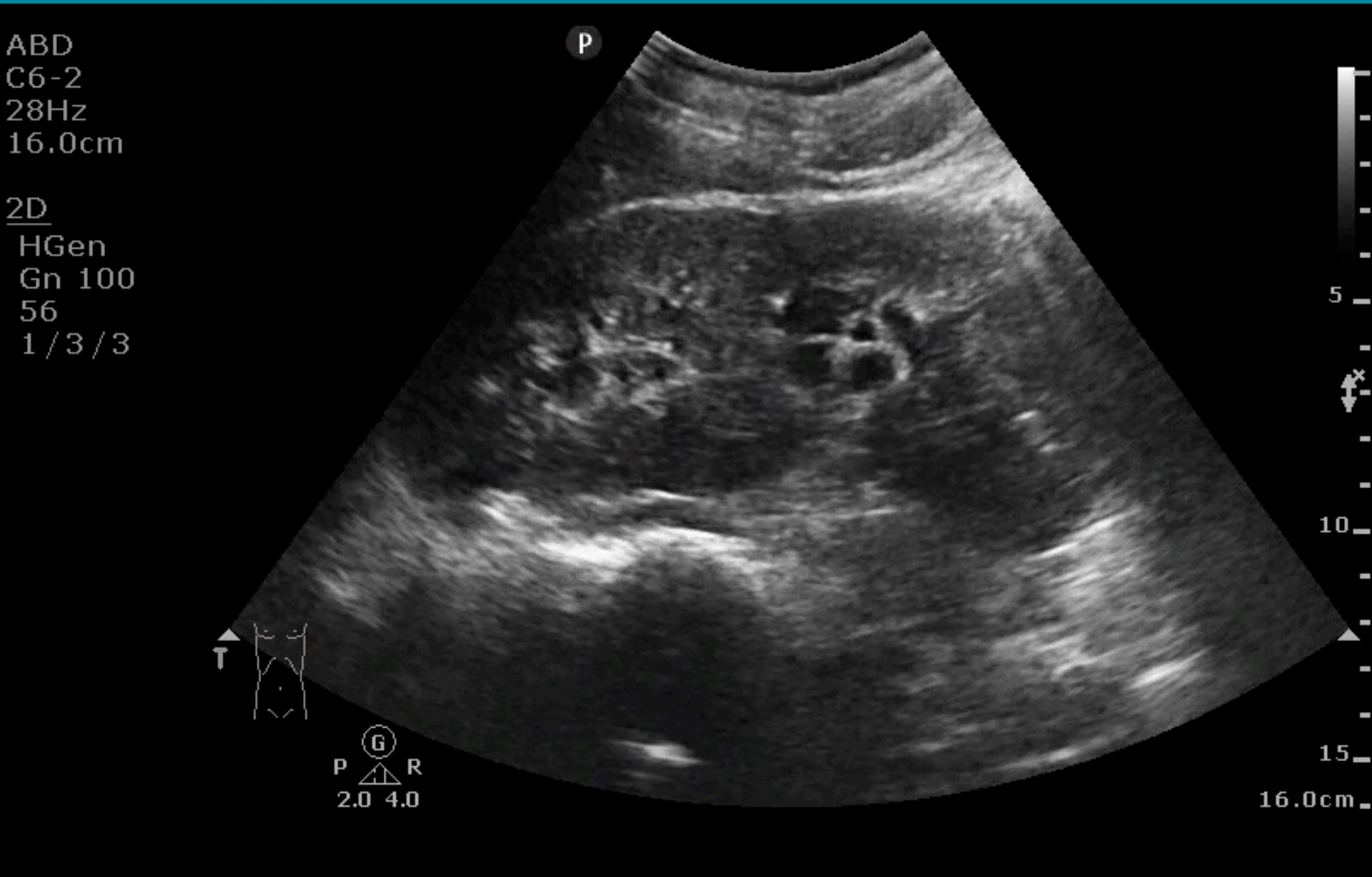

Size - atrophy

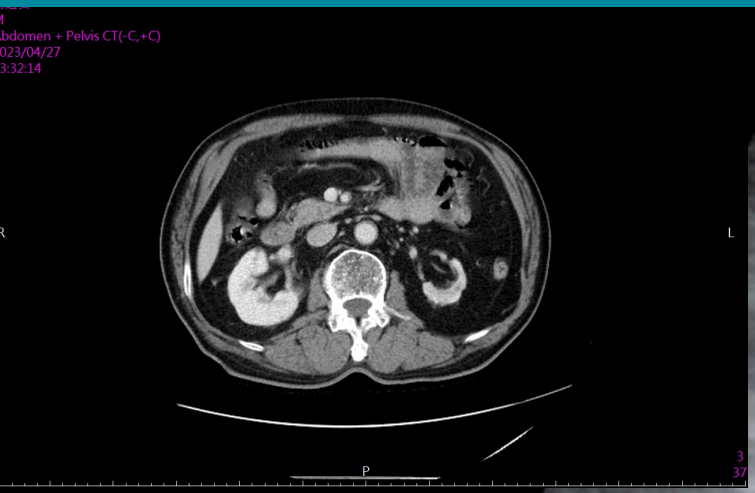

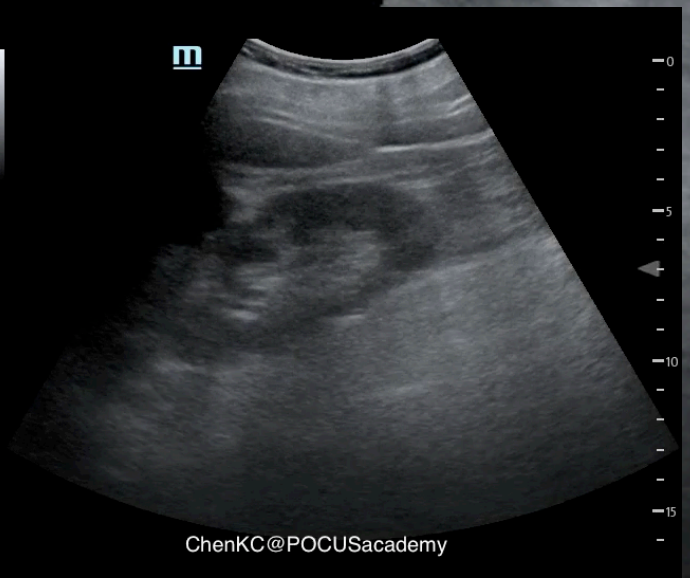

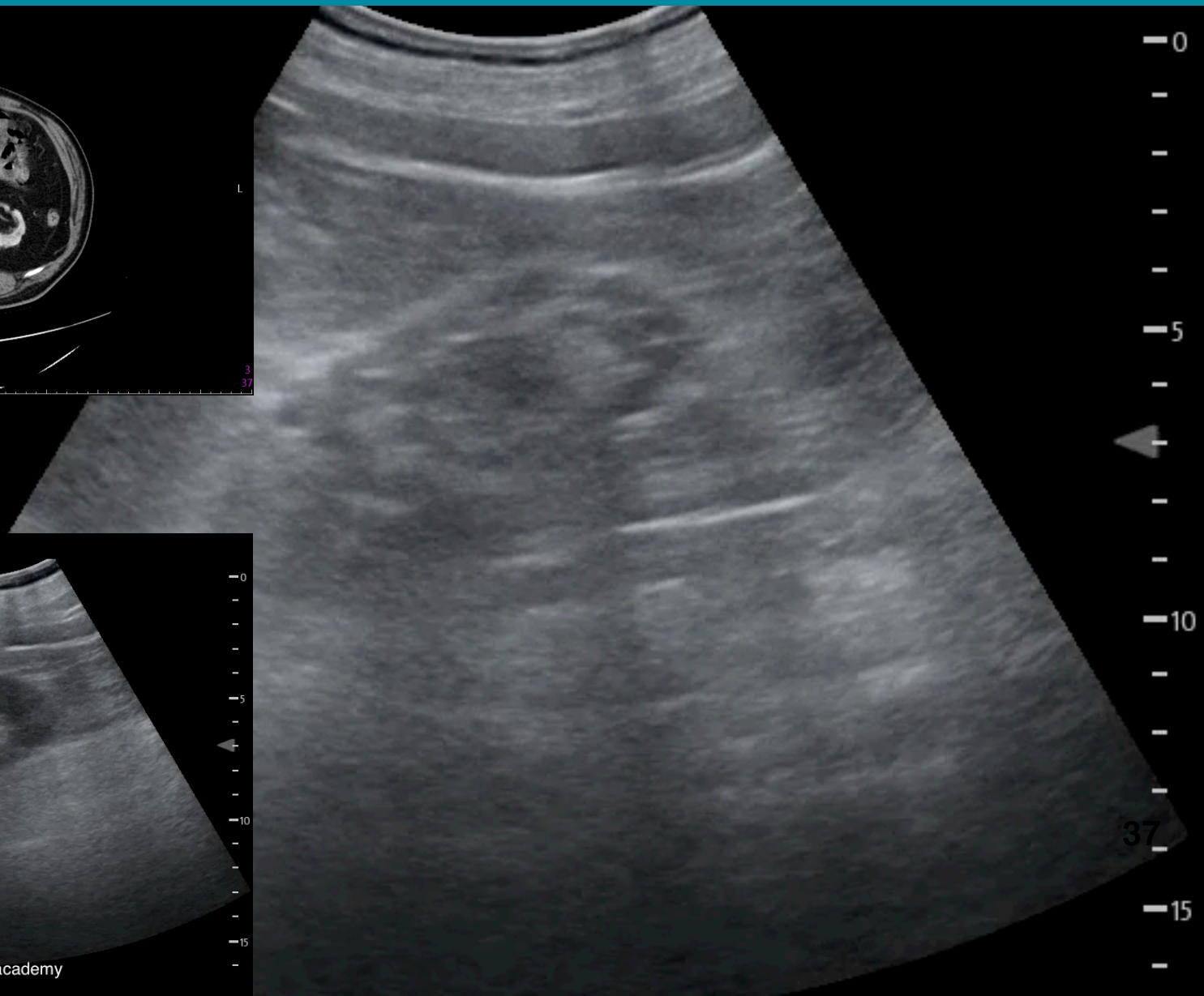

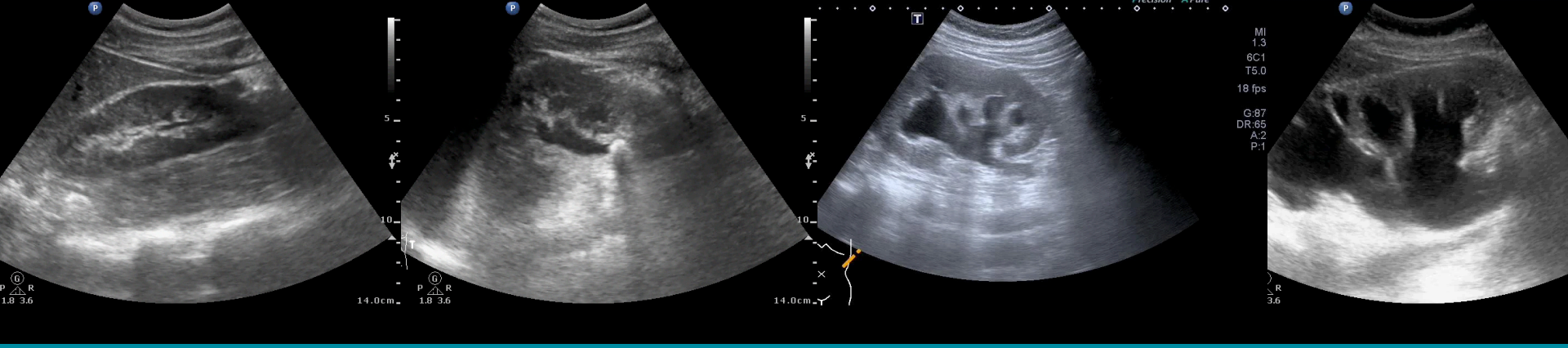

HYDRONEPHROSIS嚴重度

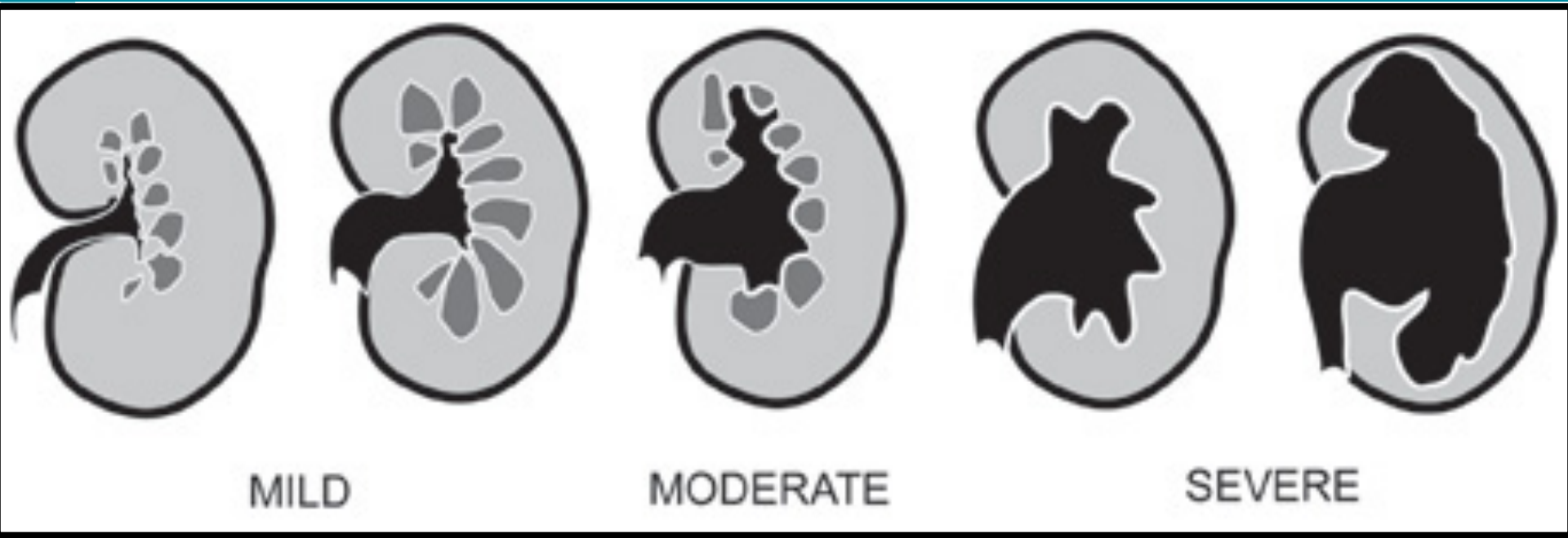

Size - before catheterization

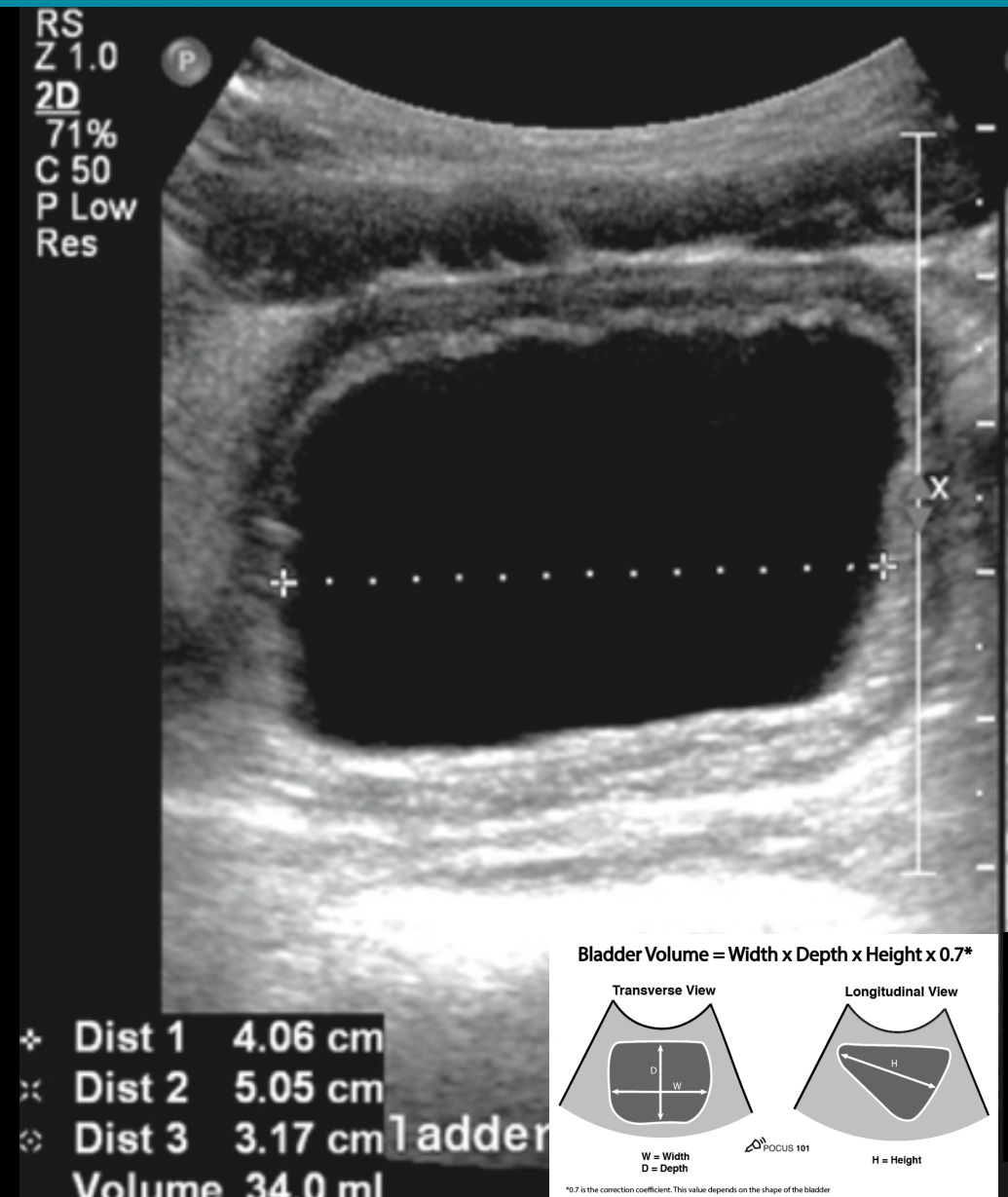

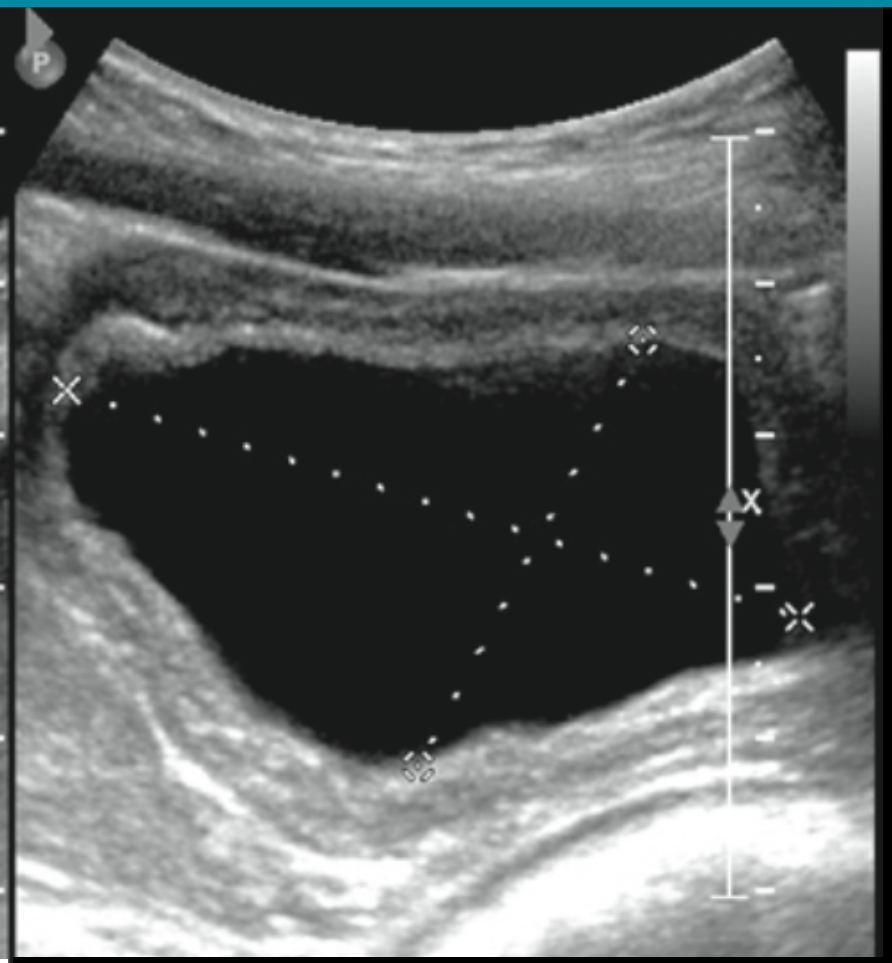

Transverse diameter ≥2 cm
~ bladder volume ≥ 2.5 cm3
Witt et al. AEM 2005

Air - UB

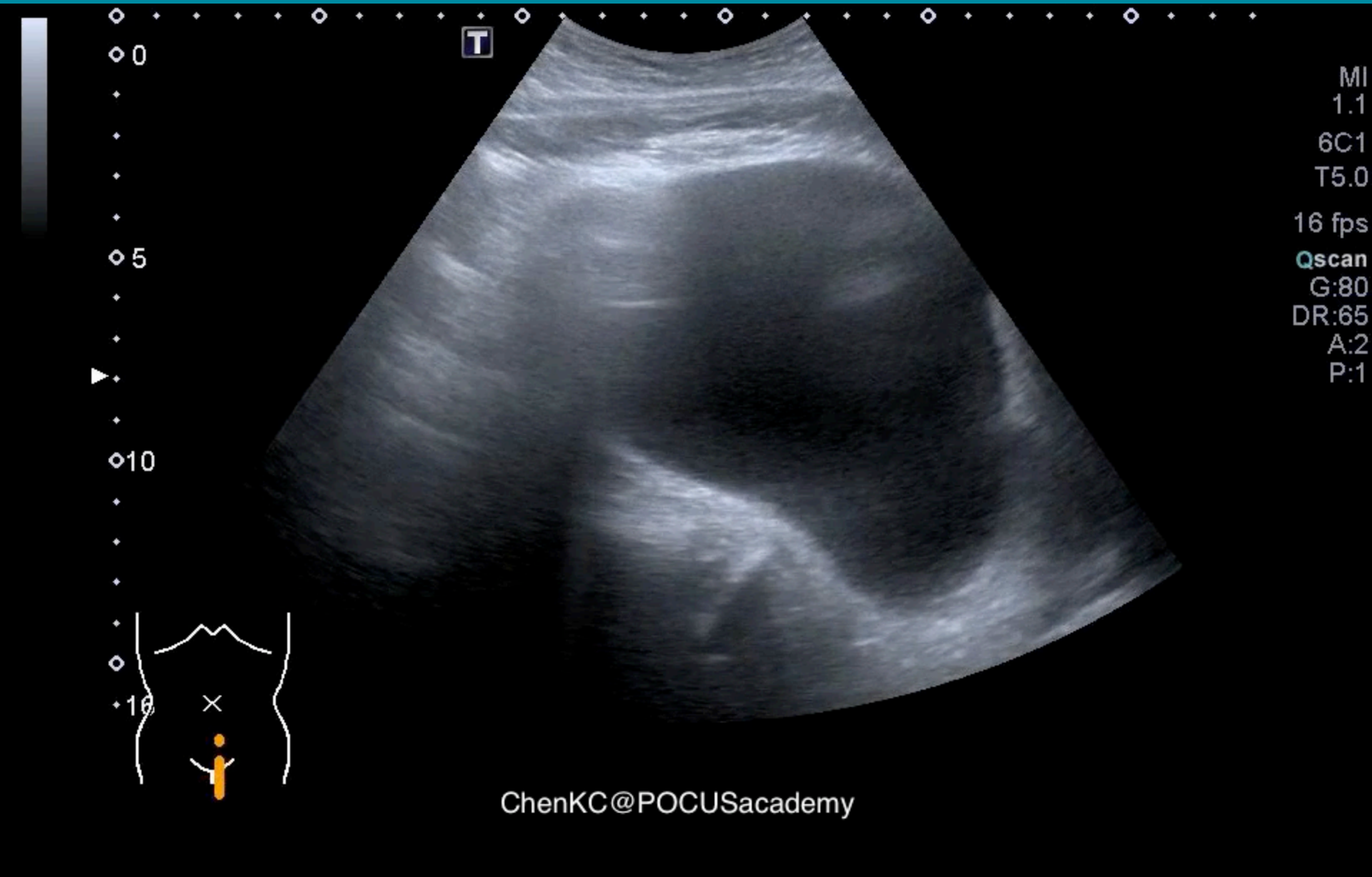
0
5
10
MI
1.1
6C1
T5.0
16 fps
Qscan
G:80
DR:65
A:2
P:1
ChenKC@POCUSacademy

Air - UB

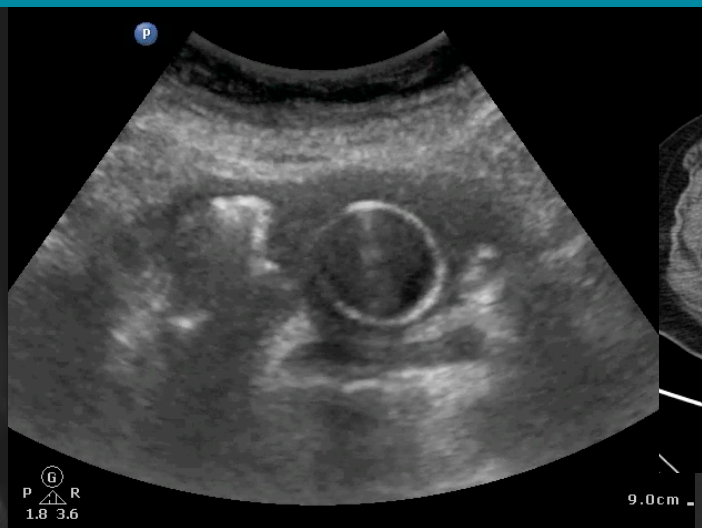
P
G
P R
1.8 3.6
9.0cm
ChenKC@POCUSacademy

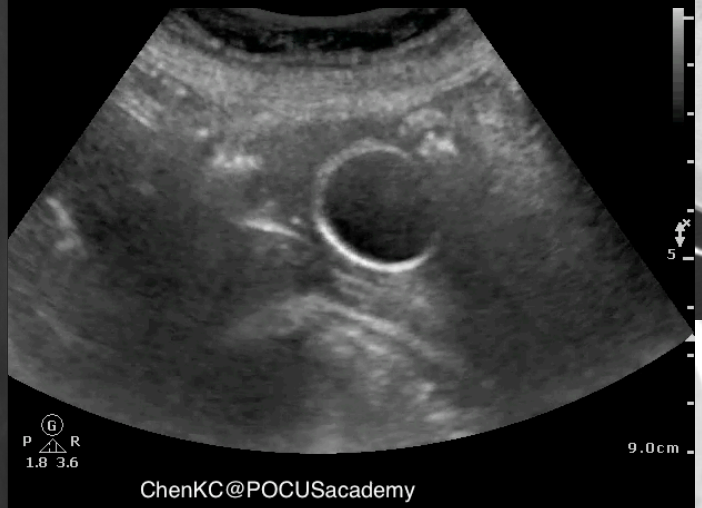
G
P R
1.8 3.6
9.0cm
ChenKC@POCUSacademy

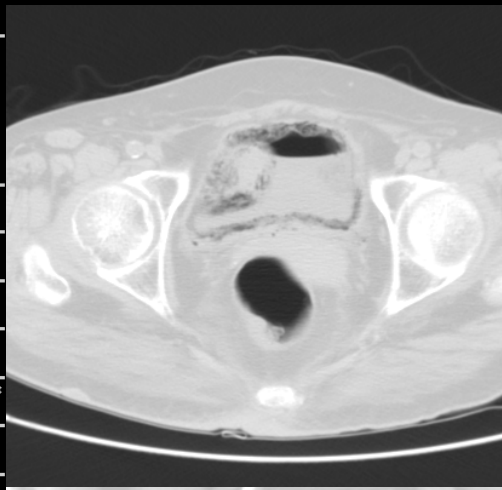

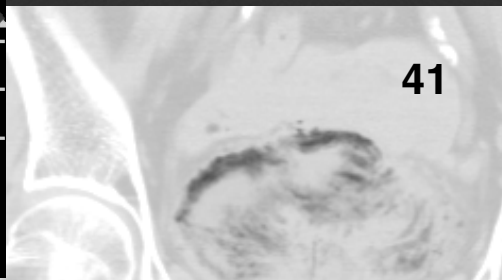

Air - kidney

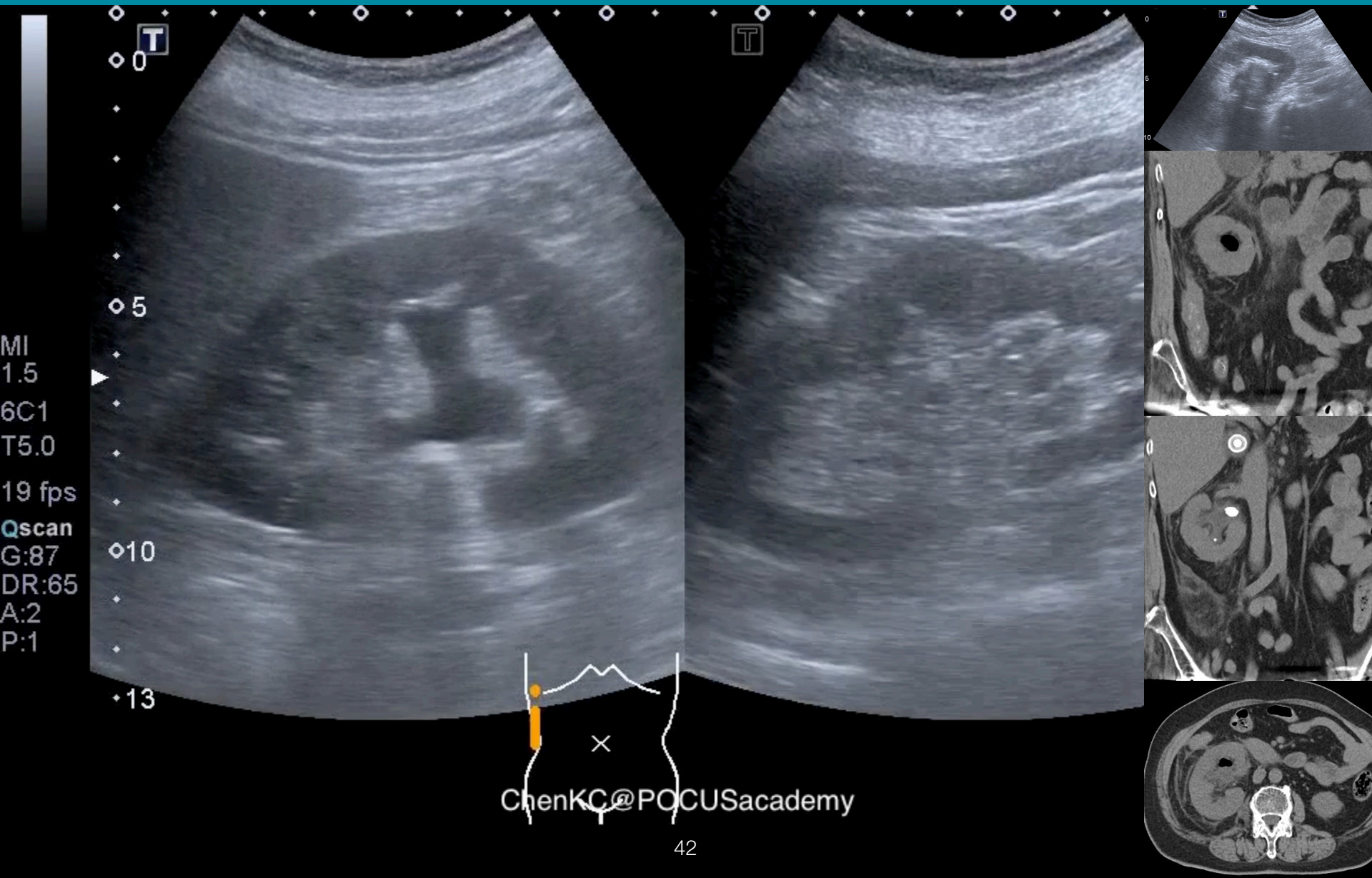
MI
1.5
6C1
T5.0
19 fps
Qscan
G:87
DR:65
A:2
P:1
0
5
10
13
ChenKC@POCUSacademy

Air - Ureter / Bladder

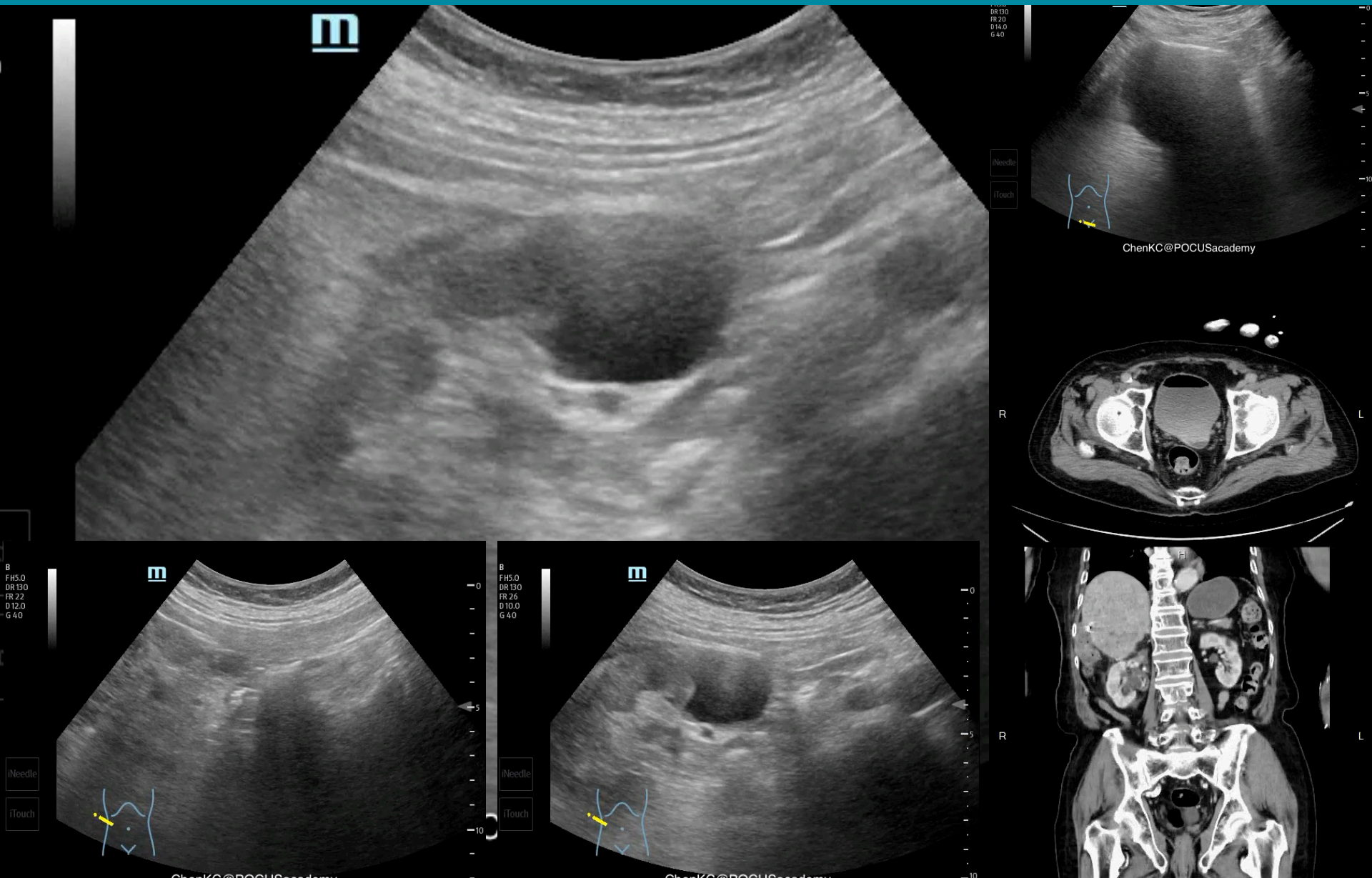

Air - kidney

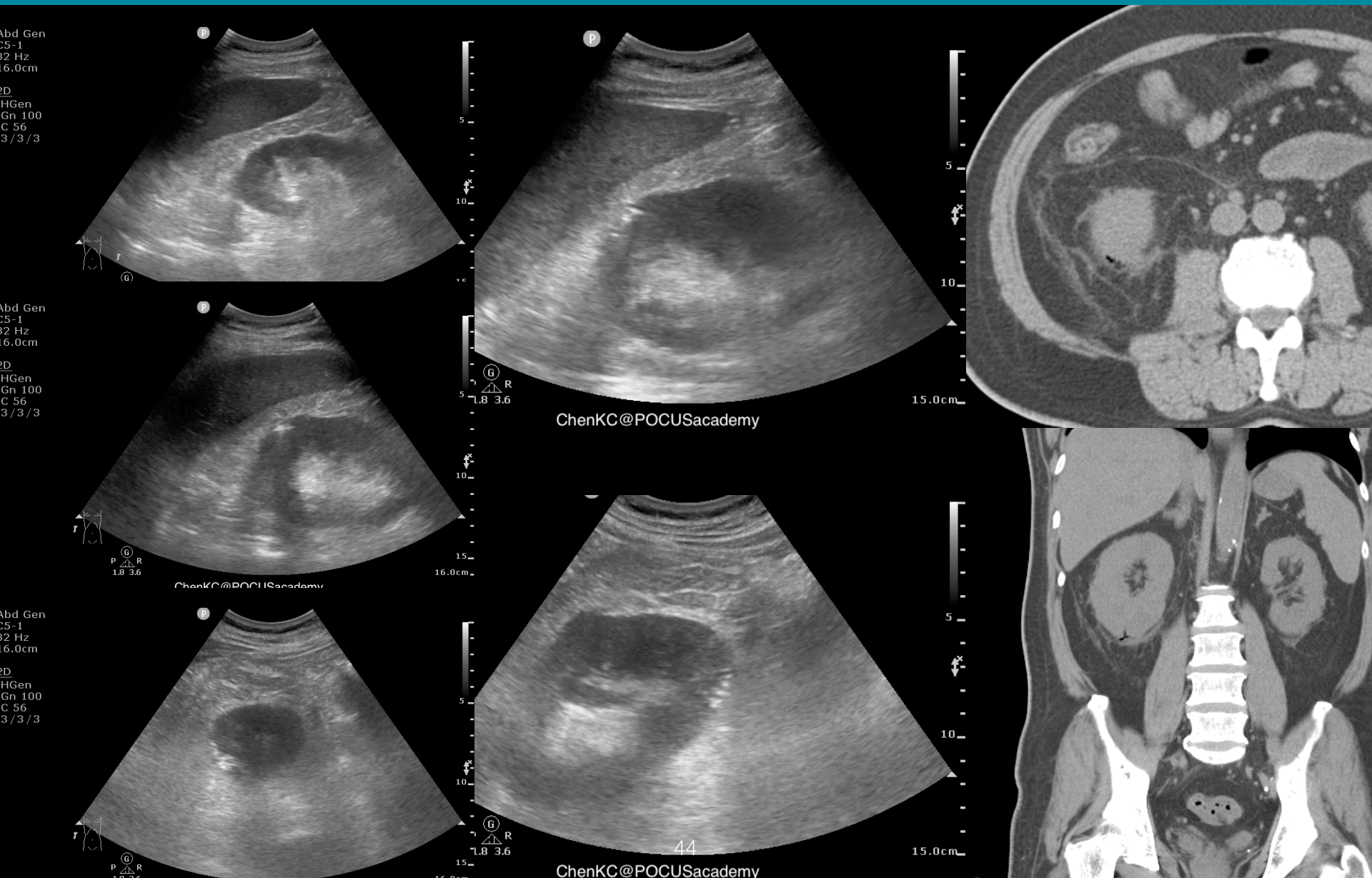
Abd Gen
C5-1
32 Hz
16.0cm
2D
HGen
Gn 100
C 56
3/3/3
ChenKC@POCUSacademy
15.0cm
16.0cm

Air - kidney

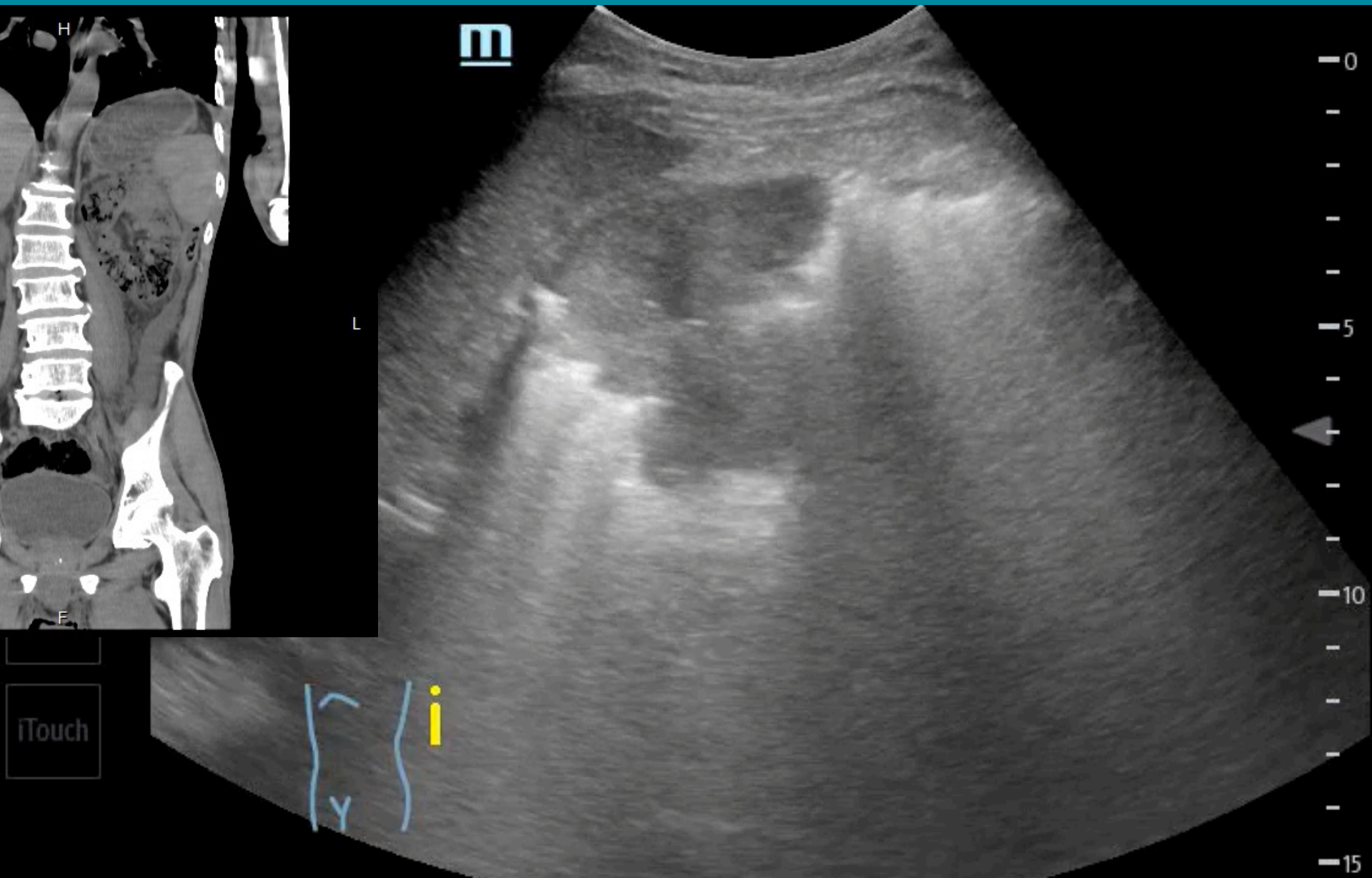

Fluid - perirenal

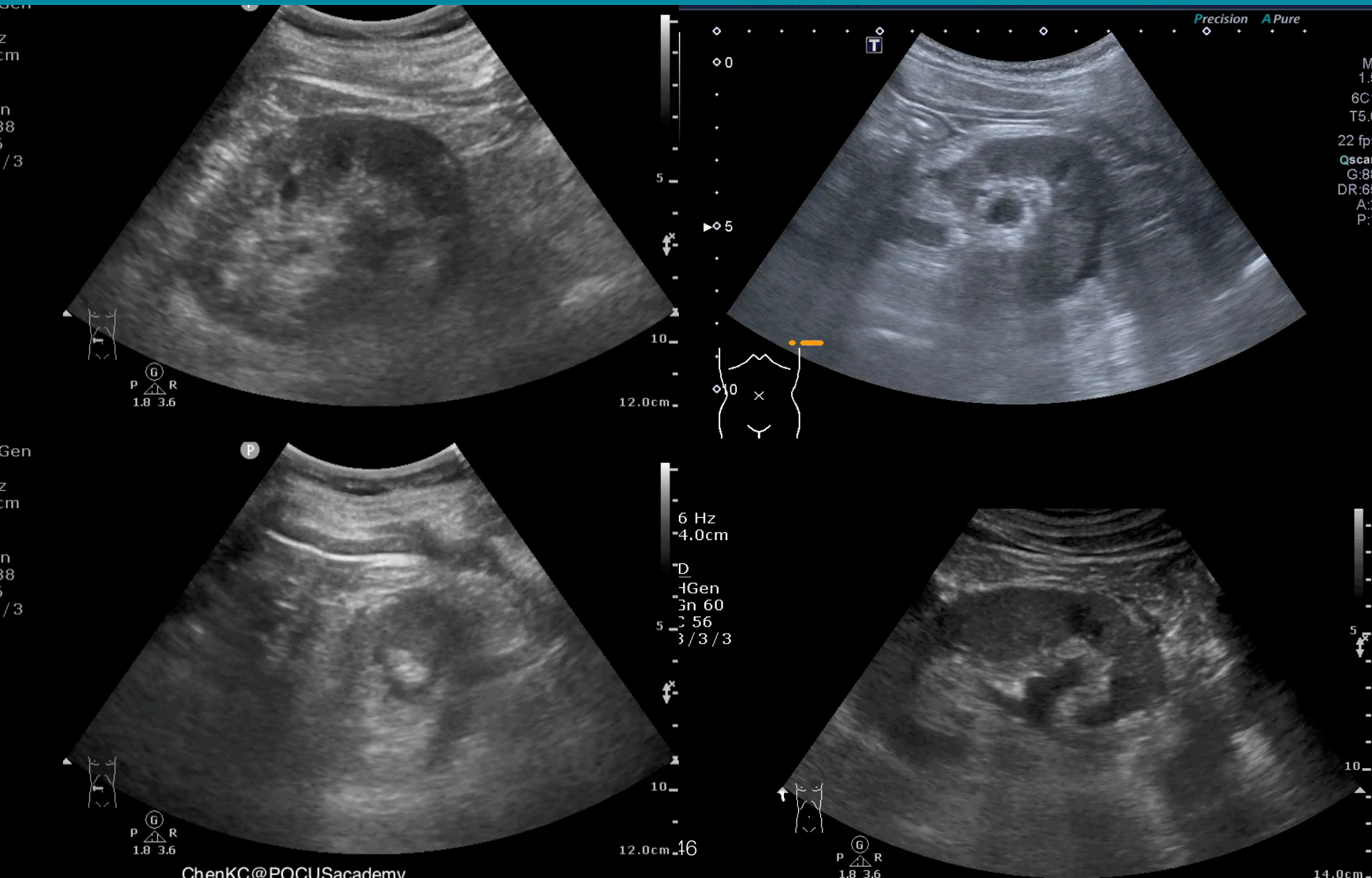

Fluid - perirenal

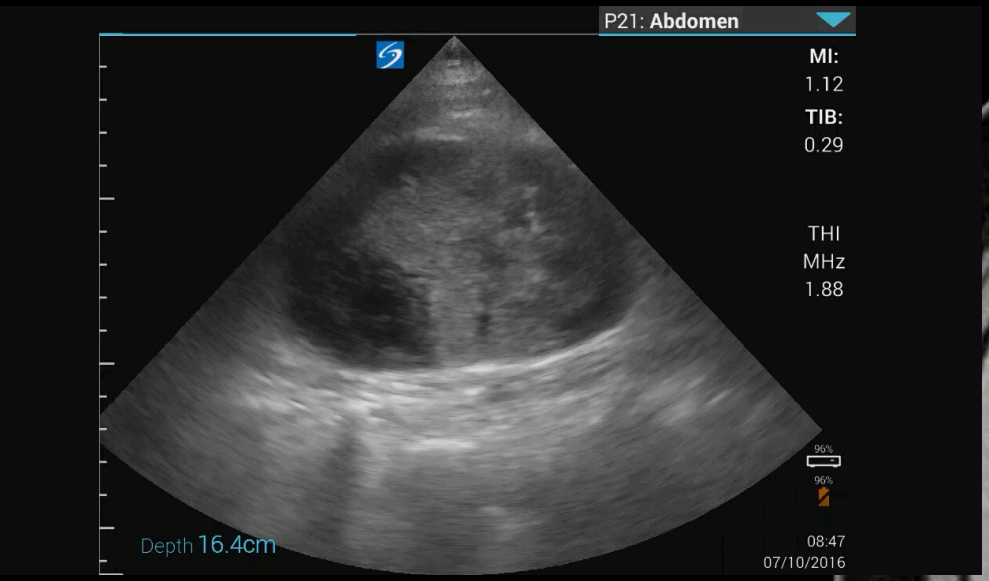

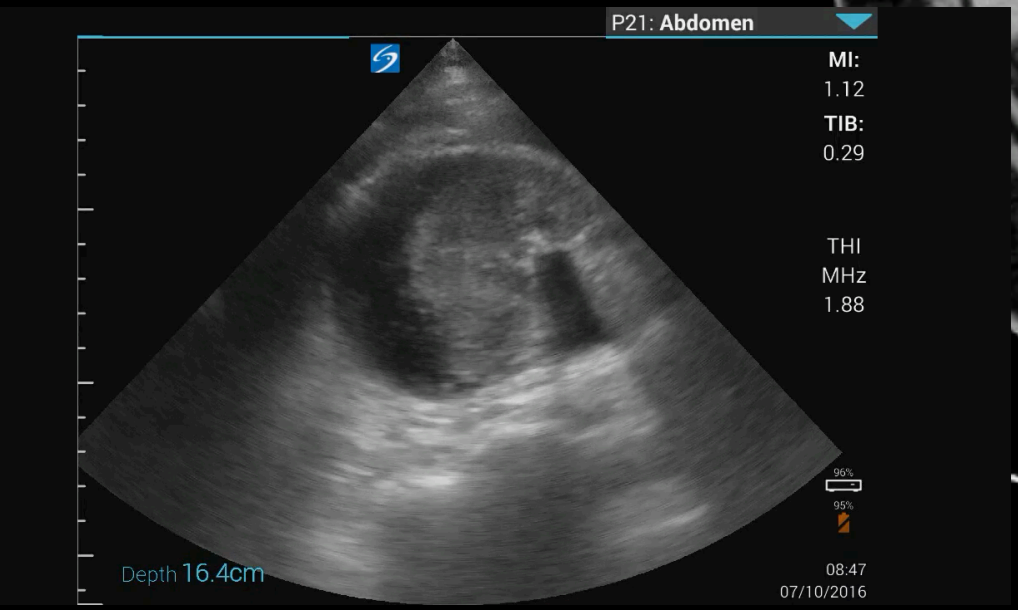

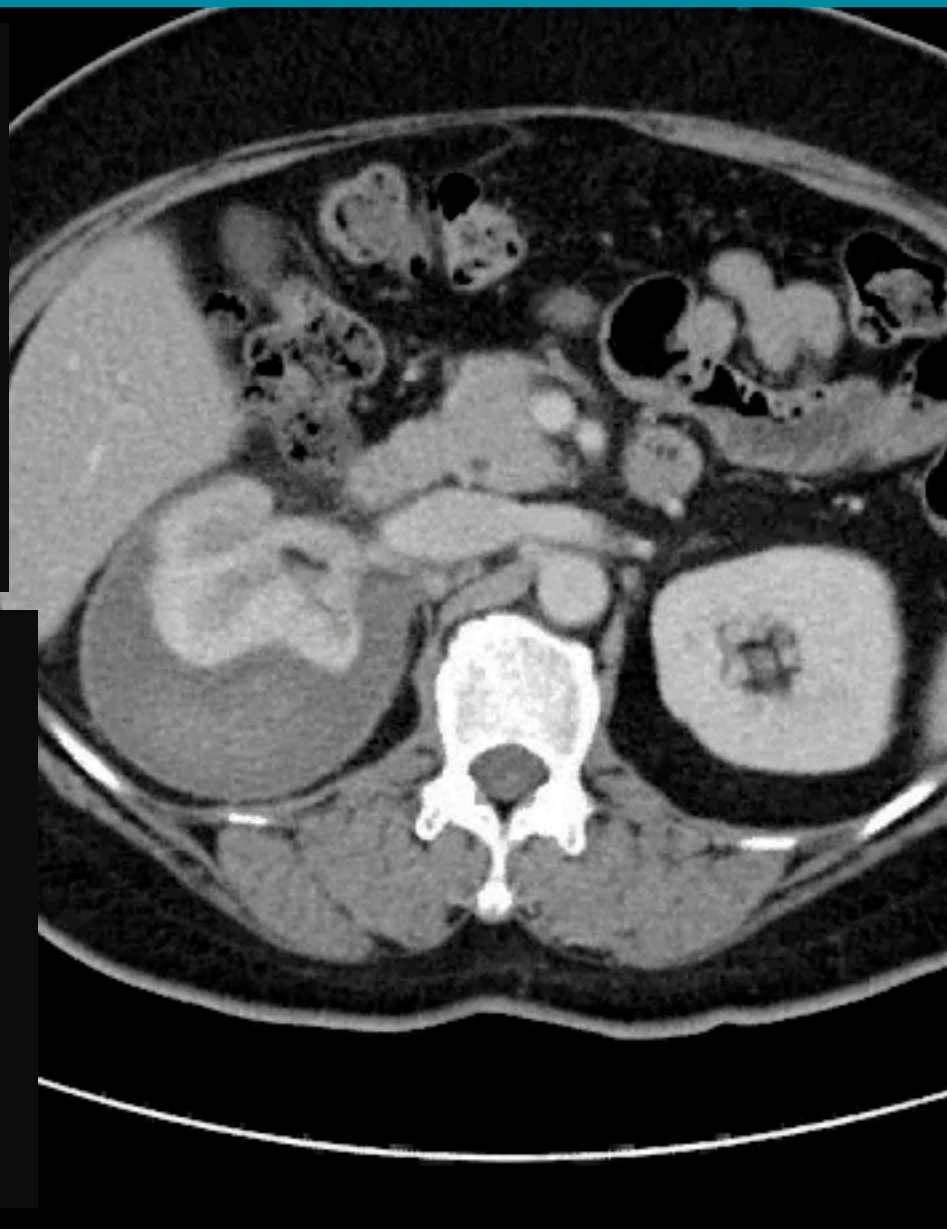

Fluid - perirenal

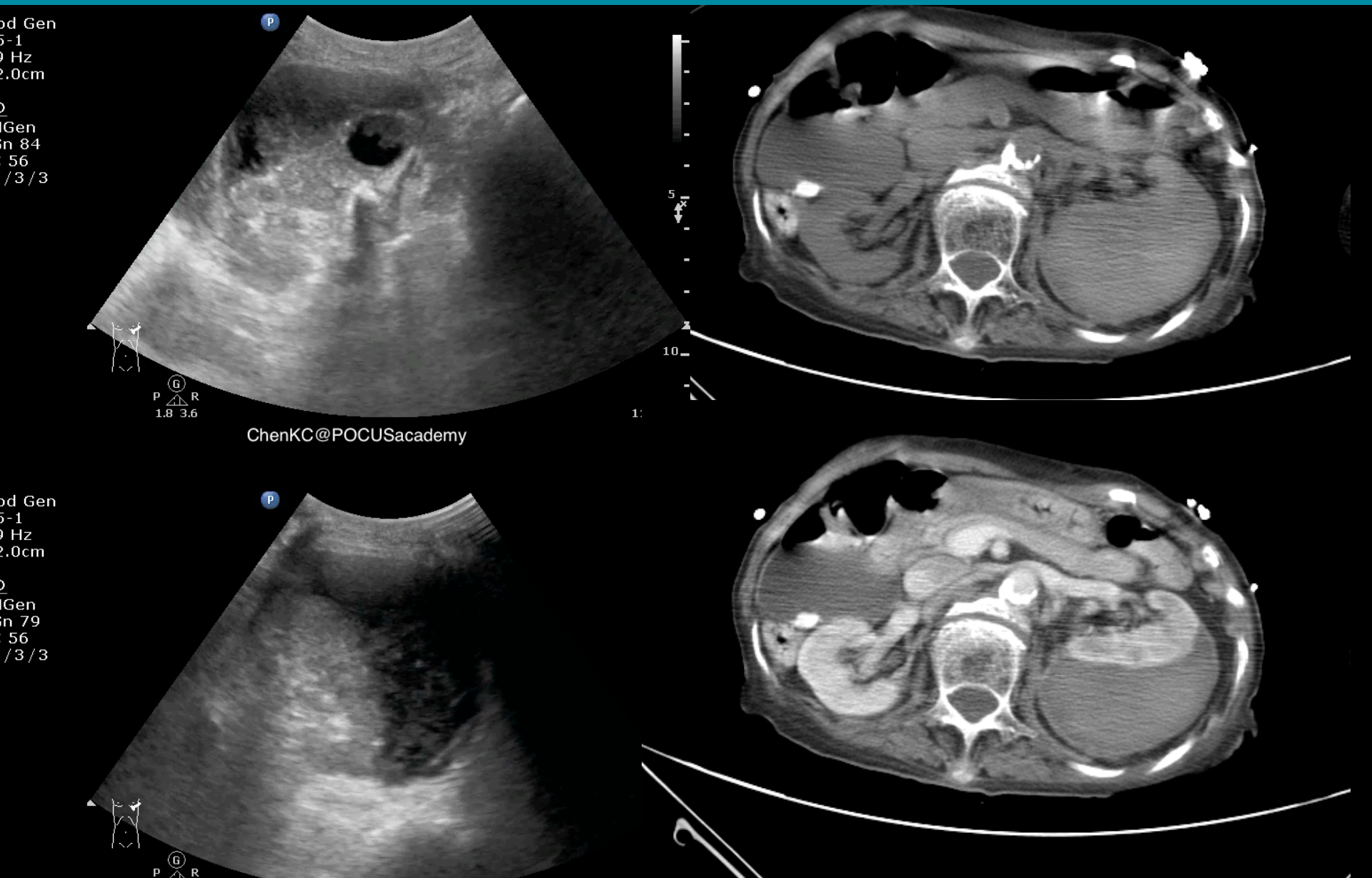

Fluid - hydronephrosis

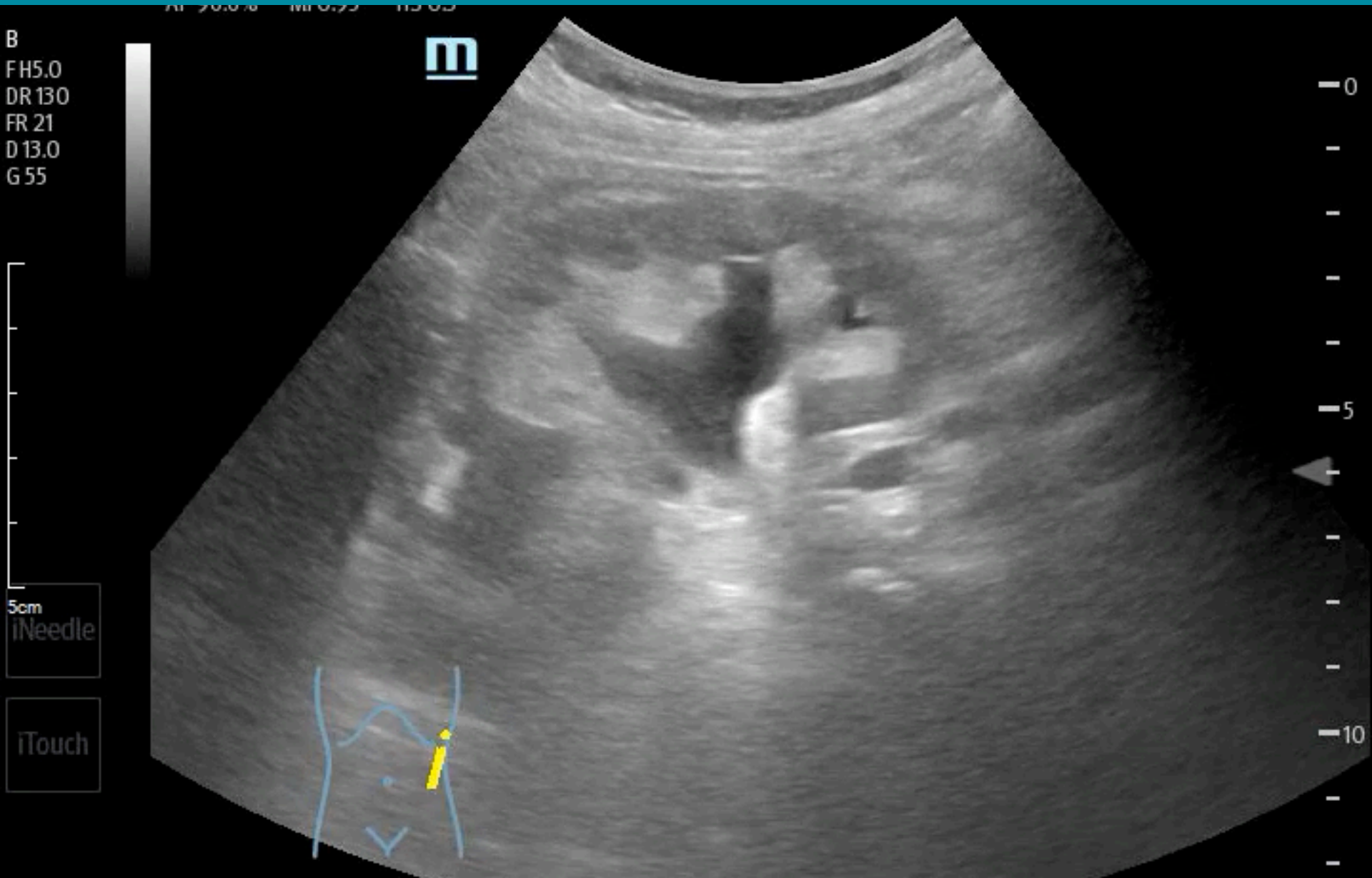

Fluid - hydronephrosis

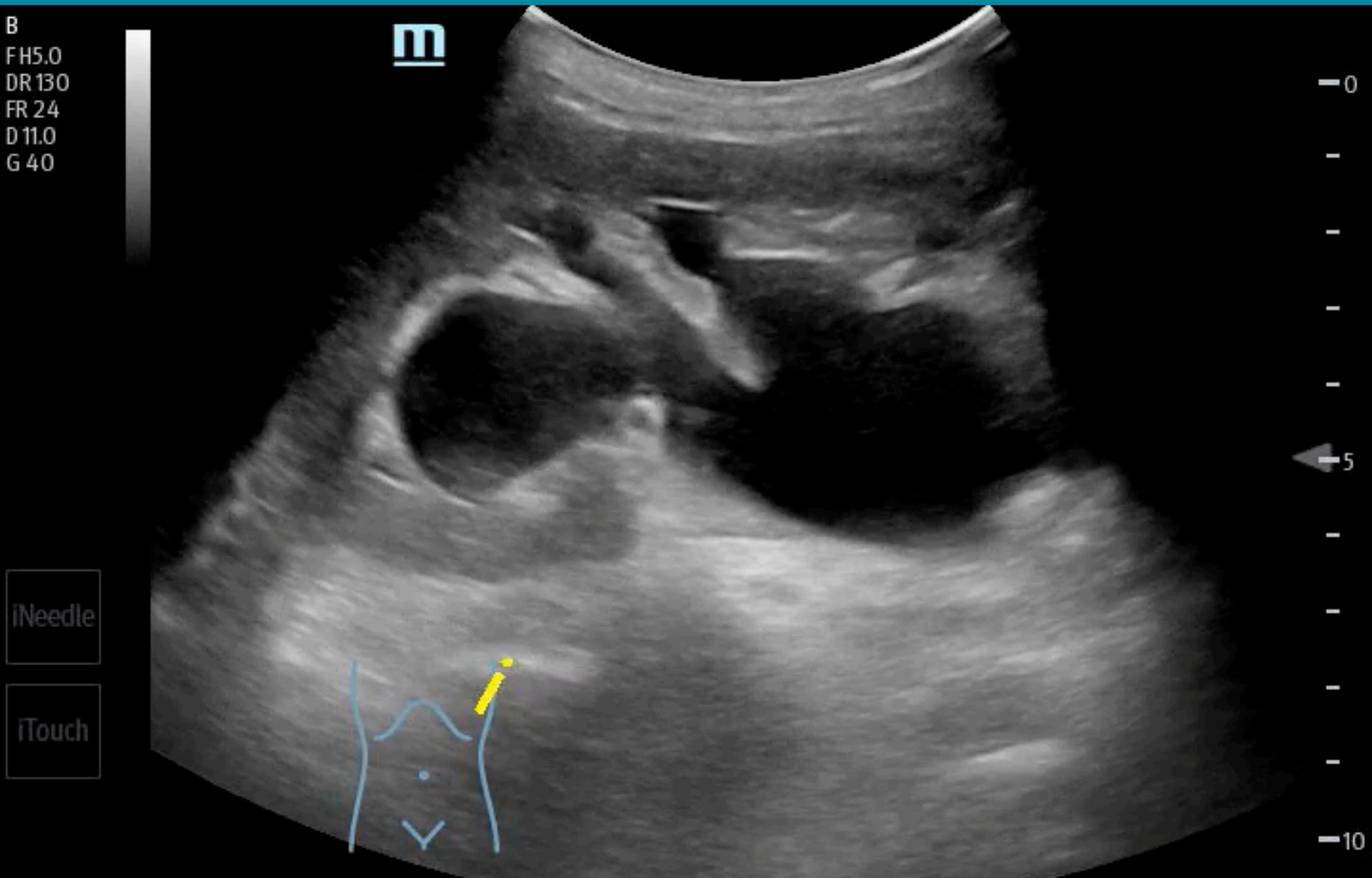

Fluid - hydronephrosis

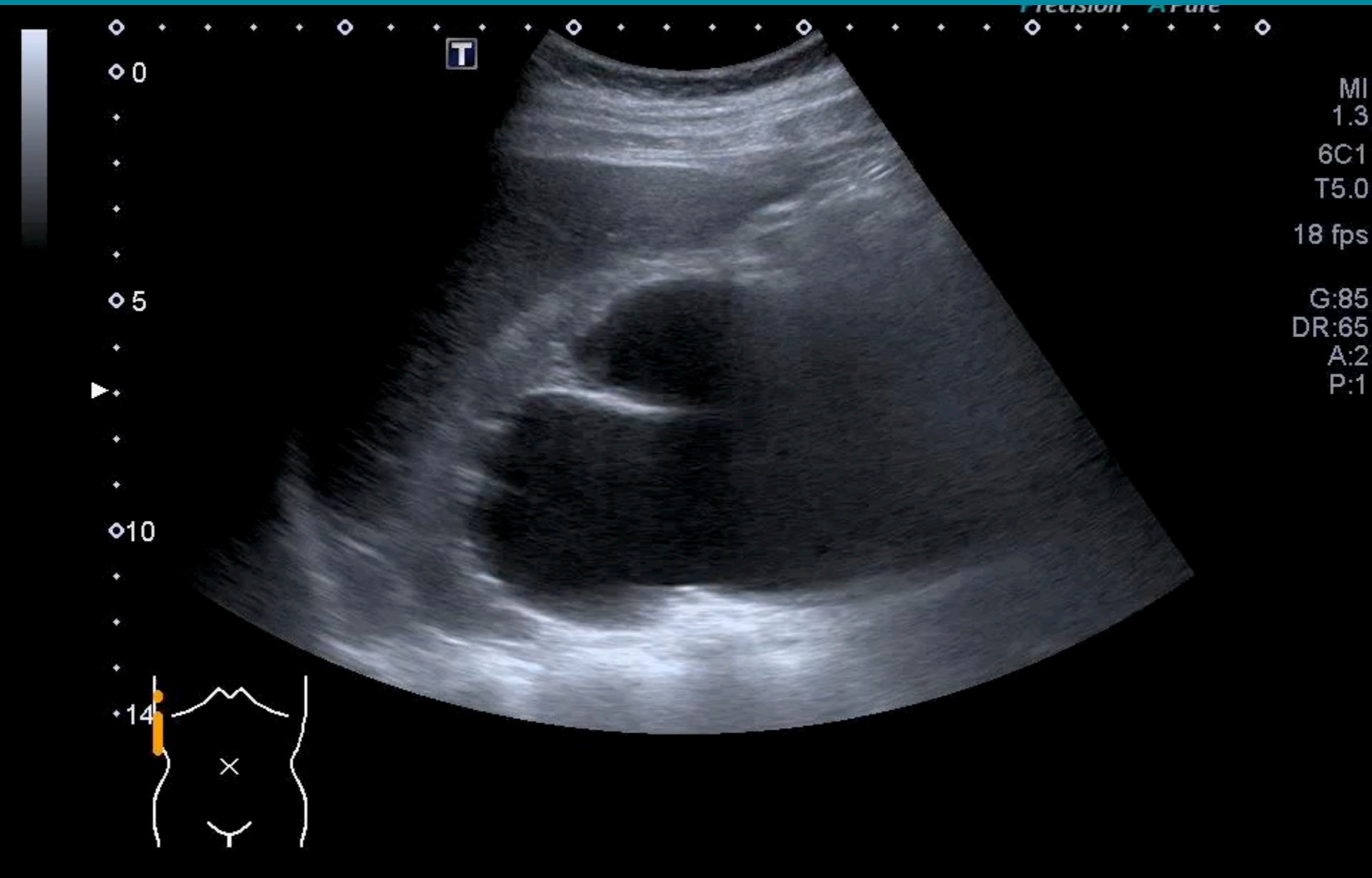

Fluid - postrenal obstruction

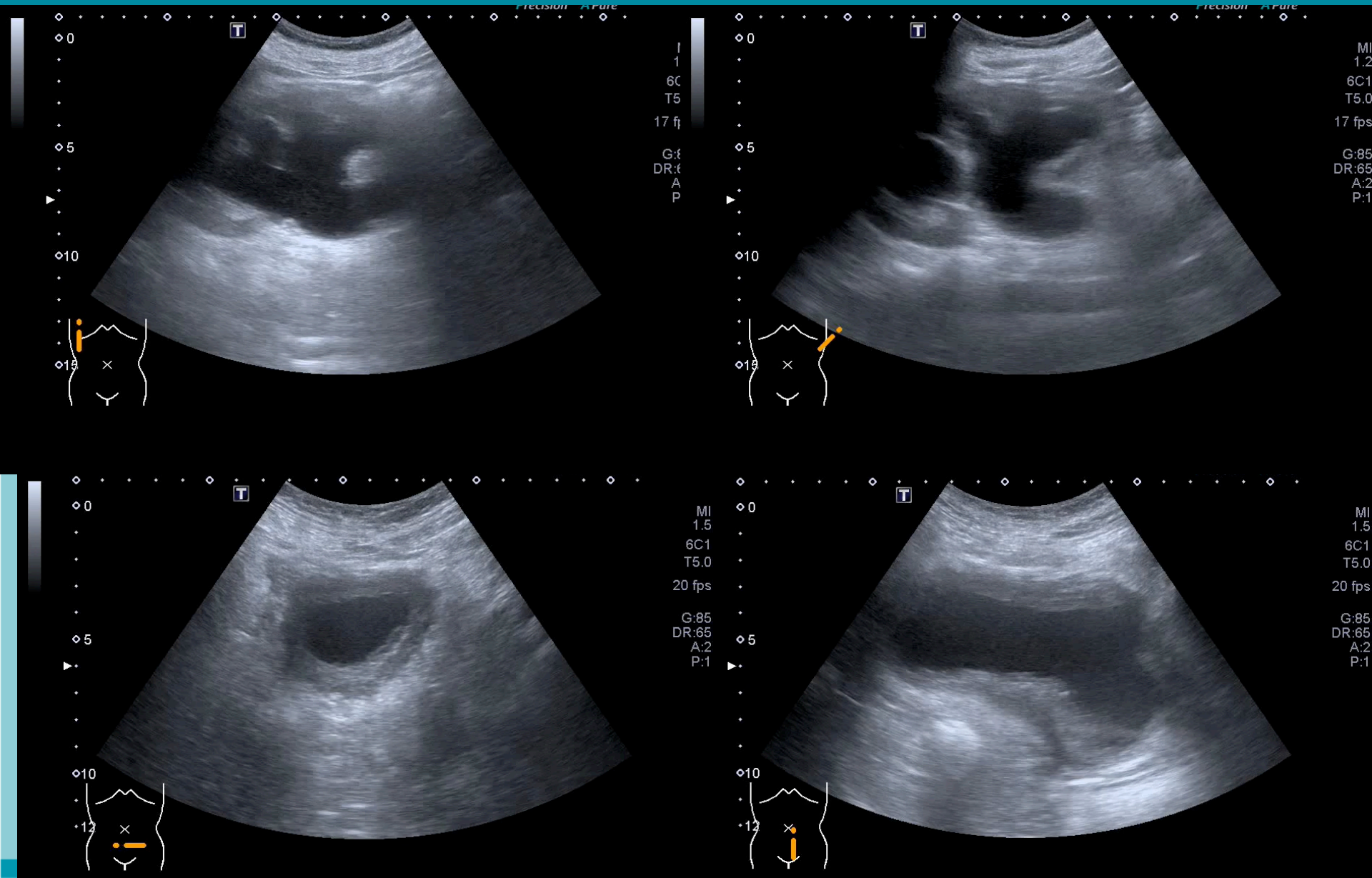

Fluid - obstruction

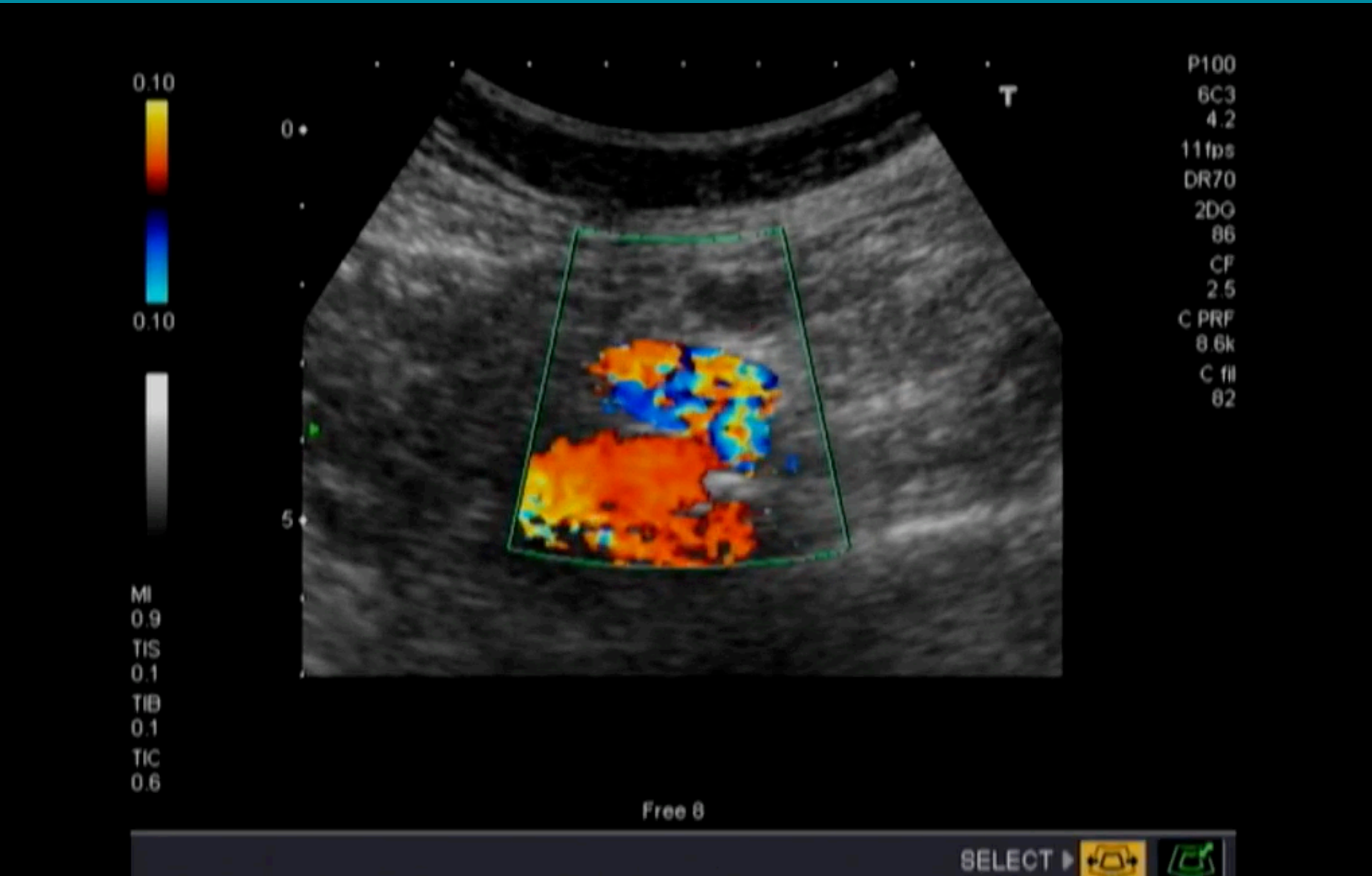

Fluid - obstruction

Echo first for better window

Echogenecity - APN

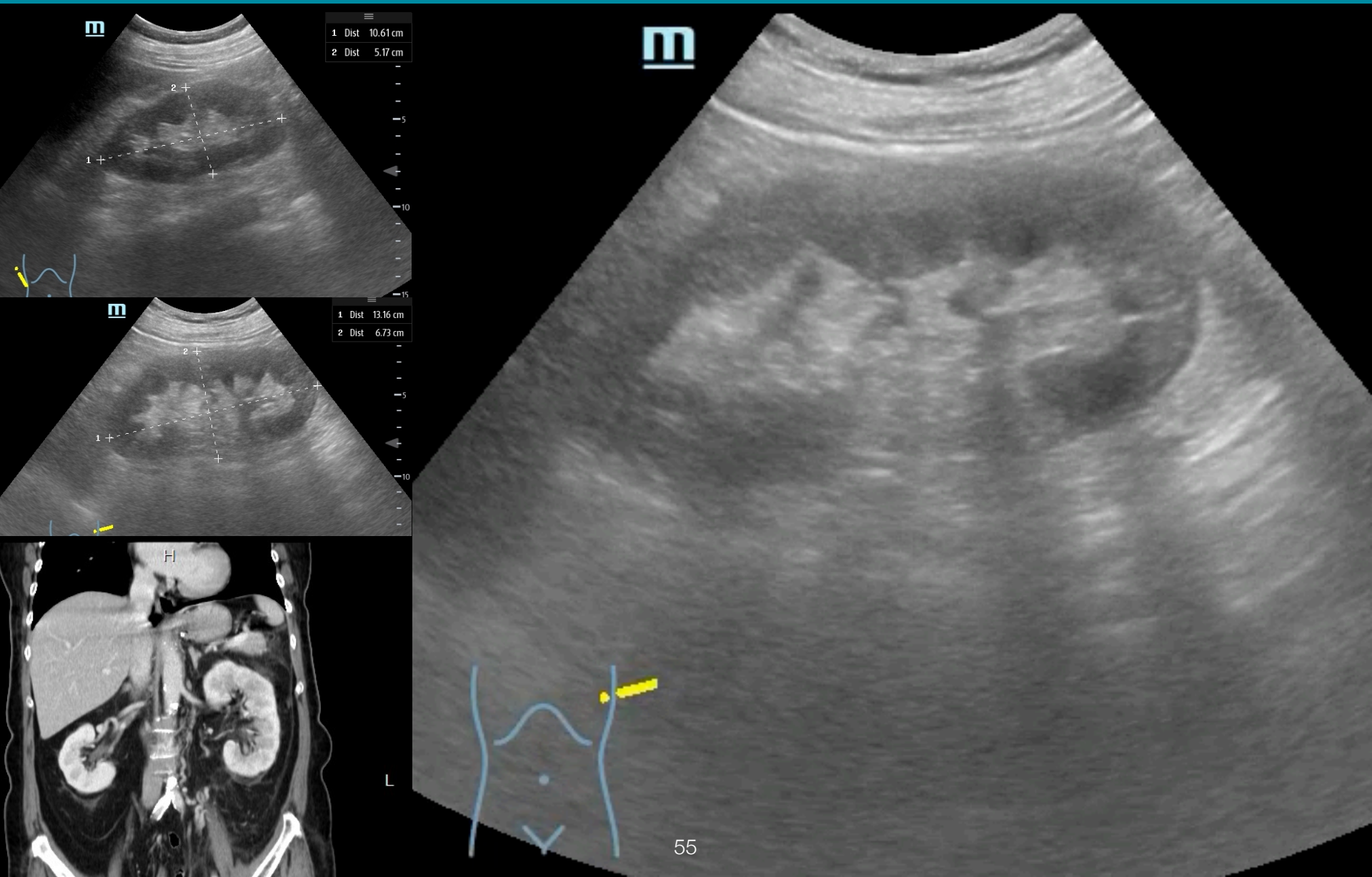

Echogenecity - APN

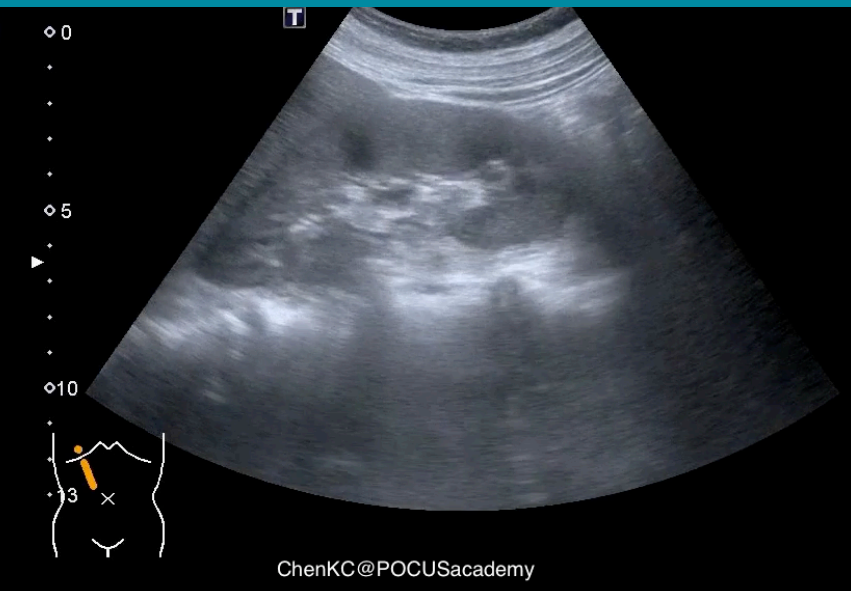

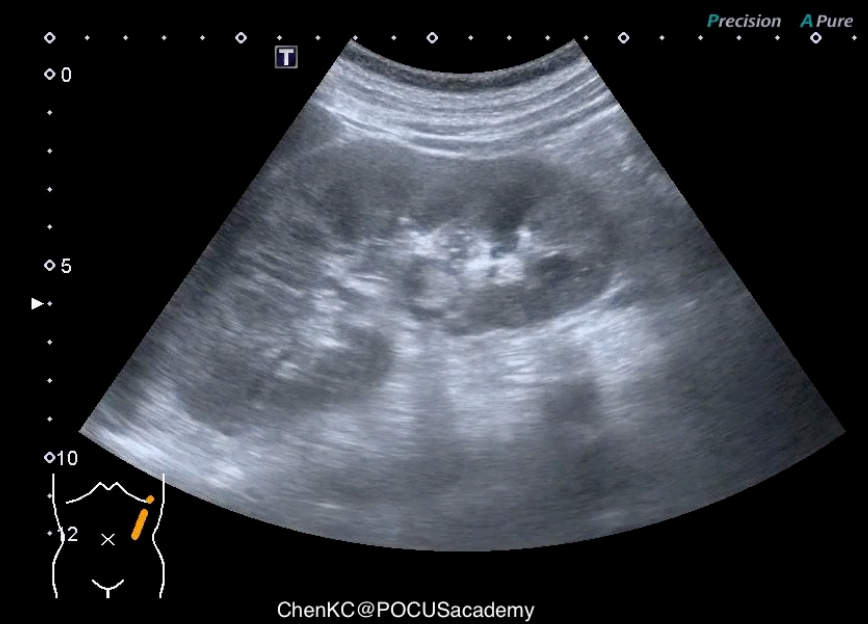

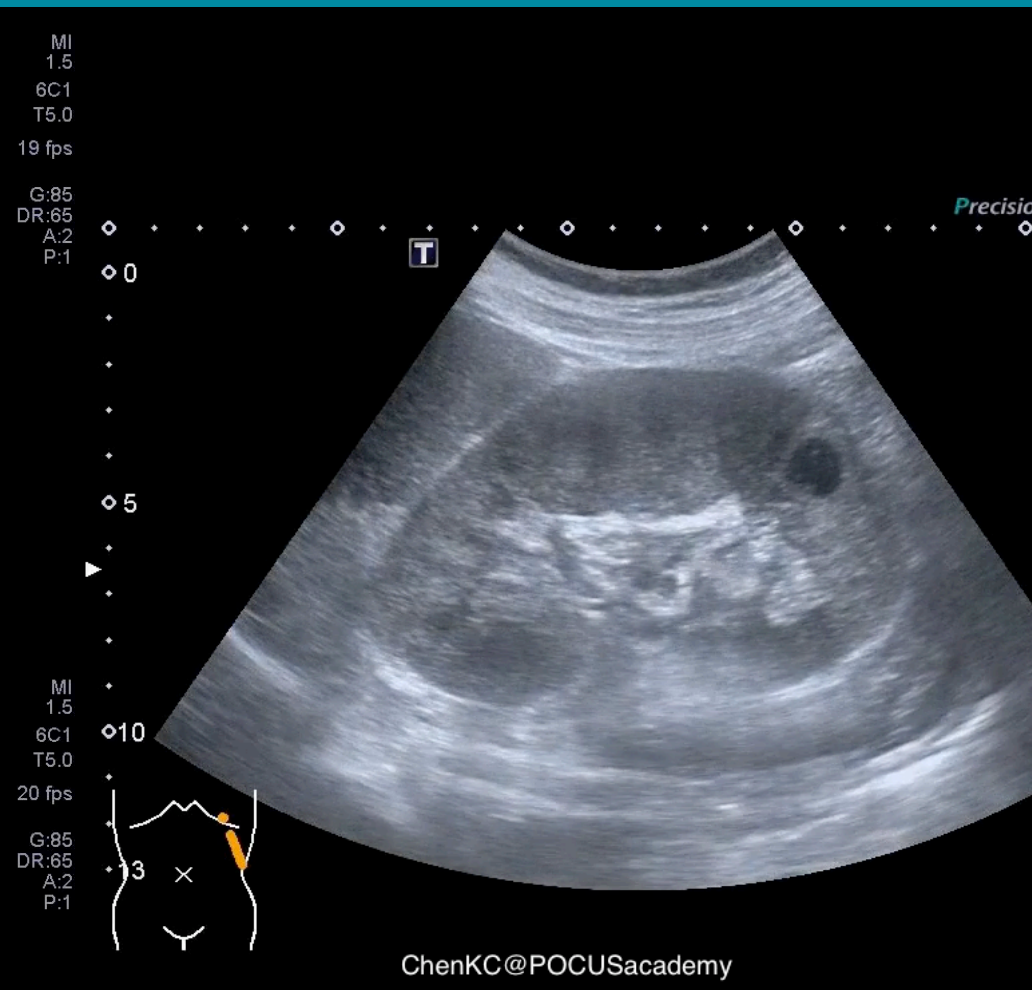

Echogenecity - ESRD

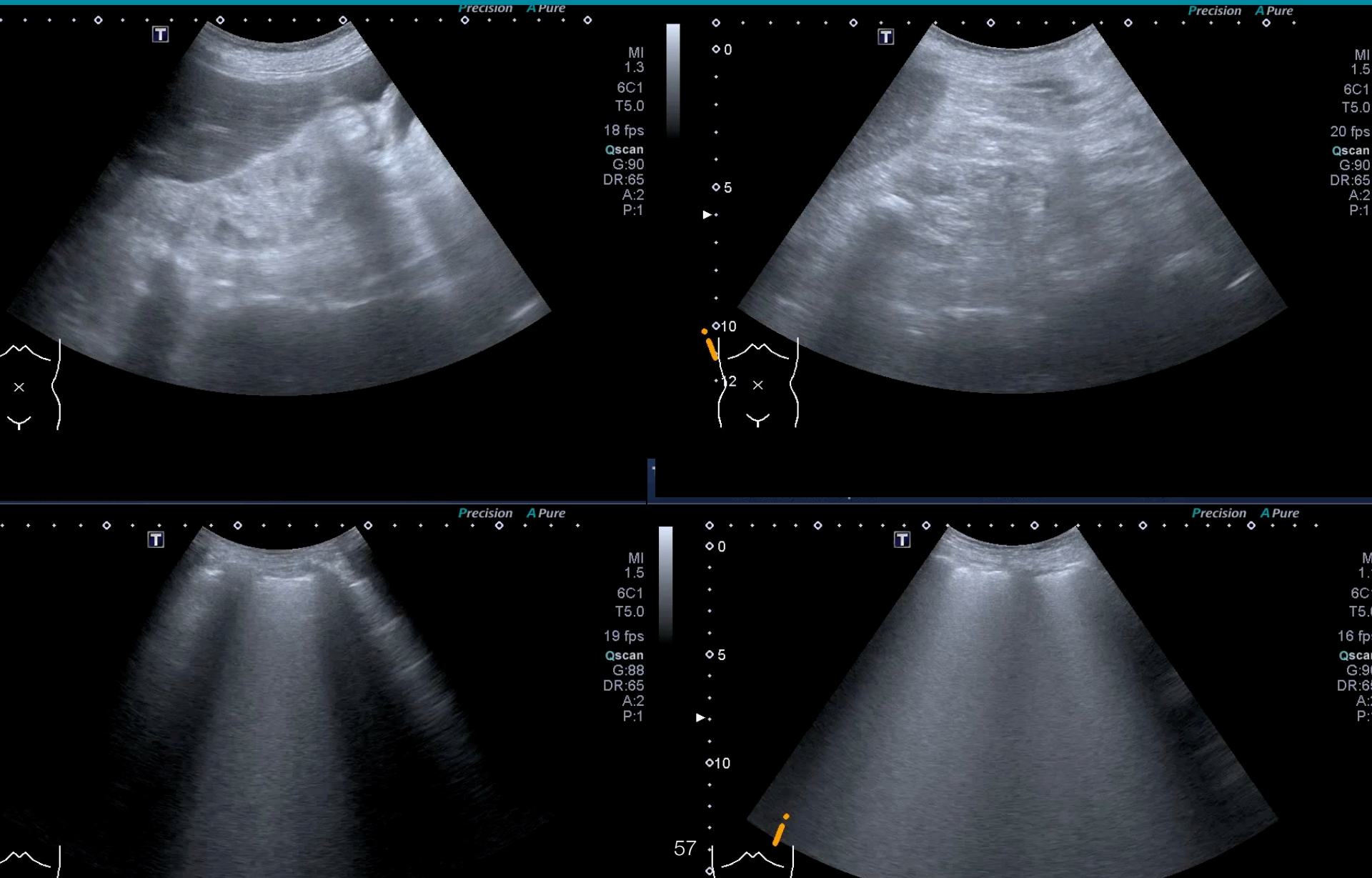

Echogenecity - Nephrotic syndrom

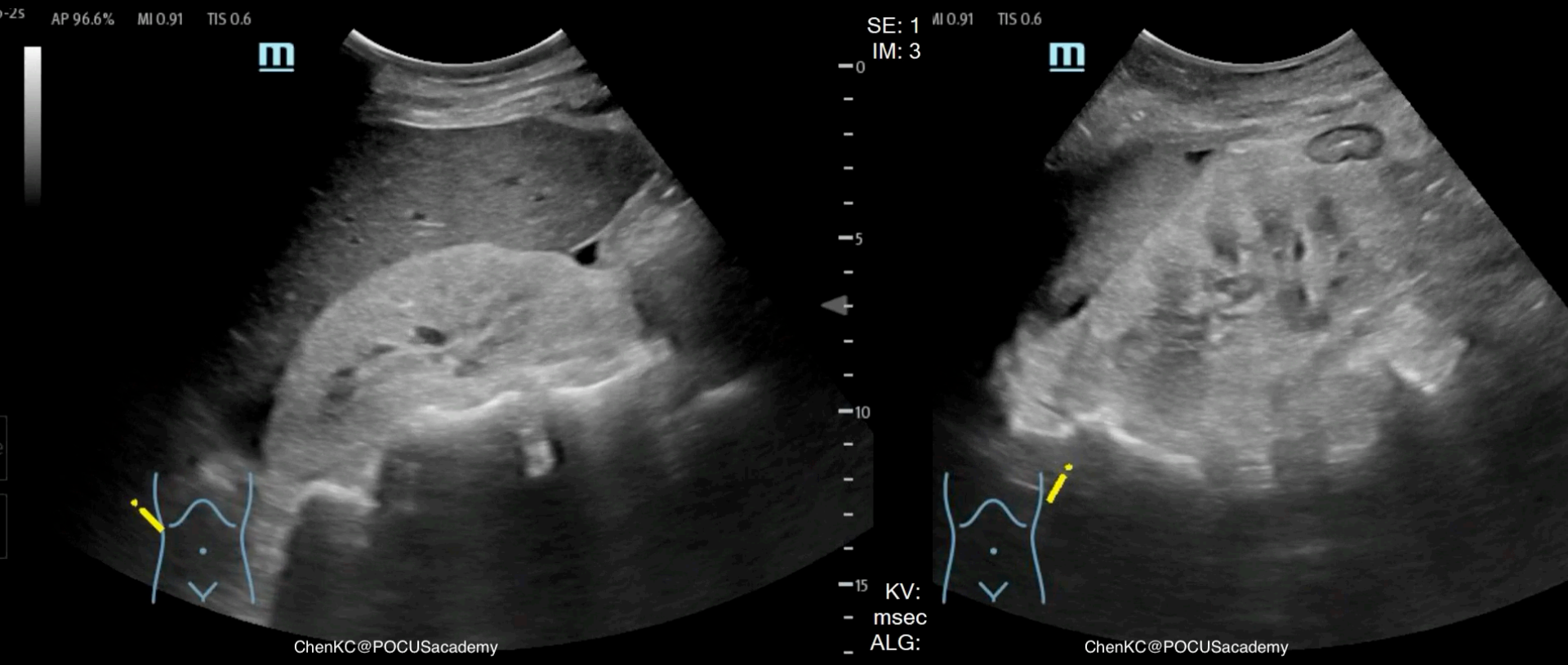

Regional - Cyst - renal

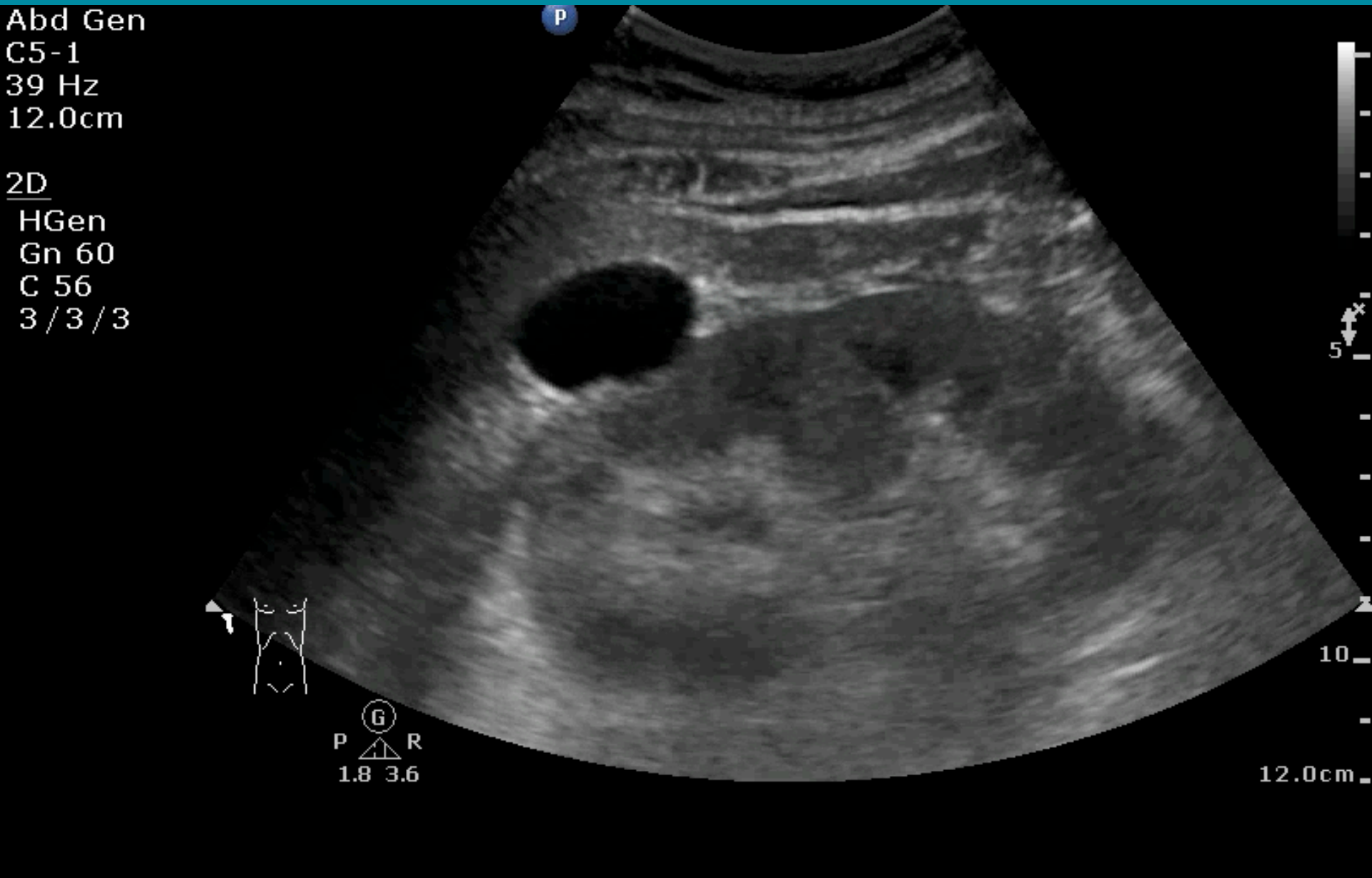

Regional - Polycystic kidney disease

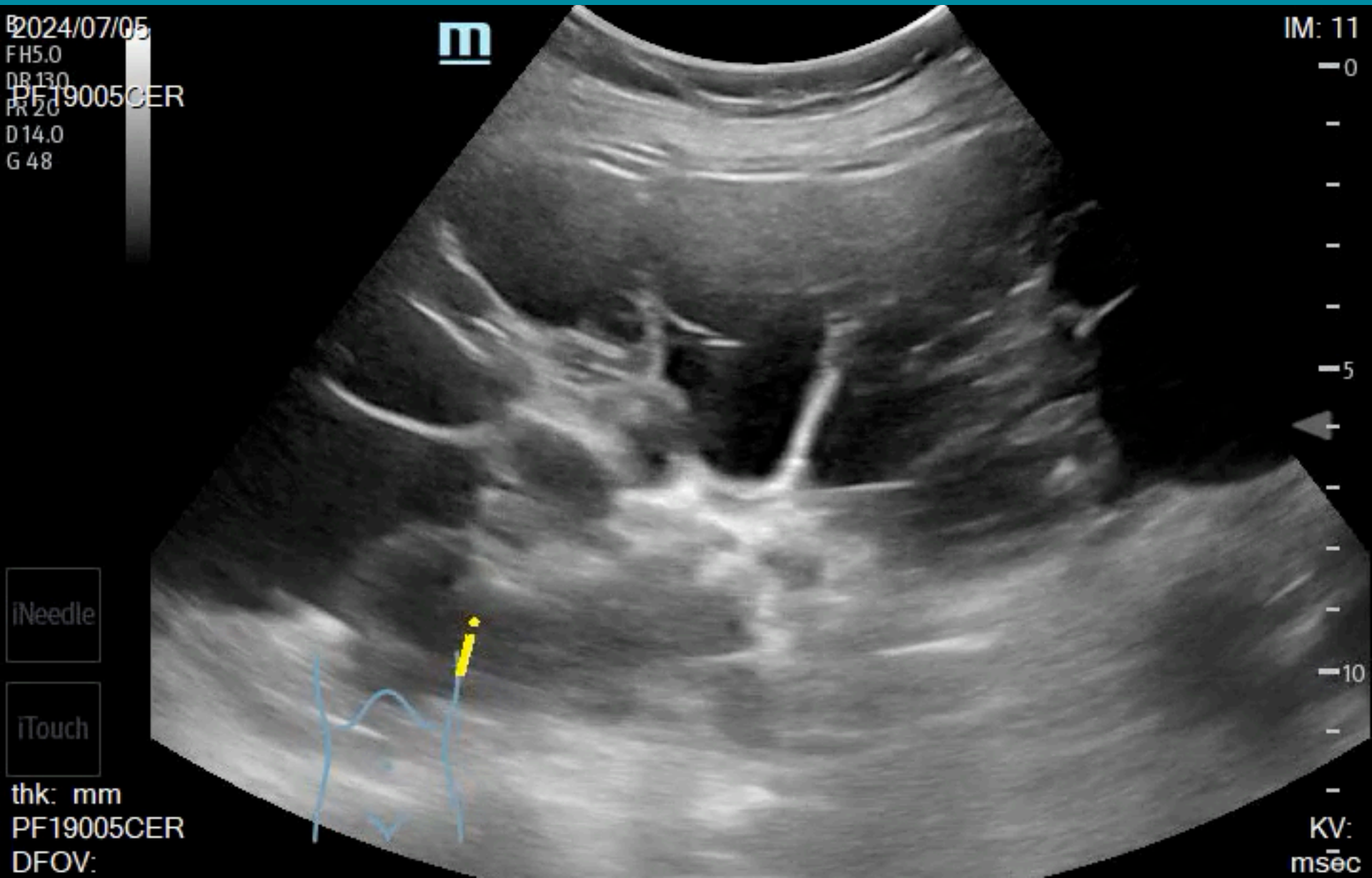

Regional - Cyst - hemorrhage

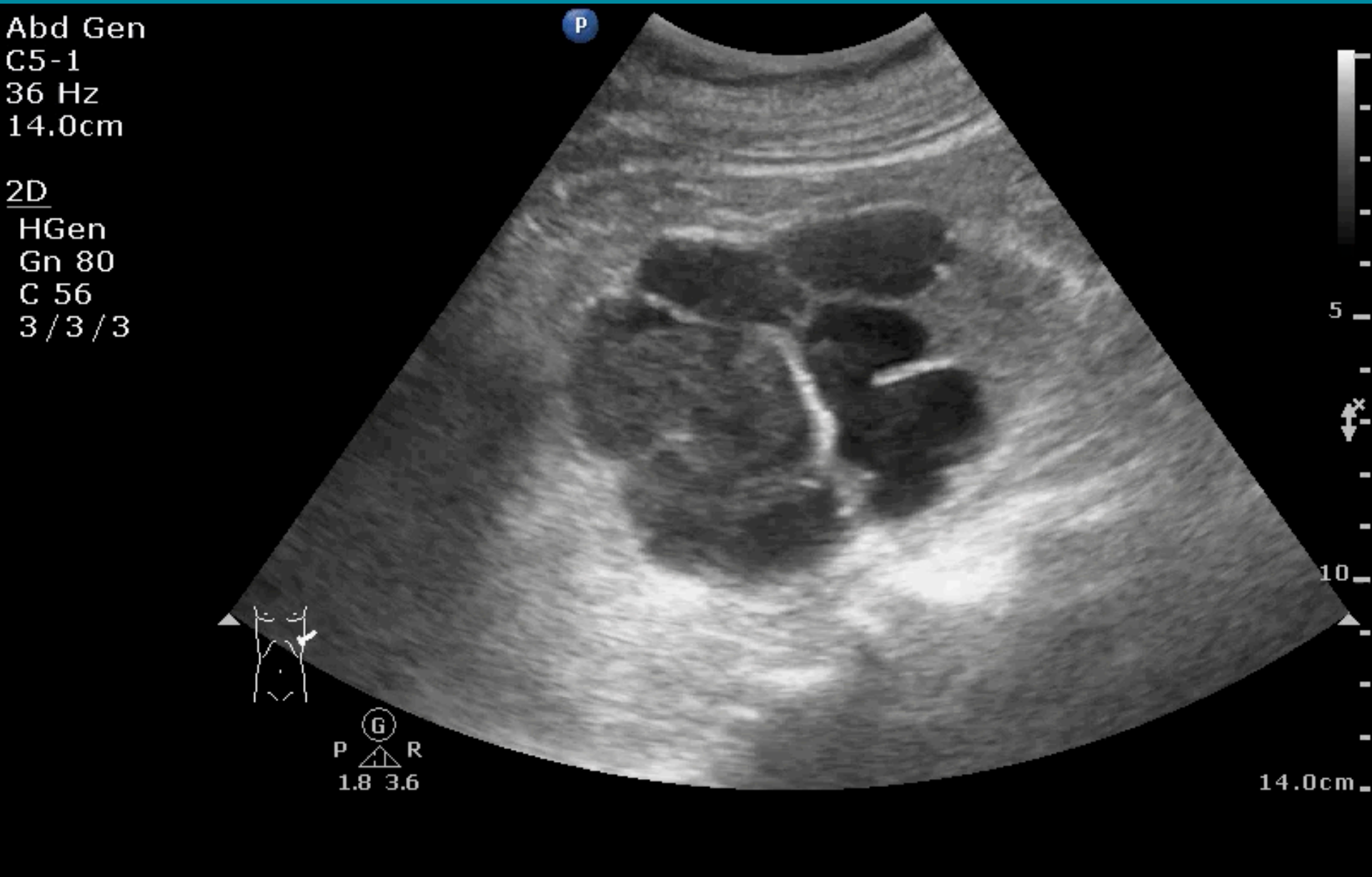

Regional - PCKD - hemorrhage

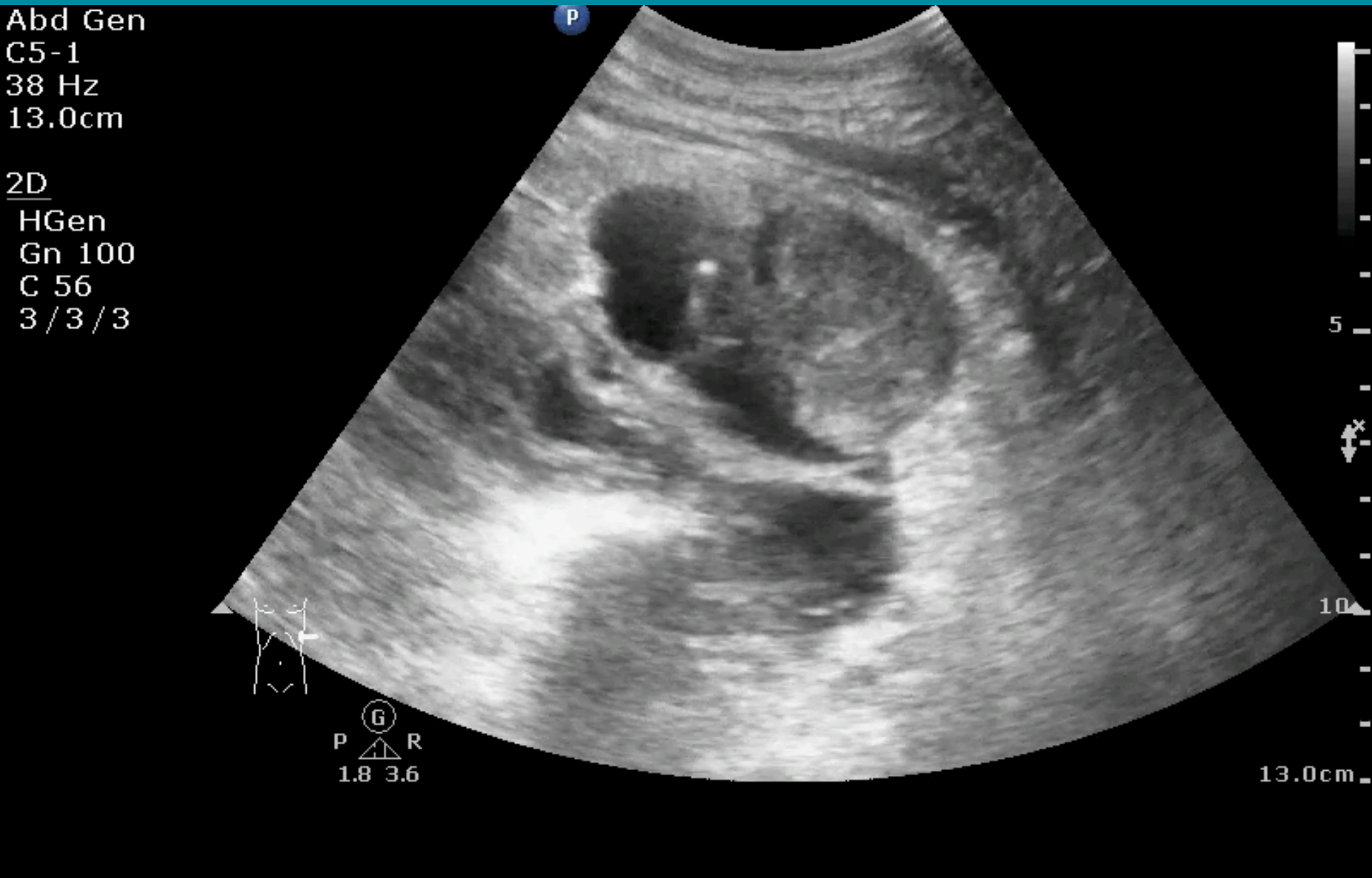

Regional - Cyst - hemorrhage

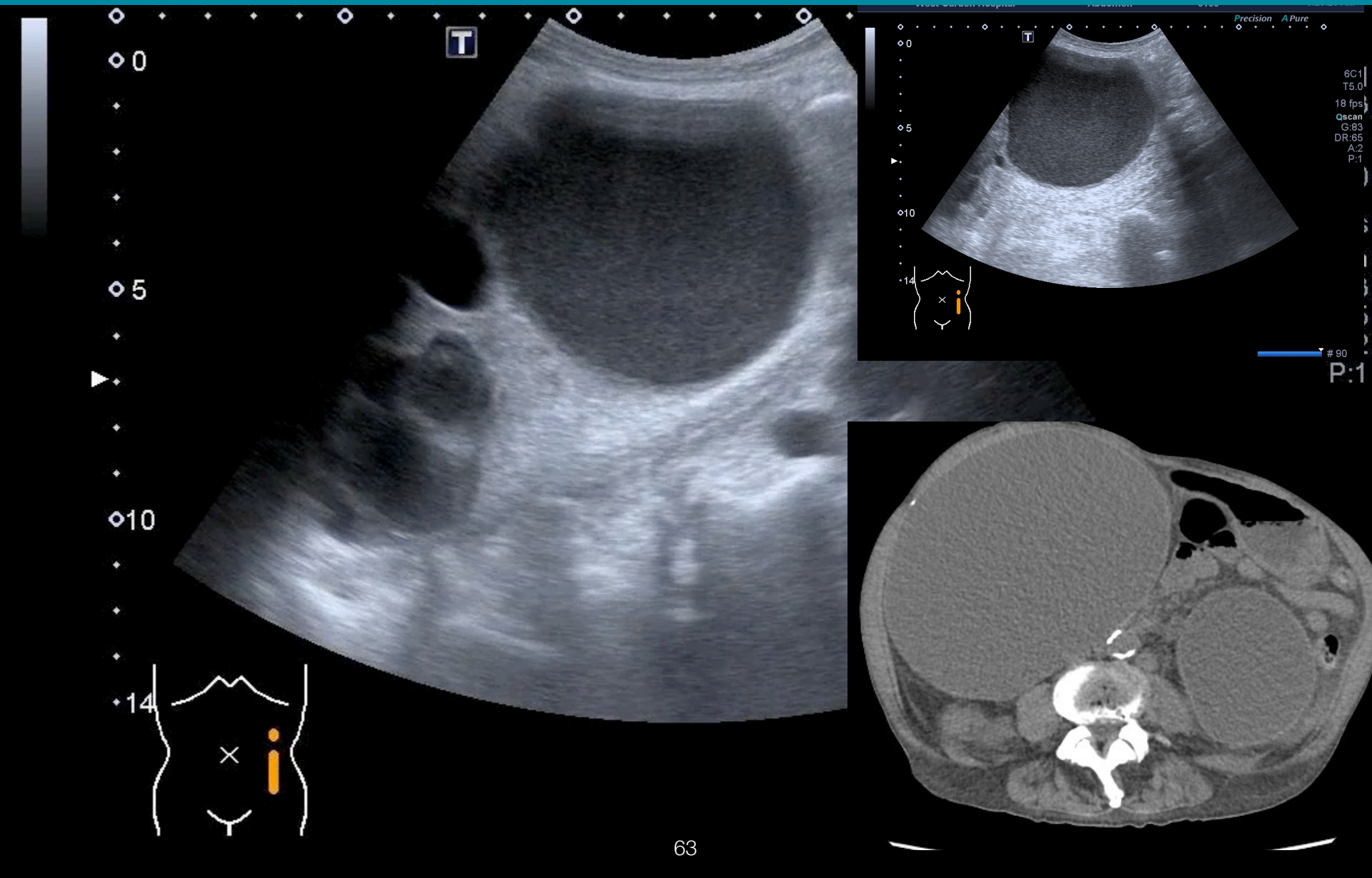

Regional - Abscess - renal

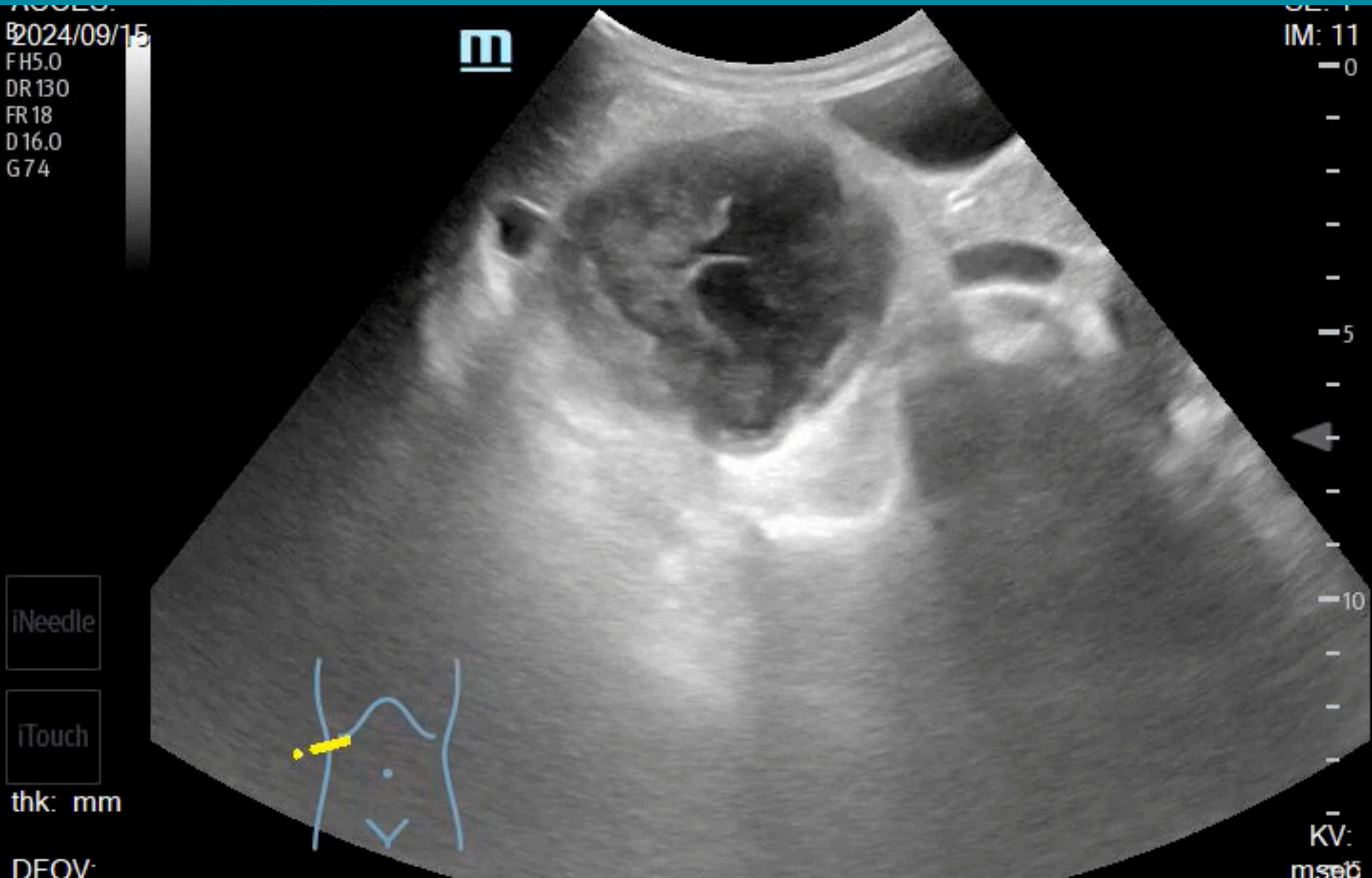

Regional - Stone - renal

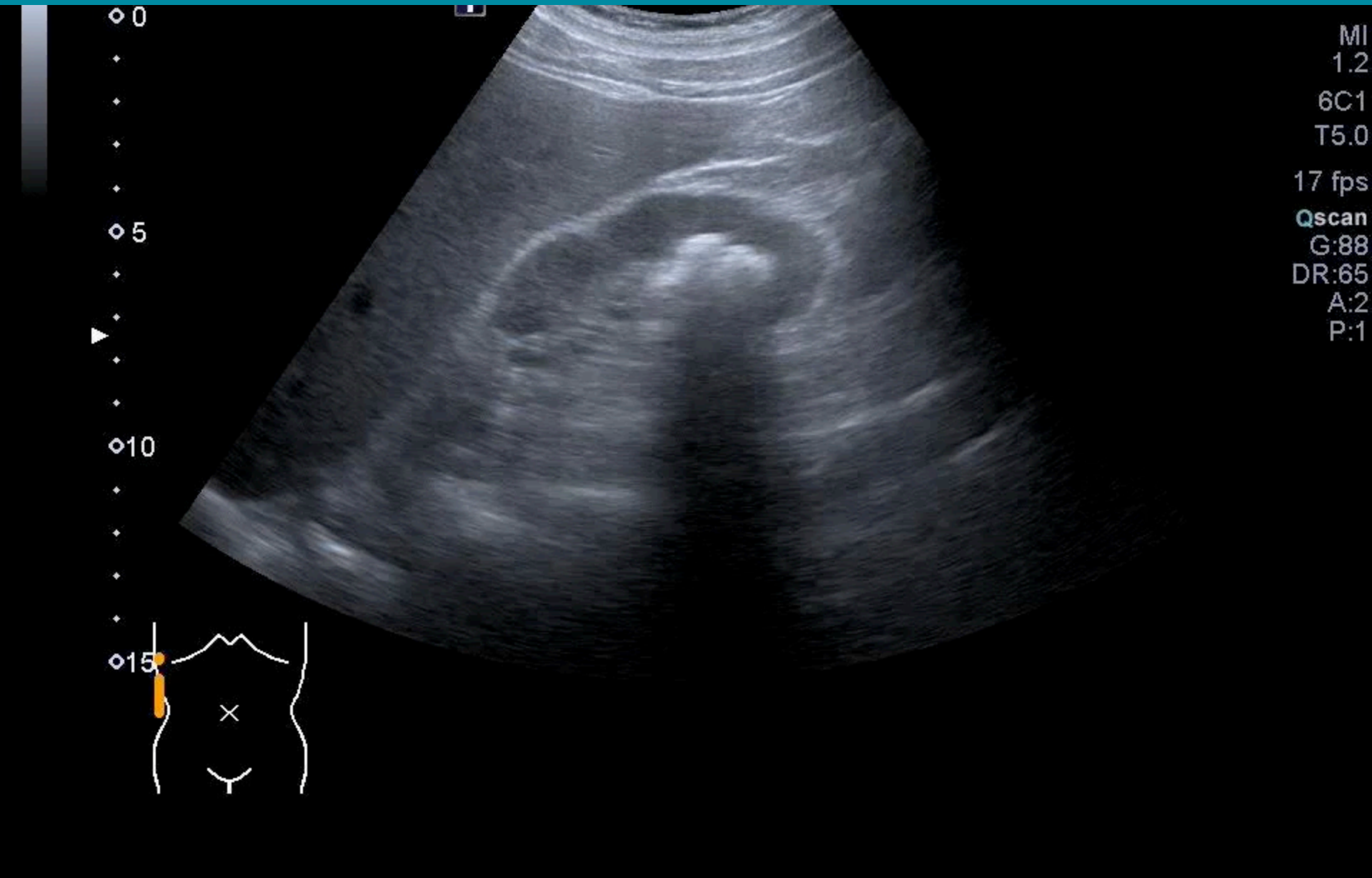

Regional - Stone - Staghorn stone

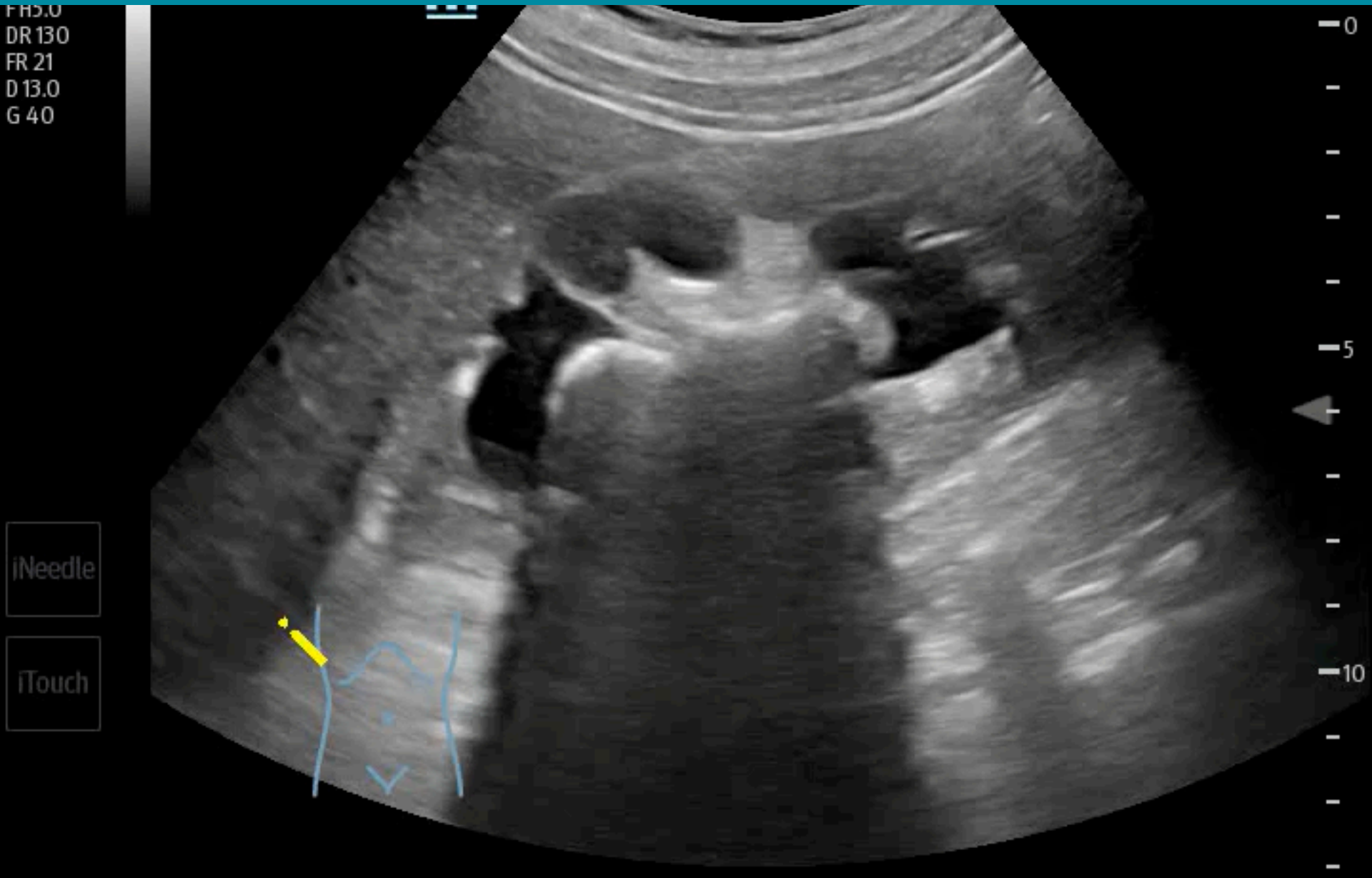

Regional - Stones - ureter

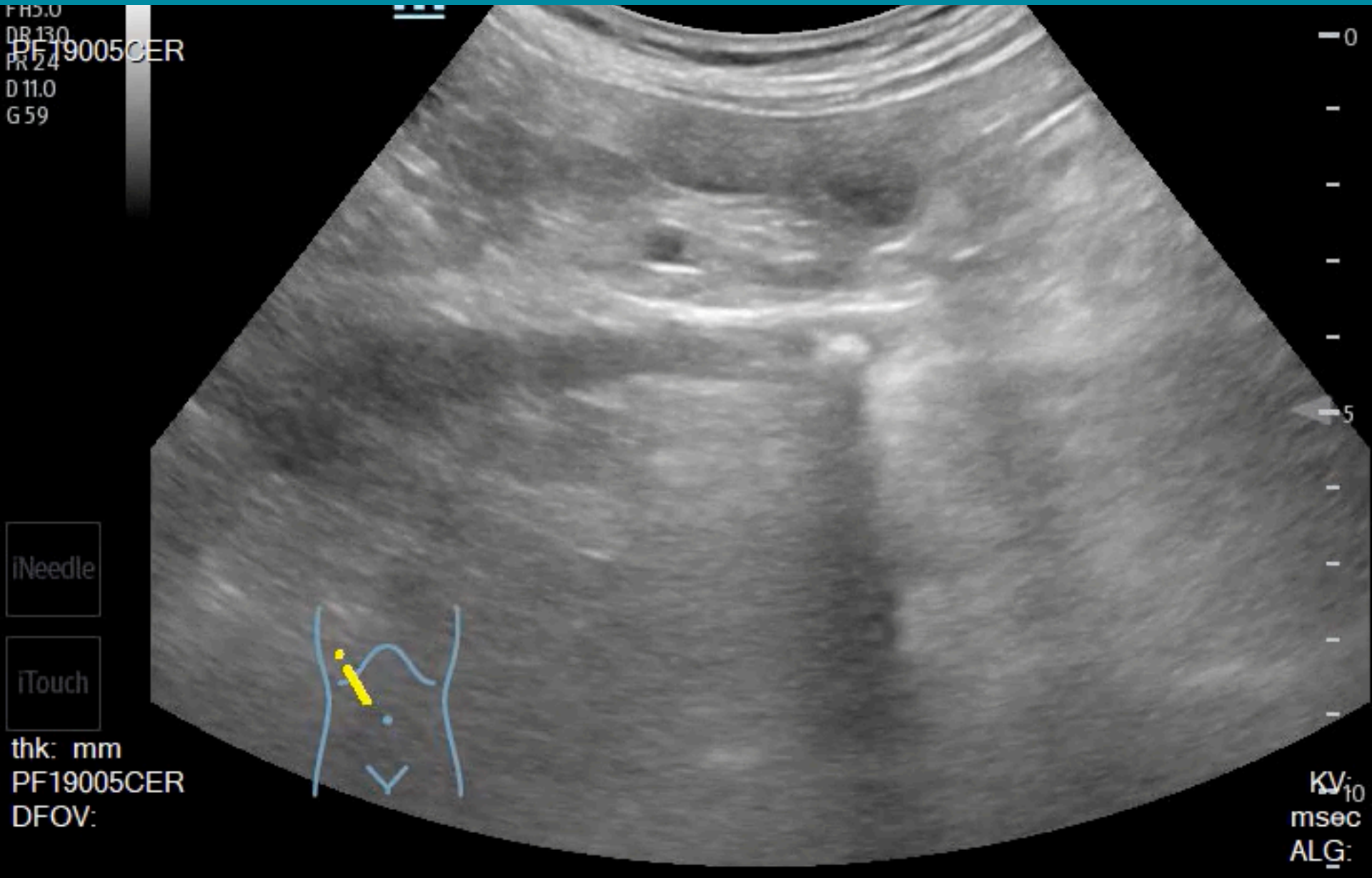

Regional - Stones - UVJ

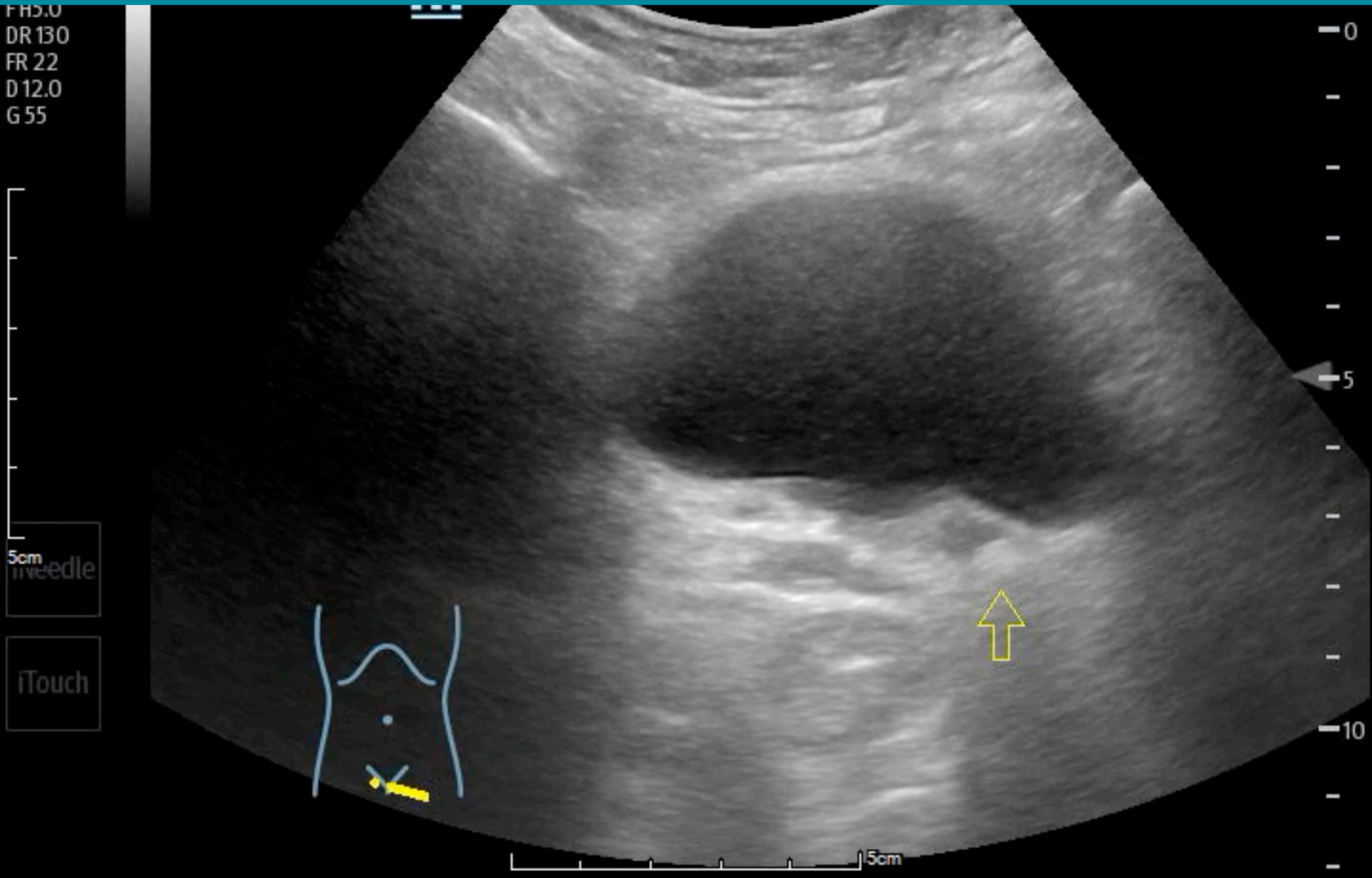

Regional - Stone - bladder

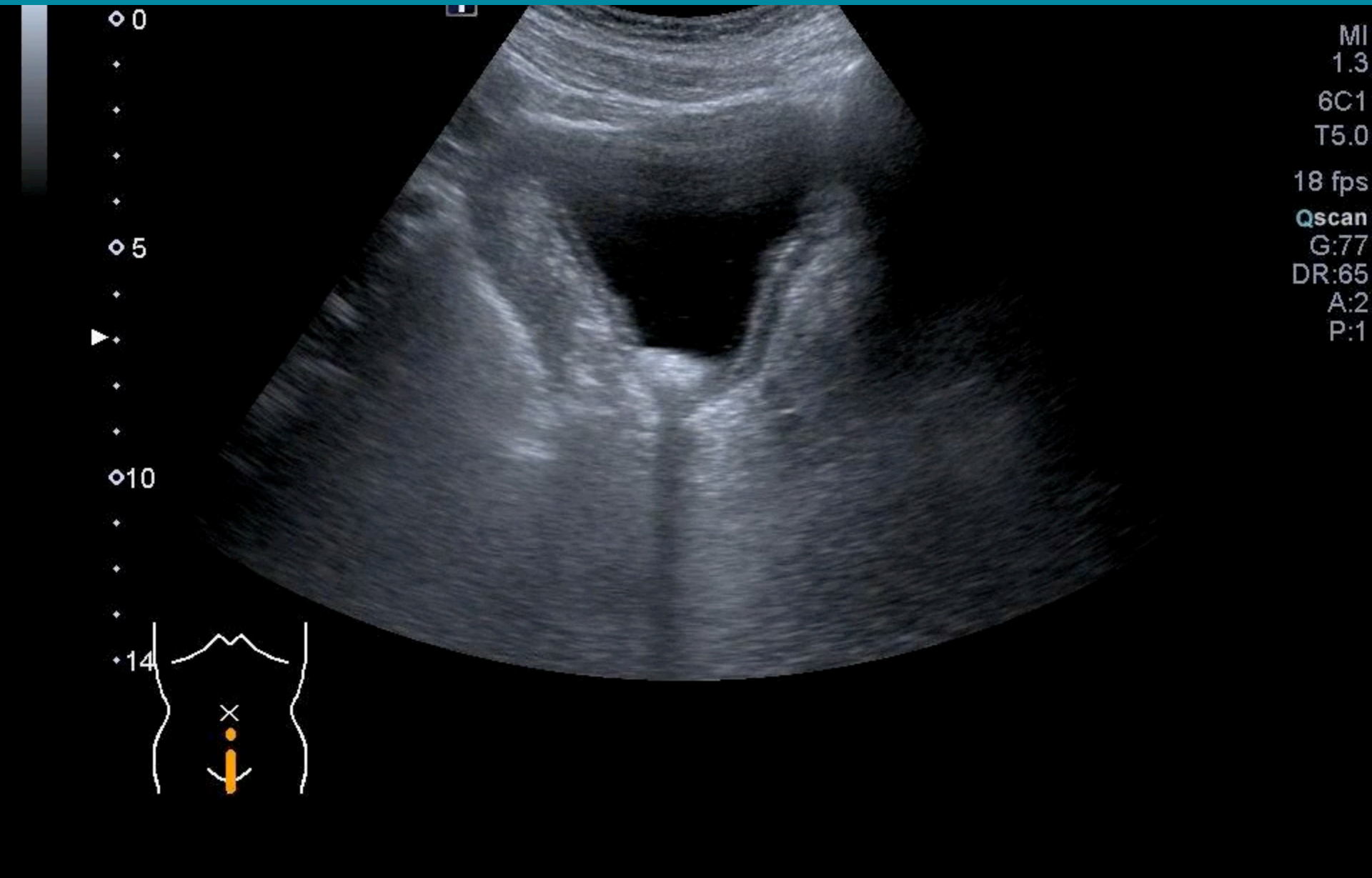

Regional - Mass - renal tumor

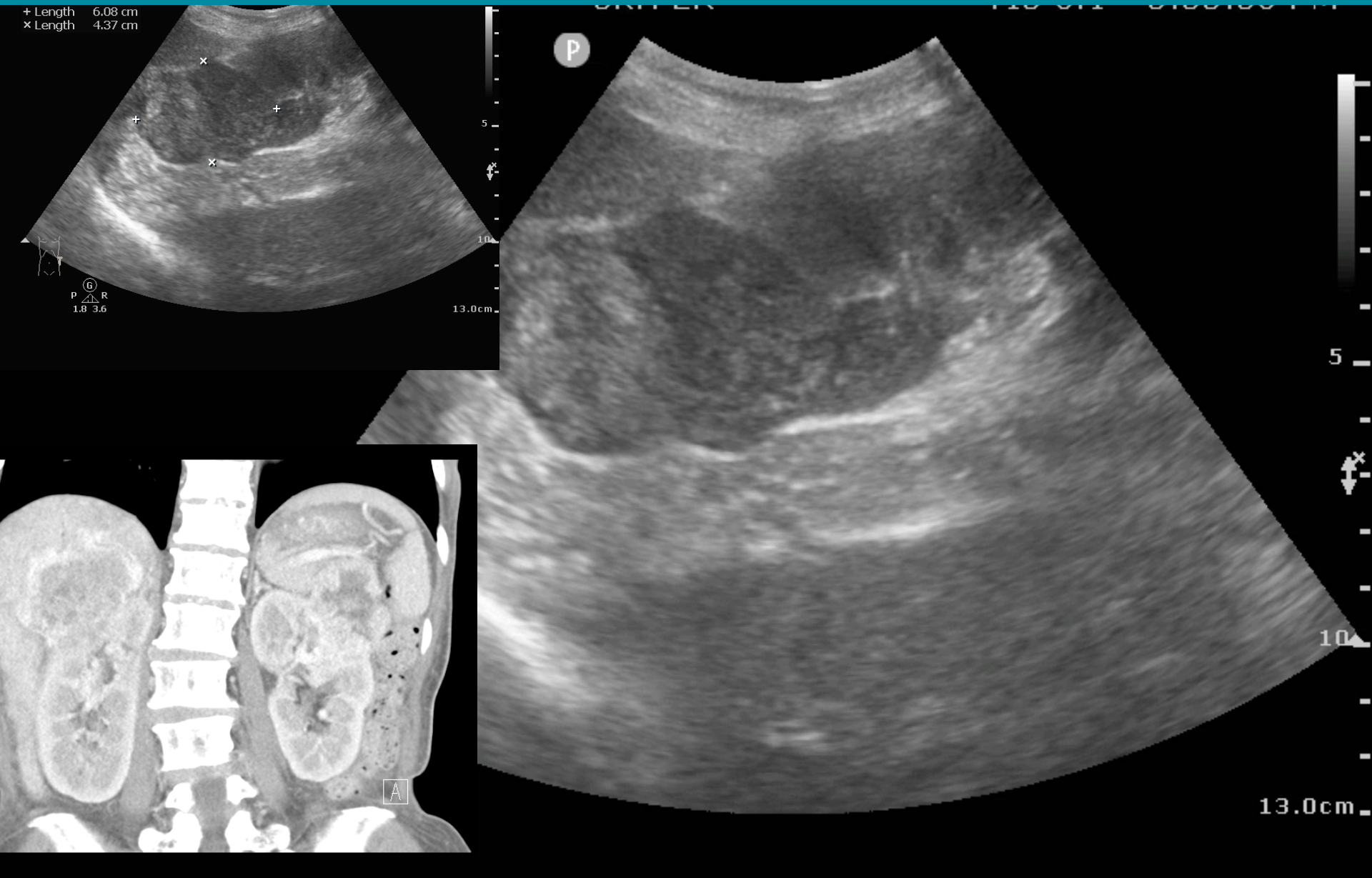

Regional - Mass - renal tumor

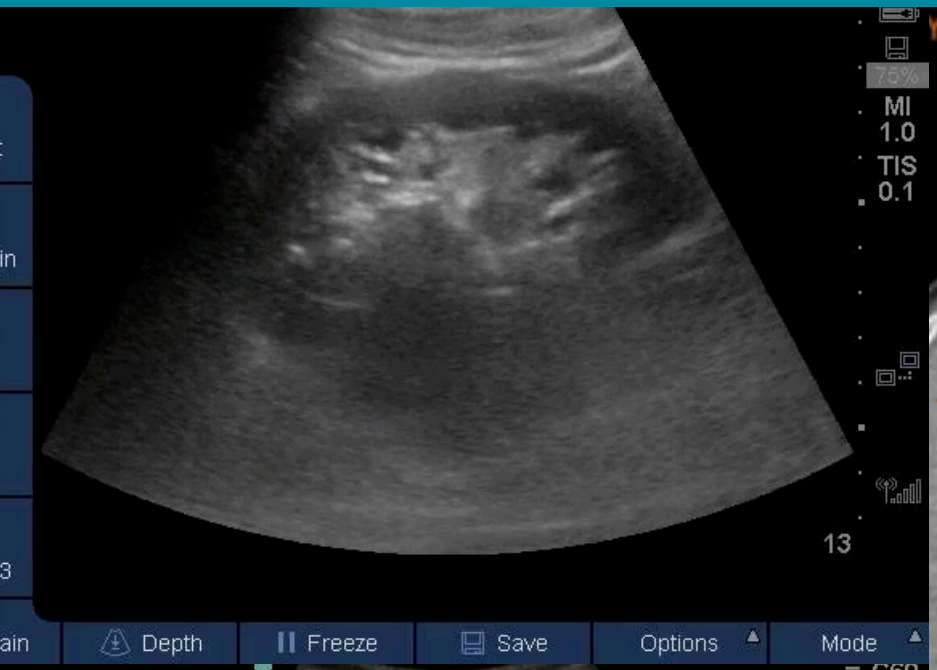

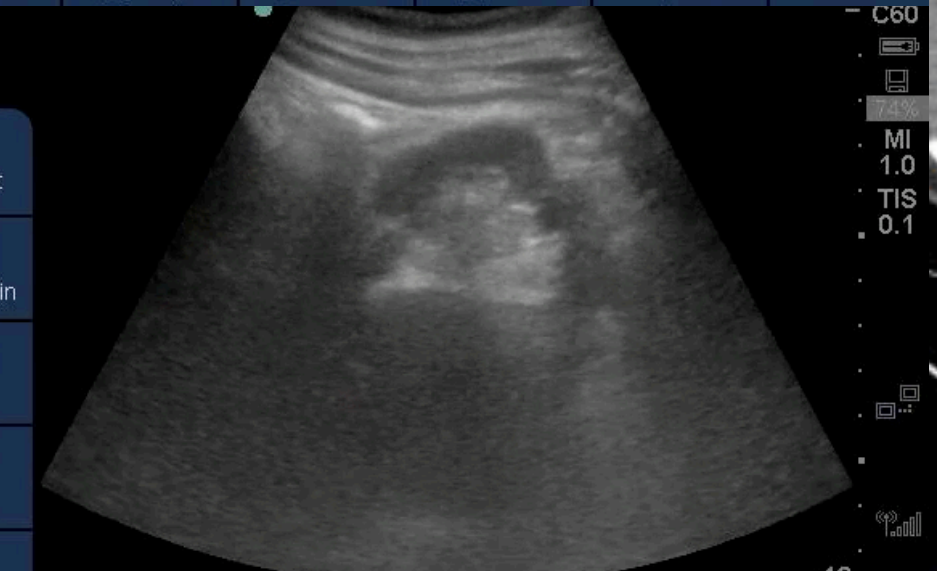

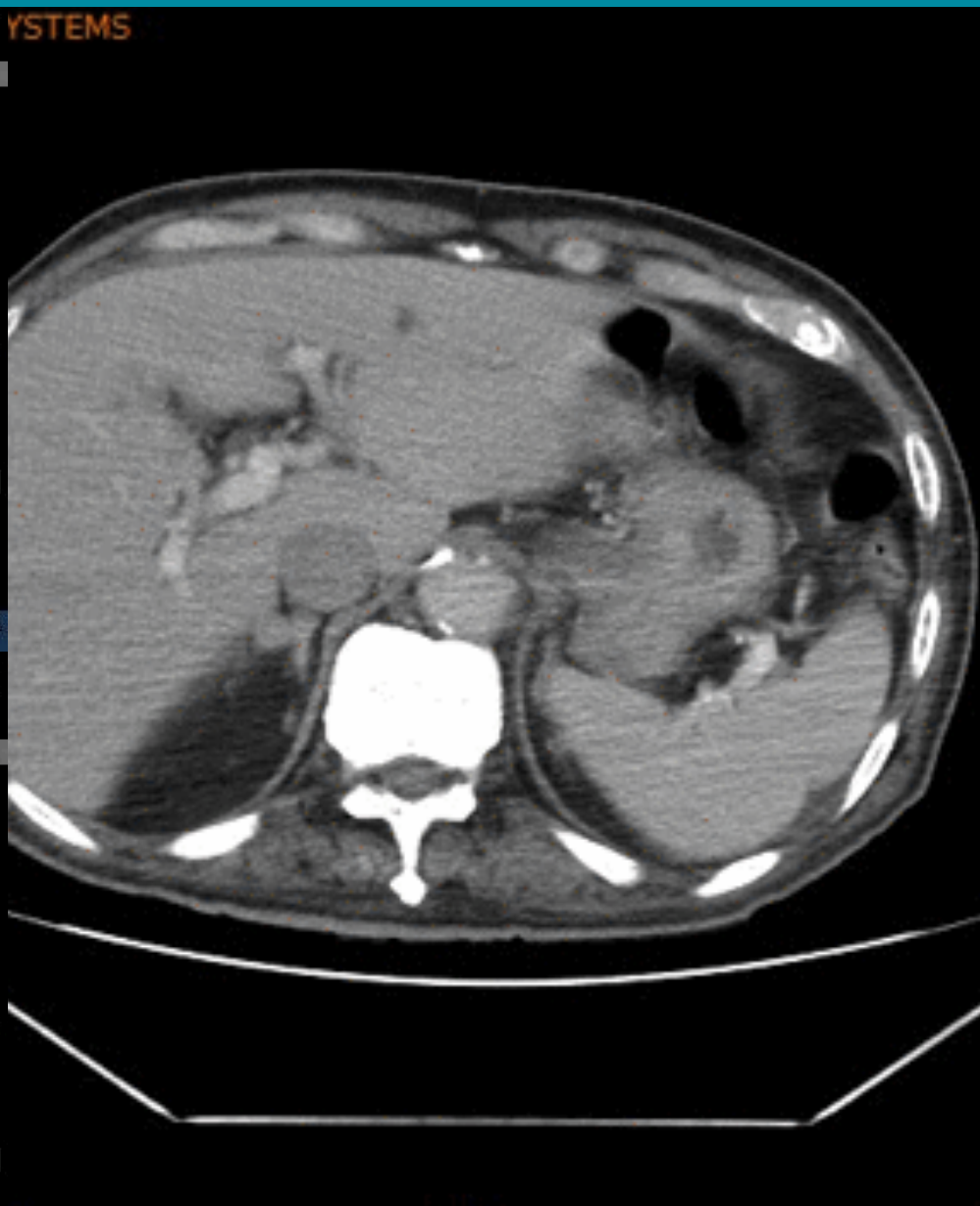

Regional - Mass - angiomyolipoma

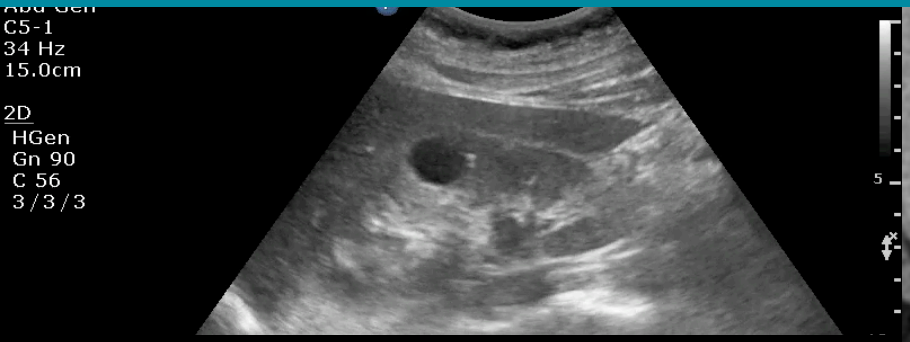

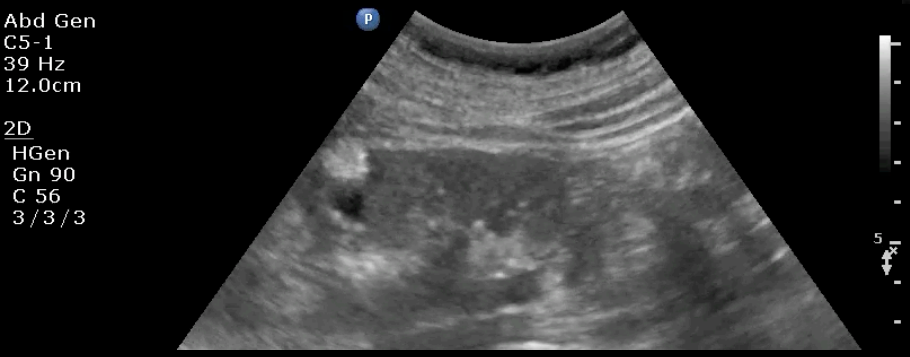

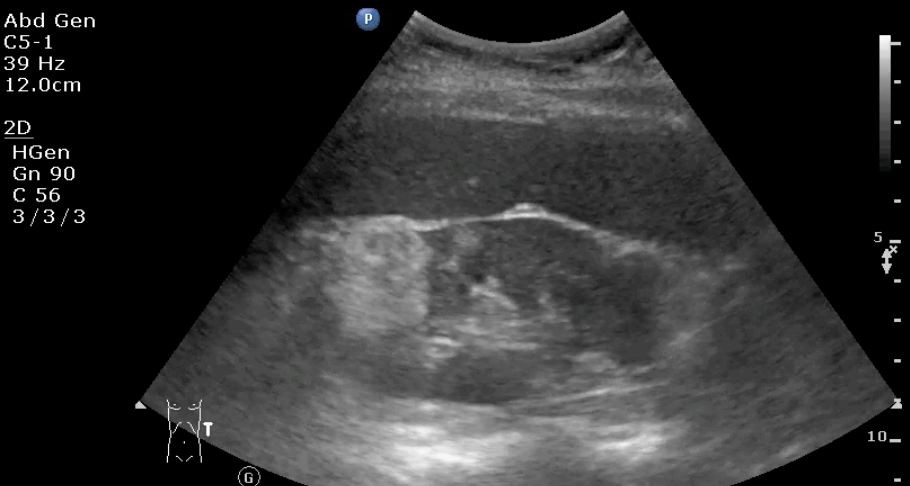

Regional - Mass - angiomyolipoma

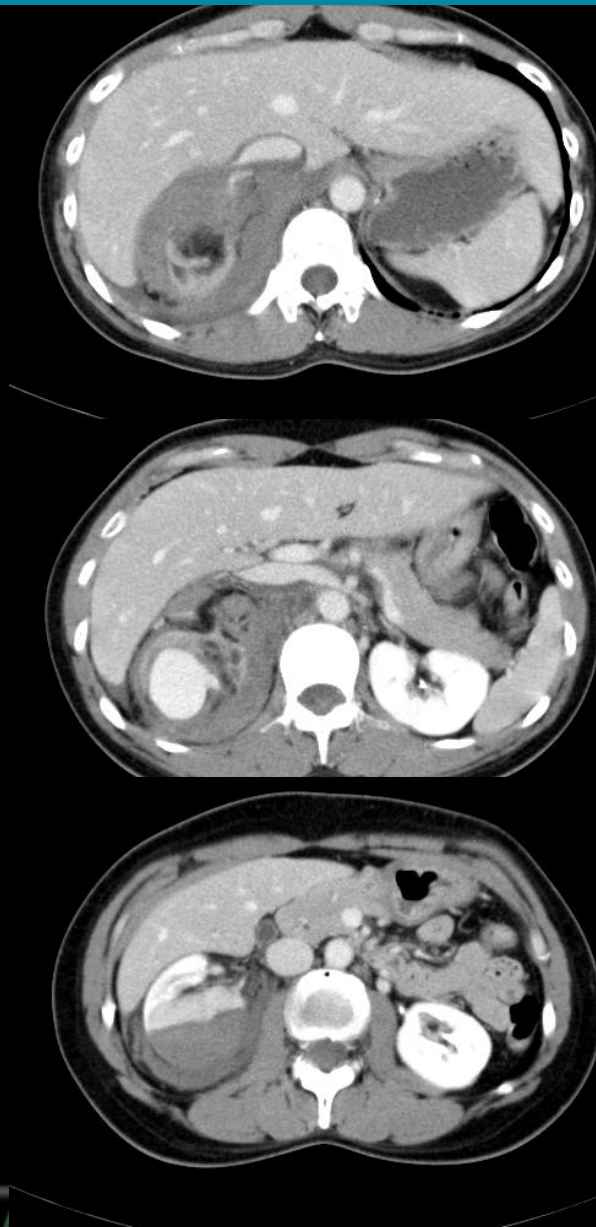

51F with abdominal pain

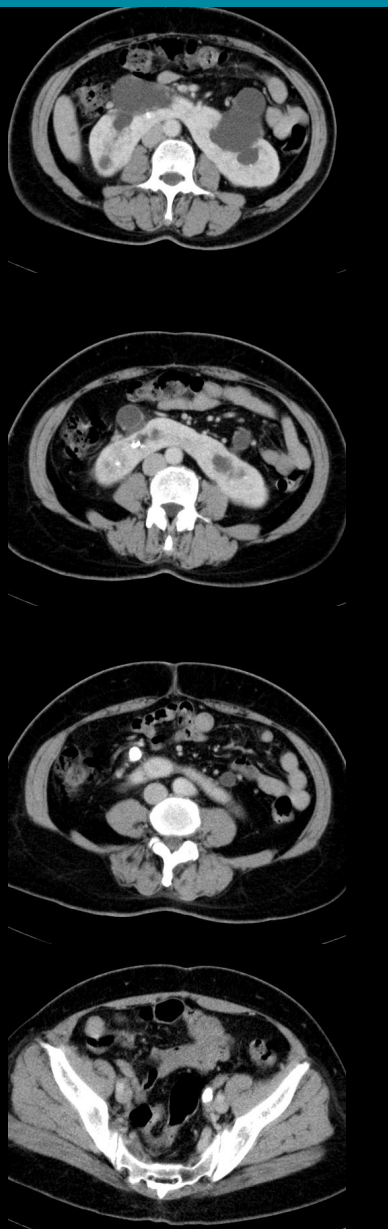

UVJ stone / Twinkling artifact

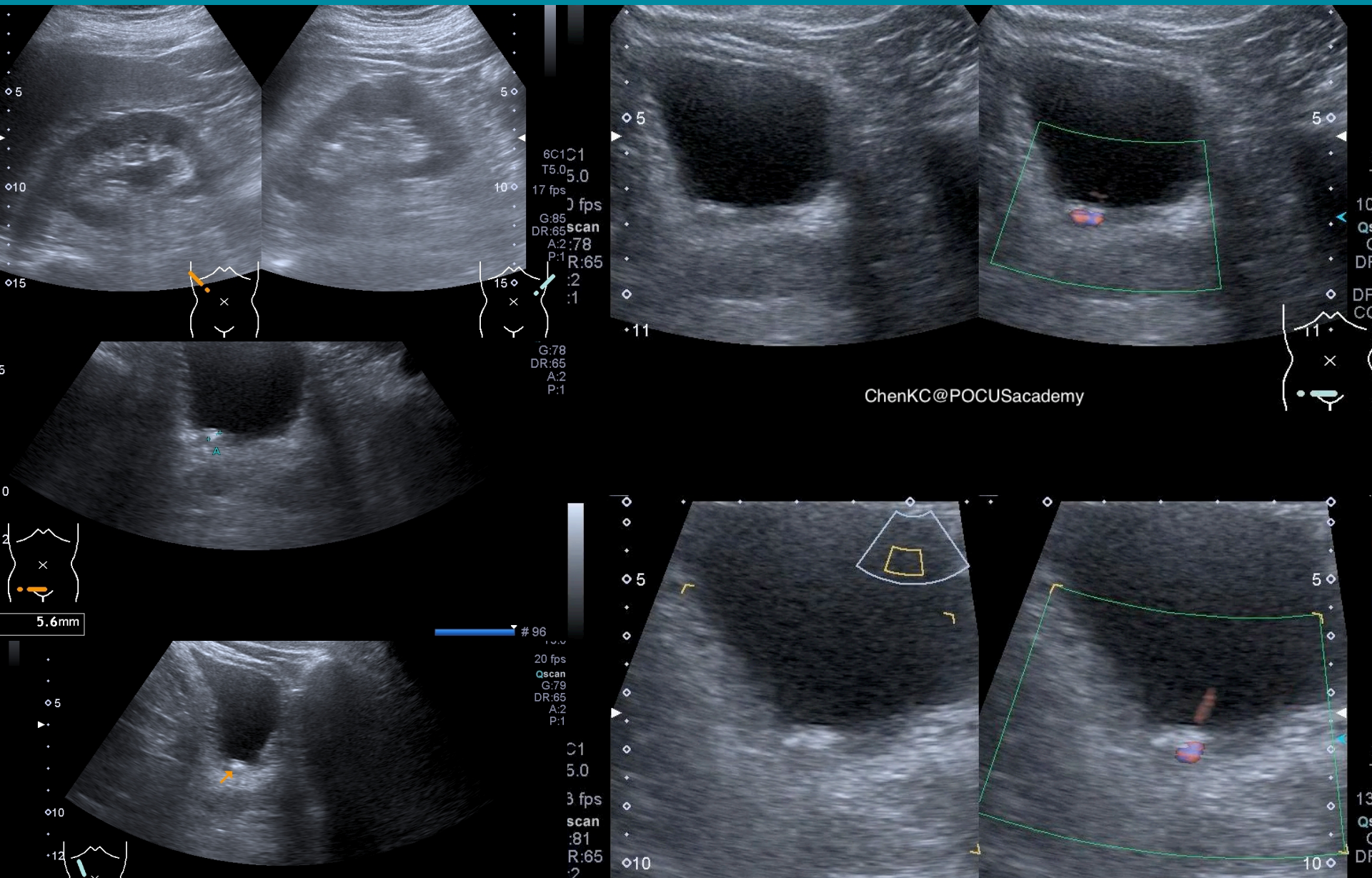

43F, RLQ pain

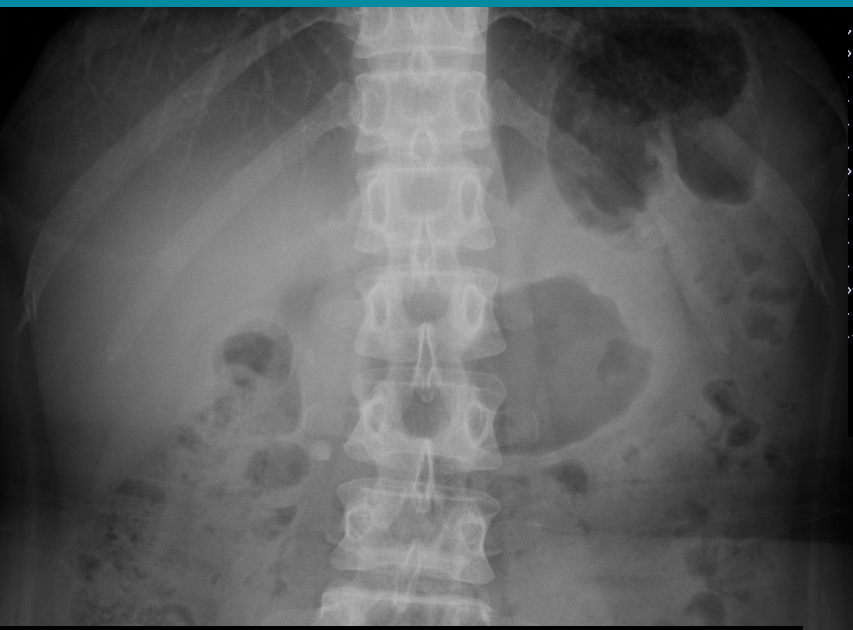

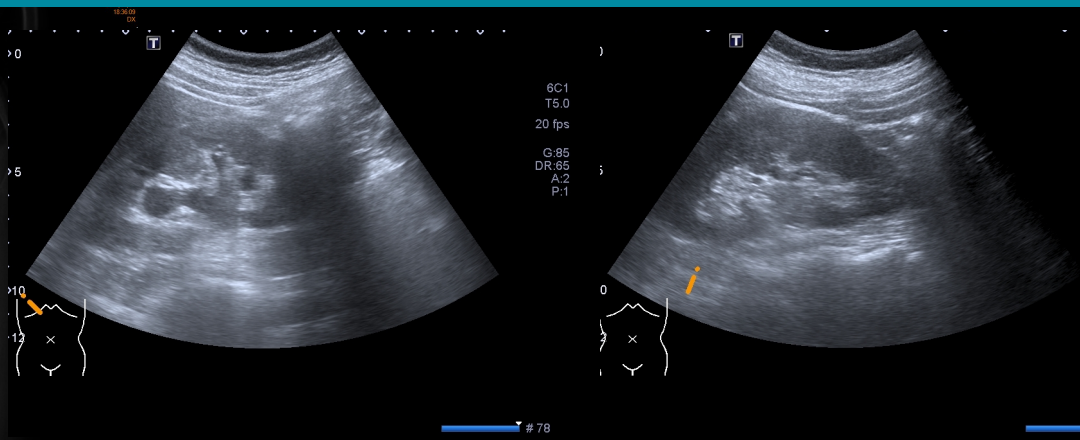
6C1
T5.0
20 fps
G:85
DR:65
A:2
P:1
78

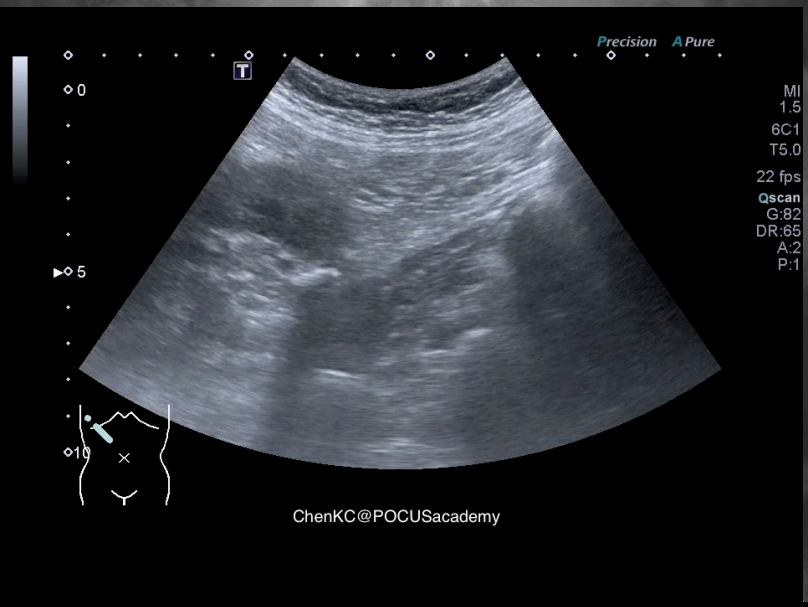
Precision
A Pure
MI
1.5
6C1
T5.0
22 fps
Qscan
G:82
DR:65
A:2
P:1
ChenKC@POCUSacademy

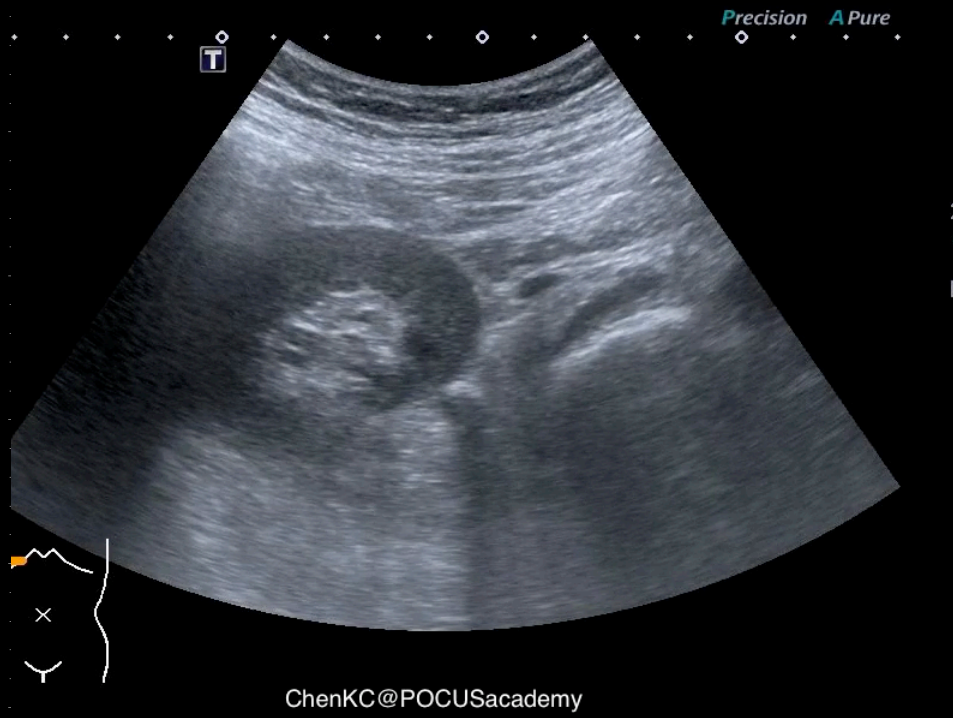
Precision
A Pure
ChenKC@POCUSacademy

72F with UTI & Sepsis

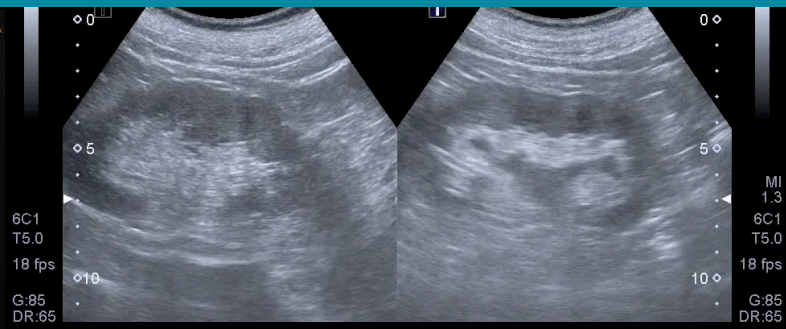

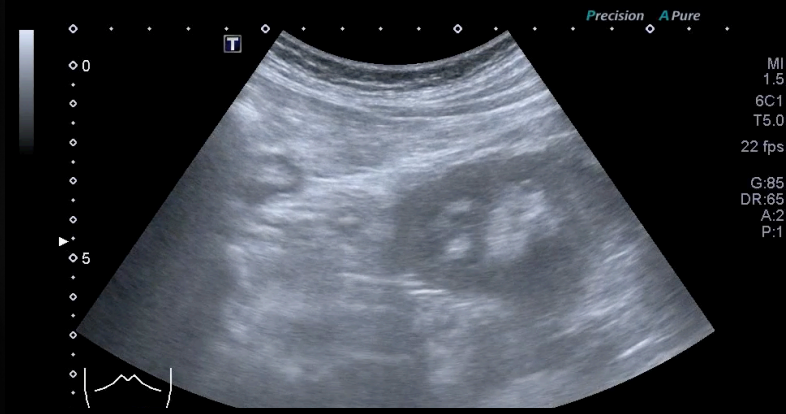

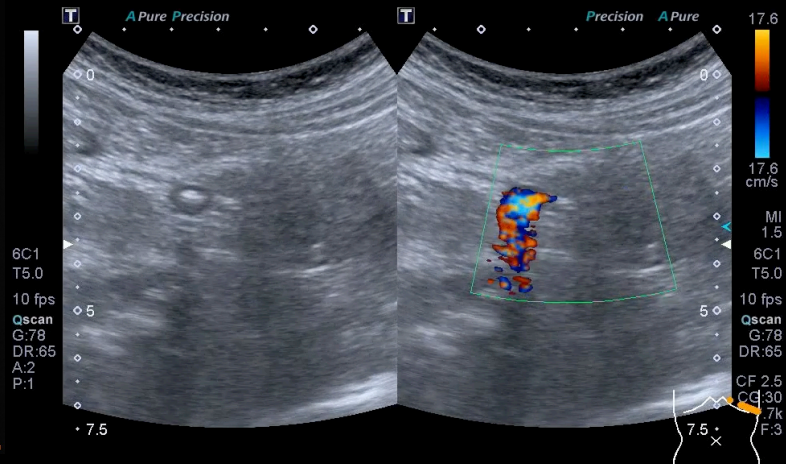

58F, Fever & left flank pain

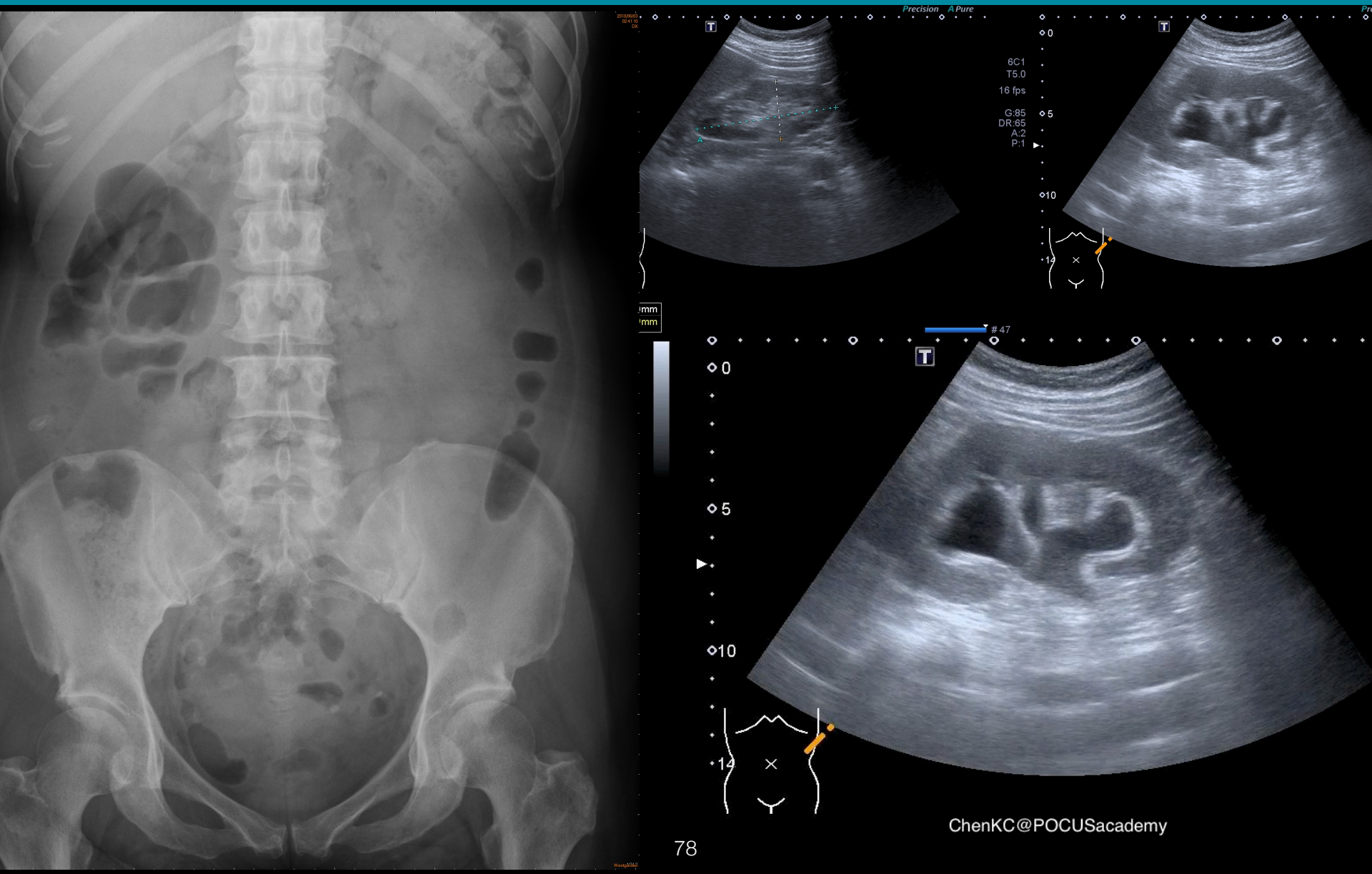

Ureteral stone with pyonephrosis

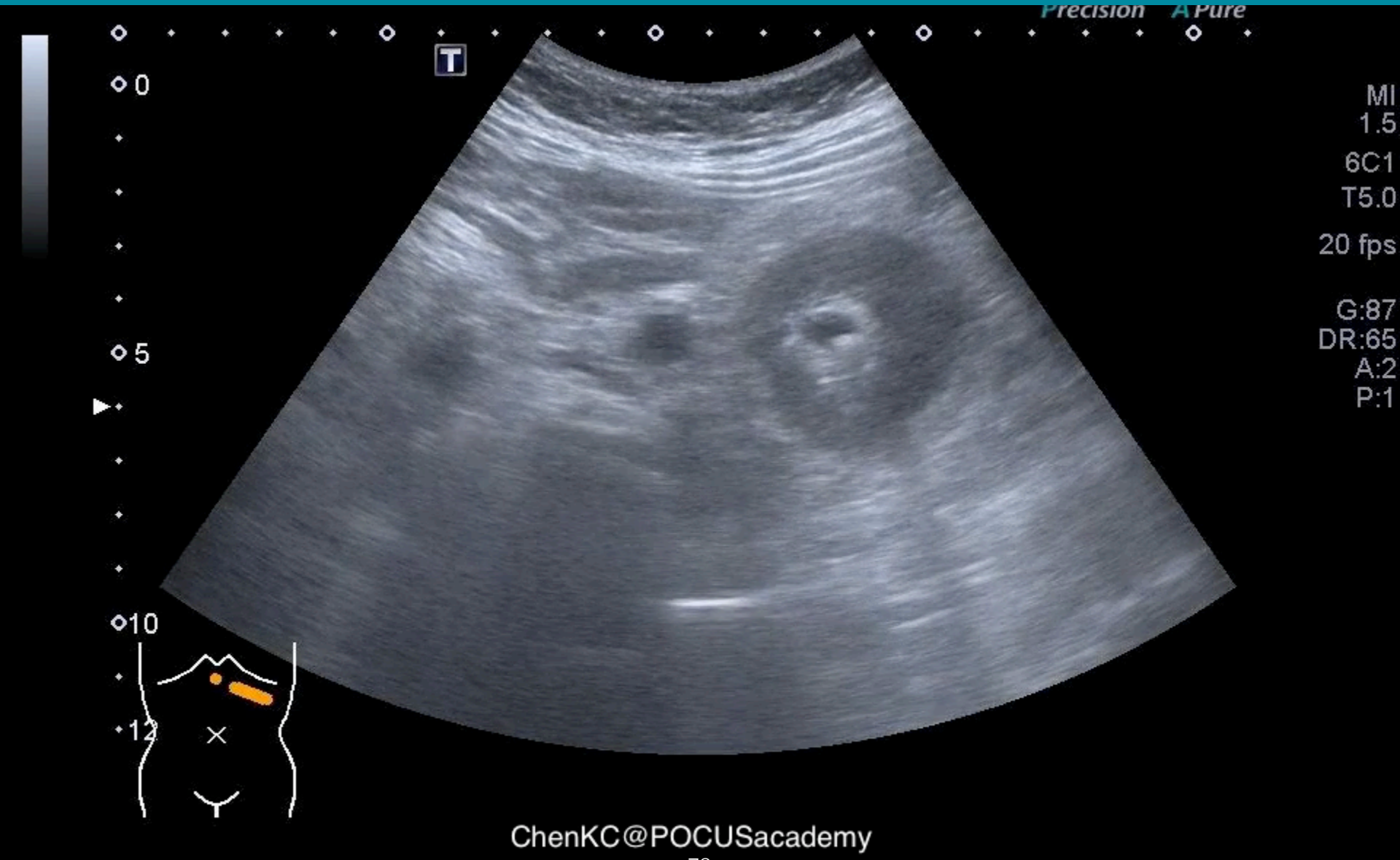

Ureteral stone with pyonephrosis

Pyonephrosis

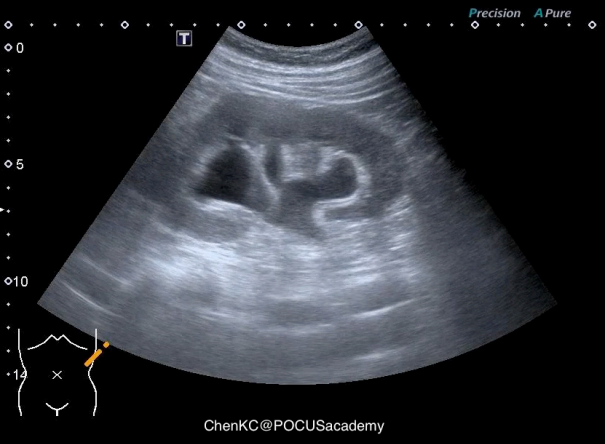

Traffic light sign

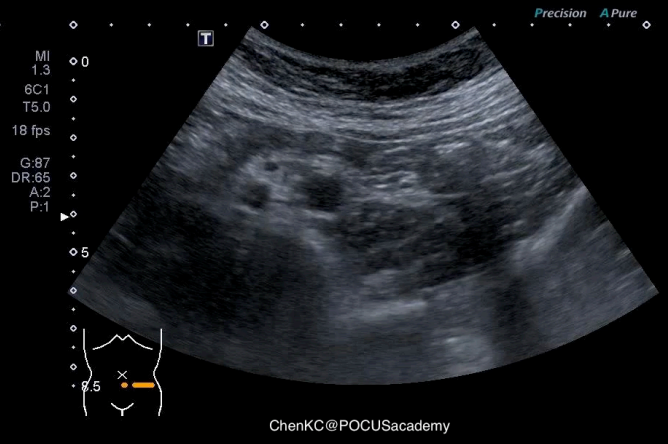

Manipulation

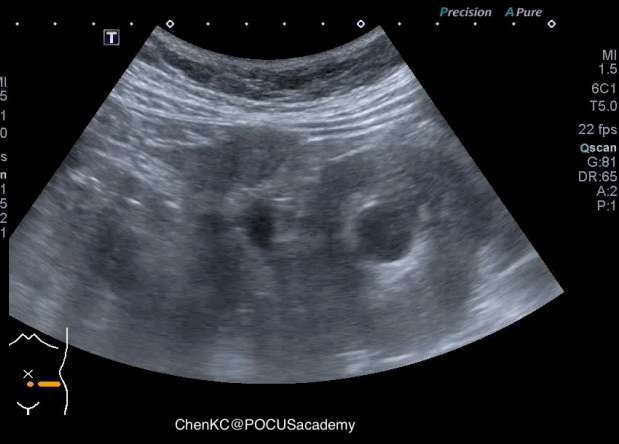

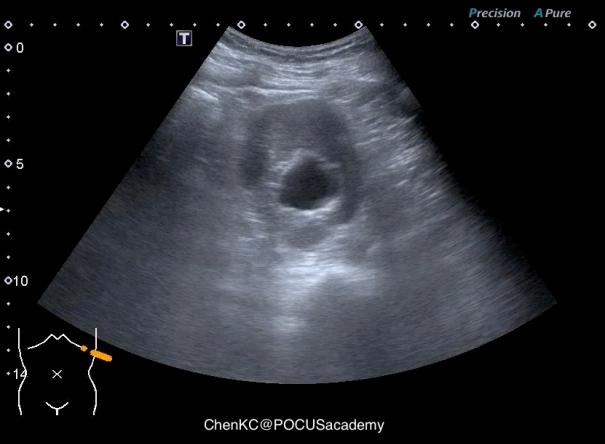

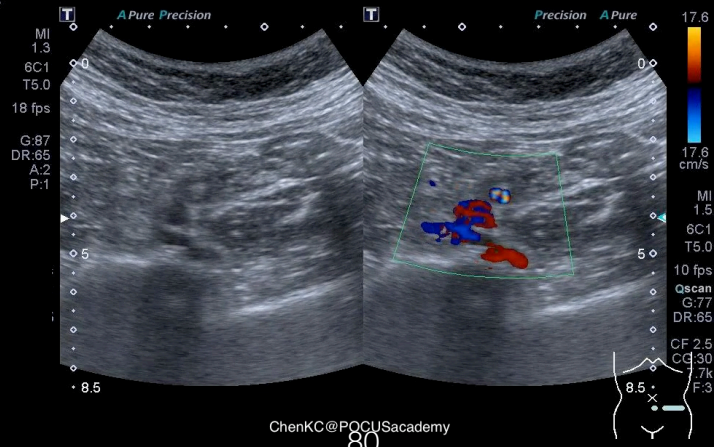

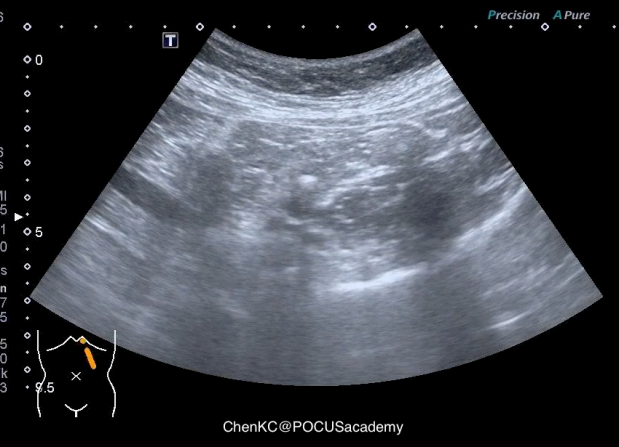

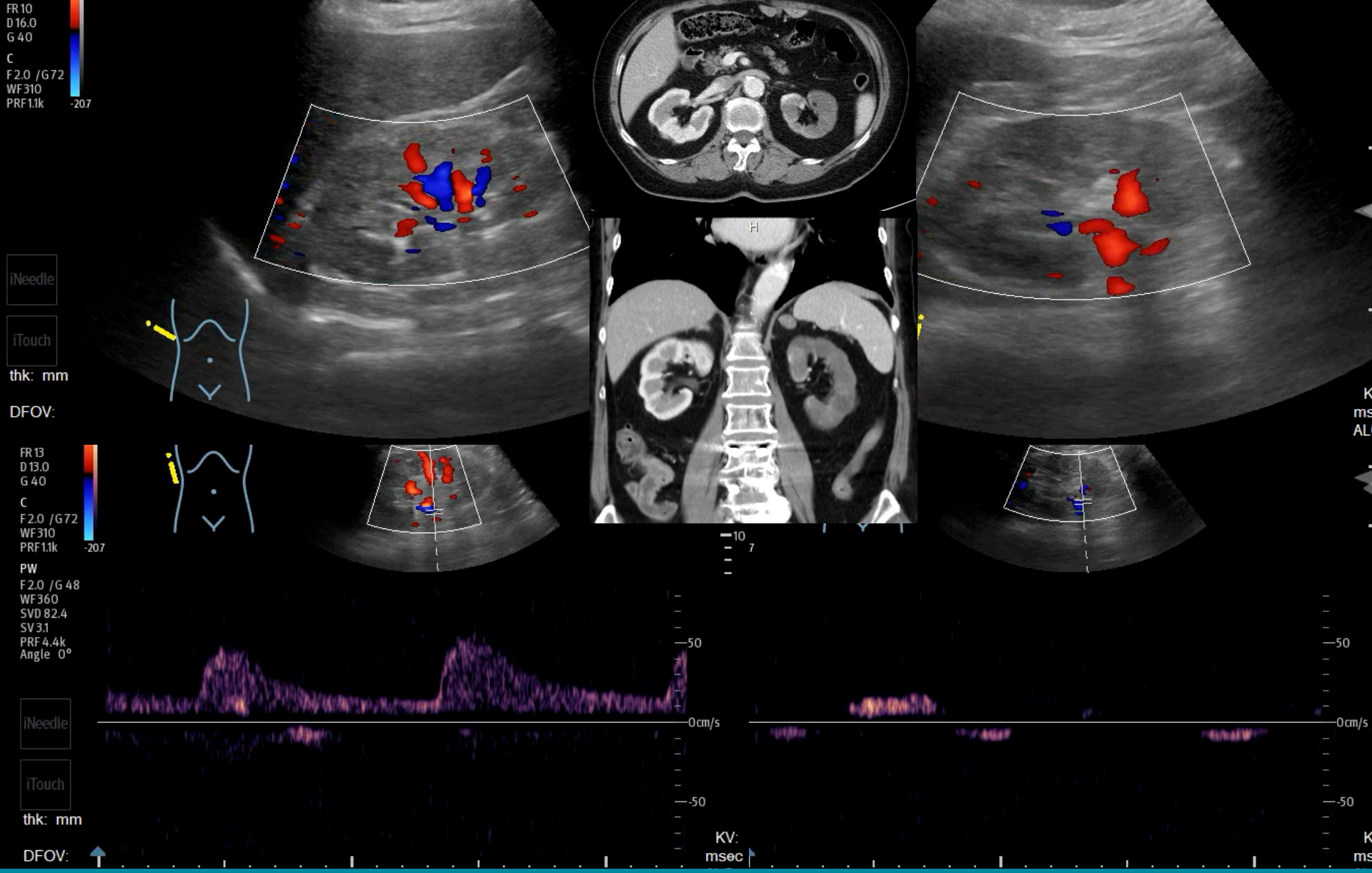

Always think about vascular emergency

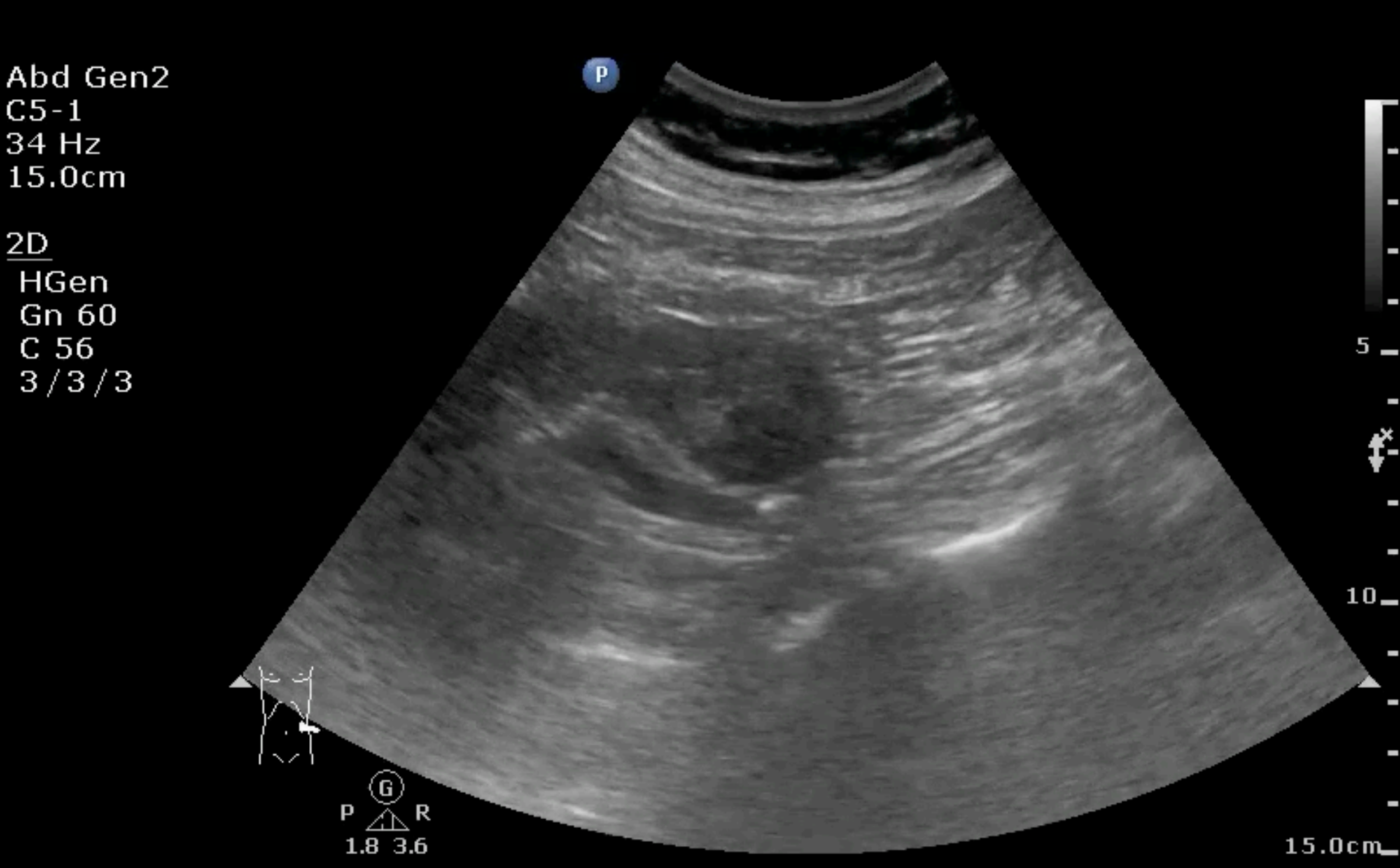
Abd Gen2
C5-1
34 Hz
15.0cm
2D
HGen
Gn 60
C 56
3/3/3
P
G
P
R
1.8 3.6
5
10
15.0cm

UPJ stone

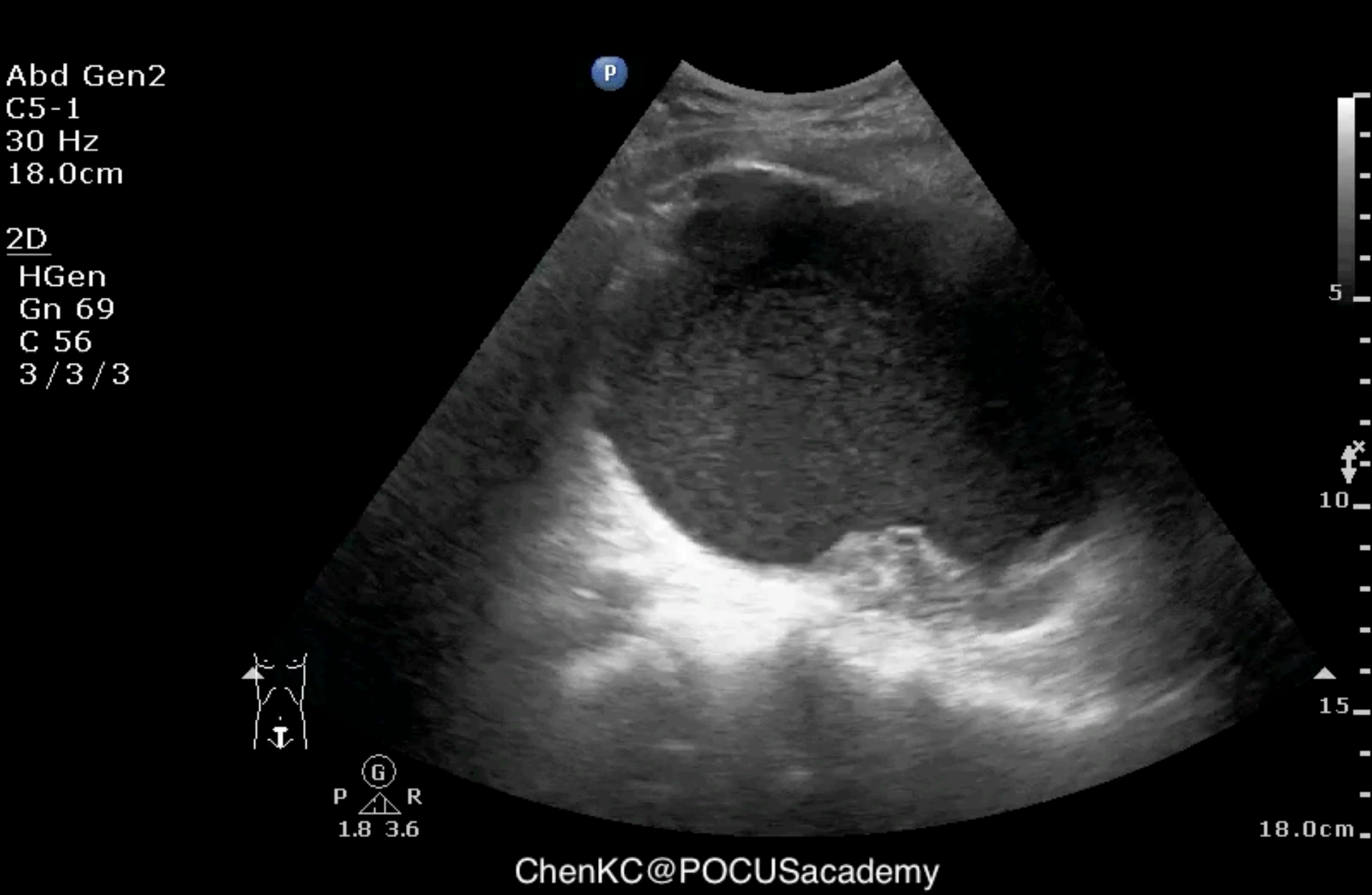

Blood clots / AUR

61M, VOMITING 5-6 TIMES FOR ONE NIGHT
CR2.13

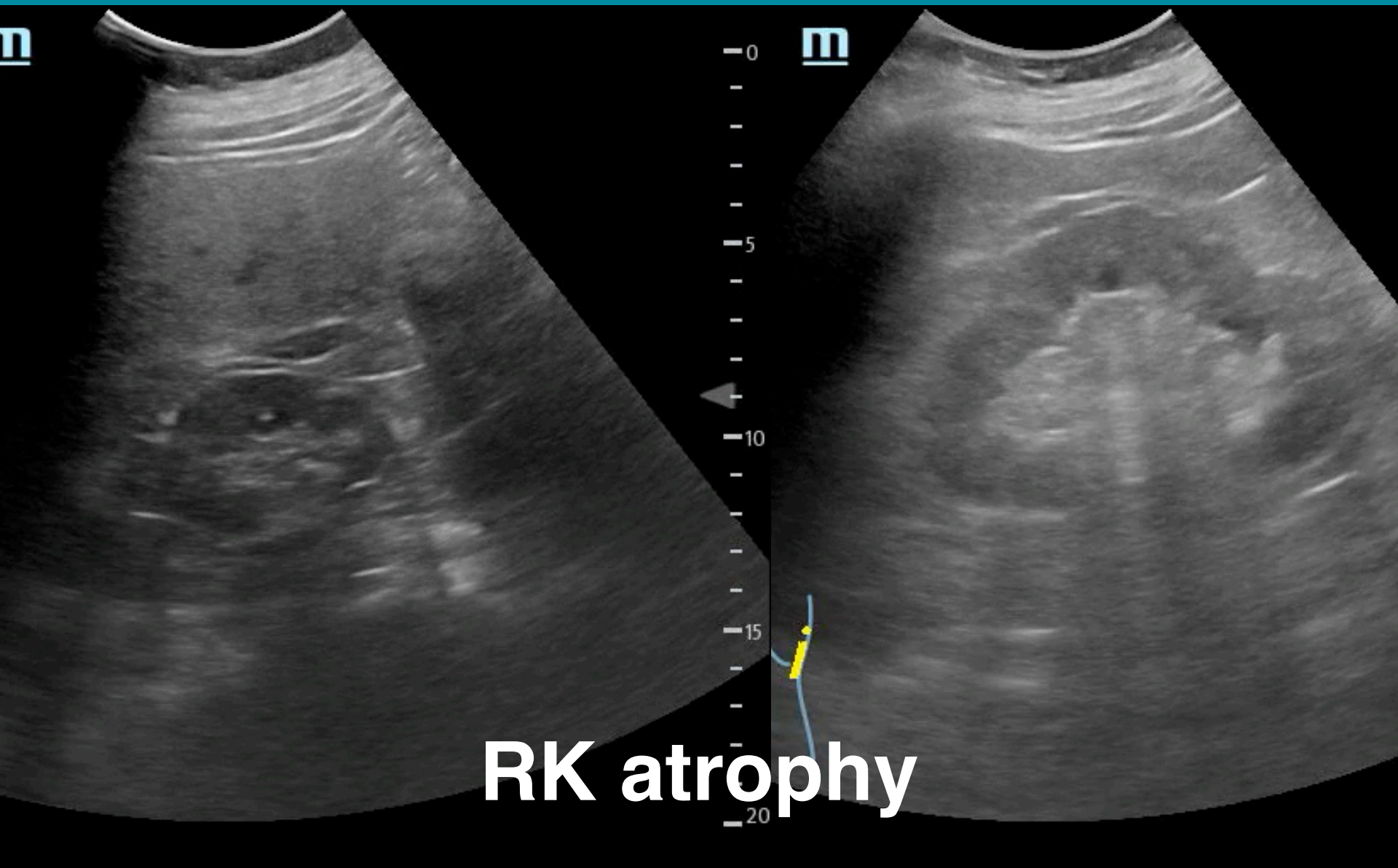

Bladder tumor/ obstruction

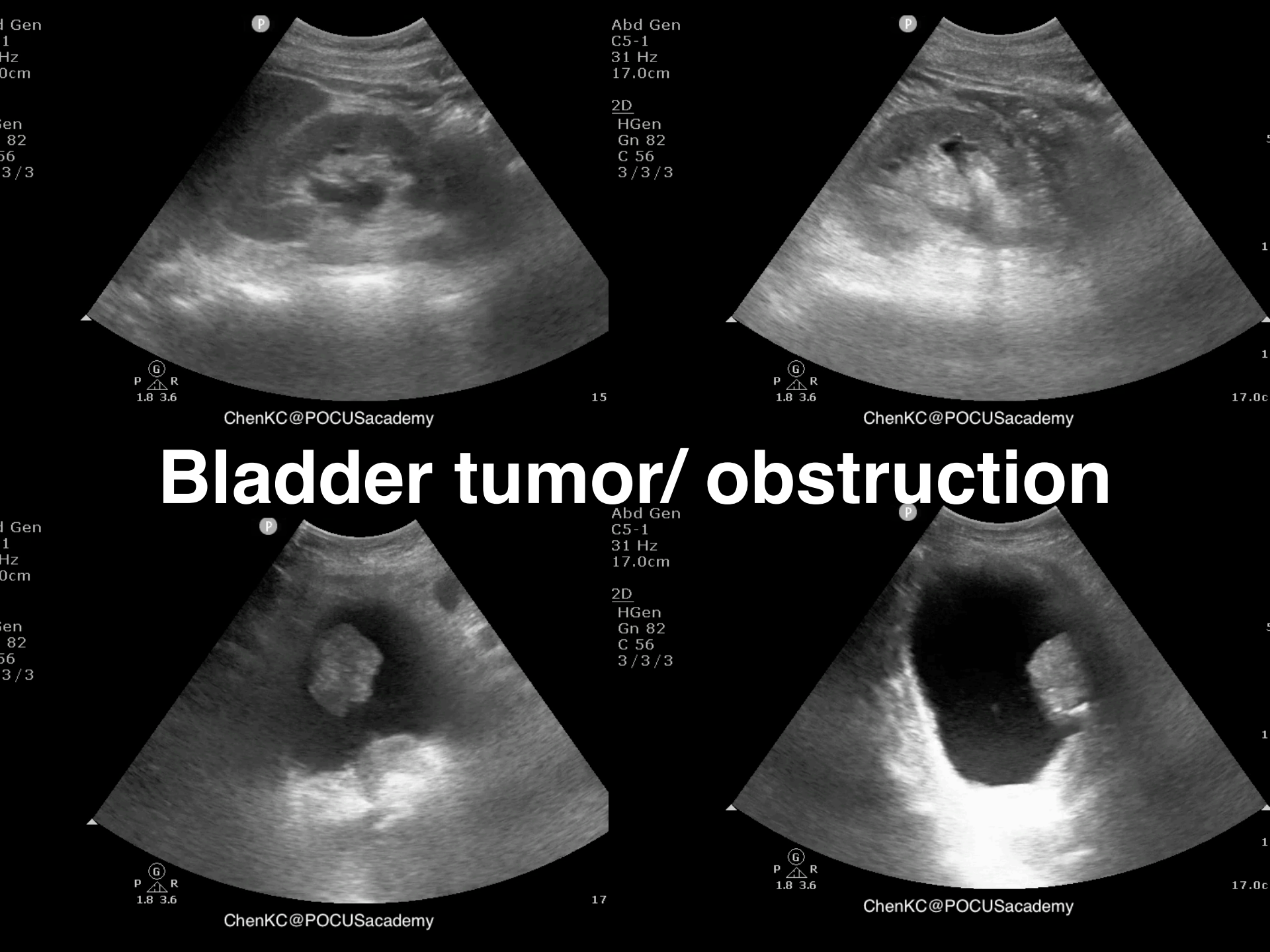

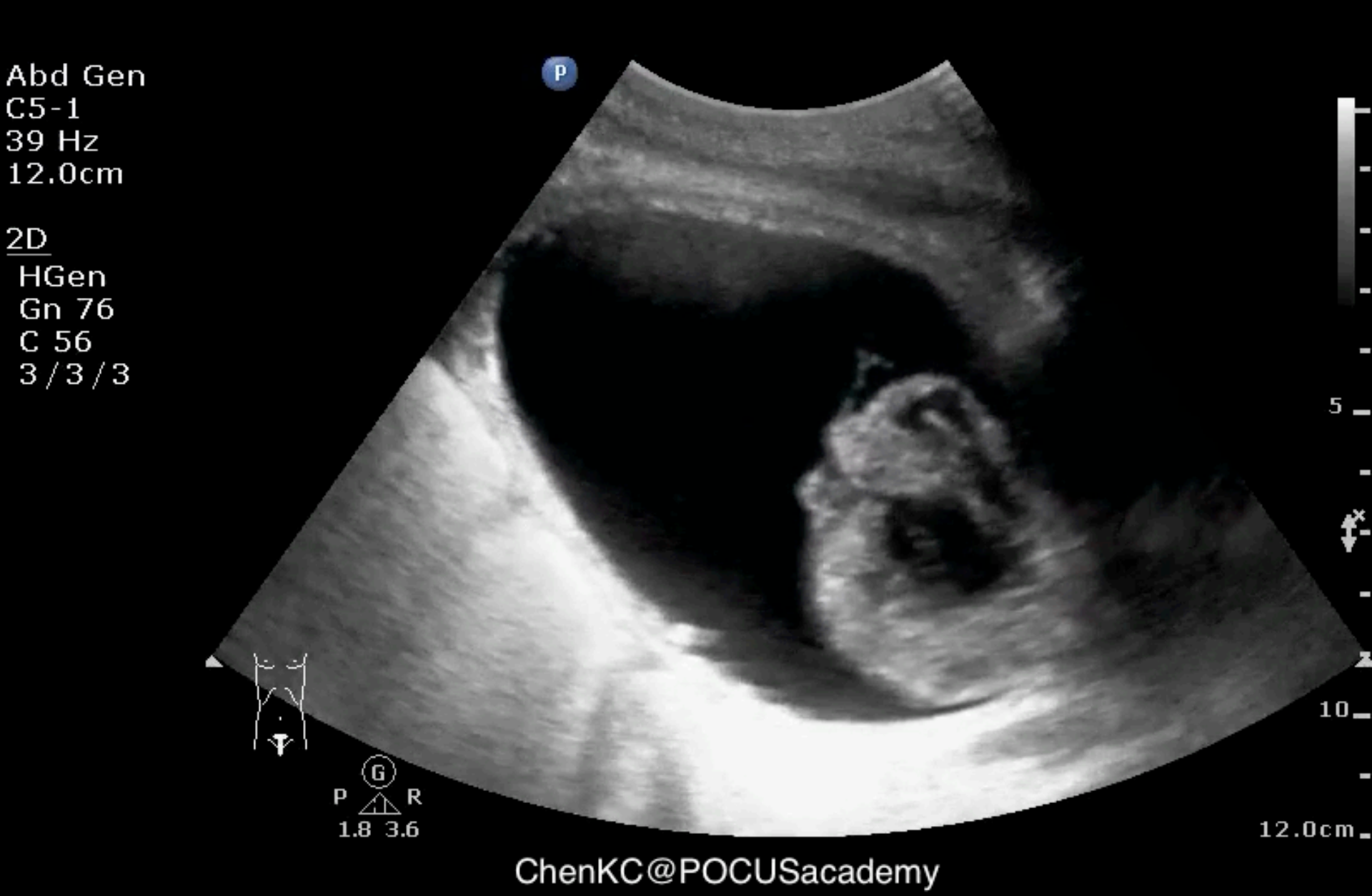

Bladder clots / AUR

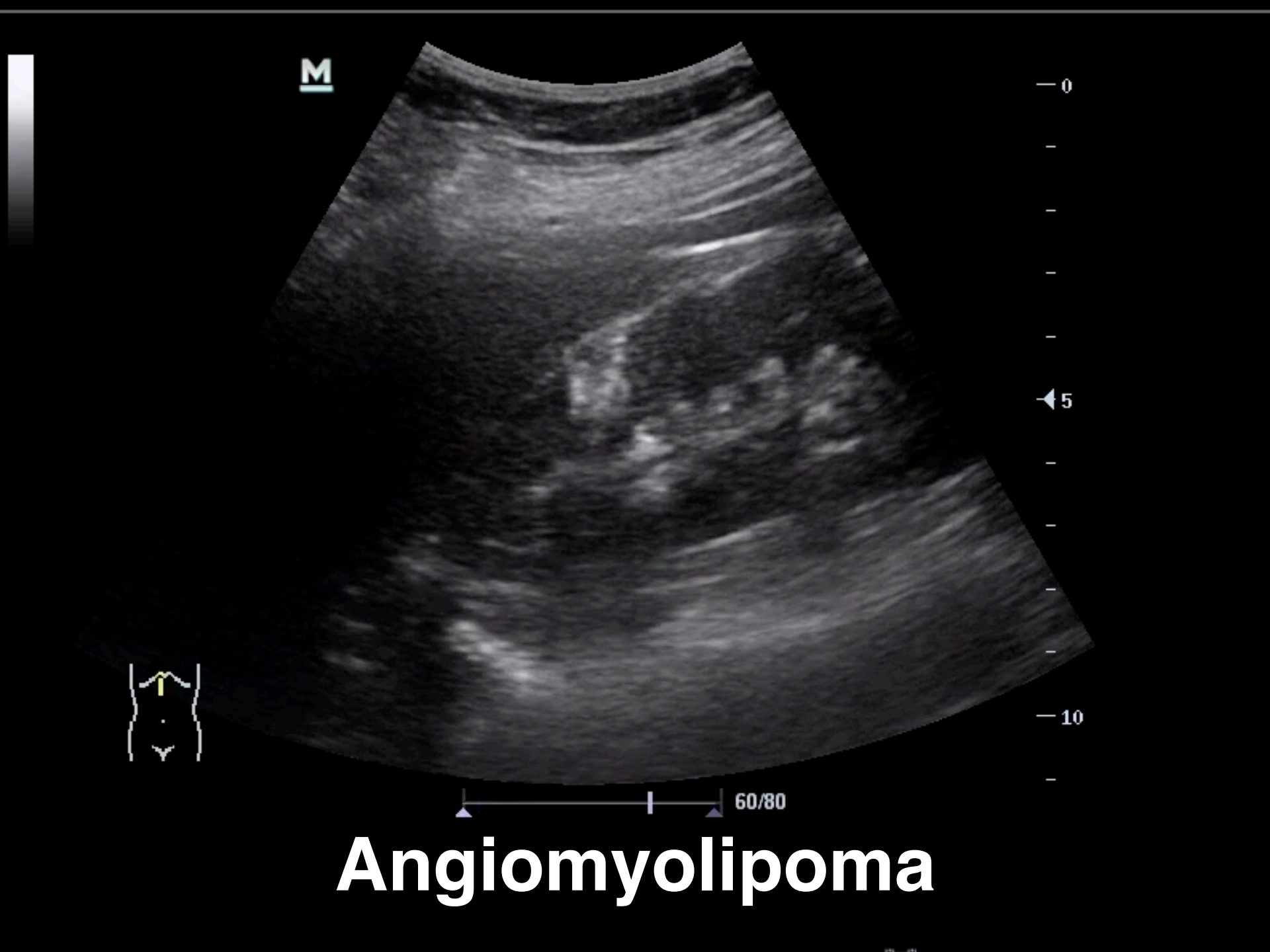

Angiomyolipoma

Bladder tumor

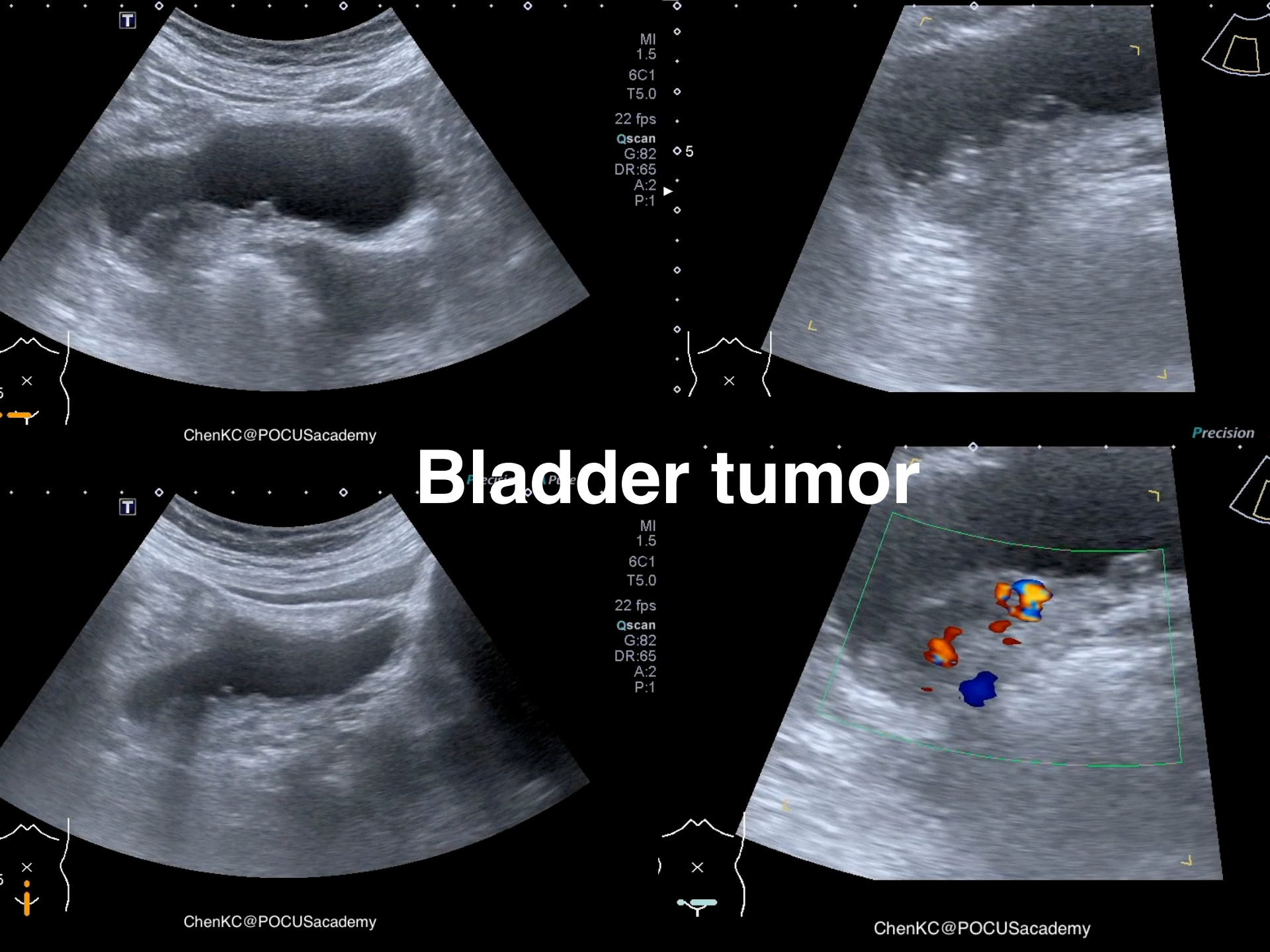

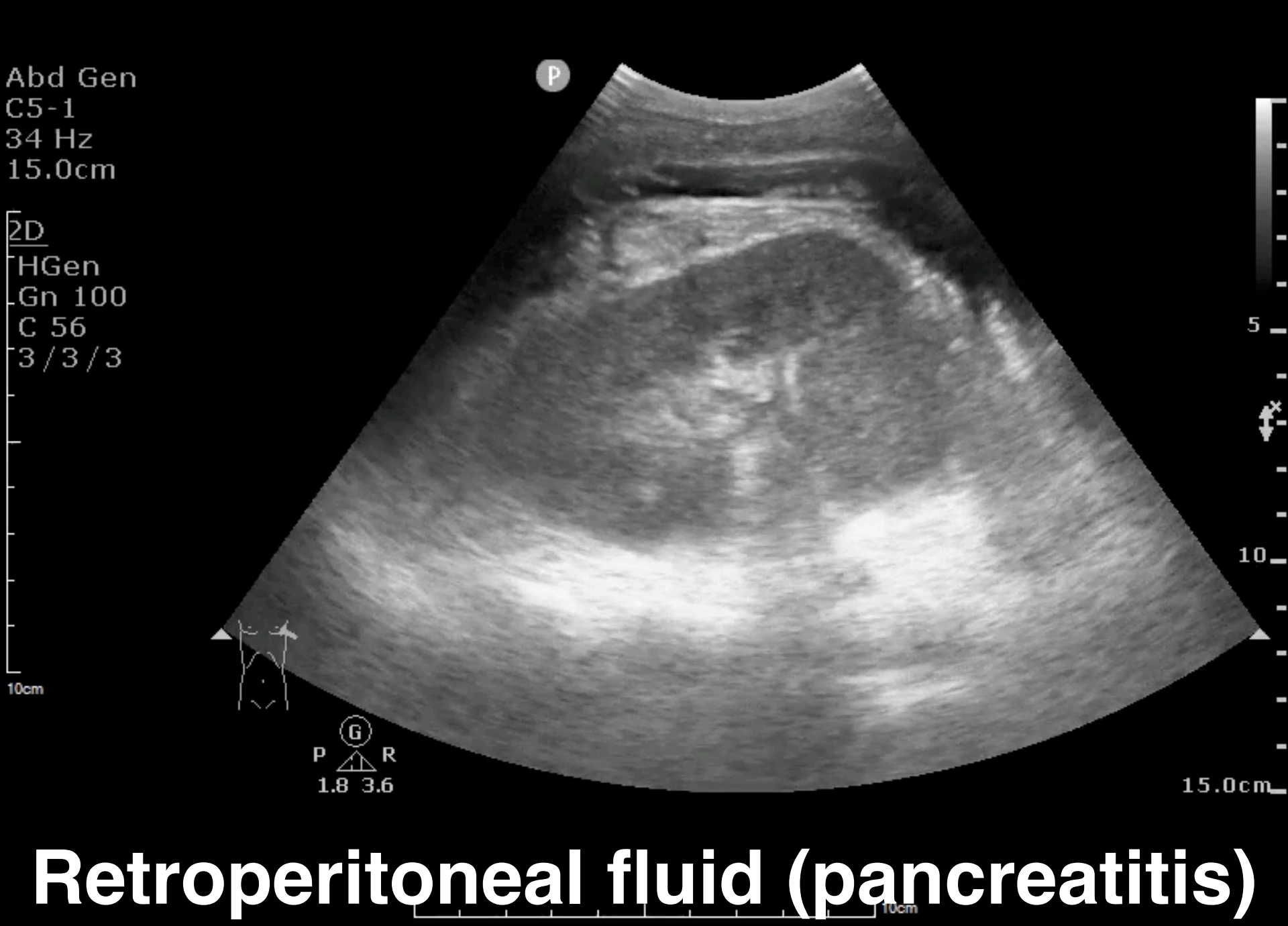

Retroperitoneal fluid (pancreatitis)

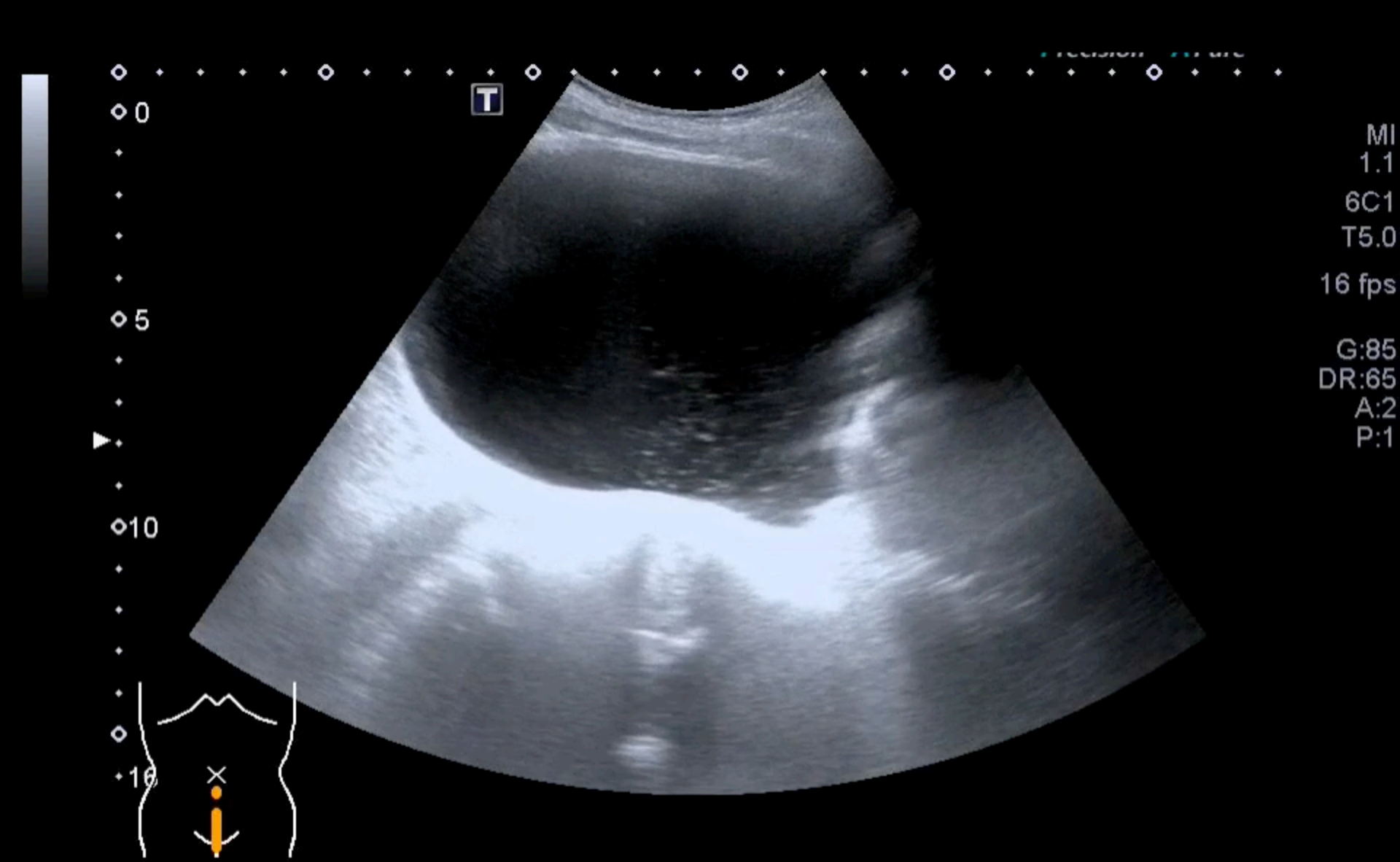

BPH / AUR

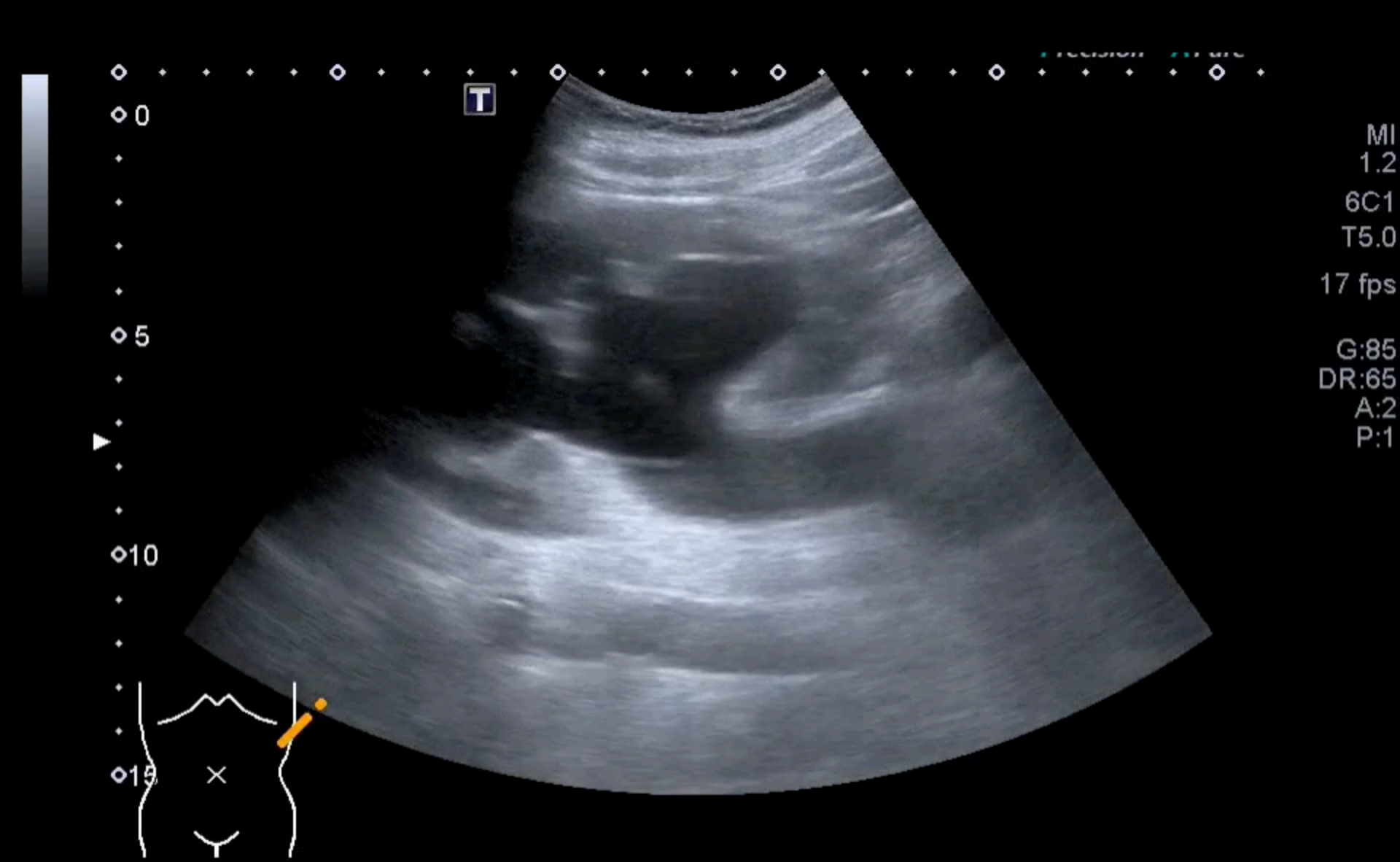

Hydronephrosis - moderate to severe

Cystitis - ketamin

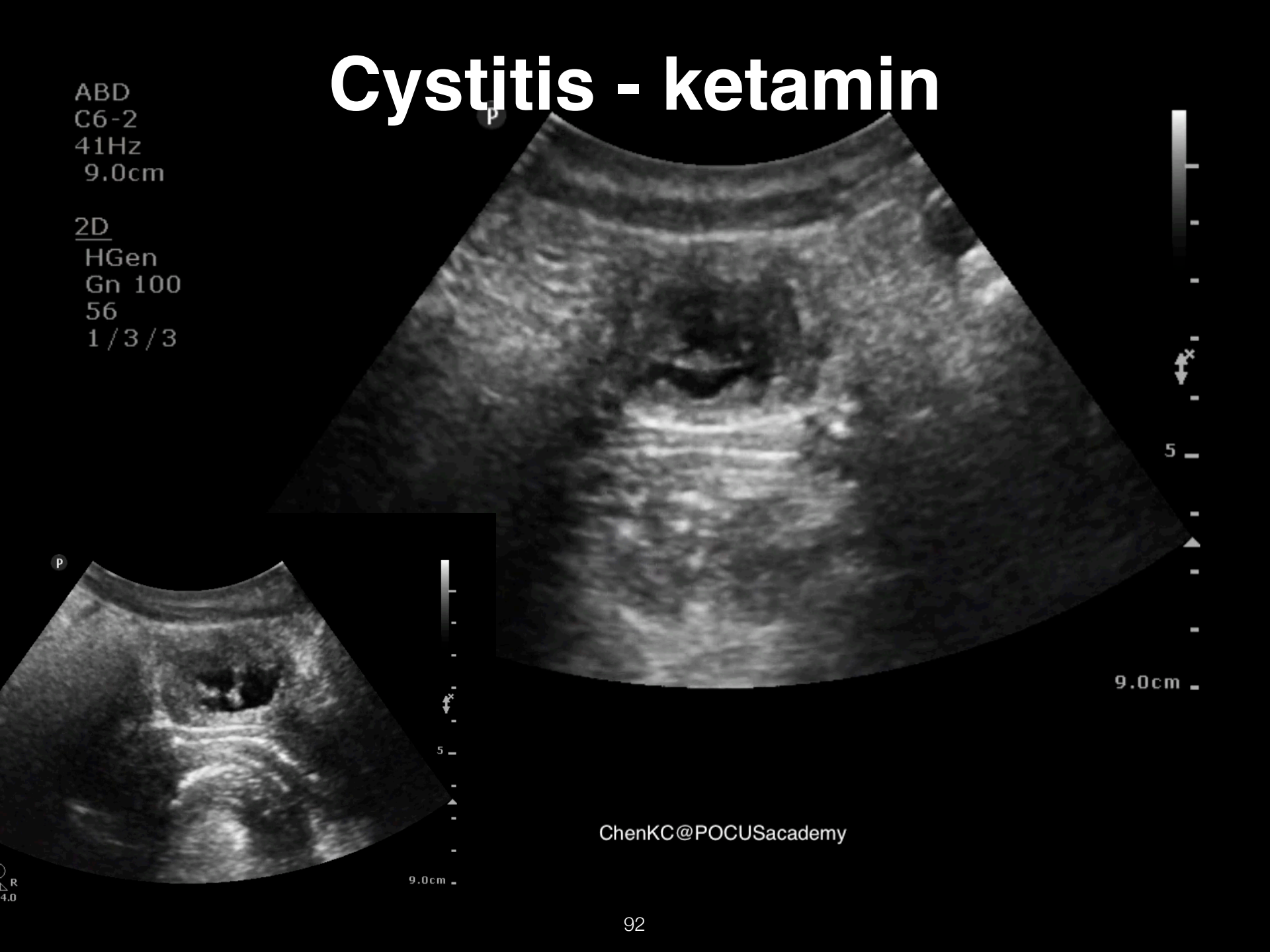

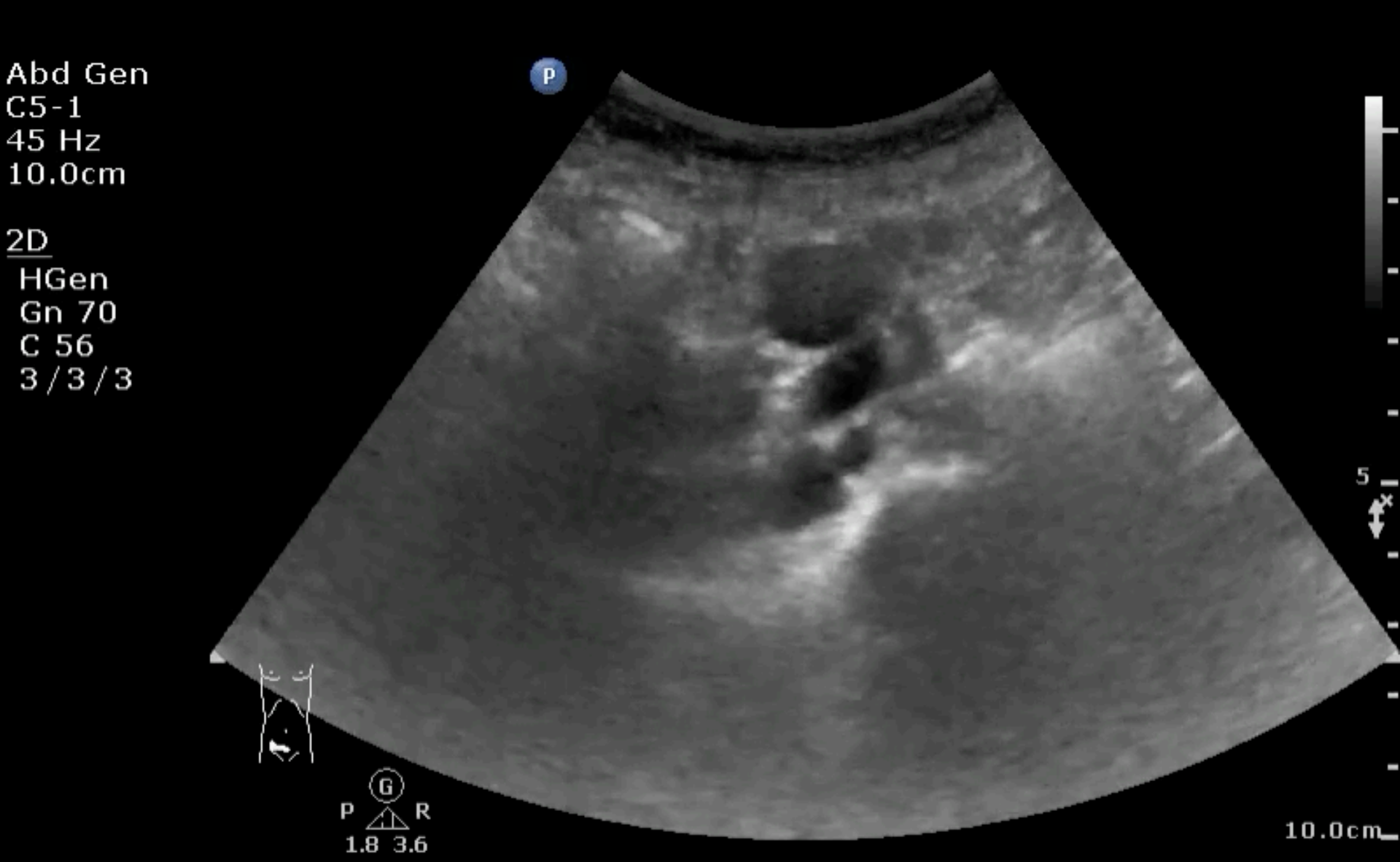

Traffic light sign

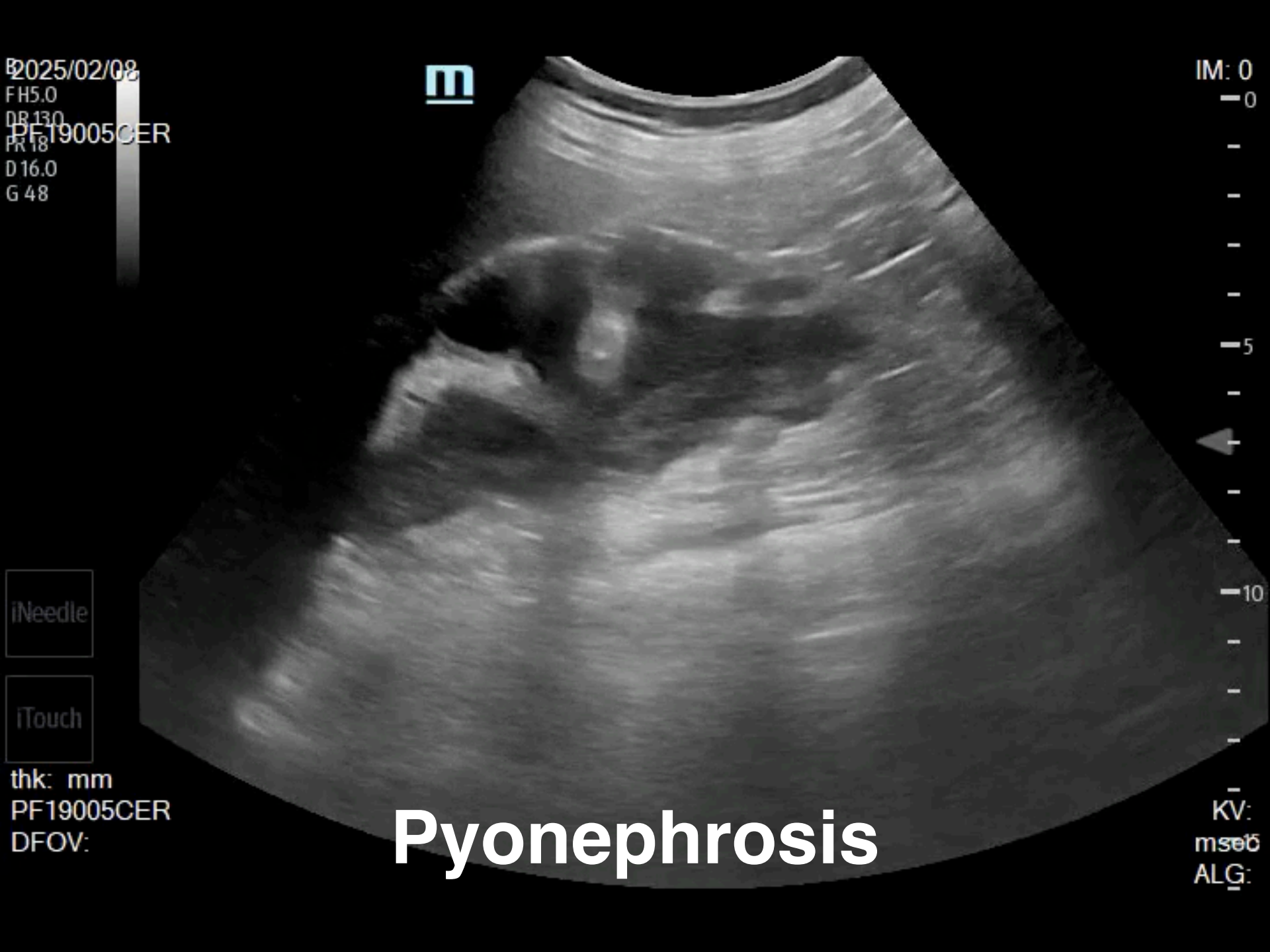

Pyonephrosis

Bladder stone

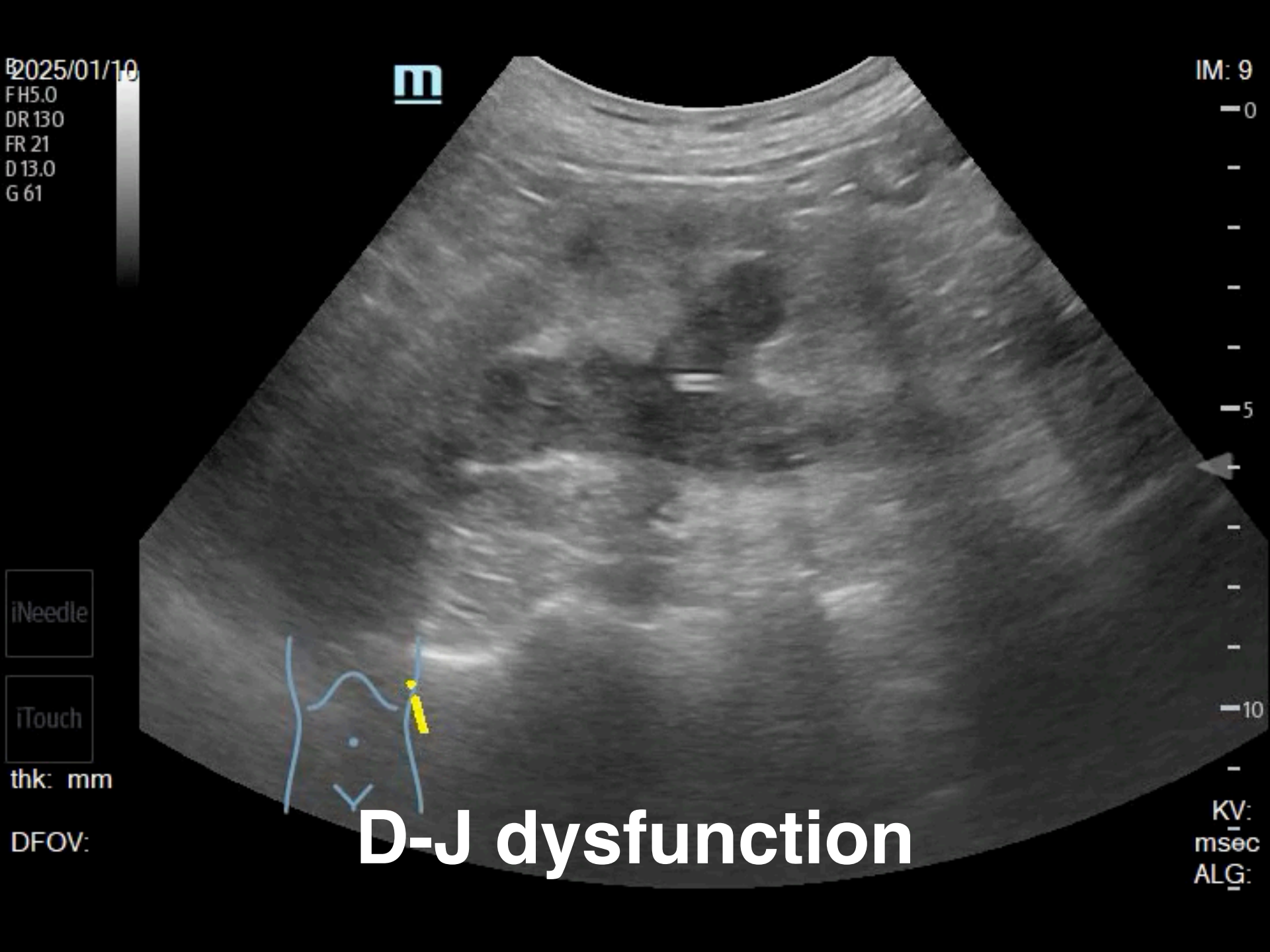

D-J dysfunction

Diverticulum / trabeculation

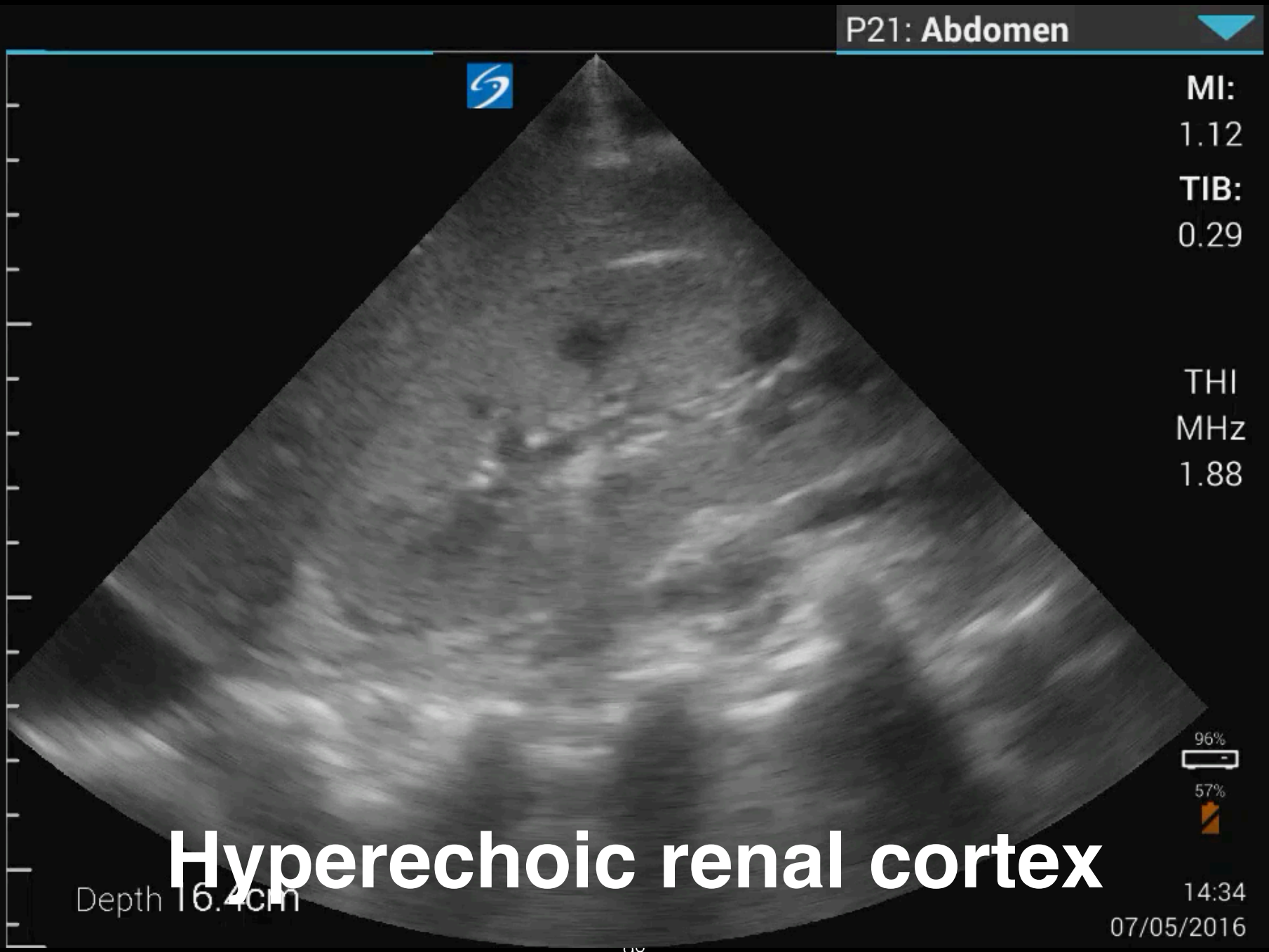

Hyperechoic renal cortex

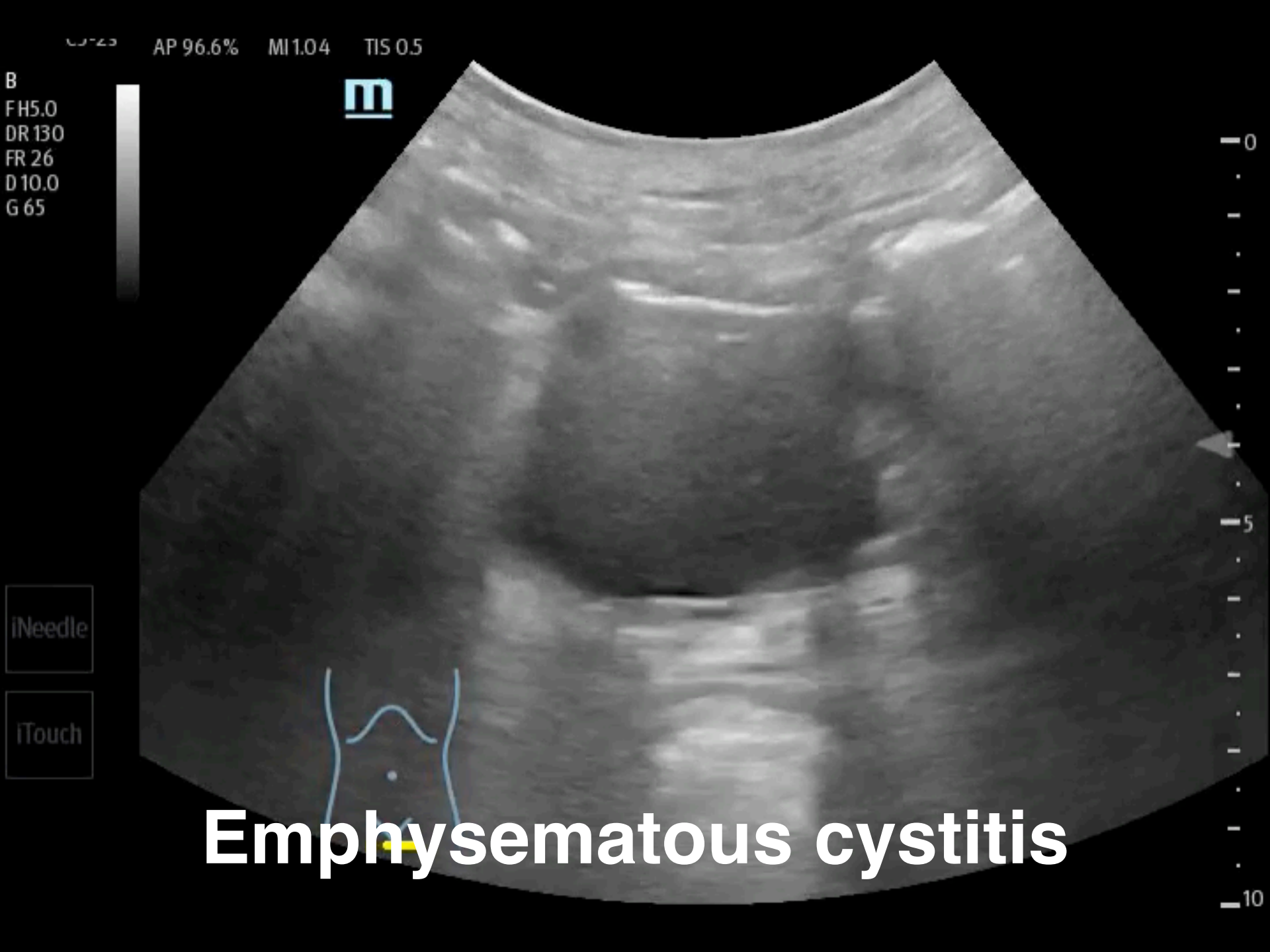

Emphysematous cystitis

Severe hydronephrosis

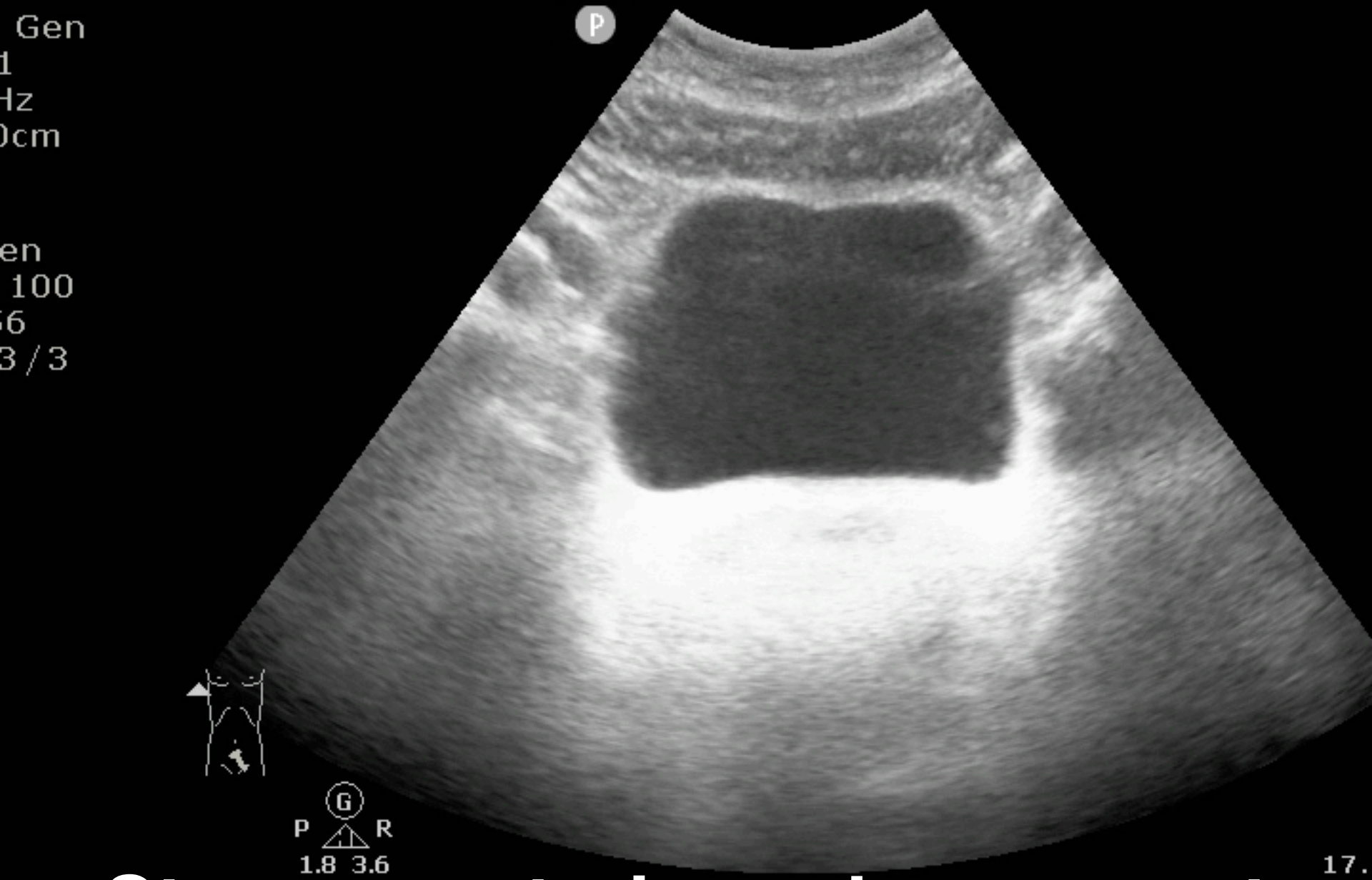

Strong posterior enhancement

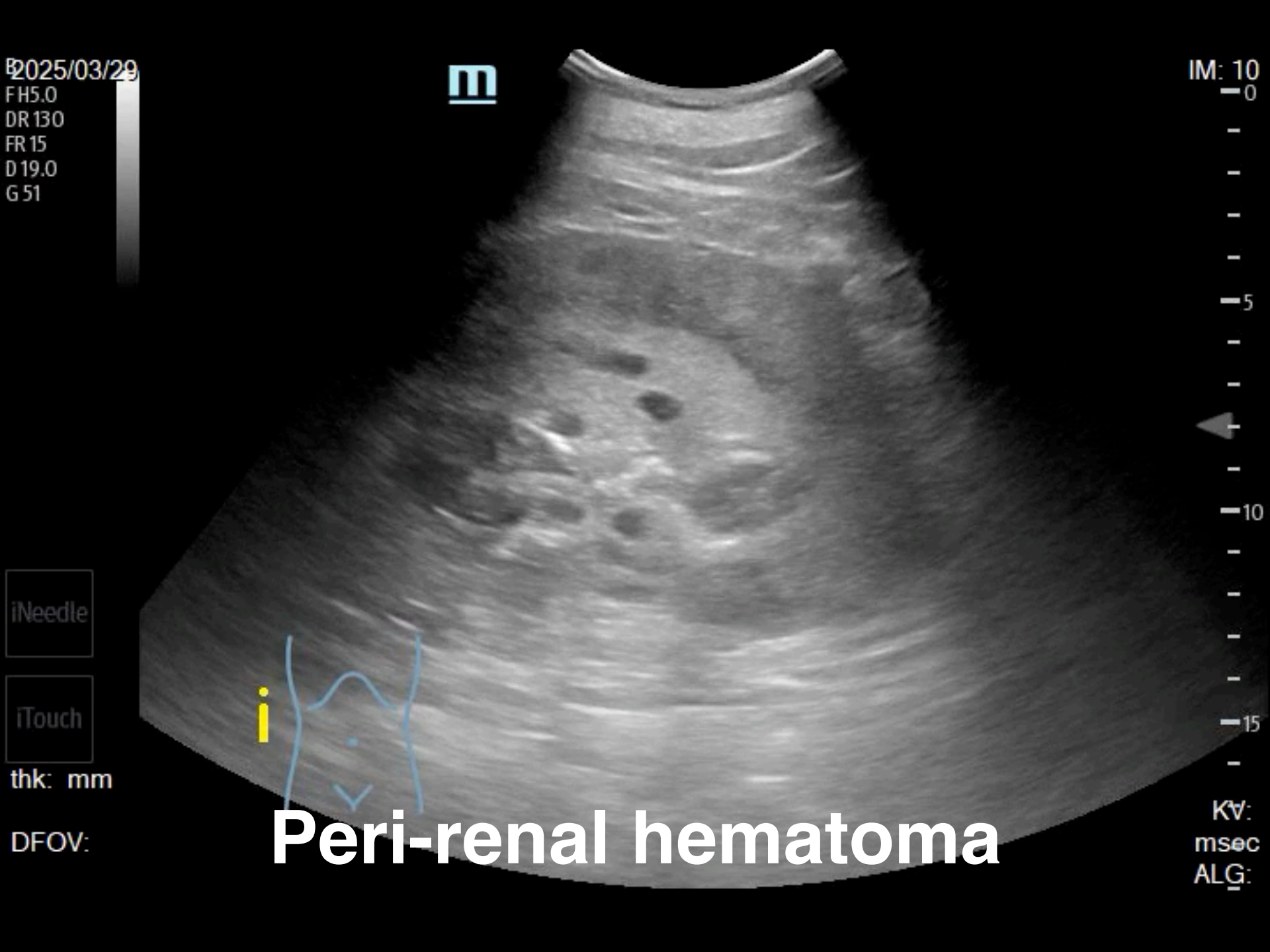
2025/03/29
FH5.0
DR 130
FR 15
D 19.0
G 51
IM: 10
0
5
10
15
iNeedle
iTouch
thk: mm
DFOV:
KV:
msec
ALG:
Peri-renal hematoma

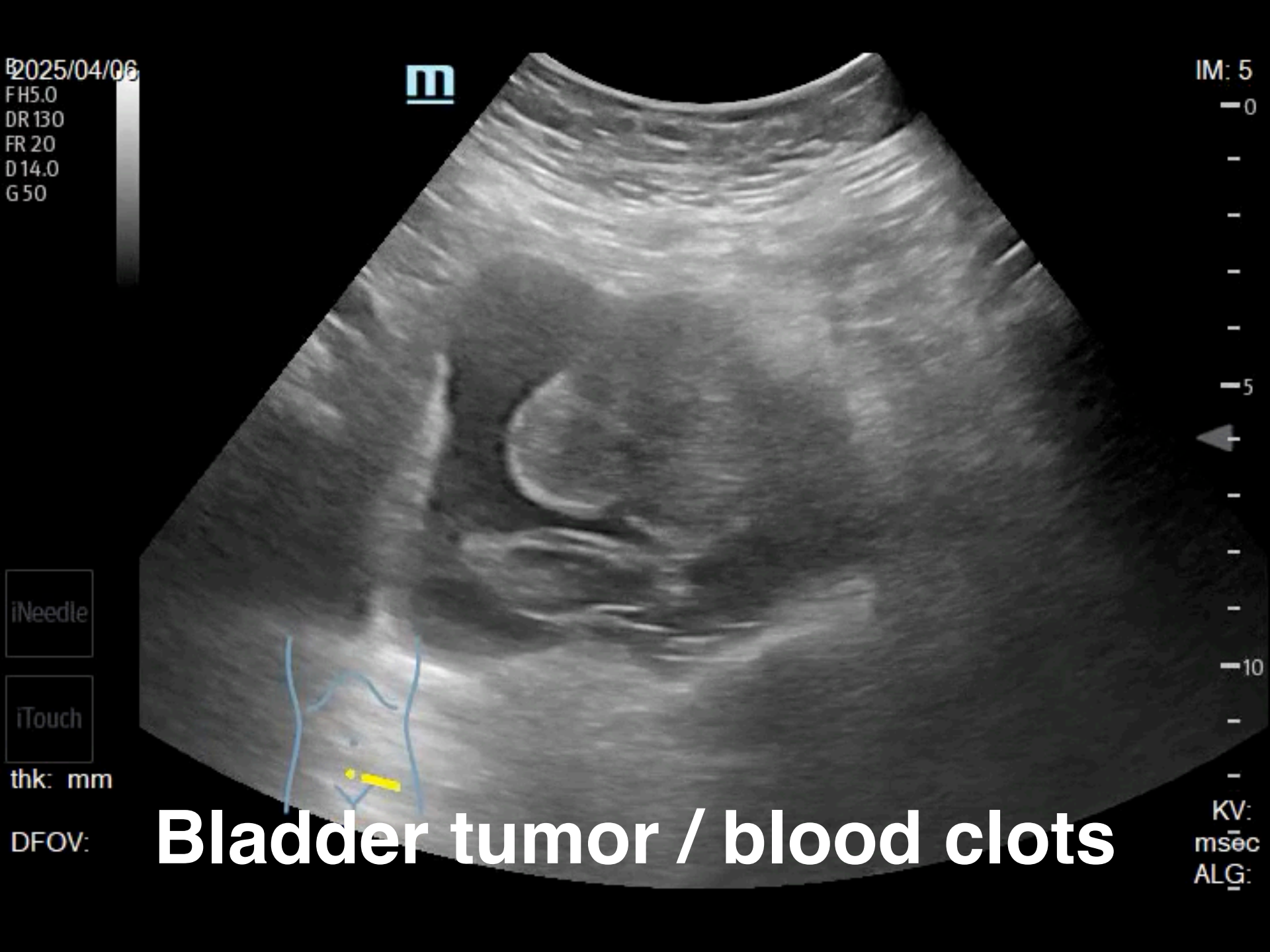
2025/04/06
FH5.0
DR 130
FR 20
D 14.0
G 50
IM: 5
0
5
10
iNeedle
iTouch
thk: mm
DFOV:
KV:
msec
ALG:
Bladder tumor / blood clots

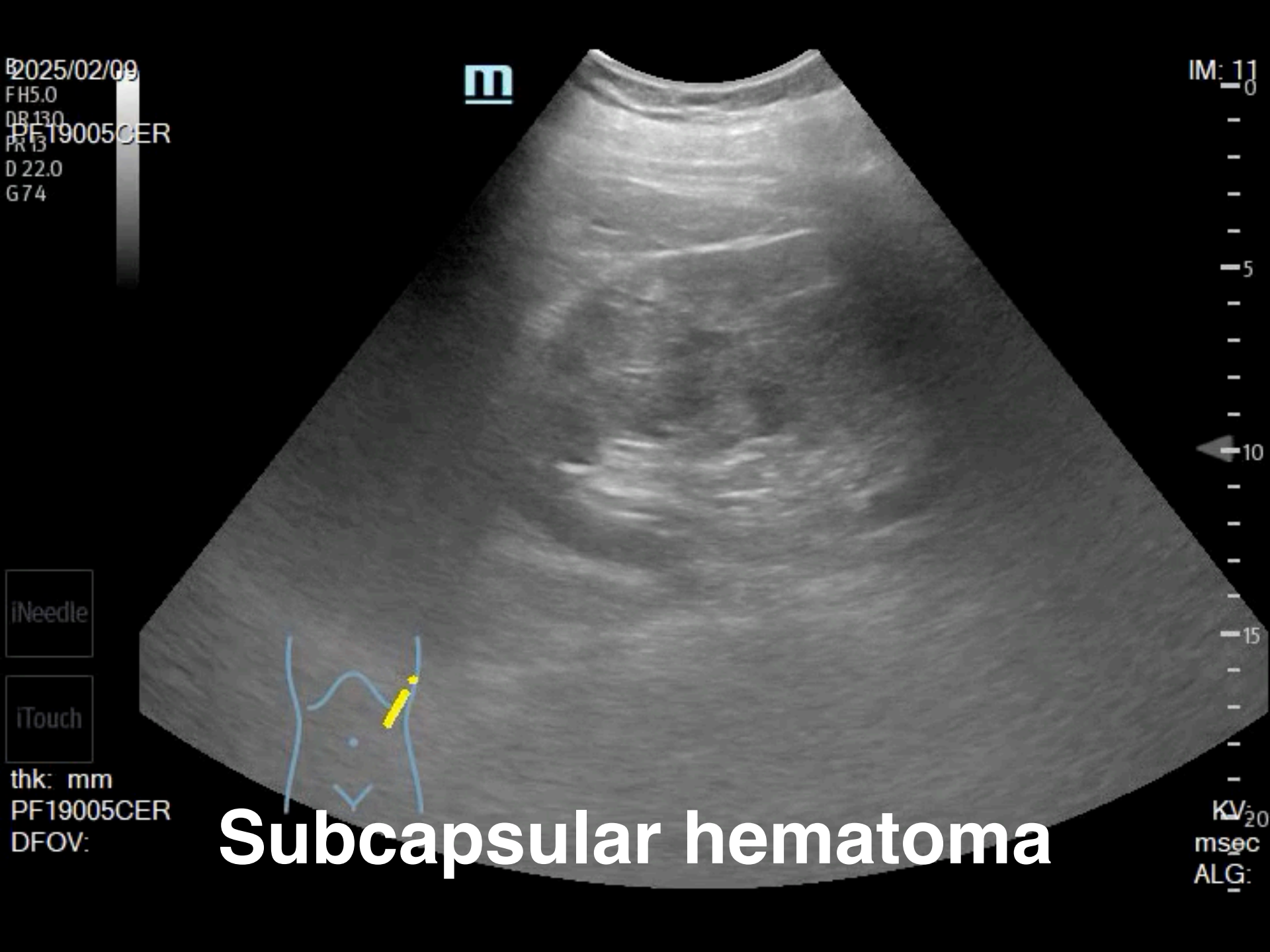

Subcapsular hematoma

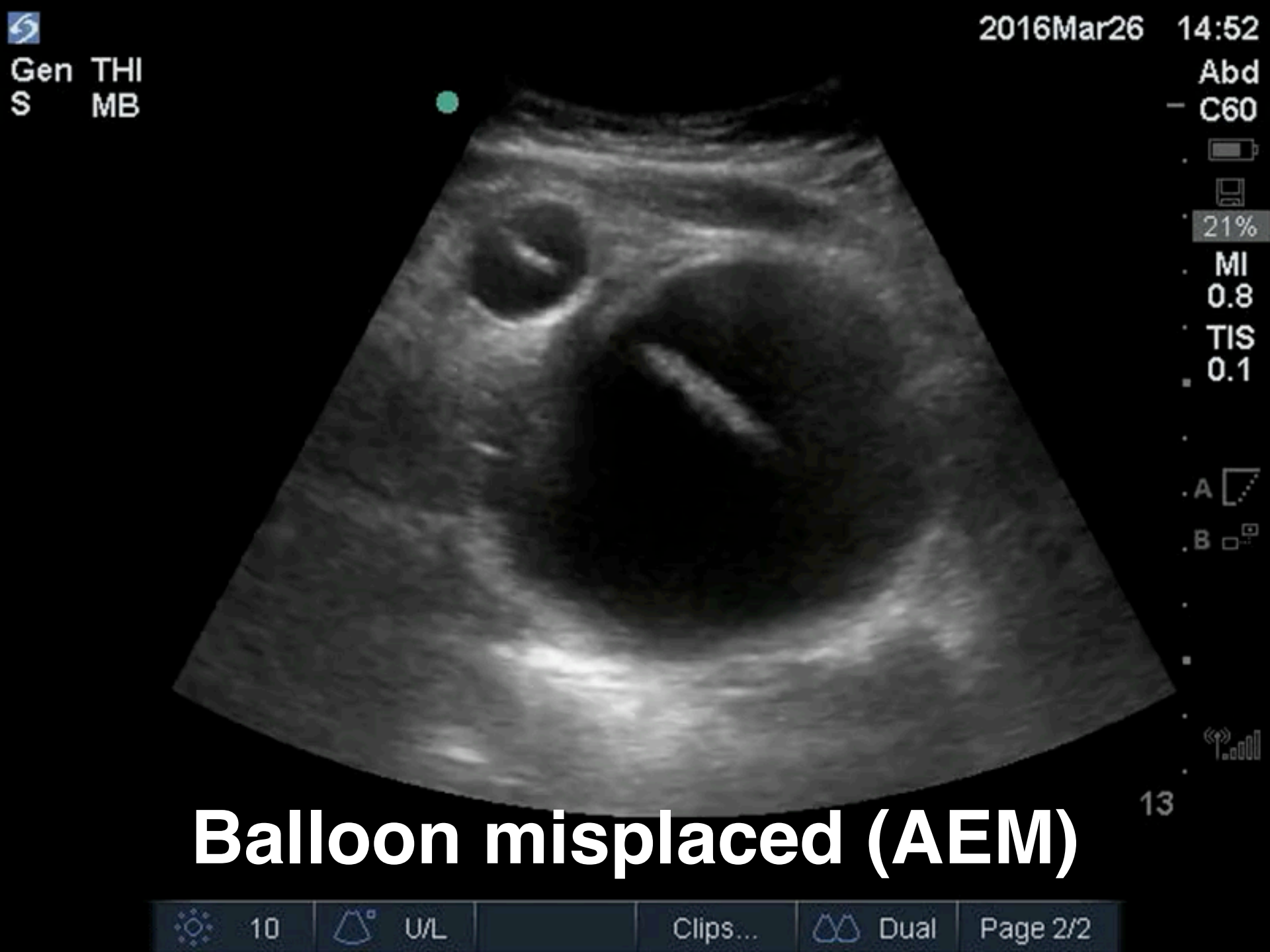

Balloon misplaced (AEM)

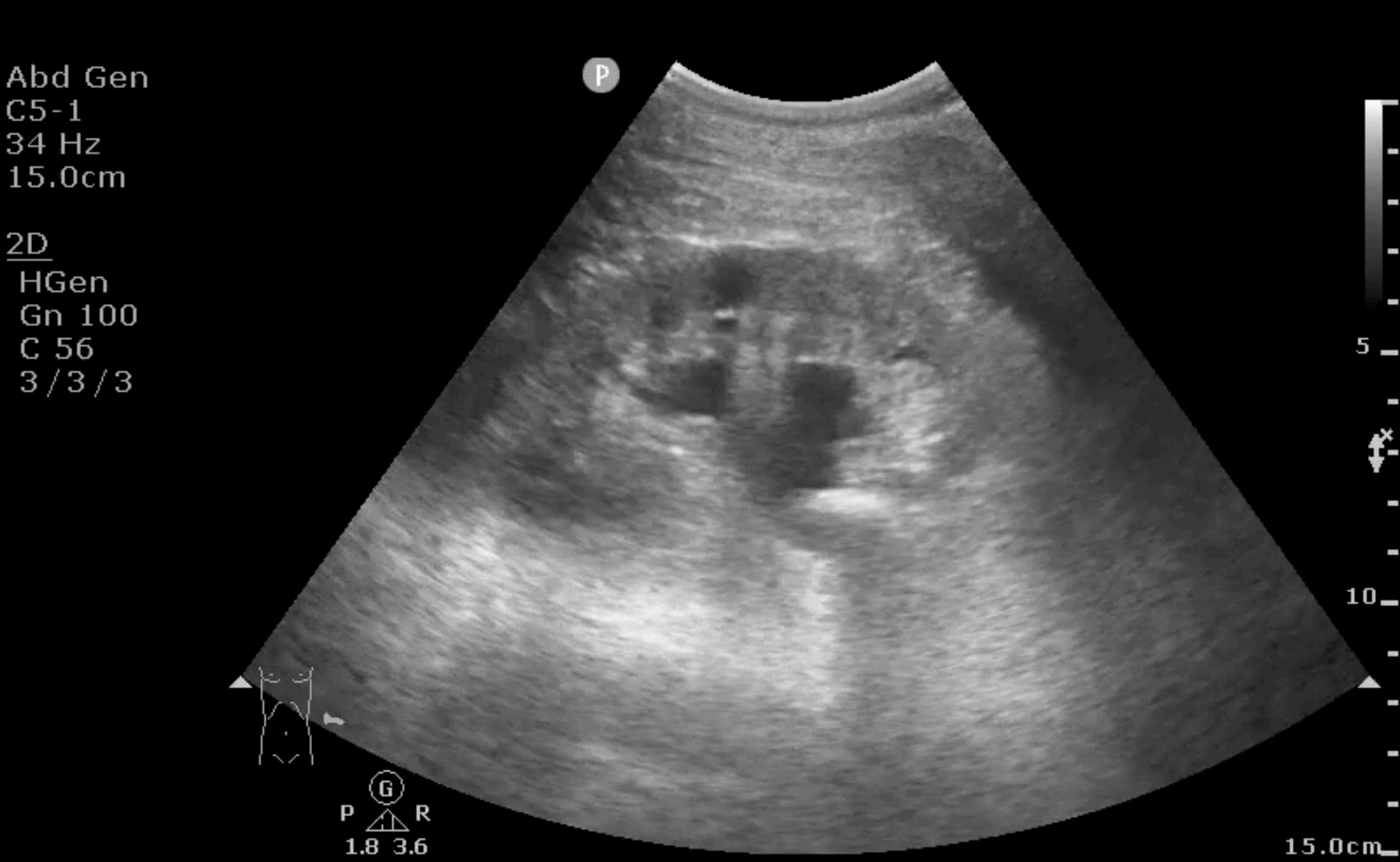

UPJ stone with hydronephrosis


P100
6C3
4.2
27fps
DR70
2DG
94
T
0
5
MI
0.7
TIS
0.2
TIB
0.2
TIC
0.7
Free 8

UVJ stone

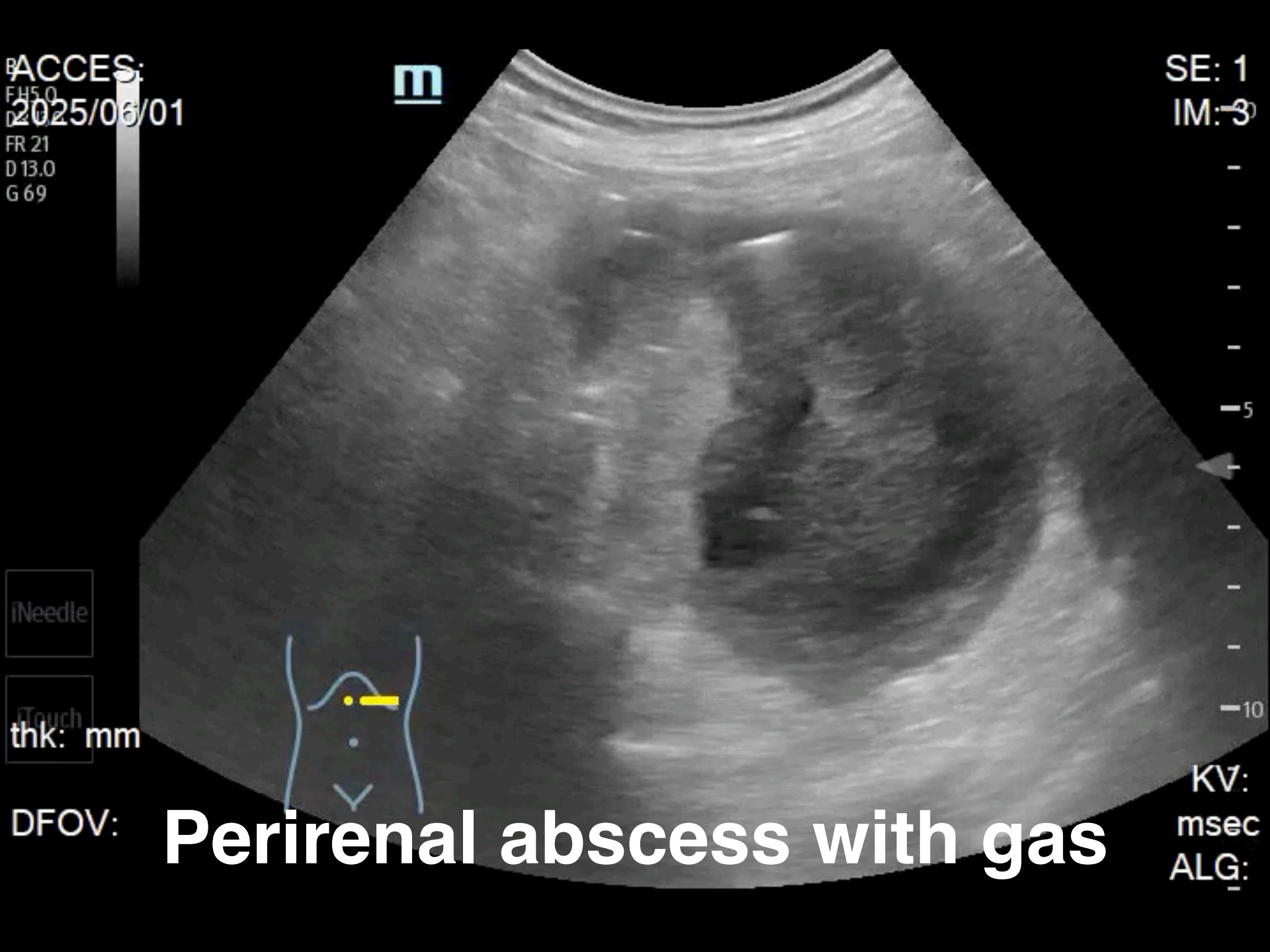
ACCES:
2025/06/01
FR 21
D 13.0
G 69
SE: 1
IM: 3
iNeedle
iTouch
thk: mm
DFOV:
KV:
msec
ALG:
Perirenal abscess with gas

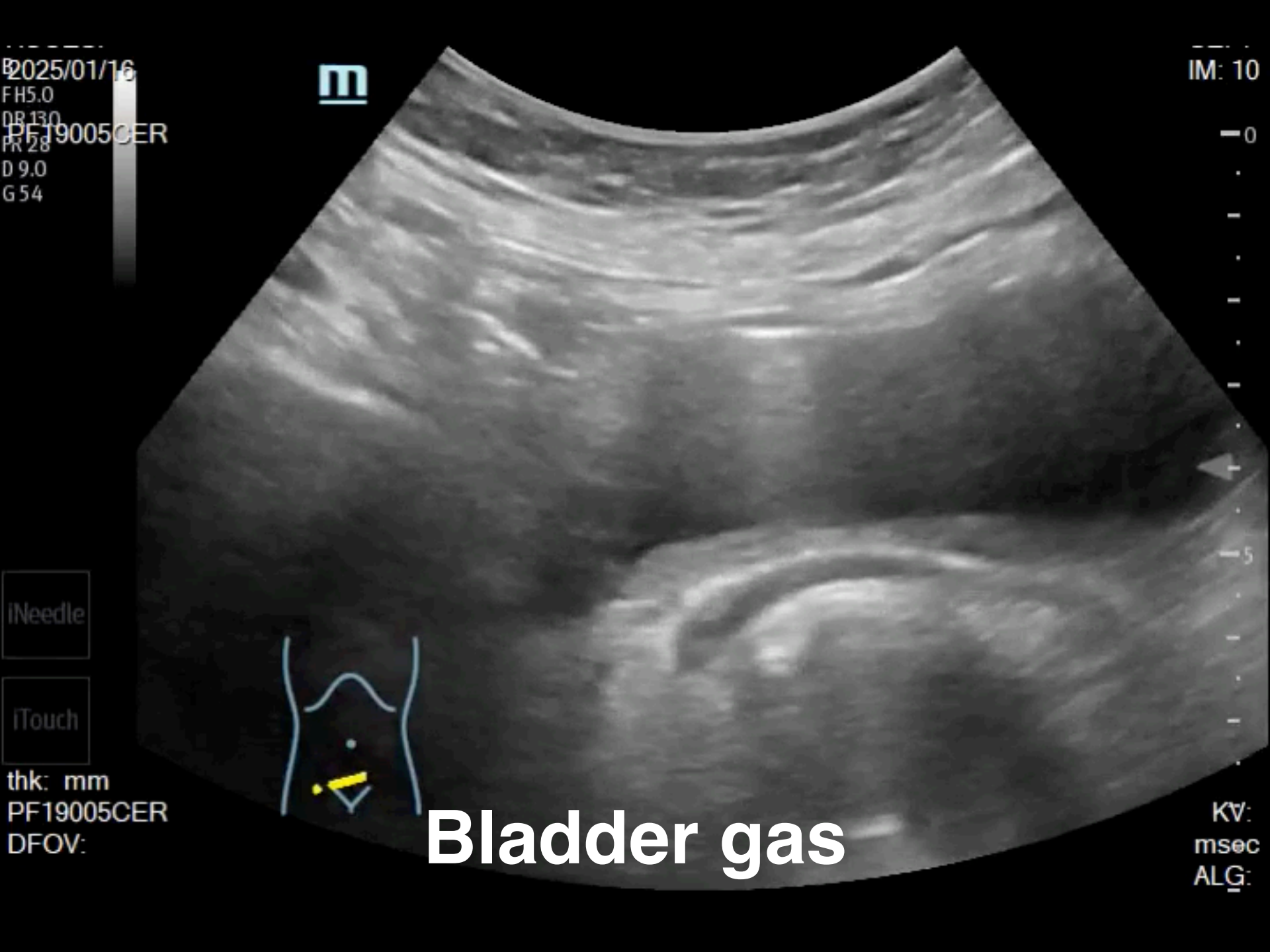
2025/01/16
FH5.0
DR 13.0
PR 28
D 9.0
G 54
PF19005CER
IM: 10
iNeedle
iTouch
thk: mm
PF19005CER
DFOV:
KV:
msec
ALG:
Bladder gas

UPJ stone / hydronephrosis

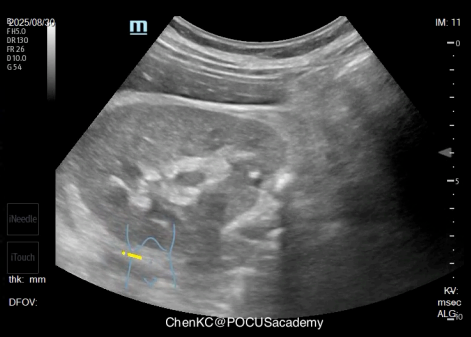

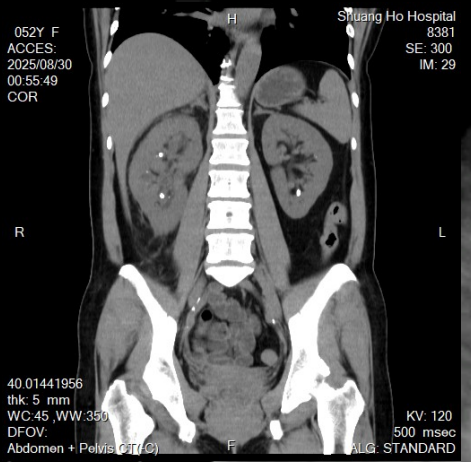

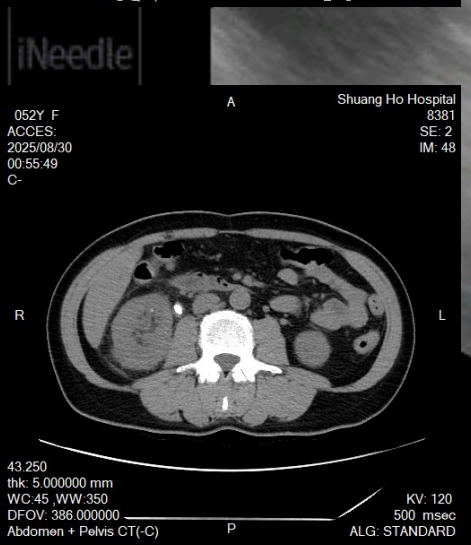

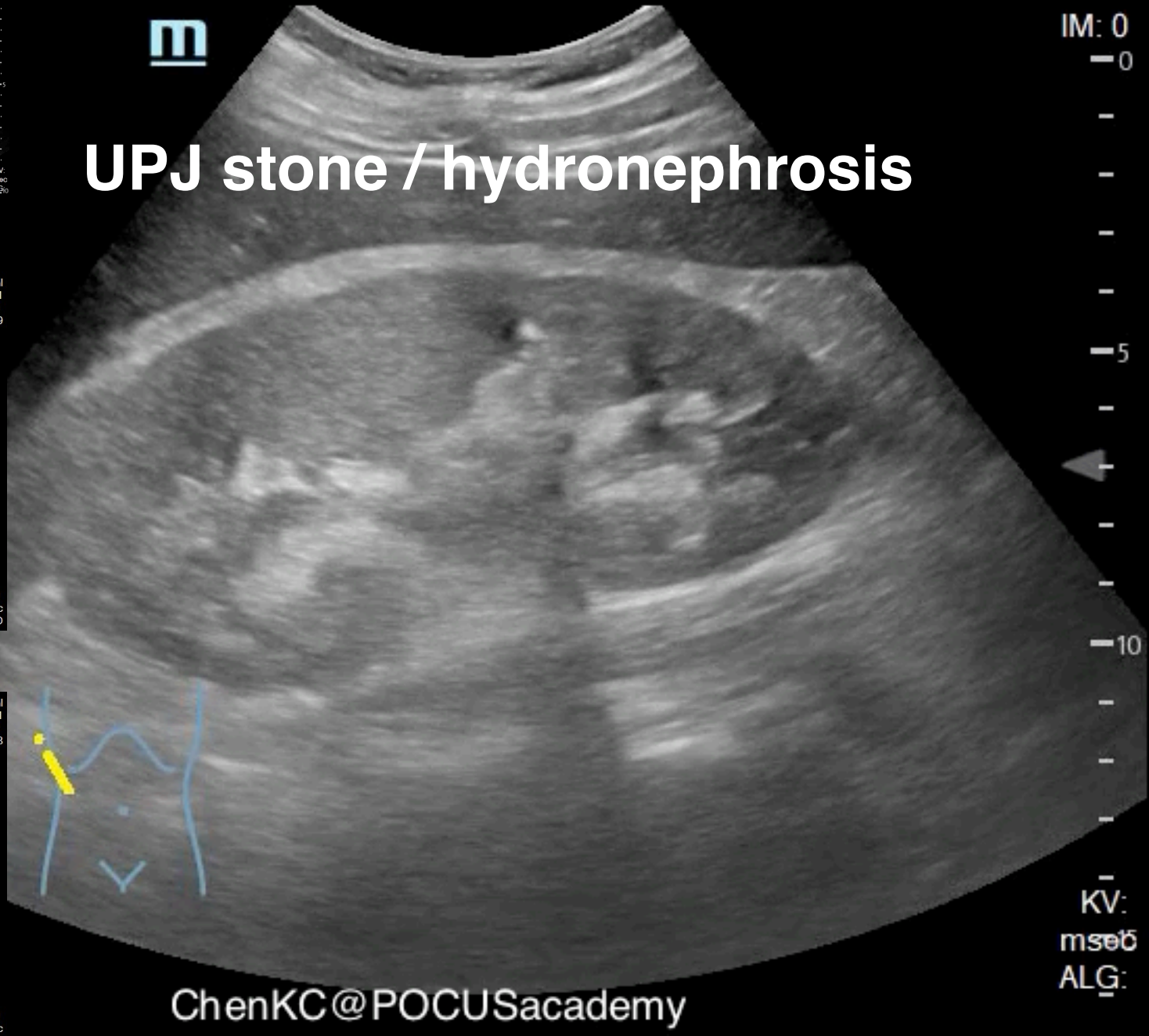


Staghorn stone
ChenKC@POCUSacademy
ChenKC@POCUSacademy
IM: 0
IM: 3
iNeedle
iTouch
thk: mm
DFOV:
KV
msec
ALG:

Kidney transplant