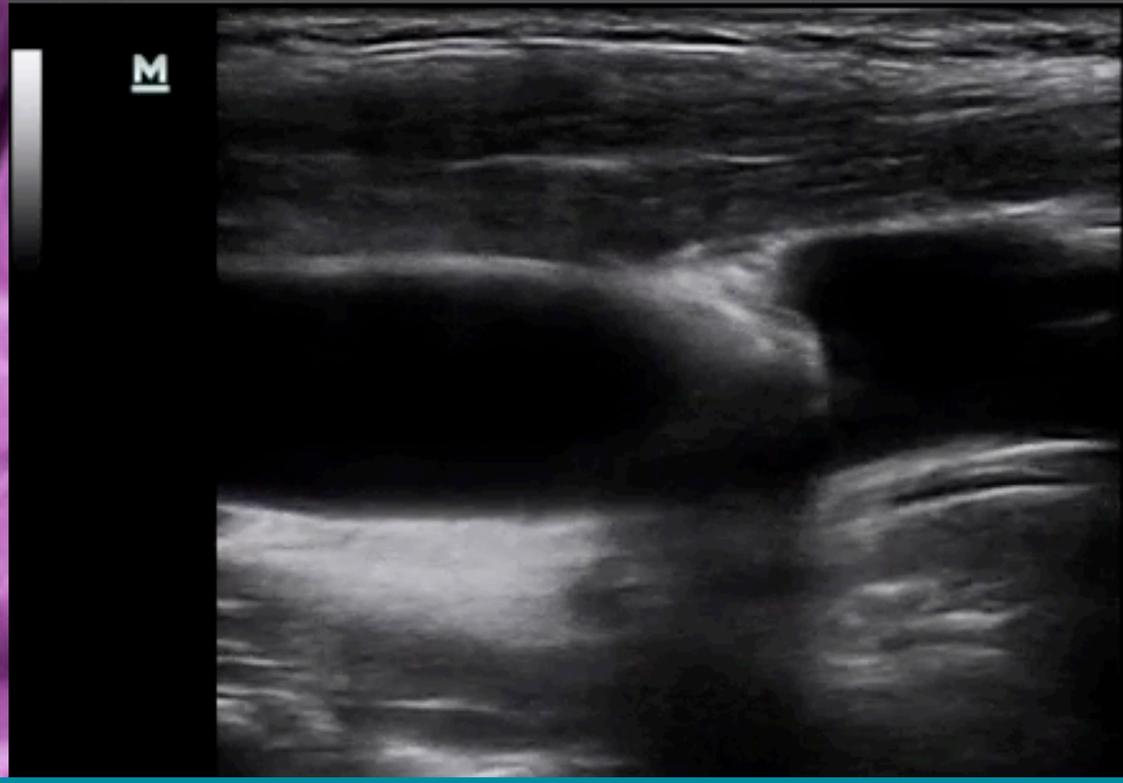

Master needling & CVC

陳國智醫師 雙和醫院急診醫學科

juice119@gmail.com

POCUSacademy.com

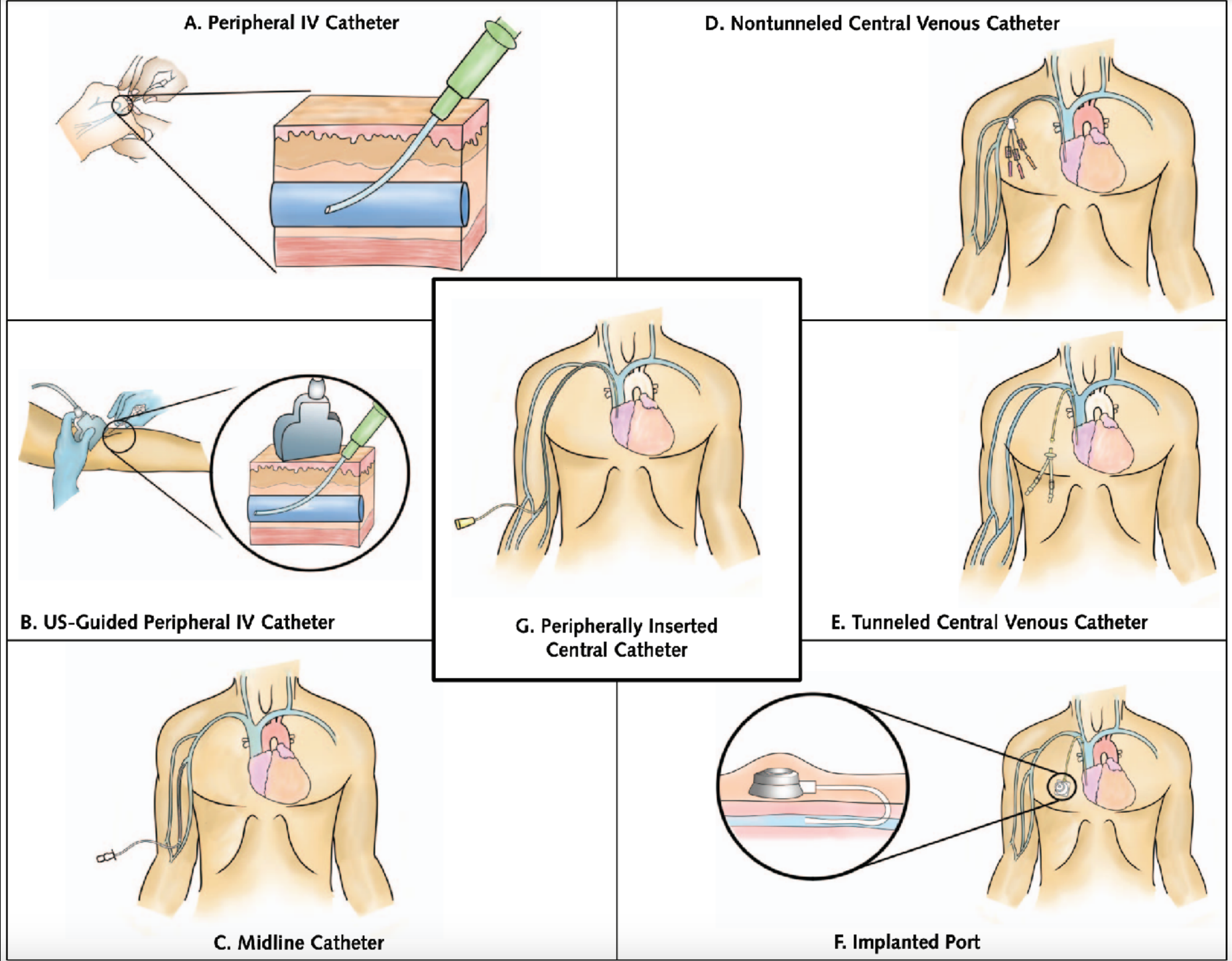

Annals of Internal Medicine SUPPLEMENT

The Michigan Appropriateness Guide for Intravenous Catheters (MAGIC): Results From a Multispecialty Panel Using the RAND/UCLA Appropriateness Method

Vineet Chopra, MD, MSc; Scott A. Flanders, MD; Sanjay Saint, MD, MPH; Scott C. Woller, MD; Naomi P. O'Grady, MD; Nasia Safdar, MD, PhD; Scott O. Trerotola, MD; Rajiv Saran, MD, PhD; Nancy Moureau, BSN, RN; Stephen Wiseman, PharmD; Mauro Pittiruti, MD; Elie A. Akl, MD, MPH, PhD; Agnes Y. Lee, MD, MSc; Anthony Counsey, MD; Lakshmi Swaminathan, MD; Jack LeDonne, MD; Carol Becker, MHSA; Sarah L. Krein, PhD, RN; and Steven J. Bernstein, MD, MPH

D. Nontunneled Central Venous Catheter

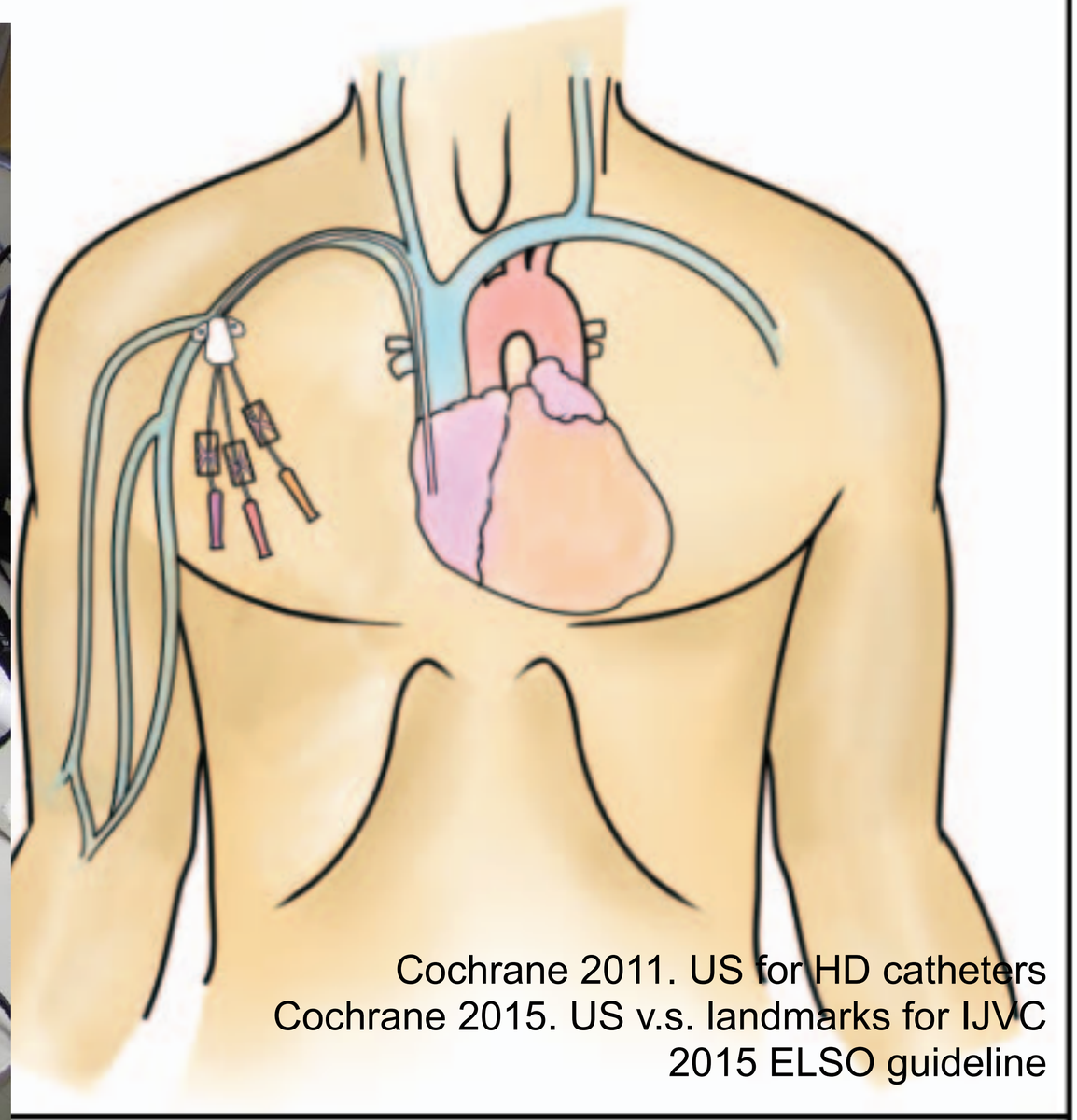

Cochrane 2011. US for HD catheters
Cochrane 2015. US v.s. landmarks for IJVC
2015 ELSO guideline

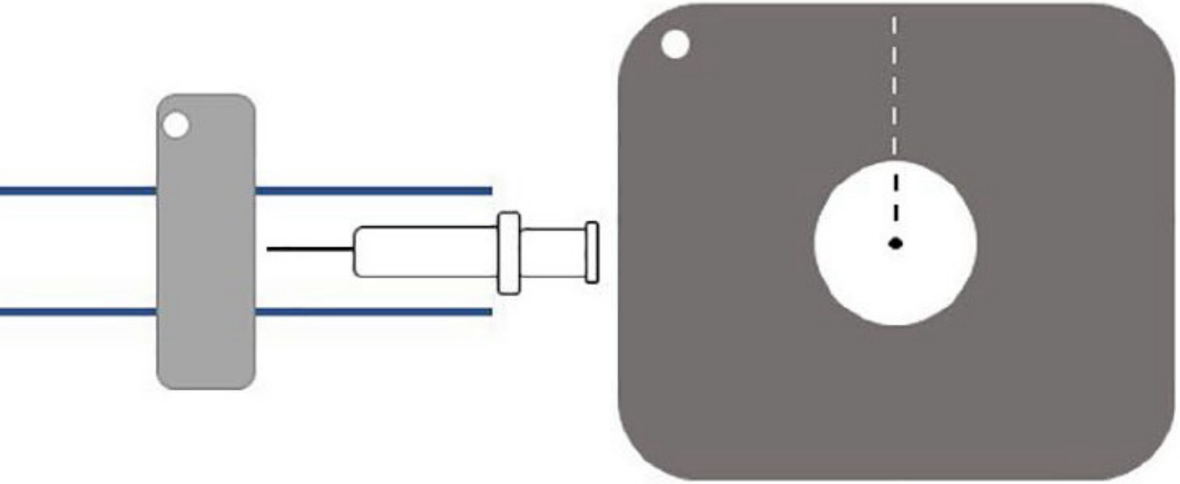

Short axis + out-of-plane technique - SA-OP

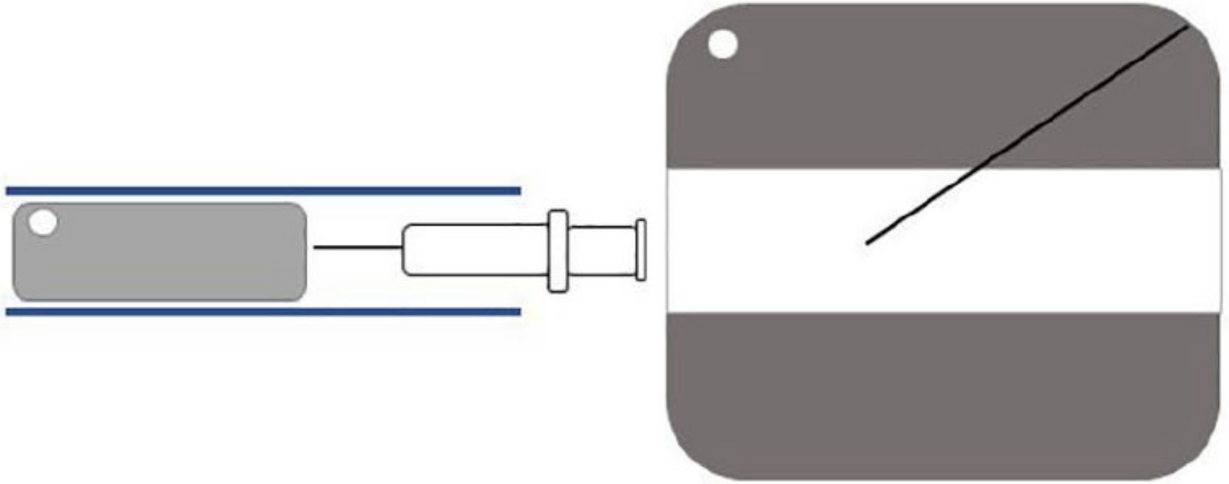

Long axis + in-plane technique - LA-IP

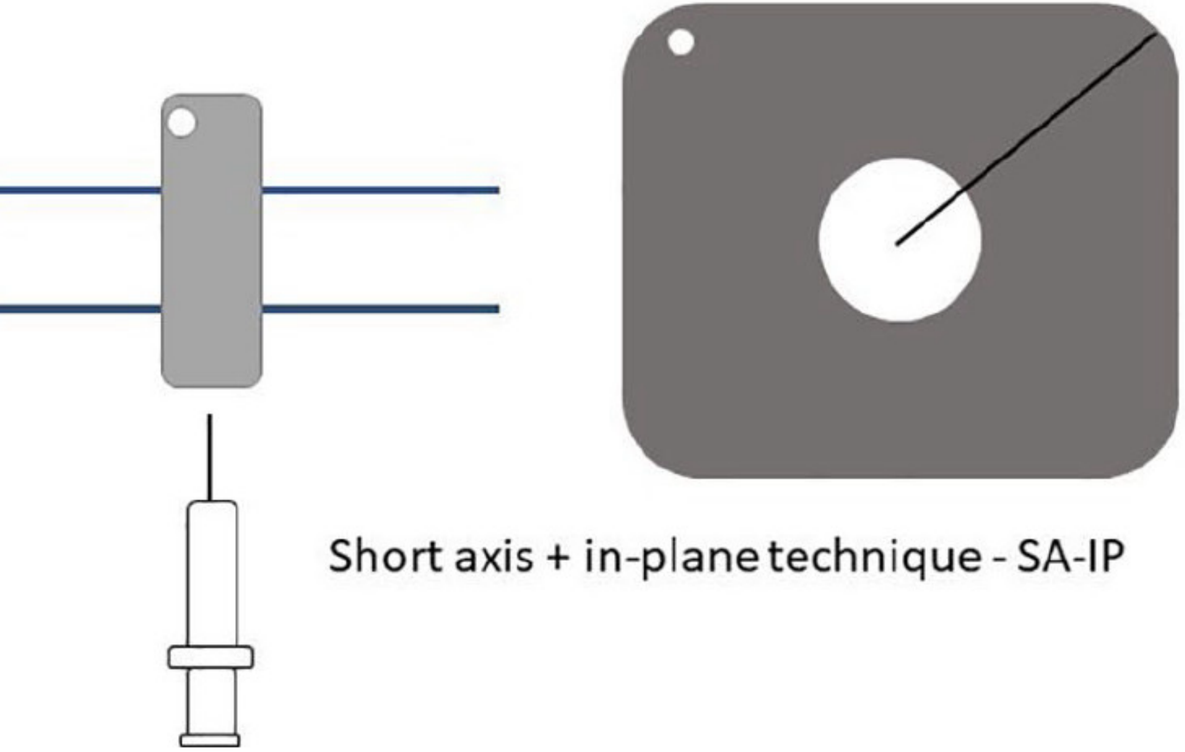

Short axis + in-plane technique - SA-IP

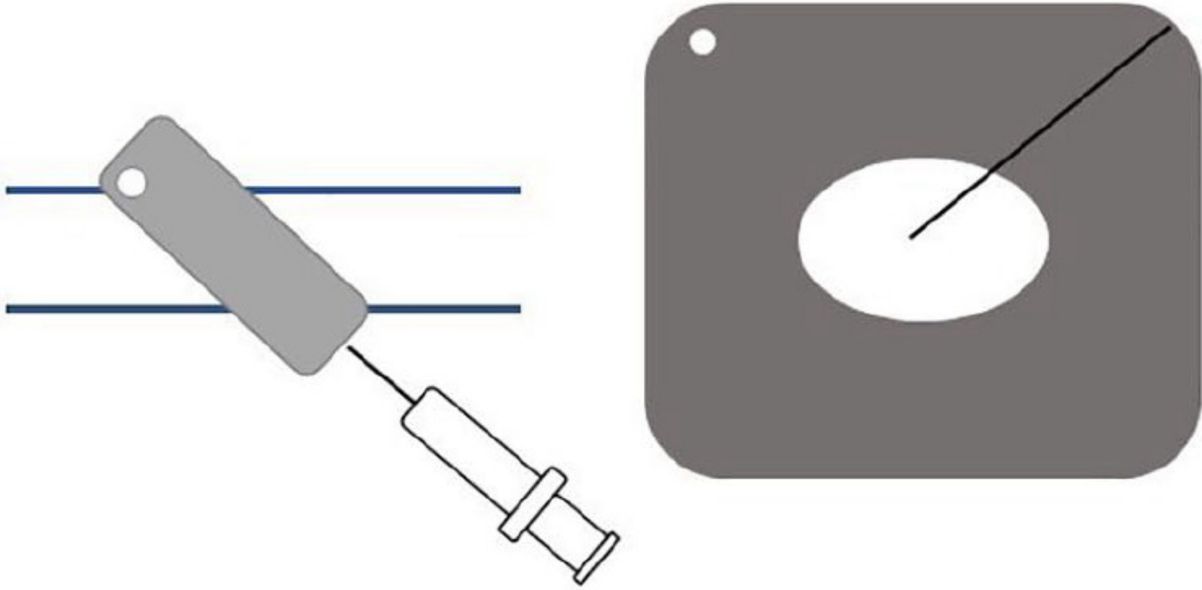

Oblique axis + in-plane technique - OA-IP

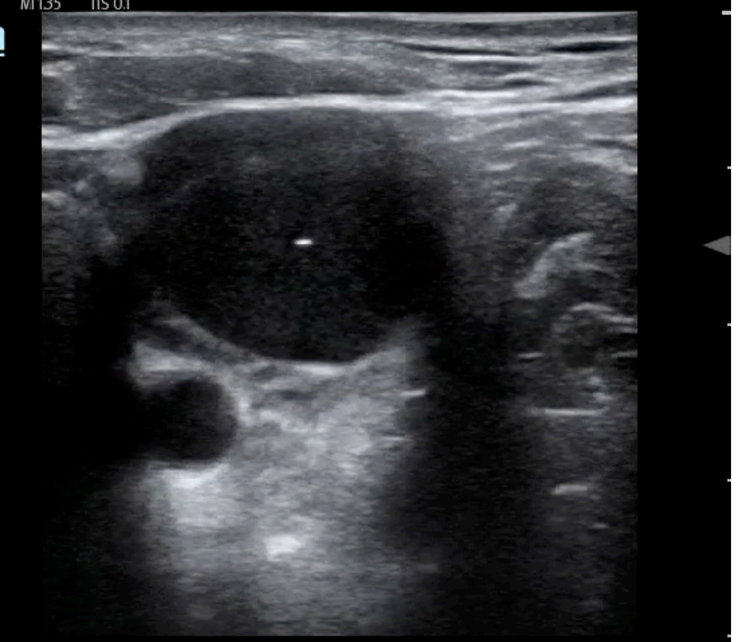

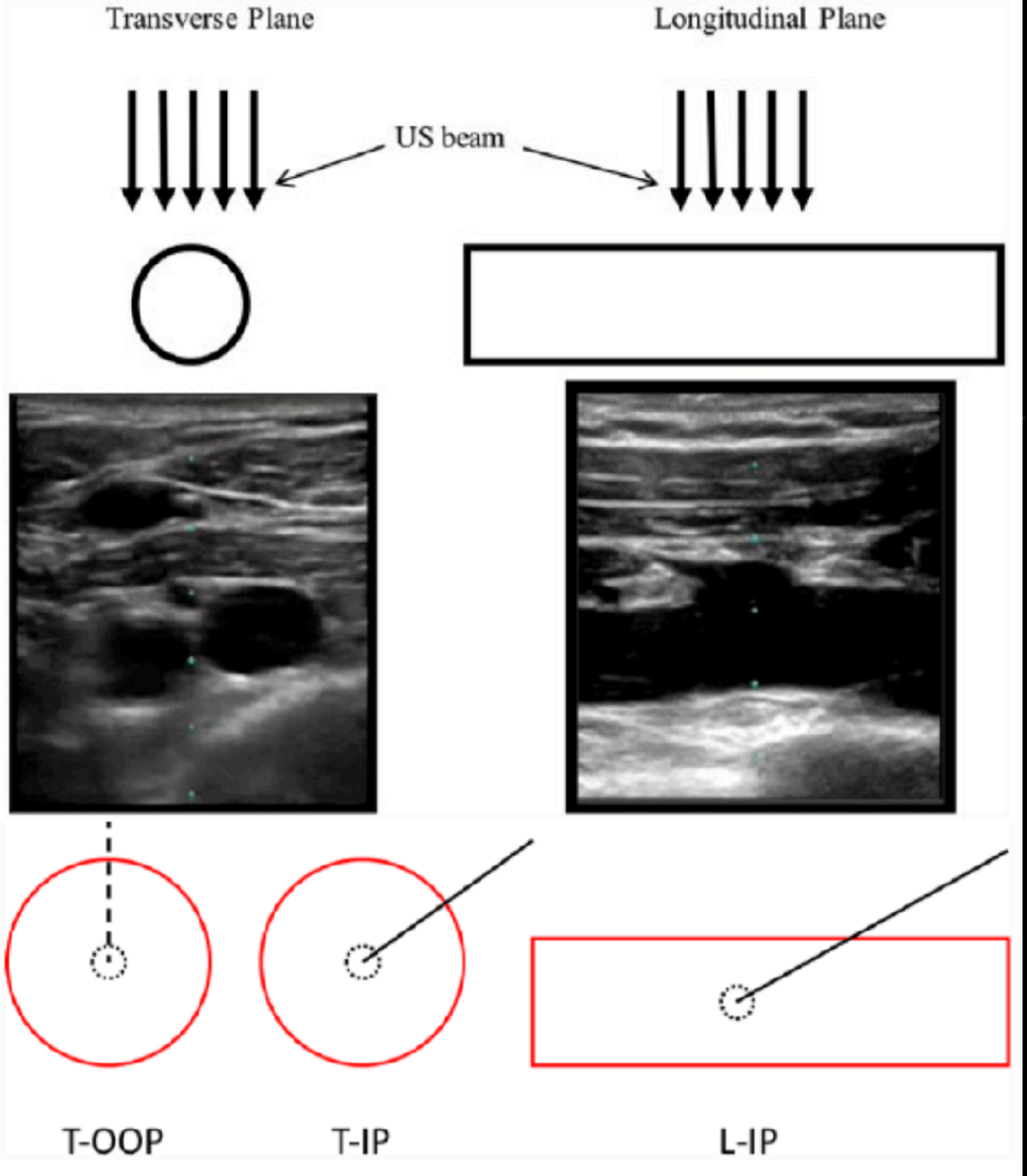
Transverse Plane
Longitudinal Plane
US beam
T-OOP
T-IP
L-IP

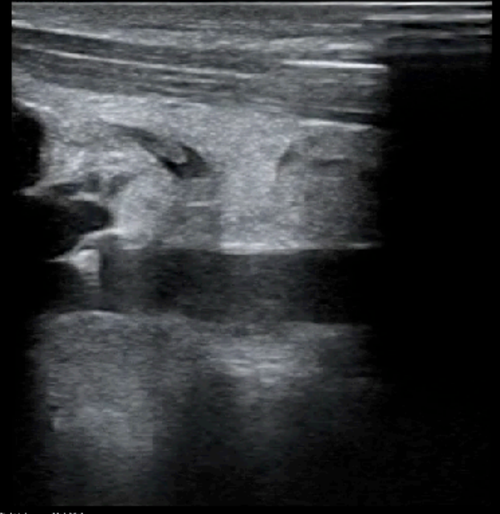


Off - plane


In - plane

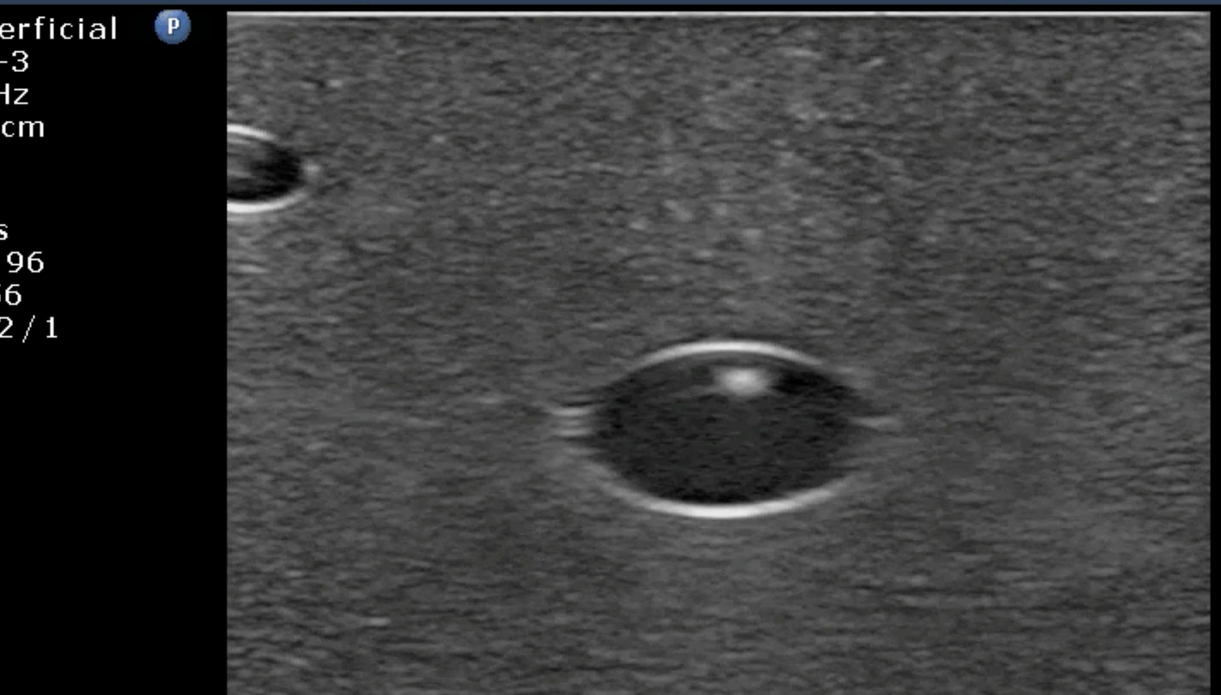
erficial
-3
Hz
cm
s
96
6
2/1

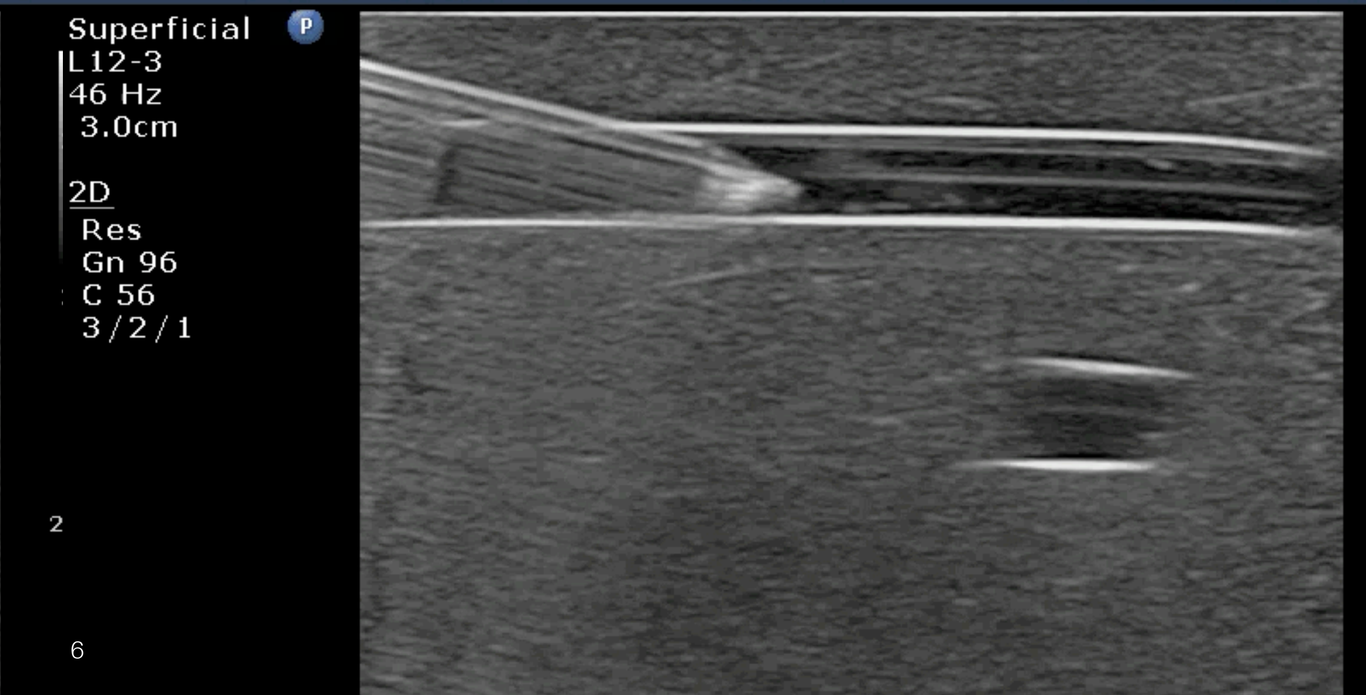
Superficial
L12-3
46 Hz
3.0cm
2D
Res
Gn 96
C 56
3/2/1
2
6

Off-plane首重針尖 / 探頭永遠走在針的前方

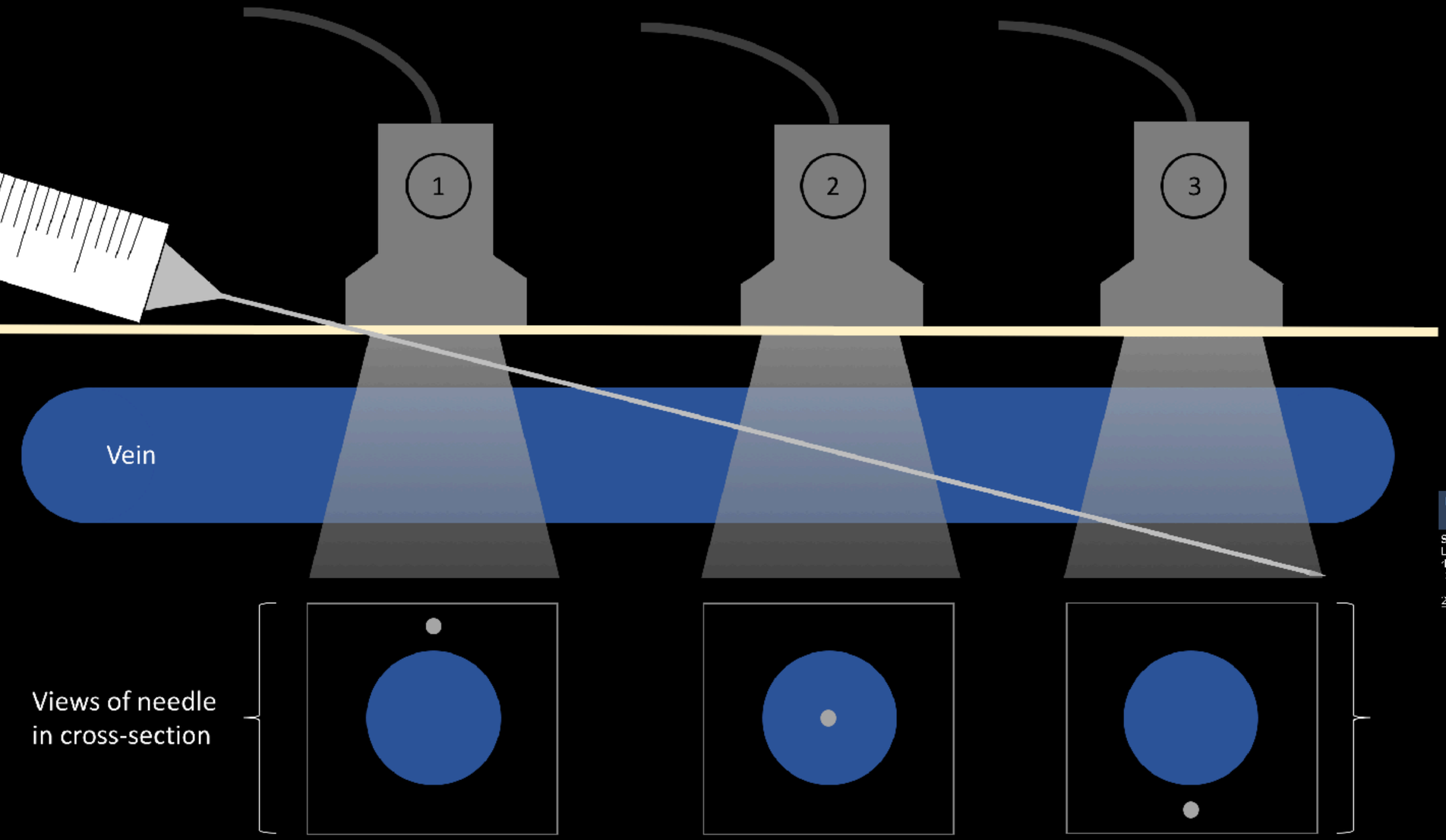

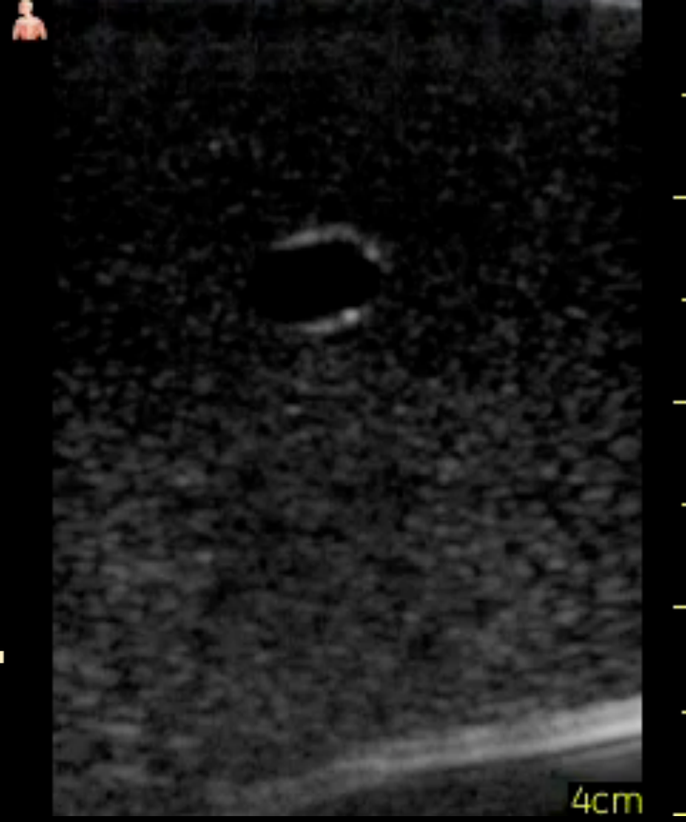

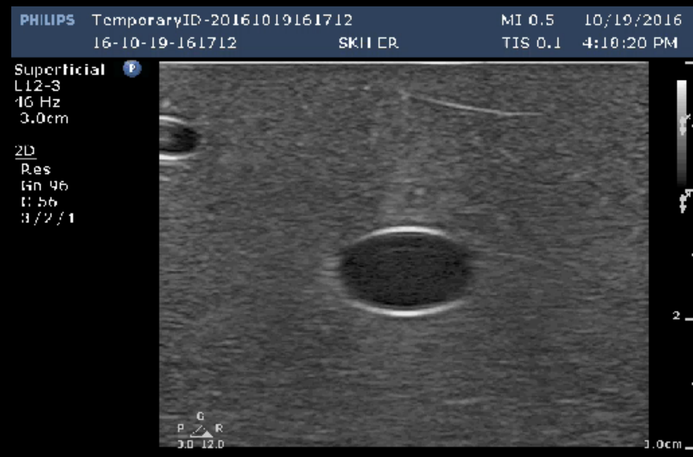

Needle Optimization / 探頭要垂直針身

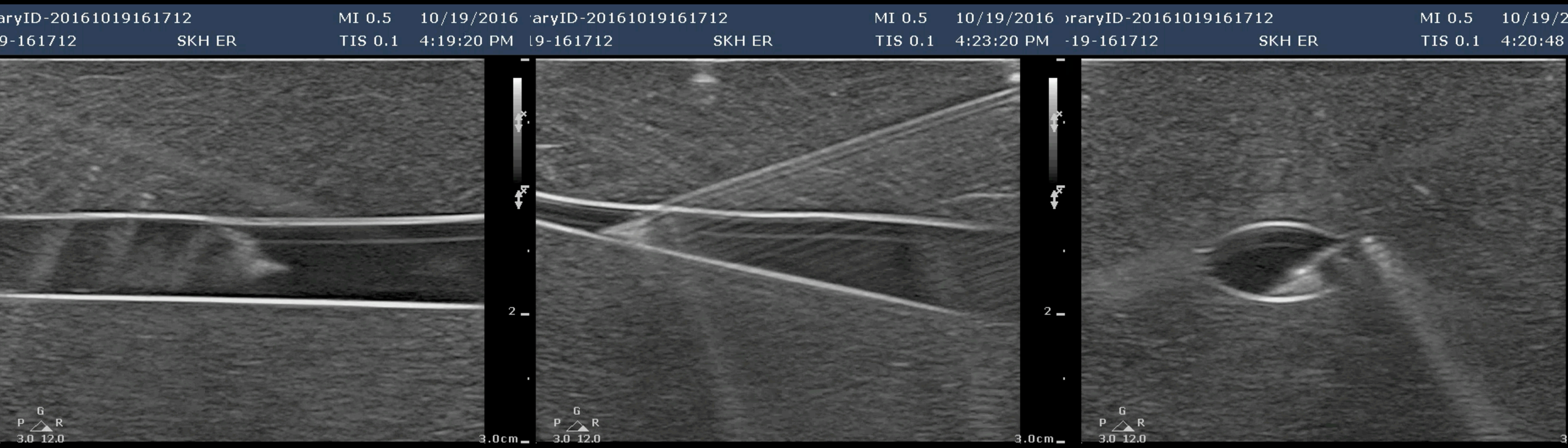

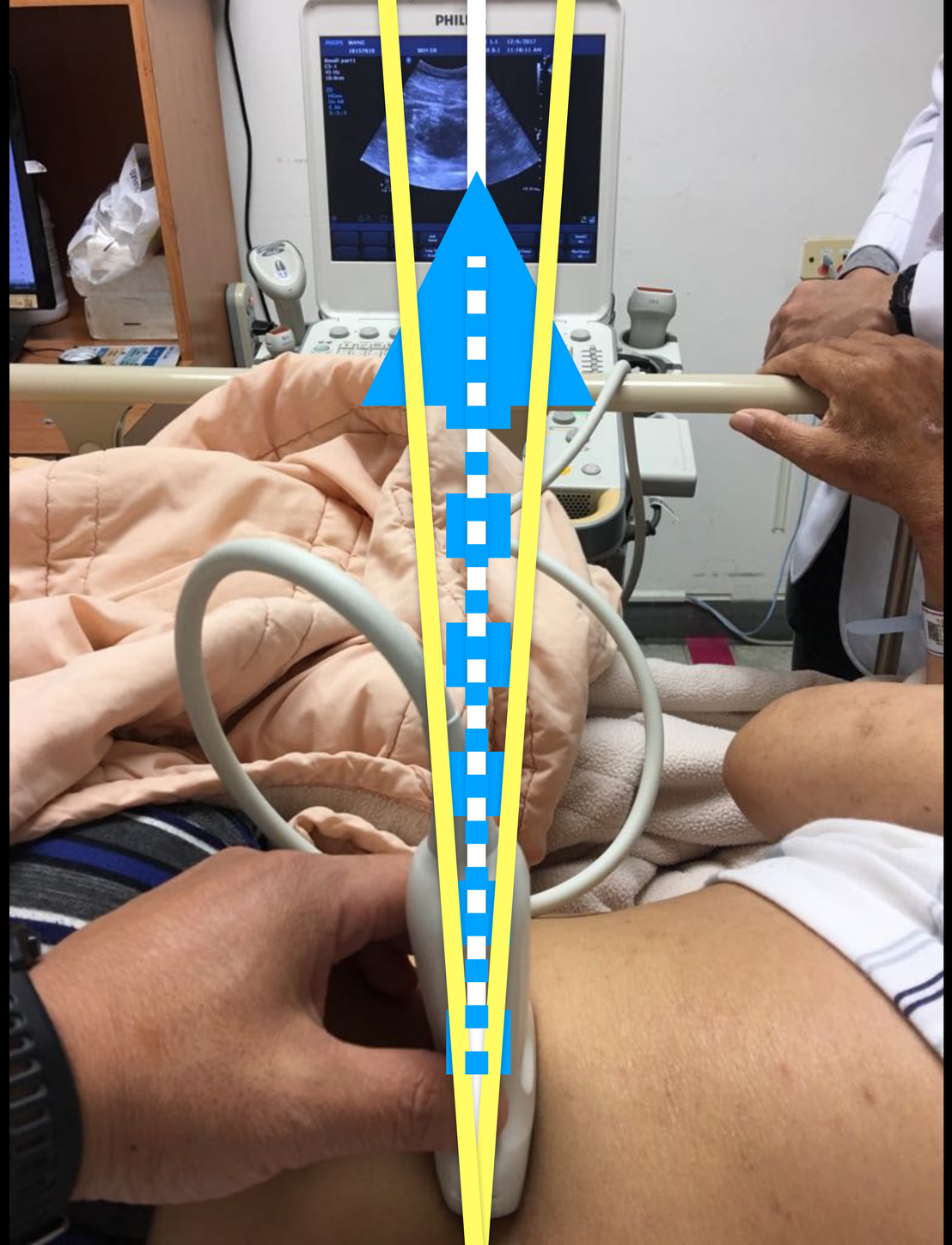

保持軸線

堅守切面

擬定路徑

Ergonomics

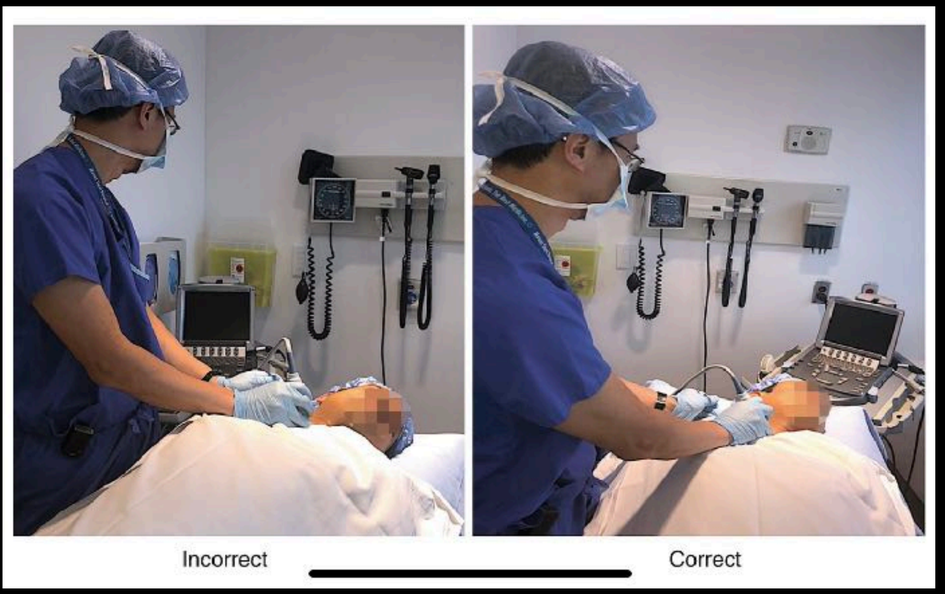

Stable hands

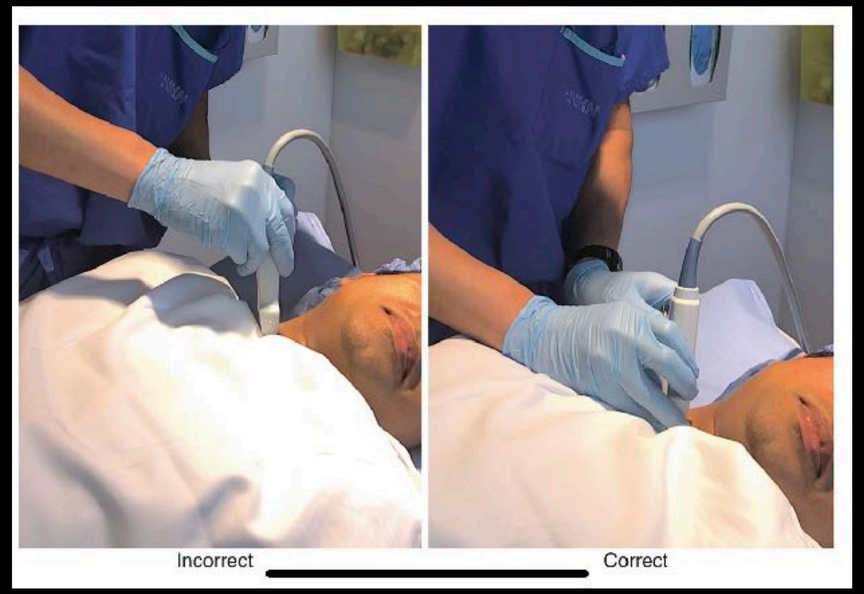

Avoid

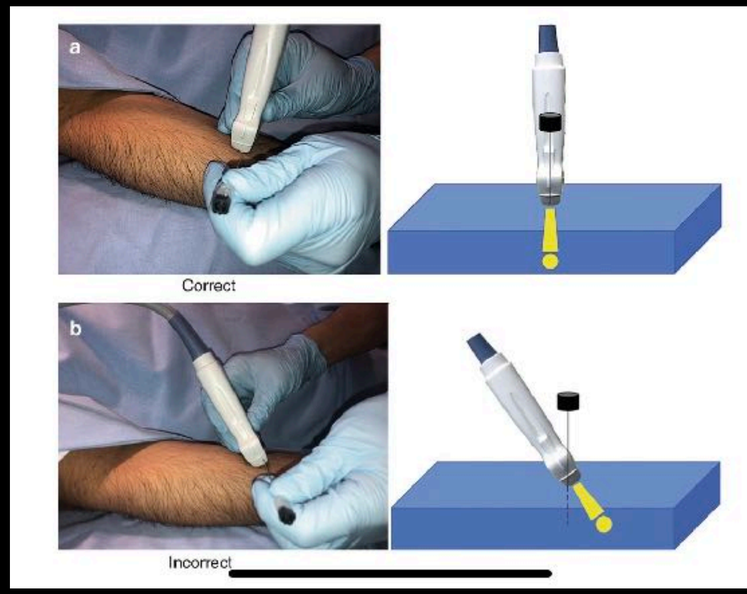

US for interventional pain management

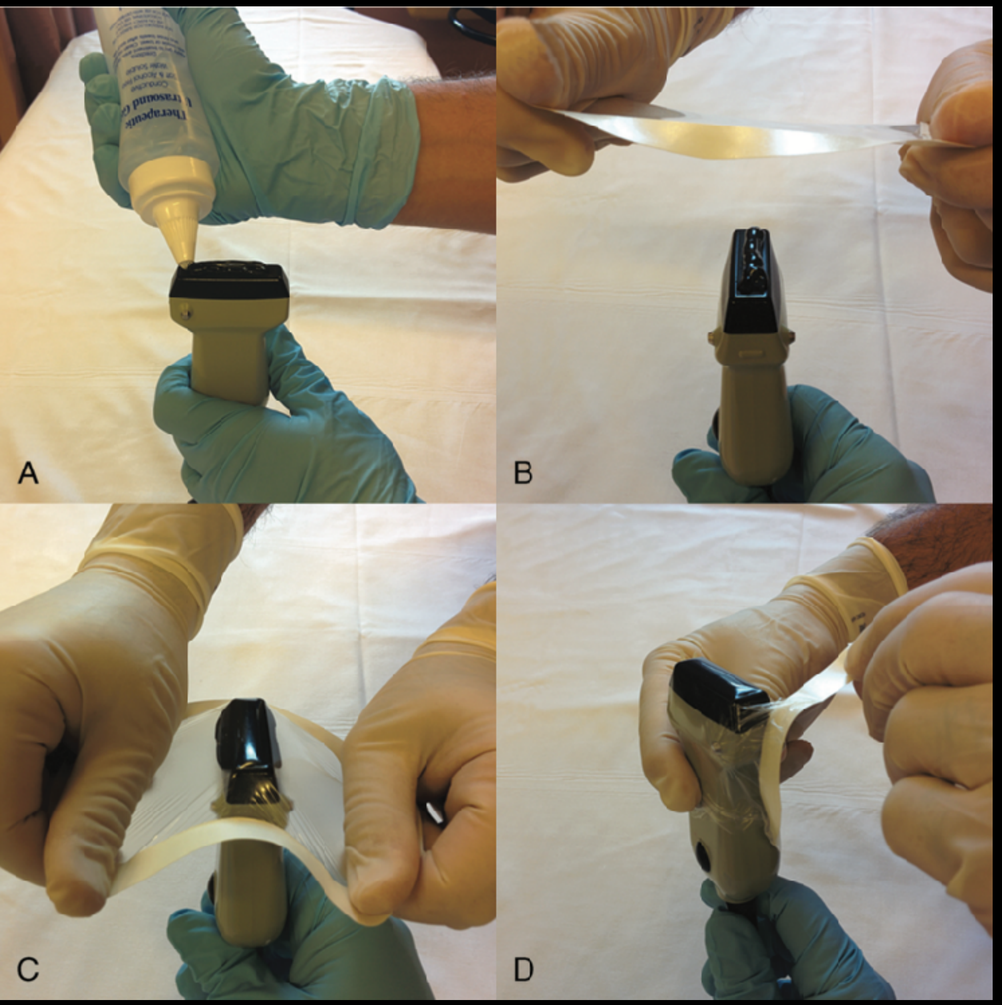

Reg Anesth Pain Med 2015;40: 82–84

US - guided CVC

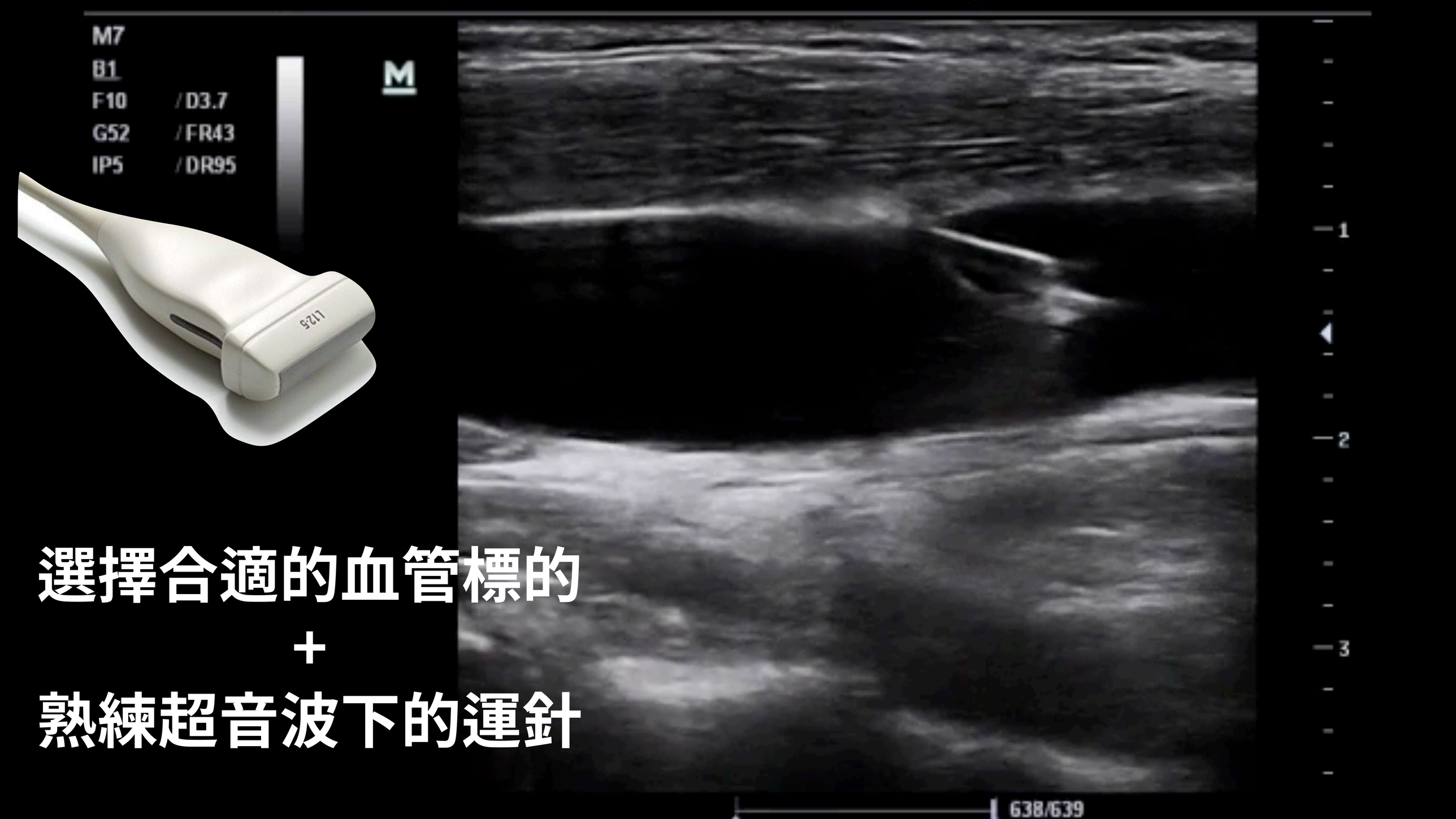

選擇合適的血管標的

+

熟練超音波下的運針

Review

JVA The Journal of Vascular Access

The Journal of Vascular Access
1–11

DOI: 10.1177/1129729818804718
journals.sagepub.com/home/jva
SAGE

Rapid Central Vein Assessment (RaCeVA): A systematic, standardized approach for ultrasound assessment before central venous catheterization

Timothy R Spencer[1] and Mauro Pittiruti[2]

7 Steps

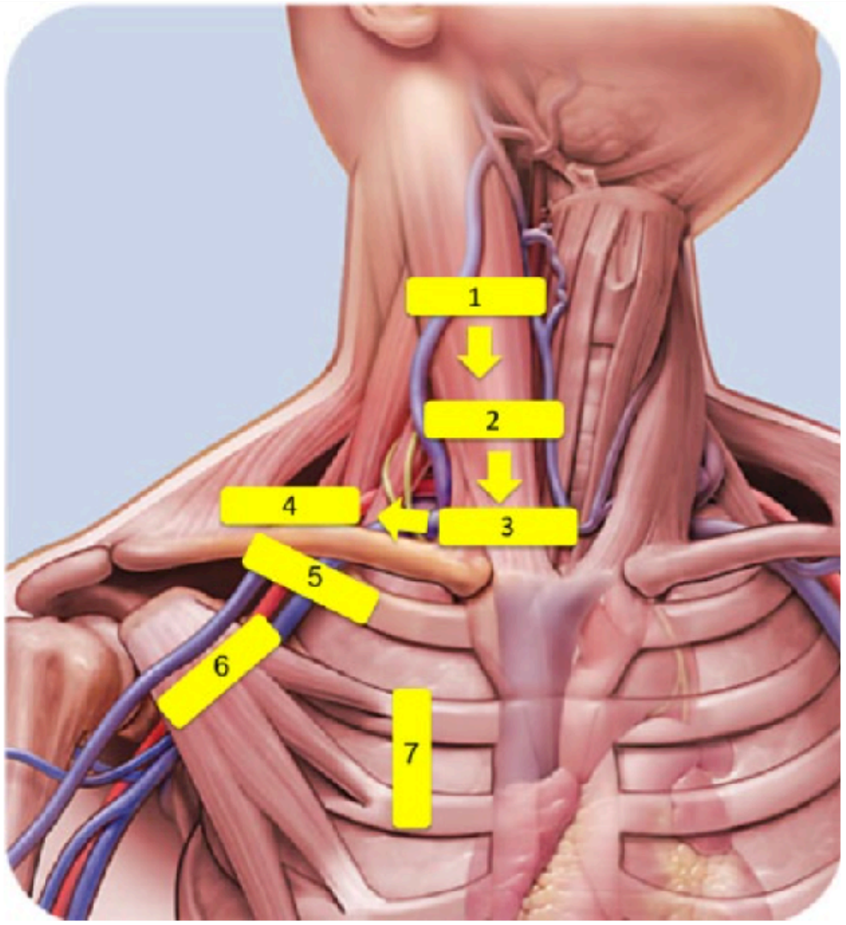

Table 1. The seven steps of the Rapid Central Vein Assessment (RaCeVA).

	Transducer position	Structures to be assessed	Surrounding structures
Step 1	Mid-neck (transverse)	Internal jugular vein Carotid artery	Thyroid gland Trachea
Step 2	Base of neck (transverse)	Internal jugular vein Carotid artery Subclavian artery	Trachea Phrenic and vagus nerve
Step 3	Sternoclavicular (transverse)	Internal jugular vein Brachiocephalic vein	Pleura (mediastinum) Phrenic nerve
Step 4	Supraclavicular (longitudinal)	Subclavian vein Subclavian artery External jugular vein	Pleura (lung apex)
Step 5	Infraclavicular (transverse)	Axillary vein Axillary artery Cephalic vein	Pleura Ribs
Step 6	Infraclavicular (longitudinal)	Axillary vein Axillary artery	Pleura Ribs
Step 7	Sliding lung (longitudinal)	Pleura (anterior chest wall)	Ribs

Catheter/ Vein: 1:3 or less

1. Size of the vein (internal diameter/caliber)
2. Depth of the vein (depth of target vessel from skin surface)
3. Respiratory variations (influence of respiratory cycle on vein diameter)
4. Compression by artery (influence of arterial pulsation on vein diameter)
5. Proximity to non-venous structures which must not be damaged (pleura, nerve, and artery)
6. Exit site location—convenience/appropriateness in terms for best care and maintenance

Review

JVA The Journal of Vascular Access

The Journal of Vascular Access
1–11

DOI: 10.1177/1129729818804718
journals.sagepub.com/home/jva
SAGE

Rapid Central Vein Assessment (RaCeVA): A systematic, standardized approach for ultrasound assessment before central venous catheterization

Timothy R Spencer[1] and Mauro Pittiruti[2]

7 Steps

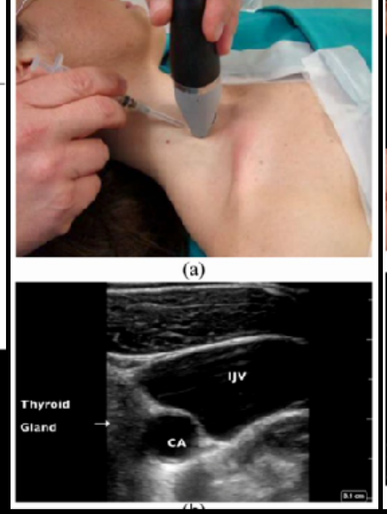

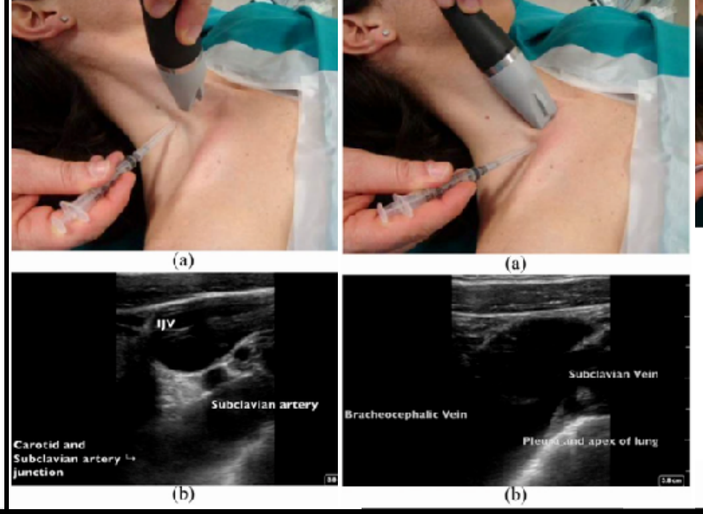

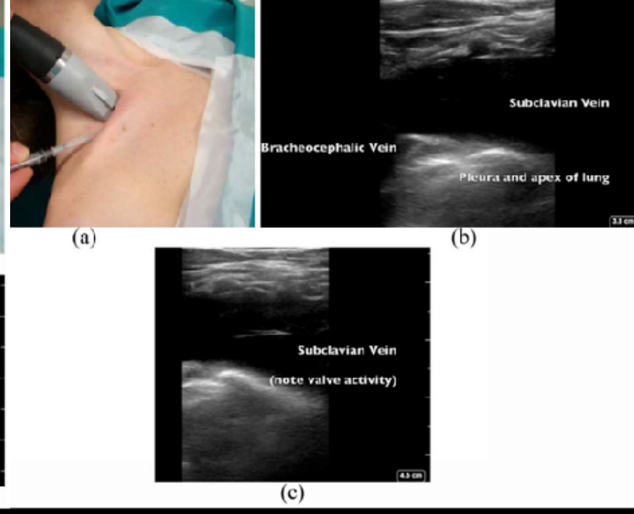

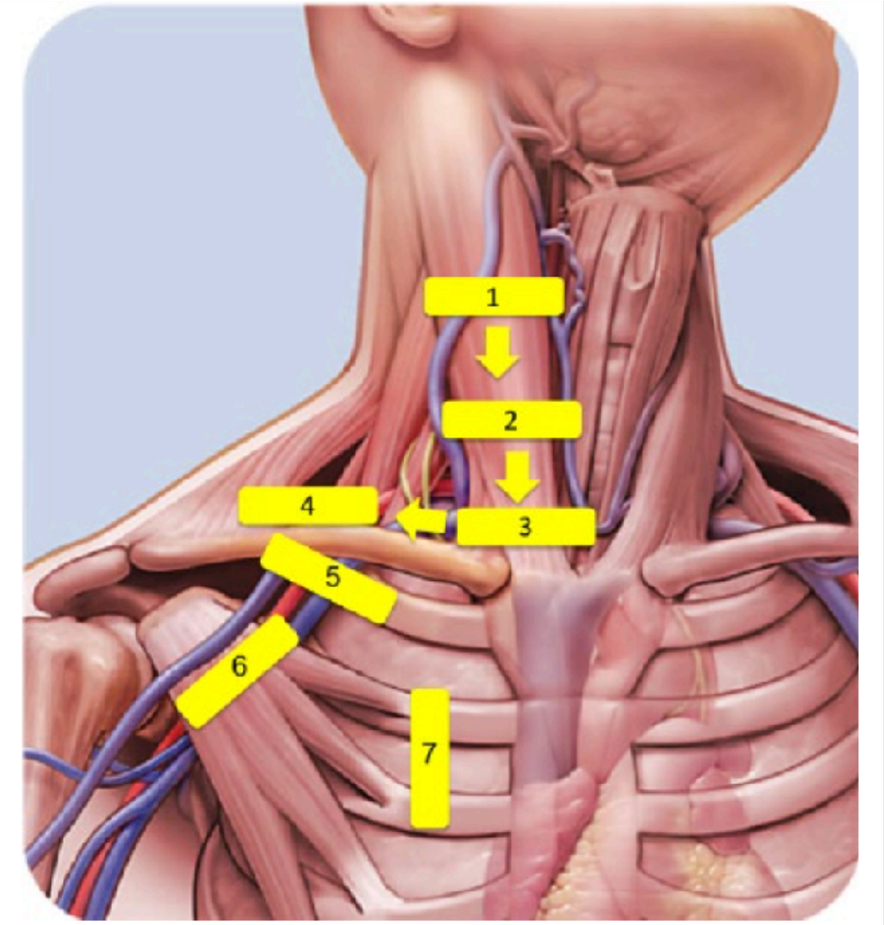

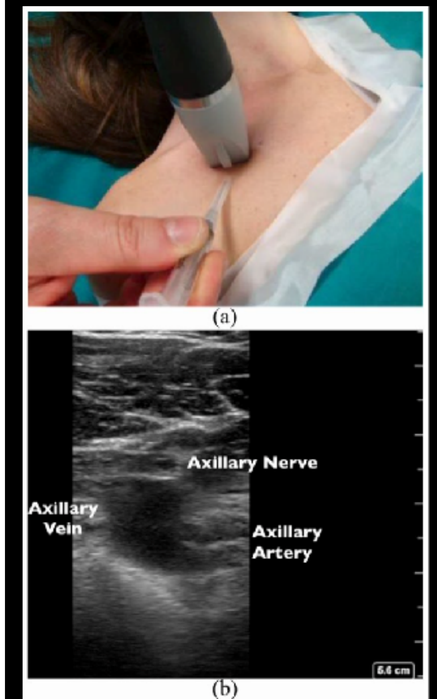

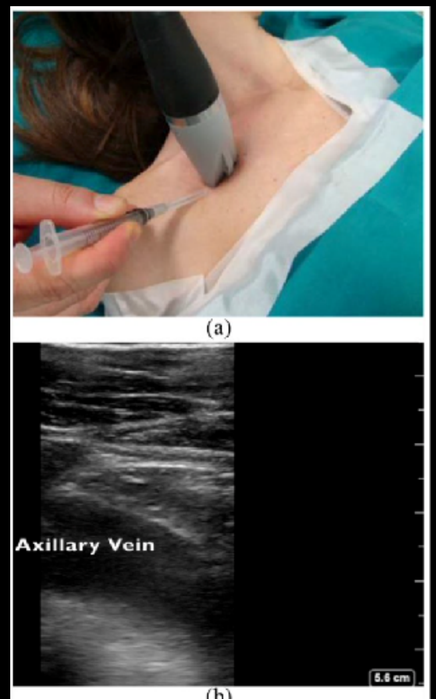

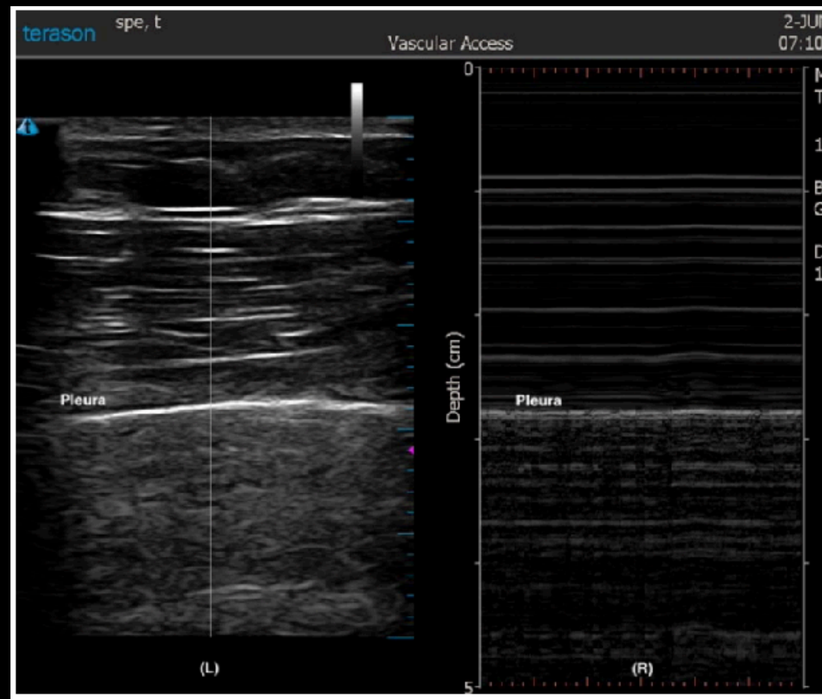

Editorial

JVA The Journal of Vascular Access

The SIC protocol: A seven-step strategy to minimize complications potentially related to the insertion of centrally inserted central catheters

The Journal of Vascular Access
2023, Vol. 24(2) 185–190

DOI: 10.1177/11297298211036002
journals.sagepub.com/home/jva
SAGE

Fabrizio Brescia[1], Mauro Pittiruti[2], Matthew Ostroff[3], Timothy R Spencer[4] and Robert B Dawson[5]

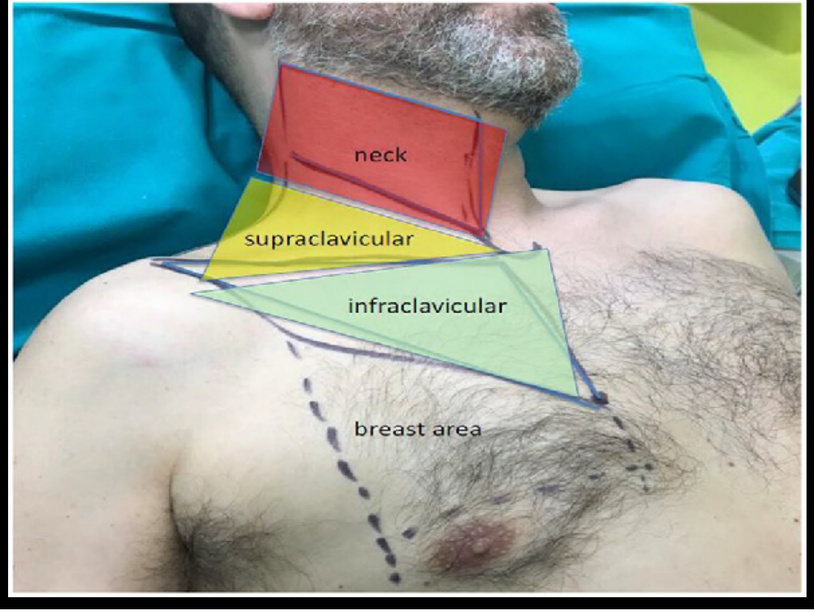

Table 1. The seven steps of the SIC protocol.

Step 1	*Preprocedural evaluation*—choice of the vein by systematic ultrasound examination of the veins of the neck and of the supra/infraclavicular region (RaCeVA protocol) and choice of the ideal exit site (Central ZIM)
Step 2	*Appropriate aseptic technique*—hand hygiene, skin antisepsis with 2% chlorhexidine in 70% alcohol, maximal barrier precautions
Step 3	*Ultrasound-guided insertion*—ultrasound-guided venipuncture, ultrasound verification of the correct direction of the guidewire (tip navigation) and of the absence of pneumothorax (pleural scan)
Step 4	*Intra-procedural assessment of tip location*—verification of the central position of the tip by intracavitary ECG and/or by transthoracic echocardiography, using the "bubble test"
Step 5	*Adequate protection of the exit site*—reduction of the risk of bleeding and risk of contamination by sealing with cyanoacrylate glue
Step 6	*Proper securement of the catheter*—stabilization of the catheter using skin-adhesive sutureless devices, transparent dressing with integrated securement or subcutaneous anchorage
Step 7	*Appropriate coverage of the exit site*—use of semi-permeable transparent dressing, preferably with high breathability

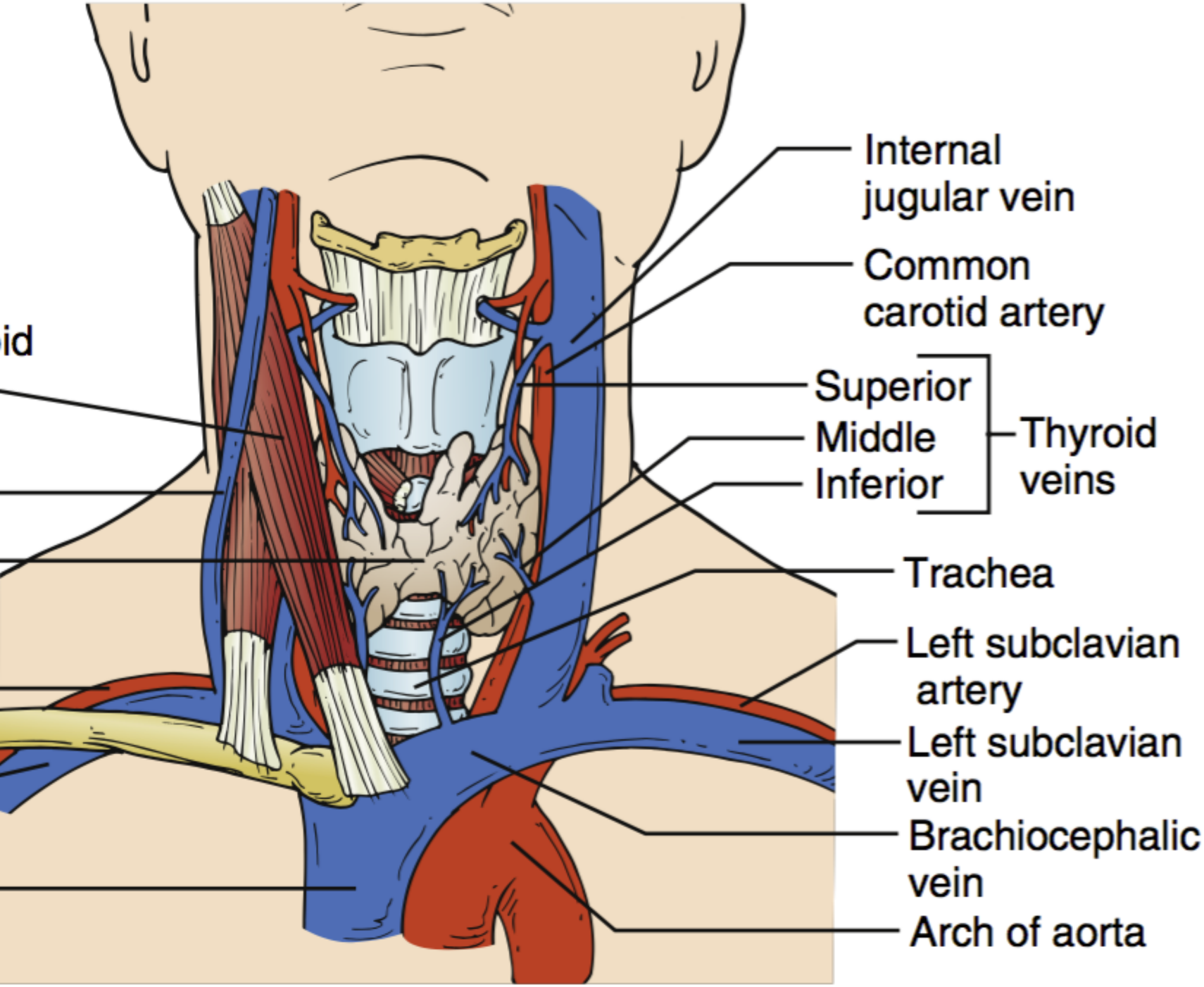
id
Internal jugular vein
Common carotid artery
Superior
Middle
Inferior
Thyroid veins
Trachea
Left subclavian artery
Left subclavian vein
Brachiocephalic vein
Arch of aorta

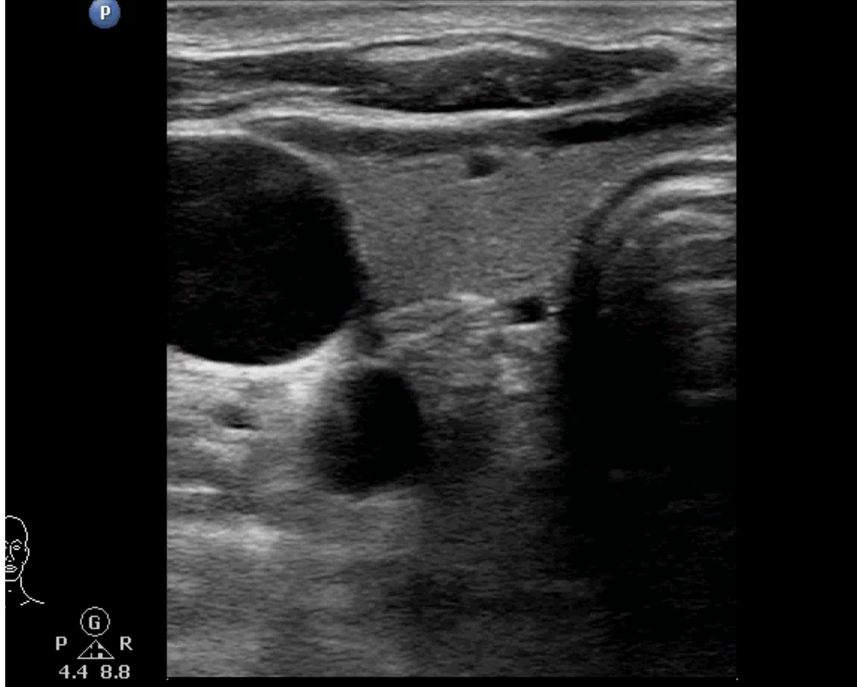
P
G
P R
4.4 8.8

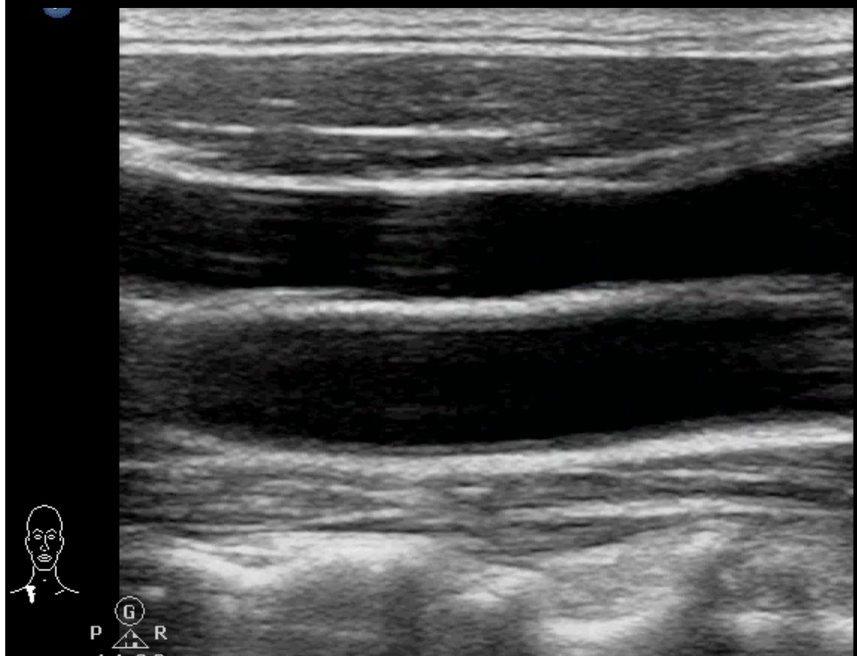
G
P R

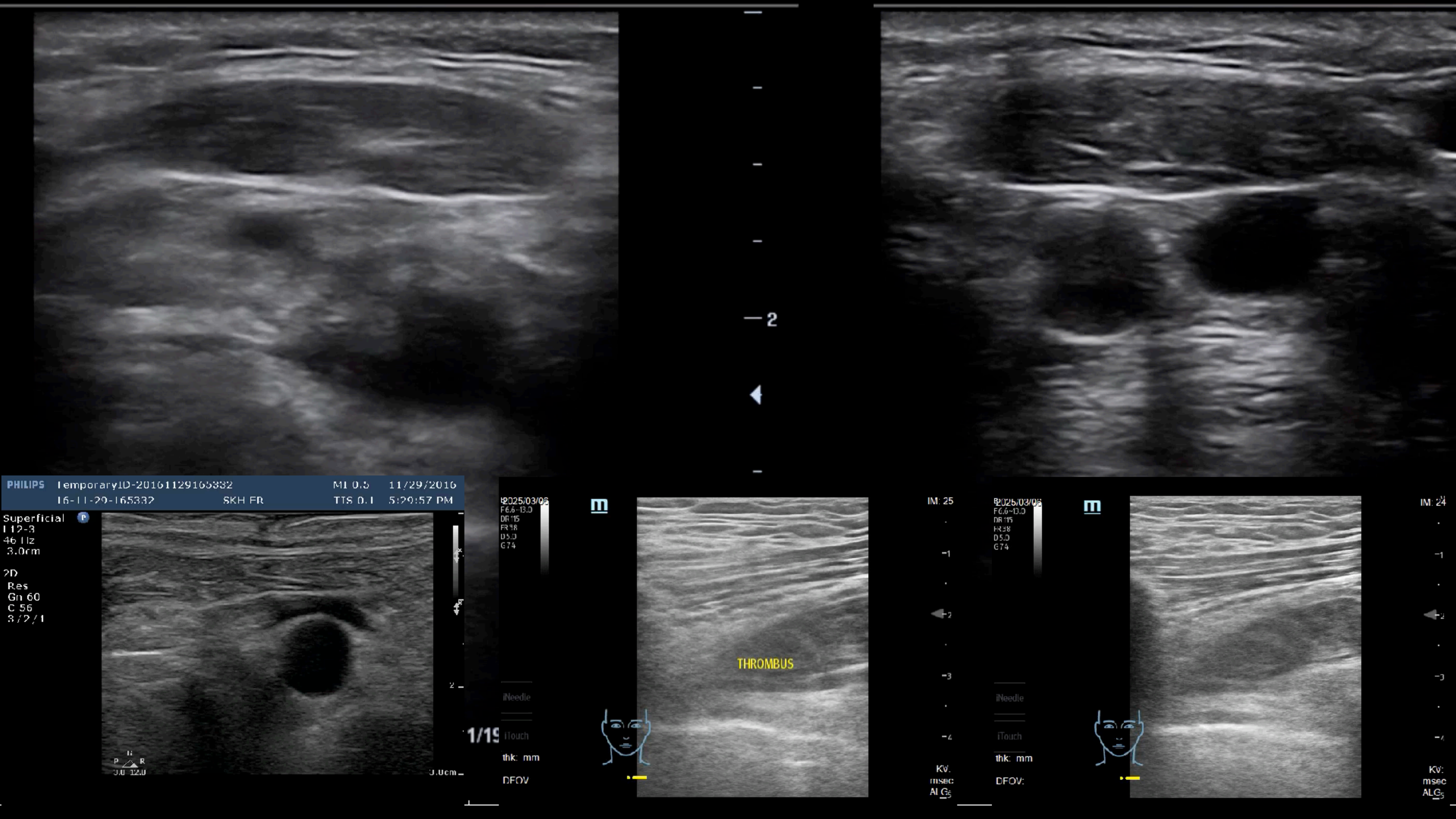
PHILIPS
TemporaryID-20161129165332
16-11-29-165332
SKH FR
MI 0.5
TTS 0.1
11/29/2016
5:29:57 PM
Superficial
L12-3
46 Hz
3.0cm
2D
Res
Gn 60
C 56
3/2/1
THROMBUS
iNeedle
iTouch
thk: mm
DFOV
IM: 25
IM: 24
Kv:
msec
ALG

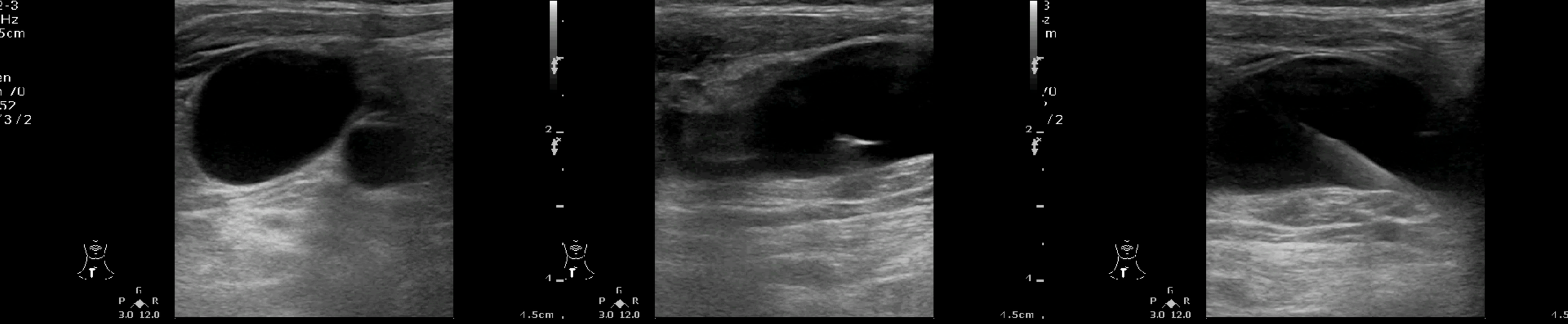

US - guided CVC

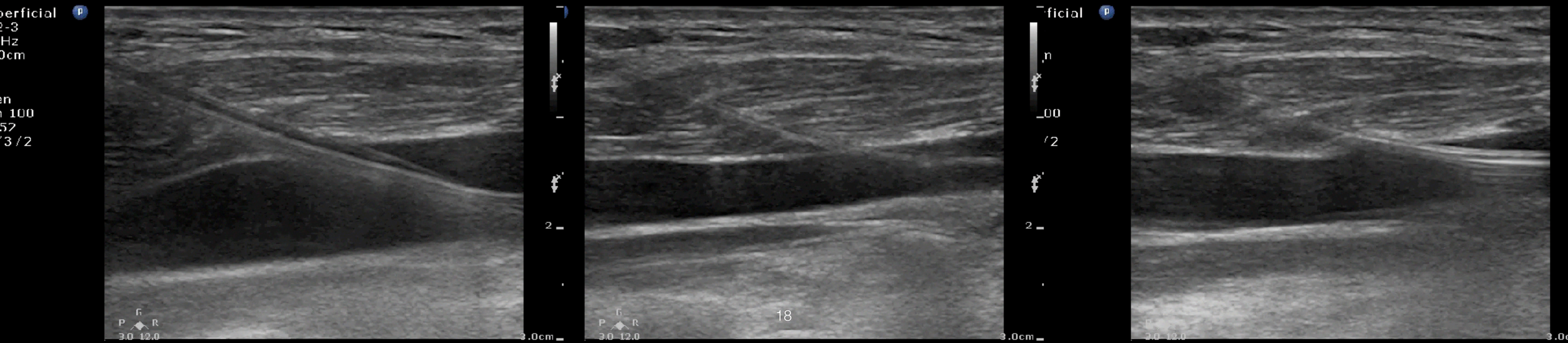

CVC confirmation

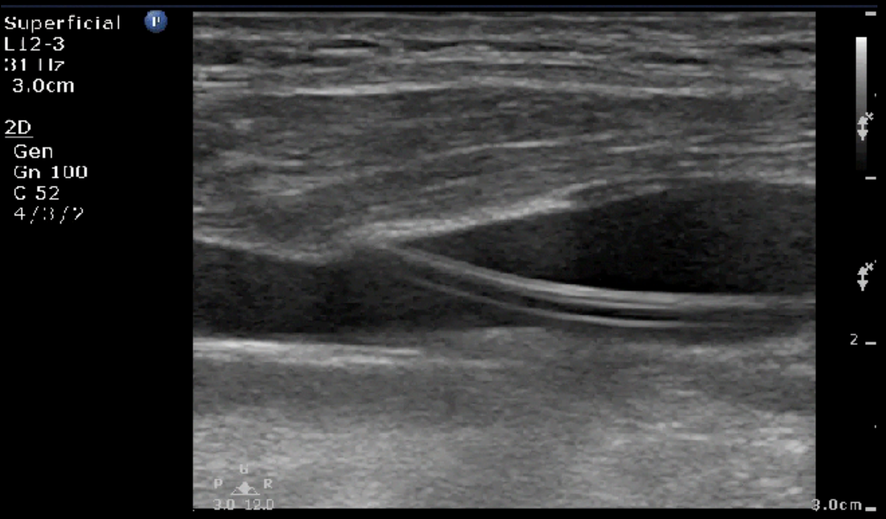

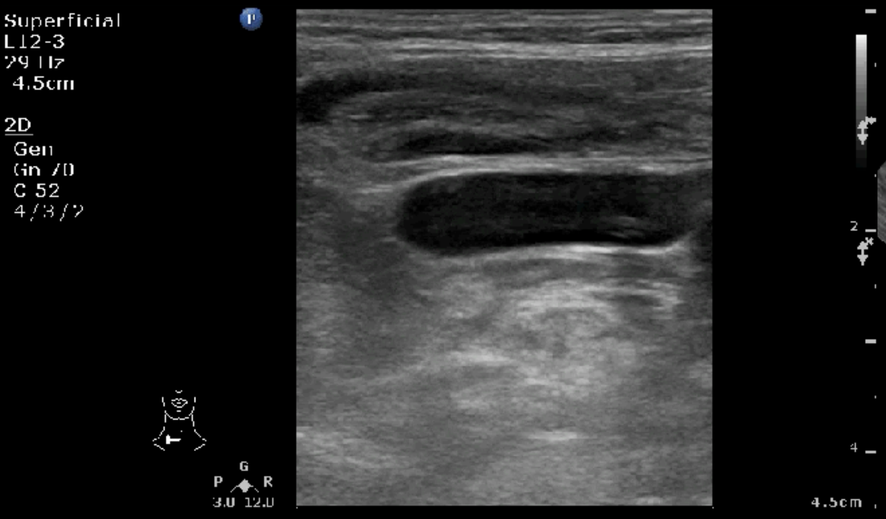

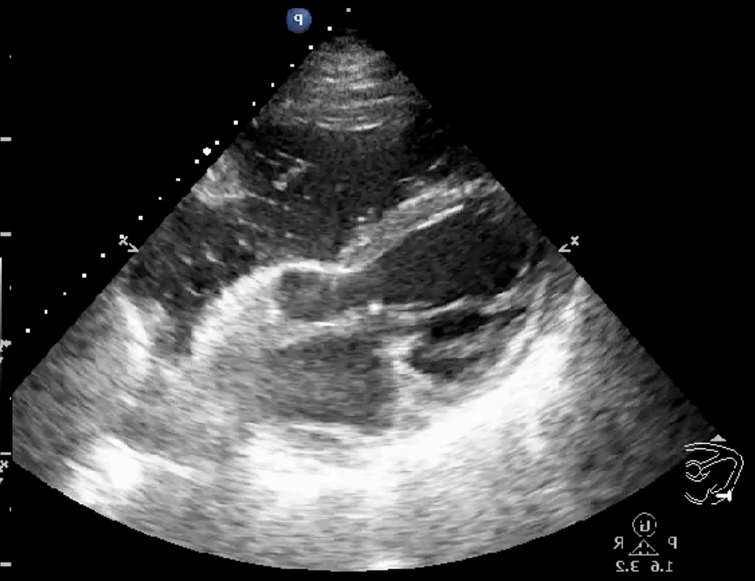

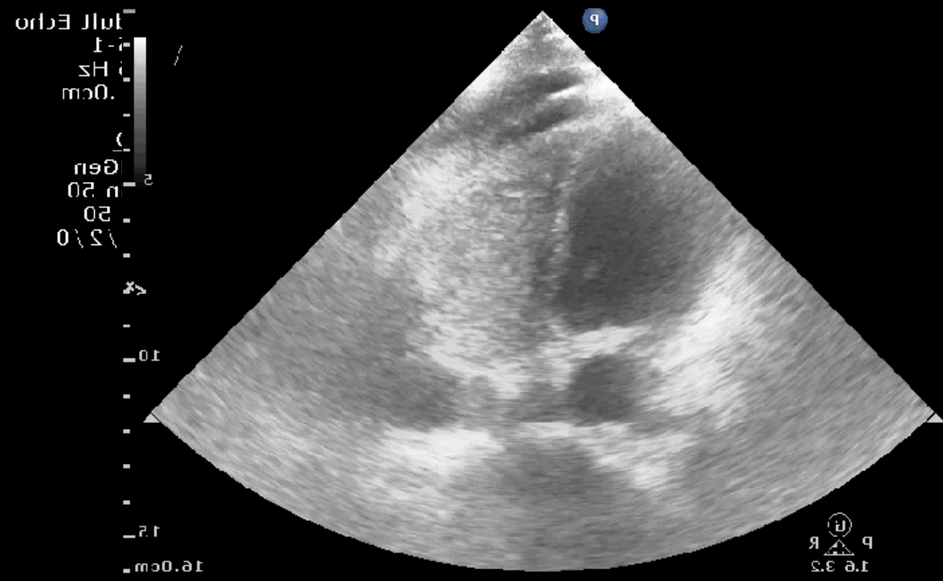

64M, 安中轉入，Shock & AMS

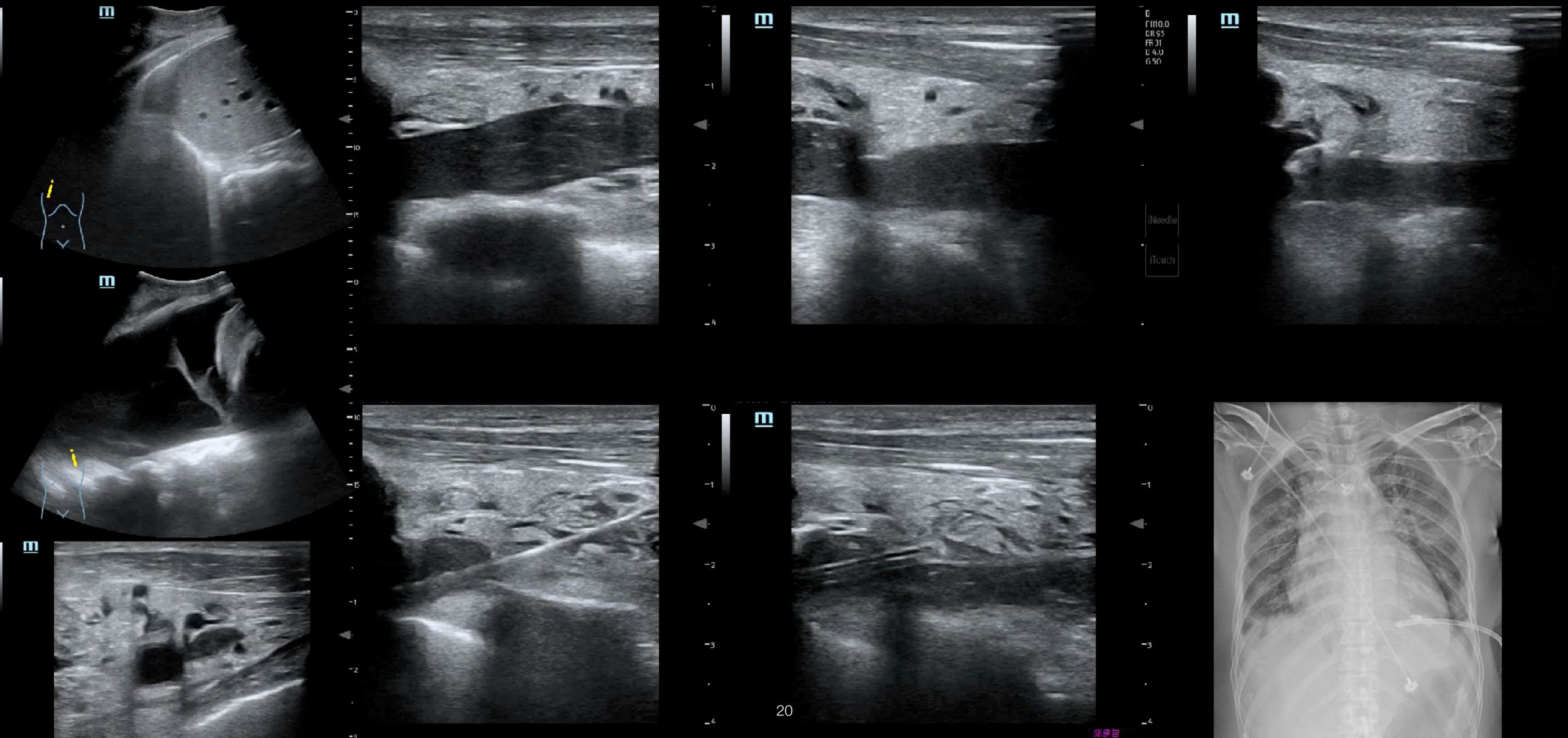

Editorial

JVA The Journal of Vascular Access

Rapid Femoral Vein Assessment (RaFeVA): A systematic protocol for ultrasound evaluation of the veins of the lower limb, so to optimize the insertion of femorally inserted central catheters

The Journal of Vascular Access
2021, Vol. 22(6) 863–872

DOI: 10.1177/1129729820965063
journals.sagepub.com/home/jva
SAGE

Fabrizio Brescia[1], Mauro Pittiruti[2], Matthew Ostroff[3] and Daniele G Biasucci[4]

	Vascular structures to be assessed	Visualization of the vein
Step 1	Common femoral artery Common femoral vein	Short axis
Step 2	Common femoral vein External iliac vein	Long axis
Step 3	Common femoral artery Common femoral vein Saphenous vein	Short axis
Step 4	Superficial femoral artery Deep femoral artery Common femoral vein	Short axis
Step 5	Superficial femoral artery Deep femoral artery Superficial femoral vein Deep femoral vein	Short axis
Step 6	Superficial femoral artery Superficial femoral vein	Short axis
Step 7	Superficial femoral artery Superficial femoral vein	Oblique axis

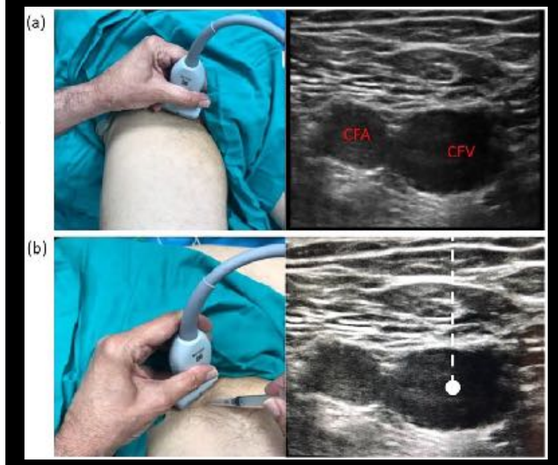

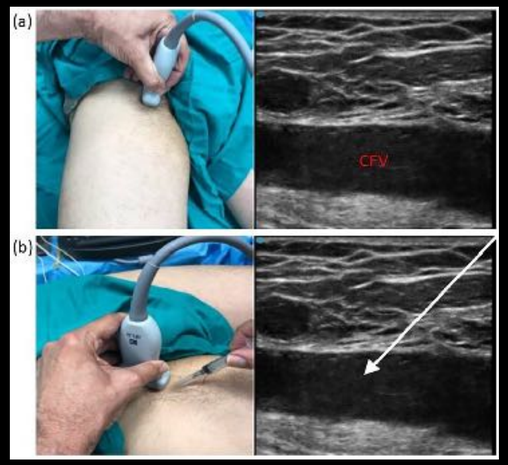

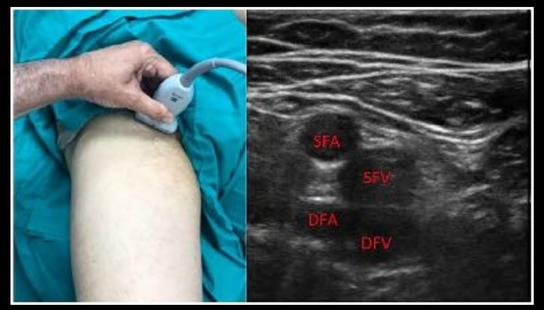

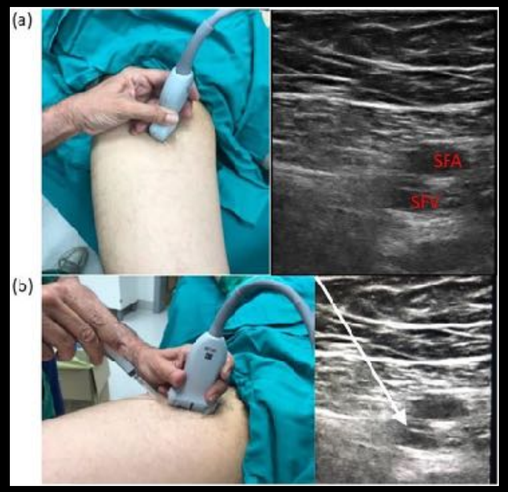

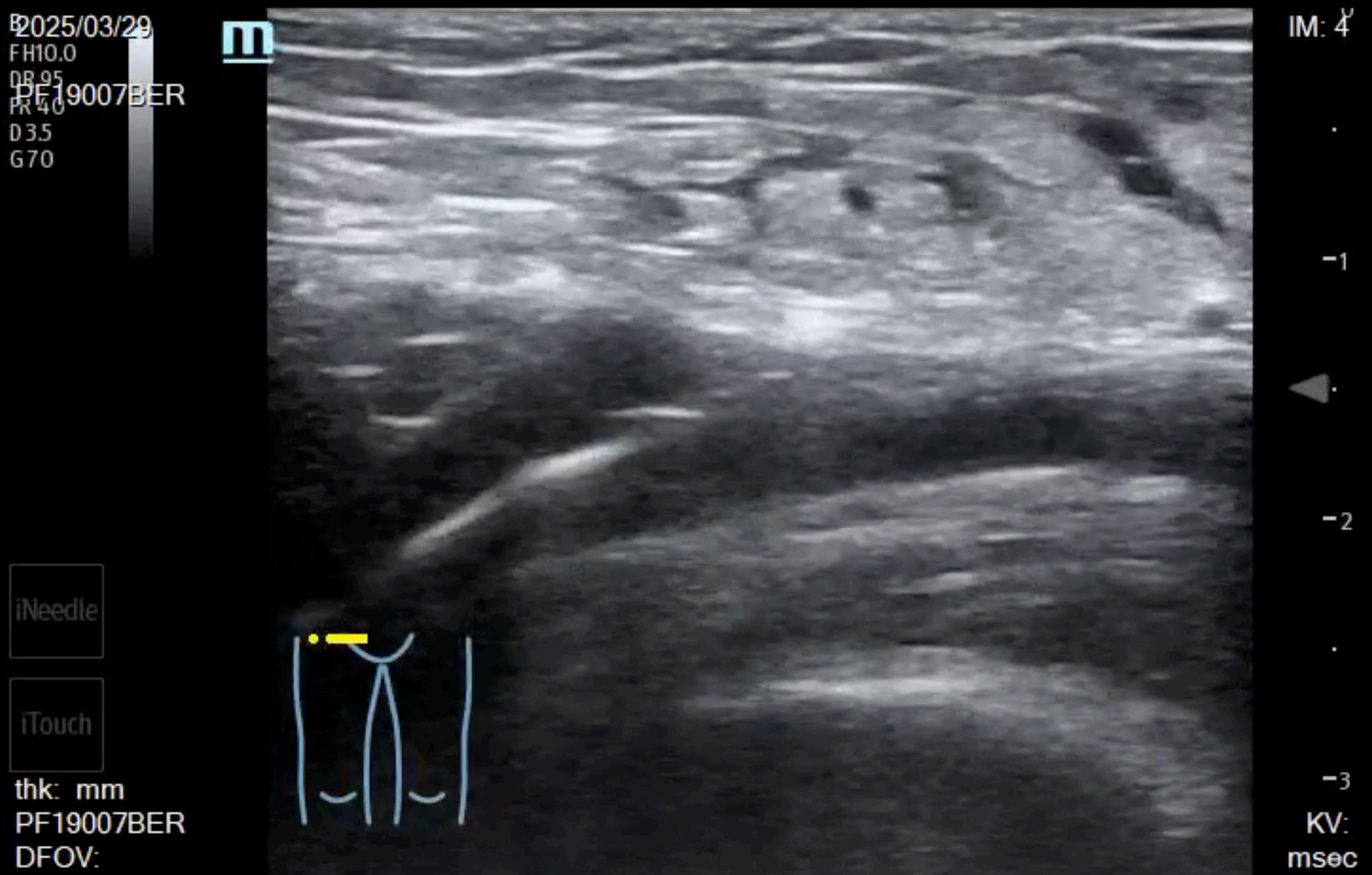

Trauma Dialysis ECMO

Editorial

JVA The Journal of Vascular Access

ECHOTIP: A structured protocol for ultrasound-based tip navigation and tip location during placement of central venous access devices in adult patients

The Journal of Vascular Access
2023, Vol. 24(4) 535–544

DOI: 10.1177/11297298211044325
journals.sagepub.com/home/jva
SAGE

Antonio La Greca[1], Emanuele Iacobone[2], Daniele Elisei[2], Daniele Guerino Biasucci[3], Vito D'Andrea[4], Giovanni Barone[5], Geremia Zito Marinosci[6]

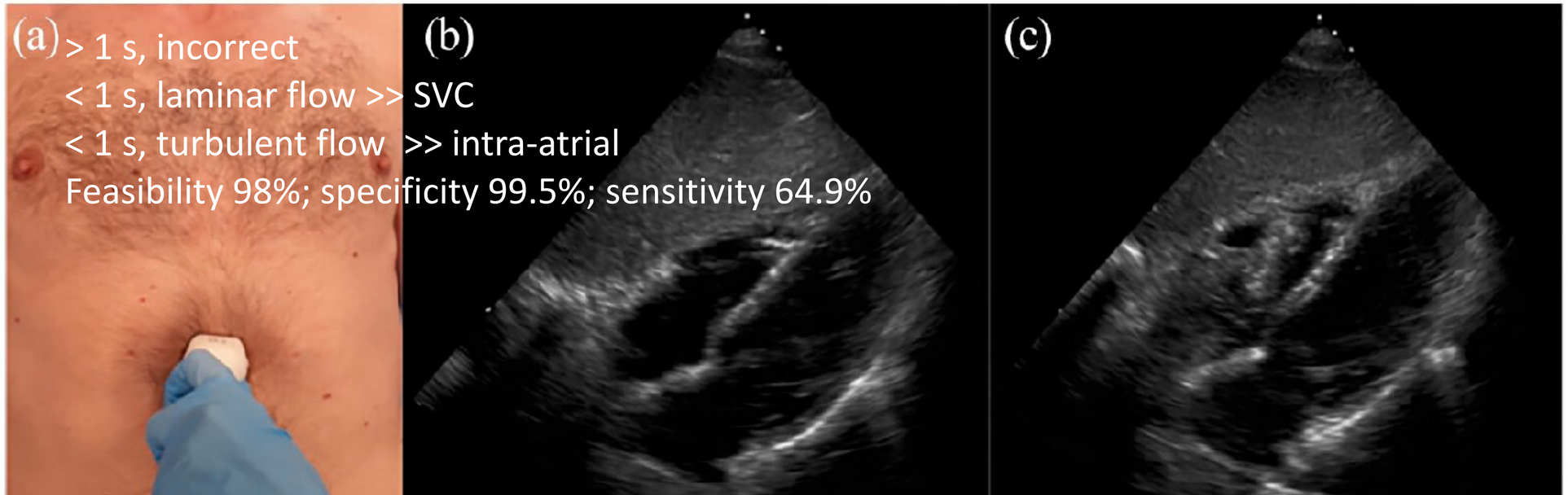

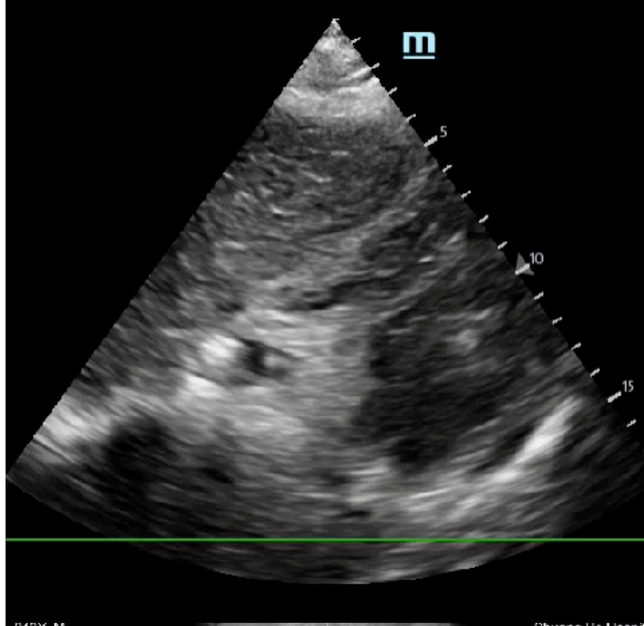

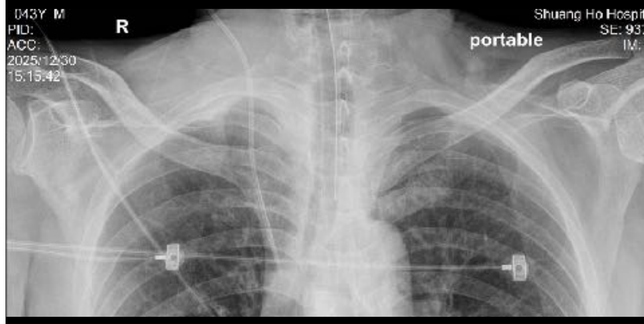

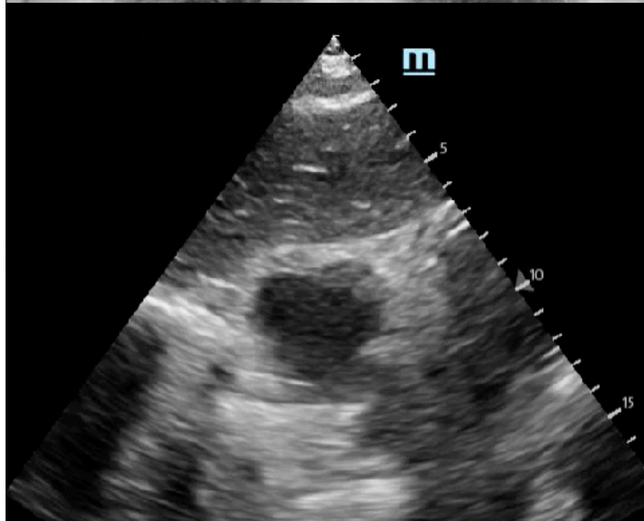

Alway check IJV for infraclavicular CVC

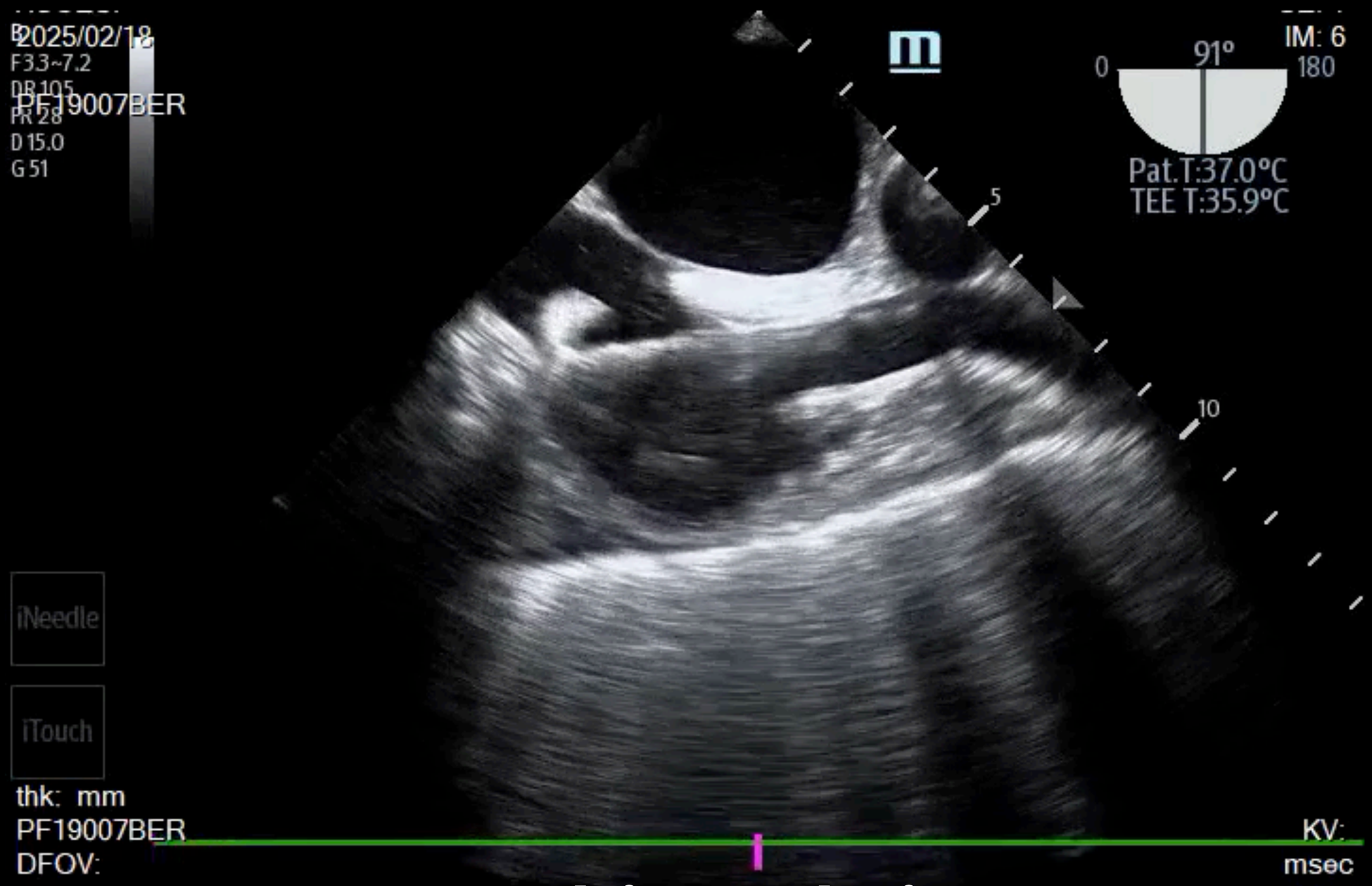

TEE - bicaval view

CVC for septic shock

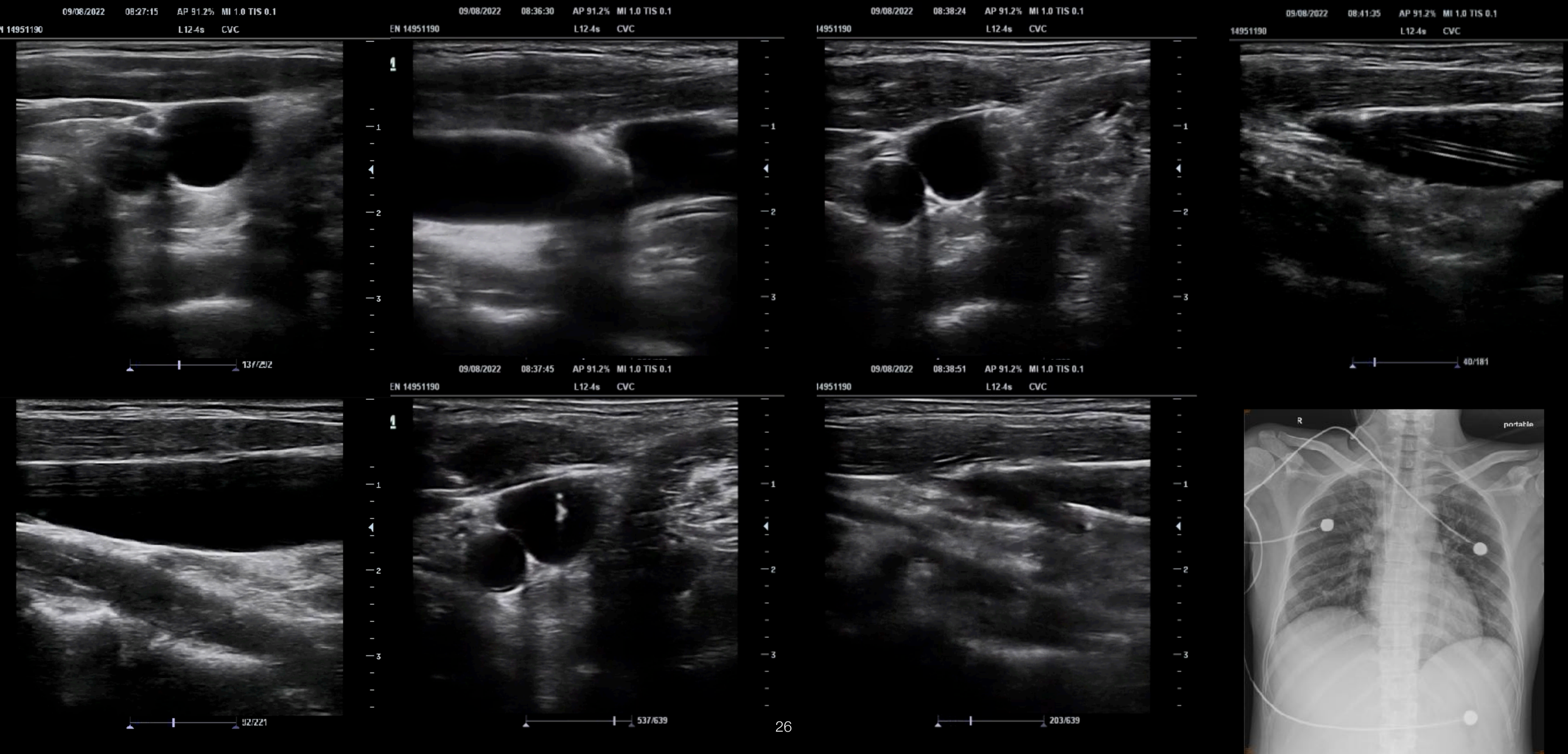

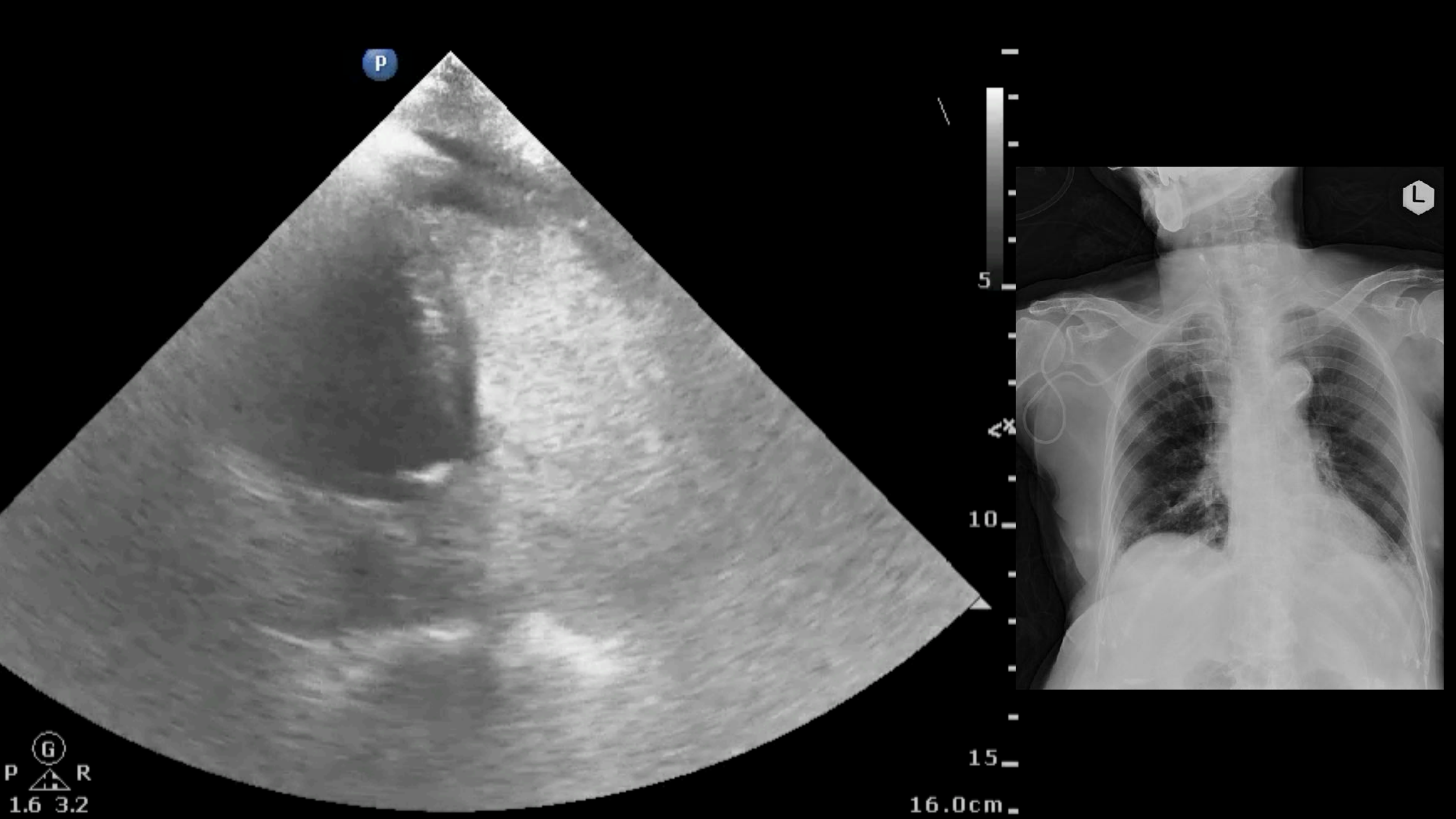
P
5
10
15
16.0cm
G
P
R
1.6 3.2
L

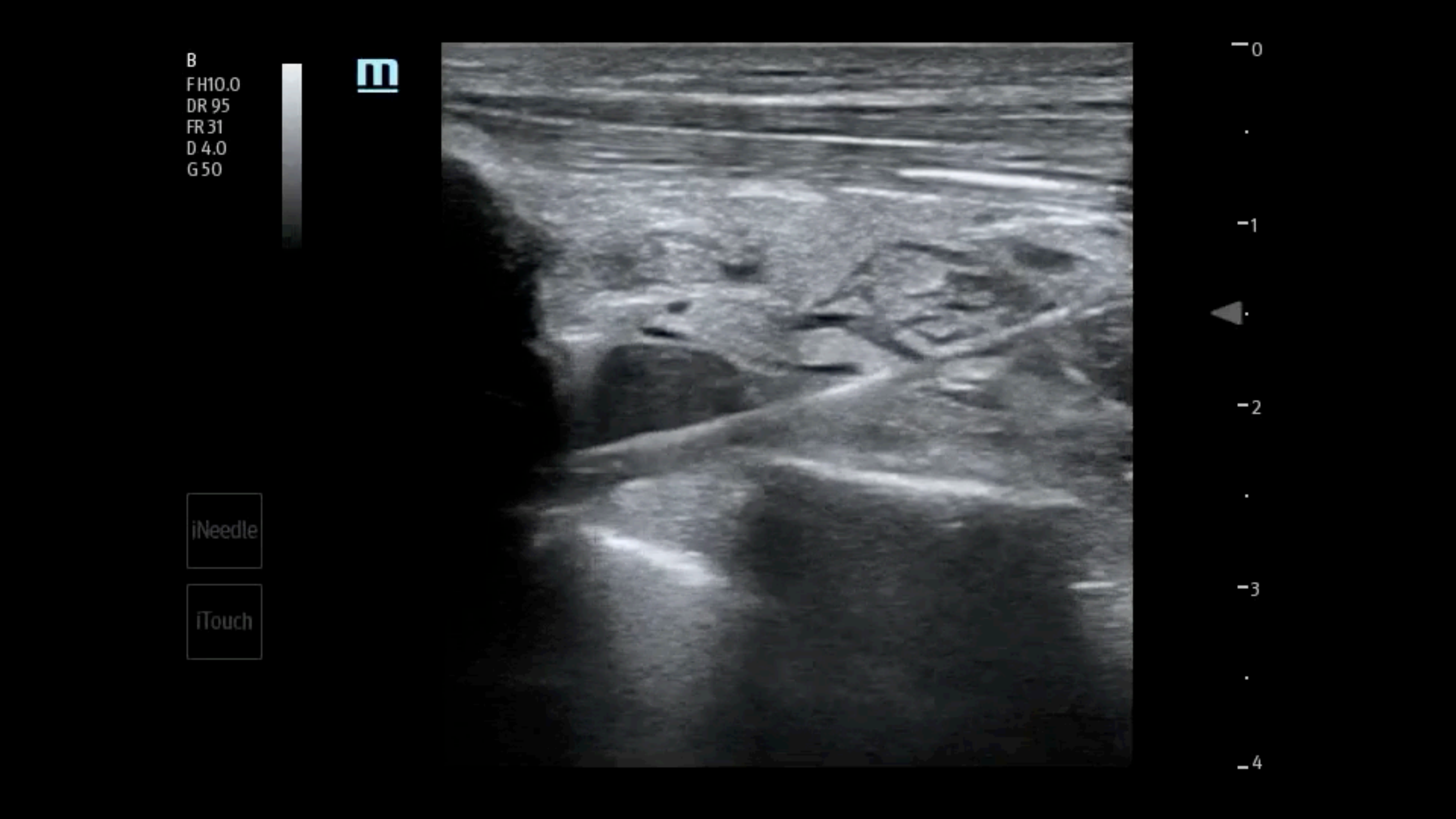
B
F H10.0
DR 95
FR 31
D 4.0
G 50
iNeedle
iTouch
0
1
2
3
4

合適血管

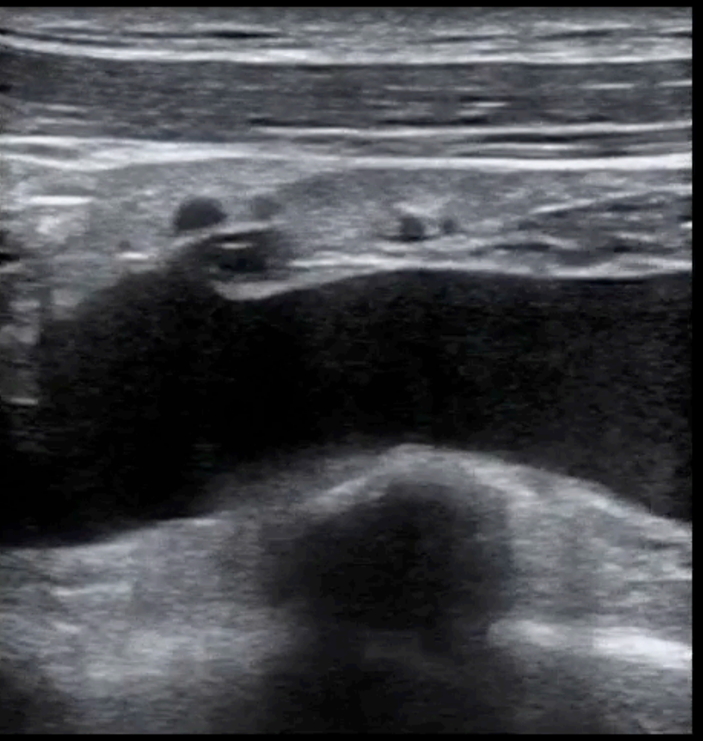

熟練運針

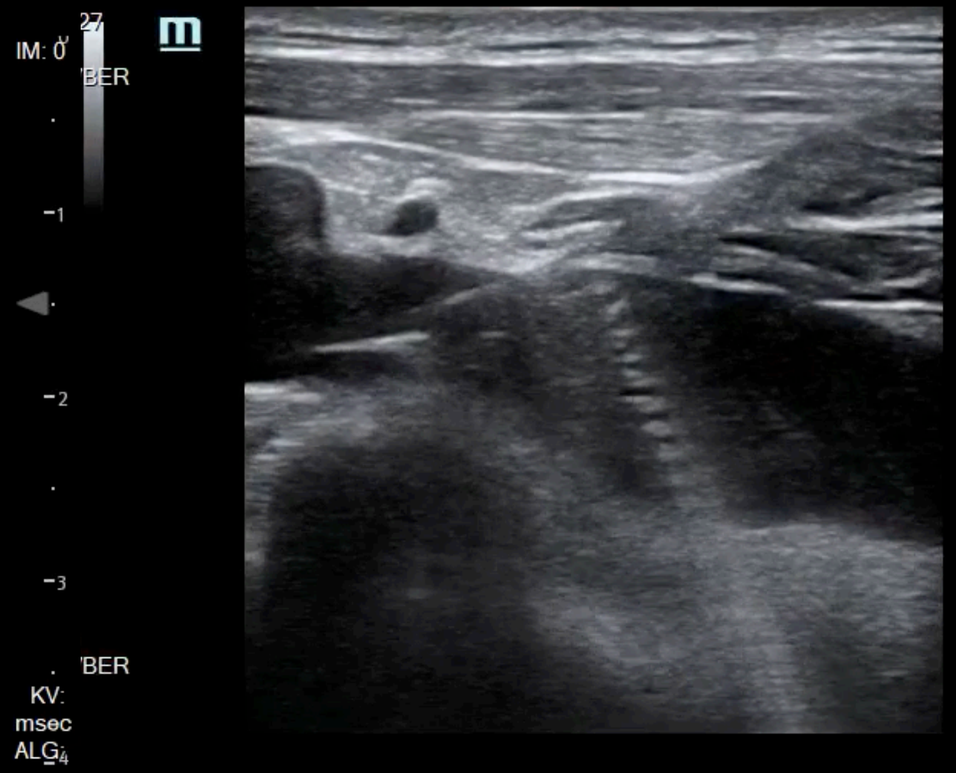

確認導線

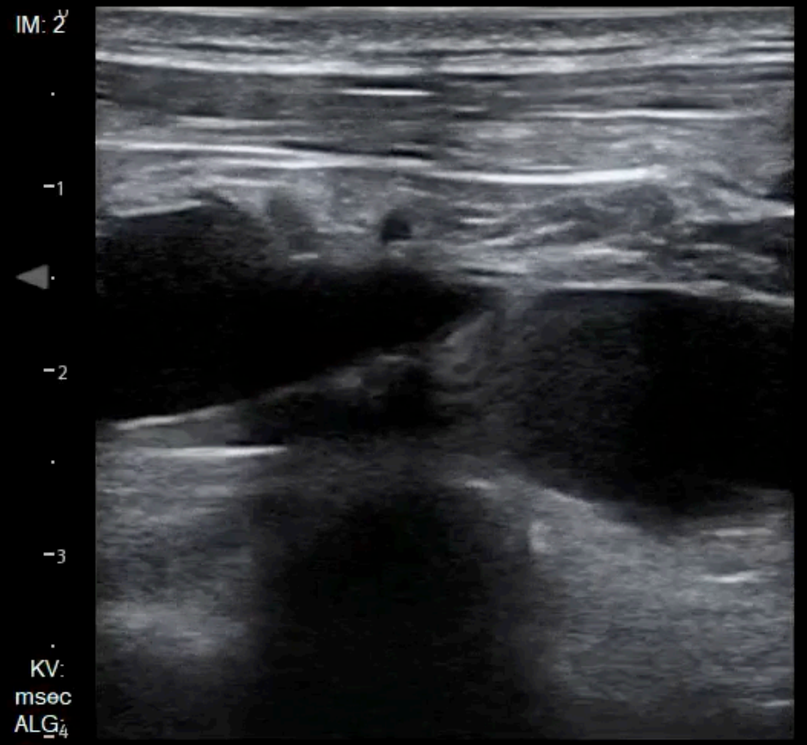

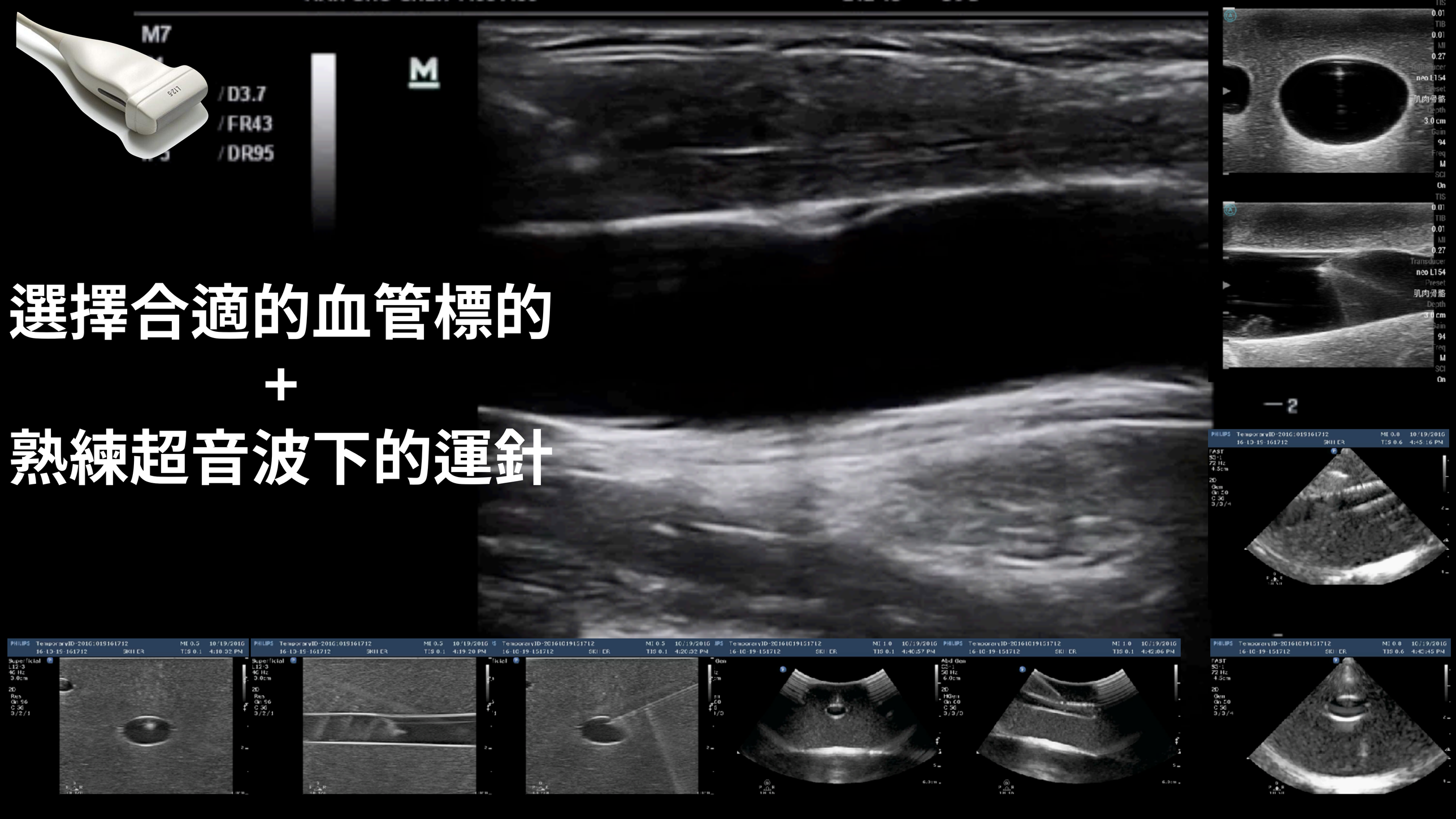

選擇合適的血管標的

+

熟練超音波下的運針