PICC

Peripherally Inserted Central Catheter

陳國智醫師 雙和醫院急診醫學科

juice119@gmail.com/ POCUSacademy.com

先進與革新急症技術中心 / Advanced & Revolutionary Technology center

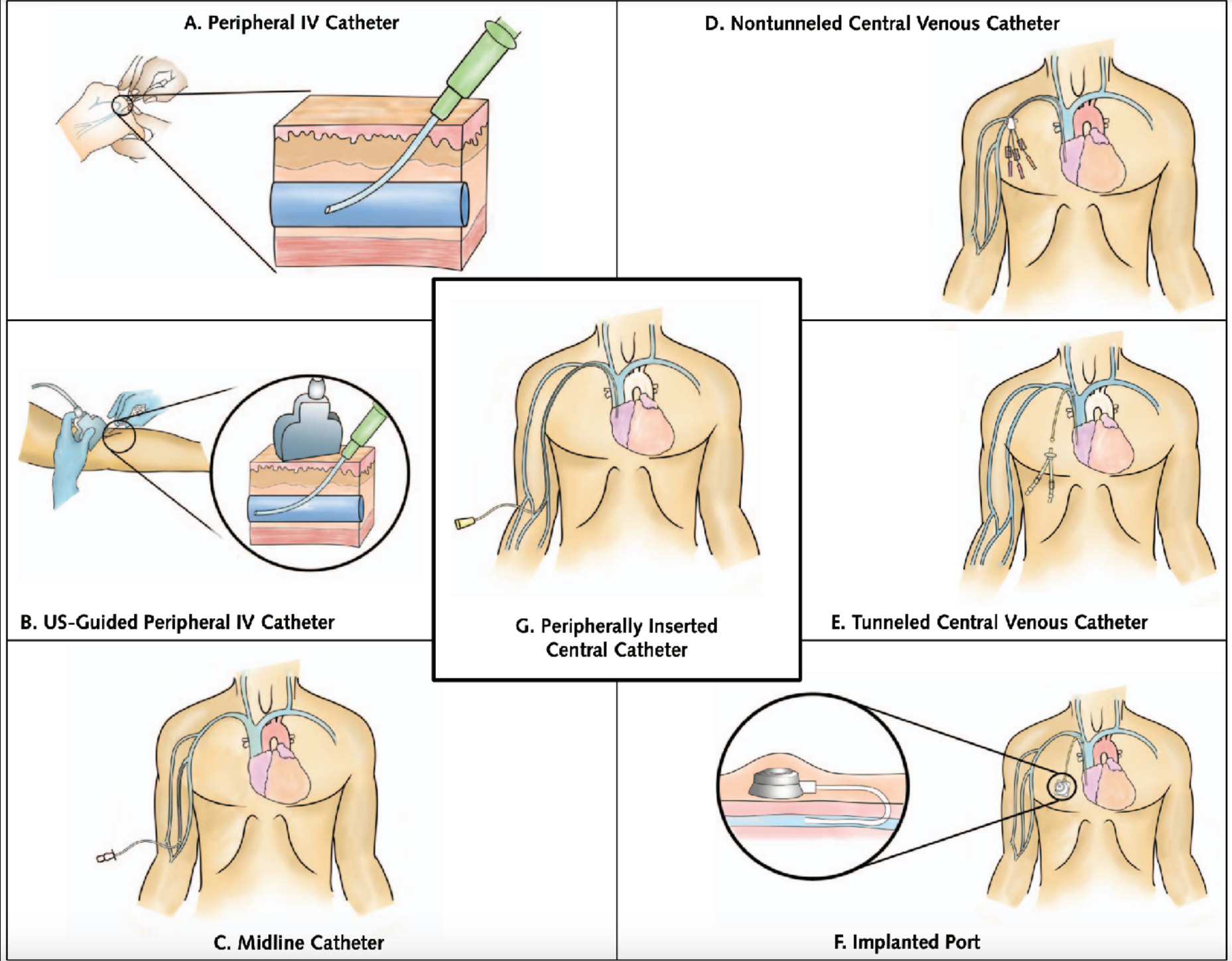

Annals of Internal Medicine SUPPLEMENT

The Michigan Appropriateness Guide for Intravenous Catheters (MAGIC): Results From a Multispecialty Panel Using the RAND/UCLA Appropriateness Method

Vineet Chopra, MD, MSc; Scott A. Flanders, MD; Sanjay Saint, MD, MPH; Scott C. Woller, MD; Naomi P. O'Grady, MD; Nasia Safdar, MD, PhD; Scott O. Trerotola, MD; Rajiv Saran, MD, PhD; Nancy Moureau, BSN, RN; Stephen Wiseman, PharmD; Mauro Pittiruti, MD; Elie A. Akl, MD, MPH, PhD; Agnes Y. Lee, MD, MSc; Anthony Counsey, MD; Lakshmi Swaminathan, MD; Jack LeDonne, MD; Carol Becker, MHSA; Sarah L. Krein, PhD, RN; and Steven J. Bernstein, MD, MPH

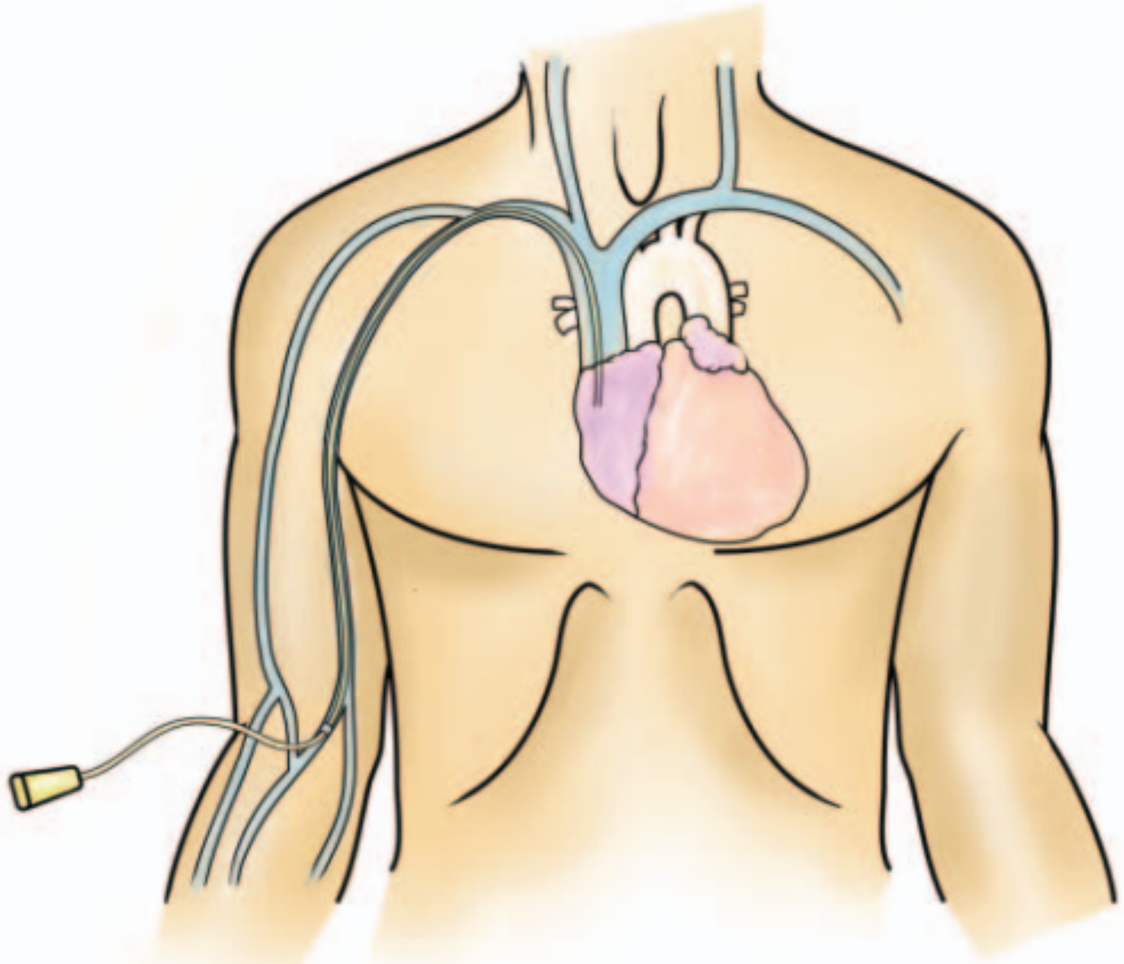

週邊置入中心靜脈導管

G. Peripherally Inserted Central Catheter

MAGIC

Michigan Appropriateness Guide for Intravenous Catheters

經週邊給予輸液時的建議

Chopra V, Ann Intern Med, 2015

Device Type	Proposed Duration of Infusion			
	≤5 d	6–14 d	15–30 d	≥31 d
Peripheral IV catheter	No preference between peripheral IV and US-guided peripheral IV catheters for use ≤5 d			
US-guided peripheral IV catheter	US-guided peripheral IV catheter preferred to peripheral IV catheter if proposed duration is 6–14 d			
Nontunneled/acute central venous catheter	Central venous catheter preferred in critically ill patients or if hemodynamic monitoring is needed for 6–14 d			
Midline catheter	Midline catheter preferred to PICC if proposed duration is ≤14 d			
PICC		PICC preferred to midline catheter if proposed duration of infusion is ≥15 d		
Tunneled catheter				PICC preferred to tunneled catheter and ports for infusion 15–30 d
Port				

Appropriate | Neutral | Inappropriate | Disagreement

無法由週邊管路治療時的建議

Chopra V, Ann Intern Med, 2015

Device Type	Proposed Duration of Infusion			
	≤5 d	6–14 d	15–30 d	≥31 d
Peripheral IV catheter				
US-guided peripheral IV catheter				
Nontunneled/acute central venous catheter	Central venous catheter preferred in critically ill patients or if hemodynamic monitoring is needed for 6–14 d			
Midline catheter				
PICC		PICCs rated as appropriate at all proposed durations of infusion		
Tunneled catheter		Tunneled catheter neutral for for use ≥15 d	No preference between tunneled catheter and PICC for proposed durations ≥15 d	
Port				No preference among port, tunneled catheter, or PICC for ≥31 d

Appropriate | Neutral | Inappropriate | Disagreement

困難靜脈管路建立時的建議

Chopra V, Ann Intern Med, 2015

Device Type	Proposed Duration of Infusion			
	≤5 d	6–14 d	15–30 d	≥31 d
Peripheral IV catheter	No preference between peripheral IV and US-guided peripheral IV catheters for use ≤5 d			
US-guided peripheral IV catheter	US-guided peripheral IV catheters preferred to peripheral IV catheters if proposed duration is 6–14 d			
Midline catheter	Midline catheters preferred to PICC if proposed duration is ≤14 d			
Nontunneled/acute central venous catheter	Central venous catheter preferred to PICC for use ≤14 d in critically ill patients			
PICC	Disagreement on appropriateness of PICC for durations <5 d	PICC use appropriate if proposed duration is ≥6 d; PICCs preferred to tunneled catheters for durations of 15–30 d		
Tunneled catheter			Tunneled catheter neutral for difficult IV access for use ≥15 d	No preference between tunneled catheter or port for use ≥31 d
Port				

Appropriate | Neutral | Inappropriate | Disagreement

需要經常抽血時的建議

Chopra V, Ann Intern Med, 2015

Device Type	Proposed Duration of Infusion			
	≤5 d	6–14 d	15–30 d	≥31 d
Peripheral IV catheter	No preference between peripheral IV and US-guided peripheral IV catheter for use ≤5 d US-guided peripheral IV catheter preferred if venous access difficult			
US-guided peripheral IV catheter				
Midline catheter	Midline catheter preferred to PICCs if proposed duration is ≤14 d		Midline catheter neutral for frequent phlebotomy at this duration	
Nontunneled/acute central venous catheter	Central venous catheter preferred to PICC for use ≤14 d in critically ill patients			
PICC	Disagreement on appropriateness of PICC for durations <5 d	PICC use appropriate if proposed duration ≥6 d; PICC preferred to tunneled catheter for durations of 15–30 d		
Tunneled catheter			Tunneled catheter neutral for difficult intravenous access for use ≥15 d	
Port	Ports inappropriate for frequent phlebotomy, regardless of proposed duration of use			

Appropriate | Neutral | Inappropriate | Disagreement

21:19

Question 1 of 5

Which of the following indication are you ordering a PICC for?

(select one)

- IV Antibiotics
- Vesicant or Irritant Chemotherapy
- Non chemotherapy Vesicant or Irritant
- Difficult Venous Access
- Frequent Blood Draws

21:20

Duration

What is your proposed duration of therapy?

(select one)

- Less than 5 days
- 6-14 days
- 15-30 days
- More than 31 days

21:20

Recommendations

Appropriate | Inappropriate

Click (i) for preference recommendations

- PICC (i)
- Tunneled Catheter (i)
- Peripheral IV Catheter
- Ultrasound Guided Peripheral Catheter
- Non-tunneled/Acute Central Venous Catheter

21:20

Preference

PICCs rated as appropriate at all proposed duration of Infusion

Click here to see the MAGIC algorithm

OK

Critical and Honest Conversations

The Evidence Behind the "Choosing Wisely" Campaign Recommendations by the American Society of Nephrology

Williams, Amy W.; Dwyer, Amy C.; Eddy, Allison A.; Fink, Jeffrey C.; Jaber, Bertrand L.; Linas, Stuart L.; Michael, Beckie; O'Hare, Ann M.; Schaefer, Heidi M.; Shaffer, Rachel N.; Trachtman, Howard; Weiner, Daniel E.; Falk, and Ronald J.

Author Information

Clinical Journal of the American Society of Nephrology 7(10):p 1664-1672, October 2012. | *DOI:* 10.2215/CJN.04970512

Avoid PICC on Patients with eGFR <45ml/min

4. Preserving veins for future creation of an arteriovenous fistula (AVF) is paramount to ensure better outcomes for patients with CKD who may eventually need HD.

CWCr: "Do not place peripherally inserted central venous catheters (PICCs) in stage 3–5 CKD patients without consulting nephrology."

Peripherally Inserted Central Catheter lines for Intensive Care Unit and onco-hematologic patients: A systematic review and meta-analysis

Georgios Mavrovounis, MD[a,*], Maria Mermiri, MD[a], Dimitrios G Chatzis, MD, PhD[b], Ioannis Pantazopoulos, MD, MSc, PhD[a]

[a] *Department of Emergency Medicine, Faculty of Medicine, School of Health Sciences, University of Thesstaly, General University Hospital of Larissa, Mezourlo 41110, Larissa, Greece*

[b] *School of Medicine, European University of Cyprus, Nicosia, Cyprus, Diogenous Str 2404, Nicosia, Cyprus*

Mavrovounis G, et al. Heart Lung 2020

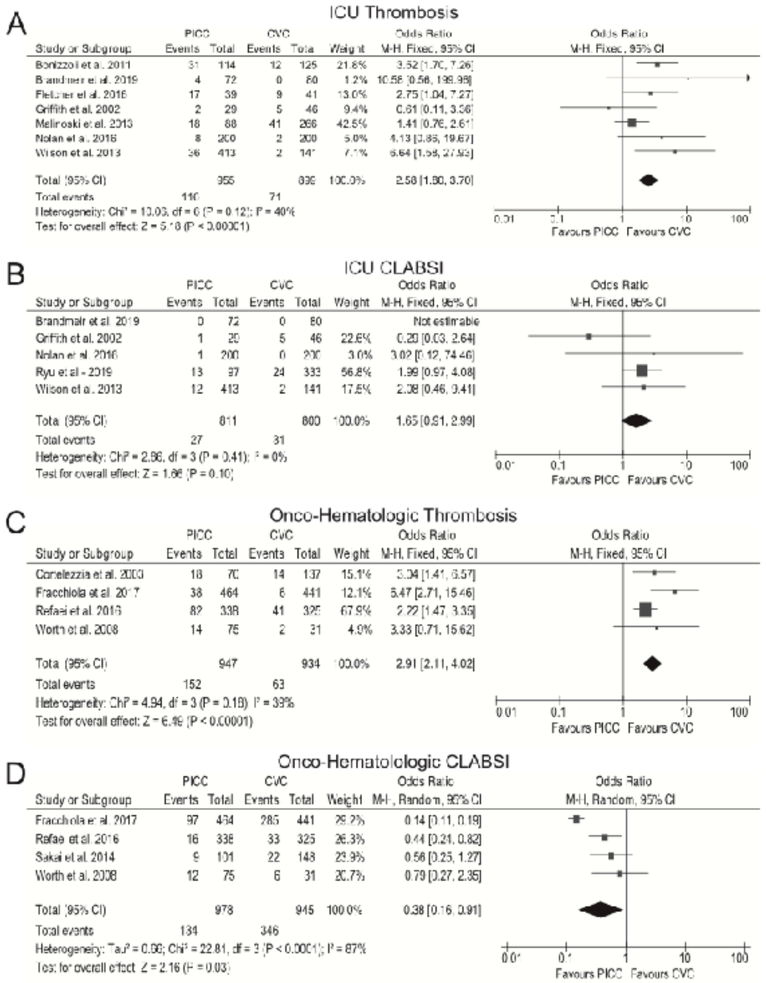

Thrombosis risk

PICC > CVC

CLABSI risk

CVC > PICC onco-hematologic patients

PICC併發症

Infection (CRBSI 1.1/1000 PICC days)
Catheter malposition / migration
Mechanical malfunction (10 ~ 27%)
Phlebitis / infiltration (2.2% ~ 23%)
Air embolism
Cardiac arrhythmia
Catheter occlusion-thrombotic
High SVC 78% v.s. Distal SVC/RA 16%
Catheter occlusion-non-thrombotic

常用的靜脈導管比較

黃耀廣醫師網站 HTTPS://WWW.CVSDOCTOR.COM/PICC-INTRODUCTION/

輸液導管	週邊靜脈留置針	週邊置入中心靜脈導管	中央靜脈導管
		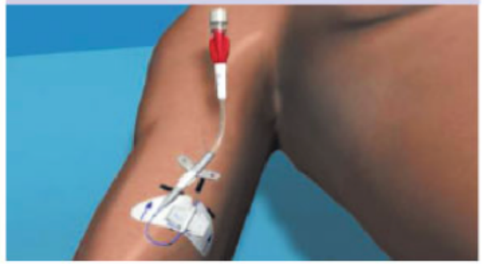	
留置時間	需要每3天更換	半年以上	每7至10 天需更換
置放者	由護理師置放	由醫師置放	由醫師置放
功能	當靜脈輸液的酸鹼值和滲透壓值和血液不同時，容易刺激血管內皮細胞而造成損傷，進而形成化學性的血栓	可監測中心靜脈壓(威力週邊置入中心導管、中央靜脈導管) 有雙腔、三腔管路，可同時提供病人多種或大量輸液 具刺激性之化學治療藥物建議應由中心靜脈導管給予，尤其是起皰性的化學治療藥物，為了避免藥物外滲時所造成的重大傷害	
合併症	無重大併發症 可能引起靜脈炎、藥物外滲、皮膚壞死	無重大併發症	放置過程可能會產生氣、血胸、大動脈穿刺、血栓感染機率較高
抽血	每次抽血均需重覆扎針	放置後**不需**重覆紮針， 自外露管路抽血即可	放置後**不需**重覆紮針， 自外露管路抽血即可
電腦斷層	由留置針施打顯影劑 可能會造成顯影劑外滲	自管路直接施打顯影劑即可 (威力週邊置入中心導管)	仍需另放置週邊靜脈留置針 (可能會造成顯影劑外滲)
放置部位	前臂或手易影響活動	手臂上段內側，**不會影響活動**	頸部或鼠蹊部，易影響活動

PICC在病人端的好處

不會影響活動、較舒適和美觀

抽血給藥方便、不必反覆挨針

藥物注射時無疼痛、化療藥物不外漏較安全

可以保護血管、療程結束後即可移除

黃耀廣醫師網站 HTTPS://WWW.CVSDOCTOR.COM/PICC-INTRODUCTION/

PICC在醫療端的好處

低侵入性、重大合併症不易發生

可長期放置、可給特殊性輸液及藥物

臨床照護較CVC容易、感染率也較低

PRESSURE INJECTABLE (CT)

黃耀廣醫師網站 HTTPS://WWW.CVSDOCTOR.COM/PICC-INTRODUCTION/

第六卷第四期
刊登日期：2023/08/31
Taiwan Emergency Medicine Bulletin 6(4)：e2023060408

How I do it: 如何在急診開始第一隻PICC？

下載PDF 分享 分享

王鎮玡、范閎皓、陳國智、翁健瑞

衛生福利部雙和醫院 急診醫學科

台灣急診醫學通訊

第六卷第四期
刊登日期：2023/08/31
Taiwan Emergency Medicine Bulletin 6(4)：e2023060408

How I do it: 如何在急診開始第一隻PICC？

下載PDF 分享 分享

王鎮玡、范閎皓、陳國智、翁健瑞

衛生福利部雙和醫院 急診醫學科

台灣急診醫學通訊

PICC 週邊置入中心靜脈導管

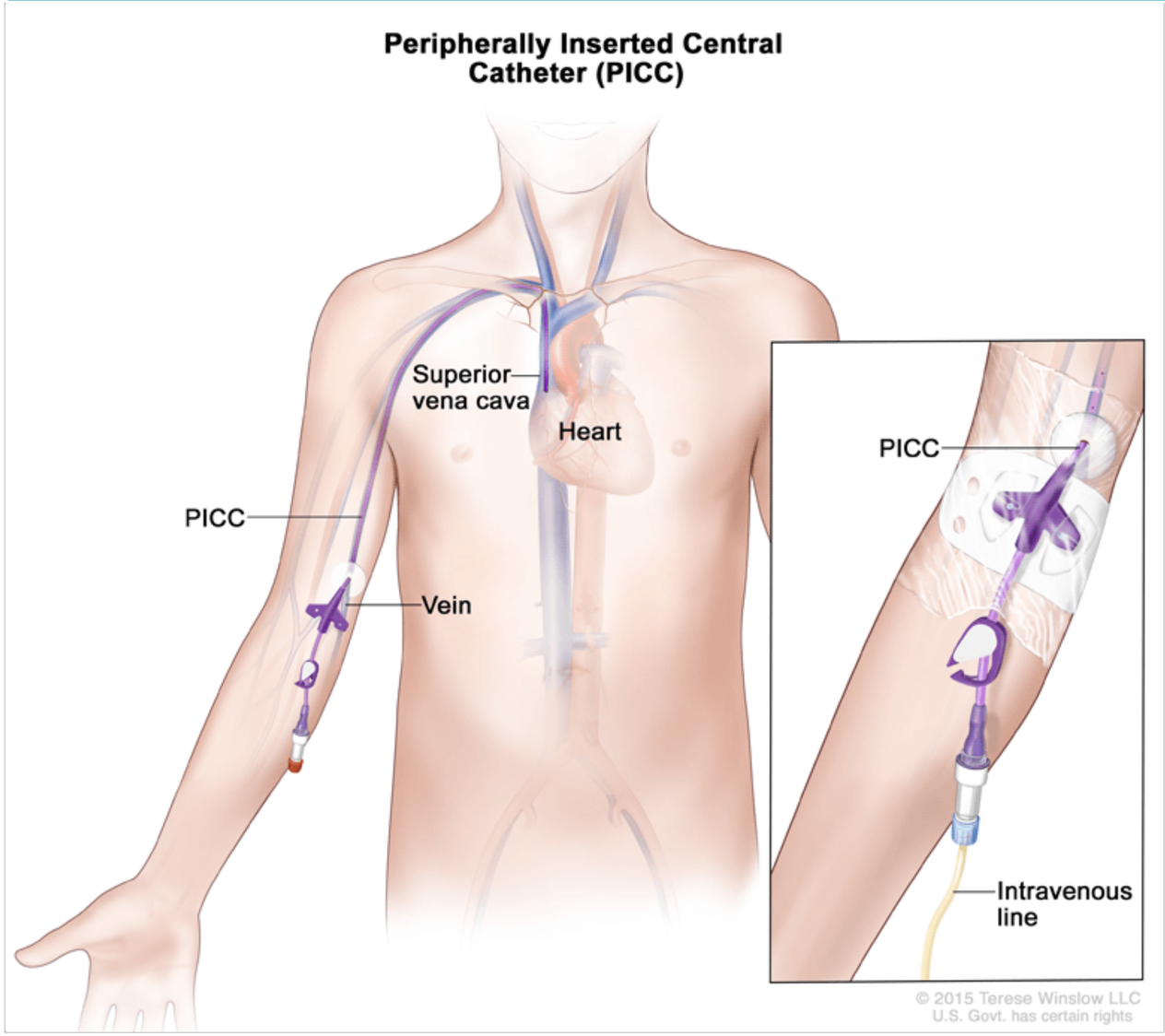

適應情境

置放選擇

導管置放

確認位置

管路照護

Teleflex Pressure Injectable PICC

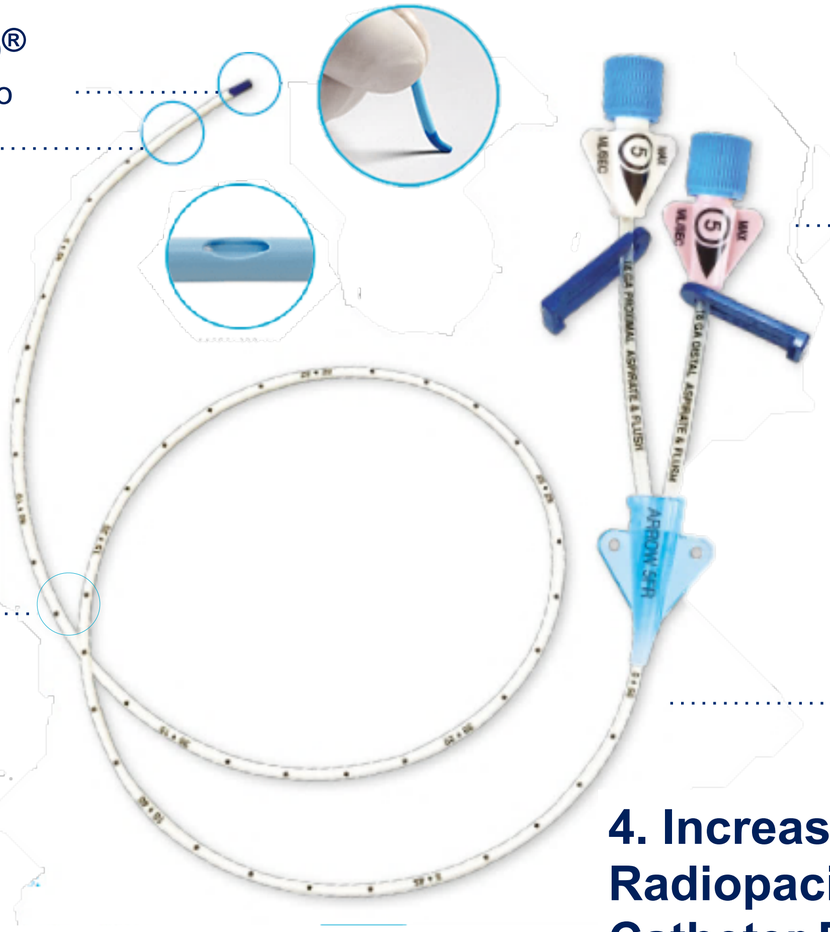

1. BlueFlex Tip®
Soft, reduces damage to delicate intima during threading process[1]

2.Staggered Exit Ports
Reduce risk of mixing incompatible drugs and solutions that may create precipitate[2]

3.Labeled Depth Marker
Every 1 cm on Catheter Body

4. Increase Radiopacity of Catheter Body

5.Taper-Free Catheter
Allow for increase blood flow around the catheter and minimizes risk of Catheter related thrombosis

6.Indicate Maximum Injection Rates

PICC健保支付標準 - 4適應症

47065B 點數 3101 (111.3.1 ~)

癌症化學治療及癌症末期之疼痛治療

下列三項適應症且預期同時治療達二週以上之病人

-使用全靜脈營養輸液(TPN)(1歲以下嬰兒本項為靜脈營養輸液，不限TPN)

-免疫不全與使用免疫抑制劑

-須接受中心靜脈導管置入(CVC)

PICC可放置期間

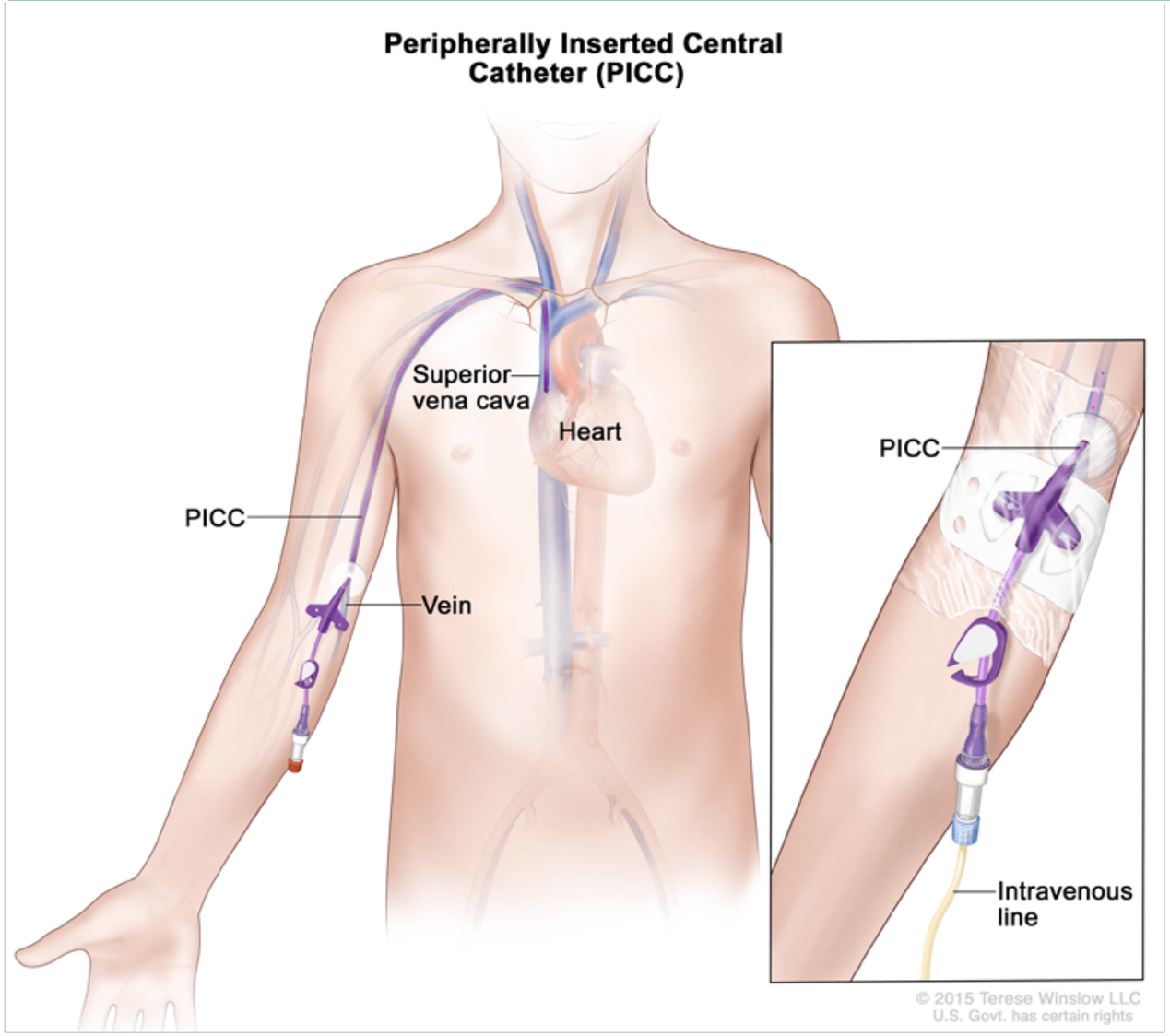

6個月 ~ 1年

Editorial

JVA The Journal of Vascular Access

The SIP protocol update: Eight strategies, incorporating Rapid Peripheral Vein Assessment (RaPeVA), to minimize complications associated with peripherally inserted central catheter insertion

The Journal of Vascular Access
1–9

Article reuse guidelines:
sagepub.com/journals-permissions
DOI: 10.1177/11297298221099838
journals.sagepub.com/home/jva
SAGE

Fabrizio Brescia[1], Mauro Pittiruti[2], Timothy R Spencer[3] and Robert B Dawson[4]

SIP PROTOCOL

Safe insertion of PICCs

Step 1	*Pre-procedural evaluation*—choose most appropriate vein by systematic ultrasound examination of the veins of the arms (see the RaPeVA protocol)
Step 2	*Appropriate antiseptic technique*—adopt a strict policy of hand hygiene, skin antisepsis with 2% chlorhexidine in 70% isopropyl alcohol, and use of maximal barrier precautions
Step 3	*Choice of vein size and exit site*—evaluate the diameter of the vein so to have an ideal catheter-vein ratio (1:3 or less); place the exit site in the green zone (see Dawson's ZIM™); consider the opportunity of tunneling the catheter, if the most appropriate vein is in the yellow zone (see the RAVESTO protocol)
Step 4	*Clear identification of median nerve and brachial artery*—identify each structure before venipuncture, using ultrasound
Step 5	*Ultrasound-guided venipuncture*—access a deep vein of the arm (either basilic or brachial vein), preferably adopting the short axis/out-of-plane approach, and use of a micro-introducer kit
Step 6	*Ultrasound-based tip navigation*—assess the correct direction of the guidewire, by a supra-clavicular ultrasound scan (see the ECHOTIP protocol)
Step 7	*Intra-procedural assessment of tip location*—use intracavitary ECG and/or ultrasound (subcostal or apical view, using the "bubble test": see the ECHOTIP protocol)
Step 8	*Appropriate securement of the catheter and protection of the exit site*—use sutureless devices only; reduce the risk of bleeding and bacterial contamination using cyanoacrylate glue and semi-permeable transparent membrane dressings

RaPeVa protocol

Rapid Peripheral Vein Assessment

Step 1	Visualization of the cephalic vein at the antecubital fossa
Step 2	Identification of the artery and brachial veins and of the confluence between the antecubital vein and basilic vein
Step 3	Identification of the basilic vein in the bicipital-humeral groove
Step 4	Examination of the nerve-vascular bundle of the arm
Step 5	Visualization of the cephalic vein over the biceps muscle
Step 6	Examination of the axillary vein in the infraclavicular area
Step 7	Examination of the internal jugular, the subclavian, and the brachio-cephalic vein in the supraclavicular area

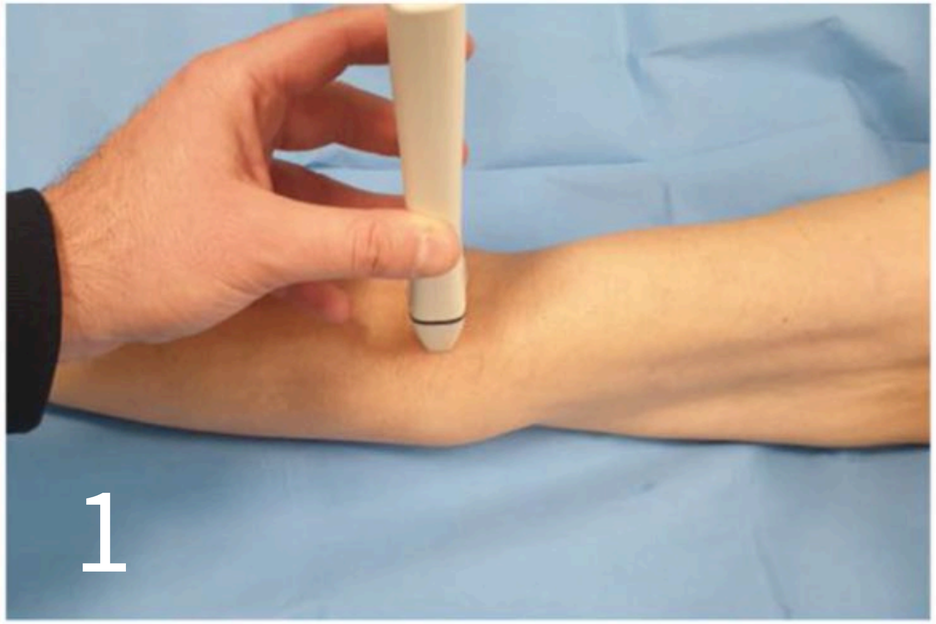

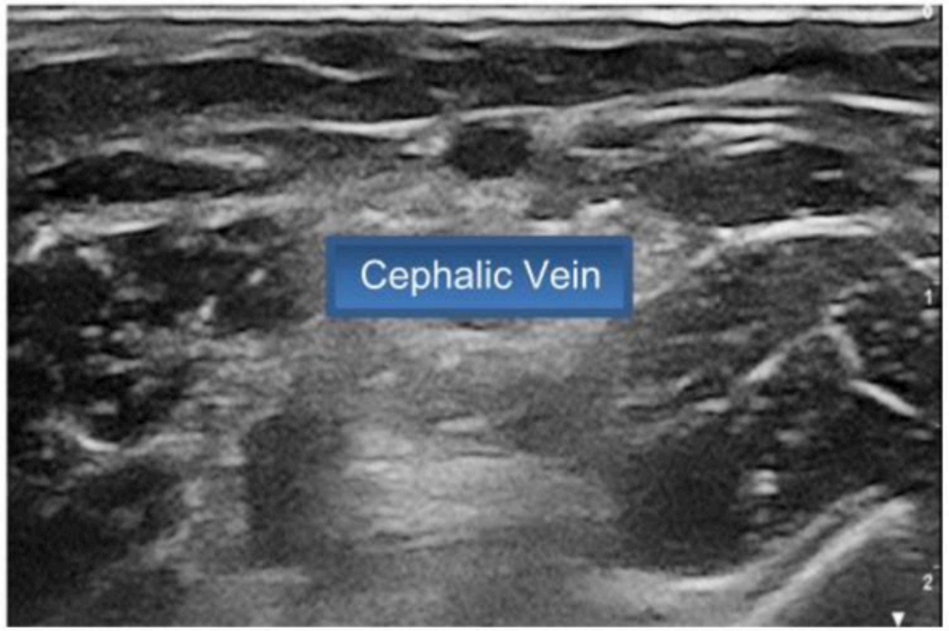

RaPeVa protocol

Rapid Peripheral Vein Assessment

Step 1	Visualization of the cephalic vein at the antecubital fossa
Step 2	Identification of the artery and brachial veins and of the confluence between the antecubital vein and basilic vein
Step 3	Identification of the basilic vein in the bicipital-humeral groove
Step 4	Examination of the nerve-vascular bundle of the arm
Step 5	Visualization of the cephalic vein over the biceps muscle
Step 6	Examination of the axillary vein in the infraclavicular area
Step 7	Examination of the internal jugular, the subclavian, and the brachio-cephalic vein in the supraclavicular area

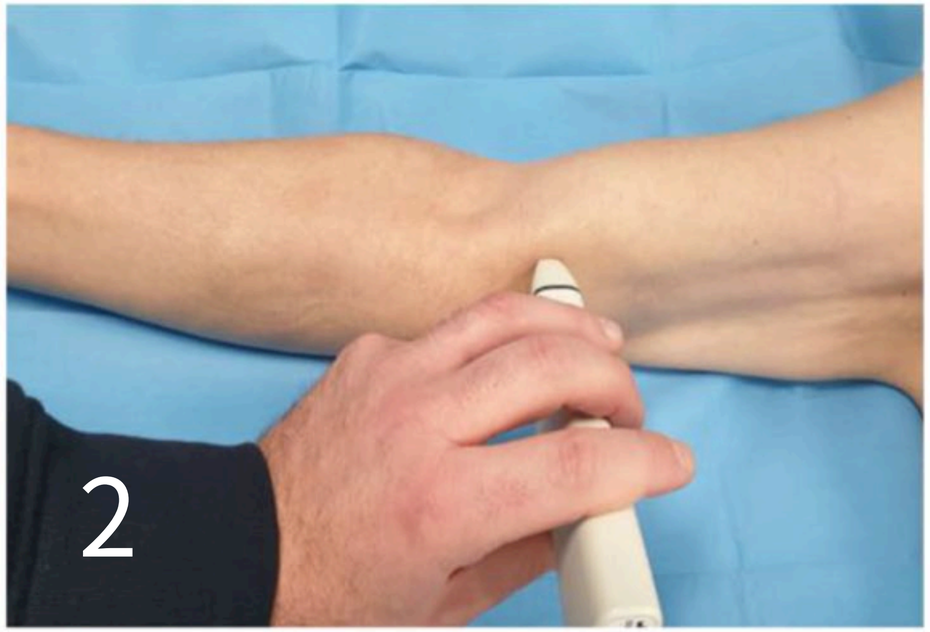

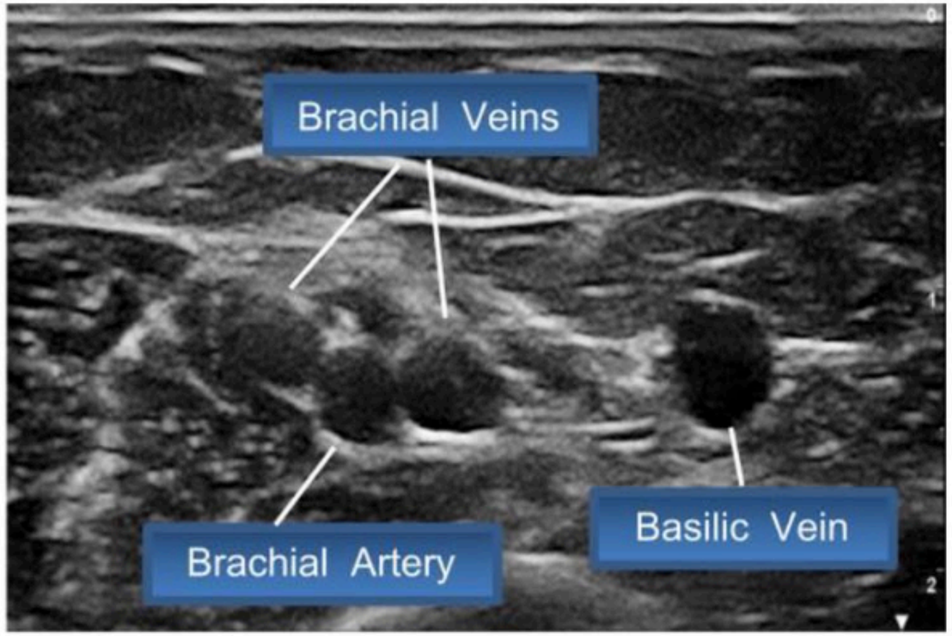

RaPeVa protocol

Rapid Peripheral Vein Assessment

Step 1	Visualization of the cephalic vein at the antecubital fossa
Step 2	Identification of the artery and brachial veins and of the confluence between the antecubital vein and basilic vein
Step 3	Identification of the basilic vein in the bicipital-humeral groove
Step 4	Examination of the nerve-vascular bundle of the arm
Step 5	Visualization of the cephalic vein over the biceps muscle
Step 6	Examination of the axillary vein in the infraclavicular area
Step 7	Examination of the internal jugular, the subclavian, and the brachio-cephalic vein in the supraclavicular area

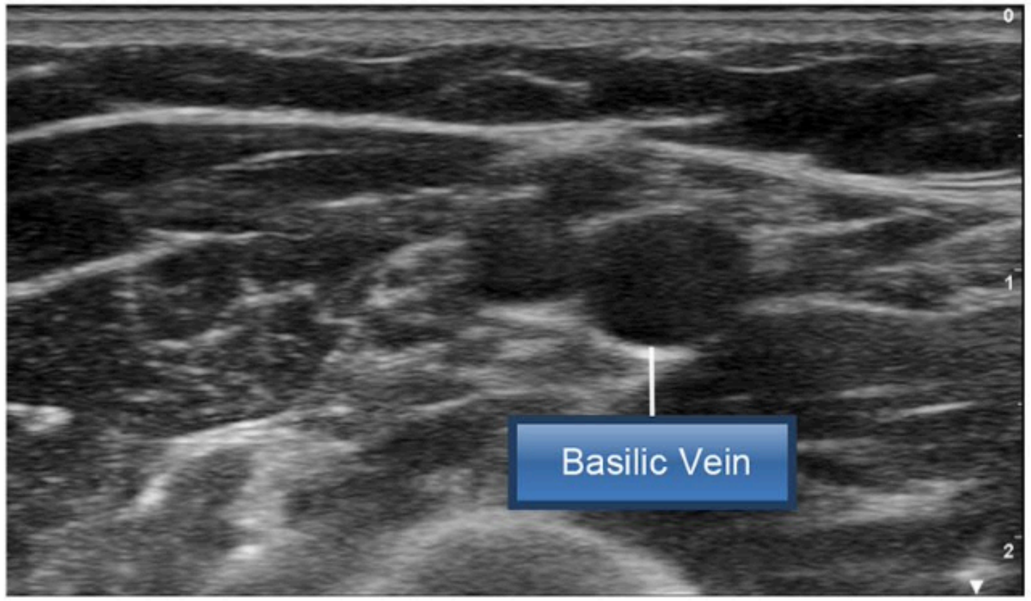

RaPeVa protocol

Rapid Peripheral Vein Assessment

Step 1	Visualization of the cephalic vein at the antecubital fossa
Step 2	Identification of the artery and brachial veins and of the confluence between the antecubital vein and basilic vein
Step 3	Identification of the basilic vein in the bicipital-humeral groove
Step 4	Examination of the nerve-vascular bundle of the arm
Step 5	Visualization of the cephalic vein over the biceps muscle
Step 6	Examination of the axillary vein in the infraclavicular area
Step 7	Examination of the internal jugular, the subclavian, and the brachio-cephalic vein in the supraclavicular area

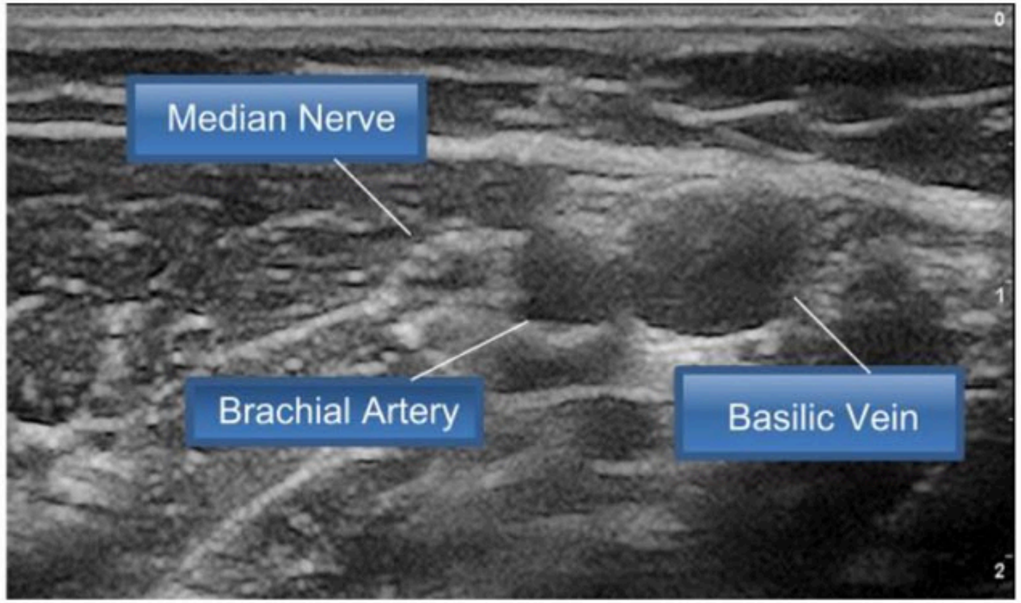

RaPeVa protocol

Rapid Peripheral Vein Assessment

Step 1	Visualization of the cephalic vein at the antecubital fossa
Step 2	Identification of the artery and brachial veins and of the confluence between the antecubital vein and basilic vein
Step 3	Identification of the basilic vein in the bicipital-humeral groove
Step 4	Examination of the nerve-vascular bundle of the arm
Step 5	Visualization of the cephalic vein over the biceps muscle
Step 6	Examination of the axillary vein in the infraclavicular area
Step 7	Examination of the internal jugular, the subclavian, and the brachio-cephalic vein in the supraclavicular area

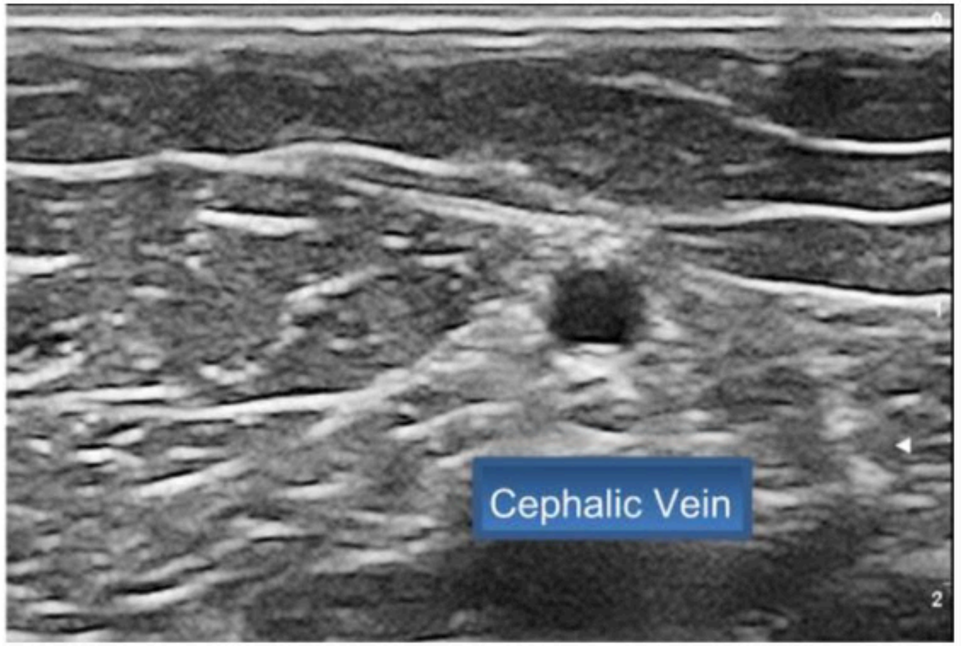

RaPeVa protocol

Rapid Peripheral Vein Assessment

Step 1	Visualization of the cephalic vein at the antecubital fossa
Step 2	Identification of the artery and brachial veins and of the confluence between the antecubital vein and basilic vein
Step 3	Identification of the basilic vein in the bicipital-humeral groove
Step 4	Examination of the nerve-vascular bundle of the arm
Step 5	Visualization of the cephalic vein over the biceps muscle
Step 6	Examination of the axillary vein in the infraclavicular area
Step 7	Examination of the internal jugular, the subclavian, and the brachio-cephalic vein in the supraclavicular area

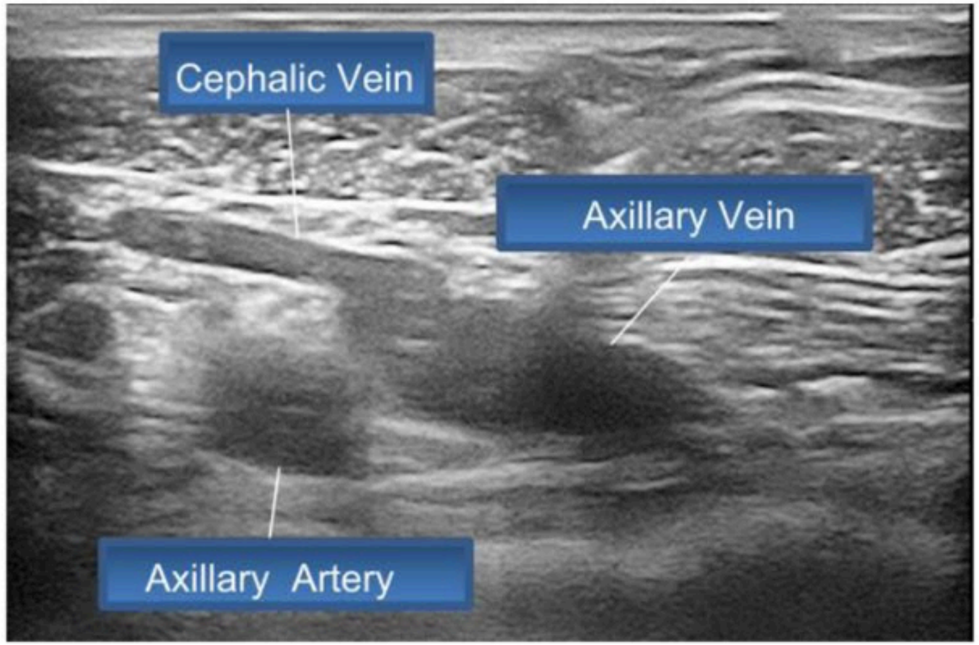

RaPeVa protocol

Rapid Peripheral Vein Assessment

Step 1	Visualization of the cephalic vein at the antecubital fossa
Step 2	Identification of the artery and brachial veins and of the confluence between the antecubital vein and basilic vein
Step 3	Identification of the basilic vein in the bicipital-humeral groove
Step 4	Examination of the nerve-vascular bundle of the arm
Step 5	Visualization of the cephalic vein over the biceps muscle
Step 6	Examination of the axillary vein in the infraclavicular area
Step 7	Examination of the internal jugular, the subclavian, and the brachio-cephalic vein in the supraclavicular area

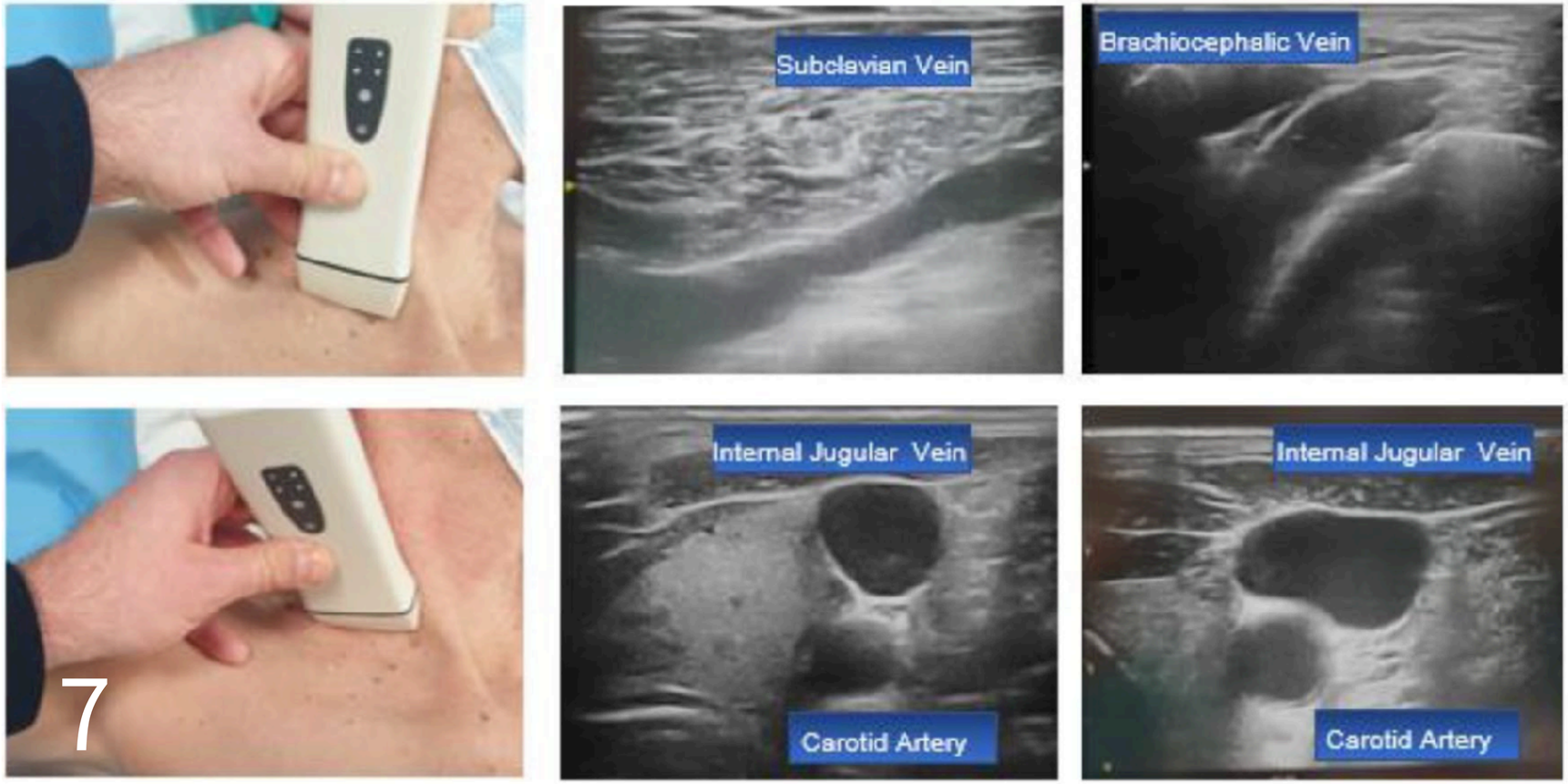

PICC置放選擇

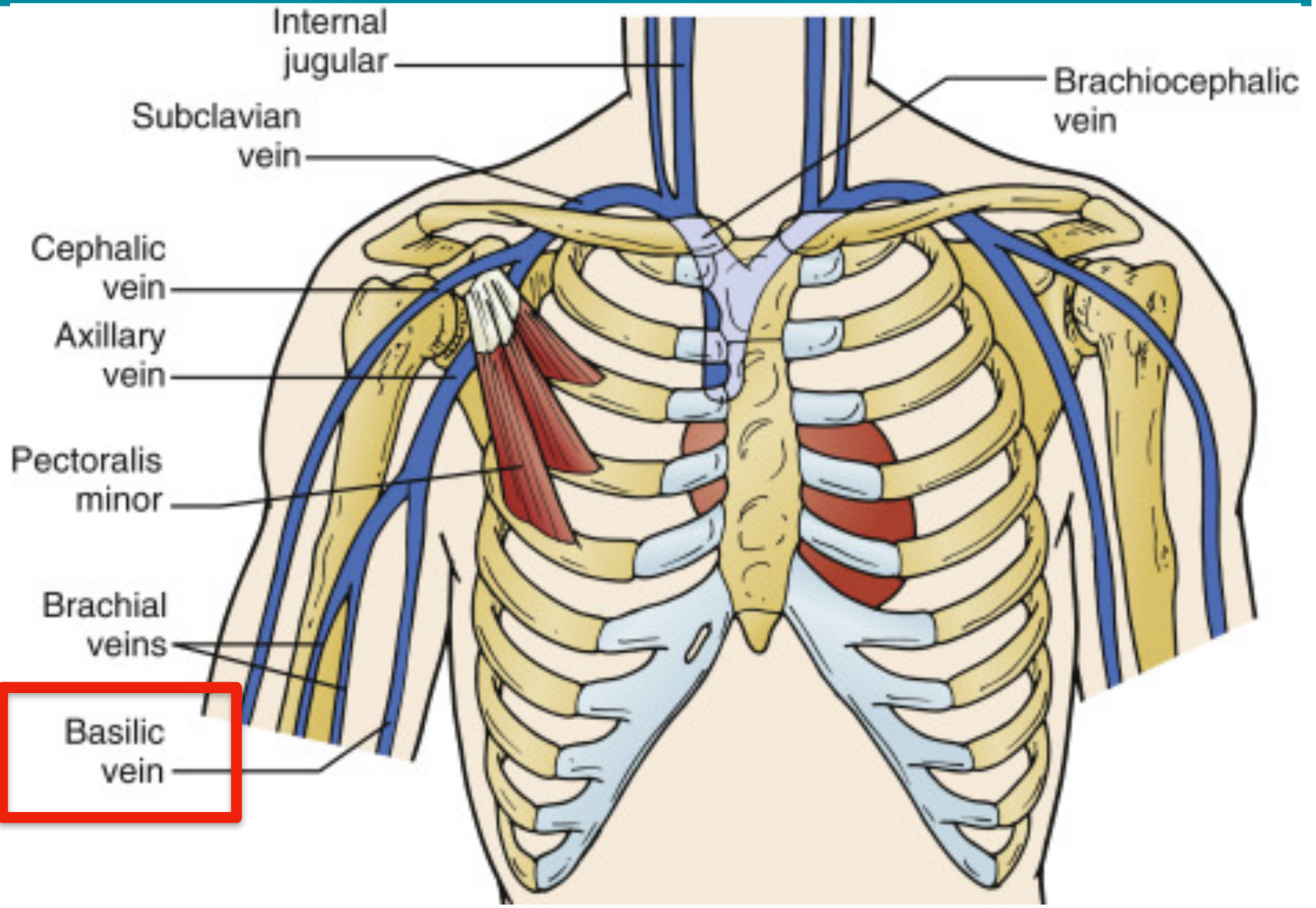
Internal jugular
Subclavian vein
Cephalic vein
Axillary vein
Pectoralis minor
Brachial veins
Basilic vein
Brachiocephalic vein

首選

APPROPRIATE VEIN
ZON INSERTION METHOD (ZIM)

	Radius of Vessel (mm)[4]	Length (CM)	Actual Diameter
Cephalic 	3[4]	38 cm	2-4 mm
Basilic 	4[4]	24 cm	4-6 mm
Axillary 	8[4]	13 cm	16 mm
Subclavian 	9.5[4]	6 cm	19 mm
SVC 	12.5[4]	7 cm	20 mm

ZIM FOR EXIT SITE

Length of the arm
(Acromion - Olecranon)

Yellow: proximal third
Green: middle third
Red: distal third

C-V RATIO

1 : 3

1Fr 0.33mm

3Fr 1mm

US GUIDED PIV

Landmark: humerus & brachial aretery

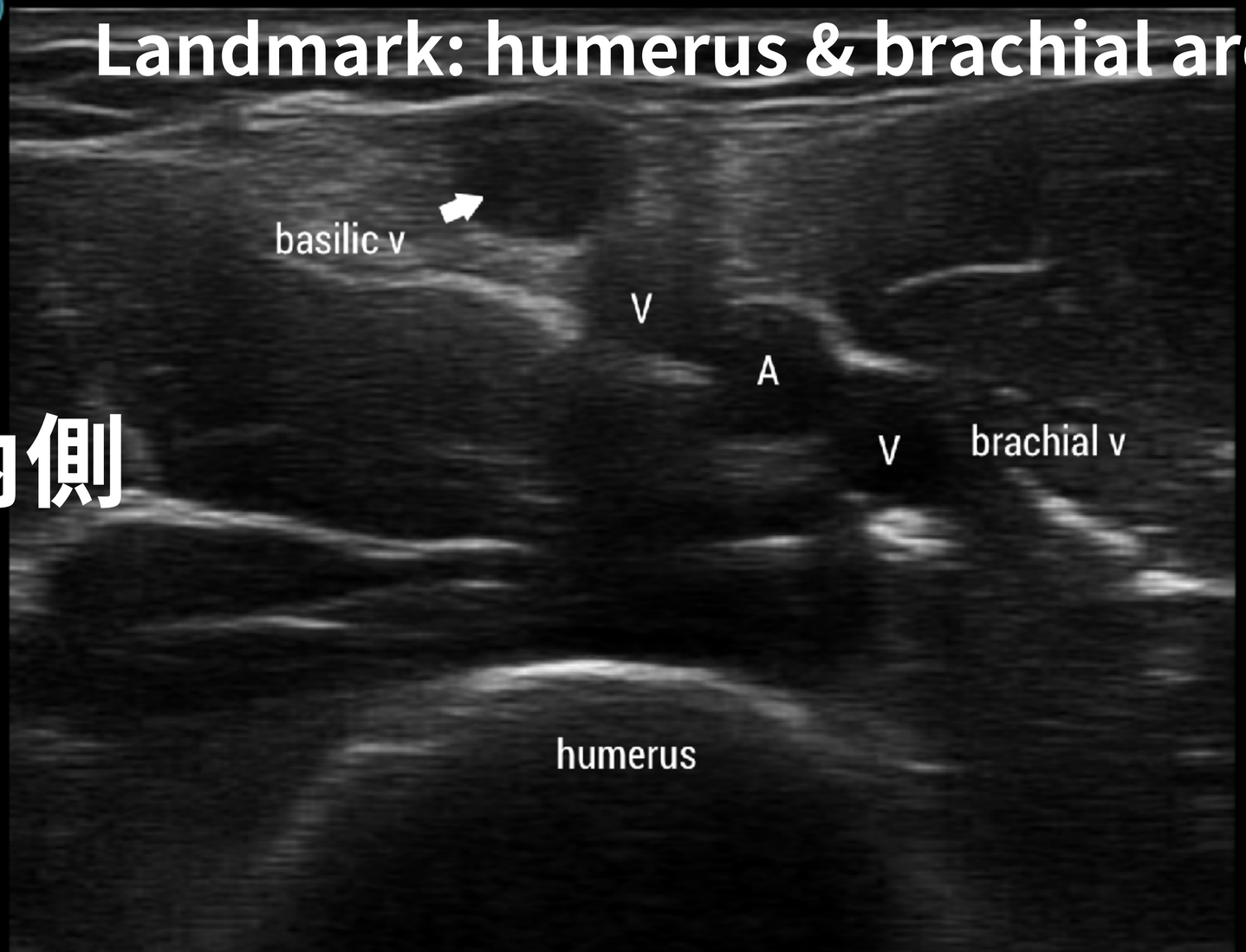

内側

外側

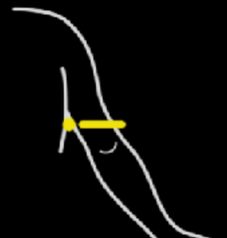

Brachial artery / vein & Basilic vein

BASILIC VEIN & BRACHIAL VEIN

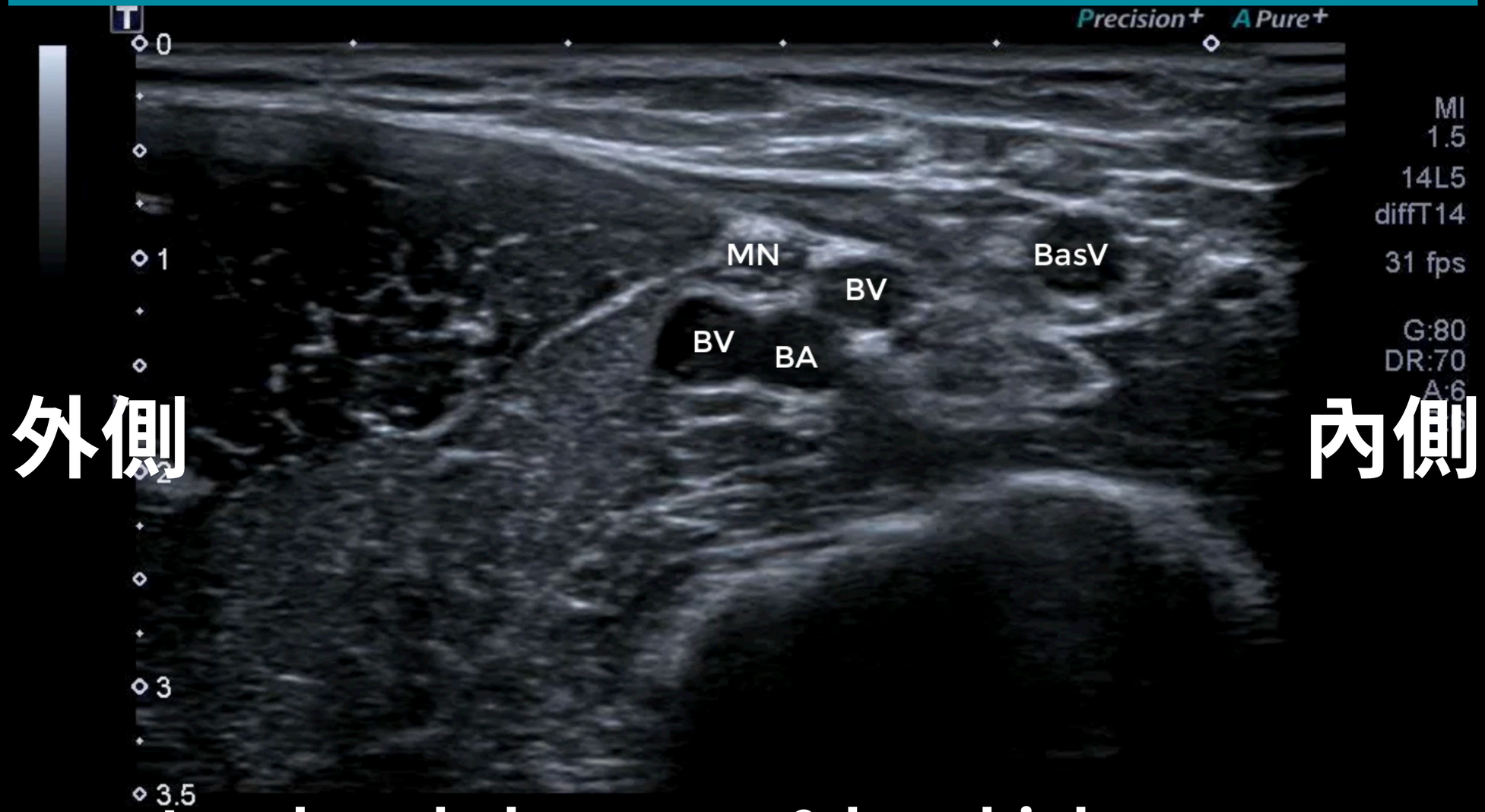

Landmark: humerus & brachial aretery

CEPHALIC VEIN

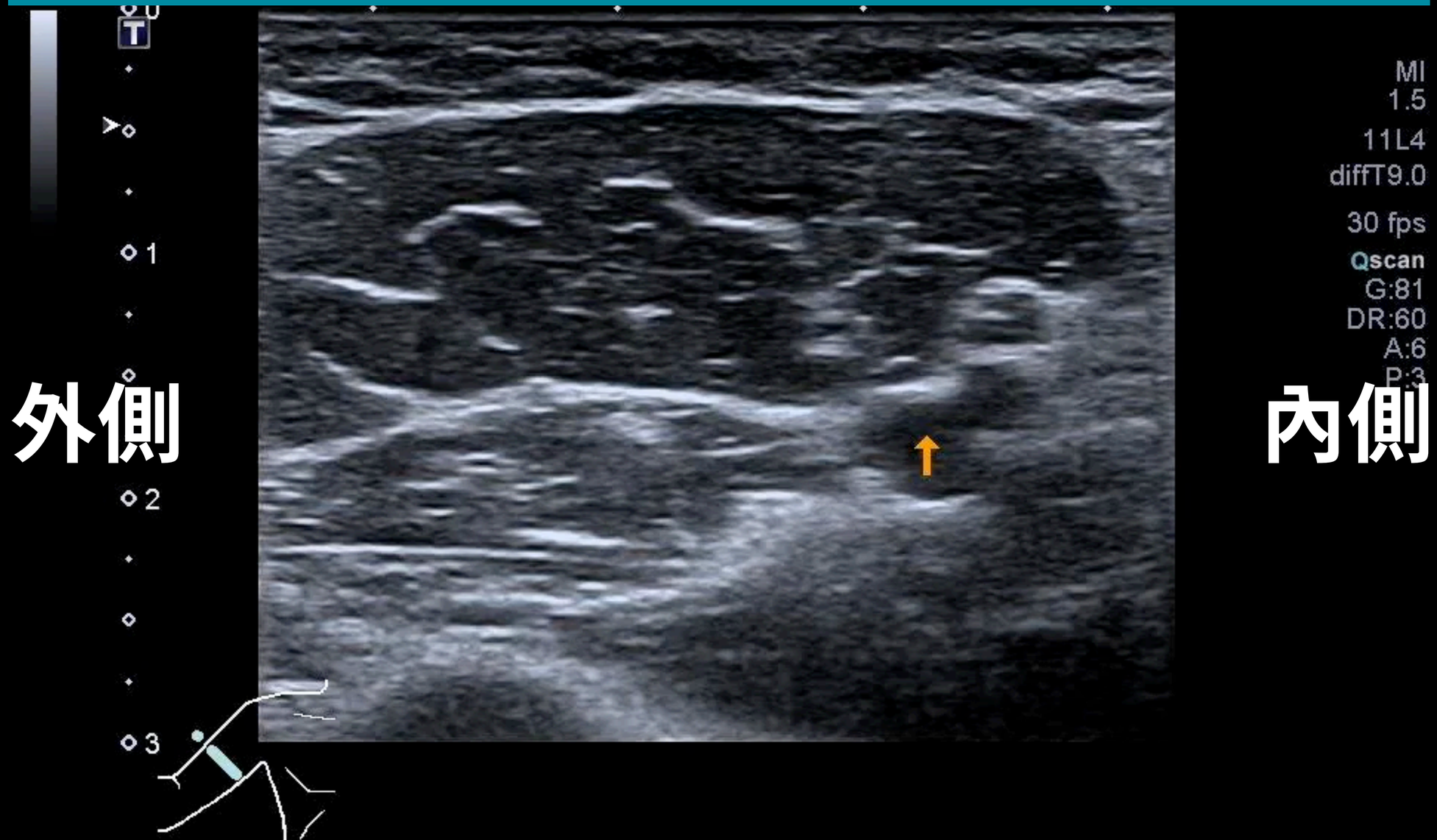

JVA The Journal of Vascular Access

Editorial

The Journal of Vascular Access
1–7

DOI: 10.1177/11297298251334888
journals.sagepub.com/home/jva
Sage

The 3 Stations of the Needle: A systematic approach for ultrasound guided venous and arterial puncture

Matthew Ostroff[1] and Nancy Moureau[2,3]

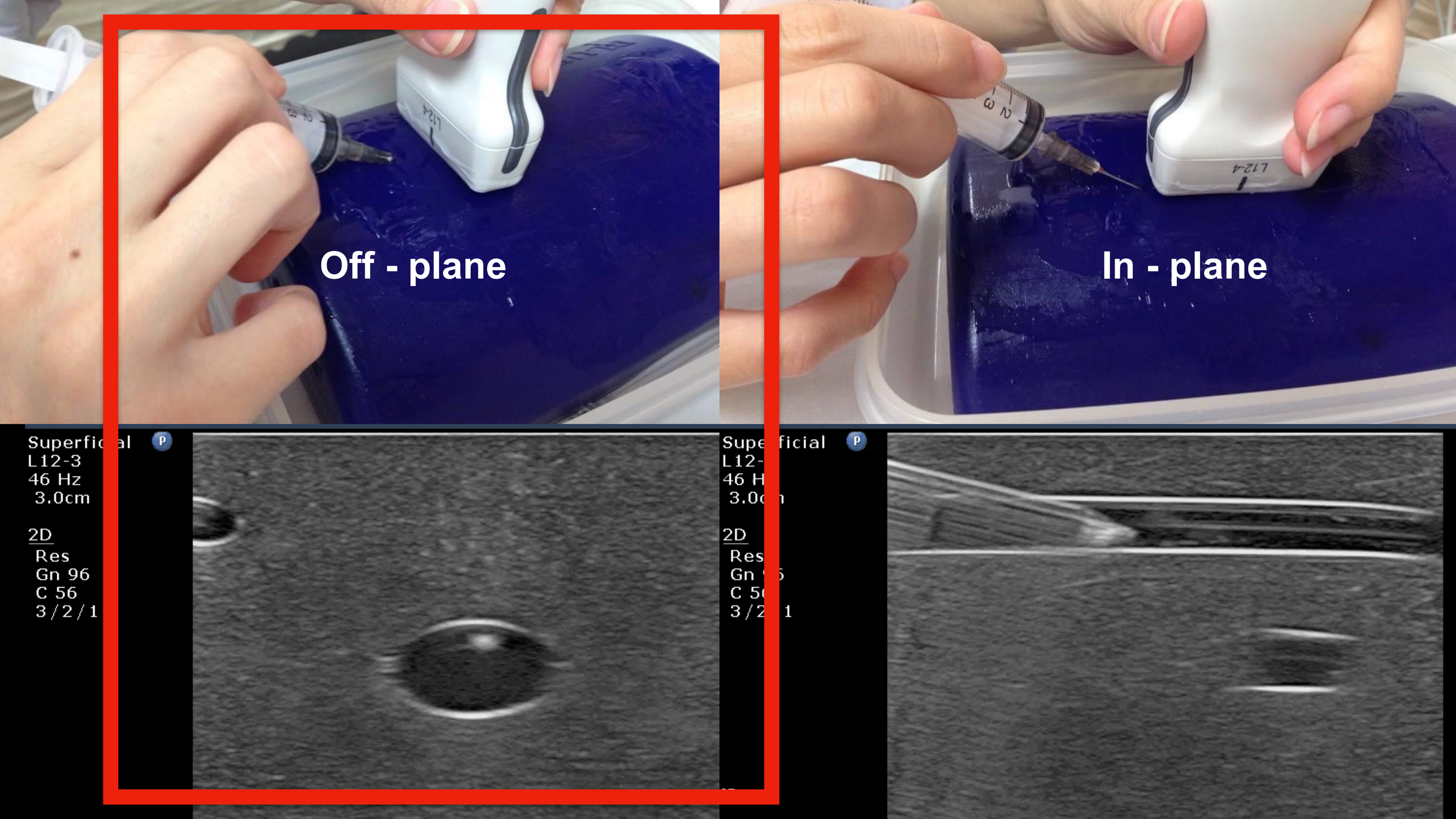
Off - plane
In - plane
Superficial
L12-3
46 Hz
3.0cm
2D
Res
Gn 96
C 56
3/2/1

Table 1. 3-Stations of the Needle.

Stations of the needle	Transverse (Short axis)	Longitudinal (Long axis)	Description	Key points
1 淺入針	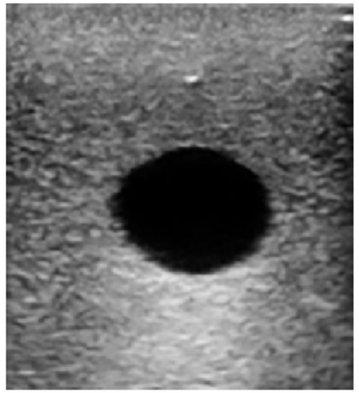		Identification of the needle tip upon skin entry to the subcutaneous tissue	Procedural time out confirming needle trajectory and depth of vessel before advancement of the needle
2 抬針尾	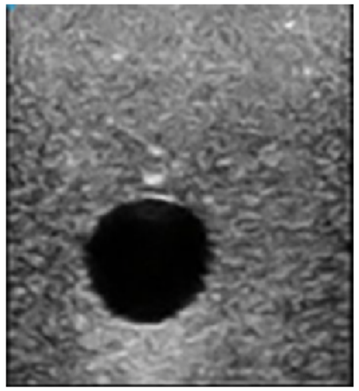		Navigation of needle tip from the subcutaneous tissue to outer wall of target vessel	Procedural time out for assessment of the surrounding structures of the intended target vessel for safe needle navigation using the PN-T
3 找針尖	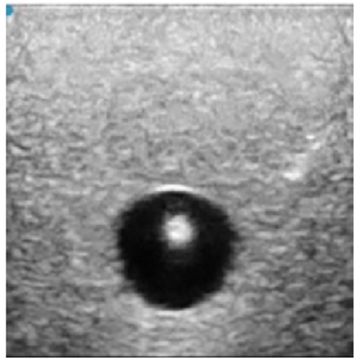	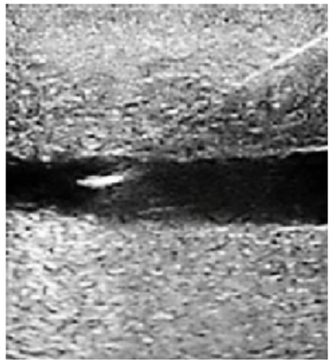	Vessel confirmation (arterial or venous) and needle advancement through vessel walls	Procedural time out before vessel puncture and P-NT for vessel purchase

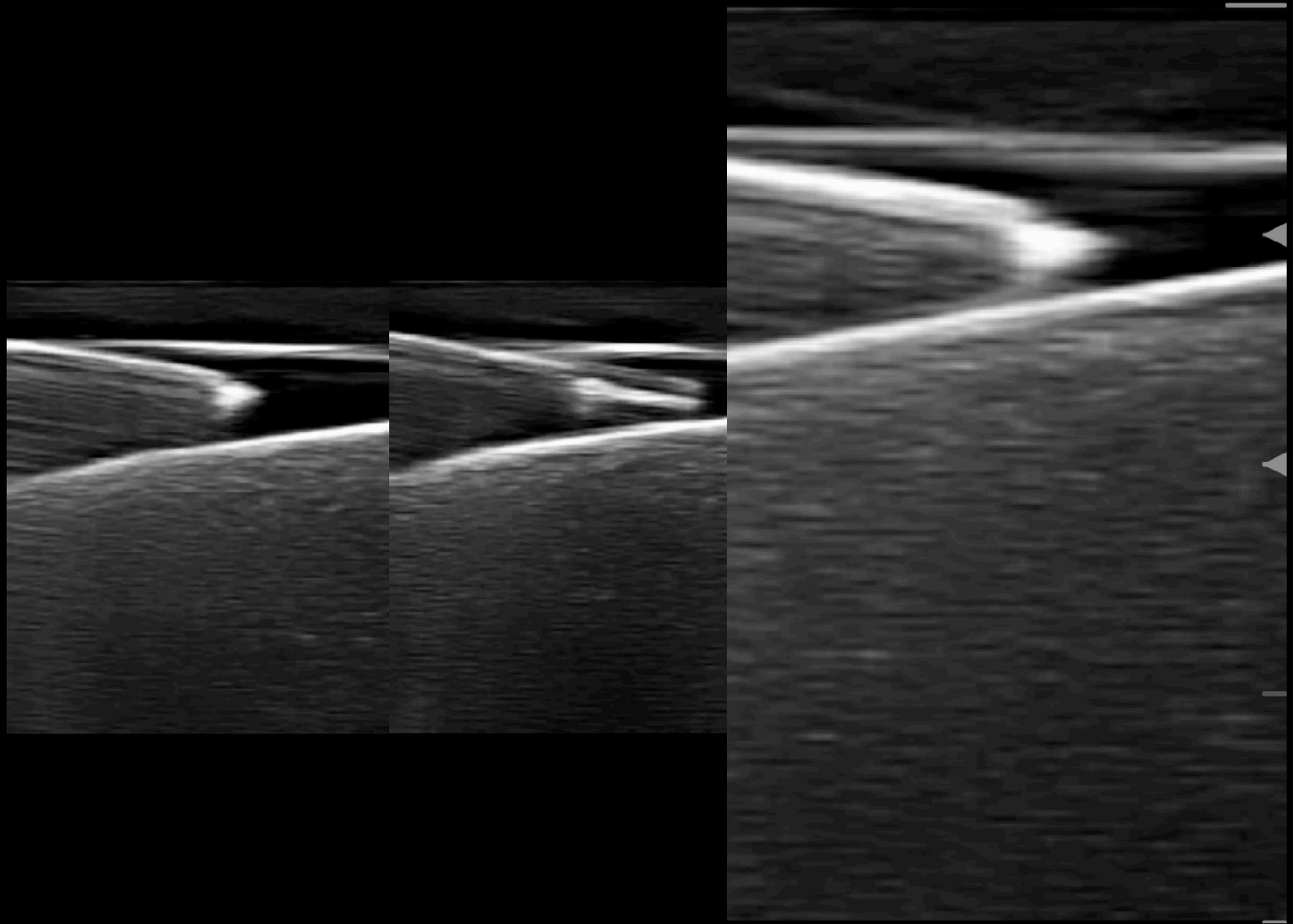

斜面由朝上轉朝下　　斜面由朝下轉朝上

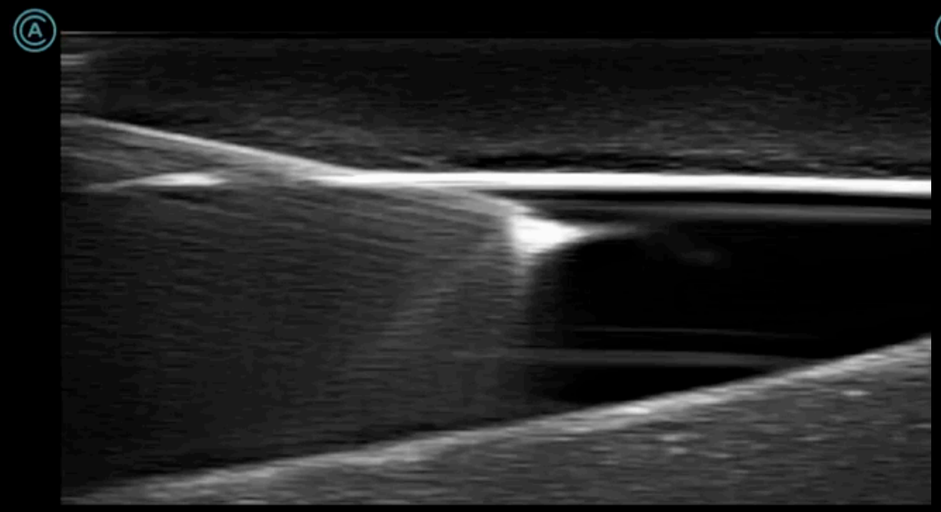

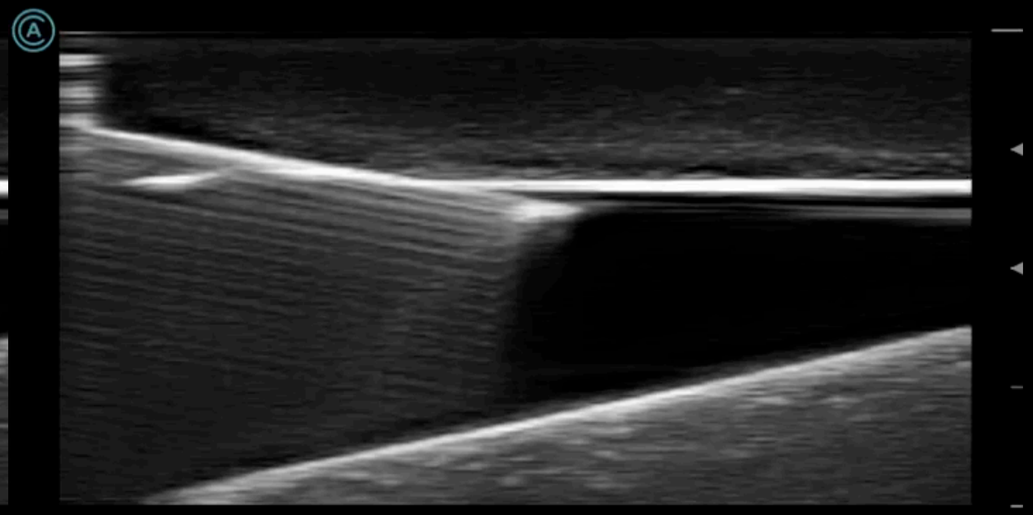

送Guidewire斜面朝下

送Catheter則斜面朝上

OFF-PLANE APPROACH

PREFERRED CHOICE FOR PICC

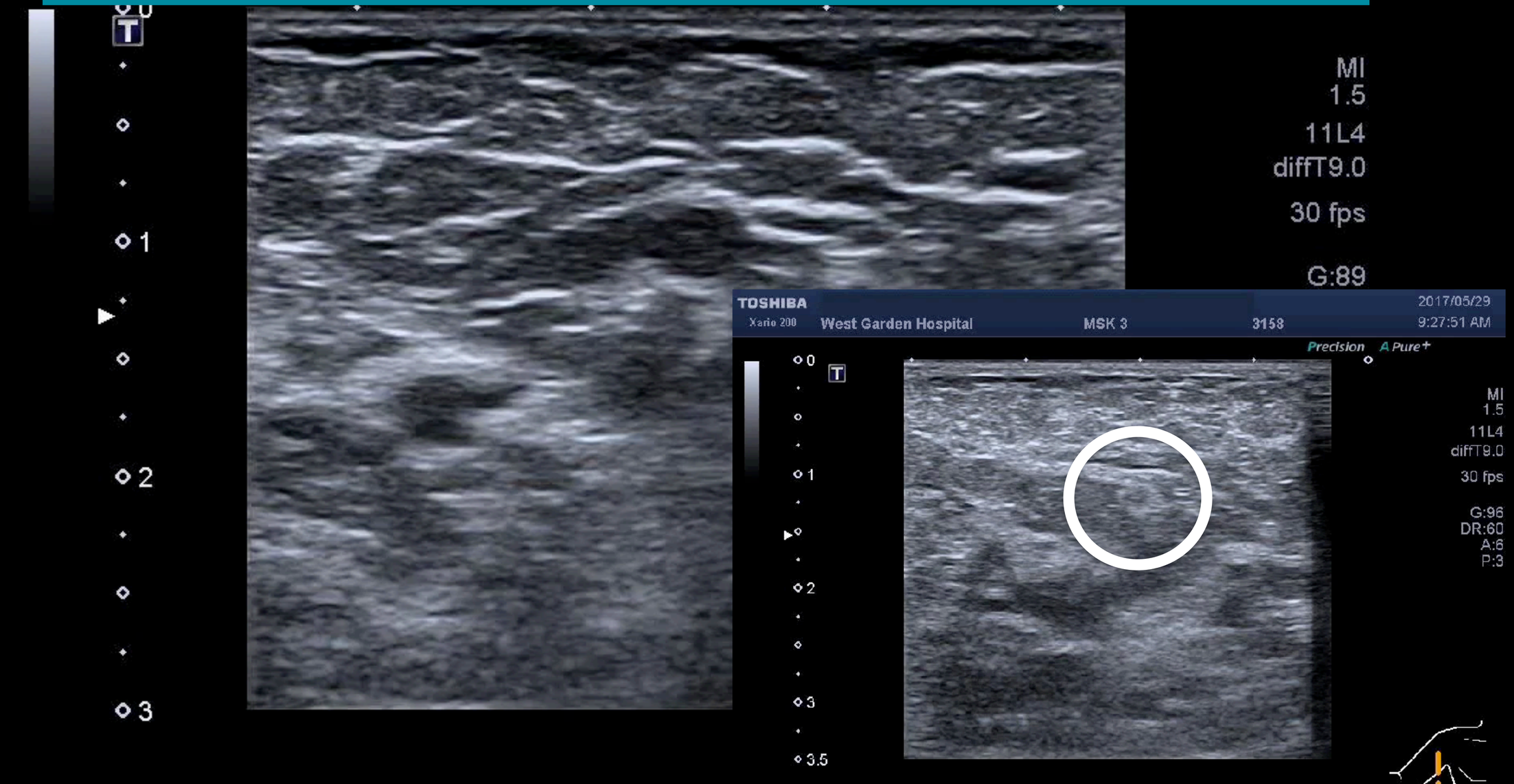


PICC Plus Stabilization Device
Statlock
Catheter Stabilization Device
ARROW SFR
ASPIRATE & FLUSH
BACKFLOW
ML/SEC


1
3
2
4

Anaesthesia, 2007, **62**, pages 818–823 doi:10.1111/j.1365-2044.2007.05139.x

Optimal skin surface landmark for the SVC–RA junction in cancer patients requiring the implantation of permanent central venous catheters

J. H. Hsu,[1] S. S. Wang,[2] D. V. Lu,[3] K. I. Cheng,[3] C. K. Wang[4] and J. R. Wu[1,5]

Departments of 1 Paediatrics and 4 Medical Imaging, Kaohsiung Medical University Hospital, 100 Tzyou 1st Road, Kaohsiung 807, Taiwan
2 Department of Surgery, Chang Gung Memorial Hospital, no. 6, Section west, Chia Pu Road, Puzi City, Chiayi 613, Taiwan
Department of 3 Anaesthesiology and 5 Paediatrics, Kaohsiung Municipal Hsiao-Kang Hospital, 482 San-Ming Road,

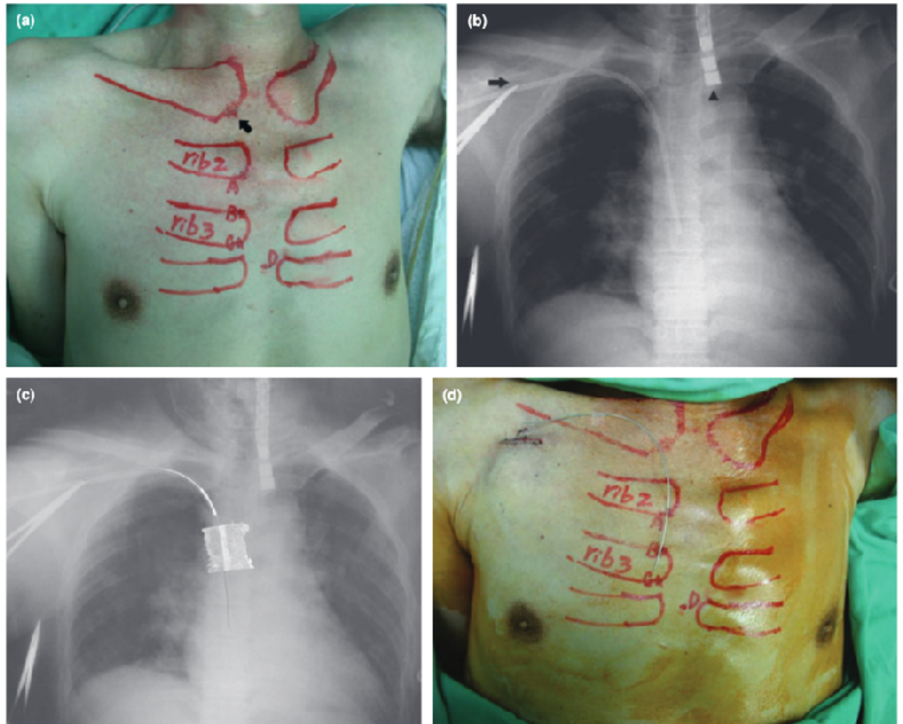

CAJ: Lower margin of R 3rd

Table 3 Number and percentage of patients with satisfactory positioning guided by different skin surface landmarks ($n = 20$).

Skin surface landmark	No. of patients with satisfactory positioning	Percentage of patients with satisfactory positioning	p value*
Point A	0	0%	< 0.0001
Point B	4	20%	
Point C	14	70%	
Point D	6	30%	

PICC導管置放

PICC導管置放

US-GUIDED PICC TIP NAVIGATION

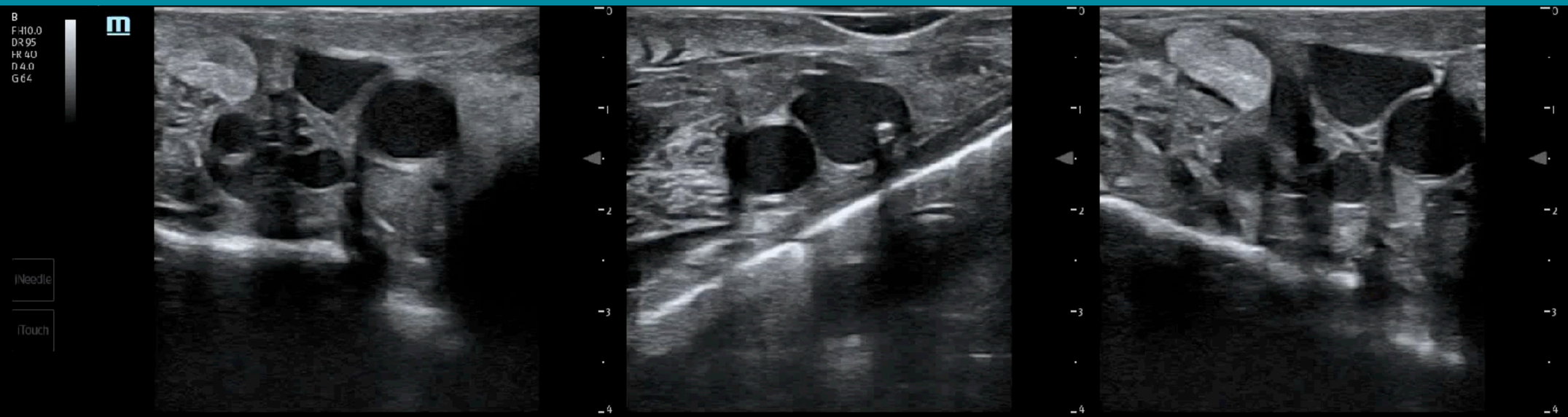

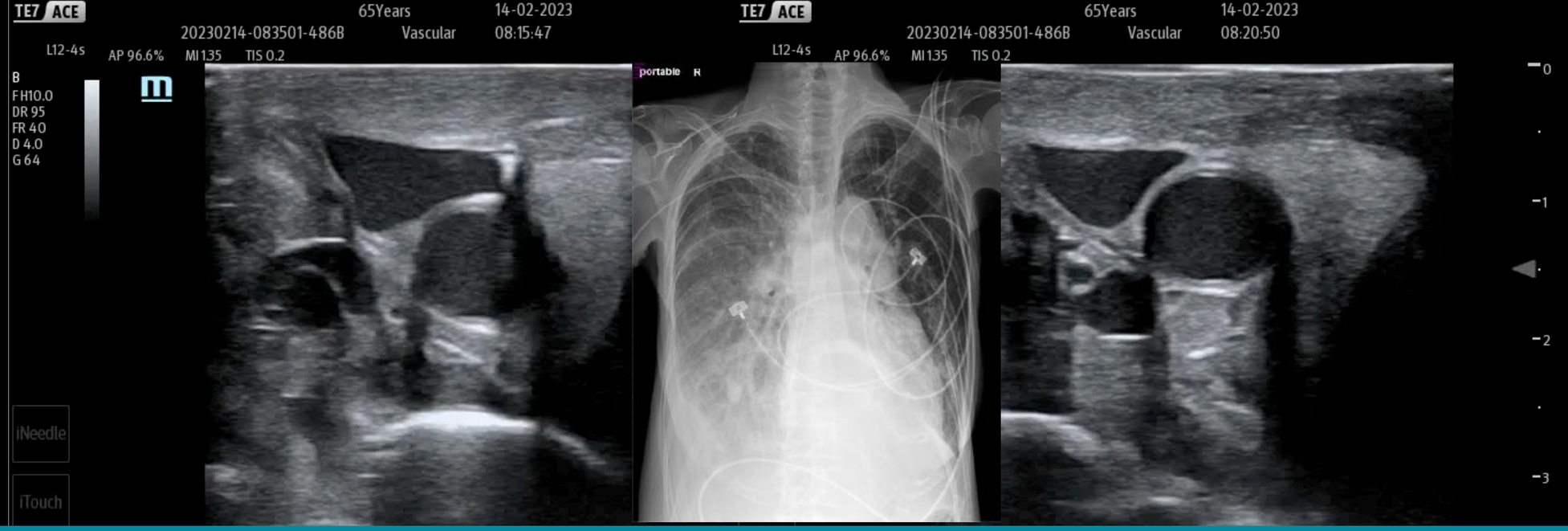

ECHOTIP PROTOCOL
TIP NAVIGATION

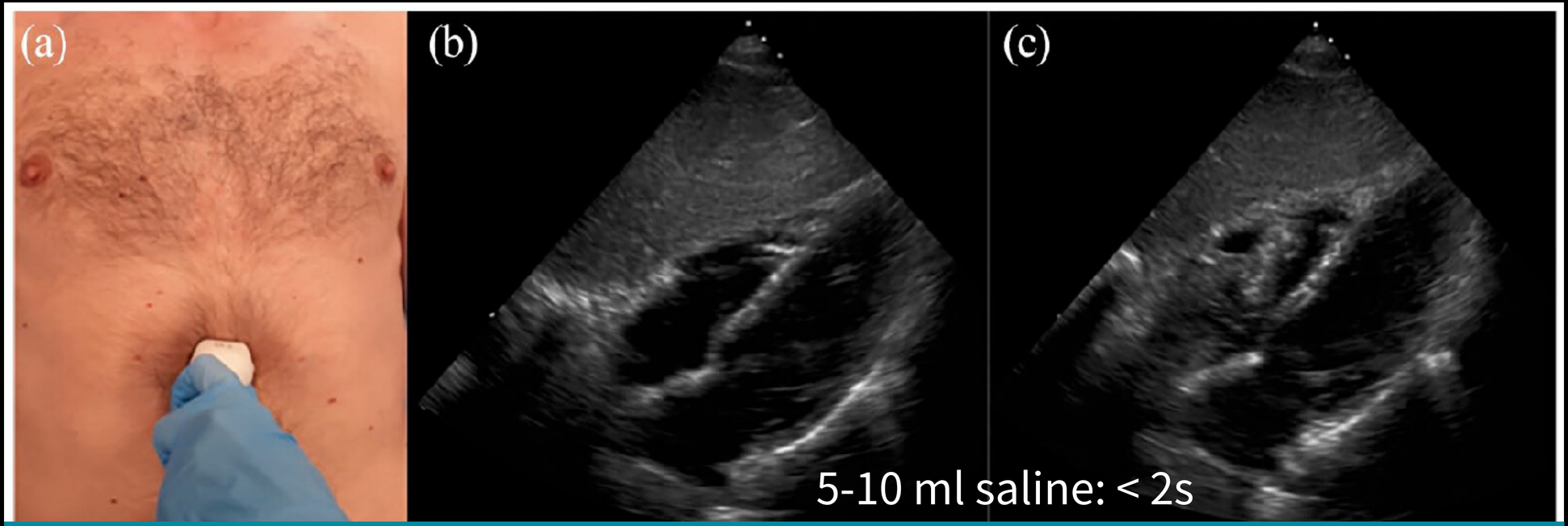

TIP LOCALIZATION

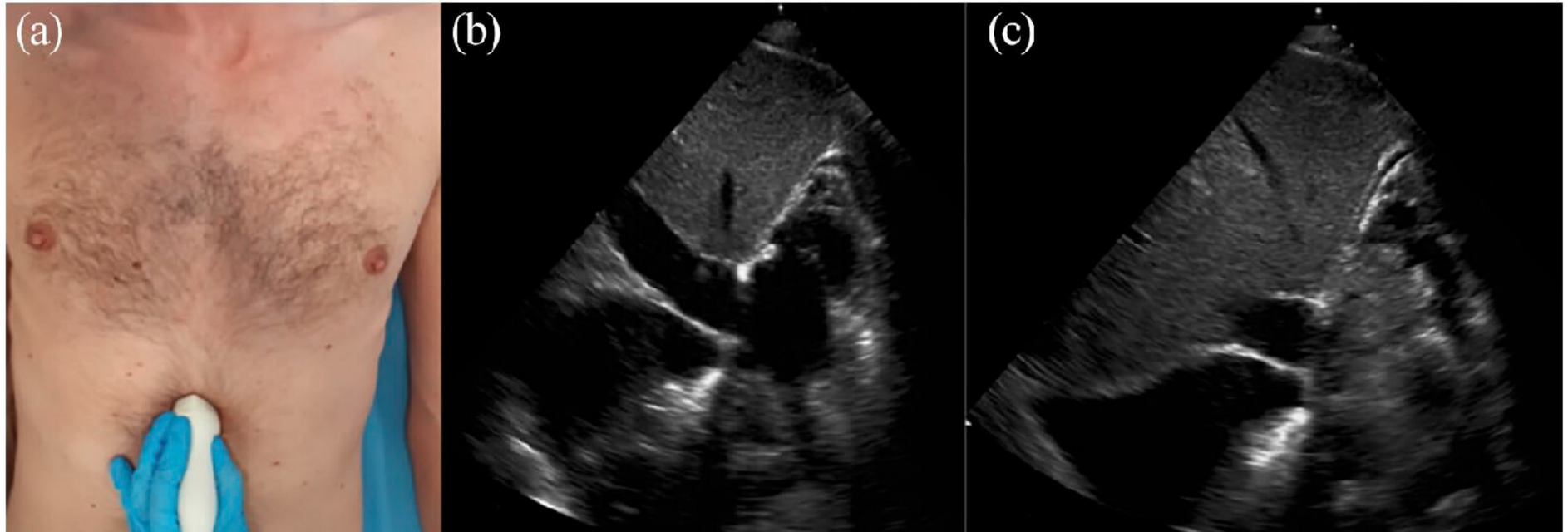

PICC確認位置 (ECHO + CXR)

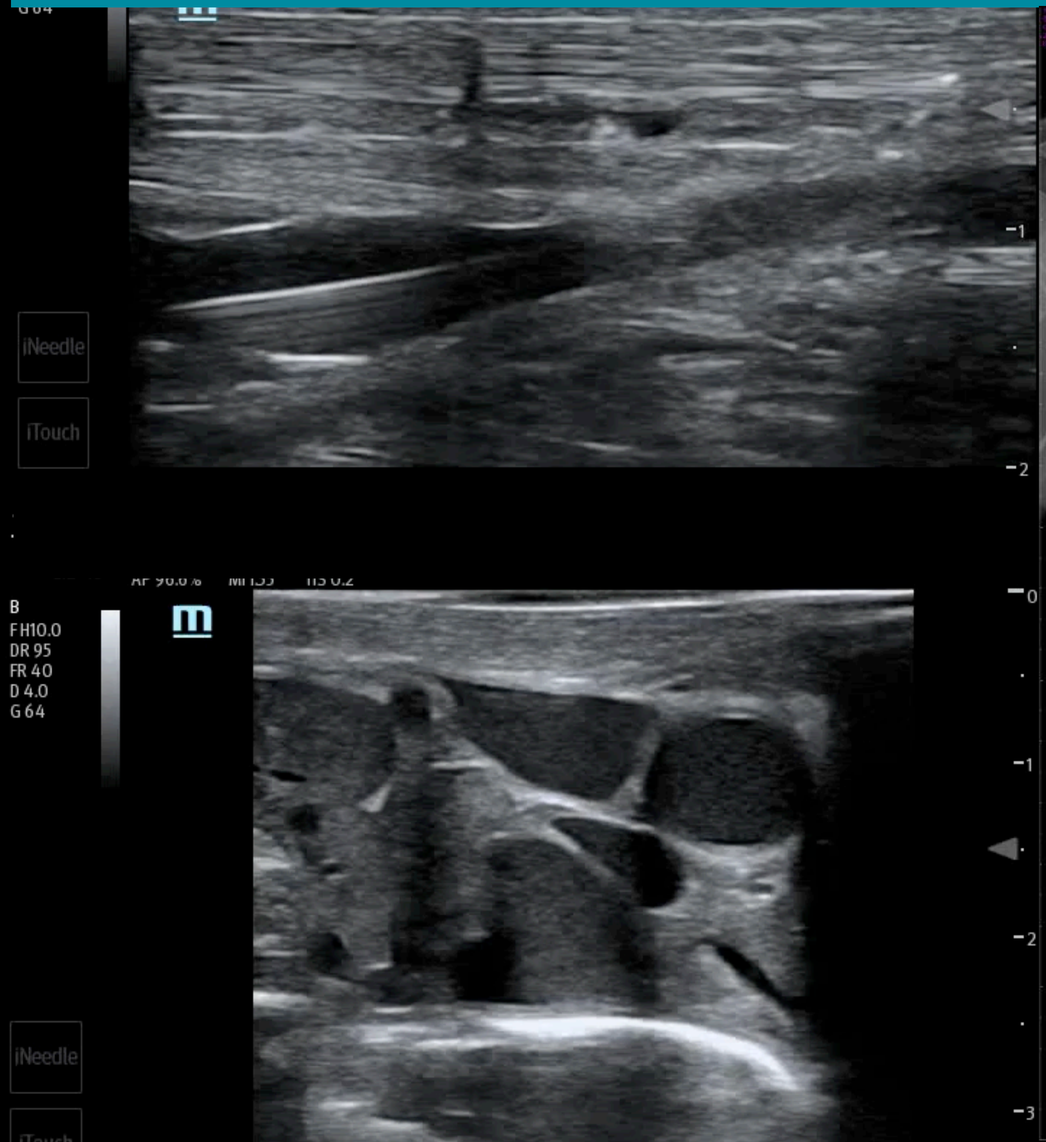

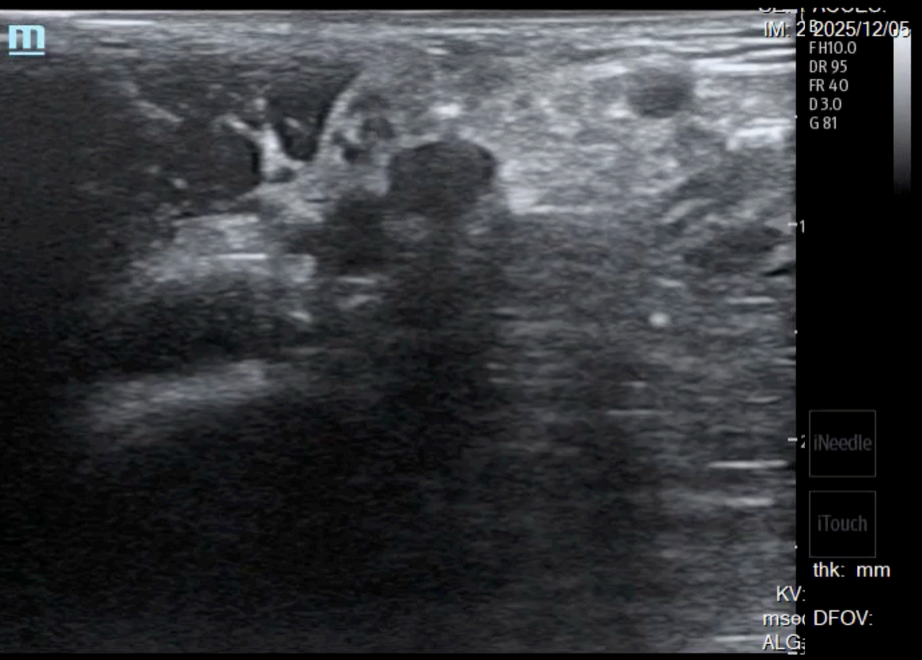
2025/12/05
F H10.0
DR 95
FR 40
D 3.0
G 81
iNeedle
iTouch
thk: mm
DFOV:

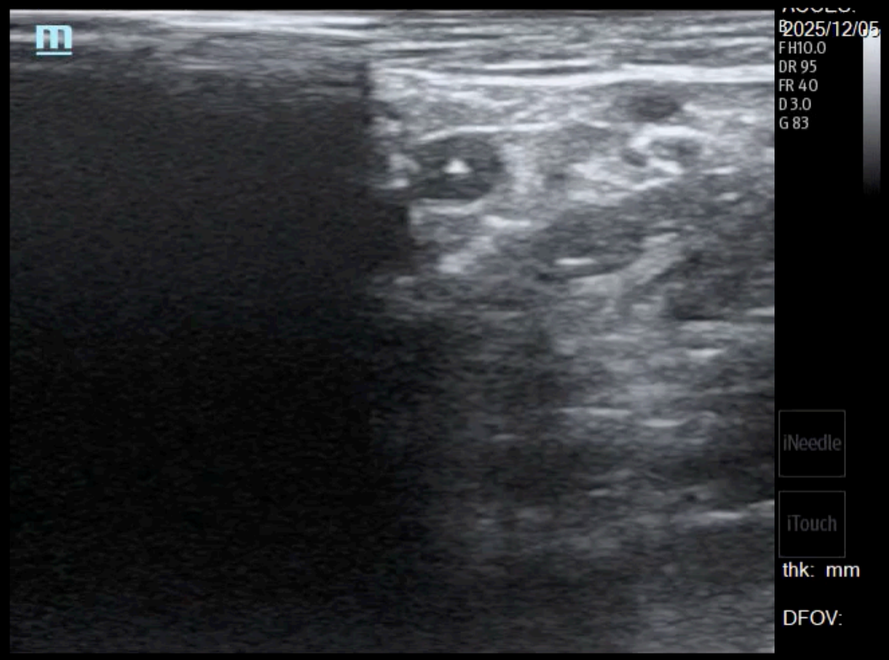
2025/12/05
F H10.0
DR 95
FR 40
D 3.0
G 83
iNeedle
iTouch
thk: mm
DFOV:

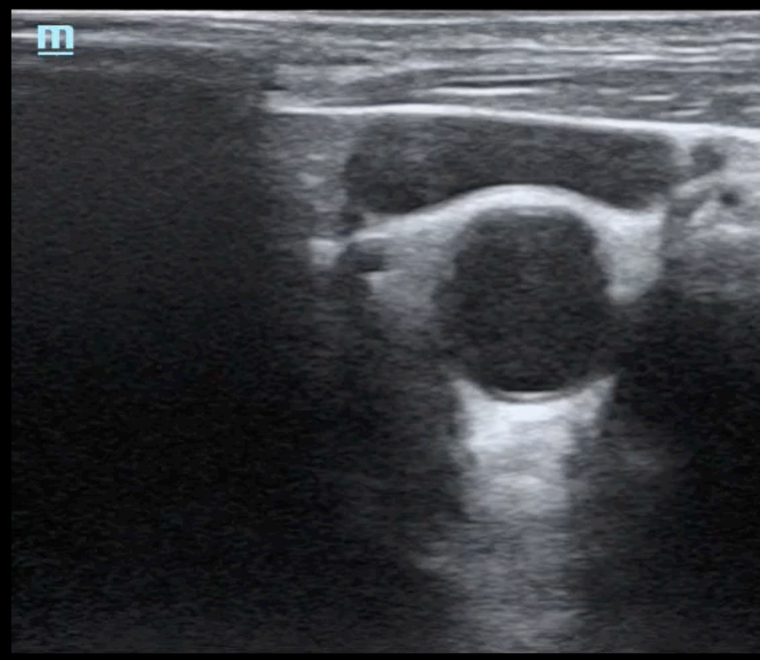


Shuang Ho Hospital
2025/12/05
iNeedle
iTouch
thk: mm
DFOV:

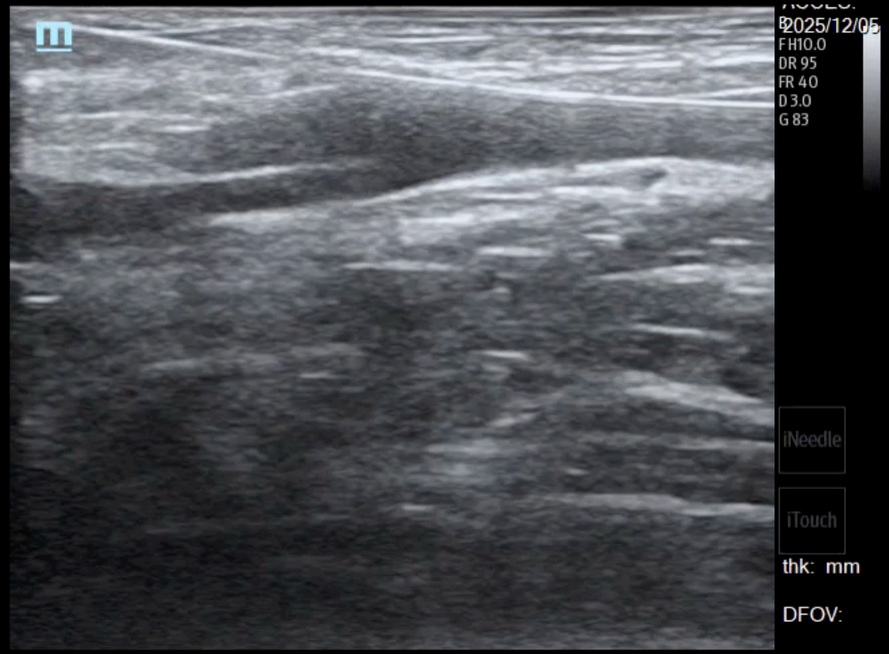
2025/12/05
F H10.0
DR 95
FR 40
D 3.0
G 83
iNeedle
iTouch
thk: mm
DFOV:

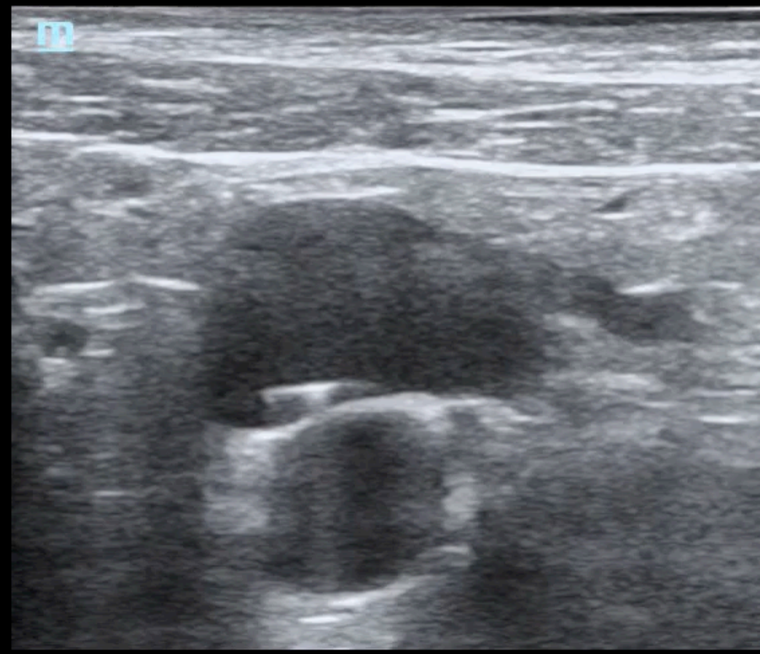


L portable

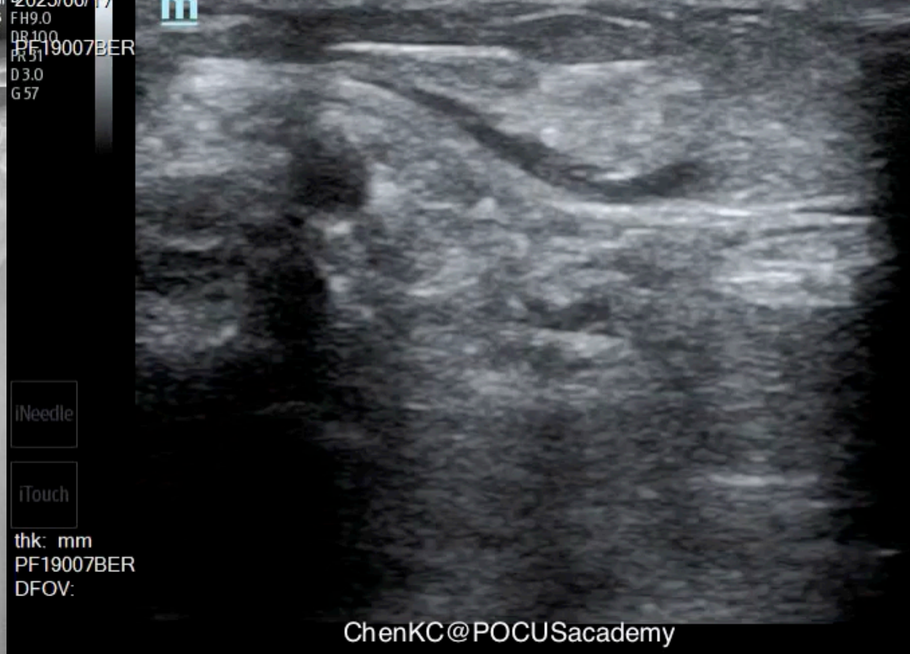
PF19007BER
FH9.0
DR100
PR51
D 3.0
G 57
iNeedle
iTouch
thk: mm
PF19007BER
DFOV:
ChenKC@POCUSacademy

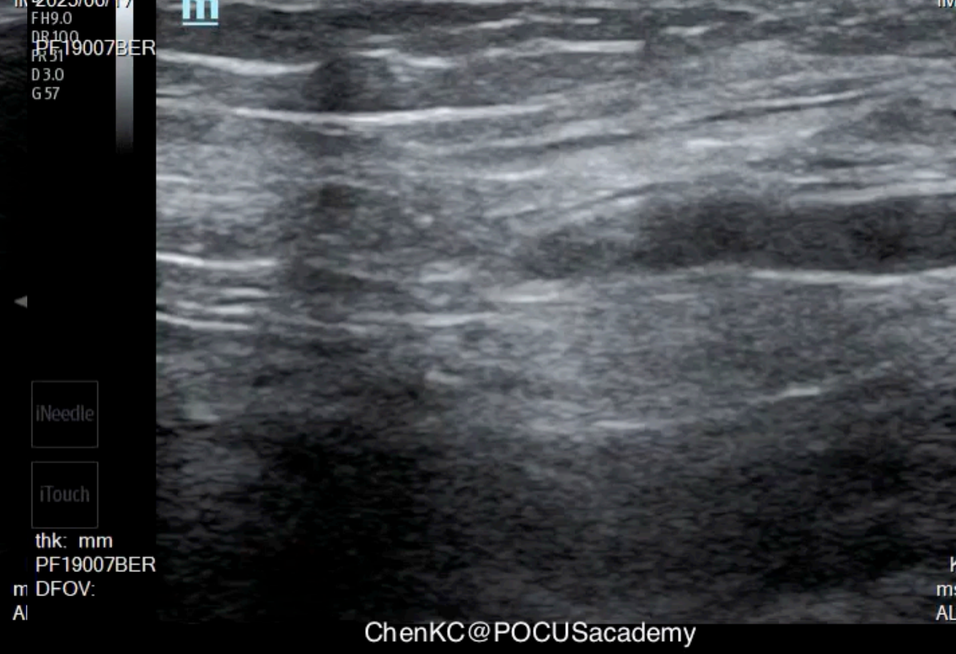
PF19007BER
FH9.0
DR100
PR51
D 3.0
G 57
iNeedle
iTouch
thk: mm
PF19007BER
DFOV:
ChenKC@POCUSacademy

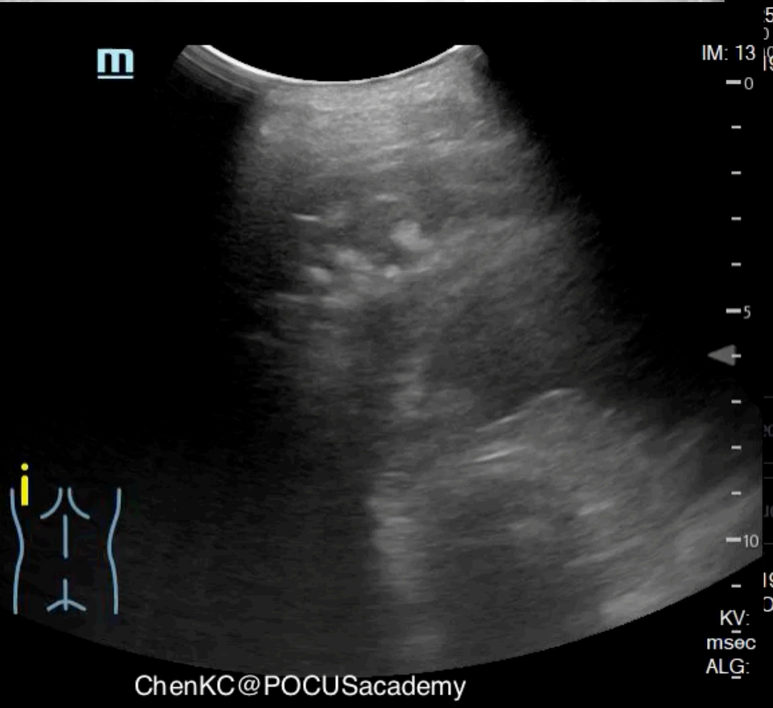
IM: 13
KV:
msec
ALG:
ChenKC@POCUSacademy

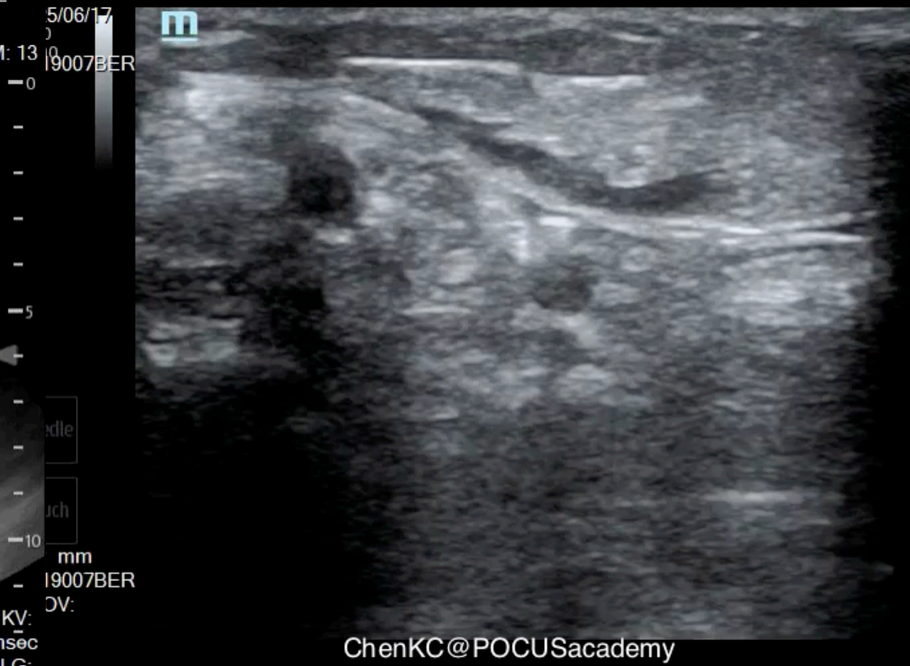
PF19007BER
FH9.0
DR100
PR51
D 4.0
G 66
iNeedle
iTouch
thk: mm
PF19007BER
DFOV:
ChenKC@POCUSacademy

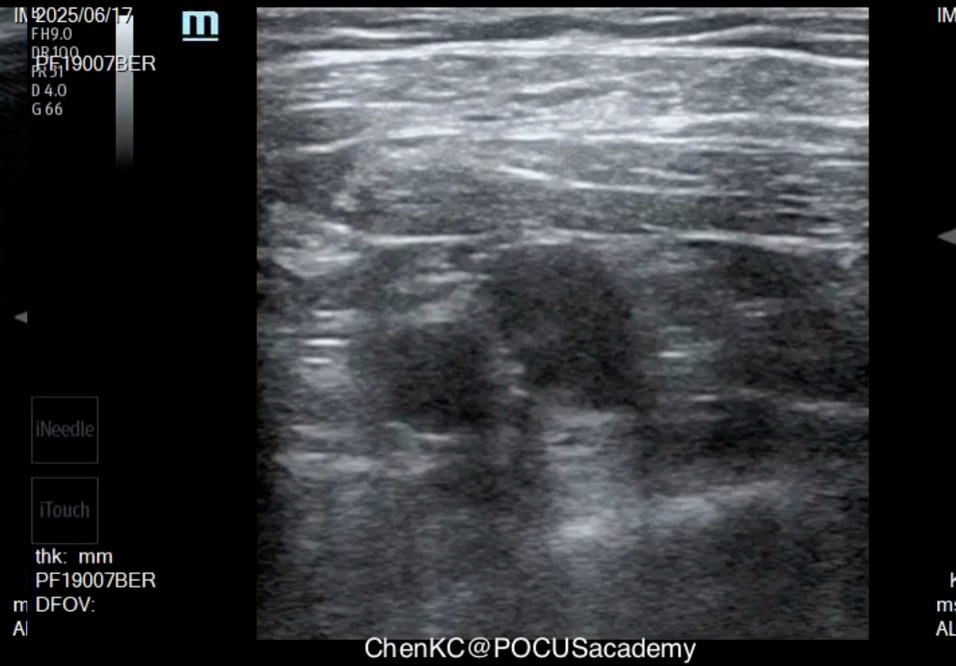
ChenKC@POCUSacademy

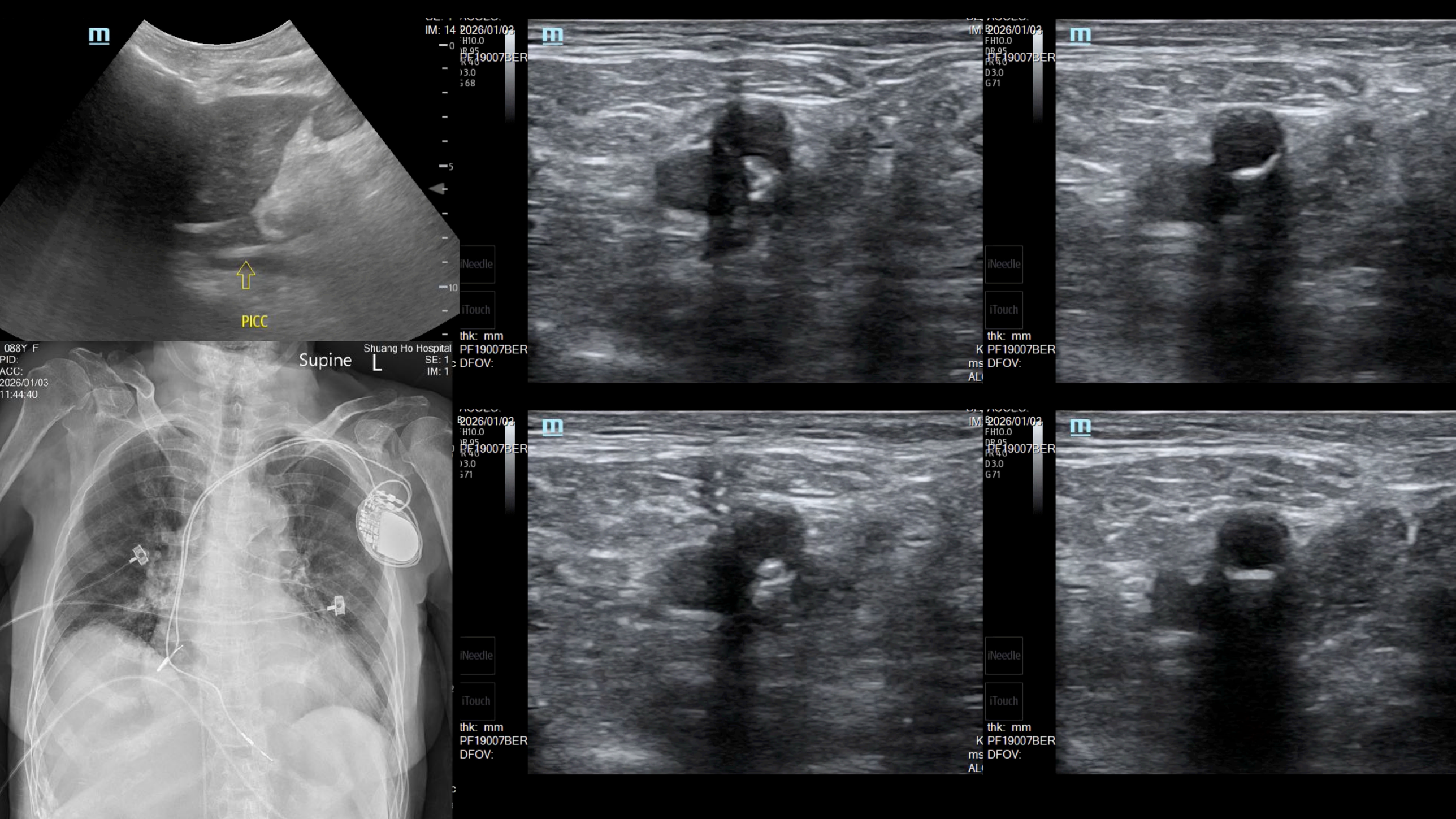
PICC
088Y F
PID:
ACC:
2026/01/03
11:44:40
Supine
L
Shuang Ho Hospital
2026/01/03
PF19007BER
iNeedle
iTouch
thk: mm
DFOV:

沖管

Q8H以10 mL N/S推停推停方式沖洗一次，

推停推停方式沖洗方式:快速推進1-2ml &每次推進間隔約0.4秒[1]

每次輸液前後、抽/輸血前後、更換管路及 / 或脂質輸注時

沖洗必須涵蓋所有導管管腔

1. ISBN 978-3-030-03148-0 ISBN 978-3-030-03149-7 (eBook) https://doi.org/10.1007/978-3-030-03149-7.S82

採血/給予藥物

1.停止全身靜脈輸注液體或血液製品 **2 分鐘**

2.消毒無針連接器或導管銜接孔 **5-15秒**

3.以 **10 mL N/S 推停推停方式**沖洗管路

4.棄血 **5 mL**

5.連接新的10 mL 針筒

6.採血

7.消毒無針連接器銜接孔或導管銜接孔 **5-15秒** (使用適當消毒劑 如chlorhexidine, povidone iodine, 或70% alcohol，請務必注意，若後續換藥施加敷料覆蓋前，應待消毒液體完全乾燥)

8.採血後以 **20 mL N/S** 脈動式沖洗管路，及適當清潔導管及任何附加裝置

閉管

1. 停止使用時及施打藥物並完成最後沖洗之後，務必進行**正壓閉管** ，保留0.5ml NS(勿全部推注完)以大拇指壓住針筒活塞後，接著關閉閥夾後再移除注射器，避免血液回流入導管內[1]

1. N/S使用，請依醫院程序及注意事項

文獻出處:
1. Gorski LA, Hadaway L, Hagle ME, et al. Infusion therapy standards of practice.J Infus Nurs. 2021;44(suppl 1):S1-S224. doi:10.1097/NAN.0000000000000396

PICC管路照護

Avoid PICC on Patients with eGFR <45ml/min

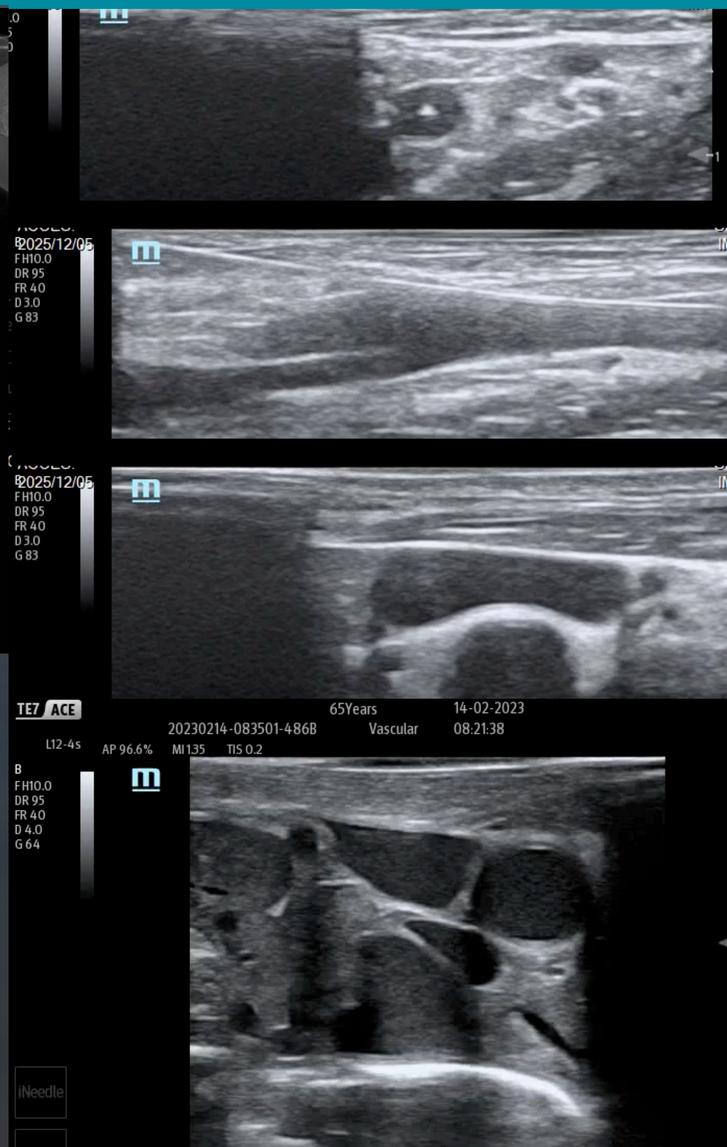

MAGIC

Michigan Appropriateness Guide for Intravenous Catheters