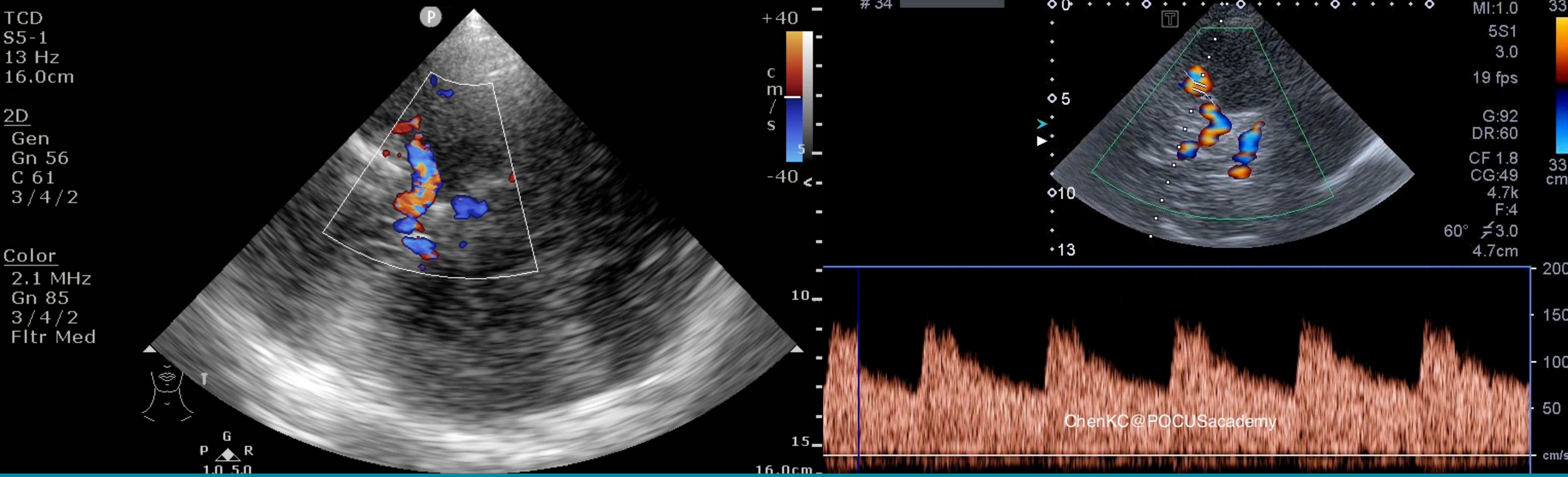

TCD
Transcranial Doppler

陳國智醫師 雙和醫院急診醫學科

juice119@gmail.com/ POCUSacademy.com

先進與革新急症技術中心 / Advanced & Revolutionary Technology center

107

TCD IN TBI

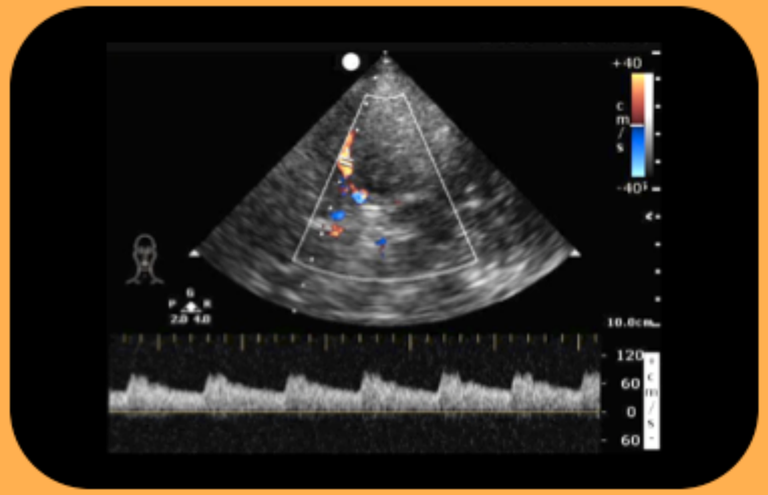

Questions:

Can transcranial doppler (TCD) screen for changes in cerebral blood flow in early traumatic brain injury (TBI)? Do these changes predict neurologic outcomes?

Methods:

Prospective observational study of head trauma patients admitted to ICU. TCD soon after admission. Compared mild-moderate TBI to severe TBI for the incidence of abnormal TCD findings. 2° outcome of finding factors associated with poor outcomes.

N = 66

Results

	GCS >8 (%)	GCS ≤8 (%)
Low EDV (<25 cm/s)	11.1	46.7
High PI (>1.3)	16.7	46.7

EDV = End diastolic velocity. PI = pulsatility index

Correlation with Glasgow Outcome Score: EDV *r* 0.52, PI *r* 0.55

High PI had 91% sens, 89% spec for poor outcome

Aly AA, Farmawy MS. Transcranial Doppler to detect early abnormalities in cerebral hemodynamics following traumatic brain injury in adult patients. Research and Opinion in Anesthesia and Intensive Care. 2020;7:274-81

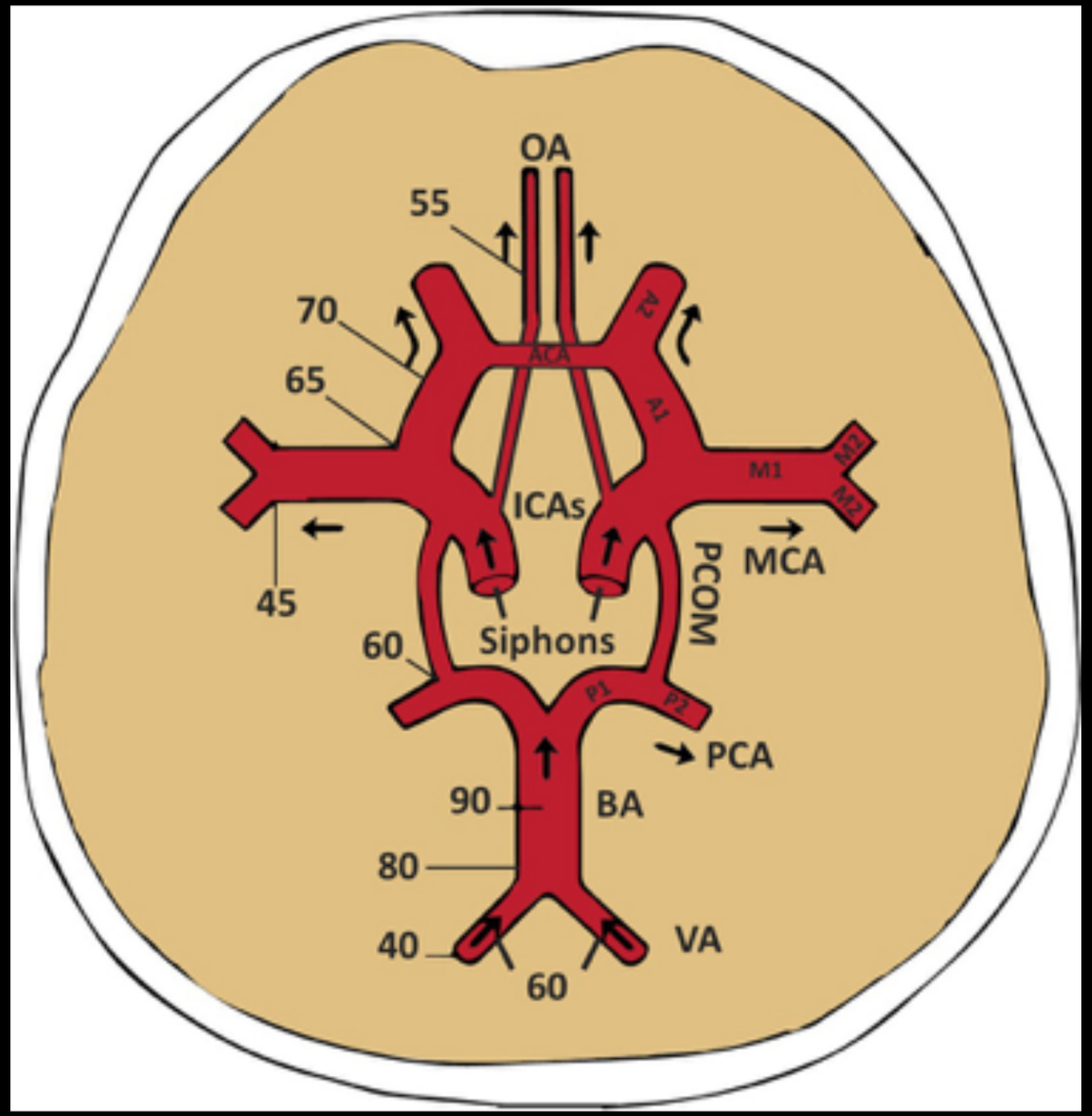

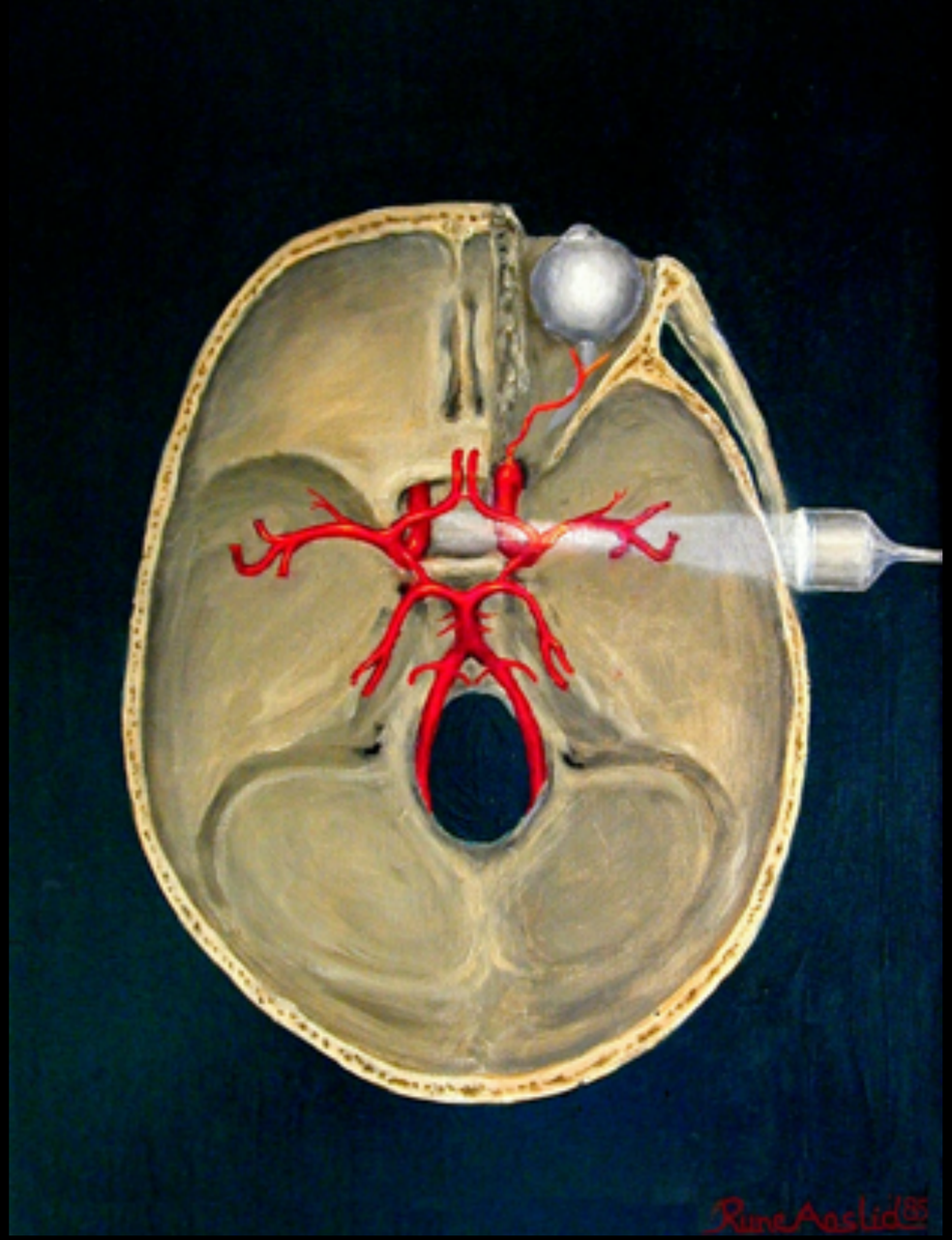

Montrief, T., et al. (2019). Incorporation of Transcranial Doppler into the emergency department for the neurocritical care patient. American Journal of Emergency Medicine 37(6): 1144-1152

MCA

ICA

VA

OA

Montrief, T., et al. (2019). Incorporation of Transcranial Doppler into the emergency department for the neurocritical care patient. American Journal of Emergency Medicine 37(6): 1144-1152

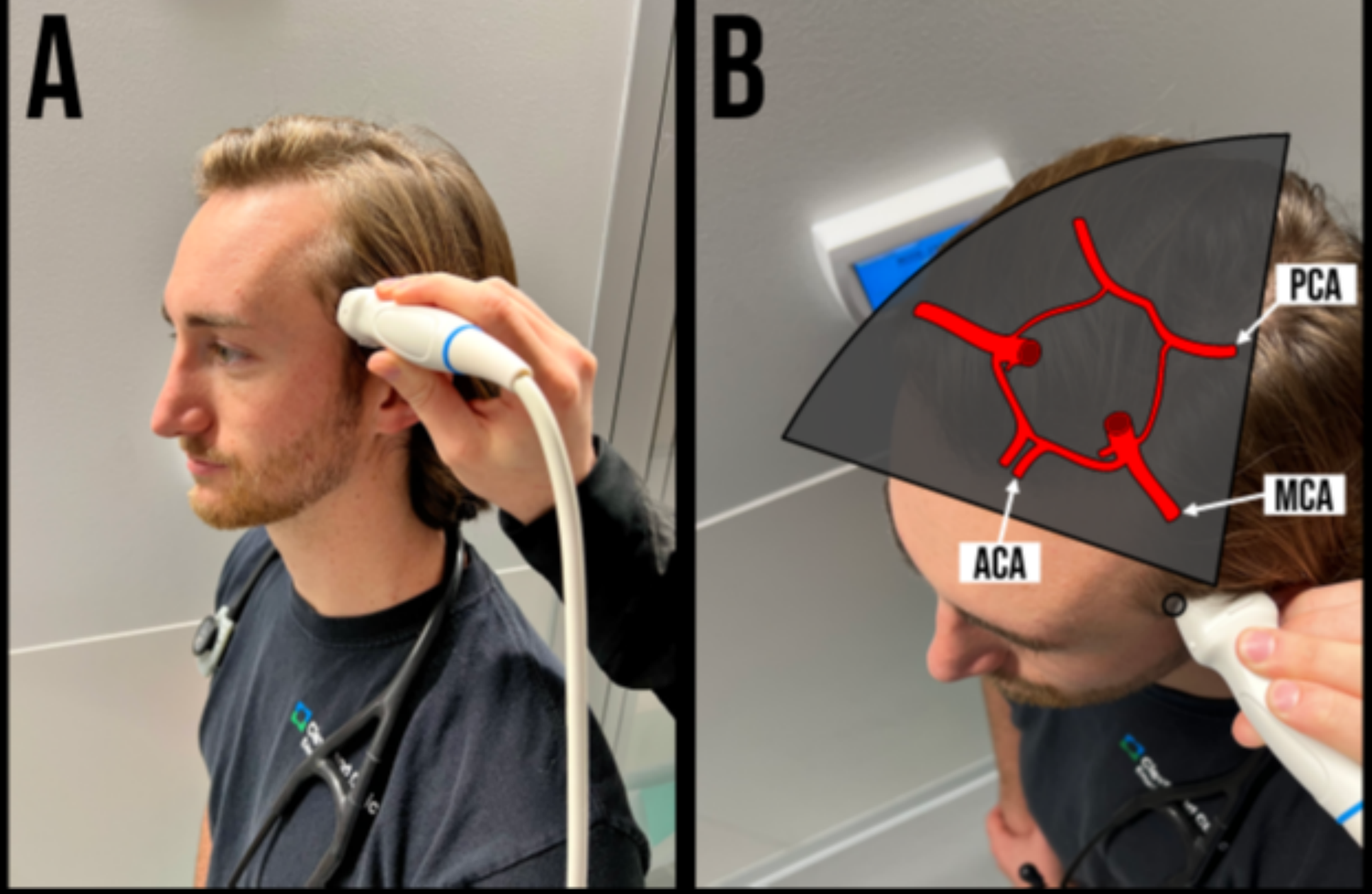

https://www.acep.org/emultrasound/newsroom/feb2024/transcranial-doppler

Trans-temporal TCD

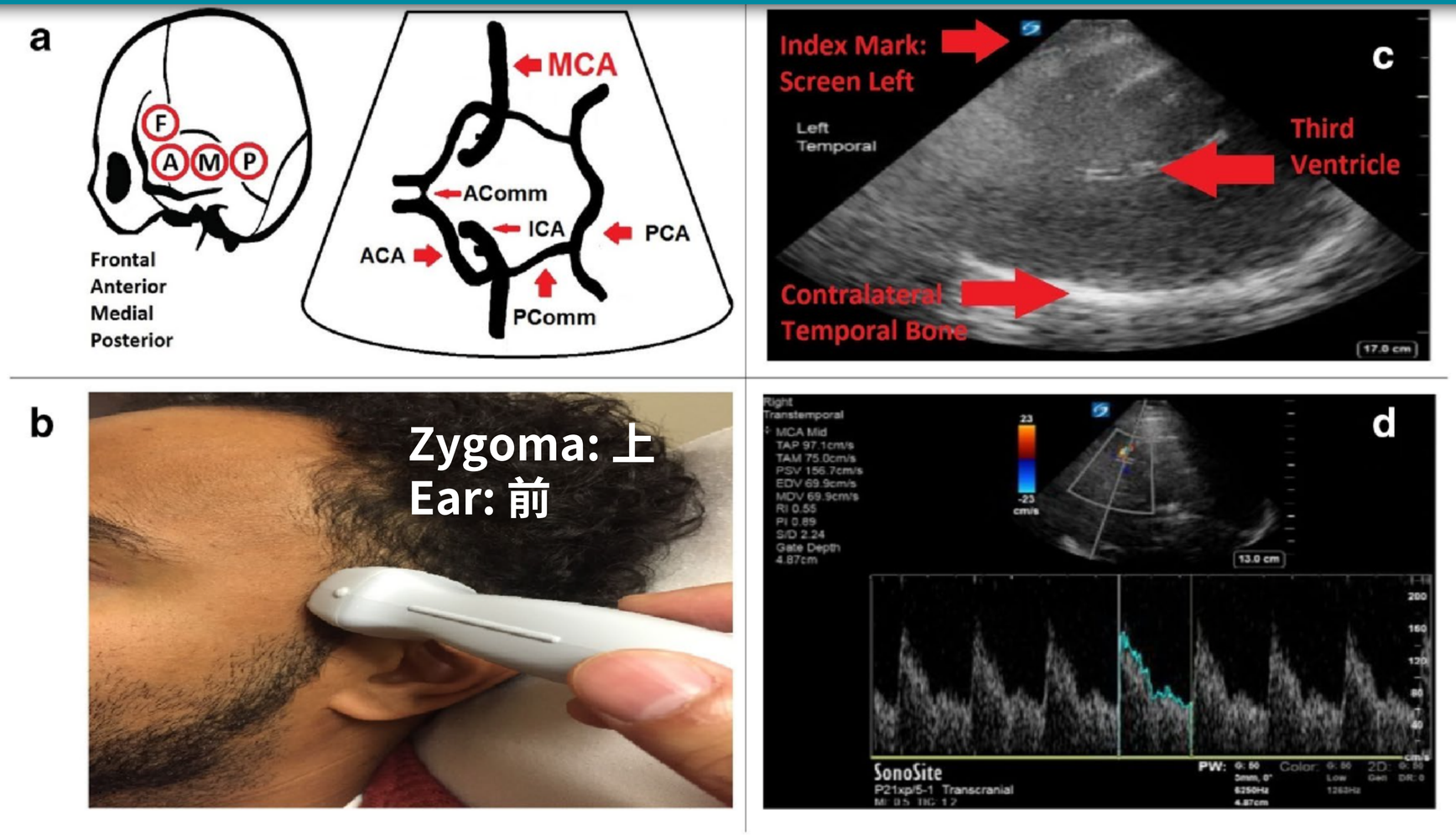

Fig. 5 Method for acquisition of transcranial Doppler. **a** Left side shows location of the trans-temporal window and its various sections: frontal, anterior, medial, and posterior. Right side illustrates Circle of Willis, with MCA highlighted. **b** Probe index mark orientation towards the patient's anterior/front. **c** Typical 2D image of TCD from trans-temporal window with index mark to screen left, with bright echogenic contralateral temporal bone, and anechoic space of midline third ventricle. **d** Typical spectral Doppler velocity waveform from MCA, with steep systolic upstroke and step-down diastolic flow (typical mean velocity of 80 cm/s)

Pulsatility Measurement

正常波形分析

生理狀態變異

心臟功能影響

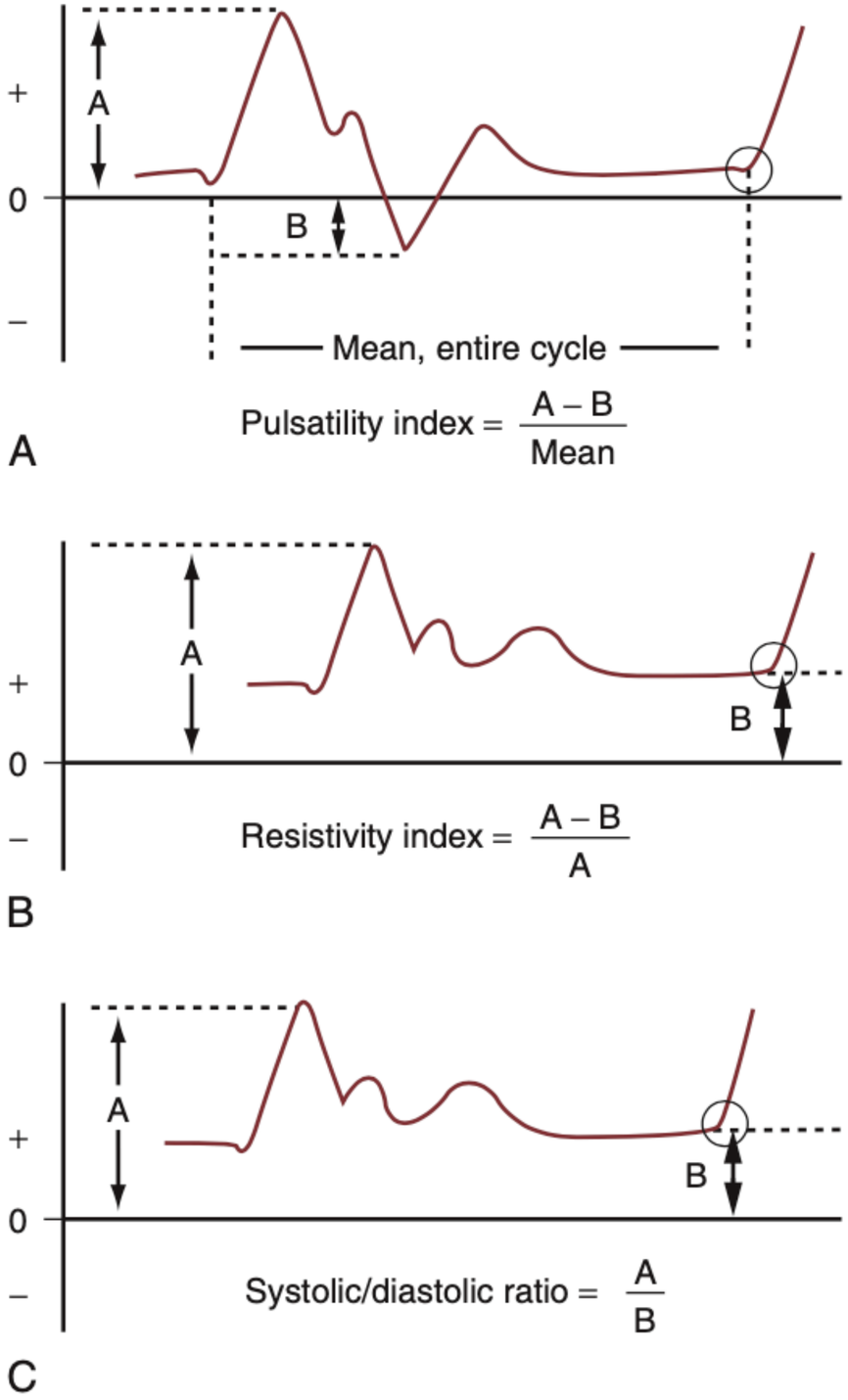

Introduction to vascular sonography_7th ed.

Pulsatility

低

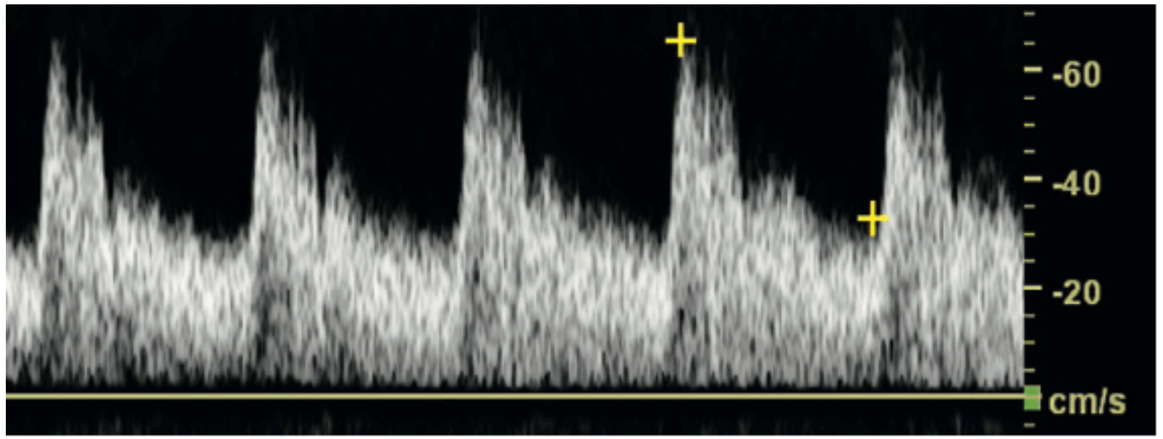

A

中

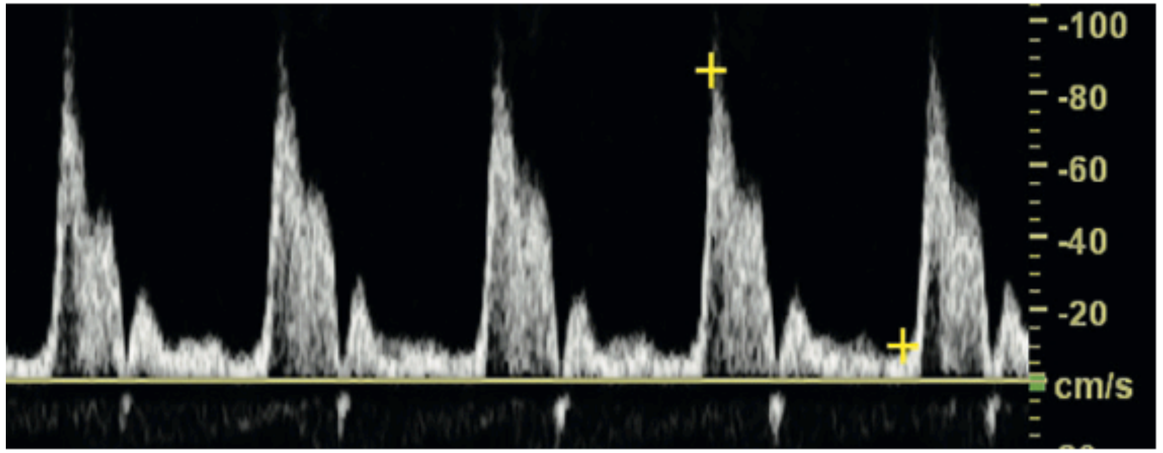

B

高

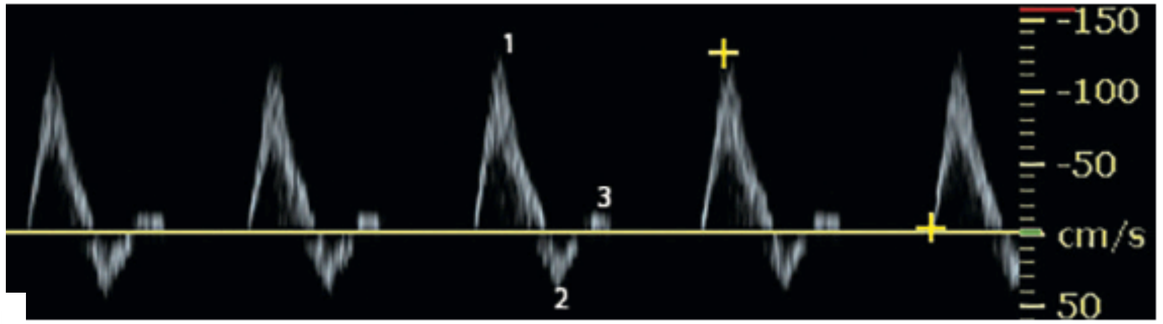

Introduction to vascular sonography_7th ed.

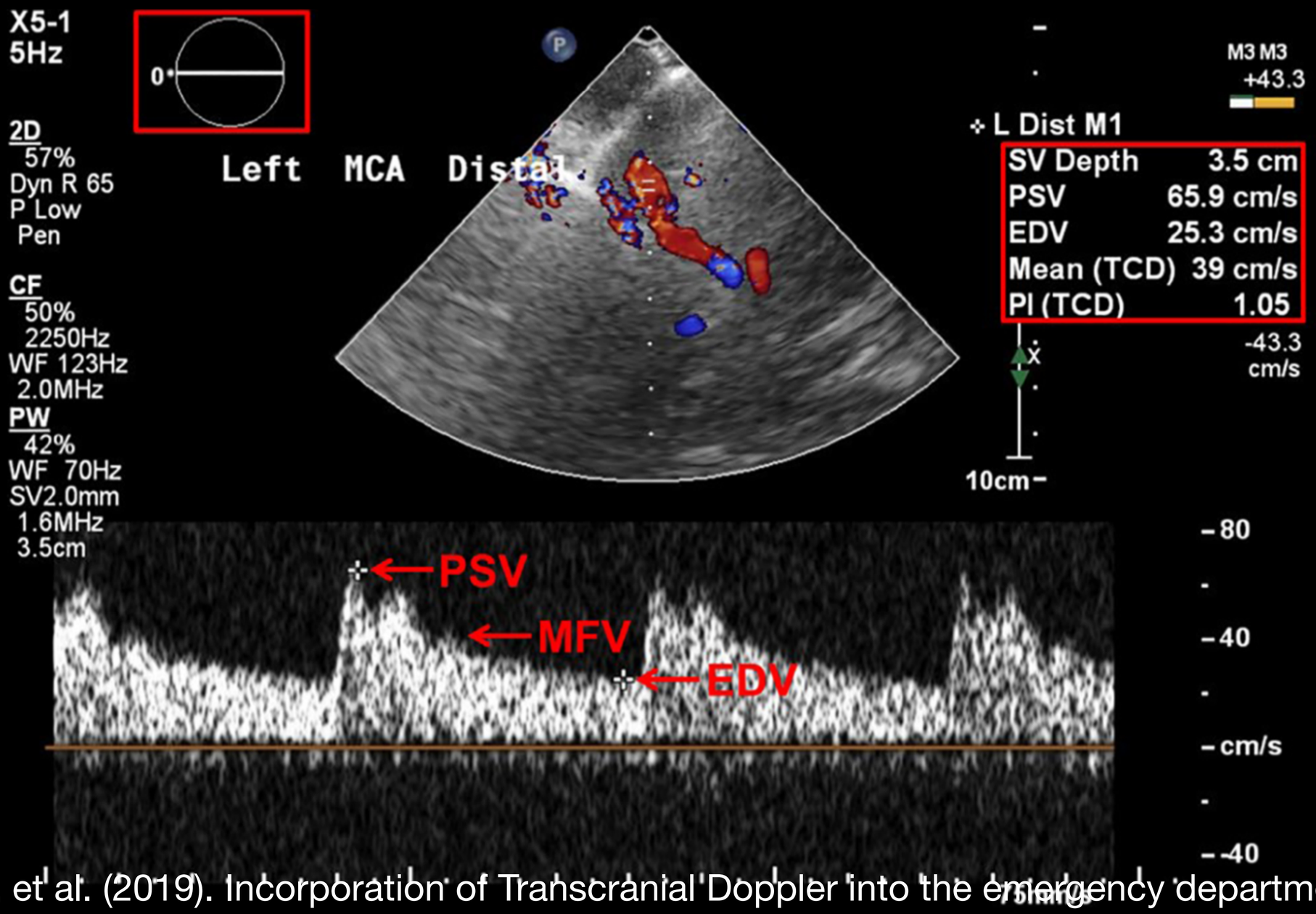

Montrief, T., et al. (2019). Incorporation of Transcranial Doppler into the emergency department for the neurocritical care patient. American Journal of Emergency Medicine 37(6): 1144-1152

Step 1:

Midbrain identification

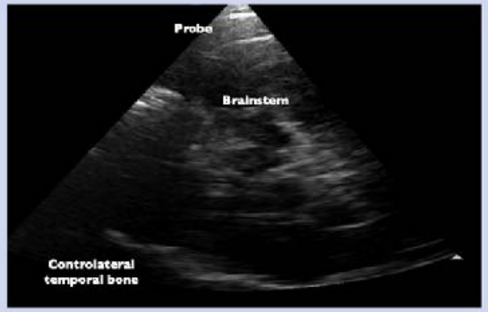

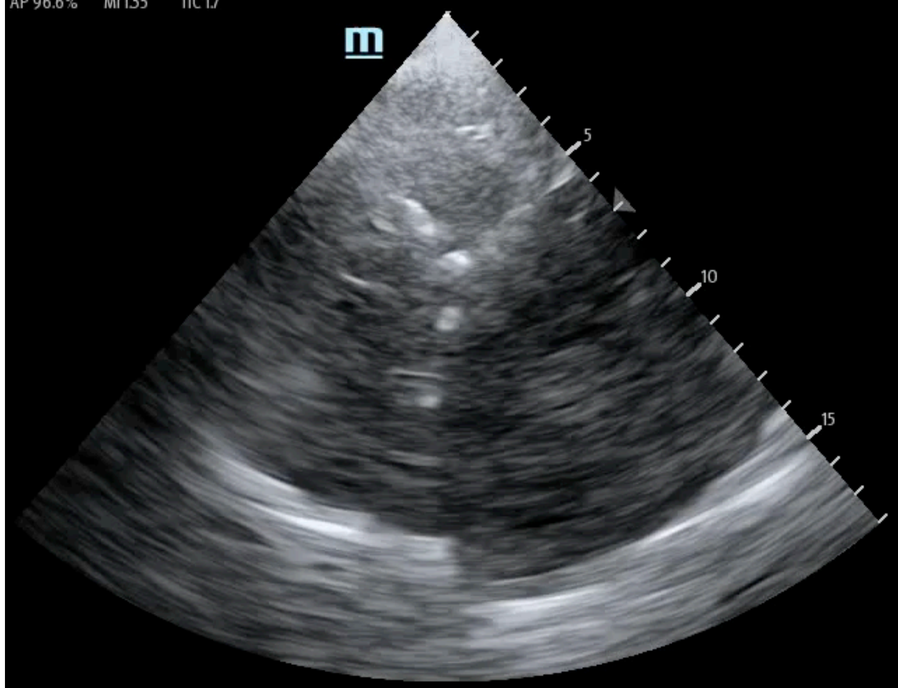

Step 2:

Color Doppler of vessels identification

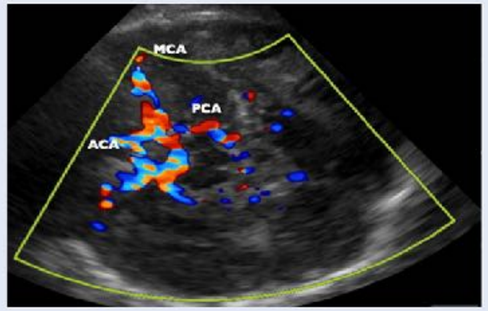

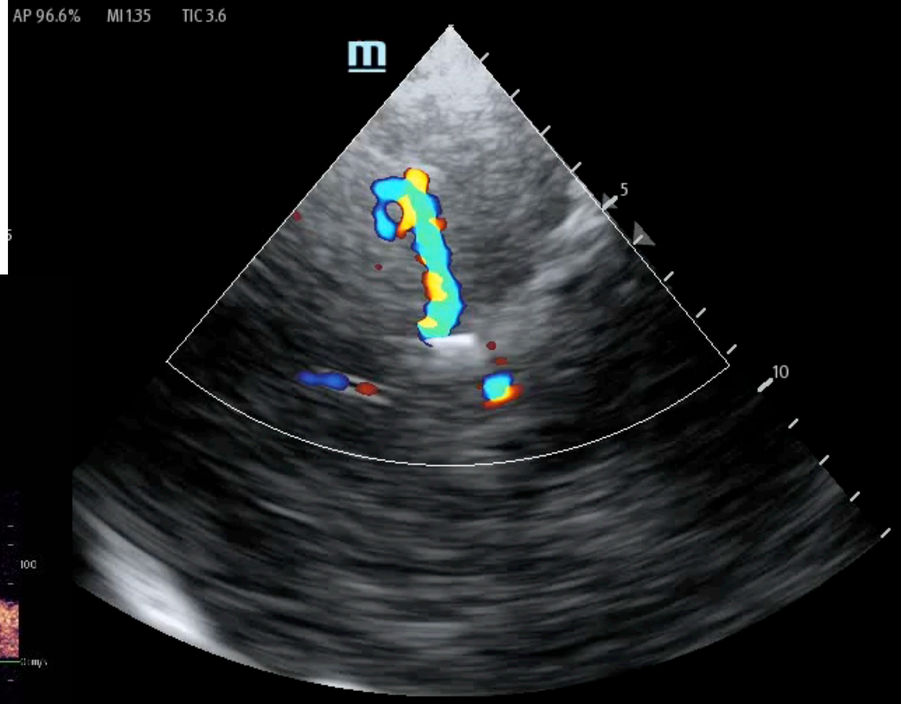

Step 3:

spectral Doppler waveforms can be obtained through pulse Doppler

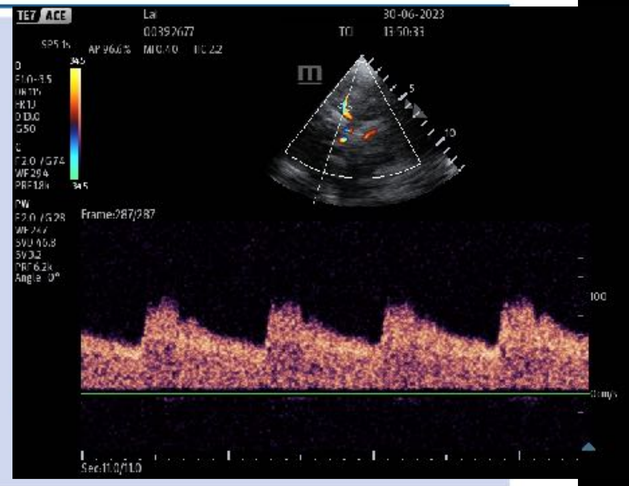

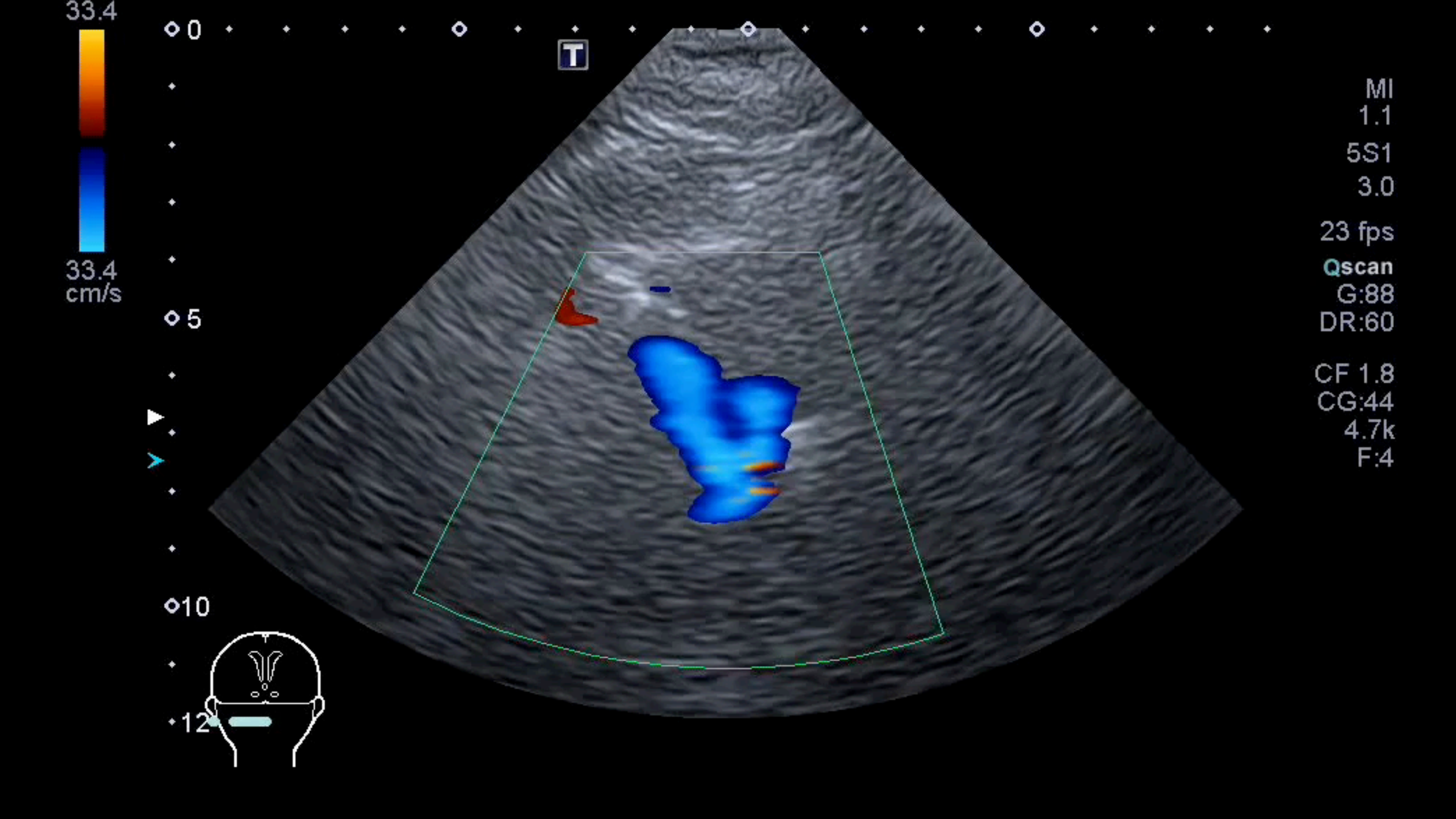
33.4
33.4
cm/s
0
5
10
12
T
MI
1.1
5S1
3.0
23 fps
Qscan
G:88
DR:60
CF 1.8
CG:44
4.7k
F:4

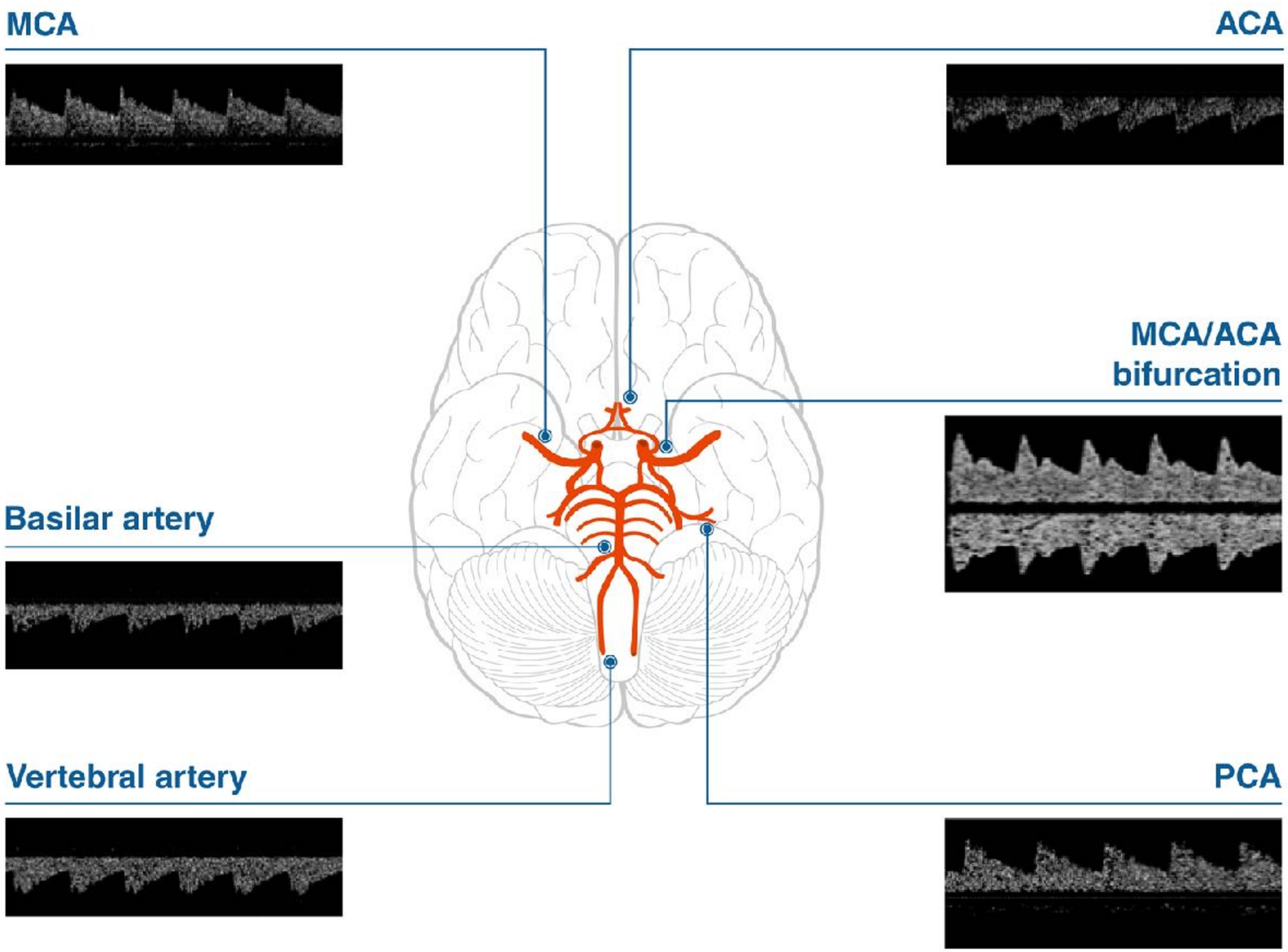
MCA
ACA
MCA/ACA
bifurcation
Basilar artery
Vertebral artery
PCA

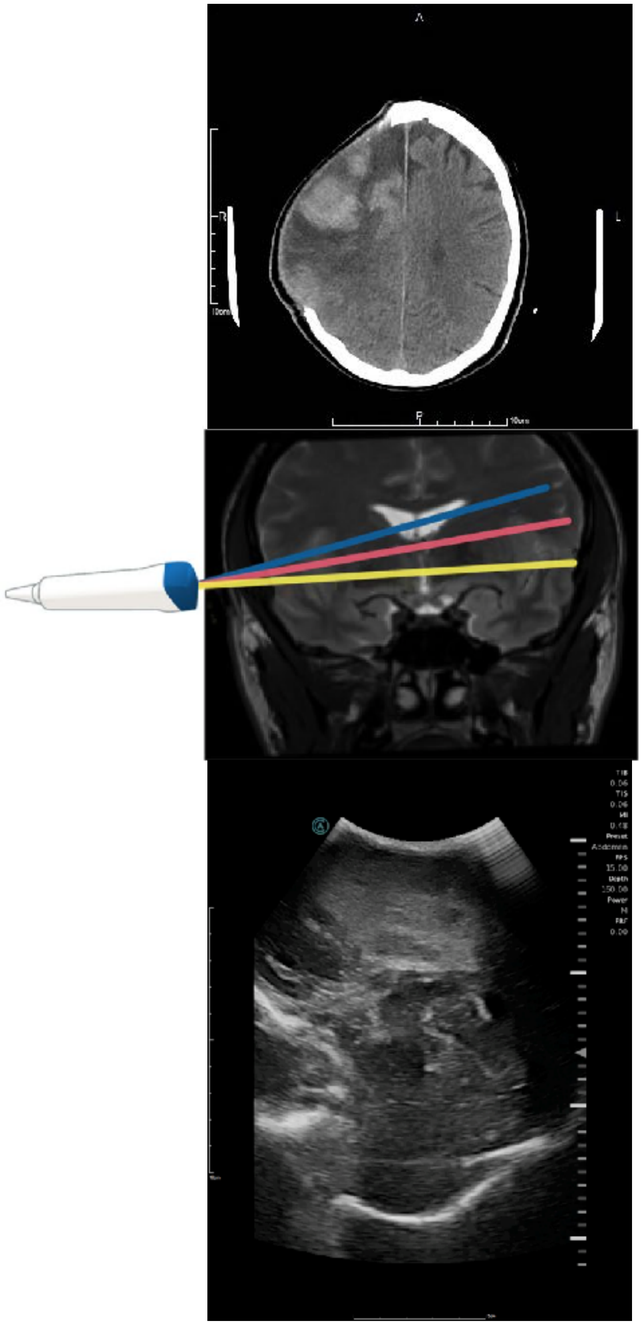

CT	Non-decompressed brain	DC
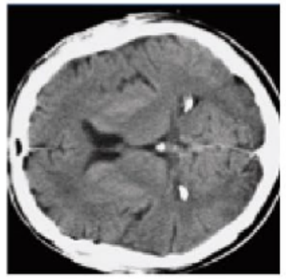	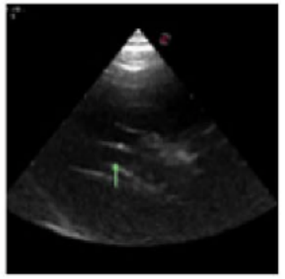	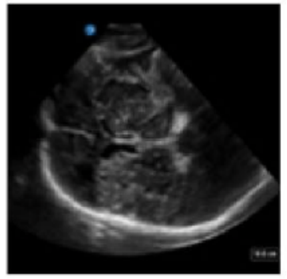
Ventricular plane		
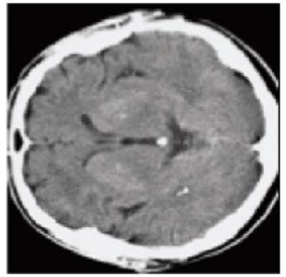	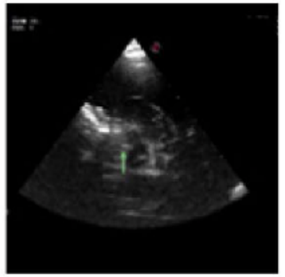	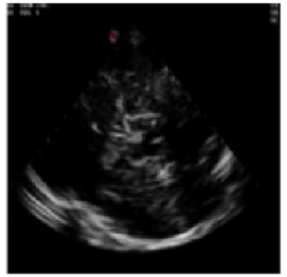
Diencephalic or III ventricle plane		
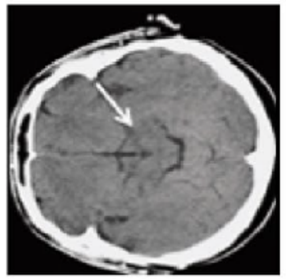	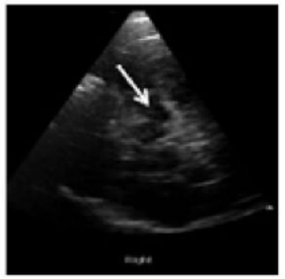	
Mesencephalic plane		

Lau and Arntfield *Crit Ultrasound J* (2017) 9:21
DOI 10.1186/s13089-017-0077-9

Critical Ultrasound Journal

REVIEW

Open Access

Point-of-care transcranial Doppler by intensivists

Vincent Issac Lau[1,2*] and Robert Thomas Arntfield[1,2]

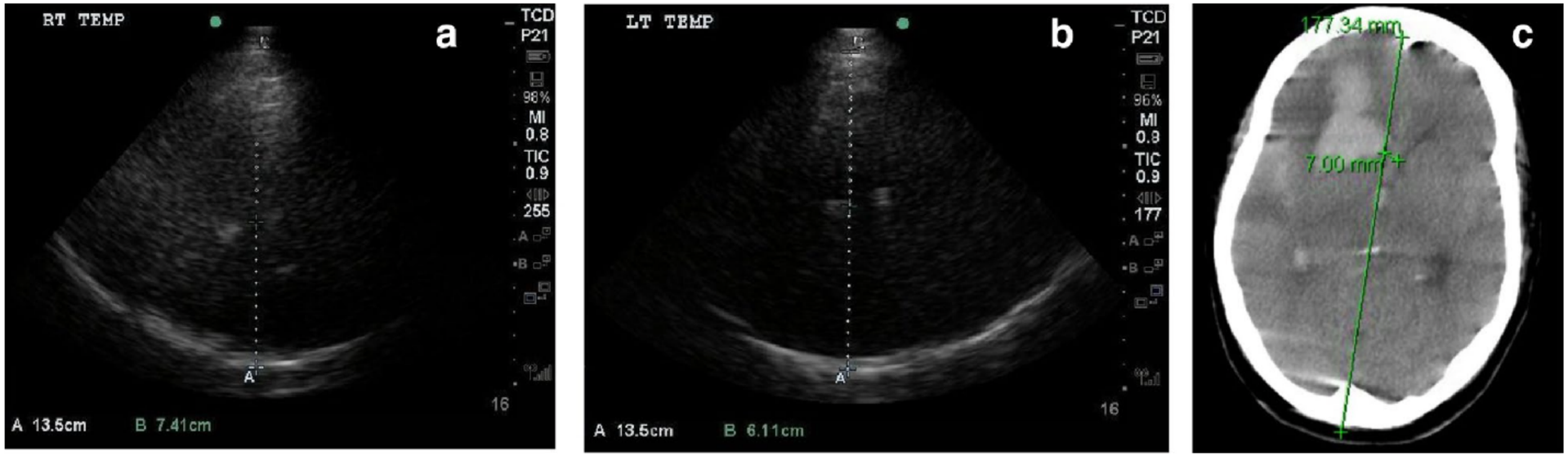

Fig. 1 Transcranial imaging for midline shift. **a** Insonation from right temporal bone to third ventricle, representing distance A (7.41 cm). **b** Insonation from left temporal bone to third ventricle, representing distance B (6.11 cm). **c** Follow-up CT scan post TCD which reveals midline shift to be 7 mm

Midline shift (MLS)

Midline shift = (distance A - distance B)/2; > 0.5 cm = poor outcome

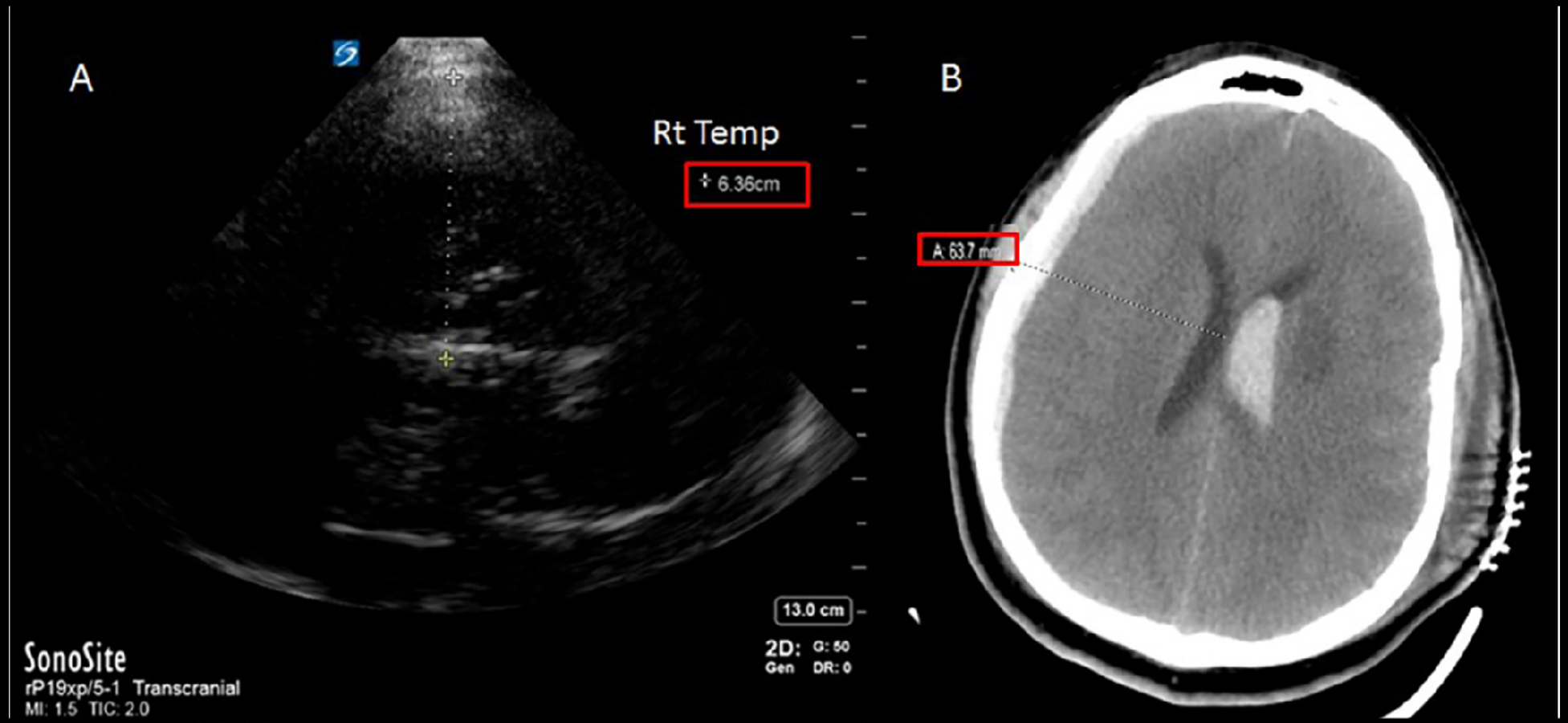

Montrief, T., et al. (2019). Incorporation of Transcranial Doppler into the emergency department for the neurocritical care patient. American Journal of Emergency Medicine 37(6): 1144-1152

ONSD for ICP

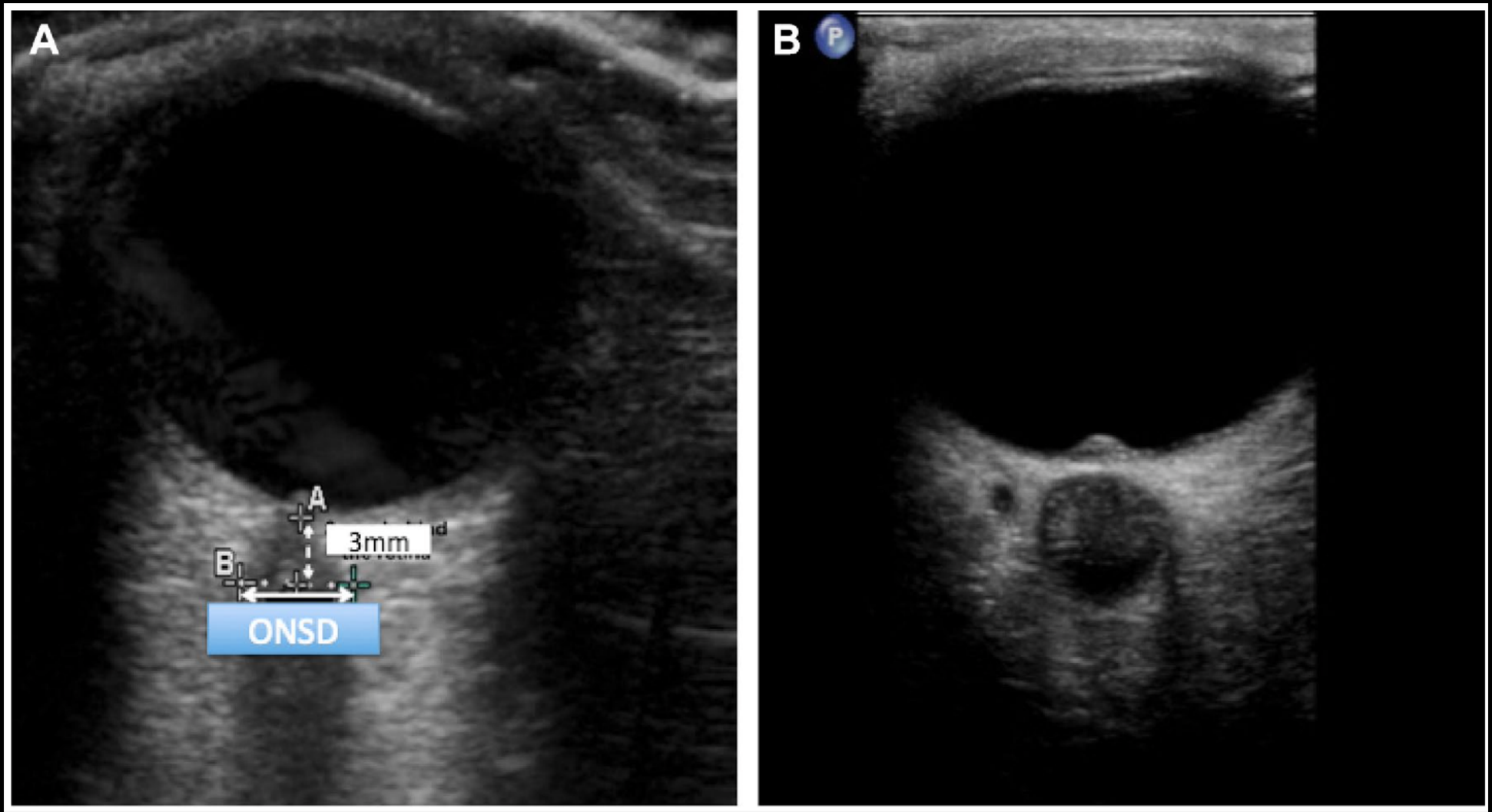

Increased ICP changes MCA flow

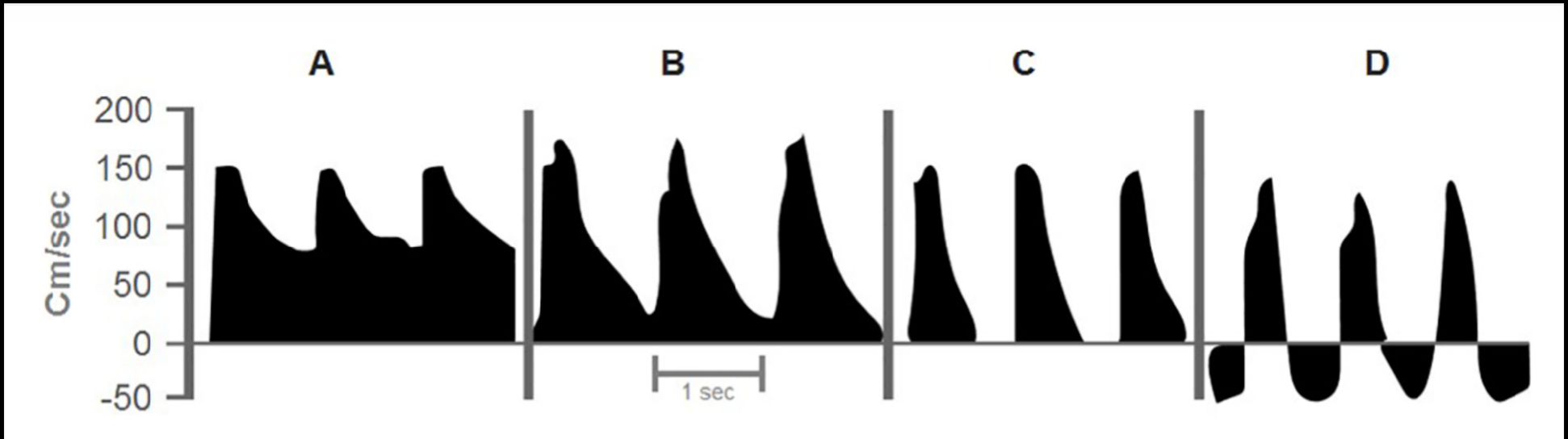

ICP measurement

Normal PI < 1.2 ~ ICP 12 mmHg

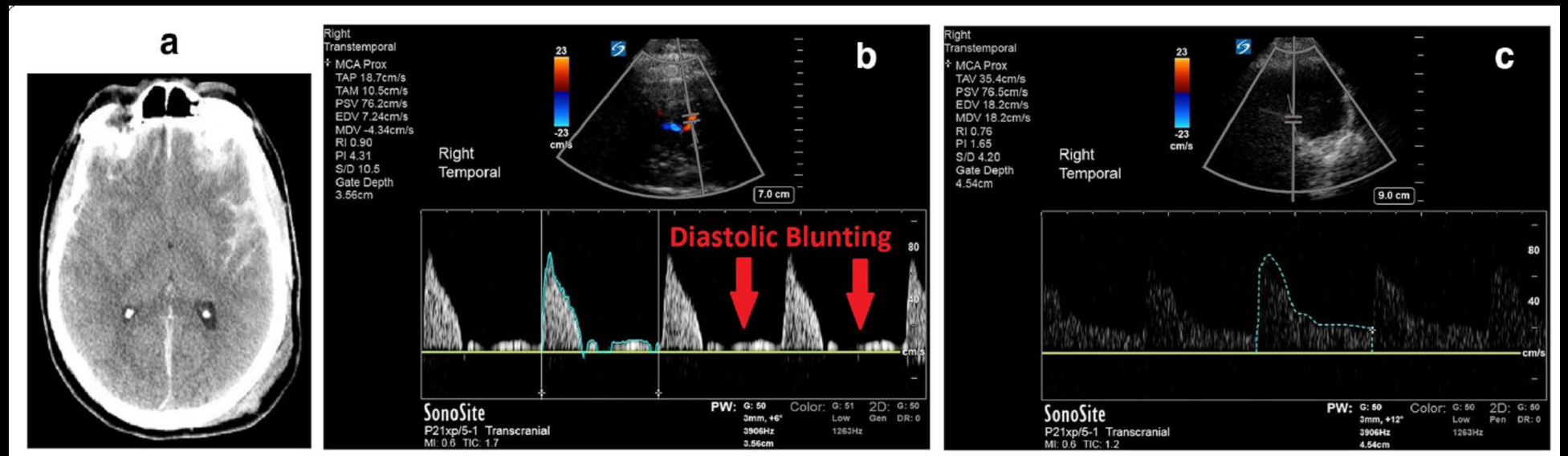

Fig. 3 Raised intra-cranial pressure by spectral Doppler on TCD, as calculated by pulsatility index. **a** Diffuse subarachnoid hemorrhage on CT head. **b** Spectral Doppler of MCA, demonstrating diastolic blunting secondary to raised ICP (pulsatility index = 4.31, ICP = 46 mmHg). **c** Following interventions to reduce ICP, there was normalization of diastolic flow in the MCA, and resolution of high ICP (pulsatility index = 1.65, ICP = 17 mmHg)

PI > 2.13 ~ ICP > 22 mmHg

MCA Vasospasm

	Time Averaged Mean (TAM)
Normal	< 80 cm/sec
Mild Vasospasm	>120 cm/sec
Moderate Vasospasm	> 160 cm/sec
Severe Vasospasm	> 200 cm/sec

CORE ULTRASOUND

Vasospasm

Lindegaard Ratio

Hyperemia	< 3
Mild Vasospasm	> 3
Moderate Vasospasm	> 4.5
Severe Vasospasm	> 6

Lindegaard ratio: MCA mean velocity / ICA (extracranial) mean velocity

Vasospasm

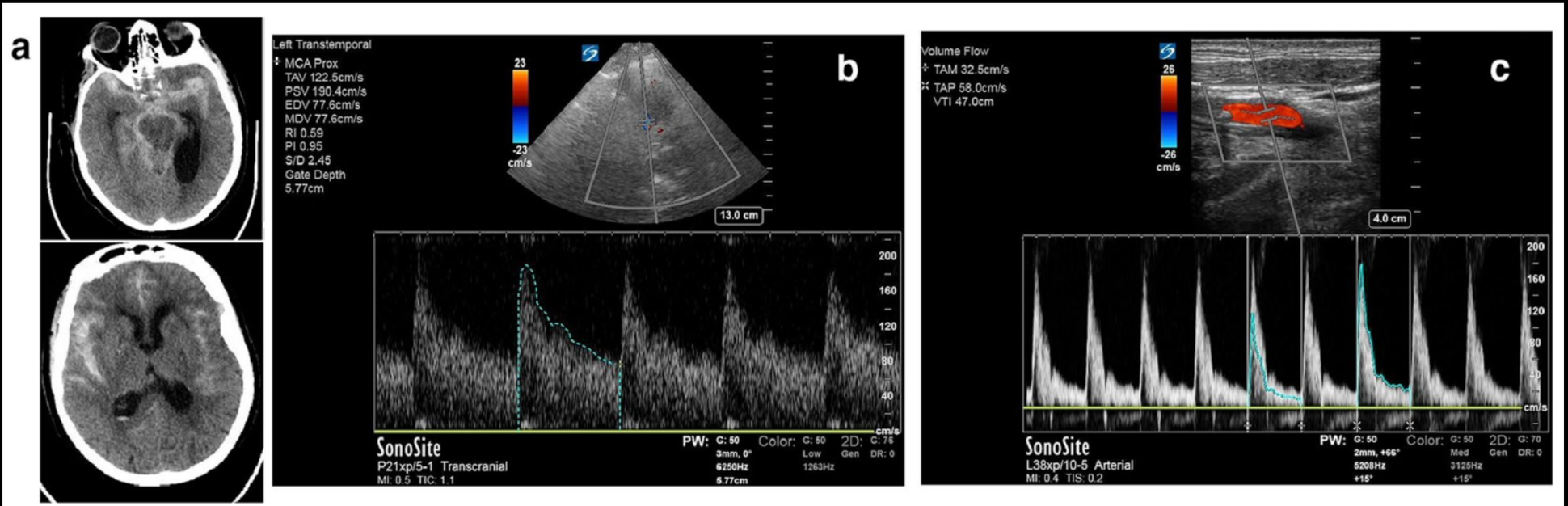

Fig. 2 Transcranial Doppler for vasospasm following subarachnoid hemorrhage. **a** CT Head demonstrating diffuse subarachnoid hemorrhage. **b** TCD measurement of left MCA flows, demonstrating a mean MCA velocity of 123 cm/s (in-keeping with mild vasospasm). **c** Measurement of ipsilateral left ICA flows for calculation of Lindegaard ratio of 3.8 (Mean MCA/ICA velocity = 123/32.5 cm/s), which confirmed mild MCA vasospasm

Progressive changes in the waveform morphology of the middle cerebral artery.

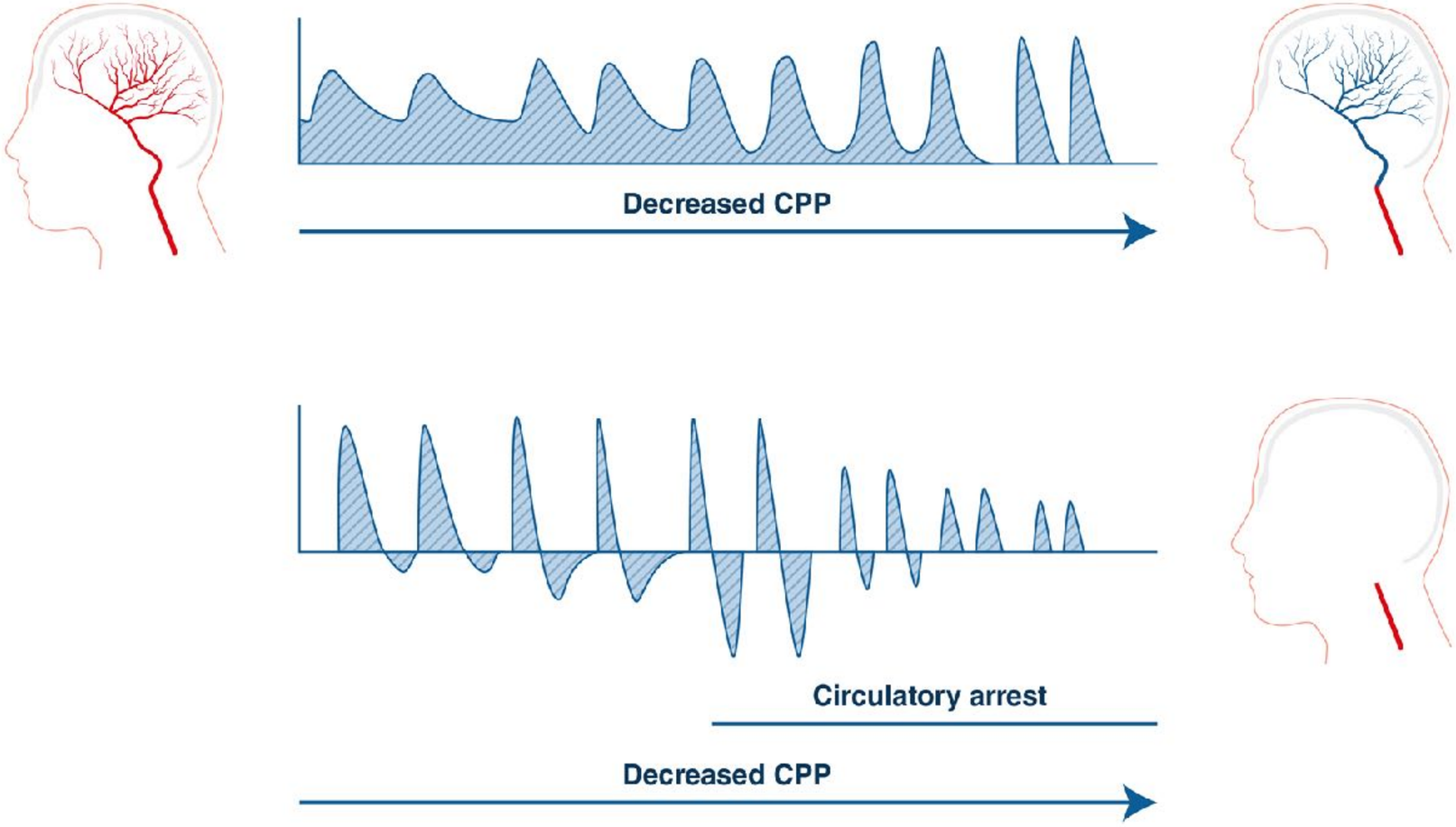

(Modified from Hassler W, Steinmetz H, Pirschel J. Transcranial Doppler study of intracranial circulatory arrest. J Neurosurg 1989; 71(2):195 – 201).

Cerebral Circulatory Arrest

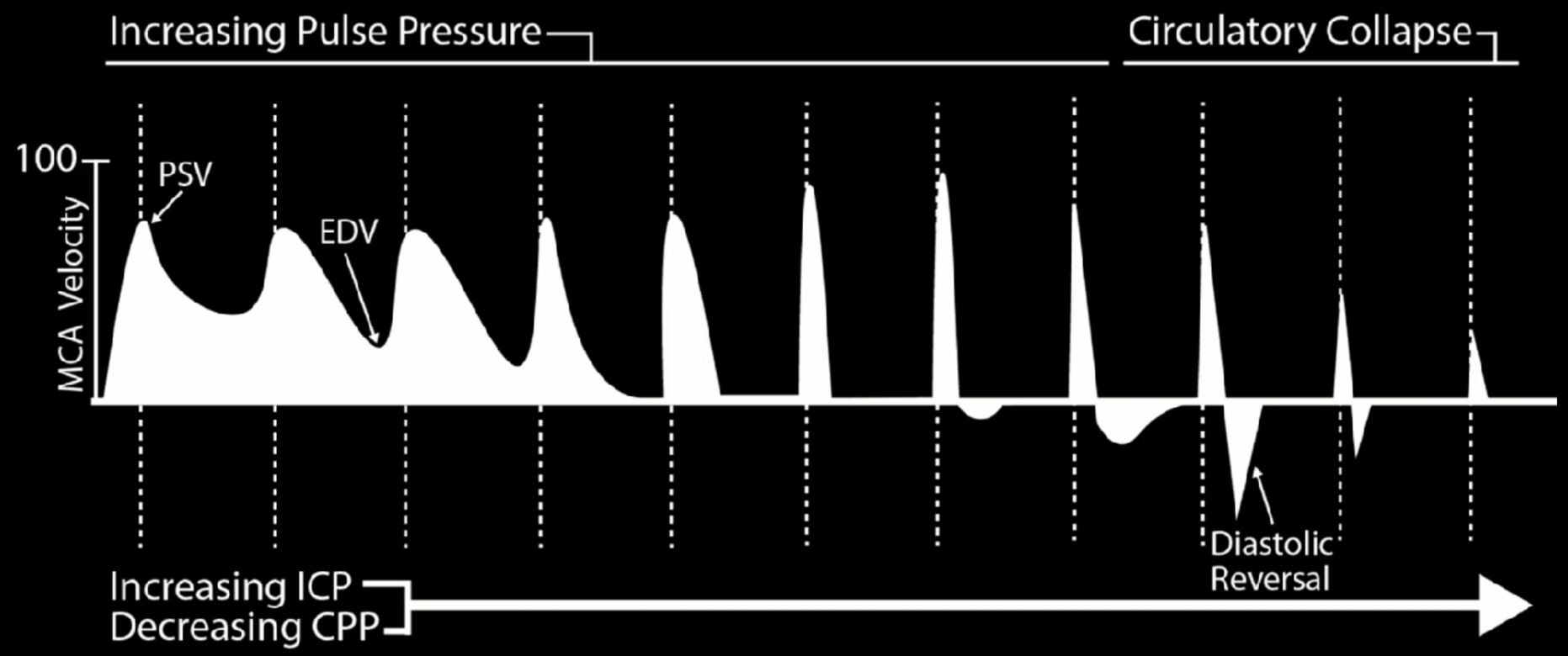

Adapted from: Hassler W, Steinmetz H, Pischel J. Transcranial Doppler study of intracranial circulatory arrest. J Neurosurg 1989; 71(2):195-201.

CORE ULTRASOUND

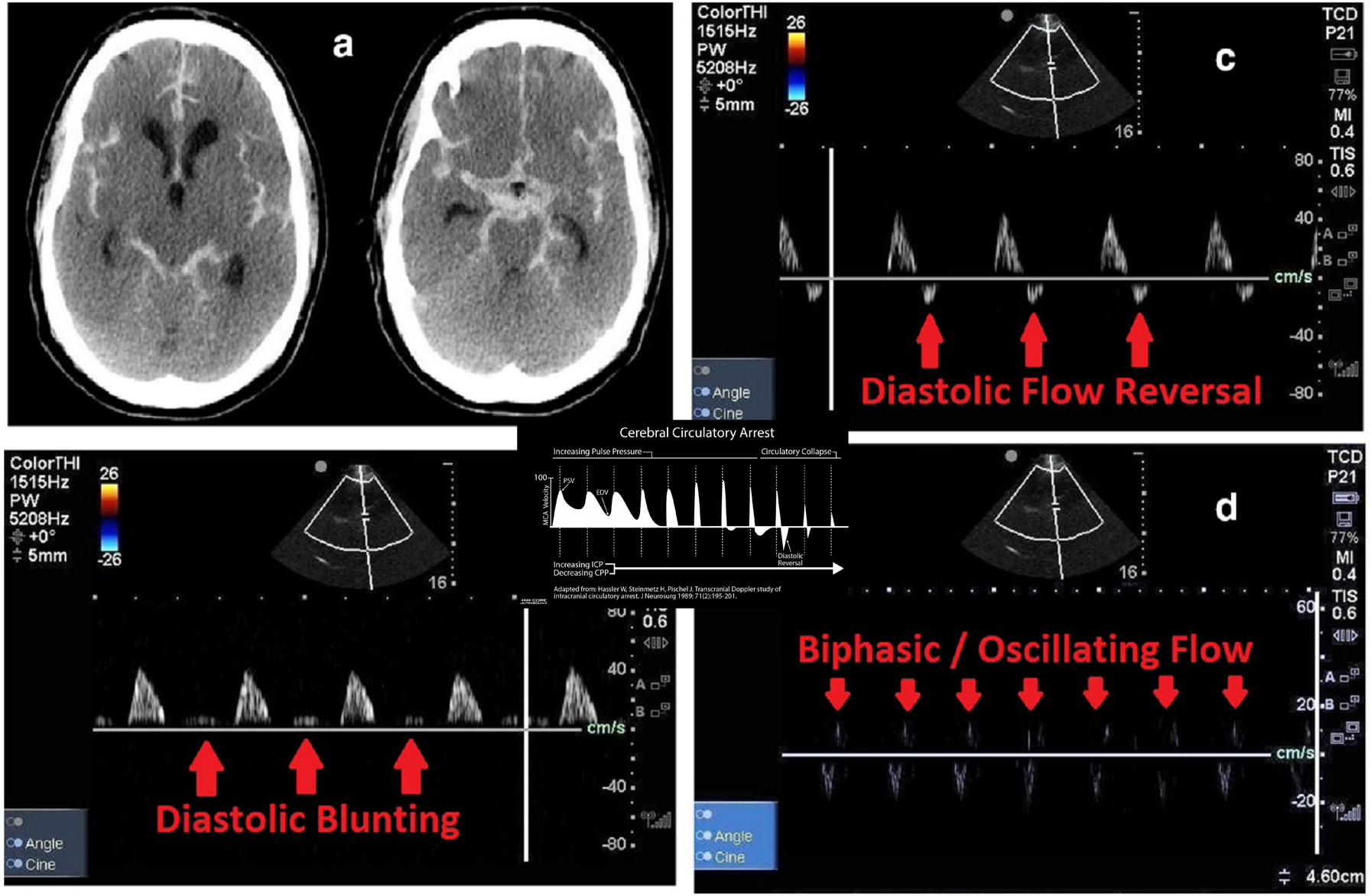

Fig. 4 Step-wise progression of cerebral circulatory arrest. **a** CT Head demonstrating diffuse subarachnoid hemorrhage. **b** Evidence of raised ICI causing decreased diastolic flow as evidenced by blunting of the spectral Doppler signal. **c** Further progression with diastolic flow reversal as rai ICP prevents forward flow in MCA, and even induces backwards flow. **d** Biphasic and oscillating flow as evidenced by net zero flow (where systo and diastolic flow are near equal to each other), indicating the first TCD stage of cerebral circulatory arrest

TCD for neurocritical care

Hydrocephalus		Marked dilated third (white line) and lateral ventricles (green lines)
Subdural haemorrhage		Subdural temporal hyperechoic collection (white arrow) in patient with TBI and neurological deterioration
Intracranial haemorrhage		Right-sided intracranial hyperechoic area consistent with haemorrhage (white arrow) in patient with decompressive craniectomy
Midline shift	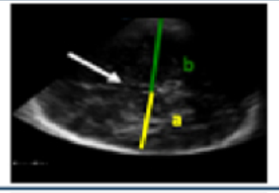	Diencephalic plane showing the typical appearance of the third ventricle; midline shift can be estimated by measuring the distances between homolateral and contralateral temporal bone with third ventricle [(a-b)/2]
Vasospasm	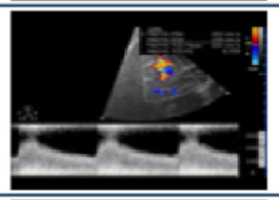	Increased MCA flow velocities, in a patient with Lindegaard ratio = 6, suggesting cerebral vasospam
Brain death	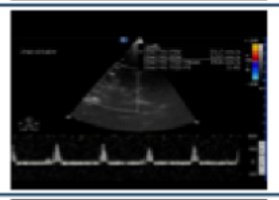	TCD flow pattern characteristic of severe intracranial hypertension leading to cerebral circulatory arrest
Central nervous system infections		Dilated ventricles with presence of endo-ventricular bacterial vegetations and the posterior horns of the lateral ventricles in patient with post-traumatic meningoencephalitis.

TCD for general ICU & ED

Liver failure	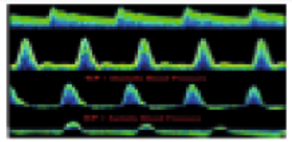  	Intracranial hypertension, haemorragic complications, flow pattern
Post-cardiac arrest syndrome	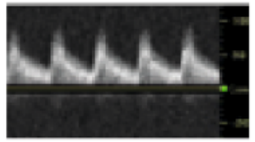  	Intracranial hypertension, flow pattern evolution during and after CPR
Severe respiratory Failure-ECMO	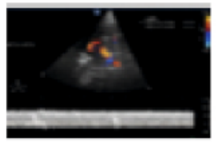  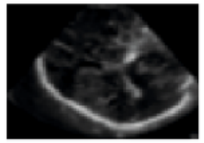	Intracranial hypertension, bleeding flow pattern
Polytrauma	  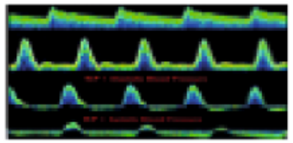	Intracranial hypertension, bleeding flow pattern evolution, intracerebral bleeding
Stroke	 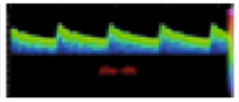 	Flow pattern evolution during reperfusion, intracerebral bleeding
Sepsis	  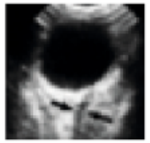	Flow pattern changes predictive for septic encephalopathy, cerebral oedema
Paediatric population	  	Intracranical bleeding, cerebral masses, intracranial hypertension
Pregnancy	  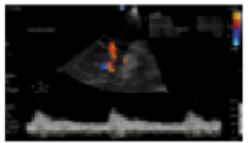	Intracranical bleeding, hypertension, neurological complications related to eclampsia

44F, 在廚房跌倒撞到後腦

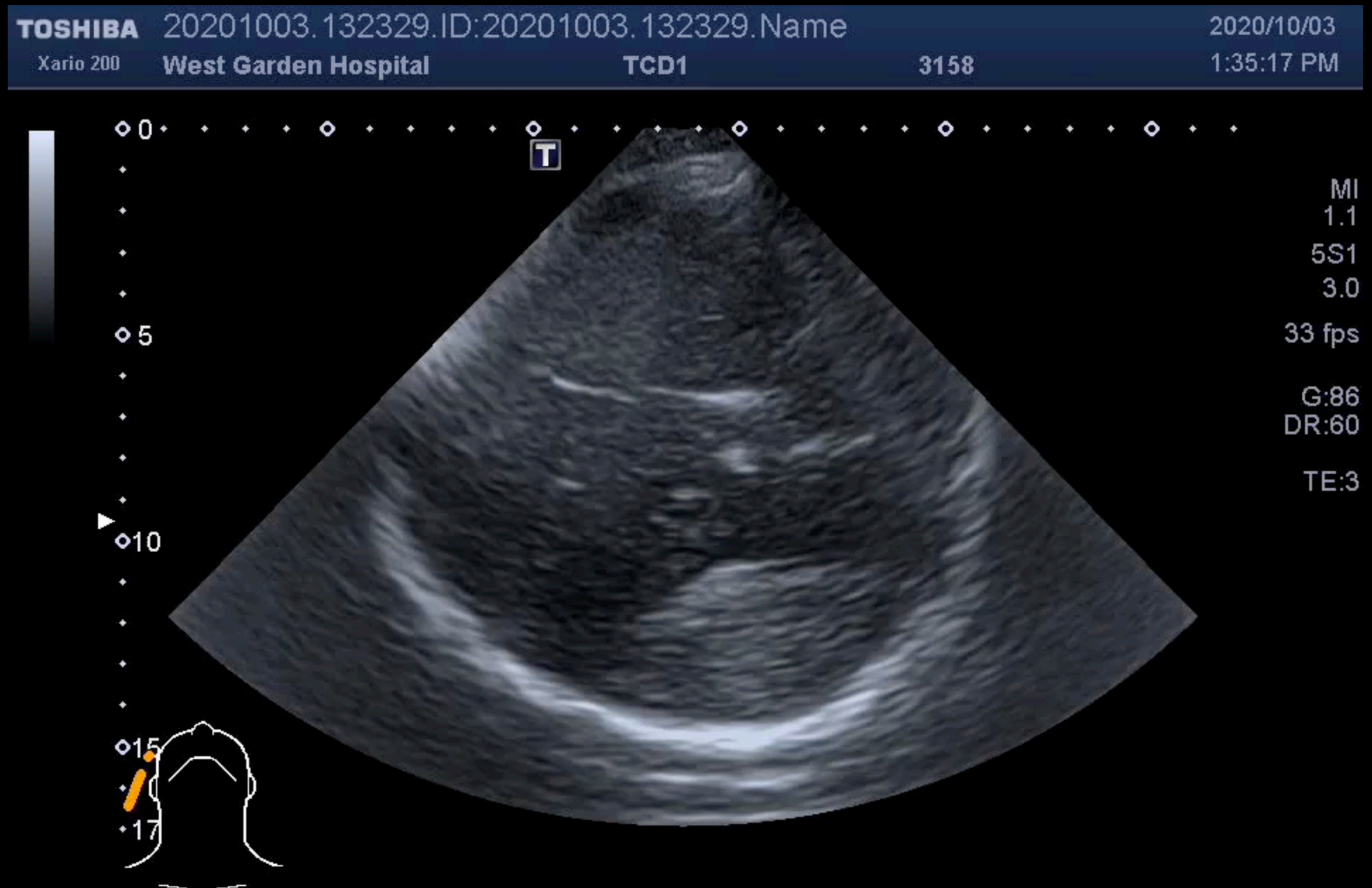

44F, 在廚房跌倒撞到後腦

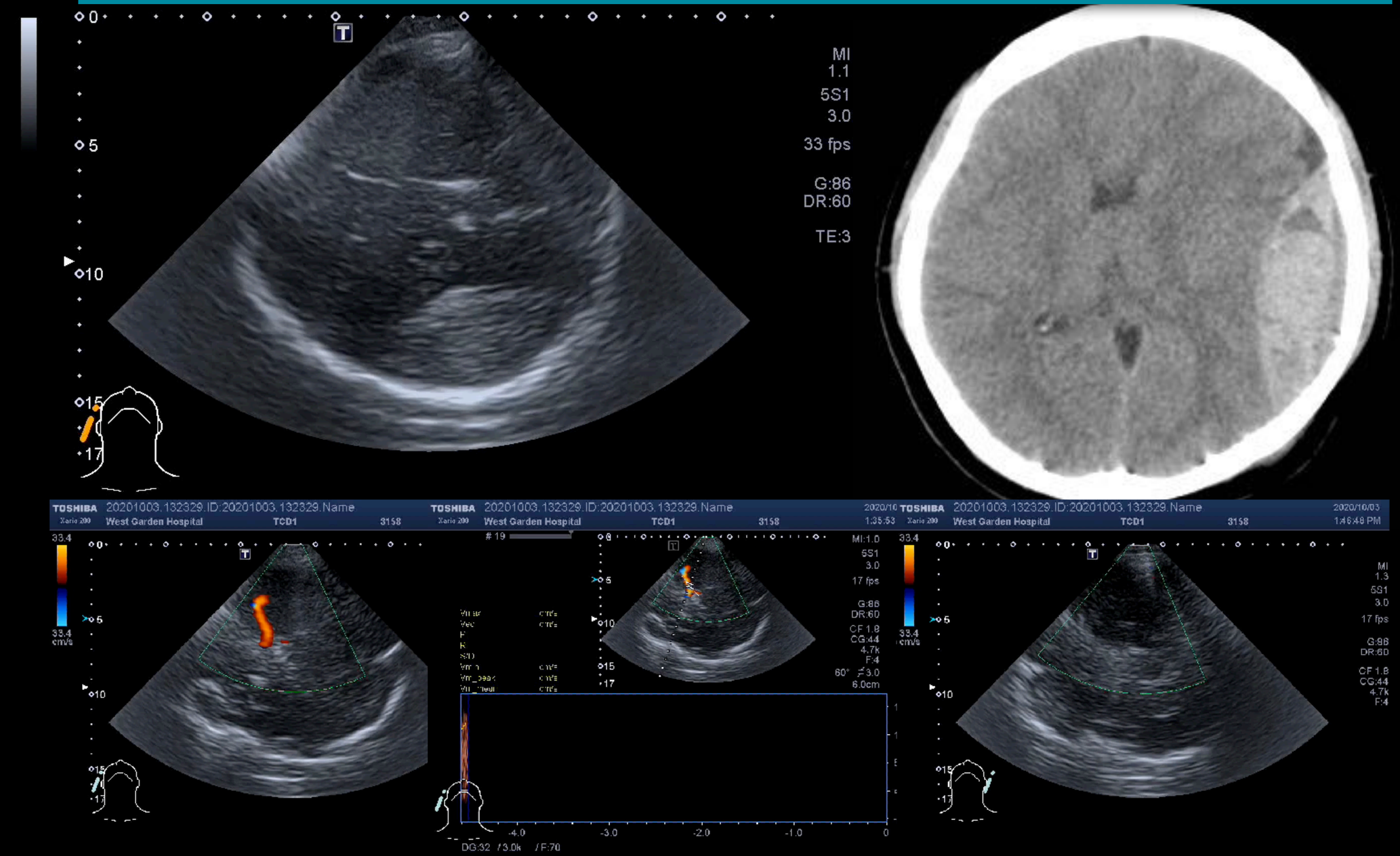

62M, Skull fx & traumatic ICH/ SAH

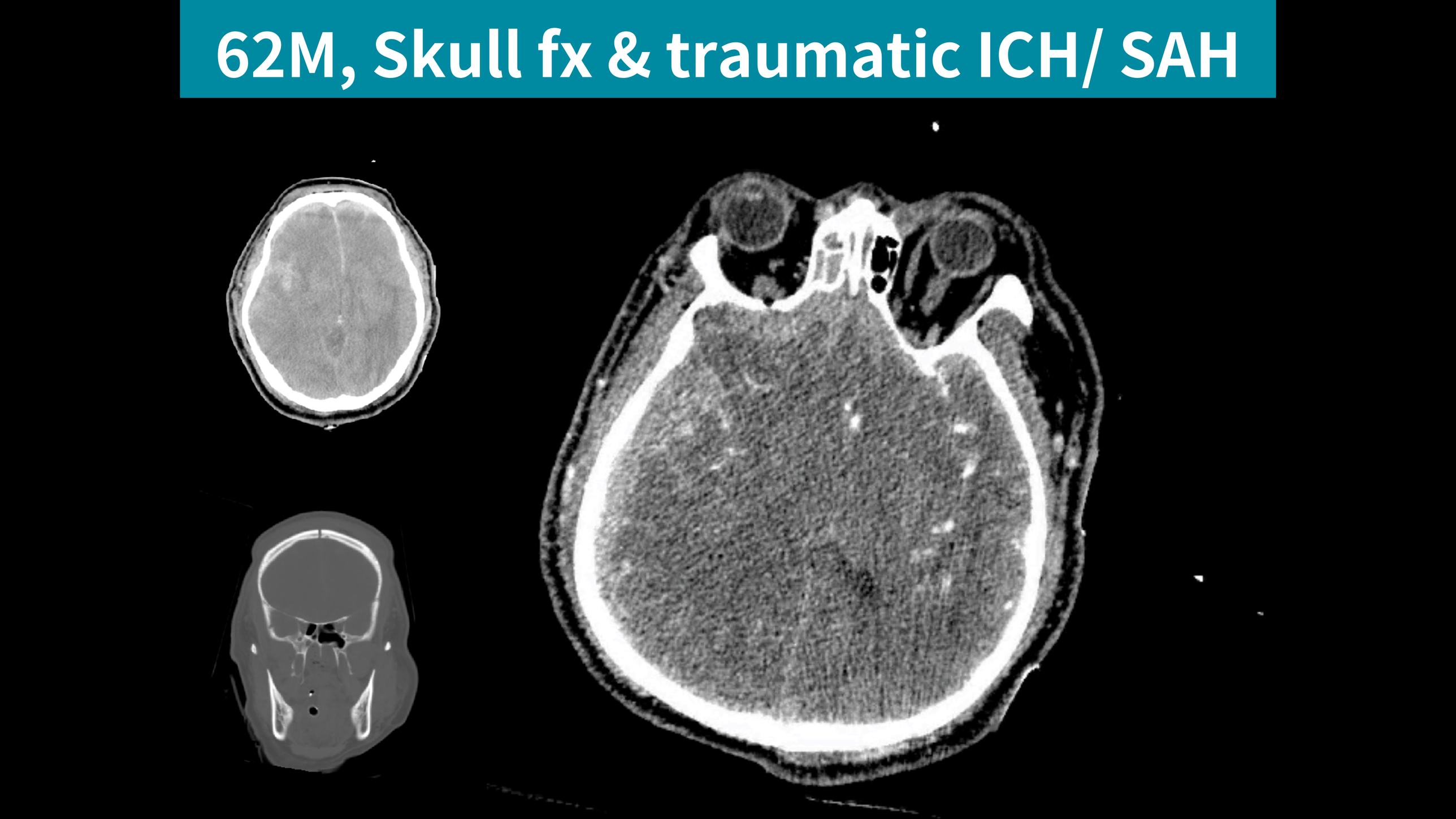

62M, Skull fx & traumatic ICH/ SAH

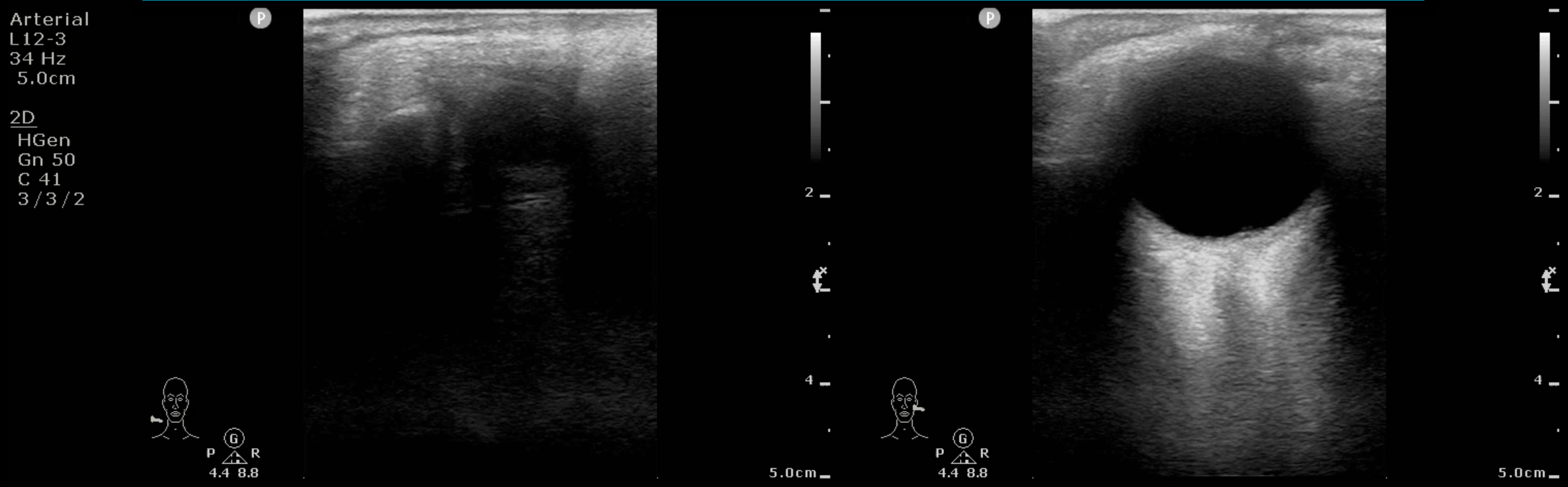

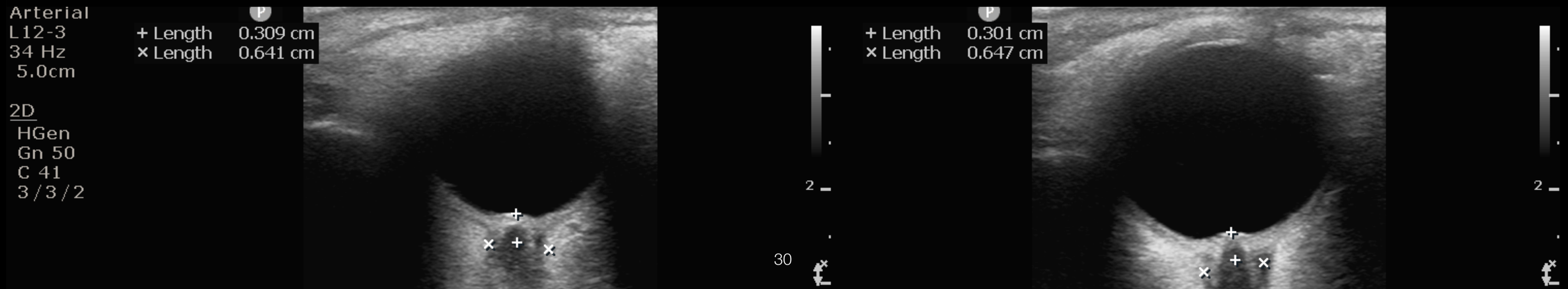

62M, Skull fx & traumatic ICH/ SAH

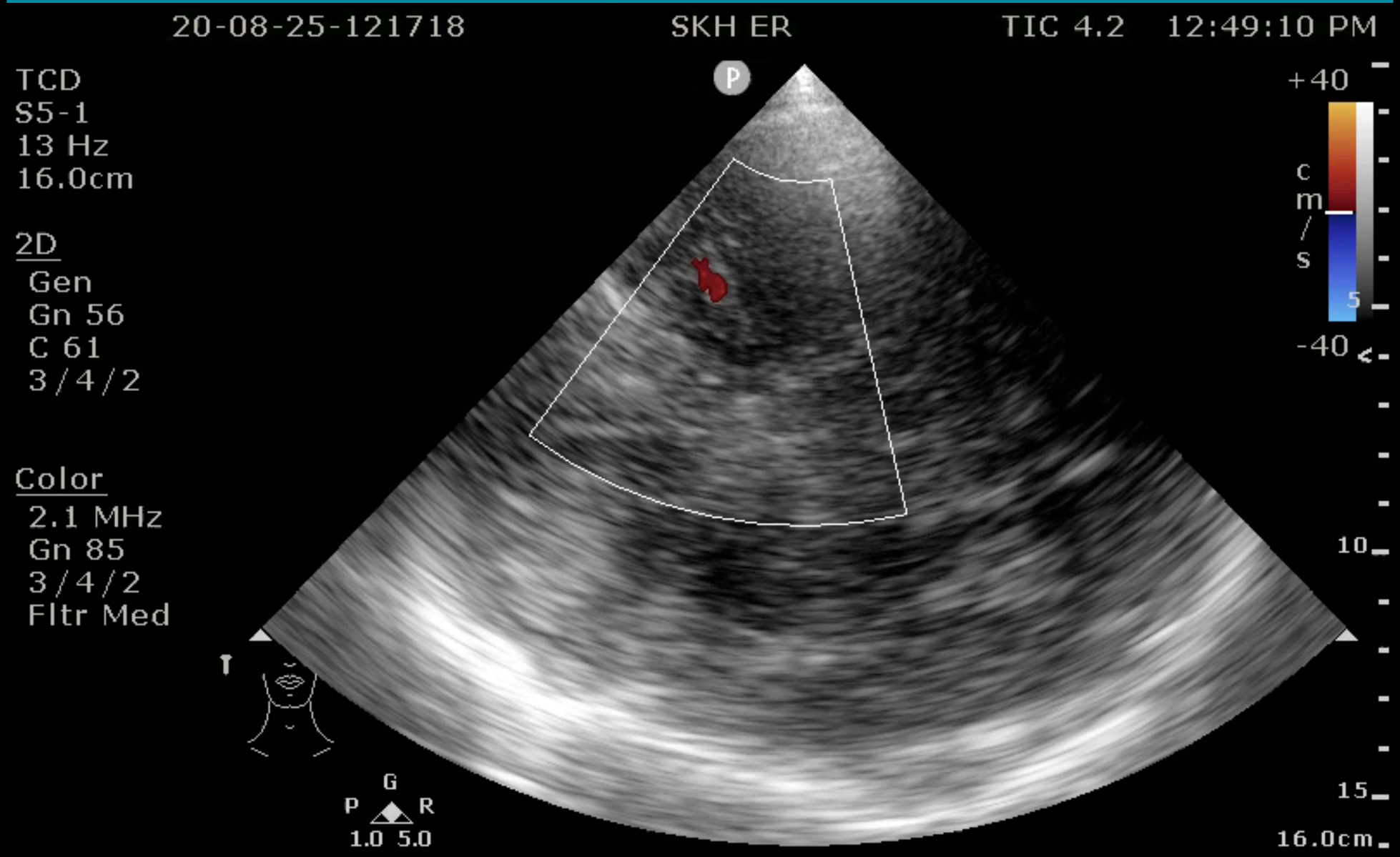

62M, Skull fx & traumatic ICH/ SAH

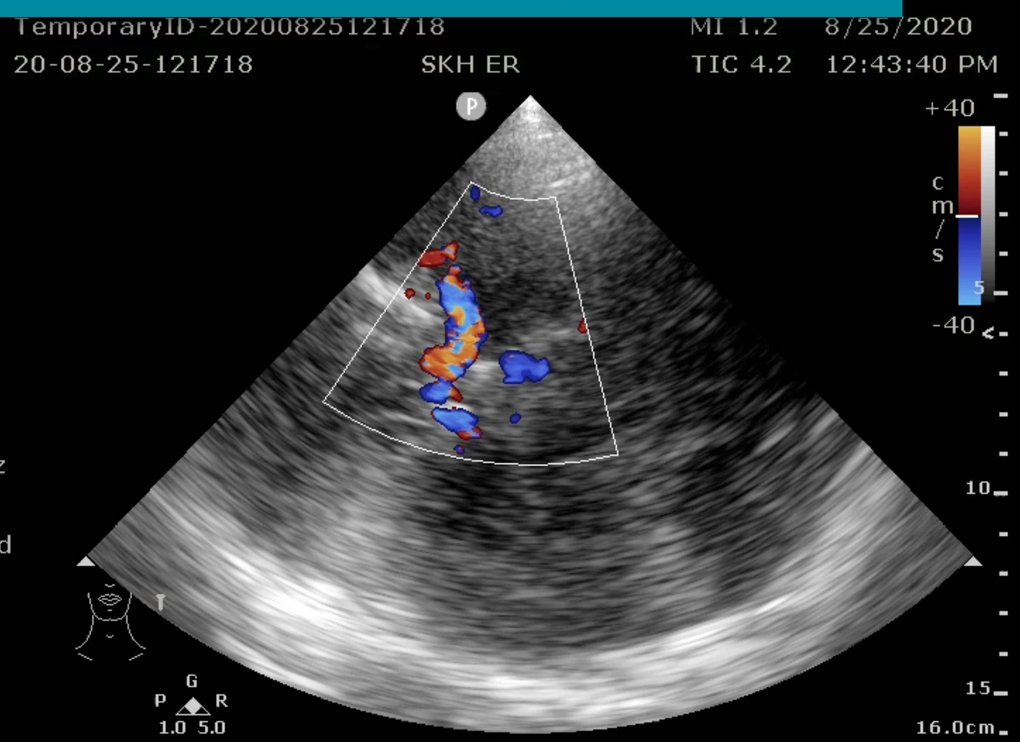

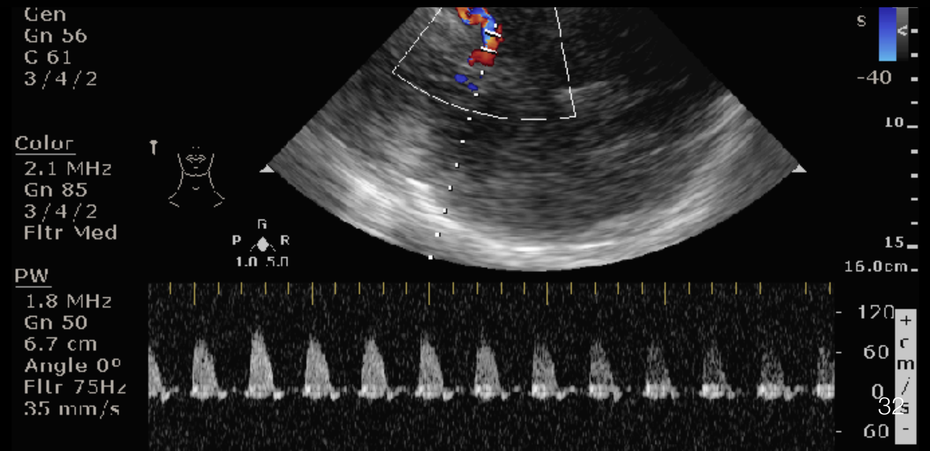

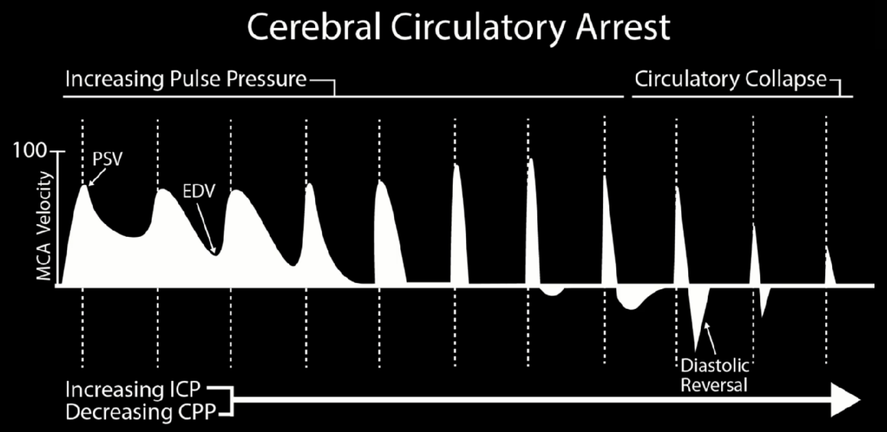

Adapted from: Hassler W, Steinmetz H, Pischel J. Transcranial Doppler study of intracranial circulatory arrest. J Neurosurg 1989; 71(2):195-201.

57M, AMS, 管理員發現倒在地下室

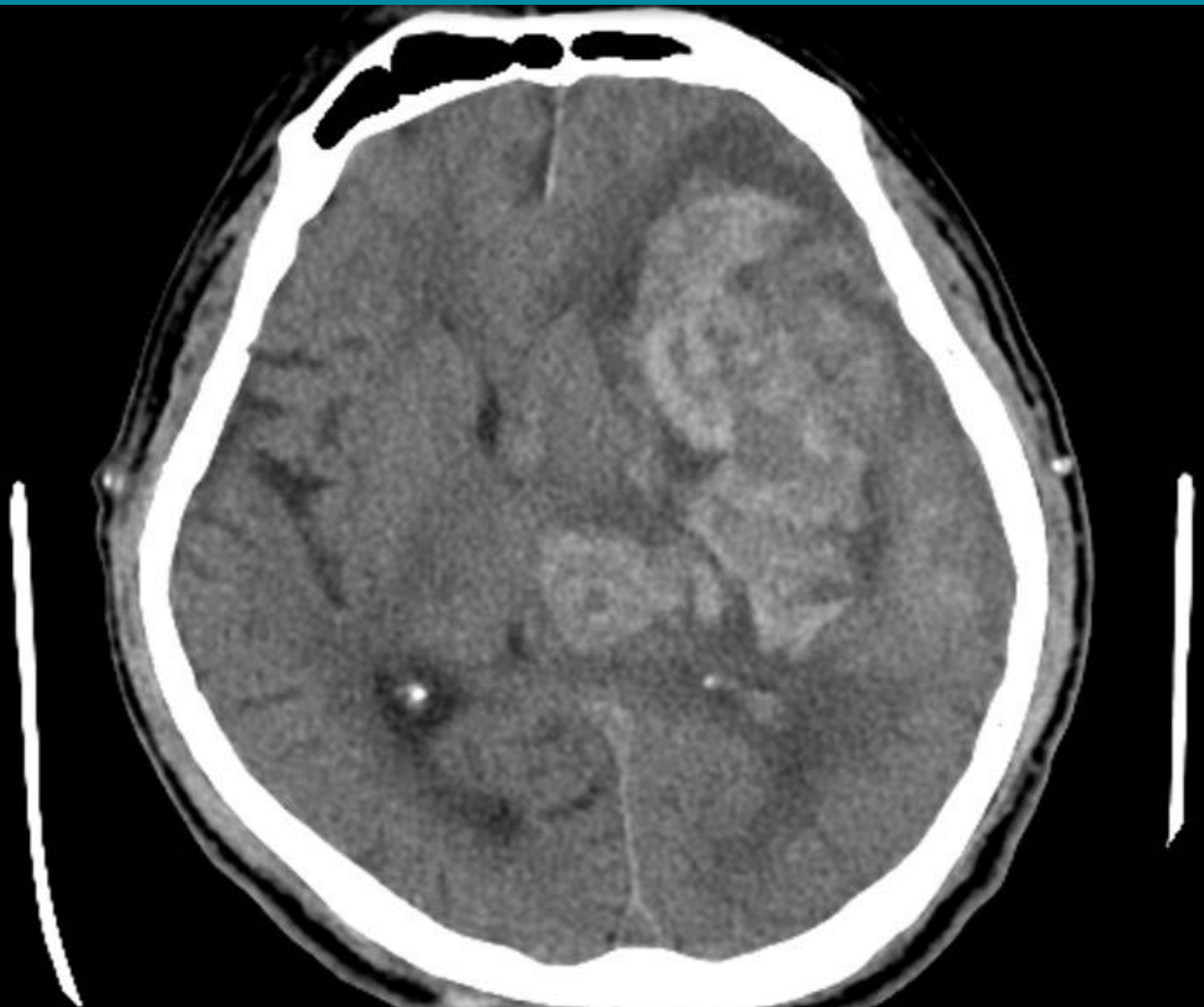

57M, AMS, 管理員發現倒在地下室

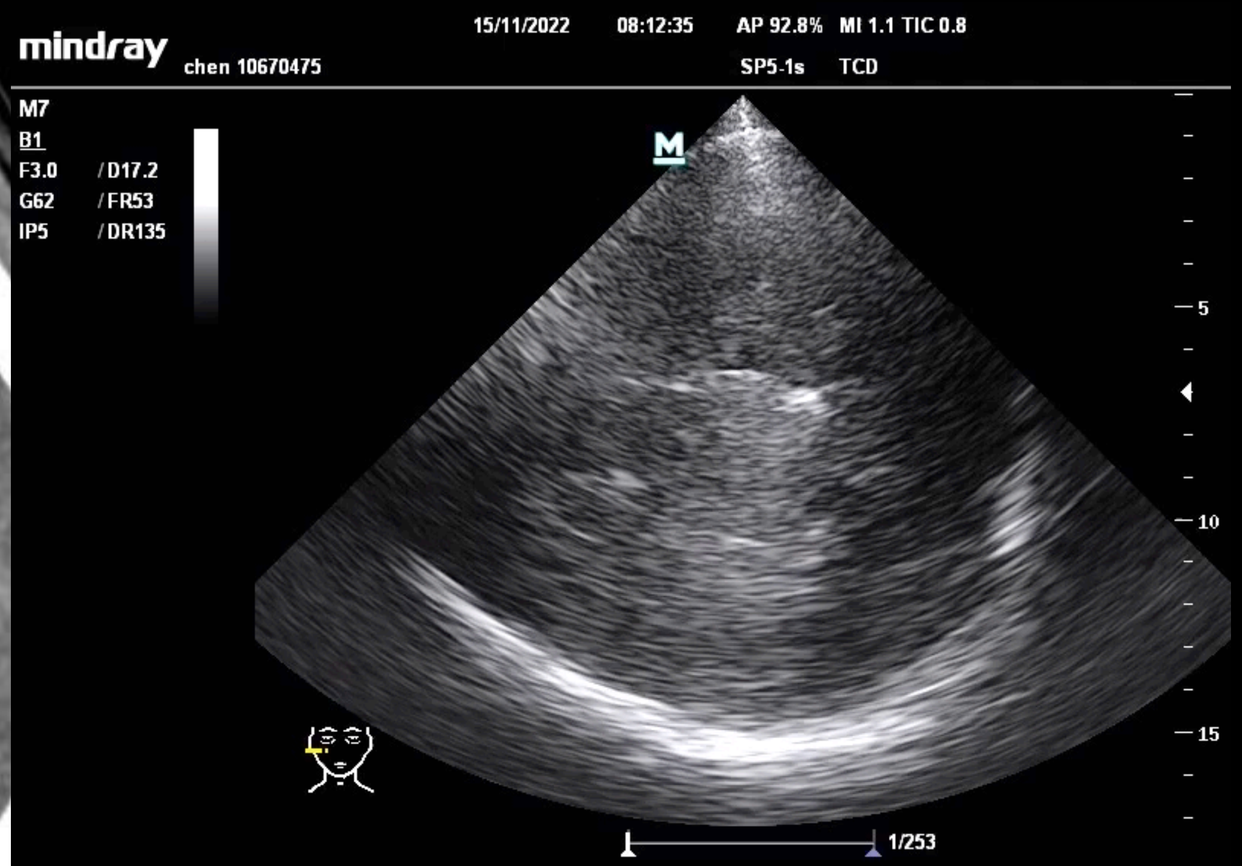

57M, AMS, 管理員發現倒在地下室

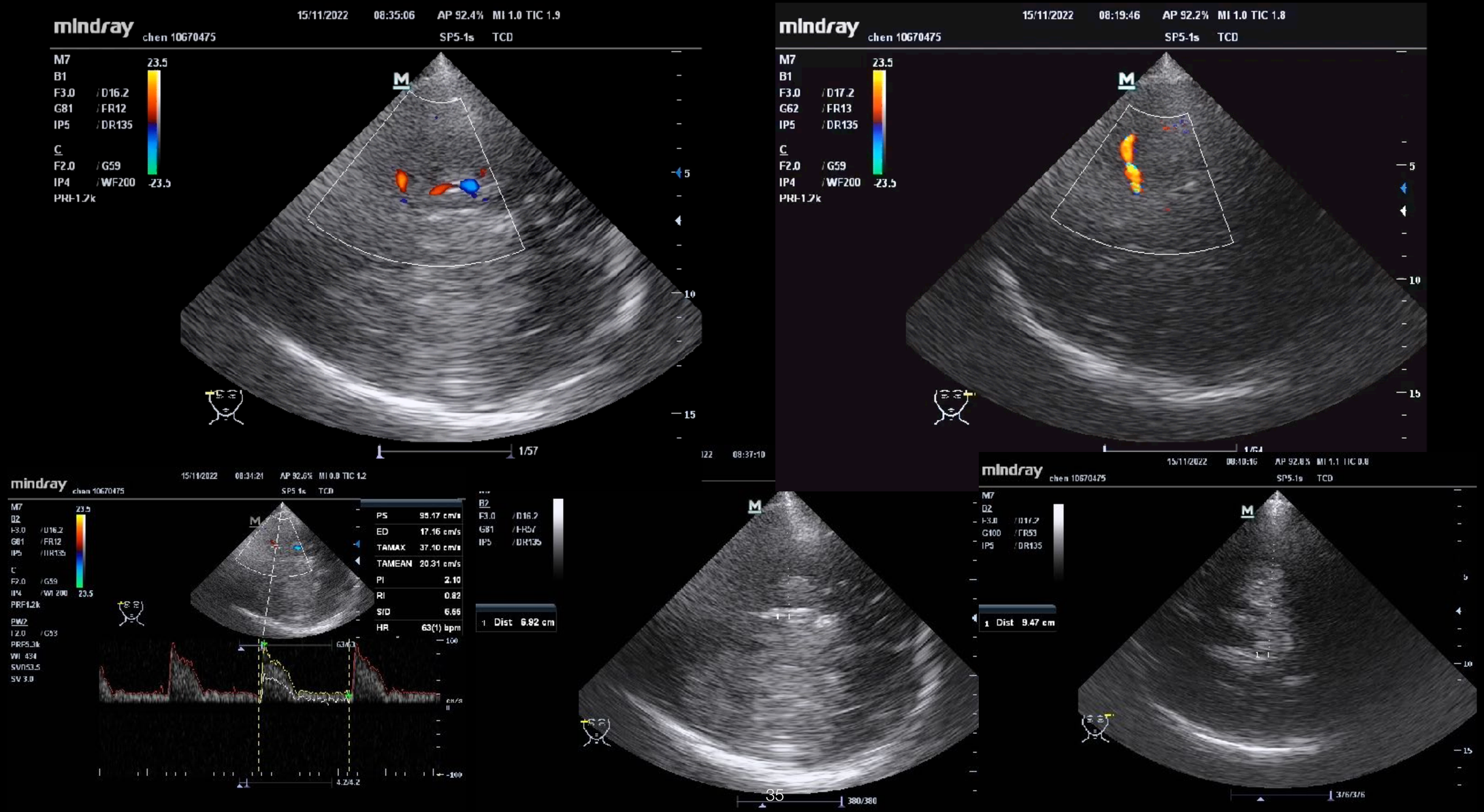

BUS in

TCD: diagnosis of arterial stenosis
- Reduced CBF velocities
- Changing flow patterns and velocities in controlateral arteries

TCD: during periprocedural thrombolysis with i recombinant tissue plasminogen activator (IV-r of symptom onset monitoring recanalization aft thrombolysis and thrombectomy

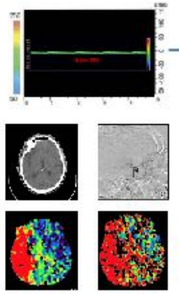

Reperfusion →

IV-rtPA
Or thrombectomy

MONITORING OF COMPLICATIONS OF REF

Complications:
- Haemorrhagic infarction
- Brain swelling

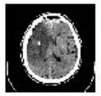

BUS: diagnosis of
- Midline shift
- Intracerebral haemorrhage of IV-tPA treatment for isch

BUS: BUS guided therapy
BUS is useful in evaluating efficacy of both me surgical treatment of intracerebral haemorrhag intracranial hypertension

PoCUS in (Resuscitation guidance, R

Bra

ONSD: intracranial hypertension

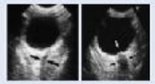

USVASC: us-guided vascular access

USVASC: us-guided vascular access

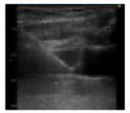

LUS: ptx diagnosis

LUS: post ca pulmonary edema/atelectasis, post cpr lung contusions/ptx/hemothorax

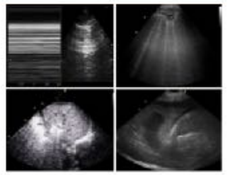

USVASC: e-cpr guidance (ecmo cannulas size choice, placement &position check)

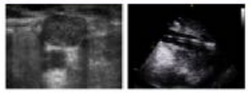

RESUSCITATION GUIDANCE

PoCUS in MULTIPLE TRAUMA

Brain Ultrasound: ICP and Cerebral Blood Flow

ONSD: raised ICP screening intracranial haemorrhage, hydrocephalus
MLS: midline shift detection

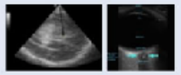

PI: pulsatility index
ECCP: Estimated CPP formula

$$PI = \frac{\text{peak systolic velocity - end diastolic velocity}}{\text{mean flow velocity}}$$

$$eCPP = (FVd/FVm)*mABP+14$$

TCD (flow pattern evolution)

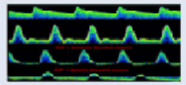

USVASC: US-guided vascular access

USVASC: US-guided vascular access

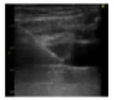

LUS: PTX/hemothorax diagnosis - chest drainage

LUS: PTX/hemotorax monitoring, lung contusions/atelectasis

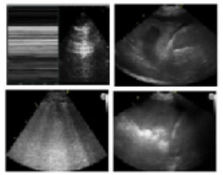

ABD US: free abdominal fluid

ABD: liver/spleen hematomas, kidney rupture, pneumoperitoneum, urinary catheter

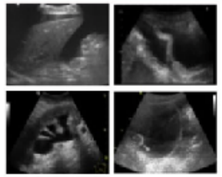

AIRWAY US: intubation check, correct tube position-emergency crycothirotomy

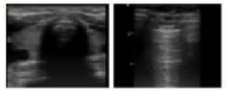

FoCUS: tamponade, severe hypovolemia, myocardial contusion-pericardiocentesis, fluid infusion, inotropes

FoCUS: hemodynamic optimization (persistent hypovolemia, pericardiocentesis monitoring)

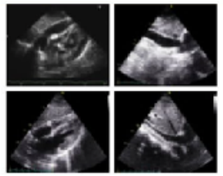

MSK-US: Ribs/sternal fractures - long bones fractures- soft tissues hematomas

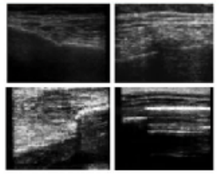

PRIMARY SURVEY SECONDARY SURVEY

TCD POCUS: VASOSPASM

Probe: Phased Array ($f \leq$ 2MHz)

Preset: TCD or Cardiac

Technique:

1. Transducer = Anterior to Ear
2. Indicator = Towards Eye in TCD / Occiput in Cardiac)
3. Color Doppler
4. Pulsed Wave Doppler
5. Spectral Analysis → Measure PSV & EDV

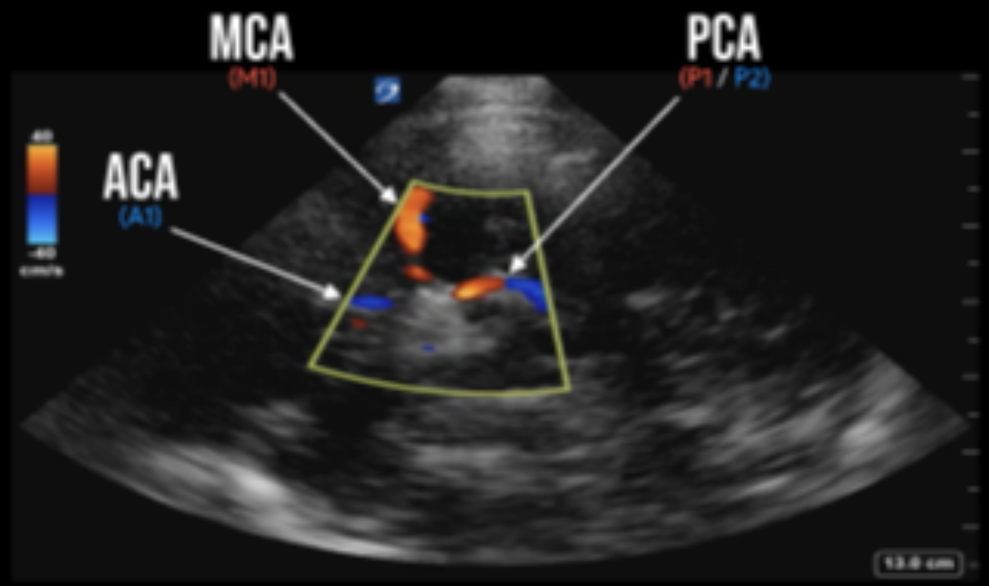

MCA MEAN FLOW VELOCITY (MCA MFV)

NORMAL	<80 CM/SEC
MILD	>120 CM/SEC
MODERATE	>150 CM/SEC
SEVERE	>200 CM/SEC

LINDEGAARD RATIO (LR)

<3	HYPERAEMIA	
>3	VASOSPASM	
	→ 3-6	MILD-MODERATE
	→ >6	SEVERE

MCA MFV = EDV + ⅓ (PSV-EDV)

$$LR = \frac{\text{IPSILATERAL MCA MFV}}{\text{IPSILATERAL ICA MFV}}$$

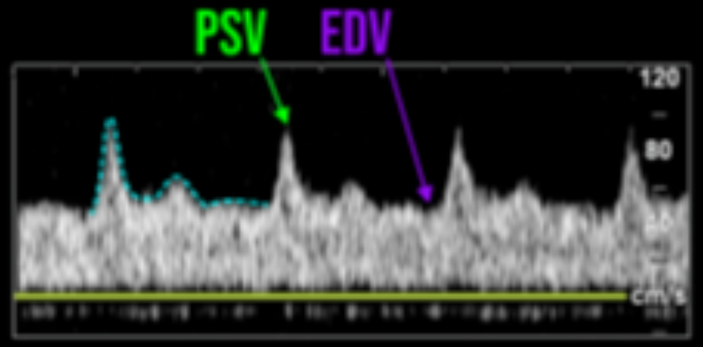

https://www.acep.org/emultrasound/newsroom/feb2024/transcranial-doppler

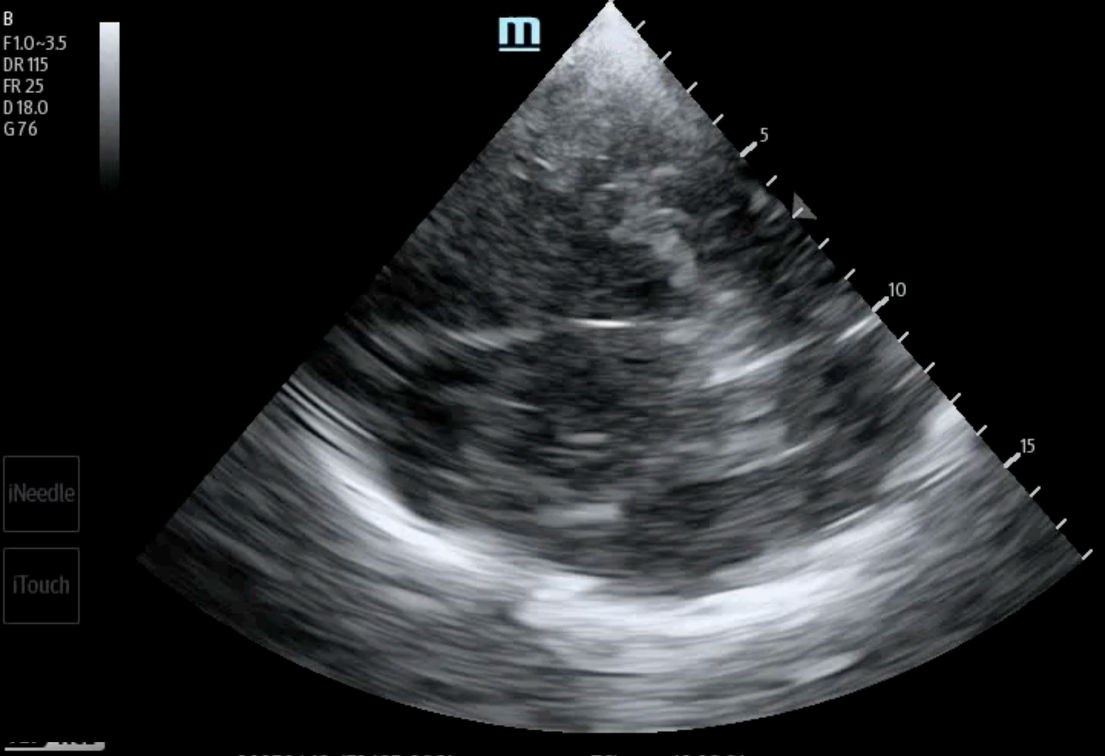
B
F1.0~3.5
DR 115
FR 25
D 18.0
G 76
iNeedle
iTouch
5
10
15
20250418-172635-28C1
TCI
18:38:31
SP5-1s
AP 96.6%
MI 1.35
TIC 1.8

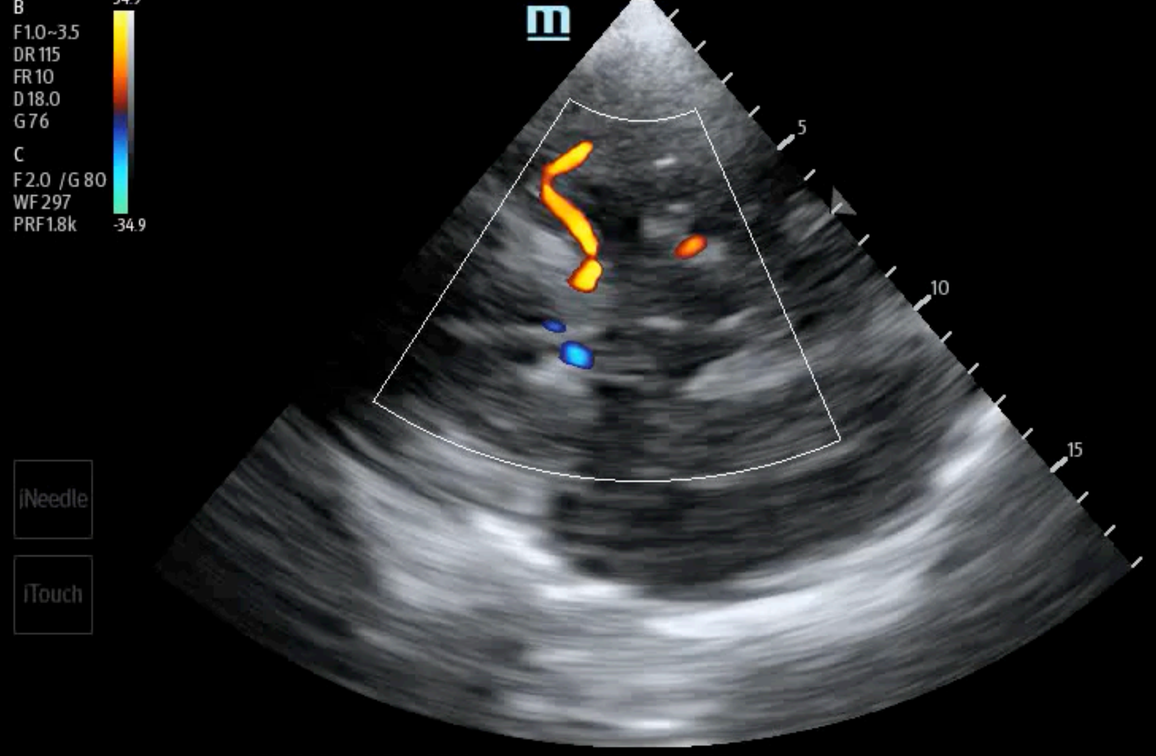
B
F1.0~3.5
DR 115
FR 10
D 18.0
G 76
C
F2.0 /G 80
WF 297
PRF 1.8k
34.9
-34.9
iNeedle
iTouch
5
10
15
20230630-165254-28C1
TCI
17:08:42
SP5-1s
AP 96.6%
MI 0.45
TIC 2.0

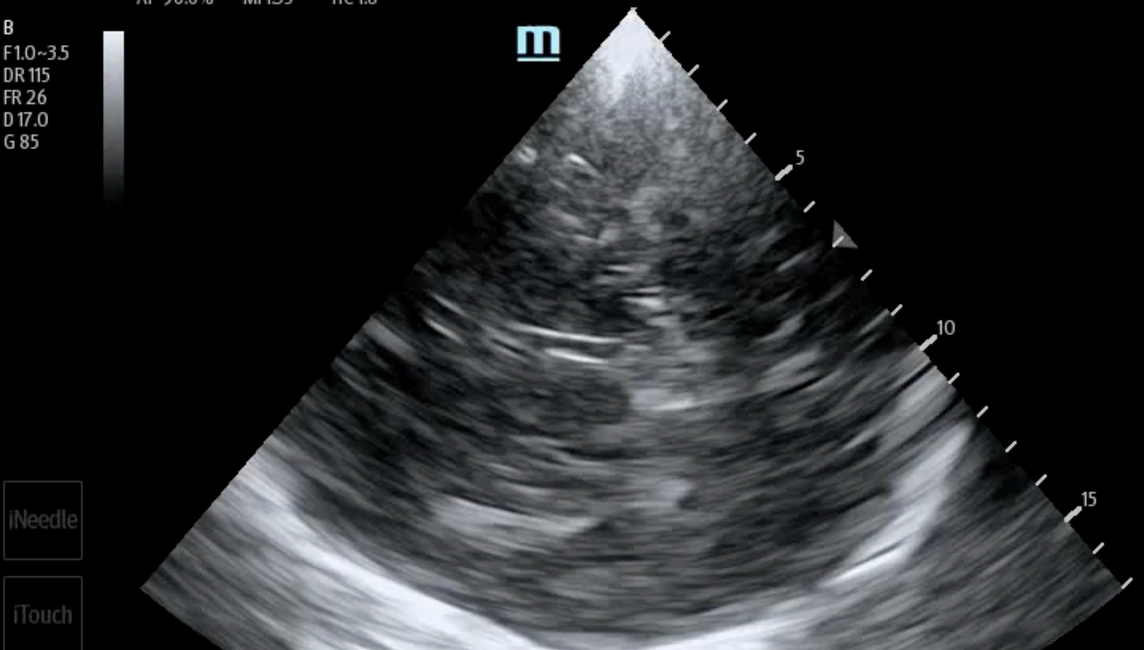
B
F1.0~3.5
DR 115
FR 26
D 17.0
G 85
iNeedle
iTouch
5
10
15

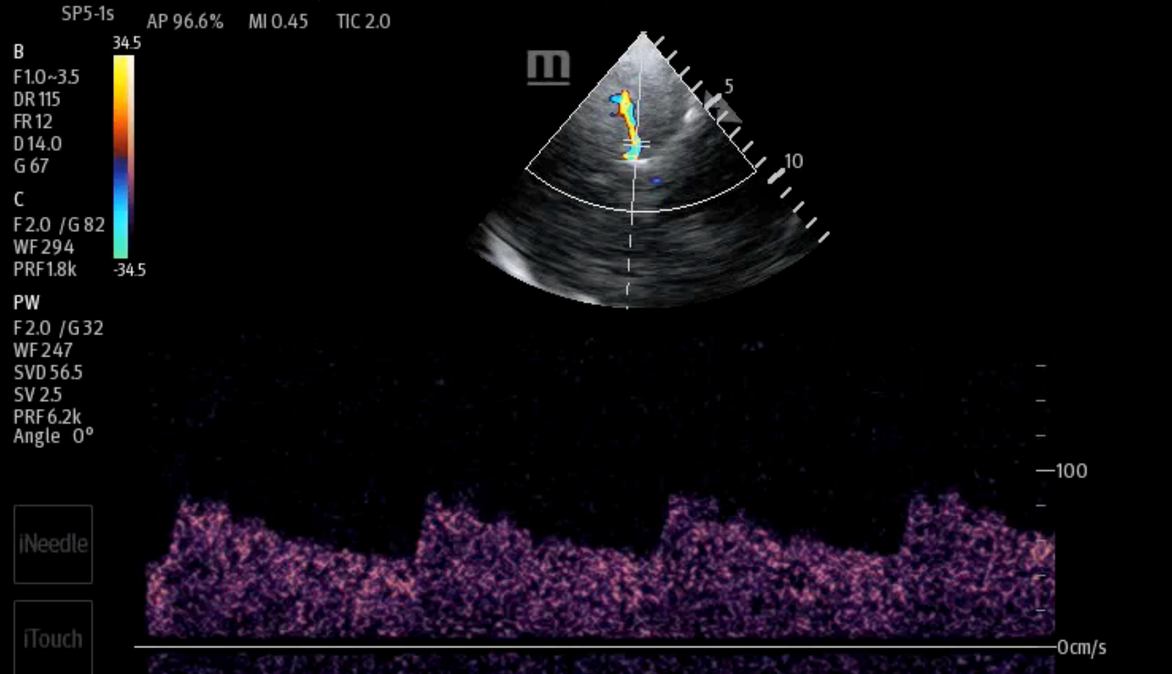
B
F1.0~3.5
DR 115
FR 12
D 14.0
G 67
C
F2.0 /G 82
WF 294
PRF 1.8k
34.5
-34.5
PW
F2.0 /G 32
WF 247
SVD 56.5
SV 2.5
PRF 6.2k
Angle 0°
iNeedle
iTouch
5
10
100
0cm/s